

3-1990

Systemic Dissemination of Pneumocystis Carinii in a Patient with Acquired Immunodeficiency Syndrome

Mahul B. Amin

Michael P. Abrash

Eugene Mezger

Gary F. Sekerak

Follow this and additional works at: <https://scholarlycommons.henryford.com/hfhmedjournal>



Part of the [Life Sciences Commons](#), [Medical Specialties Commons](#), and the [Public Health Commons](#)

Recommended Citation

Amin, Mahul B.; Abrash, Michael P.; Mezger, Eugene; and Sekerak, Gary F. (1990) "Systemic Dissemination of Pneumocystis Carinii in a Patient with Acquired Immunodeficiency Syndrome," *Henry Ford Hospital Medical Journal* : Vol. 38 : No. 1 , 68-71.

Available at: <https://scholarlycommons.henryford.com/hfhmedjournal/vol38/iss1/18>

This Article is brought to you for free and open access by Henry Ford Health System Scholarly Commons. It has been accepted for inclusion in Henry Ford Hospital Medical Journal by an authorized editor of Henry Ford Health System Scholarly Commons.

Systemic Dissemination of *Pneumocystis Carinii* in a Patient with Acquired Immunodeficiency Syndrome

Mahul B. Amin, MD,* Michael P. Abrash, MD,* Eugene Mezger, MD,† and Gary F. Sekerak, MD‡

Pneumocystis carinii is usually considered a respiratory tract pathogen; however, there are reported cases of limited and generalized dissemination of the organism from the lungs of immunocompromised patients. We present the autopsy findings of a 29-year-old male with acquired immunodeficiency syndrome (AIDS) and recurrent *Pneumocystis carinii* pneumonia who developed abnormal liver function tests. The patient had received aerosolized pentamidine because of toxic reactions to other modes of therapy. The postmortem examination revealed *Pneumocystis* in the lungs, liver, spleen, kidney, myocardium, thymus, pancreas, thyroid gland, bilateral parathyroid and adrenal glands, gastrointestinal mucosa, perihilar and mesenteric lymph nodes, and bone marrow. A high index of suspicion, especially in patients treated with aerosolized pentamidine, may lead to an increased recognition of disseminated pneumocystosis. Dissemination of the infection may be due to failure of the aerosolized drug to achieve adequate blood levels. As AIDS patients survive longer because of the developing therapeutic arsenal, disseminated pneumocystosis may be encountered with increasing frequency in these immunocompromised patients. (Henry Ford Hosp Med J 1990;38:68-71)

P*neumocystis carinii* pneumonia (PCP) was a relatively uncommon event, occurring usually in epidemics among malnourished populations or as sporadic infections in immunocompromised patients prior to the onset of acquired immunodeficiency syndrome (AIDS). With an increasing incidence of AIDS, the incidence of PCP has also increased. In about 60% of individuals with AIDS, PCP is an initial manifestation of the disease, while 80% of them will develop one or more episodes during the course of their disease (1).

The organism is usually confined to the respiratory tract, rarely extending beyond its confines to the hilar group of lymph nodes and occasionally to the spleen or liver. Isolated case reports have described limited dissemination of infection to the bone marrow (2), choroid (3), spleen (4), external ear (5,6), middle ear (7), liver (8), small bowel (9), and thyroid (1). Generalized dissemination of *Pneumocystis* (*Pneumocystis* involving multiple organs simultaneously) is exceptional and to our knowledge has thus far been reported at autopsy in only seven cases of AIDS (1,10-15). Earlier reports of generalized disseminated pneumocystosis in non-AIDS immunocompromised patients are also available (16-19).

We present a case of disseminated pneumocystosis in an AIDS patient with recurrent PCP.

Case History

A 29-year-old male was diagnosed with AIDS when he had his first episode of PCP in August 1987. He was hospitalized for a second episode of PCP a year later. Because of toxic reactions to intravenous trimethoprim-sulfamethoxazole (SXT) and pentamidine (rash and renal

toxicity, respectively), he was treated with a 21-day course of aerosolized pentamidine (600 mg/day). After discharge he received aerosolized pentamidine 300 mg every two weeks. His medications included azidothymidine (AZT) which was intermittently interrupted when he developed anemia requiring blood transfusions. A third hospitalization for PCP occurred in January 1989, but only three days after discharge he was readmitted for increasing shortness of breath, weakness, and progressive cough.

Significant physical findings included fever (39°C [102.2°F]), mild dyspnea, cervical adenopathy, and respiratory rhonchi over the left lung base. Chest roentgenogram revealed a diffuse, bilateral reticulonodular infiltrate. Consolidation was severe in the perihilar regions and left mid lung.

Initial laboratory studies revealed leukopenia (leukocyte count 2.6 $10^9/L$ [2,600/ μL], 51% polycytes, 18% bands, 14% lymphocytes, 16% monocytes, 1% eosinophils), hemoglobin 125 g/L (12.5 g/dL), hematocrit 0.36 (36%), and platelet count 10.8 $10^9/L$ (108,000/ μL); serum electrolytes, BUN, creatinine, and glucose were normal. Serum lactic dehydrogenase (617 IU/L), GOT (110 IU/L), GPT (93 IU/L), alkaline phosphatase (4.7 $\mu kat/L$ [279 IU/L]), and GGT (417 IU/L) were elevated. The total serum protein and albumin were 40 g/L (4 g/dL) and 17 g/L (1.7 g/dL), respectively. Blood cultures for aerobic and anaerobic bacteria, fungi, mycobacteria, and viruses revealed no isolates. Bronchial washings revealed no fungi or mycobacteria.

Submitted for publication: December 14, 1989.

Accepted for publication: February 6, 1990.

*Department of Pathology, Henry Ford Hospital.

†Division of Microbiology, Henry Ford Hospital.

‡Department of Internal Medicine, Henry Ford Hospital, Troy Center.

Address correspondence to Dr. Abrash, Department of Pathology, Henry Ford Hospital, 2799 W Grand Blvd, Detroit, MI 48202.

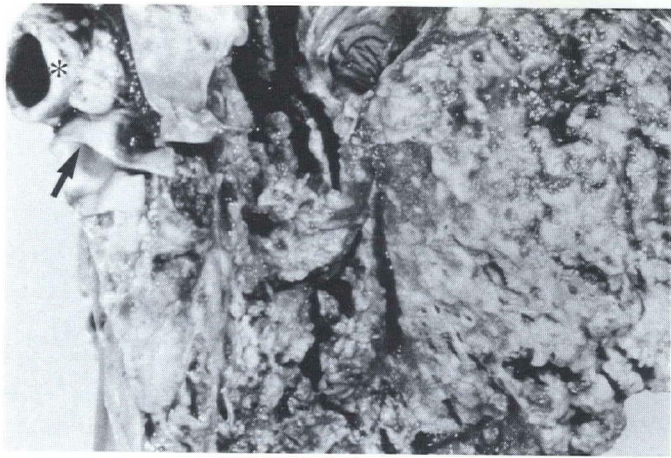

Fig 1—Lung: postfixation, showing mosaic linear pattern of softening and patchy cavitation (the asterisk indicates the major bronchus and the arrow the pulmonary artery).

During the hospitalization, the patient had pancytopenia (WBC count $1.9 \times 10^9/L$ [$1,900/\mu L$], hemoglobin 93 g/L [9.3 g/dL], and platelet count $8.9 \times 10^9/L$ [$89,000/\mu L$]) and received transfusions. At this time, his medications included dapsone, AZT, aerosolized pentamidine, and aspirin. Despite increasing respiratory difficulty, he declined bronchoscopy and open lung biopsy. Associated with the other abnormal liver function tests, he developed prolonged prothrombin time (14 seconds; control 10.5 seconds) and activated partial thromboplastin time (55 seconds; normal range 22 to 36 seconds).

The patient continued to deteriorate and died on the 22nd hospital day. A complete autopsy was performed but permit did not provide for examination of eyes. There was, however, no clinical evidence of retinitis.

Autopsy Findings

Cut surfaces of both lungs revealed a mosaic linear pattern of yellow-gray softening, seemingly in an interstitial pattern with

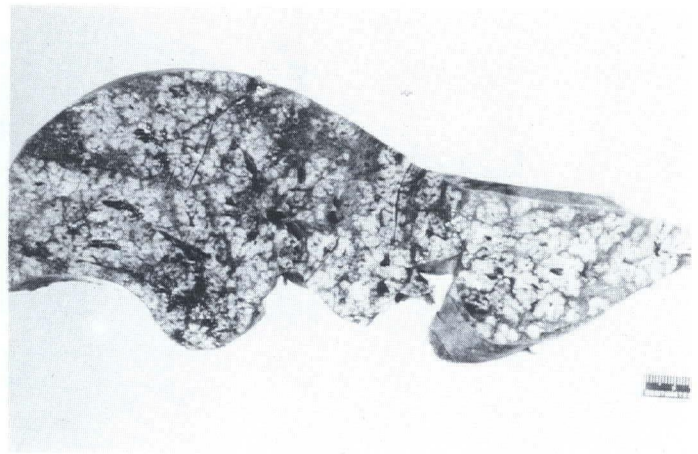

Fig 2—Liver section: postfixation, showing multiple discrete nodules, often coalescent.

patchy cavitation, measuring from less than 1 mm in the right upper lobe and up to 2 cm in the right lower lobe (Fig 1). No normal parenchyma was observed in either lung. Hilar lymph nodes were enlarged and showed similar yellow-gray softening.

Multiple discrete necrotic yellow-gray nodules, often coalescent, each measuring 1 to 3 mm were found in the liver (Fig 2), spleen, pancreas, kidneys, and mesenteric lymph nodes. Bilateral pleural effusions and ascites were also present.

Microscopy

Sections from both lungs showed PCP with confluent areas of necrosis and diffuse alveolar damage (Fig 3). Sections from the heart revealed focal myocytolysis with a distinctive granular exudate devoid of leukocytes (Fig 4). Grocott stains revealed cysts of *Pneumocystis carinii* (Fig 5).

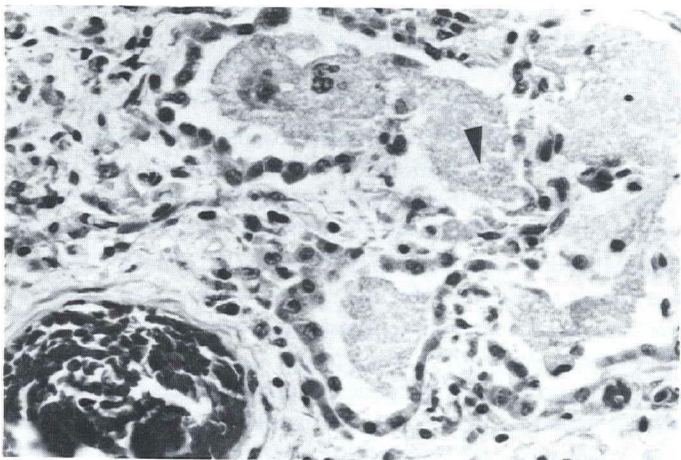


Fig 3—Lung histology showing characteristic granular exudate (arrowhead) within alveoli with pneumocyte hyperplasia (hematoxylin-eosin stain, X100).

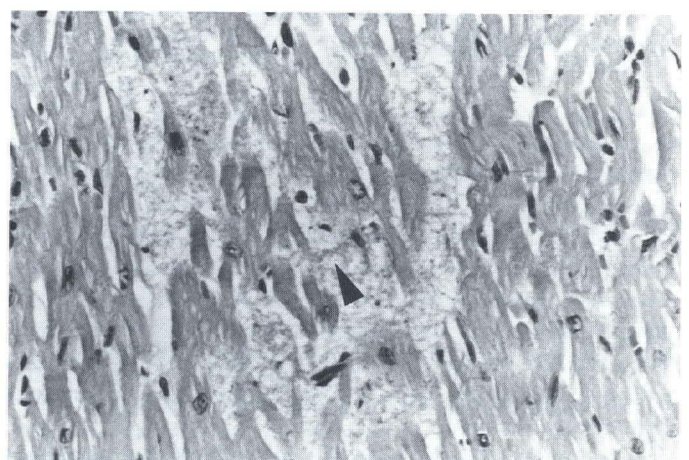


Fig 4—Heart histology: granular exudate (arrowhead) between myocardial fibers (hematoxylin-eosin stain, X66).

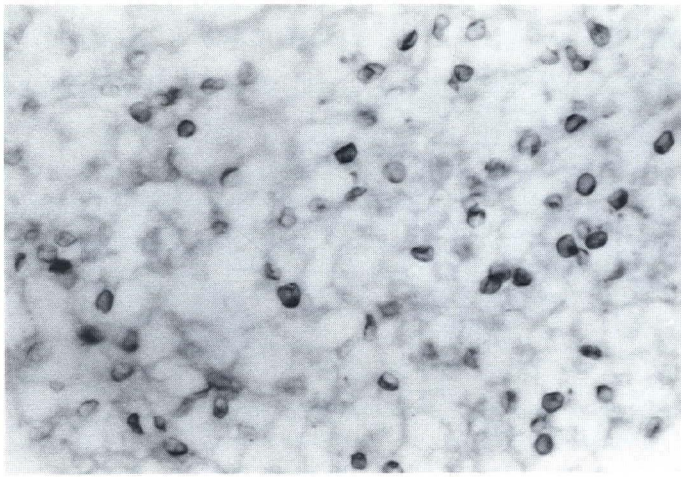


Fig 5—Pulmonary alveolar exudate showing characteristic morphology of *Pneumocystis* cysts (Grocott stain, X200).

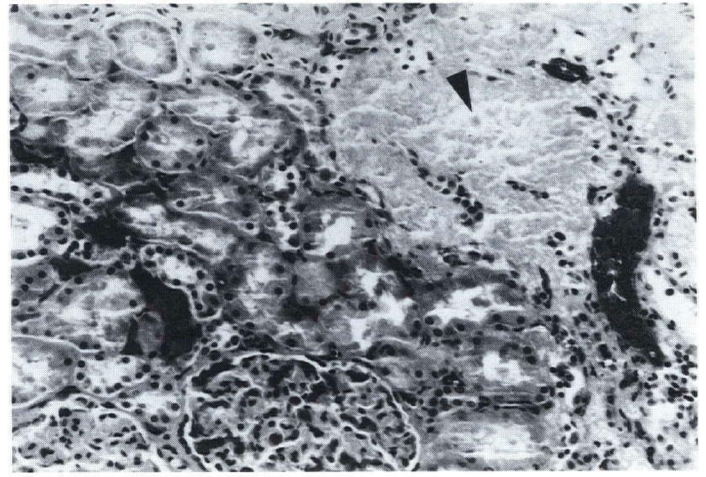


Fig 7—Kidney histology: area of necrosis with characteristic exudate (arrowhead) (hematoxylin-eosin stain, X50).

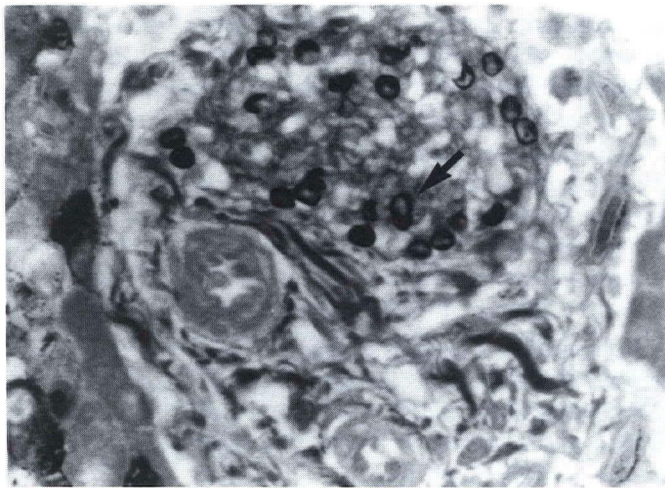


Fig 6—Liver histology: portal triad with characteristic exudate and cysts of *Pneumocystis carinii* (arrow) (Grocott stain, X200).

Sections from necrotic foci in hilar lymph nodes, liver (Fig 6), spleen, kidney (Fig 7), pancreas, and mesenteric lymph nodes revealed finely granular eosinophilic exudate which contained cysts of *Pneumocystis carinii* in Grocott stained sections.

Random sections from the thymus, thyroid gland, parathyroid glands, gastrointestinal mucosa, bone marrow (Fig 8), and both adrenal glands (Fig 9) revealed finely granular eosinophilic exudate. Again, Grocott stain revealed cysts of *Pneumocystis carinii*.

Periodic acid-Schiff and acid-fast stains did not reveal any other organisms. No viral inclusions were recognized. The sections of central nervous system did not show any evidence of *Pneumocystis carinii*. Postmortem cultures of lung and liver tissue provided no bacterial, fungal, or viral isolates.

Discussion

Several questions arise in the analysis of cases of disseminated pneumocystosis. First, why does the organism appear confined to the lungs in most cases? *Pneumocystis carinii* is a saprophyte residing in the lung, and the alveolus is the natural habitat for the organism (20). Owing to the high incidence of PCP in AIDS patients, physicians are prompt in their approach to treat the symptomatic infection. However, the organisms may occasionally find their way to the reticuloendothelial system, from which they may intermittently seed the lungs (4). This local spread may partially explain the high rate of recurrence of PCP.

Second, what factors predispose to dissemination of the organism? All answers are only speculation. A constant feature in most cases of disseminated disease has been recurrence of PCP. Pulmonary interstitial invasion and vascular invasion may result in an aggressive form of the disease which results in dissemination (2,10). In our case, vascular invasion was not demonstrated morphologically but presumably had occurred. Reported geographic differences in occurrence of dissemination may be interpreted as representing strain differences (13). The theory that surgical manipulation (resection or biopsy) of infected lungs might explain dissemination (2,17) cannot account for all cases, including ours. If indeed surgery is a mechanism for dissemination, the risk must be low, given the large numbers of AIDS patients who have had lung biopsies. Inability to completely eradicate the *Pneumocystis* infection must be an important factor. In our case, toxic reactions to intravenous pentamidine and SXT led to treatment with aerosolized pentamidine. The aerosol route does not achieve systemic therapeutic levels reached with other routes of administration of pentamidine (21,22). This failure may be a key issue in the use of aerosolized pentamidine as a form of prophylactic therapy. Oral dapsone was administered briefly. Clinical trials with dapsone indicate that it is effective for *Pneumocystis* in only about half of the patients. Dapsone plus trimethoprim is considerably more effective (21,22).

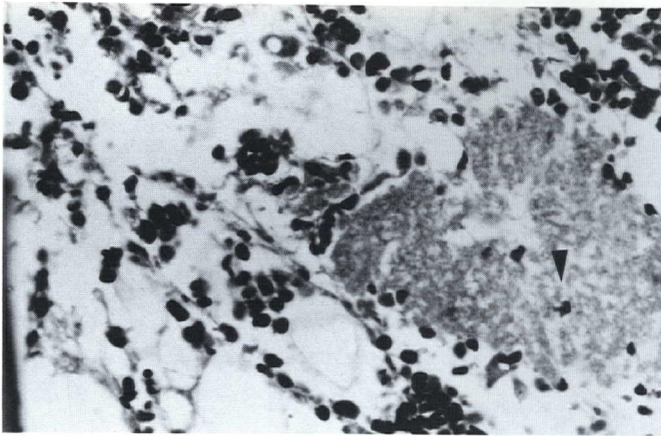


Fig 8—Bone marrow histology: characteristic exudate (arrowhead) amidst native hematopoietic cells and marrow fat (hematoxylin-eosin stain, X100).

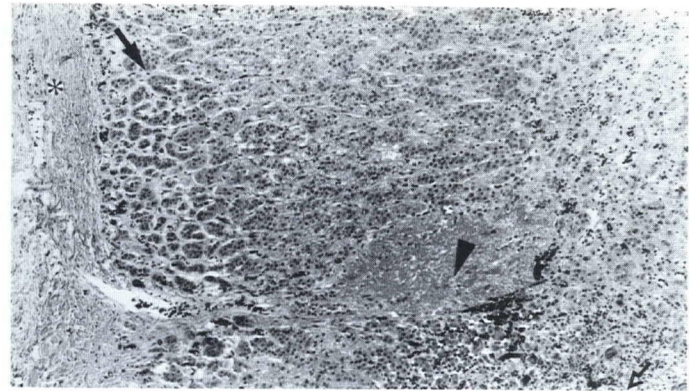


Fig 9—Adrenal gland histology: characteristic exudate (arrowhead) in the cortex (the solid arrow indicates the adrenal cortex, the hollow arrow the adrenal medulla, and the asterisk indicates the capsule) (hematoxylin-eosin stain, X100).

Finally, what are the clues that indicate dissemination? When abnormal liver or renal function tests are encountered, disseminated pneumocystosis should be considered as a differential diagnosis along with other opportunistic infections, such as cytomegalovirus, histoplasmosis, or toxoplasmosis.

Including our case with the other seven reported permits these conclusions:

1. All cases of disseminated pneumocystosis had recognizable lesions at autopsy. Microscopically, inflammatory infiltrate was notably absent (gross and microscopic features of two cases were not described in detail).

2. The central nervous system is conspicuously spared. However, cysts were detected in the Virchow-Robin space in one case (13) and in the pituitary in another (15).

3. Antemortem diagnosis, made in one case only, was based on esophageal and duodenal biopsies (10).

Disseminated pneumocystosis is a distinct but rarely recognized entity. As the incidence of AIDS increases, an increased incidence of such cases is anticipated. "High risk" cases include those with recurrent PCP, whose therapy has been limited to aerosolized pentamidine, who have pulmonary interstitial and vascular invasion, and spread to hilar lymph nodes. Heightened surveillance of patients with abnormal organ function tests and a high index of suspicion while interpreting histologic material from high risk cases may result in increased recognition.

Our case raises the issue of whether or not aerosol pentamidine therapy, producing suboptimal systemic levels, may have allowed dissemination of the organism.

References

1. Gal AA, Koss MN, Strigle S, Angritt P. Pneumocystis carinii infection in the acquired immune deficiency syndrome. *Semin Diagn Pathol* 1989;6:287-99.
2. Heyman MR, Rasmussen P. Pneumocystis carinii involvement of the bone marrow in acquired immunodeficiency syndrome. *Am J Clin Pathol* 1987;87:780-3.
3. Kwok S, O'Donnell JJ, Wood IS. Retinal cotton-wool spots in a patient with Pneumocystis carinii infection. *N Engl J Med* 1982;307:184-5.
4. Pilon VA, Echols RM, Celo JS, Elmendorf SL. Disseminated Pneumocystis carinii infection in AIDS (Letter). *N Engl J Med* 1987;316:1410-1.

5. Coulman CU, Greene I, Archibald RWR. Cutaneous pneumocystosis. *Ann Intern Med* 1987;106:396-8.
6. Schinella RA, Breda SD, Hammerschlag PE. Otic infection due to Pneumocystis carinii infection in an apparently healthy man with antibody to the human immunodeficiency virus. *Ann Intern Med* 1987;106:399-400.
7. Smith MA, Hirschfield LS, Zahtz G, Siegal FP. Pneumocystis carinii otitis media. *Am J Med* 1988;85:745-6.
8. Saldana MJ, Mones JM. Cavitation and other atypical manifestations of Pneumocystis carinii pneumonia. *Semin Diagn Pathol* 1989;6:273-86.
9. Carter TR, Cooper PH, Petri WA Jr, Kim CK, Walzer PD, Guerrant RC. Pneumocystis carinii infection of the small intestine in a patient with acquired immune deficiency syndrome. *Am J Clin Pathol* 1988;89:679-83.
10. Grimes MM, LaPook JD, Bar MH, Wasserman HS, Dwork A. Disseminated Pneumocystis carinii infection in a patient with acquired immunodeficiency syndrome. *Hum Pathol* 1987;18:307-8.
11. Steigman CK, Pastore L, Park CH, et al. AIDS case for diagnosis series, 1987. *Milit Med* 1987;152:M1-8.
12. Afessa B, Green WR, Williams WA, et al. Pneumocystis carinii pneumonia complicated by lymphadenopathy and pneumothorax. *Arch Intern Med* 1988;148:2651-4.
13. Unger PD, Rosenblum M, Krown SE. Disseminated Pneumocystis carinii infection in a patient with acquired immunodeficiency syndrome. *Hum Pathol* 1988;19:113-6.
14. Macher AM, Bardenstein DS, Zimmerman LE, Steigman CK. Pneumocystis carinii choroiditis in a male homosexual with AIDS and disseminated pulmonary and extrapulmonary P. carinii infection (Letter). *N Engl J Med* 1987;316:1092.
15. Cote RJ, Rosenblum M, Telzak EE, May M, Unger P, Cartun RW. Disseminated Pneumocystis carinii infection causing extrapulmonary organ failure: Clinical, pathologic, and immunohistochemical analysis. *Mod Pathol* 1990;3:25-30.
16. Jarnum S, Rasmussen EF, Ohlsen AS, Sorensen AW. Generalized Pneumocystis carinii infection with severe idiopathic hypoproteinemia. *Ann Intern Med* 1968;68:138-45.
17. LeGolvan DP, Heidelberg KP. Disseminated granulomatous Pneumocystis carinii pneumonia. *Arch Pathol* 1973;95:344-8.
18. Rahimi SA. Disseminated Pneumocystis carinii in thymic aplasia. *Arch Pathol* 1974;97:162-5.
19. Awen CF, Baltzan MA. Systemic dissemination of Pneumocystis carinii pneumonia. *Can Med Assoc J* 1971;104:809-12.
20. Dutz W. Pneumocystis carinii infection and interstitial plasma cell pneumonia: What does history teach? *Semin Diagn Pathol* 1989;6:195-202.
21. Masur H, Kovacs JA. Treatment and prophylaxis of Pneumocystis carinii pneumonia. *Infect Dis Clin North Am* 1988;2:419-28.
22. Fischl MA. Treatment and prophylaxis of Pneumocystis carinii pneumonia. *AIDS* 1988;2(suppl 1):S143-50.