

9-1989

Localization of Metastases from Medullary Thyroid Carcinoma Using Different Methods

Rosa C. Cabezas

Luis Berna

Montserrat Estorch

Ignacio Carrio

Angeles Garcia-Ameijeiras

Follow this and additional works at: <https://scholarlycommons.henryford.com/hfhmedjournal>



Part of the [Life Sciences Commons](#), [Medical Specialties Commons](#), and the [Public Health Commons](#)

Recommended Citation

Cabezas, Rosa C.; Berna, Luis; Estorch, Montserrat; Carrio, Ignacio; and Garcia-Ameijeiras, Angeles (1989) "Localization of Metastases from Medullary Thyroid Carcinoma Using Different Methods," *Henry Ford Hospital Medical Journal* : Vol. 37 : No. 3 , 169-172.

Available at: <https://scholarlycommons.henryford.com/hfhmedjournal/vol37/iss3/25>

This Article is brought to you for free and open access by Henry Ford Health System Scholarly Commons. It has been accepted for inclusion in Henry Ford Hospital Medical Journal by an authorized editor of Henry Ford Health System Scholarly Commons.

Localization of Metastases from Medullary Thyroid Carcinoma Using Different Methods

Rosa C. Cabezas,* Luis Berna,† Montserrat Estorch,† Ignacio Carrio,† and Angeles Garcia-Ameijeiras*

We analyzed the efficiency of three different noninvasive methods in the localization of recurrent medullary thyroid carcinoma (MTC). Nine patients (six females and three males) with biochemical evidence of disease after primary surgery were subjected to ¹³¹I anti-carcinoembryonic antigen (anti-CEA) antibody, ¹³¹I meta-iodo-benzylguanidine (MIBG), and computed tomography. Another female patient, in biochemical remission for six years after initial surgery, was also studied using the same methods. Three of the ten patients had negative results with all three methods (including the patient in remission). The other seven patients showed abnormal uptake of labeled anti-CEA antibody in various localizations; only two of these patients had a corresponding pathological image by computed tomography and only one by ¹³¹I MIBG. These preliminary results suggest that ¹³¹I anti-CEA scanning may be the most sensitive noninvasive method for the localization of MTC recurrences. (Henry Ford Hosp Med J 1989;37:169-72)

Medullary thyroid carcinoma (MTC) patients, both hereditary and sporadic, often have clinical and biochemical evidence of disease recurrence after primary surgery (1-3). Since surgery is the effective therapy for the disease (4-6) (either primary or secondary), localization of the cancer tissue and its dissemination is of primary importance.

Several localization methods have been used, from conventional plain chest roentgenograms to computed tomography and ¹³¹I meta-iodo-benzylguanidine (MIBG) scans, with variable degrees of efficiency (7-13). Some authors have also advocated the use of invasive techniques, such as venous catheterization, but this limits the areas studied and hence metastases in unsuspected organs may be missed (14).

Since all forms of MTC are known to express and secrete carcinoembryonic antigen (CEA) (15,16) and labeled monoclonal antibodies against it have been developed for human scintiscanning, we studied the ability of such an antibody to detect the presence of recurrent MTC and compared the results with those obtained in the same patients using ¹³¹I MIBG and computed tomography as the means of detection. Previous studies (17,18) have shown that ¹³¹I anti-CEA antibodies were useful for the detection of MTC, although the number of patients studied was small.

Patients

The patients' data are summarized in Table 1. We studied ten patients, seven females and three males, with mean ages of 42.14 ± 11.79 years and 46.33 ± 3.05 years, respectively. The follow-up period averaged 7.19 ± 4.09 years. All patients except case 9 had neck surgery for MTC; one of these patients had

a sternotomy a few months before the tests were performed. Case 9's MTC was diagnosed by family screening; she had ¹³¹I anti-CEA scanning prior to surgery. On physical examination the thyroid gland was considered normal. Bilateral microscopic foci of MTC, with positive immunostaining for CEA, were found in the thyroid. Two patients (cases 6 and 8) had external neck radiation after initial surgery. Calcitonin (CT) was elevated in all patients except case 10, and five patients had high levels of CEA. Three patients had hereditary MTC, whereas the other six had an apparently sporadic form of MTC. None was diagnosed as having multiple endocrine neoplasia type 2.

Materials and Methods

CT measurements were performed by radioimmunoassay using a commercial kit (Calcitonin II RIA, Incstar Corporation, Stillwater, MN). CT stimulation tests were performed as described previously (19). For the ¹³¹I anti-CEA and the ¹³¹I MIBG scans, the patients had thyroid remnant blockage with Lugol drops for a total of nine days, starting two days prior to the injection of the labeled compound. Potassium perchlorate (1 g orally) was administered two hours prior to the injection and every 12

Submitted for publication: September 30, 1989.

Accepted for publication: October 20, 1989.

*Division of Endocrinology and Metabolism, Hospital Santa Creu i Sant Pau, Barcelona, Spain.

†Division of Nuclear Medicine, Hospital Santa Creu i Sant Pau, Barcelona, Spain.

Address correspondence to Dr. Cabezas, Division of Endocrinology and Metabolism, Hospital Santa Creu i Sant Pau, Avda. S. Antonio Ma Claret 165, Barcelona 08025, Spain.

Table 1
Descriptive Data of All Patients

Case	Age at Diagnosis	Sex	Basal CT (pg/mL)	Poststimulatory CT Peak (pg/mL)	CEA μ g/L
1	49	M	280	915	<2.5
2	53	F	300	868	5.85
3	43	M	>500	9,954	94.25
4	47	M	>10,000	—	6.6
5	55	F	689	—	11.15
6	46	F	315	—	1
7	47	F	481	852	30.72
8	32	F	311	—	2.85
9	22	F	63	500	2.5
10	40	F	Undetectable	Undetectable	<2.5

Normal CT levels are \leq 100 pg/mL for males and \leq 45 to 50 pg/mL for females. Normal poststimulatory CT levels are \leq 500 pg/mL for males and \leq 200 pg/mL for females. Normal CEA is $<$ 5 μ g/L.

hours (250 mg) for seven days thereafter. The ^{131}I anti-CEA scans were performed with 1 mg of the $\text{F(ab}')_2$ fraction of anti-CEA monoclonal antibody (Sorin, Biomedica, Italy) injected intravenously. Whole body planar scans were taken at two, five, and seven days postinjection in anterior and posterior projections, using a conventional large field of view camera with a high energy collimator, 20% w centered on a 360 Kev peak. Analog and digital images of 500 K counts each collected on a 128 X 128 matrix were stored for subsequent analysis.

Within 15 days of the ^{131}I anti-CEA scan, and using a similar procedure, whole body planar scans at 24, 48, and 72 hours after intravenous administration of 1 mCi of ^{131}I MIBG were obtained in eight patients.

Cervical, thoracic, and abdominal computed tomography scans were performed in nine patients on a Siemens Somatom whole body scanner, operating at 125 Kvp and 230 mAs, with a 5 second scan time and at 8 mm slice thickness.

Results

^{131}I anti-CEA

Best results were obtained in the studies performed seven days after the intravenous injection. Case 10, who had been in biochemical remission for six years, had a normal scintiscan, whereas seven of nine patients with active disease had pathological uptake (Table 2). One such abnormal scan is shown in Fig 1. Three patients had abnormal uptake in the cervical area, one in the bilateral superior mediastinum and low cervical bed, one bilaterally in the mediastinum, and two in the left mediastinum (Fig 2). These results are summarized in Table 2. Case 3 had the tests performed on two occasions within ten months, and the results were identical on all occasions.

^{131}I MIBG

Only two of the eight patients studied had abnormal uptakes: one patient had a positive uptake in the cervical area, which was also observed in the ^{131}I anti-CEA study, and the other patient had an abnormal right paracardiac uptake which in subsequent reviews was thought to be an artifact. This patient also had a left

Table 2
Results of MTC Localization Techniques

Case	Anti-CEA	Computed Tomography	MIBG	Surgery
1	+ LM	Normal	Normal	Not Done
2	Normal	Normal	Normal	Not Done
3	+ BM	+ BM	Not Done	(+)
4	+ Neck BM	+ Neck BM	Normal	(+)
5	+ Neck	Normal	Normal	Not Done
6	+ Neck	Normal	+ Neck	Not Done
7	+ LM	Normal	Normal	Not Done
8	Normal	+ (subpleural L Nodule)	+ (R paracardiac uptake)	Not Done
9	+ Neck	Not Done	Not Done	(+)
10	Normal	Normal	Normal	—

R = right, L = left, B = bilateral, and M = mediastinum.

subpleural nodule detected by computed tomography which was not considered tumoral.

None of the patients had any adverse reactions to the administered radiolabeled compounds.

Computed tomography

Two of nine patients who had computed tomography scans had pathological images compatible with metastases in the paratracheal and infraclavicular nodes. Both had abnormal ^{131}I anti-CEA uptake in the same areas.

Other data

Three of seven patients with abnormal ^{131}I anti-CEA uptake have had surgery. Immunohistochemical analysis of the resected tissues confirmed the presence of MTC in each. Complete normalization of the CT and CEA levels was observed after surgery in only one of these three patients; one patient is awaiting right thoracotomy and the other has had a decrease of the CT levels postoperatively. One patient has refused surgery or any other invasive procedure, and another preferred external radiation when offered by a physician from another institution. The other remaining patients are awaiting surgery.

Discussion

Early detection of recurrent MTC is of primary importance since the patients' prognosis invariably worsens with the advance of the disease (15,19,20), which is partly due to the lack of effective therapy other than surgery (21,22). It is important to realize that between 50% and 70% of MTC patients already have metastases at the time of diagnosis and that approximately 50% will develop them thereafter (2-4).

Detection of primary and recurrent disease is now possible through the determinations of basal and/or poststimulatory levels of CT (1,2,19). High postoperative levels of CT are considered clear evidence of persistence of the disease, especially when an exaggerated response to the conventional secretagogues (either pentagastrin alone or pentagastrin combined

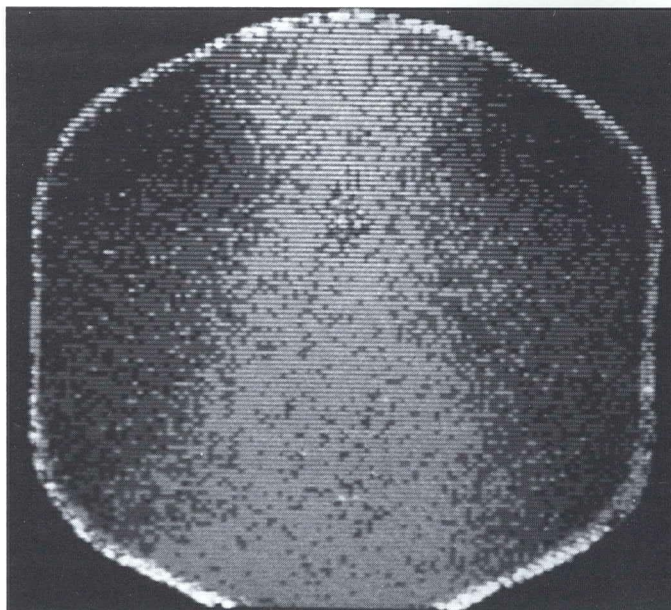


Fig 1—Anterior view of a ^{131}I anti-CEA scan showing uptake in a local neck recurrence 11 years after surgery.

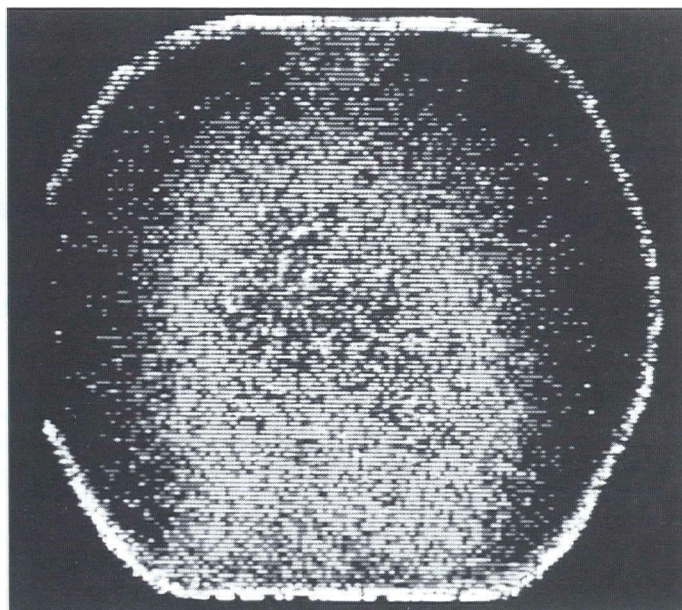


Fig 2— ^{131}I anti-CEA scan (posterior view) showing uptake in mediastinal nodes.

with calcium) is observed. In our experience, high basal or poststimulatory levels of CT after surgery (in serum obtained as early as one week after initial thyroidectomy) were always followed by increasing CT levels in the subsequent determinations, which strongly suggests persistence of disease.

Although diagnosis of disease persistence is currently possible, localization of the metastases and, possibly more important, determination of the extent of the disease have proved to be difficult in many cases. Previous reports have suggested that ^{131}I MIBG is a useful tool for detection of MTC (7-13). However, others have found poor sensitivity of the technique (18). In our study (Table 2), only one of eight patients had an abnormal ^{131}I MIBG uptake (case 8's results proved to be false-negative). Two patients had the test performed on more than one occasion within a two-year period with identical results.

Eight of nine patients with biochemical evidence of active MTC had computed tomography scans performed (some on multiple occasions), but tumor localization was possible in only two of these patients. Since our computed tomography studies were performed at 8 mm cuts, smaller metastases may have been missed; two of our patients had multiple nodes that were not detected by this technique, presumably because of their small size. Identification of normal neck structures can be difficult in cervical computed tomography scanning after certain types of procedures are done.

In our study ^{131}I anti-CEA $\text{F}(\text{ab}')_2$ antibody fragment proved to be the most sensitive technique. Although only a small number of patients were studied and we lack histologic proof in all cases, our results suggest that this technique may be valuable in the localization of MTC sites. In case 9, who has normal CEA values and the hereditary type of MTC diagnosed by family

screening, the ^{131}I anti-CEA uptake was positive only in the cervical area. No macroscopic thyroid nodules were seen at thyroidectomy. Her CT levels remained undetectable postoperatively. Results in this patient indicate that even microscopic MTC can be detected by ^{131}I anti-CEA scanning. It could be argued that the remaining normal thyroid had accumulated free ^{131}I . However, the administration of ^{131}I blocking agents prior to and during the seven days of the test would have prevented the uptake by the normal thyroid. We have used the same procedure as that used in gastrointestinal cancer patients whose thyroid glands are intact and in whom free ^{131}I thyroid uptake is not seen.

Case 10, who was in biochemical and clinical remission for six years, had a negative ^{131}I anti-CEA uptake. Although this may indicate that the test is reliable with respect to negative results, the lack of uptake in cases 2 and 8 (both with moderately elevated CT levels) refutes this assumption. Whether the patients who showed uptake in some areas did not have other, as yet undetected, metastases remains to be seen. Of the three patients operated on, one still shows inexplicably high CT levels, although the ^{131}I anti-CEA results are negative. No false-positive results for this test have been found. Since not all patients have had surgery, no firm conclusion can yet be made.

Although we have not observed any adverse reactions in the patients studied, this possibility cannot be excluded. Since the test may be repeated several times, it is possible that some patients may develop blocking anti-idiotypic antibodies against the $\text{F}(\text{ab}')_2$ anti-CEA fragment rendering it inactive.

Our results suggest that, of the three techniques studied, ^{131}I anti-CEA screening is the most sensitive and promising technique, although studies in larger patient populations are needed.

Acknowledgments

We thank Mrs. Angeles Rodriguez for her secretarial assistance.

This work was supported by FISS grants 87/927 and 89/0023.

References

1. Graze K, Spiler II, Tashjian AH Jr, et al. Natural history of familial medullary thyroid carcinoma: Effect of a program for early diagnosis. *N Engl J Med* 1978;299:980-5.
2. Saad MF, Ordonez NG, Rashid RK, et al. Medullary carcinoma of the thyroid: A study of the clinical features and prognostic factors in 161 patients. *Medicine* 1984;63:319-42.
3. Chong GC, Beahrs OH, Sizemore GW, Woolner LH. Medullary carcinoma of the thyroid gland. *Cancer* 1975;35:695-704.
4. Russell CF, Van Heerden JA, Sizemore GW, et al. The surgical management of medullary thyroid carcinoma. *Ann Surg* 1983;197:42-8.
5. Norton JA, Doppman JL, Brennan MF. Localization and resection of clinically inapparent medullary carcinoma of the thyroid. *Surgery* 1980;87:616-22.
6. Tisell LE, Hausson G, Jansson S, Salander H. Reoperation in the treatment of asymptomatic metastasizing medullary thyroid carcinoma. *Surgery* 1986;99:60-6.
7. Endo K, Shiomi K, Kasagi K, et al. Imaging of medullary thyroid cancer with ¹³¹I-MIBG. *Lancet* 1984;2:233.
8. Connell JMC, Hilditch TE, Elliot A, Semple PF. I-131-MIBG and medullary carcinoma of the thyroid (Letter). *Lancet* 1984;2:1273-4.
9. Sone T, Fukunaga M, Otsuka N, et al. Metastatic medullary thyroid cancer: Localization with iodine-131 metaiodobenzylguanidine. *J Nucl Med* 1985;26:604-8.
10. Ansari AN, Siegel ME, De Quattro V, Gazarian LH. Imaging of medullary thyroid carcinoma and hyperfunctioning adrenal medulla using iodine-131 metaiodobenzylguanidine. *J Nucl Med* 1986;27:1858-60.
11. Baulieu JL, Guilloteau D, Delisle MJ, et al. Radioiodinated metaiodobenzylguanidine uptake in medullary thyroid cancer: A French cooperative study. *Cancer* 1987;60:2189-94.
12. Perdriset R, Rohmer V, Lejeune JJ, Bigorgne JC, Jallet P. Thyroid uptake of MIBG in Sipple's syndrome. *Eur J Nucl Med* 1988;14:37-8.
13. Guilloteau D, Baulieu JL, Besuard JC. Medullary thyroid carcinoma imaging in an animal model: Use of radiolabeled anticalcitonin F(ab')₂ and meta-iodobenzylguanidine. *Eur J Nucl Med* 1985;11:198-200.
14. Mrad MDB, Gardet P, Roche A, et al. Value of venous catheterization and calcitonin studies in the treatment and management of clinically inapparent medullary thyroid carcinoma. *Cancer* 1989;63:133-8.
15. Schroder S, Bocker W, Baisch H, et al. Prognostic factors in medullary thyroid carcinomas: Survival in relation to age, sex, stage, histology, immunocytochemistry, and DNA content. *Cancer* 1988;61:806-16.
16. Rougier PV, Calmettes C, Laplanche A, et al. The values of calcitonin and carcinoembryonic antigen in the treatment and management of nonfamilial medullary thyroid carcinoma. *Cancer* 1983;51:855-62.
17. Berche C, Mach JP, Lumbroso JD, et al. Tomoscintigraphy for detecting gastrointestinal and medullary thyroid cancers: First clinical results using radiolabelled monoclonal antibodies against carcinoembryonic antigen. *Br Med J* 1982;285:1447-51.
18. Hoefnagel CA, Delprat CC, Zauw D, van Der Schoot JB. New radio-nuclide tracers for the diagnosis and therapy of medullary thyroid carcinoma. *Clin Nucl Med* 1988;13:159-65.
19. Wells S Jr, Baylin SB, Leight GS, Dale JK, Dilley WG, Farndon JR. The importance of early diagnosis in patients with hereditary medullary thyroid carcinoma. *Ann Surg* 1982;195:595-9.
20. Hay ID. Prognostic factors in thyroid carcinoma. *Thyroid Today* 1989;12:1-9.
21. Samaan NA, Schultz PN, Hickey RC. Medullary thyroid carcinoma: Prognosis of familial versus sporadic disease and the role of radiotherapy. *J Clin Endocrinol Metab* 1988;67:801-5.
22. Kvoles LK, Buck M. Chemotherapy of endocrine malignancies: A review. *Semin Oncol* 1987;14:343-53.