

9-1989

The Importance of Screening for Medullary Thyroid Carcinoma in Families of Patients with MEN 2

A. Frilling

P. E. Goretzki

L. Bastian

H. D. Roeher

Follow this and additional works at: <https://scholarlycommons.henryford.com/hfhmedjournal>



Part of the [Life Sciences Commons](#), [Medical Specialties Commons](#), and the [Public Health Commons](#)

Recommended Citation

Frilling, A.; Goretzki, P. E.; Bastian, L.; and Roeher, H. D. (1989) "The Importance of Screening for Medullary Thyroid Carcinoma in Families of Patients with MEN 2," *Henry Ford Hospital Medical Journal* : Vol. 37 : No. 3 , 122-123.

Available at: <https://scholarlycommons.henryford.com/hfhmedjournal/vol37/iss3/10>

This Article is brought to you for free and open access by Henry Ford Health System Scholarly Commons. It has been accepted for inclusion in Henry Ford Hospital Medical Journal by an authorized editor of Henry Ford Health System Scholarly Commons.

The Importance of Screening for Medullary Thyroid Carcinoma in Families of Patients with MEN 2

A. Frilling,* P.E. Goretzki,* L. Bastian,* and H.D. Roehrer*

Family screening for medullary thyroid cancer (MTC) is important for detecting members of multiple endocrine neoplasia type 2 (MEN 2) families who may be gene carriers but show no clinical evidence of the disease. Most members of our MEN 2 families are screened yearly by measuring basal and pentagastrin-stimulated calcitonin (CT) levels. A 15-year-old first-degree relative of an affected member of the D-kindred showed a normal basal and an elevated stimulated CT level. Clinical examination, ultrasonography, and scintigraphy were normal. Thyroidectomy and bilateral neck dissection revealed a multicentric MTC with no lymph node involvement. In the O-kindred we detected elevated basal and/or stimulated CT levels in three asymptomatic first-degree relatives. At surgery we found a small multicentric MTC in one family member, C-cell hyperplasia in another member, and bilateral lymph node metastases in one member who had been previously thyroidectomized. Basal and stimulated CT estimations in MEN 2 family members provide an effective method for detecting MTC in early, treatable stages. (Henry Ford Hosp Med J 1989;37:122-3)

Medullary thyroid carcinoma (MTC) occurs in about 25% of patients in the hereditary form (1,2). Prospective screening for hereditary MTC began in 1969 when Melvin et al (1,3) performed studies on the J-kindred. Clinical penetrance of the multiple endocrine neoplasia type 2 (MEN 2) gene has been shown to be incomplete in that less than 100% of gene carriers will show clinical symptoms (4,5). Measurement of basal and stimulated calcitonin (CT) and carcinoembryonic antigen (CEA) in serum allows detection of affected subjects (6-10). Because surgery is the only effective therapeutic procedure and only patients in occult tumor stage can be treated curatively, family screening for MTC is of great importance. This study presents the results of screening in two MEN 2 families.

Case Reports

Case 1

MTC, pheochromocytoma, and Hirschsprung's disease have been known to occur in the D-kindred since 1979. This 16-year-old male had a segmental colon resection at age 1 year and a subtotal colectomy for Hirschsprung's disease at age 3 years. The patient's mother had a thyroidectomy in 1983 for a MTC, and screening for MTC was performed yearly on the patient thereafter. The mother's brother, two sisters, and the son of one sister have had MTC and pheochromocytomas. Two sons of the other affected sister have had MTC and Hirschsprung's disease. Basal and pentagastrin-stimulated CT levels and CEA were within the normal range (CT < 100 pg/mL, CEA < 5 ng/mL) until 1986 when CT had increased to 186 pg/mL basally and to 944 pg/mL after pentagastrin stimulation (0.5 µg/kg body weight). The CEA was 13.5 ng/mL (Figure). Physical examination, ultrasonography, and scintigraphy were normal. The patient underwent total thyroidectomy and bilateral modified neck dissection, and histologic study showed a multifocal MTC without metastases to the cervical nodes. Postoperatively the basal and stimulated CT levels have been normal (Figure).

Case 2

This 26-year-old female is a member of the O-kindred with MEN 2A. In 1977 she had atrial septal defect surgery. She has had recurrent kidney stones since 1981. Parathyroid hormone (PTH) and calcium blood levels were elevated to 1.05 ng/mL and 6.4 mmol/mL, respectively (normal range less than 0.55 ng/mL and 4.9 mmol/mL, respectively). Attempts to localize a parathyroid adenoma by computed tomography were unsuccessful, and the patient had neck exploration and removal of a parathyroid adenoma in 1986. Postoperatively PTH and calcium decreased to normal. In 1987 the patient developed palpitations with tachycardia but her blood pressure was normal. Her plasma epinephrine level was elevated to 416 ng/L (normal 90 to 130 ng/L) and urinary excretion of vanillylmandelic acid was 66 mg/day (normal less than 7.5 mg/day). The basal CT level was 54 pmol/L (normal less than 100 pmol/L) and increased to a peak value of 581 pmol/L after pentagastrin. The CEA was within the normal range. Computed tomography confirmed bilateral adrenal masses. Bilateral pheochromocytomas were removed first and thyroidectomy and bilateral modified neck dissection were performed later. The histologic examination confirmed the presence of a small MTC with no lymph node metastases. The patient has been screened yearly and no evidence for tumor recurrence has been found.

Case 3

This 27-year-old female member of the O-kindred was screened annually for MTC and pheochromocytoma. In 1987 the basal CT level was within the normal range but the pentagastrin-stimulated CT level was elevated to a peak value of 865 pmol/L. The CEA level was also elevated (7.26 ng/mL). Clinical examination and ultrasonography of the thyroid

Submitted for publication: October 24, 1989.

Accepted for publication: November 20, 1989.

*Department of Surgery, Heinrich-Heine University, Dusseldorf, West Germany.

Address correspondence to Dr. Frilling, Department of Surgery, Heinrich-Heine University Dusseldorf, Moorenstr.5, 4000 Dusseldorf, West Germany.

showed no abnormalities. On thyroidectomy and bilateral neck dissection C-cell hyperplasia was found with no metastases to the lymph nodes. Postoperatively stimulated CT levels decreased to normal.

Case 4

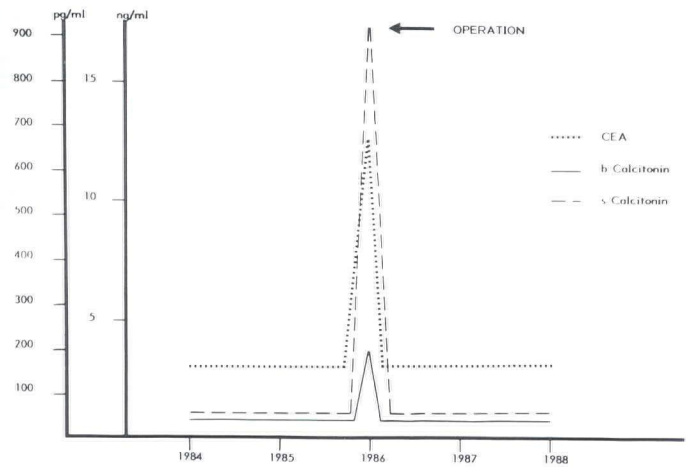
This 48-year-old female was the index case of the O-kindred, having had a left adrenalectomy for pheochromocytoma in 1983. Thyroid enlargement was observed first in 1976. In 1987 a cold thyroid nodule was detected by scintigraphy. The basal CT level was elevated to 2,240 pmol/L. The patient underwent thyroidectomy, and multicentric MTC with lymph node metastases were found. Two months later the patient had bilateral neck dissection which revealed two small metastases. In 1988 basal and stimulated CT were within the normal range but had increased in 1989 to 130 pmol/L and 2,100 pmol/L, respectively, even though clinical examination, ultrasonography, computed tomography, and ¹³¹I meta-iodo-benzylguanidine showed no evidence of any tumor recurrences.

Discussion

MTC is a rare thyroid neoplasm characterized by the CT-secreting tumor and the possibility of familial occurrence. Surgery is a curative therapeutic procedure (1, 11-13) only when the disease is still in the occult stage. CT assay provides a diagnostic tool for the detection of MTC in clinically unapparent cases (3). By frequent screening in our MEN 2 kindreds (one with patients with Hirschsprung's disease as well as MTC and pheochromocytomas), we have been able to diagnose the MTC in three family members in preclinical stages.

References

1. Melvin KEW, Tashjian AH Jr, Miller HA. Studies in familial (medullary) thyroid carcinoma. *Recent Prog Horm Res* 1972;28:399-470.
2. Saad MF, Ordonez NG, Rashid RK, et al. Medullary carcinoma of the thyroid: A study of the clinical features and prognostic factors in 161 patients. *Medicine (Baltimore)* 1984;63:319-42.
3. Melvin KEW, Miller HH, Tashjian AH Jr. Early diagnosis of medullary carcinoma of the thyroid gland by means of calcitonin assay. *N Engl J Med* 1971;285:1115-20.
4. Ponder BAJ, Coffey R, Gagel RF, et al. Risk estimation and screening in families of patients with medullary thyroid carcinoma. *Lancet* 1988;2:397-401.
5. Ponder BAJ. Medullary thyroid carcinoma: Screening the family of the apparently sporadic case. In: Muller HJ, Weber W, eds. *Familial cancer*. Basel: Karger, 1985:112-4.



Figure—Calcitonin and CEA serum levels.

6. Saad MF, Fritsche HA Jr, Samaan NA. Diagnostic and prognostic values of carcinoembryonic antigen in medullary carcinoma of the thyroid. *J Clin Endocrinol Metab* 1984;58:889-94.
7. Schifter S, Williams ED, Craig RK, Hansen HH. Calcitonin gene-related peptide and calcitonin in medullary thyroid carcinoma. *Clin Endocrinol* 1986;25:703-10.
8. Tashjian AH Jr, Howland BG, Melvin KEW, Hill CS Jr. Immunoassay of human calcitonin: Clinical measurement, relation to serum calcitonin and studies in patients with medullary carcinoma. *N Engl J Med* 1970;283:890-5.
9. Hennessy JF, Wells SA Jr, Ontjes DA, Cooper CW. A comparison of pentagastrin injection and calcium infusion as provocative agents for the detection of medullary carcinoma of the thyroid. *J Clin Endocrinol Metab* 1974;39:487-95.
10. Ponder BAJ, Finer N, Coffey R, et al. Family screening in medullary thyroid carcinoma presenting without a family history. *Q J Med* 1988;252:299-308.
11. Russell CF, van Heerden JA, Sizemore GW, et al. The surgical management of medullary thyroid carcinoma. *Ann Surg* 1983;197:42-8.
12. Wells SA Jr, Dilley WG, Farndon JA, Leight GS, Baylin SB. Early diagnosis and treatment of medullary thyroid carcinoma. *Arch Intern Med* 1985;145:1248-52.
13. Saad MF, Guido JJ, Samaan NA. Radioactive iodine in the treatment of medullary carcinoma of the thyroid. *J Clin Endocrinol Metab* 1983;57:124-8.