

6-1989

## A Suggested New Approach to Supraventricular Tachydysrhythmia After Coronary Bypass Surgery

Walter Kao

Mihai Gheorghiade

Follow this and additional works at: <https://scholarlycommons.henryford.com/hfhmedjournal>



Part of the [Life Sciences Commons](#), [Medical Specialties Commons](#), and the [Public Health Commons](#)

---

### Recommended Citation

Kao, Walter and Gheorghiade, Mihai (1989) "A Suggested New Approach to Supraventricular Tachydysrhythmia After Coronary Bypass Surgery," *Henry Ford Hospital Medical Journal* : Vol. 37 : No. 2 , 66-68.

Available at: <https://scholarlycommons.henryford.com/hfhmedjournal/vol37/iss2/4>

This Article is brought to you for free and open access by Henry Ford Health System Scholarly Commons. It has been accepted for inclusion in Henry Ford Hospital Medical Journal by an authorized editor of Henry Ford Health System Scholarly Commons.

# A Suggested New Approach to Supraventricular Tachydysrhythmia After Coronary Bypass Surgery

Walter Kao, MD,\* and Mihai Gheorghiade, MD\*

Supraventricular tachydysrhythmia is a well-recognized complication of coronary bypass surgery (1). With a reported incidence of 10% to over 40%, the disorder represents a considerable source of morbidity and cost in terms of extended hospitalization and additional diagnostic and therapeutic interventions. Conventional therapeutic measures are often limited by the tenuous hemodynamic status common in the immediate postoperative period. We propose an alternative approach to the management of a patient with this troublesome entity.

## Case Report

A 67-year-old white male was in good health until January 2, 1988, when he presented elsewhere with complaints of exertional shortness of breath and a mild, dry cough that had begun earlier that day. He denied any symptoms of chest or abdominal discomfort, fever, chills, diaphoresis, or palpitations. He was diagnosed as having congestive heart failure by physical examination and chest roentgenogram and was admitted and treated with 12.5 mg of captopril every eight hours, 10 mg of isosorbide dinitrate every eight hours, and 40 mg/day of furosemide. On the second hospital day echocardiography revealed a mildly enlarged left atrium with an estimated left ventricular ejection fraction of 30%. The patient's symptoms improved, and he was transferred to our institution for further evaluation. There was no history of ischemic heart disease, hypertension, hypercholesterolemia, or glucose intolerance. The patient had not smoked for more than 20 years, and the family history was unremarkable.

## Physical examination

The patient was a well-developed white male in no distress. Supine blood pressure was 130/70 mm Hg, pulse 74 beats/min without orthostatic change, and respiration 16 breaths/min. The skin was warm and dry. Head and neck examination was unremarkable. The thyroid was normal to palpation without bruits. Adenopathy was not present. The chest was clear to auscultation and percussion, with good air movement. Cardiac examination revealed a point of maximal impulse of normal location, size, and character. S1 was somewhat diminished, and S2 was physiologic. No S3, S4, or murmurs were heard. Jugular venous distention was not present, and carotid pulses exhibited normal volume and upstroke. Abdominal examination was unremarkable. There was no clubbing, cyanosis, or edema, and neurologic examination revealed no abnormalities. Electrocardiography revealed a normal sinus rhythm with normal P-R interval, left anterior hemiblock, and interventricular conduction delay and was consistent with an old anterior wall myocardial infarction (Fig 1).

## Hospital course

Left heart catheterization and coronary arteriography, performed in an effort to determine the etiology of the patient's heart failure, revealed a left dominant system with 90% proximal stenoses of the right, circumflex, and left anterior descending coronary arteries. The left main coronary artery was normal. Left-sided hemodynamics were normal, and the calculated left ventricular ejection fraction was 35%. Inferior and apical hypokinesis and mild-to-moderate mitral regurgitation were noted during left ventriculography. The patient's symptoms were thought to be secondary to myocardial ischemia, and coronary bypass surgery was performed, with left internal mammary anastomosis to the distal left anterior descending and saphenous vein grafts to the obtuse marginal and intermediate branches of the circumflex. Postoperatively, the patient was transferred to the surgical intensive care unit where the perioperative course was uneventful; however, while preparations were being made to transfer him to an intermediate care unit, he complained of palpitations. An electrocardiogram revealed atrial flutter with a ventricular response rate of 150 beats/min which spontaneously resolved to atrial fibrillation. His ventricular rate was maintained at 80 to 100 beats/min with digoxin (0.25 mg orally) and low-dose propranolol, and he was transferred to the intermediate care unit. He did well until two days later, when he complained of fluttering in his chest and generalized uneasiness. He appeared diaphoretic and pale. Supine blood pressure was 160/74 mm Hg, and the pulse was 165 beats/min and regular. He denied chest pain or shortness of breath. The chest was clear, and cardiac examination was unchanged. An electrocardiogram demonstrated a narrow complex tachycardia at 165 beats/min, again diagnosed as atrial flutter with a rapid ventricular response (Fig 2). Attempts were made to convert the arrhythmia by atrial overdrive pacing through chest temporary electrodes that are routinely placed at the time of surgery. Several initial attempts (current of 10 mA, pulse width 0.1 msec, rates 350, 375, and 450 for 10 to 20 seconds) were unsuccessful despite adequate atrial capture. The patient then received a 60 mg tablet of diltiazem, and the same overdrive pacing protocol repeated 30 minutes later (Fig 3) converted the arrhythmia to a normal sinus rhythm of 80 beats/min (Fig 4). The flutter rate did not change following diltiazem administration. The remainder of his hospitalization was uneventful.

## Discussion

Although the phenomenon of postcoronary bypass supraventricular tachydysrhythmia is well described, the underlying pathophysiologic mechanisms remain unclear. Several factors

Submitted for publication: June 14, 1989.

Accepted for publication: August 1, 1989.

\*Division of Cardiovascular Medicine, Henry Ford Hospital.

Address correspondence to Dr. Gheorghiade, Division of Cardiovascular Medicine, Henry Ford Hospital, 2799 W Grand Blvd, Detroit, MI 48202.

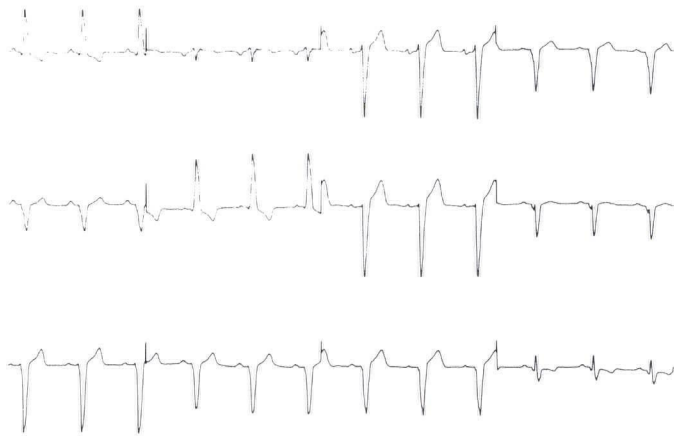

Fig 1—Electrocardiogram prior to the surgical procedure consistent with prior anterior wall myocardial infarction.

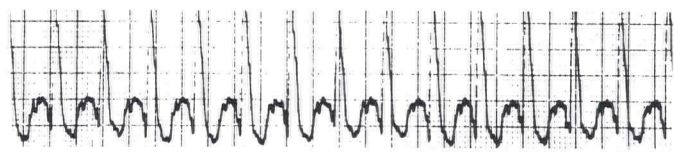


Fig 2—Atrial flutter with 2:1 ventricular response.

have been implicated, including reaction of the atrial myocardium to anatomic insult, elevated sympathetic tone in the perioperative period, and potentiated atrial excitability related to abrupt preoperative discontinuation of beta-adrenergic blocker therapy. Efforts have been made to prevent this complication by prophylactic therapy with digoxin alone (2), digoxin in combination with a beta-blocker (3,4), or a beta-blocker alone (5,6). Calcium channel blockers, particularly verapamil, have been used to treat a variety of supraventricular tachydysrhythmias (7). However, the negative inotropic effects associated with verapamil require great caution in its use soon after coronary bypass surgery when left ventricular function may be decreased.

Diltiazem hydrochloride is safe and effective in preventing paroxysmal supraventricular tachydysrhythmia (8,9) and, when given in conjunction with propranolol (10), can terminate supraventricular tachydysrhythmia. The drug slows conduction through both nodal as well as accessory pathways (11,12) and is generally associated with a lesser degree of negative inotropism than other currently available calcium channel blockers (13).

Our patient had clinical as well as radiographic evidence of left ventricular dysfunction prior to coronary bypass surgery. Digoxin and low doses of propranolol controlled the ventricular rate while the patient was in atrial fibrillation but failed to prevent the second episode of atrial flutter. Repeated attempts to

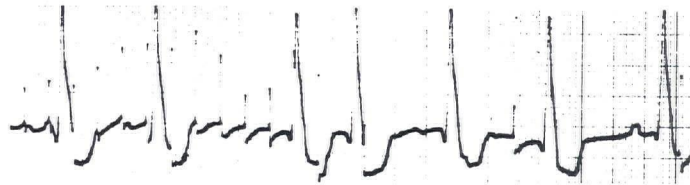


Fig 3—Rapid (373) atrial pacing with atrial capture resulting in the conversion of atrial flutter to sinus rhythm.

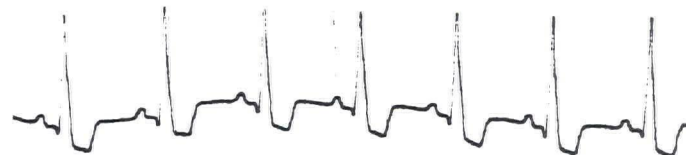

Fig 4—Restoration to normal sinus rhythm.

convert the arrhythmia using atrial overdrive pacing were unsuccessful. After the patient had received the diltiazem tablet, we were able to convert the tachydysrhythmia to normal sinus rhythm by employing the same pacing protocol. Although this case represents an isolated occurrence and the causal relationship has not yet been established, diltiazem in addition to overdrive pacing through chest temporary electrodes placed routinely at the time of surgery may be useful in the management of supraventricular tachydysrhythmia after coronary bypass surgery. It should be noted that therapeutic blood levels of the drug are reached in 30 to 45 minutes after oral administration. The incidence of side effects is relatively low. Randomized prospective studies are needed to determine whether calcium channel blockers with a negative chronotropic effect, such as diltiazem and verapamil, in addition to overdrive pacing, should be considered along with digoxin or beta-blockers in the management of supraventricular tachydysrhythmia occurring after coronary bypass surgery.

## References

1. Stephenson LW, MacVaugh H III, Tomasello DN, Josephson ME. Propranolol for prevention of postoperative cardiac arrhythmias: A randomized study. *Ann Thorac Surg* 1980;29:113-6.
2. O'Kane H, Geha A, Baue A, Klerger R, Krone R, Oliver GC. Prophylactic digitalization in aortocoronary bypass patients (Abstract). *Circulation* 1972;46:199.
3. Roffman JA, Fieldman A. Digoxin and propranolol in the prophylaxis of supraventricular tachydysrhythmias after coronary artery bypass surgery. *Ann Thorac Surg* 1981;31:496-501.
4. Parker FB Jr, Greiner-Hayes C, Bove EL, Marvasti MA, Johnson LW, Eich RH. Supraventricular arrhythmias following coronary artery bypass: The effect of preoperative digitalis. *J Thorac Cardiovasc Surg* 1983;86:594-600.
5. Mohr R, Smolinsky A, Goor DA. Prevention of supraventricular tachyar-

rhythmia with low-dose propranolol after coronary bypass. *J Thorac Cardiovasc Surg* 1981;81:840-5.

6. Matangi MR, Neutze JM, Graham KJ, Hill DG, Kerr AR, Barratt-Boyes BG. Arrhythmia prophylaxis after aorta-coronary bypass: The effect of mini-dose propranolol. *J Thorac Cardiovasc Surg* 1985;89:439-43.

7. Krikler DM, Spurrell RA. Verapamil in the treatment of paroxysmal supraventricular tachycardia. *Postgrad Med J* 1974;50:447-53.

8. Betriu A, Chaitman BR, Bourassa MG, et al. Beneficial effect of intravenous diltiazem in the acute management of paroxysmal supraventricular tachyarrhythmias. *Circulation* 1983;67:88-94.

9. Yeh SJ, Kou HC, Lin FC, Hung JS, Wu D. Effects of oral diltiazem in paroxysmal supraventricular tachycardia. *Am J Cardiol* 1983;52:271-8.

10. Yeh SJ, Lin FC, Chou YY, Hung JS, Wu D. Termination of paroxysmal supraventricular tachycardia with a single oral dose of diltiazem and propranolol. *Circulation* 1985;71:104-9.

11. Sadr-Ameli MA, Shenasa M, Faugere G, Lacombe P, Nadeau R. Efficacy and safety of intravenous and oral diltiazem in the WPW syndrome (Abstract). *Circulation* 1985;72:III-126.

12. Perelman MS, Webb SC, Krikler DM, Rowland E. A comparison of the electrophysiologic effects of diltiazem and verapamil (Abstract). *Circulation* 1985;72:III-440.

13. Packer M, Kessler PD, Lee WH. Calcium-channel blockade in the management of severe chronic congestive heart failure: A bridge too far. *Circulation* 1987;75:V-56-64.