

12-1988

Bladder Catheter Knotting: A Case Report

Mark G. Goetting

Follow this and additional works at: <https://scholarlycommons.henryford.com/hfhmedjournal>



Part of the [Life Sciences Commons](#), [Medical Specialties Commons](#), and the [Public Health Commons](#)

Recommended Citation

Goetting, Mark G. (1988) "Bladder Catheter Knotting: A Case Report," *Henry Ford Hospital Medical Journal* : Vol. 36 : No. 4 , 191-192.

Available at: <https://scholarlycommons.henryford.com/hfhmedjournal/vol36/iss4/6>

This Article is brought to you for free and open access by Henry Ford Health System Scholarly Commons. It has been accepted for inclusion in Henry Ford Hospital Medical Journal by an authorized editor of Henry Ford Health System Scholarly Commons.

Bladder Catheter Knotting: A Case Report

Mark G. Goetting, MD*

Bladder catheterization is a common procedure in the critically ill patient. Since the development of the rubber double-lumen, balloon-tipped Foley catheter, serious mechanical complications resulting from the procedure are unusual (1). The urethra of small infants often cannot accommodate the diameters of these catheters. Therefore, sterile feeding tubes are substituted. Because these tubes are not balloon-tipped, proper insertion length cannot be confirmed by placing traction on the device, sometimes resulting in excessive catheter length within the bladder.

The following case report is an example of spontaneous catheter knotting which resulted in significant penile injury. Guidelines for catheter insertion and radiographic warning signs are discussed.

Case Report

An 11-day-old circumcised male, who was born prematurely at a weight of 2.8 kg (6.2 lb), presented with bacterial meningitis and sepsis. As part of routine monitoring, an 8 French feeding tube was passed into his urinary bladder using routine sterile technique on the first day of hospitalization. He responded well to antibiotic therapy and was much improved by the third day of hospitalization. On the fourth day, urine output from the catheter declined over several hours and then stopped. The nurse attempted to irrigate the catheter but could not. While removing the catheter she noted slight resistance. A large knot in the catheter (Fig 1) was delivered, resulting in a full-thickness laceration from the meatus to the coronal sulcus through the median raphe (Fig 2). Another 8 French catheter was promptly reinserted. The catheter was removed uneventfully in five days. Surgical intervention was not required for the patient's laceration, and he was discharged 25 days after admission. At four months of age, the infant's penis had healed but the defect in the glans remained.

Retrospective review of chest radiographs obtained prior to his injury demonstrated excessive length and coiling of the catheter within his bladder on the second and third day of hospitalization (Fig 3).

Discussion

Placement of a bladder catheter can be performed safely in almost all infants. The catheter should pass with no significant resistance. The membranous and prostatic portions of the infant urethra dilate easily. Care must be taken not to exceed the neces-

sary length of insertion; otherwise bladder puncture or catheter knotting may result.

Unlike the adult, the infant's bladder is an abdominal structure completely above the symphysis pubis (2). The apex of the

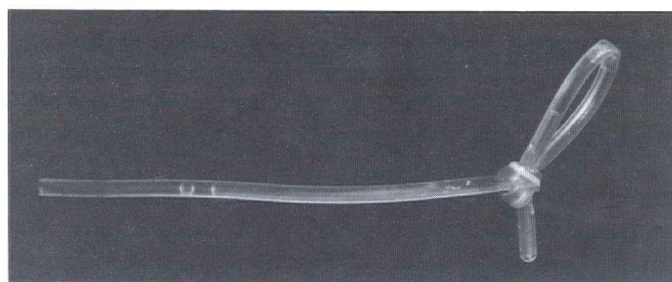


Fig 1—Catheter knot removed from patient.

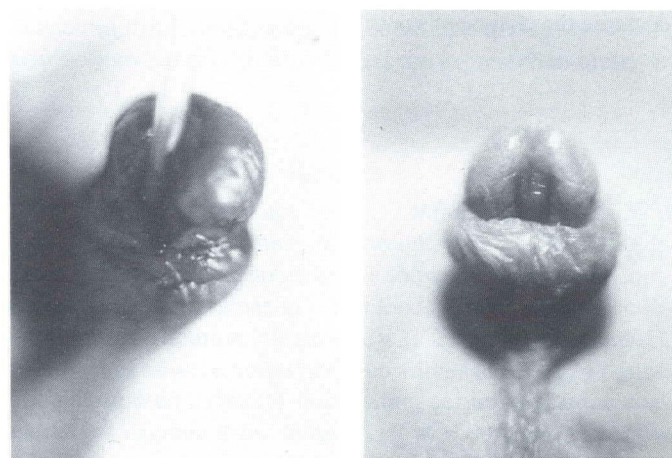


Fig 2—Penile laceration at time of injury (left) and four months later (right).

Submitted for publication: June 1, 1988.

Accepted for publication: July 1, 1988.

*Division of Pediatric Critical Care Medicine, Henry Ford Hospital.

Address correspondence to Dr. Goetting, Division of Pediatric Critical Care Medicine, Henry Ford Hospital, 2799 W Grand Blvd, Detroit, MI 48202.

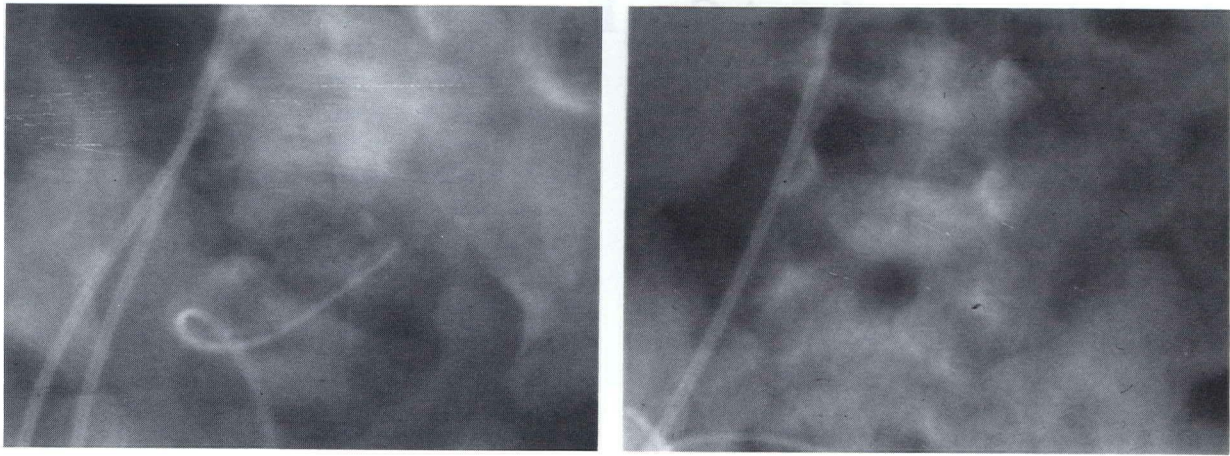


Fig 3—Radiograms showing excessive catheter length on days 2 (left) and 3 (right).

bladder extends about two-thirds the distance to the umbilicus. Before inserting the catheter, the distance between the mid portion of the symphysis pubis and the umbilicus should be measured. For girls, this distance is the maximum length that the catheter should be inserted. For boys, this distance should be added to the length of the penis. The catheter is advanced slowly until urine flow is seen or this maximum length is inserted. With this method we have not had mechanical problems caused by catheterization.

Chest radiography was performed daily on our patient to confirm endotracheal tube, gastric tube, and vascular catheter positions. Fortunately, two films demonstrated portions of the bladder catheter coiled in the abdomen. This is an important radiographic warning that the catheter should be pulled back to decrease the chance of knotting.

To our knowledge this sort of bladder catheter knotting has not been reported previously. Obviously the potential for this problem does exist. During the removal of such a catheter, virtually no resistance should occur. If resistance is detected, this should prompt a halt in the procedure followed by reevaluation. Radiography may be useful in detecting the problem.

References

1. Schabel SI, Rittenberg GM. Complications of the Foley catheter. *CRC Crit Rev Diagn Imaging* 1981;16:219.
2. William PL, Warwick R. *Gray's anatomy*. 36th British ed. Philadelphia: WB Saunders Co, 1980:1405.