Henry Ford Hospital Medical Journal

Volume 36 | Number 4 Article 5

12-1988

Perinatal Idiopathic Hemochromatosis

Usha B. Raju

Sudhakar Ezhuthachan

Chan K. Ma

Follow this and additional works at: https://scholarlycommons.henryford.com/hfhmedjournal

Part of the Life Sciences Commons, Medical Specialties Commons, and the Public Health Commons

Recommended Citation
Raju, Usha B.; Ezhuthachan, Sudhakar; and Ma, Chan K. (1988) "Perinatal Idiopathic Hemochromatosis," *Henry Ford Hospital Medical Journal* : Vol. 36 : No. 4 , 187-190.
Available at: https://scholarlycommons.henryford.com/hfhmedjournal/vol36/iss4/5

This Article is brought to you for free and open access by Henry Ford Health System Scholarly Commons. It has been accepted for inclusion in Henry Ford Hospital Medical Journal by an authorized editor of Henry Ford Health System Scholarly Commons.

Perinatal Idiopathic Hemochromatosis

Usha B. Raju, MD,* Sudhakar Ezhuthachan, MD, DCH,† and Chan K. Ma, MD*

We report the clinicopathologic features of an infant who died of a rare form of perinatal cirrhosis associated with idiopathic hepatic and extrahepatic parenchymal siderosis. The infant appeared normal at birth but soon became severely ill, following a progressively downhill course associated with hypoglycemia, metabolic acidosis, bleeding diathesis, jaundice, and shock. The infant died at 7 days of age. The manifestations were those of hepatic failure but mimicked sepsis and disseminated intravascular coagulation. Cirrhosis, giant cell transformation, and parenchymal iron deposition characteristic of perinatal idiopathic hemochromatosis, a recently emerging clinicopathologic entity of unknown etiology, were present in this infant. These clinical and pathologic features differ from other neonatal liver diseases in their acute onset immediately after birth, a catastrophic clinical course ending fatally, and the morphologic manifestation of significant iron overload. (Henry Ford Hosp Med J 1988;36:187-90)

Perinatal idiopathic hemochromatosis is a rare disorder emerging as a distinct clinicopathologic entity (1-8). The extreme intrauterine hepatic damage resulting in cirrhosis is apparently incompatible with extrauterine life, and the newborn infant follows a rapidly downhill course with coagulation problems, hypoglycemia, and jaundice. Histologically, cirrhosis and giant cell transformation of the liver are associated with marked parenchymal iron deposition in the liver, pancreas, heart, and to a lesser degree in other organs. The distribution of iron deposition is similar to that seen in idiopathic hemochromatosis of adults. We describe the clinicopathologic features of an infant who died of cirrhosis and iron overload and briefly review the pertinent literature.

Case Report

A 3,160 g (6 lb 9 oz), white male infant was born at term by normal spontaneous vaginal delivery to a 28-year-old, gravida 5, para 3, white woman. The Apgar scores were 9 and 10 at 1 and 5 minutes, respectively. The mother's first pregnancy had ended with a spontaneous abortion at eight weeks, and the fourth was a female term stillbirth. The intrauterine death was attributed to a short cord. The mother has two normal, living children. This pregnancy was significant for a urinary tract infection very early in the pregnancy.

By one hour of age, the infant was noted to be pale, gray, and hypotonic with mild retractions and tachypnea. Hypoglycemia was identified, and the infant appeared to improve clinically following administration of glucose. At 25 hours of age, he again deteriorated and was noted to have hypothermia. The blood glucose was low (0.9 mmol/L [17 mg/dL]), as was the blood pressure (40/15 mm Hg), but no evidence of any respiratory distress was present. The lungs were clear to auscultation, and the heart sounds were normal and without a murmur. Hepatosplenomegaly was not present, and the kidneys were not palpable. Metabolic acidosis was corrected with intravenous bicarbonate, and plasmanate was infused to correct hypotension. Hematological parameters demonstrated a platelet count of 37,000/μL, total WBC count of 12,500/μL with a differential count of 0.55 neutrophils, 0.23 bands, 0.05 lymphocytes, 0.14 monocytes, 0.03 eosinophils, 25 nucleated RBC/100 WBC, moderate burr cells and fragmented red cells, hemoglobin of 15.8 g/dL, and hematocrit of 50%. After a complete workup for sepsis, ampicillin and gentamicin were administered at appropriate doses.

During the next four days the infant developed progressive renal failure, pulmonary and gastrointestinal hemorrhage, hypotension, hypoxemia, metabolic and respiratory acidosis, and persistent low hematocrits. Treatment included vasopressors, fresh frozen plasma, platelet and packed red cell transfusions, and mechanical ventilation.

By the fourth day, abdominal distension and free fluid in the peritoneal cavity were also observed, and the infant became icteric with a total bilirubin of 169 μmol/L (9.9 mg/dL) and a direct bilirubin of 41 μmol/L (2.4 mg/dL). Serum albumin was 18 g/L (1.8 g/dL), SGOT was 134 IU/L, and SGPT was 24 IU/L. Toxoplasma, rubella, cytomegalovirus, and herpes titers were within normal limits, and VDRL was nonreactive. Karyotype analysis was normal. There was no blood group incompatibility. Blood, urine, and cerebrospinal fluid cultures were negative.

Laparotomy was performed on the infant's fourth day of life to rule out any major abdominal pathology. Serosanguinous peritoneal fluid and a nodular liver were identified at laparotomy, and the liver was biopsied. The infant progressively deteriorated and died on the seventh day despite resuscitative measures.

Submitted for publication: June 1, 1988.
Accepted for publication: June 21, 1988.
*Department of Pathology, Henry Ford Hospital.
†Department of Pediatrics, Henry Ford Hospital.
Address correspondence to Dr. Raju, Department of Pathology, Henry Ford Hospital, 2799 W Grand Blvd, Detroit, MI 48202.

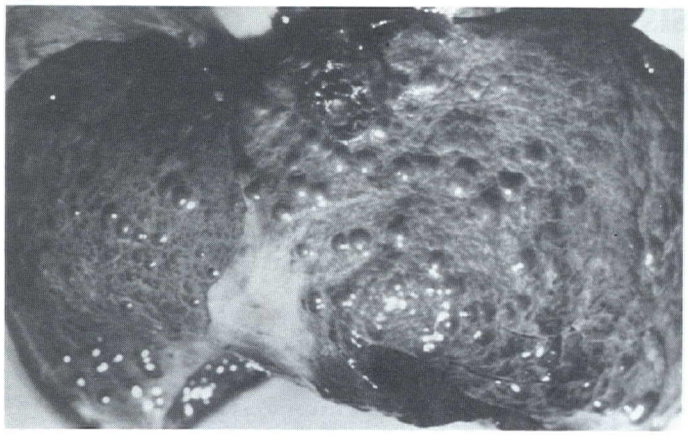

Fig 1—Shrunken, cirrhotic liver with micronodules.

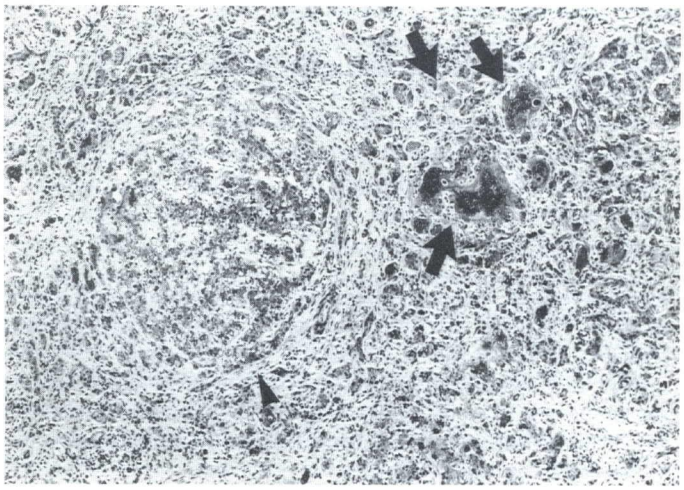

Fig 2—Liver: A regenerative nodule is seen on the left (arrowhead), and giant cell transformation and bile ductular proliferation are seen on the right (arrows) (trichrome stain 70 X).

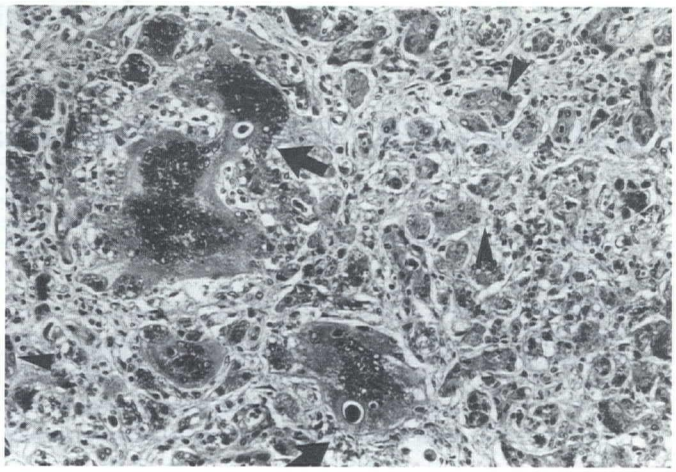

Fig 3—Liver: The giant cells with numerous nuclei have abundant brown pigment and large droplets of bile (arrows). Distorted hepatic cell nests and proliferating bile ductules are present in a fibrotic stroma (arrowheads) (trichrome stain 175 X).

Pathology

At autopsy, the shrunken, hard, nodular liver weighed 55 g (normal 155 g), and the dark red-brown cut surface was studded with 0.1 to 0.2 cm nodules (Fig 1). The extrahepatic biliary tree was normally developed. The distended gallbladder was filled with clear mucus. The spleen was enlarged (18.6 g [normal 10 g]) and congested. The heart was also slightly enlarged (31.9 g [normal 21 g]).

Histologically, the liver architecture was markedly distorted and replaced by small nodules comprised of intact hepatocytes and demarcated by fibrous tissue bands. The nodules were separated by diffuse areas of fibrosis incorporating many regenerating hepatocytes, multinucleated giant cells (giant cell transformation of hepatocytes), and bile ductules (Figs 2 and 3). A moderate degree of canalicular bile stasis was present. The iron content of the organs was evaluated by Prussian blue stain for iron and graded 0 (none) to 4 + (coarse and fine granules of iron in almost all of the cells) according to the scheme used by Blisard and Bartow (1). The hepatocytes, giant cells, and bile ductules contained abundant (4 +), brown, granular hemosiderin pigment (Fig 4A). A small amount of iron was present in reticuloendothelial cells (Kupffer cells and macrophages of the liver). Abundant (4 +) hemosiderin was present in the pancreatic acinar epithelium (Fig 4B), and a lesser degree of iron deposition was noted in islets of pancreas (2 +), myocardium (2 +), renal tubules (1 +), and adrenal cortex (1 +). A very small amount of iron was present in isolated reticuloendothelial cells of the spleen (1 +). Other significant findings included islet cell hyperplasia in the pancreas; bilateral intrapulmonary hemorrhage; petechial and ecchymotic hemorrhages of the skin, esophagus, kidney, and urinary bladder; and an area of ischemic colitis. No structural abnormalities were evident in the brain or kidneys.

Discussion

Idiopathic neonatal cirrhosis is a rare disorder in which the affected infant may be stillborn or succumb to complications of cirrhosis and hepatic failure (9-12). The hepatic damage is advanced by birth and histologically manifests as cirrhosis with variable degree of giant cell transformation and cholestasis. Cirrhosis associated with heavy parenchymal iron deposition in the liver, pancreas, myocardium, and endocrine glands has been reported in about 26 cases (5,6), but the actual incidence is probably higher. Fienberg (2) used the term perinatal idiopathic hemochromatosis (PIH) for this distinctive subset. The diagnostic criteria for PIH as defined by Fienberg (2) and more recently by Knisely et al (5) include: 1) a rapidly progressive clinical course with death in the early neonatal period; 2) increased tissue iron deposition in the liver, pancreas, heart, and endocrine glands, with the extrahepatic reticuloendothelial system relatively unaffected; and 3) no evidence for hemolytic disease, syndromes

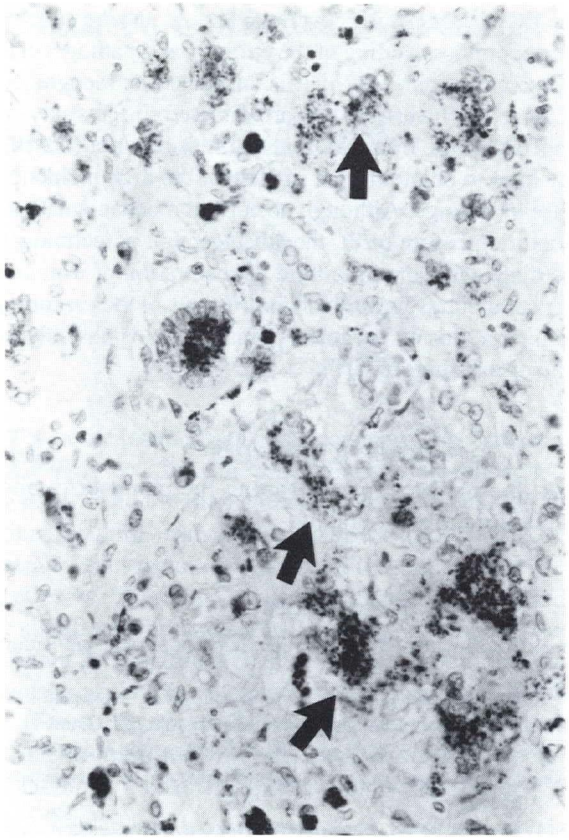

Fig 4A—Liver: The giant cells and hepatic parenchymal cells are loaded with hemosiderin (arrows) (Prussian blue stain for iron 175 X).

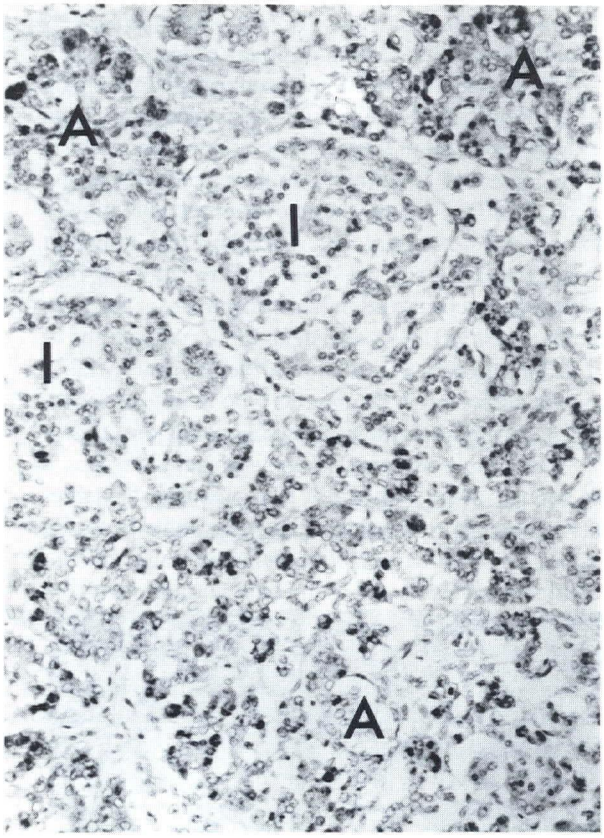

Fig 4B—Heavy hemosiderin deposition is also present in the pancreatic acinar cells (A). The islet cells (I) also have small quantities of hemosiderin (Prussian blue stain for iron 175 X).

associated with hemosiderosis, or exogenous iron overload from transfusions.

This neonate followed a catastrophic clinical course similar to cases of PIH previously reported (2) and presented special clinical problems. The bleeding diathesis, hypoglycemia, and subsequent jaundice were caused primarily by liver failure. The differential diagnosis also included all the hepatic disorders manifesting with conjugated or mixed hyperbilirubinemia, most of which could be excluded because they usually do not present this early with hepatic failure. Laparotomy performed for a suspected abdominal event also excluded extrahepatic biliary atresia. The histologic appearance of the nodular liver revealed the triad of cirrhosis, giant cell transformation, and parenchymal siderosis and did not correspond to the morphologic appearance of any known metabolic disease affecting the liver. Cirrhosis is a late occurrence during the course of metabolic diseases affecting the liver (10). Parenchymal iron deposition and cirrhosis are not features of the conditions characteristically associated with giant cell transformation, such as extrahepatic biliary atresia and neonatal hepatitis. Giant cell transformation of hepatocytes is a response of the fetal and neonatal liver to injury and does not signify specific etiology. In the absence of cirrhosis, this is a reversible condition but may later progress to cirrhosis (13). The other disorder associated with significant hepatic iron deposition is the Zellweger syndrome, characterized by hypotonia and cerebral, renal, and skeletal abnormalities, which also may have a variable pattern of hepatic fibrosis. While this syndrome's clinical features are distinct and easily separable from PIH, its variable liver morphology does not include giant cell transformation (14). The combination of cirrhosis, giant cell transformation, and parenchymal iron deposition appears to be unique to PIH (1-8).

The hepatic and extrahepatic parenchymal iron deposition in this case and those reported previously is similar to that of idiopathic hemochromatosis in adults (2,15). There is disproportionately little reticuloendothelial hemosiderin in the liver and little or none outside the liver. In transfusion-associated hemosiderosis and that due to isoimmune hemolytic disorders, the iron deposition is most prominent in the spleen and other reticuloendothelial cells (5,15) and occurs over a prolonged period of time. Iron uptake, storage, and utilization is a complex process in which the liver plays an important role (15). The hepatocytes remove the excess iron from circulation, store the iron primarily in the form of unstainable ferritin and in small quantities as stainable hemosiderin, and release it as needed. Prolonged massive iron overload, as in adult idiopathic hemochromatosis, leads to accumulation of iron in the hepatocytes in the form of hemosiderin. Smaller quantities of septal reticuloen-

dothelial siderosis seen in later stages of hemochromatosis is a secondary phenomenon due to phagocytosis of iron liberated from necrotic hepatocytes. Deposition of iron in the extrahepatic parenchymal cells probably results from an inadequacy of the hepatic iron storage system in the presence of cirrhosis.

Although the increased amount of parenchymal iron appears relatively specific for PIH (1), the cause of iron accumulation in this condition has not been identified. Excessive iron transport across the placenta similar to the excessive transport of iron across the intestinal mucosa in adult hemochromatosis has been suggested as the cause (3). No consistent abnormal patterns of iron intake during pregnancy or abnormalities of iron metabolism have been documented in the parents who have been evaluated, but the disease has been documented in several pairs of siblings (2,5,7,8). A simple or complex enzyme defect causing a block in the mobilization of hepatic iron, leading to its accumulation, continues to be considered as an etiologic factor for PIH (2,5,7), but the specific metabolic defect remains unidentified. Maternal antibodies to any of the fetal antigens involved in iron transport, storage, and metabolism have also been considered in its pathogenesis (5). Association with histocompatibility antigens, as noted in patients with adult idiopathic hemochromatosis, was not documented in the affected infants because none were tested. The mother of one pair of affected siblings had an HLA A_3 and B_7—the types common in recessively inherited hemochromatosis in adults (8). The HLA type of the infant or mother in our case is unknown. Although not well documented, an autosomal recessive or co-dominant type of inheritance pattern was favored in a recent review (5).

Bleeding diathesis has been a consistent manifestation of most reported cases of PIH (1,5,6). Decreased vitamin K-dependent coagulation factors and thrombocytopenia have been documented in one previous case (6). In our case, complete coagulation profile has not been investigated due to the catastrophic clinical course, but the cause of bleeding diathesis is probably due to a combination of thrombocytopenia and exaggerated deficiency of the naturally low vitamin K-dependent coagulation factors due to hepatic insufficiency. The thrombocytopenia was perhaps due to hypersplenism and/or consumptive coagulopathy. The uniformly fatal course of these newborns within days of birth appears to be due to cirrhosis and liver failure. Since the advanced liver damage has occurred in utero, the outlook for this condition, even if diagnosed immediately after birth, appears dismal. Diagnosis is seldom made during the life of the infants (1-8). The combination of hypoglycemia, hypotonia, and bleeding diathesis, with evidence of hepatic failure in a newborn infant, should alert the clinician to the possibility of PIH. Tests for iron metabolism such as a Rous test for hemosiderin in the urine; serum iron, transferrin, and ferritin; and liver scans for iron overload should also be considered (5). Further understanding of the etiology and pathogenesis of this disease can occur only if it is suspected or recognized soon after birth and investigations are directed to the study of iron metabolism of the infant. Subsequent pregnancies of the mother may have to be monitored in view of the high incidence of the disease in siblings. Although no current mechanism identifies the condition before birth, the advancement of techniques for in utero diagnosis (amniotic fluid concentration of iron and its transport compounds, umbilical cord venous blood sampling by direct puncture during pregnancy) may make it possible to diagnose the disease before birth.

Acknowledgments

We thank Sherryl McCray for typing the manuscript and Nancy Peshkin for the photography.

References

1. Blisard KS, Bartow SA. Neonatal hemochromatosis. Hum Pathol 1986;17:376-83.

2. Fienberg R. Perinatal idiopathic hemochromatosis: Giant cell hepatitis interpreted as an inborn error of metabolism. Am J Clin Pathol 1960;33:480-91.

3. Goldfischer S, Grotsky HW, Chang CH, et al. Idiopathic neonatal iron storage involving the liver, pancreas, heart, and endocrine and exocrine glands. Hepatology 1981;1:58-64.

4. Greco MA, Richards HMS, Finegold MJ. Parenchymal cell siderosis in infancy (Abstract). Lab Invest 1978;38:387.

5. Knisely AS, Magid MS, Dische R, Cutz E. Neonatal hemochromatosis. Birth Defects 1987;23:75-102.

6. Kurnetz R, Yang SS, Holmes R, Harrison DD. Neonatal jaundice and coagulopathy. J Pediatr 1985;107:982-7.

7. Laurendeau T, Hill JE, Manning GB. Idiopathic neonatal hemochromatosis in siblings: An inborn error of metabolism. Arch Pathol 1961;72:410-23.

8. Silver MM, Valberg LS. Tissue iron quantitation in five cases of perinatal hemochromatosis (Abstract). Lab Invest 1986;54:9P.

9. Craig JM, Gellis SS, Hsia DYY. Cirrhosis of liver in infants and children. Am J Dis Child 1955;90:299-322.

10. Hardwick DF, Dimmick JE. Metabolic cirrhosis of infancy and childhood. Perspect Pediatr Pathol 1976;3:103-44.

11. Peace R. Fatal hepatitis and cirrhosis in infancy: Critical analysis of 32 cases studied at necropsy. Arch Pathol 1956;61:107-19.

12. Thaler MM. Fatal neonatal cirrhosis: Entity or end result? A comparative study of 24 cases. Pediatrics 1964;33:721-34.

13. Craig JM, Landing BH. Form of hepatitis in neonatal period simulating biliary atresia. Arch Pathol 1952;54:321-33.

14. Danks DM, Tippett P, Adams C, Campbell P. Cerebro-hepato-renal syndrome of Zellweger: A report of eight cases with comments upon the incidence, the liver lesion, and a fault in pipecolic acid metabolism. J Pediatr 1975;86:382-7.

15. Kent G, Bahu RM. Iron overload. In: MacSween R, Anthony PP, Scheuer PJ, eds. Pathology of liver. 1st ed. New York: Churchill Livingstone, 1979:148-63.