

# Endovascular Treatment of Intracranial Aneurysms: Diversity in Treatment Techniques of Varying Anatomical Presentations

*Patriawan Putu<sup>1</sup>, Sitanggang Firman<sup>1</sup>, Mohd Redzuan Ismail<sup>2</sup>,  
Nik Azuan Nik Ismail<sup>2</sup>, Nur Yazmin Yaacob<sup>2</sup>, Ahmad Sobri Muda<sup>2</sup>*

<sup>1</sup> Department of Radiology, Sanglah Hospital, Bali, Indonesia.

<sup>2</sup> Department of Radiology, Universiti Kebangsaan Malaysia Medical Centre, Kuala Lumpur, Malaysia.

## **Correspondence mail:**

Ahmad Sobri Muda. Department of Radiology, Universiti Kebangsaan Malaysia Medical Centre, Jalan Yaacob Latif, Bandar Tun Razak, 56000 Cheras, Kuala Lumpur, Malaysia. email: [sobri\\_muda@yahoo.com](mailto:sobri_muda@yahoo.com).

## **ABSTRAK**

*Kami membahas dan menggambarkan berbagai pilihan pengobatan endovaskular aneurisma intrakranial, serta bagaimana menjelaskan teknik endovaskular yang sering digunakan dalam pengobatan aneurisma otak. Kami memilih lima kasus berbagai jenis aneurisma untuk menunjukkan bagaimana pengobatan dengan endovaskular (EVT) dilakukan. Kateterisasi secara selektif aneurisma intrakranial dan pengobatan endovaskular secara teknis sangat mungkin sebagai pilihan, menawarkan pengobatan alternatif selain dari pendekatan pembedahan. Kami membahas fitur radiografi, presentasi klinis, dan strategi pengobatan endovaskular aneurisma intrakranial.*

**Kata kunci:** *pengobatan endovaskular, aneurisma intrakranial, sten intrakranial, balloon assisted.*

## **ABSTRACT**

*We discuss and illustrate various endovascular treatment options for intracranial aneurysms, to reflect common technique used in endovascular treatment of brain aneurysm. We select five cases of various aneurysm types to show assortments of endovascular treatment (EVT) are performed. Selective catheterization of the intracranial aneurysms and endovascular treatments are technically feasible, offering a viable alternative to the surgical approach. We discuss the radiographic features, clinical presentation, and strategies of endovascular treatment of intracranial aneurysms.*

**Key words:** *endovascular treatment, intracranial aneurysm, intracranial stent, balloon assisted.*

## **INTRODUCTION**

Ruptured cerebral aneurysms carry high rates of mortality and morbidity. Typically, these result in subarachnoid haemorrhage (SAH) and intracranial hematoma (ICH) formation, either of which constitutes a stroke. Other sequelae include rebleeding, hydrocephalus (the excessive accumulation of cerebrospinal fluid)

and vasospasm (spasm, or narrowing, of the blood vessels) may also occur thus contributing to mortality and disability rates up to 44% and 19% respectively.<sup>1</sup> Treatment of unruptured aneurysms are rather controversial. Some centres use certain parameters to exclude interventional option which among others include: lack of associated symptoms, aneurysm size less than 7

mm, lesion in the anterior circulation, age older than 64 years, and no personal or family history of SAH.<sup>2</sup> The annual rupture rate of aneurysm is 1.0% with no history of SAH and 1.3% with previous history of SAH.<sup>3</sup>

Endovascular techniques were originally pioneered for diagnostic purposes by radiologists. Basic techniques involve obtaining arterial access and selective catheterisation of the relevant vessels usually by interventional radiologist or trained doctor to perform endovascular procedures. The endovascular procedure varies from case to case and is generally divided into vascular access phase and intervention phase. Access phase consists of placement of guider catheter in the carotid artery or vertebral artery. The following intervention phase involves microcatheter advancement into the aneurysm sac and deployment of coils. Adjunctive techniques maybe employed such as stent-assisted or balloon-assisted coiling. Intracranial stents have been shown to be useful in the treatment of fusiform and wide-necked aneurysms. Self-expanding neuro-interventional microstents are primarily developed for stent-assisted coiling, but further therapeutic haemodynamic effect is also possible by “stent- in- stent” or telescopic technique. Successful application of this technique has been well documented.<sup>4</sup> Just recently, flow-diverter stents have been developed and specially designed to have lower porosity than regular stents to achieve flow disruption and potential aneurysm occlusion.<sup>5</sup>

Radiology Department of Sanglah Hospital, Bali has the capability, resources and expertise to offer full fledged interventional procedures including neurointervention and head and neck intervention.

## SELECTED ILLUSTRATIONS

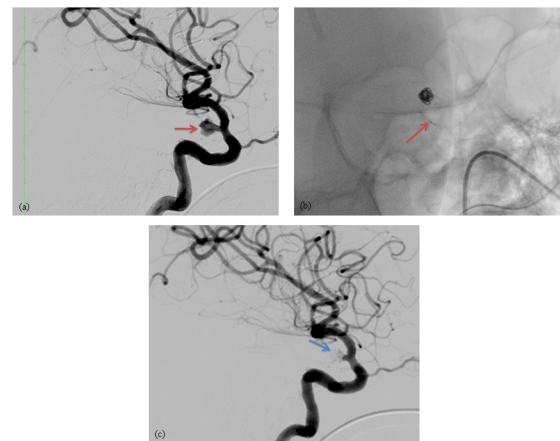
### Internal Carotid Artery (ICA) Aneurysm with Favourable Geometry

A 69 year-old gentleman presented with reduced consciousness level, was found to have SAH with intraventricular extension. Computed Tomography Angiogram (CTA) revealed left supraclinoid ICA aneurysm. Conventional clipping was unsuccessful because of the calcified nature of the aneurysm's neck and part

of the neck was also within the cavernous sinus.

The patient then underwent endovascular treatment. The procedure was performed under general anaesthesia with biplane angiography system. An in-dwelling sheath and Headhunter catheter were used to access the left ICA. Digital subtraction angiography (DSA) demonstrated a saccular aneurysm at the left supraclinoid ICA measuring approximately 7 mm in height and<sup>5,6</sup> mm in width with the neck measuring 1.9mm (**Figure 1a**).

The aneurysm was catheterized using a microcatheter (SL-10, Boston Scientific Corporation) with the assistance of a microguide wire (Transend 14, Boston Scientific Corporation). Coil embolization performed with initial creation of a coil basket at the fundus of the aneurysm using 5 mm x 12 cm coil (Microplex; Microvention) (**Figure 1b**). Subsequent coiling was performed with the aim to archive tight packing using multiple coils of various sizes. Post-embolization and 3DRA confirmed occlusion of the aneurysm (**Figure 1c**).



**Figure 1.** (a) DSA showing left supraclinoid ICA aneurysm; (b) Coil deployment with coil delivery wire marker match the 2nd microcatheter tip marker (standard 3 cm from distal tip marker); (c) Post embolization DSA showing good occlusion of the ICA aneurysm with minimal neck remnant

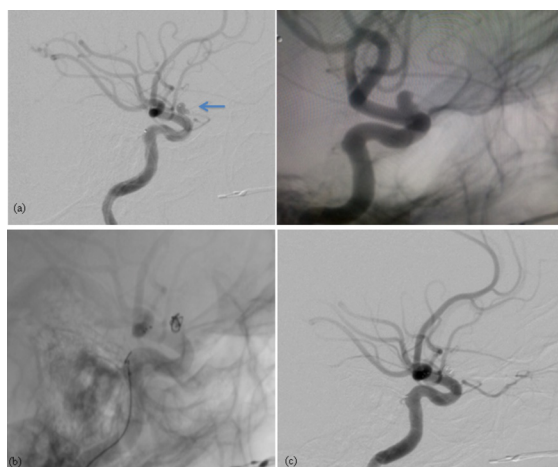
### Stent-assisted Coiling of Wide Neck ICA Aneurysm

A 54 year-old lady presented with headache and was found to have a left ICA aneurysm following MRI examination. DSA confirmed the presence of the aneurysm and she was electively admitted for endovascular treatment of

unruptured left supraclinoid aneurysm (**Figure 2a**).

We planned to treat the patient with stent-assisted coiling to ensure we can deliver the coil mass into the aneurysm without prolapsing into the parent artery due to the wide neck dimension of the aneurysm. Five days prior to the treatment, the patient was placed on aspirin 150 mg and Plavix 75 mg daily to prepare for the stent placement. Guiding catheter size 5F was advanced from both common femoral arteries approaches into the left ICA. Microcatheter (SL 10; Boston Scientific) and microwire (Transend 14, Boston Scientific Corporation) were used to access the aneurysm. We used the jail technique whereby the stent (LEO+; Balt, France) when the microcatheter tip has been positioned in the aneurysm, jailing the catheter between the fully expanded stent and vessel wall. This technique stabilises the microcatheter tip during coil delivery and ensures the coil placement within the aneurysm, exterior to the stent.

Detachable coils were then delivered to the aneurysm using the stent as a scaffolding (**Figure 2b**). Post-embolization DSA showed complete occlusion of the aneurysms with patent parent artery (**Figure 2c**). She was nursed overnight in ICU and discharged at day 4 post-procedure. At 3 months follow-up, there was a small residual neck and at 1 year follow-up the aneurysm was well obliterated.

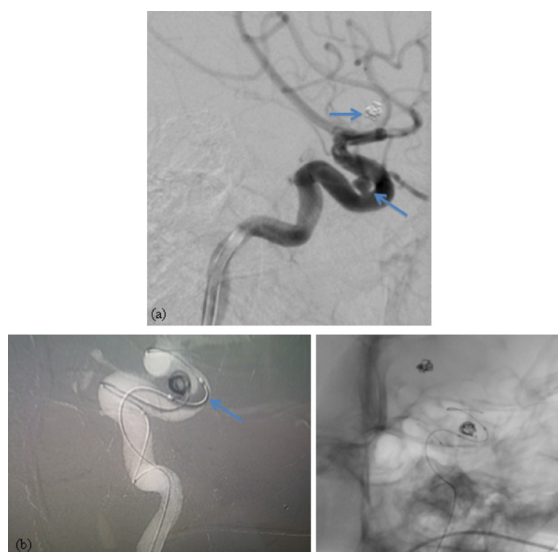


**Figure 2.** (a) Left supraclinoid ICA aneurysm noted on DSA; (b) Fully deployed LEO+ stent and microcatheter tip already placed within the aneurysm with 1st coil being delivered. The jail technique stabilizes the microcatheter tip between the fully expanded stent and vessel wall; (c) Post embolization DSA

### Balloon-assisted Coiling in an Angulated Siphon ICA Aneurysm

The patient is a 41 year-old lady with two aneurysms, each at the anterior communicating artery and at the left carotid siphon over the paraophthalmic region. The initial treatment was performed in another centre whereby the anterior communicating artery aneurysm was treated endovascularly successfully. The left ICA aneurysm treatment was unsuccessful due to tortuosity and angulation of the carotid siphon resulting in failure of cannulation of the paraophthalmic aneurysm (**Figure 3a**).

Our strategy was to use balloon in stabilizing the microcatheter tip during cannulation and coiling. We used semi-complaint non-detachable balloon (Hyperglide 4 mm x 15 mm; Balt, France) to assist the microcatheter (SL-10; Boston Scientific) tip stabilization. During microcatheter cannulation and coiling, the balloon was inflated intermittently of not more than 2 minutes each time, under live fluoroscopy (**Figure 3b**).



**Figure 3.** (a) Coiled anterior communicating artery aneurysm and another aneurysm at the left carotid siphon, paraophthalmic region; (b) Delivery of 1st coil with balloon at the parent artery, which was inflated (seen as a filling defect) during coil placement and deflated after fully deployed but not yet detached, to test the stability of the coil mass

We managed to occlude the aneurysm using three detachable coils. She was discharged on day 4 post-procedure after an overnight stay in ICU.

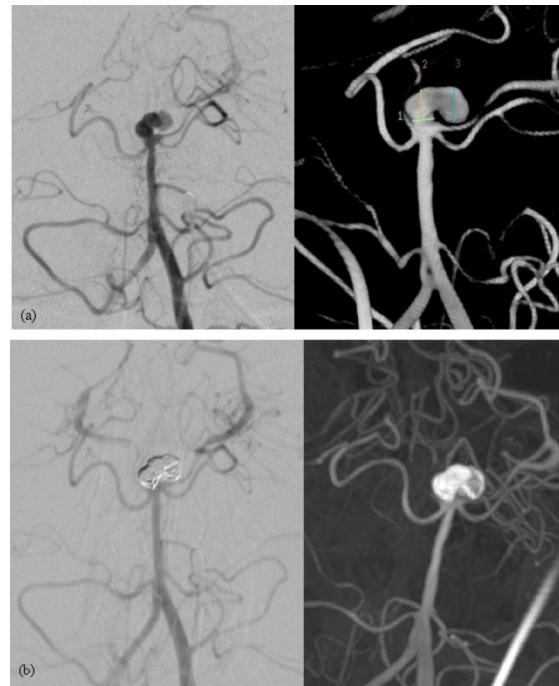
### Balloon-assisted Coiling in Bifurcated Aneurysm

A 31 year-old gentleman presented with sudden onset of severe headache. Non-contrasted CT brain demonstrated SAH and subsequent CTA examination revealed a complex bilobed basilar tip aneurysm. The sizes of the proximal and distal lobules of the aneurysm were 3.9 mm (height) x 3.8 mm (width) and 4.9 mm (height) x 4.8 mm (width) respectively with the neck measuring 3 mm (**Figure 4a**). Endovascular embolization was the elected treatment option as agreed by the neurosurgeon and interventional neuroradiologist. To facilitate treatment of this broad-necked complex aneurysm, we decided for balloon-assisted coiling.

Under general anesthesia, bilateral common femoral arteries approaches were performed. Two guiding catheters (NeuroPath; Micrus, USA and Envoy; Stryker, USA) were placed in both vertebral arteries for separate introduction of balloon- microcatheter and coiling- microcatheters (Headway 17; Microvention). A semi-compliant non-detachable balloon (Scepter C 4mm x 10mm; Microvention, USA) was advanced into the left posterior cerebral artery (PCA) across the aneurysm neck while the coiling-microcatheter tip was positioned inside the aneurysm's sac (**Figure 4b**). The balloon was inflated intermittently of not more than 2 minutes each time, under fluoroscopic guidance, to guard the coil from prolapsing into the parent artery, during coil deployment. Post procedural angiography demonstrated stable coil with minimal residual neck (**Figure 4c**). The patient was transferred out to the intensive care unit in stable condition and was discharged home 2 days later.

### Mycotic Aneurysm at M4 Segment

A 50 year-old male with known case of mitral valve replacement, presented with intracerebral haematoma and SAH. Clot evacuation performed. In view of non-typical location of intracerebral haematoma, SAH and previous history of valve replacement, ruptured mycotic aneurysm was suspected (**Figure 5a**). We proceeded with cerebral angiogram, which showed distal right M4 segment aneurysm (**Figure 5b**). Due to the distal location of the aneurysm, we decided to



**Figure 4.** (a) DSA showing complex broad neck bilobed basilar tip aneurysm; (b) Post embolization show complete occlusion noted, with coil mass occupying the bilobed aneurysm and pattern both PCA

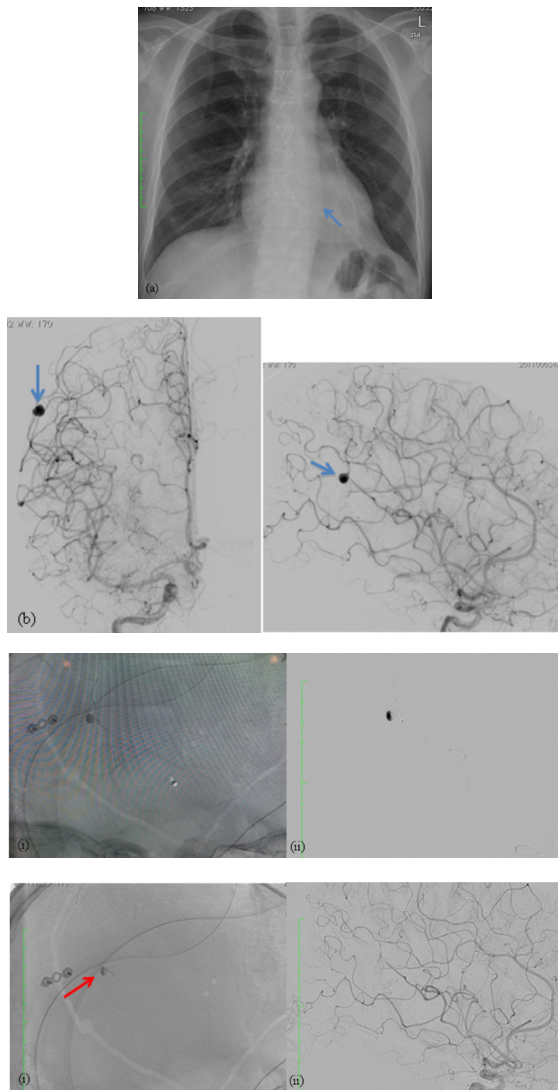
occlude the aneurysm including the parent artery using liquid embolic material.

We use flow-guided microcatheter (Magic 1.5F; Balt, France) to navigate the distal parent artery with aneurysm. We placed the microcatheter tip at the junction of the aneurysm and the parent artery (**Figure 5c**). We then injected hystoacryl glue with dilution of 1:3 under intermittent fluoroscopy over a period of 3 minutes until the glue occupied the aneurysm and reflux partly into the parent artery. Post procedural angiography showed occluded parent artery with glue cast within the aneurysm sac (**Figure 5d**). Patient was well with no further intracranial hemorrhage and was discharged after day 14 of procedure.

### DISCUSSION

The true incidence and prevalence of intracranial aneurysms are difficult to estimate and there are marked prevalence variations worldwide. Generally it is thought that the prevalence of intracranial aneurysm in the general population is approximately 6% with higher occurrence in Asian population.<sup>6</sup> The most





**Figure 5.** (a) Chest radiograph showing the artificial valve; (b) DSA showing distal M2 segment of MCA mycotic aneurysm; (c) (i) Distal cannulation with microcatheter tip at the junction of the aneurysm, DSA, (ii) Un-subtracted image; (d) (i) Hystoacryl glue cast post embolization (red arrow); (ii) DSA showing complete obliteration of the mycotic aneurysm without significant perfusion defect

common clinical presentation of intracranial aneurysms described in the literature is the SAH (80%).<sup>9,10</sup> Collective data regarding incidence of cerebral aneurysm and SAH in Indonesia is limited. Jusuf and Wedra reported the incidence of SAH in Indonesia is estimated to be 1.4% based on their study of acute stroke in 28 hospital in Indonesia.<sup>8</sup> The reported annual incidence of SAH in Malaysia is estimated to be 3 to 4 per 100,000 population, with aneurysm accounting for 1.1-1.7 per 100,000 population.<sup>7</sup> The most common sites for intracranial aneurysms are the anterior communicating artery (30–35%),

posterior communicating artery (30–35%) and the bifurcation of the middle cerebral artery (20%).<sup>10</sup>

In our opinion, endovascular treatment (EVT) should be considered as an important option for treatment of intracranial aneurysm. Majority of medical centres worldwide even consider EVT as the first line of treatment for most ruptured brain aneurysm cases. The outcome, complication rates and treatment success are better than other treatment options.<sup>9,11</sup> Nowadays various techniques have been employed to treat more complicated aneurysm like wide neck aneurysms or fusiform aneurysms using balloon-assistance or intracranial stents.<sup>12,13</sup> However, aggressive and risky endovascular treatment should not be performed at the cost of increasing morbidity and mortality risks.

Coiling of aneurysm is performed under live fluoroscopy guidance. The sheath and guiding catheter are continuously flushed with heparinized saline. For effective coiling, the tip of the microcatheter ideally should be at the center of aneurysm and not against the wall. Typically few working projections are used and changed accordingly to achieve optimal visualization of the parent artery, microcatheter tip and aneurysm. The selection of the first coil is crucial because it determines the optimal aneurysm packing. The aneurysm is then densely packed with softer coils of decreasing diameter, until no more coils can be deployed into the aneurysm. Wide-necked aneurysms, generally defined as having a dome-to-neck ratio of  $<2:1$  can be difficult to treat with coiling alone. Several strategies exist to coil wide-necked aneurysms using adjunctive techniques. Balloon-assisted coiling technique introduced by Moret, is performed by temporarily inflating a balloon across the aneurysm neck to prevent coil protrusion into the parent artery.<sup>14</sup>

Parent artery that is too small to accommodate balloon can also be temporarily protected using microcatheter.<sup>15</sup> Advancement in stent technology is significant for the betterment in endovascular treatment strategy. Basically a stent is a metal mesh device in the shape of a pipe or tube, which is placed inside the parent artery at the site of the aneurysm to cover the neck of the

aneurysm. This helps to maintain the deployed coils within the aneurysm sac. The stents are usually made of nitinol, a high grade metal alloy of nickel and titanium mixture. Placement of intracranial stent necessitates pretreatment and long term antiplatelet therapy to prevent in-stent thrombosis.

## CONCLUSION

Endovascular treatment is rapidly becoming a mainstay of treatment for intracranial aneurysms. With development of advanced medical devices, improved image guided tools and more refined endovascular experience, various endovascular techniques are achievable not only to treat routine narrow neck saccular intracranial aneurysm, but also complex, wide neck and fusiform shape aneurysms. Endovascular treatment is technically proven to be feasible, safe and effective.<sup>9</sup>

## ACKNOWLEDGMENTS

The authors would like to express an appreciation towards Ms Farizwana Ridzwan for her technical help in preparing this manuscript. Also, an acknowledgment to Endovascular and Interventional Radiology Unit, Department of Radiology, UKM Medical Centre for the co-operation in all cases involved.

## REFERENCES

1. Nieuwkamp DJ, Setz LE, Algra A, Linn FH, de Rooij NK, Rinkel GJ. Changes in case fatality of aneurysmal subarachnoid hemorrhage over time according to age sex and region: a meta-analysis. *Lancet Neurol.* 2009;8:635–42.
2. Wagner M, Stenger K. Unruptured intracranial aneurysms: using evidence and outcomes to guide patient teaching. *Crit Care Nurs Q.* 2005;28:341–54.
3. The UCAS Japan Investigators. The natural course of unruptured cerebral aneurysms in a Japanese cohort. *N Engl J Med.* 2012;366:2474–82.
4. Higashida RT, Halbach VV, Dowd CF, Juravsky L, Meagher S. Initial clinical experience with a new self-expanding nitinol stent for the treatment of intracranial cerebral aneurysms: the Cordis Enterprise stent. *AJNR Am J Neuroradiol.* 2005;26:1751–6.
5. Machi P, Lobotesis K, Vendrell JF, Riquelme C, Eker O, Costalat V, Bonafe A. Endovascular therapeutic strategies in ruptured intracranial aneurysms. *Euro J Radiol.* Published Online First: 25 March 2013. doi: 10.1016/j.ejrad.2013.01.034.
6. Ellenbogen RG, Abdulrauf SI, Sekhar LN. Principles of neurological surgery: Expert consult – online and print. Philadelphia, PA: Elsevier Saunders; 2012. p. 84.
7. Chee CP. Subarachnoid haemorrhage, aneurysm and arteriovenous malformation: a review of Malaysian and South East populations. *Neurol J Southeast Asia.* 1998;3:51–5.
8. Misbach J, Ali W. Stroke in Indonesia: a first large prospective hospital-based study of acute stroke in 28 hospitals in Indonesia. *J Clin Neuroscience.* 2001;8:245–9.
9. Molyneux AJ, Kerr RS, Yu LM, Clarke M, Sneade M, Yarnold JA, Sandercock P. International Subarachnoid Aneurysm Trial (ISAT) of neurosurgical clipping versus endovascular coiling in 2143 patients with ruptured intracranial aneurysms: a randomised comparison of effects on survival, dependency, seizures, rebleeding, subgroups, and aneurysm occlusion. *Lancet.* 2005;366:809–17. doi: 10.1016/S0140-6736(05)67214-5.
10. Muda AS, Izwan ZZ, Rozman Z, Jegan T, Azizi AB. Endovascular treatment of cerebral aneurysm: early in a Malaysian tertiary centre. *J Surg Acad.* 2011;1:57–63.
11. Andreou A, Ioannidis I, Mitsos A. Endovascular treatment of peripheral intracranial aneurysms. *AJNR.* 2007;28:355–61.
12. Chitale R, Chalouhi N, Theofanis T, et al. Treatment of ruptured intracranial aneurysms: comparison of stenting and balloon remodeling. *Neurosurg.* 2013;72:953–9.
13. Chalouhi N, Jabbour P, Singhal S, et al. Stent-assisted coiling of intracranial aneurysms: predictors of complications, recanalization, and outcome in 508 cases. *Stroke.* 2013;44:1348–53.
14. Moret J, Cognard C, Weill A, Castaing L, Rey A. Reconstruction technique in the treatment of wide-neck intracranial aneurysms. Long-term angiographic and clinical results: apropos of 56 cases. *J Neuroradiol.* 1997;24:30–44.
15. Shin YS, Kim DI, Lee SI, Chung JI, Yoon PH, Lee KC. The usefulness of the new “double-catheter technique” in the treatment of parent artery incorporated wide-necked aneurysm with Guglielmi detachable coils. Technical notes. *Interv Neuroradiol.* 2000;6:61–4.