

## Practical Guidelines Management of Graves Ophthalmopathy

*Imam Subekti<sup>1</sup>, Pradana Soewondo<sup>1</sup>, Suharko Soebardi<sup>1</sup>,  
Budiman Darmowidjojo<sup>1</sup>, Dante S. Harbuwono<sup>1</sup>, Dyah Purnamasari<sup>1</sup>,  
Tri J. E. Tarigan<sup>1</sup>, Wismandari Wisnu<sup>1</sup>, Dicky L. Tahapary<sup>1</sup>,  
Farid Kurniawan<sup>1</sup>, M. Sidik<sup>2</sup>, Syntia Nusanti<sup>2</sup>, Salmarezka Dewiputri<sup>2</sup>,  
Hernawita Suharko<sup>2</sup>, Gusti G. Suardana<sup>2</sup>, Indrati Suroyo<sup>3</sup>, Vally Wulani<sup>3</sup>,  
Alvita D. Siswoyo<sup>4</sup>, Soehartati Gondhowiardjo<sup>5</sup>, Henry Kodrat<sup>5</sup>*

<sup>1</sup> Department of Internal Medicine, Faculty of Medicine Universitas Indonesia - Cipto Mangunkusumo Hospital, Jakarta, Indonesia.

<sup>2</sup> Department of Ophthalmology, Faculty of Medicine Universitas Indonesia - Cipto Mangunkusumo Hospital, Jakarta, Indonesia.

<sup>3</sup> Department of Radiology, Faculty of Medicine Universitas Indonesia - Cipto Mangunkusumo Hospital, Jakarta, Indonesia.

<sup>4</sup> Department of Radiology, Faculty of Medicine Universitas Indonesia - Cipto Mangunkusumo Hospital, Jakarta, Indonesia.

<sup>5</sup> Department of Radiotherapy, Faculty of Medicine Universitas Indonesia - Cipto Mangunkusumo Hospital, Jakarta, Indonesia.

### **Corresponding Author:**

*Prof. Imam Subekti, MD., PhD. Division of Endocrinology and Metabolism, Department of Internal Medicine, Faculty of Medicine Universitas Indonesia - Cipto Mangunkusumo Hospital. Jl. Diponegoro no. 71, Jakarta 10430. Indonesia. email: imam.subekti@ui.ac.id.*

### **ABSTRAK**

*Oftalmopati Graves merupakan manifestasi ekstra-tiroid yang paling sering dijumpai pada pasien dengan penyakit Graves, yang didasari oleh kondisi inflamasi dan autoimun pada jaringan orbital. Panduan praktis ini dibuat oleh tim dengan anggota yang terdiri dari berbagai disiplin ilmu, dan diharapkan dapat memberikan panduan untuk pendekatan diagnosis dan tatalaksana oftalmopati Graves dalam praktek klinik sehari-hari untuk meningkatkan mutu pelayanan dan hasil pengobatan pada pasien.*

**Kata kunci:** oftalmopati graves, diagnosis, tata laksana.

### **ABSTRACT**

*Graves' ophthalmopathy is the most common extra-thyroid manifestation in patients with Graves' disease, based on inflammatory and autoimmune conditions in orbital tissue. This practical guideline was formed by a multidisciplinary team, and is intended to provide guidance for diagnosis and management of Graves' ophthalmopathy in daily clinical practice to improve quality of care and treatment outcome.*

**Keywords:** Graves' ophthalmopathy, diagnosis, management.

## INTRODUCTION

Graves' ophthalmopathy (GO) is one of the most common extra-thyroid manifestation of Graves' disease. Clinically visible manifestation of GO can be observed in approximately 25-50% of patients with Graves' disease.<sup>1</sup> However, when computed-tomography (CT) scan or orbital magnetic resonance imaging (MRI) was performed, GO can be detected in almost 90% of the patients.<sup>2</sup> According to Cipto Mangunkusumo National General Hospital, Jakarta, Indonesia in 2004, prevalence of Graves' disease in all patients with thyroid symptoms was 21%. About 32% of which presented with clinically visible eye abnormalities.<sup>3</sup> A study by Subekti et al. at Cipto Mangunkusumo National General Hospital, diagnosis of GO was made in 37.3% of patients coming to the hospital with clinical eye abnormalities and 83.6% of patients through orbital CT scans.<sup>4</sup>

In GO treatment, there is no guarantee that the eye abnormalities will improve along with the improvement of thyrotoxicosis. GO management was often not optimal because of the unstandardized parameters. Therefore, in order to achieve the desired treatment results, management of GO must include a comprehensive assessment of the clinical activity and severity of GO as well as the quality of life of patients.<sup>1</sup>

This practical guide is intended to provide guidance for primary care physicians/ doctors, specialists (internal medicine, eye, radiology, nuclear medicine, radiotherapy, surgery, etc.), specialist-consultants (endocrinology and

metabolism consultants, eye consultants, radiology consultants, nuclear medicine consultants, etc.), and related healthcare providers in the diagnosis and management of GO in order to improve quality of care and treatment outcomes.

## DEFINITION

Graves Ophthalmopathy (GO) is an inflammatory eye disease in the orbita, including its consequences, which are associated with autoimmune thyroid disease.<sup>5</sup>

## PATHOGENESIS

Genetic, environmental, and endogenous factors can change the characteristic of the TSH receptor, which causes B lymphocytes to produce antibodies against the TSH receptor (TSHR-Ab). The TSHR-Ab binds to the TSH receptor which causes hyperthyroidism leading to thyrotoxicosis as well as thyroid follicle cell hyperplasia leading to the development of goitre. TSHR-Ab also binds to TSH receptor in adipocytes and orbital fibroblast, thus initiates the secretion of proinflammatory cytokines by T cells and glycosaminoglycans (GAG) by fibroblasts. Proinflammatory cytokines can cause fibrosis, while accumulation of GAG contributes to the increase of volume of extraocular muscle, connective tissue, and orbital adipocytes.

## RISK FACTOR

**Table 1** showed risk factors for GO based on the American Thyroid Association (ATA) 2016.<sup>5</sup>

**Table 1.** GO risk factor<sup>5</sup>

Risk factor	Comments	Amenable to intervention
Age	Advanced age, have a higher risk for severe GO	No
Gender	GO is more frequent in women, but more severe in men	No
Genetic	Highest prevalence of GO in Caucasians, lowest in Asians. Immunomodulatory genes likely involved	No
Mechanical factors	Orbital lateral wall angle is wider in GO patients	No
TSHR-Ab	Predicts GO risk and treatment response	No
Smoking	Increases GO progression and decreases treatment efficacy	Yes
Thyroid dysfunction	Need for expeditious control of hyperthyroidism then prevention of hypothyroidism post graves disease therapy.	Yes
Radioactive Iodine (RAI) therapy	Risk is additive to smoking; increased with preexistent and active GO; preventable by glucocorticoids 6–12 weeks post RAI.	Yes

## DIAGNOSIS

### Clinical Features

The diagnosis of GO is established by the presence of ocular signs and symptoms. The ocular symptoms of GO are gritty sensation in the eyes, pressure or pain in the eyes (30%), double vision (17%), lacrimation/ photophobia (15-20%), and blurred vision (7.5%). The ocular signs of GO are conjunctival and eyelid edema, proptosis or exophthalmus, eyelid retraction (>90%), lid lag (50%), restrictive extraocular myopathy (40%), and optic nerve dysfunction (5%). Other clinical features includes pretibial myxedema (4%), acropachy (1%), and myasthenia gravis (<1%). In Graves' disease with typical eye abnormalities, diagnosis can be made without orbital imaging. Some ocular features of GO can be seen on **Appendix 1** ([www.actamedindones.org/index.php/ijim/article/view/1062/pdf\\_append](http://www.actamedindones.org/index.php/ijim/article/view/1062/pdf_append)).

### Imaging

Imaging modalities in GO are orbital CT scans and MRI. Orbital imaging is done to evaluate: (1) Non-characteristic/ asymmetrical eye abnormalities; (2) involvement/ compression of optic nerves; and (3) Orbital structures in preparation for decompression and rehabilitation surgeries. Orbital CT scan is not routinely performed in mild GO, unless there is complaint of diplopia or suspicion of other retroorbital abnormalities. Orbital imaging plays an

important role in the differential diagnosis and interdisciplinary management of GO patients. Extraocular muscle thickening has been found through CT scan in mild GO (grade 0 in NOSPECS classification).<sup>2</sup>

## CLASSIFICATION

GO classification is based on clinical activity score and degree of severity. Clinical activity and severity assessment are tools to choose the appropriate treatment options.

Clinical activity is clinical symptoms and signs that addresses the degree of inflammation. It is assessed using clinical activity score (CAS), which consists of active and inactive GO.

Degree of severity is clinical features of the eye associated with changes in anatomical structure, risk of sight-threatening GO, and quality of life. It is assessed using EuGOGO (European Group on Graves' Orbitopathy) criteria, which consists of mild, moderate-to-severe, and very severe GO. Assessment criteria can be seen in **Table 2** and **Table 3**.

Data obtained from the NOSPECS examination is then used to determine the severity of GO based on EuGOGO criteria.

## MANAGEMENT

Every GO patient needs to undergo a treatment program in order to achieve euthyroidism, smoking cessation, and local eye

**Table 2.** GO clinical activity score (CAS)<sup>1</sup>

CAS first examination, point 1-7:

1. Spontaneous retrobulbar pain
2. Pain on attempted upward or downward gaze
3. Swelling of eyelids
4. Redness of eyelids
5. Redness of conjunctiva
6. Swelling of conjunctiva (chemosis)
7. Swelling of caruncle or plica

Monitoring after 1-3 months, point 8-10:

8. Increase in measured proptosis >2 mm
9. Decrease in eye movement limit of >8o any direction
10. Decrease in visual acuity equal to 1 Snellen chart line

Note:

\*active GO = CAS  $\geq$ 3/7 in first examination or >4/10 on monitoring

\*inactive GO = CAS <3/7 in first examination or  $\leq$ 4/10 on monitoring

**Table 3.** GO degree of severity with NOSPECS<sup>1</sup>


---

<b>No signs or symptoms (degree of severity 0)</b>
<b>Only signs, no symptoms (degree of severity 1)</b>
Lid aperture (distance between lid margins in mm with patient looking in primary position, sitting relaxed, with distant fixation)
<b>Soft tissue involvement (degree of severity 2)</b>
Swelling/redness of the eyes
<b>Proptosis (degree of severity 3)</b>
Exophthalmos (in mm: using the same Hertel exophthalmometer and same intercanthal distance for an individual patient)
<b>Extraocular muscle involvement (degree of severity 4)</b>
Eye muscle ductions in degrees; subjective diplopia score:
- Intermittent (diplopia when tired or first awakening);
- Inconstant (diplopia at extremes of gaze);
- Constant (continuous diplopia in primary or reading position).
<b>Corneal involvement (degree of severity 5)</b>
Absent/ punctuate keratopathy, ulcer
<b>Sight loss (optic nerve involvement) (degree of severity 6)</b>
Best-corrected visual acuity, color vision, optic disk, relative afferent papillary defect, visual fields (if optic nerve compression is suspected)

---

**Table 4.** Assessment of GO severity based on EuGOGO<sup>1</sup>**Mild GO**

Mild GO manifestations have a minimum impact on the daily life. It usually appears in one or more of the following signs:

- Minor lid retraction (<2 mm)
- Mild soft-tissue involvement
- Exophthalmos <3 mm above normal for race and gender (women 18 mm, men 20 mm)
- No or intermittent diplopia
- Corneal exposure responsive to lubricants

**Moderate-to-severe GO**

Patients without sight-threatening GO with sufficient impact on the daily life, who need immunosuppression (if GO is active) or surgical intervention (if inactive). Two or more of the following sign usually appear:

- Lid retraction (≥2 mm)
- Moderate or severe soft-tissue involvement
- Exophthalmos ≥3 mm above normal for race and gender (women 18 mm, men 20 mm)
- Inconstant or constant diplopia

**Very severe GO (sight-threatening)**

Patients with dysthyroid optic neuropathy (DON) or sight-threatening corneal breakdown.

Rare cases: Eyeball subluxation, severe form of "frozen eye", choroidal folds, postural visual darkening.

---

care. Patients with mild GO that can be controlled with antithyroid drugs and local lubricants do not need to be referred to specialists. All GO patients with hyperthyroidism are treated to achieve euthyroidism by reducing either the synthesis of thyroid hormone through antithyroid drugs or the amount of thyroid tissue through radioactive iodine or total thyroidectomy. Patients with hyperthyroidism who get radioactive

iodine treatment and show risk factors for GO or patients with mild active GO can be given glucocorticoid prophylaxis.<sup>6</sup>

Approach in GO management includes non-pharmacological, pharmacological, rehabilitative surgery, and radiotherapy, based on the assessment of clinical activity and degree of severity (**Figure 1**).

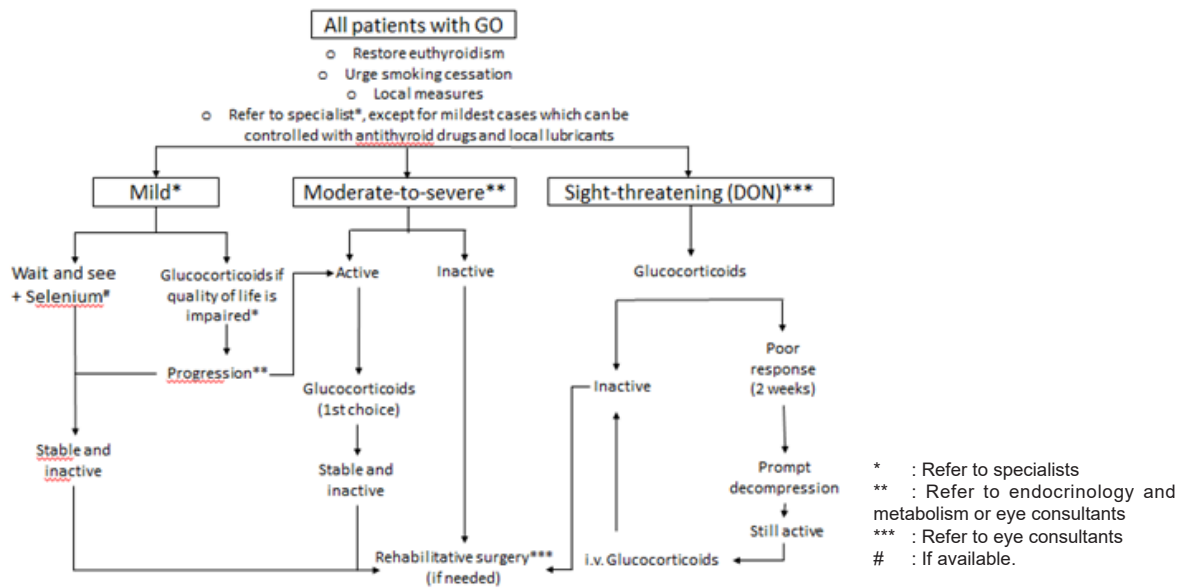


Figure 1. Management of GO<sup>1</sup>

**Topical Eye Care**

Dry eyes are treated with preservative-free artificial tear eye drops with osmoprotective agents and long-acting analgesics. If needed, it can be used several times a day to protect the surface and epithelium of the eyes and to control eye symptoms in the early stage of the disease. In the later stage, gel or ointment can be used, especially at night.<sup>1,7</sup> Elevating the head and closing the eyes using eye-tape at night can help prevent nocturnal corneal dryness.<sup>8</sup> Mild diplopia can be controlled with the use of prisms.<sup>8</sup> In addition, protective goggles can also be used to keep the eyes from foreign objects.

**Pharmacological Therapy, Rehabilitative Surgery, and Radiotherapy**

The choice of pharmacological therapy, rehabilitative surgery, and radiotherapy are based on clinical activity and degree of severity.

Glucocorticoids are the first choice on pharmacological therapy that can be given for clinically active GO. Glucocorticoids can be administered through oral, intravenous, or local route. Local administration of glucocorticoids through subconjunctival or retrobulbar injection is not recommended due to the risk of trauma and unproven effectiveness. Intravenous glucocorticoids have showed better response and improvement in clinical activity compared with oral administration. Some contraindications of methylprednisolone as part of GO therapy are

- (1) History of viral hepatitis (evidence of recent viral hepatitis);
- (2) Significant liver dysfunction;
- (3) Severe cardiovascular morbidity;
- (4) Uncontrolled hypertension;
- (5) Psychiatric disorders;
- (6) Uncontrolled diabetes.<sup>8,9</sup>

Proton pump inhibitors can be administered along with glucocorticoids to prevent peptic ulcers, and bone protection may be required, especially in patients high-risk for osteoporosis.

Side effects of high-dose oral glucocorticoids include cataracts, peptic ulcer, prolonged suppression of adrenal function, Cushing’s syndrome, hypertension, diabetes, osteoporosis, reactivation of chronic disease (such as tuberculosis), infection, and psychosis.<sup>8</sup>

If intravenous glucocorticoid administration is not possible, oral prednisone can be given for 12 weeks, with initial dose of 0.2 gram/day, gradually tapered down to and 0.01 gram/week (cumulative dose of 4 grams).<sup>10,11</sup>

There are several alternatives to glucocorticoids that are extensively studied, such as rituximab, anti-interleukin-6 (IL-6) tocilizumab receptor, and anti-insulin growth factor 1 receptor (IGF-1R) teprotumumab.<sup>12</sup> Rituximab is a second-line therapy that can be given to moderate-to-severe active GO who fail the initial therapy or show glucocorticoids resistance.<sup>13</sup> Tocilizumab is associated with ocular improvement, such as increase in visual acuity and decrease in intraocular pressure.<sup>14</sup>

Teprotumumab is a new immunosuppressive agents which can effectively reduce proptosis and improve clinical activity of GO.<sup>15</sup>

### Mild GO

In mild GO, the focus is to give a topical eye protection and control of the risk factors. When the impact of GO on quality of life exceeds the risk of therapy, intravenous glucocorticoids as immunosuppressive agents can be given to active GO and rehabilitative surgery for inactive GO.

Treatment of mild GO begins with observation and, if available, twice-daily selenium 100 mg for 6 months in order to improve eye symptoms and quality of life, as well as to prevent the progression of GO. In a controlled clinical trial, no side effects of selenium were shown in GO. Selenium is less effective in mild chronic inactive GO, thus if needed, rehabilitative surgery is more recommended.<sup>1</sup>

### Moderate-to-severe Active GO

High-dose systemic glucocorticoids are the first line of moderate-to-severe active GO. Intravenous glucocorticoids show 70-80% effectiveness, while oral administration only 50%. In addition, intravenous glucocorticoids show better tolerance than oral.

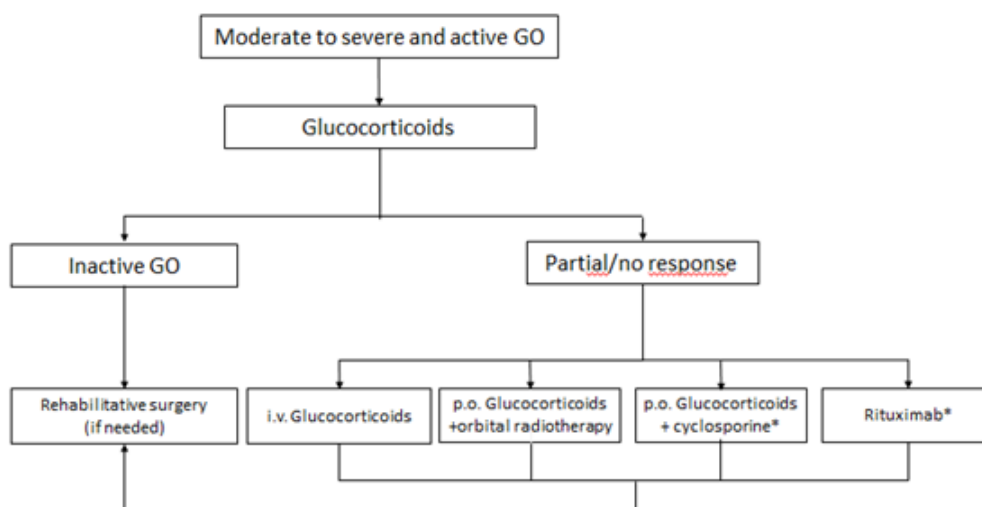
Moderate-to-severe active GO management and steps after 4 weeks of treatment can be seen in **Figure 2**.<sup>1,7</sup>

Methylprednisolone is given as much as 500 mg/day for 3 consecutive days, repeated every week for 4 weeks, so that the cumulative dose

of 6 grams is obtained. Glucocorticoid therapy as first line is generally effective for moderate-to-severe active GO.

If there is a partial or inadequate response to glucocorticoids, there are several therapeutic options:

1. Second course intravenous glucocorticoids if the patients show good tolerance in first course of glucocorticoids, but does not exceed 8 gram cumulative dose in the second course of administration
2. Combination of oral glucocorticoids and orbital radiotherapy
  - Orbital radiotherapy shows potential to provide a synergistic effect along with oral glucocorticoids.
  - Cumulative dose 20 Gy per eye divided into 10 daily doses given over a period of 2 weeks, or a dose of 1 Gy per week for a period of 20 weeks, which has the same effectiveness and better tolerance.<sup>1</sup>
  - Mild transient exacerbation of ocular symptoms might occur and can be controlled with low-dose oral glucocorticoids.
  - Contraindications to radiotherapy in GO are history of retinopathy and/or uncontrolled diabetes.
  - Radiotherapy can be done using CT scan-based technique, such as 3-dimensional conformal radiotherapy (3DCRT), intensity modulated radiotherapy



**Figure 2.** Moderate-to-severe active GO treatment<sup>1</sup>



- (IMRT), or volumetric modulated arc radiotherapy (VMAT).
3. Combination of oral glucocorticoids and cyclosporine
    - Prednisone 100 mg/day gradually tapered down for 3 months, given in single or combination with cyclosporine with initial dose of 5 mg/kg/day for 12 months. Combination therapy is associated with better ocular outcome and lower rate of recurrence, or
    - Prednisone with initial dose of 60 mg/day with/or cyclosporine with initial dose of 7.5 mg/kg/day for 12 weeks. As many as 60% of patients who did not respond to single therapy show better response to combination therapy.
  4. Rituximab
    - Rituximab 1,000 mg given twice in two weeks, or rituximab 100 mg followed by injection of 500 mg single dose.
    - Side effects can be prevented by antihistamine premedication and 100 mg hydrocortisone. Side effects of periorbital edema and inflammation can also occur.
  5. Other therapies
    - Periocular triamcinolone injection 20 mg/week for 4 consecutive weeks show decrease in diplopia and the size of the extraocular muscle in newly active GO without local or systemic side effects.
    - Subconjunctival triamcinolone injection is effective in reducing swelling and mild retraction of the eyelids in new onset of GO, with transient elevation in IOP.<sup>1</sup>
    - If symptoms relapse after glucocorticoid doses tapered down or there is no clinical improvement after glucocorticoid administration, bromocriptine 1.25-7.5 mg/day gradually increased can be considered for 3-10 months single or in with glucocorticoid.<sup>1-5</sup>
    - Methotrexate is an alternative in case of glucocorticoid side effects, either 7.5-15 mg/week orally or 20 mg by subcutaneous injection.<sup>7,8</sup>

Choice of therapy mentioned above can be considered as second-line therapy. However, the

choice of therapy should be decided together in a multidisciplinary manner, taking into account the advantages and disadvantages for patients from various aspects.

#### **Moderate-to-severe Inactive GO**

Rehabilitative surgery is recommended in patients with GO who have significant altered visual function or quality of life after GO become inactive for at least 6 months. If more than one procedure of rehabilitative surgery is needed, the sequence of procedures is performed, namely decompression surgery, strabismus surgery, then periorbital and eyelids cosmetic surgery, since the prior procedure affect the latter.

- a. Orbital decompression surgery. Orbital decompression surgery is indicated in severe and persistent proptosis, especially if there is an inadequate response to glucocorticoid therapy and or orbital radiotherapy and if there is keratitis, and optic neuropathy due to suppression of the optic nerve.<sup>8</sup> Decompression surgery aims to reduce intraocular pressure, reduce exophthalmus, eyelids retraction, pain, reduce strabismus, and improve blurred vision due to orbital microvasculopathy and optic nerve.
- b. Strabismus surgery. Strabismus surgery aims to improve diplopia. This surgery is needed because extraocular muscle involvement often does not respond to drug therapy and worsens after orbital decompression surgery.
- c. Periorbital and eyelids cosmetic surgery. This surgery aims to repair the eyelids. Retraction of the upper and lower eyelids is a combination of the inflammatory and fibrotic process, adrenergic stimulation, as well as vertical rectus muscle restriction. In addition, exophthalmus also increases eyelids aperture.

#### **Very Severe GO**

Very severe GO caused by dysthyroid optic neuropathy (DON) and or exposure to the cornea or corneal damage is an emergency that requires immediate treatment. Eyeball subluxation can occur through the traction of the optic nerve with/without corneal damage.

First-line therapy in DON is intravenous glucocorticoids, for example single

methylprednisolone 500-1,000 mg for 3 consecutive days or intervals a day for 1 week. If the response is not good or there is deterioration in visual function, decompression surgery needs to be performed.<sup>1</sup>

## MONITORING

Initial response can predict a long-term response to glucocorticoid therapy. Things to consider in monitoring:

1. Glucocorticoids should not be used for more than 12 weeks with cumulative dose of methylprednisolone not exceeding 8 grams.
2. Blood glucose, liver function, and blood pressure should be controlled every month during therapy.
3. After cessation of glucocorticoids, it is necessary to monitor orbital vascular congestion that resembles active GO images, such as eyelid edema, eyelid or conjunctival redness, and chemosis, especially in patients with longer duration of illness.<sup>1,7</sup>

## QUALITY OF LIFE ASSESSMENT

GO management should be done through a “centered” approach to patients, which includes the effects of the disease and therapeutic effects on quality of life and psychosocial aspects of the patient (**Appendix 1**).

## REFERENCES

1. Bartalena L, Baldeschi L, Boboridis K, et al. The 2016 European Thyroid Association/European Group on Graves' Orbitopathy Guidelines for the Management of Graves' Orbitopathy. *Eur Thyroid J*. 2016;5:9–26.
2. Kartono D. Korelasi antara ketebalan otot ekstraokular pada CT scan orbita dengan derajat oftalmopati graves. FKUI. Jakarta; 2017.
3. Subekti I. Diagnosis dan pengelolaan oftalmopati Graves. Jakarta Endocrinology Meeting. Jakarta: Divisi Metabolik Endokrinologi, Departemen Ilmu Penyakit Dalam FKUI/RSCM; 2008. p. 30–5.
4. Subekti I. Hubungan TSH receptor antibody, thyroid stimulating antibody, dan thyroid blocking antibody dengan aktivitas klinis dan derajat keparahan oftalmopati graves. Fakultas Kedokteran Universitas Indonesia. Jakarta.; 2011.
5. Ross DS, Burch HB, Cooper DS, et al. 2016 American Thyroid Association Guidelines for Diagnosis and Management of Hyperthyroidism and Other Causes of Thyrotoxicosis. *Thyroid*. 2016;26(10):1343–421.
6. Kahaly GJ, Bartalena L, Hegedüs L, Leenhardt L, Poppe K, Pearce SH. 2018 European Thyroid Association Guideline for the Management of Graves' Hyperthyroidism. *Eur Thyroid J*. 2018;7:167–86.
7. Bahn RS, Burch HB, Cooper DS, et al. Hyperthyroidism and other causes of thyrotoxicosis: Management Guidelines of the American Thyroid Association and American Association of Clinical Endocrinologists. *Endocr Pr*. 2011;21(6):593–646.
8. Bartalena L, Marcocci C, Pinchera A. Treating severe Graves' ophthalmopathy. *Baillieres Clin Endocrinol Metab*. 1997;11(3):521–36.
9. Tu X, Dong Y, Zhang H, Su Q. Corticosteroids for Graves' ophthalmopathy: Systematic review and meta-analysis. 2018;2018.
10. Kahaly GJ, Pitz S, Hommel G, Dittmar M. Randomized, Single blind trial of intravenous versus oral steroid monotherapy in Graves' orbitopathy. *J Clin Endocrinol Metab*. 2005;90(9):5234–40.
11. Bartalena L, Baldeschi L, Dickinson A, et al. Consensus statement of the European Group on Graves' orbitopathy (EUGOGO) on management of GO. *Eur J Endocrinol*. 2008;158:273–85.
12. Wiersinga WM. Advances in treatment of active, moderate-to-severe Graves' ophthalmopathy. *Lancet Diabetes Endocrinol*. 2017;5(2):134–42.
13. Stan MN, Salvi M. Rituximab therapy for Graves' orbitopathy – lessons from randomized control trials. *Eur J Endocrinol*. 2017;176(2):R101-9.
14. Atienza-Mateo B, V.Calvo-Río, Martín-Varillas JL, Demetrio-Pablo R. Anti-IL6-receptor Tocilizumab in Graves orbitopathy. Multicenter study of 29 patients. *Sci Abstr*. 2018;SAT0601:1153–4.
15. Fleming JC, Dailey RA, Tang RA, et al. Teprotumumab for thyroid-associated ophthalmopathy. *N Engl J Med*. 2017;376(18):1748-61.