

CASE REPORT

A Rare Case Series of Ischemic Stroke Following Russell's Viper Snake Bite in India

Venkata K. Pothukuchi¹, Alok Kumar², Chennamsetty Teja¹, Archana Verma³

¹ Department of Internal Medicine, Siddhartha Medical College and Government General Hospital, Vijayawada, Andhra Pradesh, India.

² Department of Forensic Medicine and Toxicology, Uttar Pradesh University of Medical Sciences, Saifai, Etawah, India.

³ Department of Neurology, Uttar Pradesh University of Medical Sciences, Saifai, Etawah, India.

Corresponding Author:

Prof. Alok Kumar, MD. Department of Forensic Medicine and Toxicology, Uttar Pradesh University of Medical Sciences, Saifai, Etawah. 206130 (U.P.), India. email: drsalok@rediffmail.com.

ABSTRAK

Gigitan ular adalah masalah medis yang utama di India. Di antara berbagai manifestasinya, komplikasi serebral jarang ditemukan pada literatur. Terlebih lagi, stroke iskemik akibat gigitan ular cukup langka. Kami melaporkan serangkaian kasus dari dua kasus serupa yang mengembangkan manifestasi neurologis setelah gigitan ular viper Russell. Pada pemeriksaan CT scan menunjukkan infark serebral. Kemungkinan mekanisme penyebab kejadian yang mencakup koagulasi intravaskular diseminata, toksin yang diinduksi vaskulitis, dan kerusakan endotel akan dibahas pada artikel ini.

Kata kunci: strok iskemik, infark serebral, ular viper Russell, gigitan ular.

ABSTRACT

Snakebite is an important medical problem in India. Among their various manifestations, cerebral complications are uncommonly found in literature. Moreover, Ischemic stroke following snake bite is quite rare. Here we report a case series of two such cases that developed neurological manifestations following Russell's viper bite. On computerized tomography (CT) scan of brain; cerebral infarcts were revealed. Their likely mechanisms are discussed in present study which include disseminated intravascular coagulation, toxin induced vasculitis and endothelial damage.

Keywords: ischemic stroke, cerebral infarct, Russell's viper, snake bite.

INTRODUCTION

Over 20,00,000 cases of snake bites are reported annually in India, among them 35,000 to 50,000 people die.^{1,2} Russell's viper (*Vipera russelli siamensis*), is widely distributed and responsible for most of the fatalities of snake bite in India.^{2,3}

Its envenoming causes multiple local and systemic manifestations including severe local bite site injury, cellulitis, neuroparalysis, coagulopathy, acute kidney injury (AKI),

renal failure, generalized rhabdomyolysis, shock, spontaneous systemic bleeding, and hemorrhagic manifestations including pituitary and intracranial hemorrhage.³ Very often, the neurological manifestations confine only to cranial nerves commonly causing ptosis and external ophthalmoplegia.

Only very few cases of ischemic stroke due to snake bites have been reported, suggesting the mechanisms such as toxic vasculitis causing endothelial injury leading to thrombosis,

hypotension and hypercoagulability state.⁴ Here, we are presenting two cases of an unusual complication, cerebral infarction following Russell's viper bite.

CASE ILLUSTRATION

Case 1

A 70-year-old, previously healthy male was admitted in emergency department with a history of snake bite on right foot one day back, when he was walking in his garden. The offending snake was killed by his neighbors and later on identified as Russell's viper. He presented with a history of bleeding gums, blackish colored urine, decreased urine output and swollen right foot. On examination, patient was conscious and coherent but bilateral ptosis was noted without any other focal neurological deficits and bleeding manifestations. His 20 minute whole blood clot test (20 WBCT) and urine albumin test was positive with raised serum creatinine (2.5 mg/dl). Patient was treated with 20 vials of anti-snake venom (ASV) along with repeated doses of Neostigmine 0.5 mg I/M half hourly and atropine 0.6 mg I/V till ptosis was recovered. Antibiotic coverage along with Tetanus toxoid was also given. Patient was improving but on the 4th day, he had a seizure attack followed by involuntary movement of right upper limb along with decreased power of the right upper limb and lower limb for which he was treated with levetiracetam 500 mg tablet orally twice daily. His computerized tomogram (CT) scan of the brain was taken which revealed infarct in left capsuloganglionic area (**Figure 1**). Patient was treated with clopidogrel 75 mg per day orally. Power was improved and patient was later discharged on 12th day.

Case 2

A previously healthy male of 55 years was admitted for a snake bite on his left foot, sustained during working in his fields. The snake was later killed and identified as Russell's viper. He presented with severe pain along with two deep fang marks, erythema and edema. There were no other hemorrhagic or neurological manifestations, but Twenty minute whole blood clotting test (20 minute WBCT) was positive.

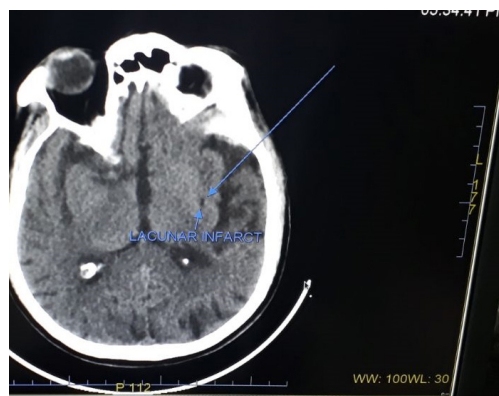


Figure 1. CT Brain showing acute infarcts in left capsuloganglionic area.

He was immediately treated with 30ml loading dose of equine polyvalent antivenom (ASV-ASIA, Bharat Serum and Vaccines Ltd.), followed by continuous intravenous administration of 30ml of anti-snake venom in normal saline. While receiving treatment, he developed ptosis, immediately 10 vials of ASV was given as infusion followed by again 10 vials of ASV as infusion after 1 hour along with Neostigmine 0.5 mg I/M half hourly and atropine 0.6 mg I/V till improvement. Tetanus toxoid was given and a course of antibiotic injection of Ceftriaxone was also started. On the next day also further 5 vials of ASV was given as infusion along with tapering doses of atropine and neostigmine as 20 minute WBCT was still positive, which normalized on the 3rd day. However, another dose of 10 vials of ASV was given on that day. Initial laboratory investigations revealed that blood sugar was 100mg/dl, blood urea was 60 mg/dl, serum bilirubin was 2.3 mg/dl, serum creatinine was 1.6 mg/dl, alanine transaminase was 38 IU, aspartate transaminase was 89 IU and alkaline phosphatase was 69IU/Lt.

On the seventh day, patient developed left side weakness and speech disturbances. Left hemiplegia and expressive aphasia was also revealed on neurological examination. Brain CT scan showed acute ischemic infarcts in bilateral frontal lobes. Lipid profile, Electrocardiogram, and Echocardiogram were normal. Patient was treated with aspirin and clopidogrel orally. There was remarkable improvement in the motor power and speech on discharge at the tenth day.

DISCUSSION

This paper describes two cases of snake bite with an atypical clinical presentation. Cerebral complications, particularly ischemic complications, after snake bite are rare. Very few cases of cerebral infarction resulting from a viper bite have been reported.⁵⁻⁷ In a study including 309 snake bite patients, Mosquera, et al.⁵ reported cerebrovascular complications in 8 patients (2.6%) only, 7 hemorrhagic strokes and 1 ischemic stroke. Bashir and Jinkins reported a case in whom Russell's viper envenomation resulted in hemiplegia and aphasia, consistent with bilateral frontal lobe infarction.⁶ similarly; Murthy, et al.⁷ reported a case of cerebral infarction and diffuse encephalopathy following a viper bite.

Viper snake venom is a complex toxin with rich components dominantly affecting hemostatic mechanisms.⁸ In large doses, it can cause massive intravascular coagulation leading to small and even large vessel occlusions resulting in cerebral infarction.⁹ Toxic vasculitis caused by certain viperine species may result in thrombosis.⁷ Bashir and Jinkins⁶ suggested direct action of the venom on vascular endothelial cells. Hemorrhagins, the complement mediated, toxic components of Viperidae snake venom may result in severe vascular spasm, endothelial damage and increased vascular permeability all of which may contribute to vascular occlusion.⁷ Hypercoagulation due to procoagulants in the venom, such as arginine, esterase and hydrolase^{6,7} and hyperviscosity caused by hypovolemia and hypoperfusion secondary to hypotension may also contribute to vessel occlusion.

Our patient had both neurological (ptosis) and hematological manifestations (20WBCT positive). Some of the Russell's viper bite from south India has produced neuroparalysis with incoagulable blood.¹⁰ In India whole blood clotting time of more than 20 min is virtually diagnostic of viper bite and rules out elapid bite.^{10,11} Systemic spontaneous bleeding and 20 minutes whole blood clotting test (20WBCT) are bedside tests to know systemic envenomation in viper bite. When there is no systemic envenomation the case should be observed for 24 hrs clinically and with repeated 20WBCT

before discharged.^{10,12}

The patients developed cerebral infarction after 7 days, fairly similar to a report of an adolescent who developed bilateral posterior circulation stroke after 1 week of snake bite.¹³ They concluded that stroke was probably due to toxic vasculitis or toxin-induced vascular spasm and endothelial damage.¹³ Ranawaka UK et al¹⁴ stated in their article that there was no agreed time cut-off for classifying neurological manifestations into "acute" and "delayed. Serum sickness type reactions develop in 1 to 12 days after antivenom therapy (mean 7 days). Clinical features include fever, nausea, arthralgia, myalgia, arthritis, mononeuritic multiplex, recurrent urticaria, lymphadenopathy, neuritis and even encephalopathy. They usually respond to oral antihistamine.^{10,11} but in our case, there were no such features and patient was improved with aspirin and clopidogrel.

It seems that the cerebral infarction in our patients was the result of toxic vasculitis or toxin induced vascular spasm and endothelial damage as no other risk factors were present.

CONCLUSION

Following snake bite, emphasis should be given to the prompt diagnosis and treatment because the most important factor in determining survival following a severe envenomation is the amount of time elapsed between the bite and specific treatment. Early administration of ASV is essential to neutralize the maximum circulating venom before it is fixed in tissue. Therefore, it should be given to cases with evidence of systemic envenomation as early as possible.

REFERENCES

1. David AW. Guidelines for the clinical management of snake-bites in the south-east Asia region. New Delhi: World Health Organization, Regional Office for South East Asia; 2005. p. 1-67.
2. Warrell DA. Snake venoms in science and clinical medicine. Russell's viper: Biology, venom and treatment of bites. *Trans R Soc Trop Med Hyg.* 1989;83:732-40.
3. Narang SK, Paleti S, Azeez Asad M A, Samina T. Acute ischemic infarct in the middle cerebral artery territory following a Russell's viper bite. *Neurol India.* 2009;57:479-80.

4. Mugundhan K, Thruvarutchelvan K, Sivakumar S. Posterior circulation stroke in young male following snake bite. *J Assoc Physicians India*. 2008;56:713-4.
5. Mosquera A, Idrovo LA, Tafur A, Del Brutto OH. Stroke following Bothrops spp. snakebite. *Neurology*. 2003;60:1577-80.
6. Bashir R, Jinkins J. Cerebral infarction in a young female following snake bite. *Stroke*. 1985;16:328-30.
7. Murthy JM, Kishore LT, Naidu KS. Cerebral infarction after envenomation by viper. *J Comput Assist Tomogr*. 1997;21:35-7.
8. Marsh NA. Snake venom affecting haemostatic mechanism - A consideration of their mechanism, practical applications and biological significance. *Blood Coagul Fibrinolysis*. 1994;5:399-410.
9. Schwartzman RJ, Hill JB. Neurologic complications of disseminated intravascular coagulation. *Neurology*. 1982;32:791-7.
10. Biranchni Narayan Mohapatra, CBK Mohanty, Cuttack. Guidelines for Anti Snake Venom Therapy. *Medicine Update*. 2010;20:426-30.
11. Deshpande, Rushikesh Prabhakar, et al. Adverse drug reaction profile of anti-snake venom in a rural tertiary care teaching hospital. *J Young Pharmacists*. 2013;5(2):41-45.
12. Simpson ID. Snakebite Management in India, the first few hours: A guide for primary care physicians. *J Indian Med Assoc*. 2007;105:324-35.
13. Vale Thiago Cardoso, Leite Alysson Ferreira, Hora Priscila Ribeiro da, Coury Marayra Inês França, Silva Ricardo Cipriano da, Teixeira Antônio Lúcio. Bilateral posterior circulation stroke secondary to a crotalid envenomation: case report. *Rev Soc Bras Med Trop*. 2013;46(2):255-6.
14. Ranawaka UK, Lalloo DG, de Silva HJ. Neurotoxicity in snakebite-the limits of our knowledge. *PLoS Neglected Tropical Diseases*. 2013;7(10)e2302.