

The first report of direct skeletal attachment method applying for tibia prosthetic leg in a chicken by cortical screw

Piyabongkarn Damrongdej

Linthong Veterinary Clinic, 172 Ramkhamhaeng Road Minburi district Bangkok, 10510, Thailand

Article info

Received 21.10.2019

Received in revised form

29.11.2019

Accepted 02.12.2019

Correspondence author

Piyabongkarn Damrongdej

Phone: (66)814061396

E-mail: damrongdej10510@gmail.com

2019 Damrongdej P. This is an open-access article distributed under the terms of the Creative Commons Attribution License, which permits unrestricted use, distribution, and reproduction in any medium, provided the original author and source are credited.

Abstract

This is the first report of successful method for direct skeletal attachment for invent tibia prosthetic leg in a chicken amputee by using 3.0 mm stainless steel cortical screw as an intramedullary bone stem for right tibia endoprosthesis leg part and using acrylic with some part of endotracheal tube as an exoprosthesis leg part. This surgery was performed in a chicken amputee without bone cement using. A chicken could stand and sometime walk after 15 days of surgery. No complication problem with a screw's stump. This intramedullary bone stem technique by a screw can adapt using in other parts of long bone animal amputee. This technique can apply for invent endoprosthesis limb in other small animal amputees and can use intramedullary screw technique with other long bones such as femur, humerus, radius, and ulna because this technique uses only one stainless 316L screw so the surgery cost is not too much. The surgical procedure is not complicated and blood loss during surgery is not much so the risk for this technique is low.

Key words: chicken, endoprosthesis leg, direct skeletal attachment.



Contents

| | |
|---------------------------------|---|
| 1. Introduction | 3 |
| 2. Materials and methods | 3 |
| 3. Results and discussion | 5 |
| 4. Conclusions | 5 |
| References | 5 |

Citation:

Damrongdej, P. (2019). The first report of direct skeletal attachment method applying for tibia prosthetic leg in a chicken by cortical screw. *Ukrainian Journal of Veterinary and Agricultural Sciences*, 2(3), 3–5.

1. Introduction

Prosthetic limbs in veterinary medicine are limited use in chicken, cat and dog amputee but the most cases are exoprosthesis limb. Indication for limb amputation in veterinary surgery is severe trauma, ischemic necrosis, intractable orthopedic infection, congenital deformity, bone tumor (Fitzpatrick et al., 2011). In direct skeletal attachment method of limb prosthetic, a construct is implanted into an amputee's residuum bone and protrudes out of the residuum's skin (Pitkin, 2013). Direct skeletal attachment or osseointegrated implant are limited find in only dog and cat. Osseointegrated implant improves the ease of fixation of the exoprosthesis limb part to the amputation stump, reduce skin and soft tissue stump problems from prolong contact time between skin's stump with exoprosthesis limb part. The prosthetic leg in the chickens are found only exoprosthesis leg with skin's stump but no research literature appears about screw's stump endoprosthesis leg from direct skeletal

attachment method that is used in chicken. This is the first report about osseointegrated screw implant that is used as intramedullary stem for invent endoprosthesis leg and used acrylic and endotracheal tube for invent exoprosthesis leg in a chicken.

2. Materials and methods

Case presentation

A chicken weighted around 400 grams with severe lacerated wound on the right tibiotarsal joint for 3 days from a lizard bite (Fig. 1). After accident 3 days, a chicken owner did not want to amputate its. The first time of surgery, a tibiotarsal joint was repaired with 2.0 mm titanium plate, then the wound was cleaned every day with iodine solution and antibiotic cream (Fig. 2). Five days after wound dressing, the wound was changed to gangrenous septic wound. A right leg was amputated, then screw stump for endoprosthesis limb part was constructed.

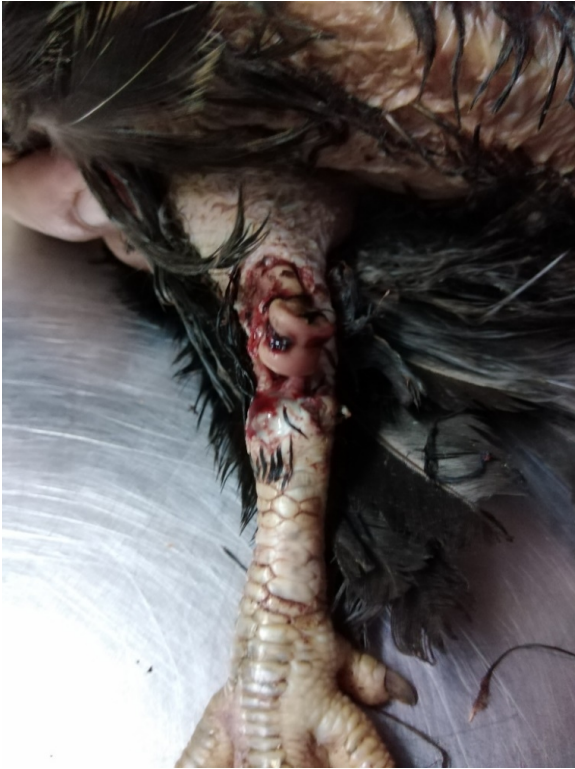

Fig. 1. The lacerated wound at tibiometatarsal joint

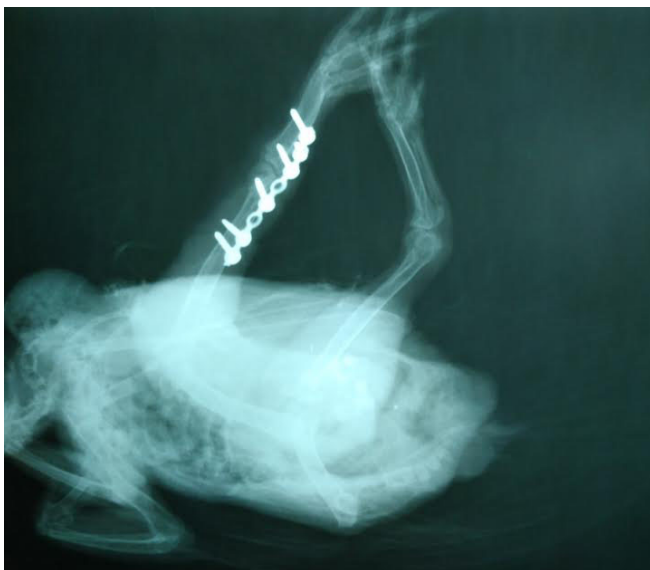

Fig. 2. Radiography showed 2.0 titanium maxillofacial plate was used for repair tibiometatarsal joint complete luxation

Surgical procedures for screw stump endoprosthesis limb part

A chicken was anesthetized with 4 % isoflurane by anesthetic mask. The skin, gastrocnemius muscle, and peroneus longus muscle were incised around the tibia until to found middle tibia. The tibia was transverse osteotomy at the site of middle tibia by oscillating saw. 3.0 mm stainless steel cortical screw with 4 cm in length was inserted to the residuum tibia until to proximal tibia but not penetrated to stifle joint. The muscles and skin were sutured by 3/0 chromic catgut and 3/0 nylon, consecutively, 2 cm of screw outside from the skin was screw's residuum for screw's stump (Fig. 3). The screw's stump was dressed every day until 10 days, the nylon sutures were removed from the stump.

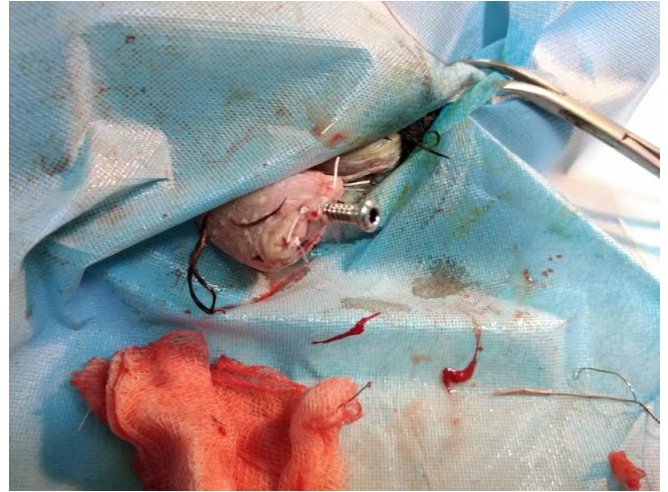

Fig. 3. Screw's stump as an endoprosthesis tibia leg part

Invention for exoprosthesis limb part

Two cm outside from screw's stump was remodeled to exoprosthesis limb part by using acrylic and endotracheal tube (Fig. 4, Fig. 5).

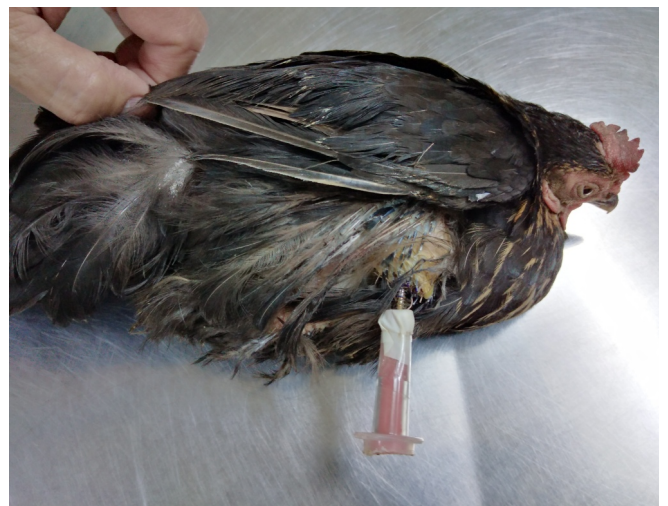

Fig. 4. Acrylic and some part of endotracheal tube as an exoprosthesis leg part was remodeled with screw's stump (endoprosthesis leg part)

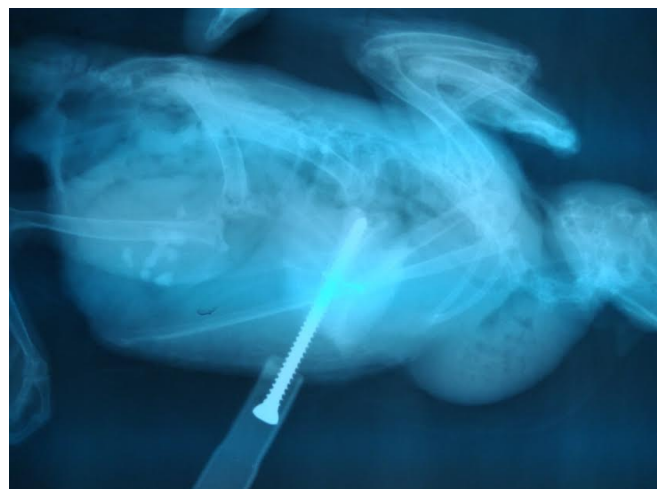


Fig. 5. Radiography showed endoprosthesis and exoprosthesis leg

3. Results and discussion

15 days after surgery, a chicken could be stand by both legs, walked in sometimes because may be in surgery procedure, a screw was inserted deep to stifle joint and damaged the joint that induced stifle joint inflammation but this problem can prevent by carefully screw insertion. 30 days after surgery a screw's stump was not showed sign of infection or inflammation. This is the first report of endoprosthesis leg in a chicken by using a screw to invention of screw's stump and no using of bone cement for fix the screw into tibia medulla. The exoprosthesis leg part by acrylic and endotracheal tube in this surgery was suitable in function and easy to operate but sometime, a chicken showed abnormal walking posture that maybe related the acrylic and endotracheal tube weight. This technique can apply for invent endoprosthesis limb in other small animal amputees and can use intramedullary screw technique with other long bones such as femur, humerus, radius, and ulna because this technique uses only one stainless 316L screw so the surgery cost is not too much. The surgical procedure is not complicated and blood loss during surgery is not much so the risk for this technique is low. In 2017, Fitzpatrick, N. et al., reported successful clinical outcome after use intraosseous transcutaneous amputation prosthetic in 4 dogs (Fitzpatrick et al., 2011). The literature of endoprosthesis limbs in animal are found in dog and cat. In chicken prosthetic leg reports are only exoprosthesis leg that were invented by 3D-printer but no appear endoprosthesis limb by screw's stump literature report. Skin's stump without endoprosthesis limb part can

induce stump infection due to stump interface exoprosthesis limb part. New design and new material for intramedullary stem such as titanium particles with a calcium-phosphate coating that are osteoconductive properties can lead to successful osseointegration limb prosthetic in human (Pitkin, 2013). The titanium screw can use instead of stainless-steel screw that it has low in weight and good in for osteoconductive properties.

4. Conclusions

3.0 mm cortical screw was a good intramedullary stem for tibia endoprosthesis leg in chicken. No complication from screw's stump after 30 days of surgery. The result showed a chicken could stand and walk in sometimes after 15 days of surgery. Direct skeletal attachment limb prosthetic by stainless steel screw is interesting choice for chicken amputee.

References

- Fitzpatrick, N., Smith, T. J., Pendegrass, C. J., Yeadon, R., Ring, M., Goodship, A. E., & Blunn, G. W. (2011). Intraosseous transcutaneous amputation prosthesis (ITAP) for limb salvage in 4 dogs. *Veterinary surgery*, 40(8), 909–925. doi: 10.1111/j.1532-950X.2011.00891.x.
- Pitkin, M. (2013). Design features of implants for direct skeletal attachment of limb prostheses. *Journal of biomedical materials research. Part A*, 101(11), 3339–3348. doi: 10.1002/jbm.a.34606.