

ISSN 0120-4157

Biomédica

Revista del Instituto Nacional de Salud

PUBLICACIÓN ANTICIPADA EN LINEA

El Comité Editorial de *Biomédica* ya aprobó para publicación este manuscrito, teniendo en cuenta los conceptos de los pares académicos que lo evaluaron. Se publica anticipadamente en versión pdf en forma provisional con base en la última versión electrónica del manuscrito pero sin que aún haya sido diagramado ni se le haya hecho la corrección de estilo.

Siéntase libre de descargar, usar, distribuir y citar esta versión preliminar tal y como lo indicamos pero, por favor, recuerde que la versión impresa final y en formato pdf pueden ser diferentes.

Citación provisional:

Rodríguez-Pérez EG, Arce-Mendoza AY, Saldívar-Palacios R, Escandón-Vargas K. Fatal *Strongyloides stercoralis* hyperinfection syndrome in an alcoholic, diabetic patient from Mexico. *Biomédica*. 2020;40 (Sp.1).

Recibido: 06-06-19

Aceptado: 14-01-20

Publicación en línea: 22-01-20

Fatal *Strongyloides stercoralis* hyperinfection syndrome in an alcoholic, diabetic patient from Mexico

***Strongyloides stercoralis* hyperinfection in a Mexican patient**

Síndrome de hiperinfección por *Strongyloides stercoralis* mortal en un paciente diabético y alcohólico de México

Elba G. Rodríguez-Pérez ¹, Alma Y. Arce-Mendoza ², Roberto Saldívar-Palacios ³, Kevin Escandón-Vargas ⁴

¹ Parasitología Clínica, Hospital Universitario Dr. José Eleuterio González, Universidad Autónoma de Nuevo León, Monterrey, México

² Departamento de Inmunología, Facultad de Medicina, Universidad Autónoma de Nuevo León, Monterrey, México

³ Departamento de Microbiología, Facultad de Medicina, Universidad Autónoma de Nuevo León, Monterrey, México

⁴ Escuela de Medicina, Universidad del Valle, Cali, Colombia

Corresponding author

Kevin Escandón-Vargas, Escuela de Medicina, Universidad del Valle, Calle 4B # 36 00, Cali, Colombia

Tel. (57 2) 5185652

kevin.escandonvargas@gmail.com

Authors' contributions

Kevin Escandón-Vargas performed the literature review and drafted the manuscript.

All authors contributed to the report design, interpretation of data and revised the manuscript for important intellectual content and gave final approval of the version to be published.

Strongyloides stercoralis hyperinfection syndrome is a medical emergency requiring a high level of suspicion. Immunocompromised patients are particularly at high risk of hyperinfection syndrome; however, malnutrition, alcoholism, and diabetes mellitus also need to be considered as predisposing factors. Diagnosis and treatment of *Strongyloides* hyperinfection are challenging, and patients with this disease often have severe complications. Consequently, mortality is overwhelmingly high, with rates above 60%. Herein, we report a case of *Strongyloides* hyperinfection in a 40-year-old alcoholic, diabetic patient, who lived in Mexico. Unfortunately, the late diagnosis resulted in fatality despite treatment and supportive measures. Increased awareness is needed to prevent the dire consequences of strongyloidiasis.

Keywords: *Strongyloides stercoralis*; strongyloidiasis; neglected diseases; Mexico.

El síndrome de hiperinfección por *Strongyloides stercoralis* es una emergencia médica que requiere mayor sospecha clínica. Los pacientes inmunocomprometidos tienen alto riesgo de síndrome de hiperinfección; sin embargo, la desnutrición, el alcoholismo y la diabetes mellitus también deben considerarse factores predisponentes. El diagnóstico y el tratamiento de la hiperinfección por *Strongyloides* son desafiantes, y los pacientes con esta enfermedad a menudo tienen complicaciones graves. Como consecuencia, la mortalidad es abrumadoramente alta, con tasas superiores al 60%. Aquí, presentamos un caso de hiperinfección por *Strongyloides* en un paciente diabético y alcohólico de 40 años, que vivía en México. Infortunadamente, el diagnóstico tardío causó su muerte a pesar del tratamiento y las medidas de soporte. Se necesita un mayor conocimiento para prevenir las terribles consecuencias de la estrongiloidiasis.

Palabras clave: *Strongyloides stercoralis*; estrongiloidiasis; enfermedades desatendidas; México.

Strongyloidiasis is a neglected parasitic disease mainly caused by *Strongyloides stercoralis*, and to a lesser extent, by *S. fuelleborni*. It is estimated to affect at least 370 million people worldwide, especially in tropical and subtropical regions (1,2). Although there is a lack of updated and comprehensive epidemiological data for *S. stercoralis*, strongyloidiasis is considered to be largely endemic to Mexico. In a few community- and hospital-based surveys, the prevalence of *S. stercoralis* has been estimated from 0.1% to 68% (3-5).

S. stercoralis has a complex life cycle with both free-living and parasitic developmental stages including autoinfection (1,6,7). Rhabditiform larvae (L1, usual diagnostic stage) are passed in the stool after hatching from eggs deposited in the intestinal mucosa of an infected definitive host (human or dog). These larvae develop directly or indirectly into filariform larvae (L3, infective stage) that penetrate the intact skin after contact with contaminated soil. Filariform larvae migrate via the bloodstream and lymphatics to the lungs, from where they ascend the tracheobronchial tree and are swallowed to reach the gastrointestinal tract. In the small intestine, larvae mature into adult female worms, which live embedded in the submucosa and produce eggs via parthenogenesis, yielding rhabditiform larvae. These larvae can either be excreted in the stool or can become filariform larvae and penetrate intestinal mucosa or perianal skin, resulting in autoinfection.

The unique life cycle of *S. stercoralis* is determinant for the presentation forms in infected persons. Infection ranges from asymptomatic to chronic symptomatic strongyloidiasis and to the severe/disseminated forms of the disease (7). Herein, we report a fatal case of *S. stercoralis* hyperinfection in a hypoalbuminemic, alcoholic, and diabetic patient from Mexico.

Case presentation

A 40-year-old Mexican-born male with a history of homelessness was admitted to a hospital in Monterrey, Mexico, for abdominal pain and vomiting of 2 weeks' duration. The patient complained of a 10 kg weight loss in the previous month. The patient originally came from a low-income area in Oaxaca and had been living in Monterrey for the last 5 years. He had a history of alcoholism and diabetes mellitus. He did not take any medications. On examination, he was afebrile, tachycardic, dehydrated, and with normal oxygen saturation. The pulmonary examination was unremarkable. He had a distended, slightly tender abdomen with diminished bowel sounds. His white blood cell count was 16,200/ μ L with 92.3% neutrophils and 0.66% eosinophils (107/ μ L). Hemoglobin was 10.4 g/dL and plasma glucose was 133 mg/dL. Hyponatremia and hypokalemia were noted. Serum total proteins and albumin were low (5.3 g/dL and 2.3 g/dL, respectively). An abdominal X-ray showed dilated small bowel loops suggestive of paralytic ileus. The initial treatment consisted of fluid resuscitation and placement of a nasogastric tube. On hospital day 3, his persistent ileus prompted the surgery service to perform a laparotomy. Over the next 48 hours, the patient presented shortness of breath, hemoptysis, and fever. A chest X-ray revealed bilateral diffuse interstitial infiltrates (Figure 1), and the patient was empirically started on imipenem/cilastatin and vancomycin for presumed bacteremia. Due to clinical worsening, he underwent bronchoscopy with bronchoalveolar lavage (BAL), which yielded a bloody lavage fluid from the right middle lobe. Pathological examination revealed numerous *S. stercoralis* filariform larvae (Figure 2). Subsequently, stool examination confirmed the presence of rhabditiform larvae (Figure 3). Human T-cell lymphotropic virus type-1 (HTLV-1) and

human immunodeficiency virus (HIV) serologies were negative. *S. stercoralis* larvae from BAL and feces provided diagnostic proof of hyperinfection syndrome.

On hospital day 10, the patient was started on oral ivermectin 12 mg daily; however, 2 days later, ivermectin was given per rectum owing to reduced oral intake. Later that day, the patient was taken to surgery for repair of omental evisceration.

Postoperatively, the patient continued to deteriorate and developed respiratory failure requiring mechanical ventilation. He was transferred to the intensive care unit, where he died despite treatment and supportive measures.

Informed consent for this publication and the accompanying images was obtained from the patient's nearest relative.

Discussion

Strongyloidiasis can present in a wide variety of forms. In immunocompetent hosts, *S. stercoralis* mostly causes asymptomatic chronic infections that may persist for decades because of the ability of the parasite to sustain itself by low-level autoinfection. Gastrointestinal and dermatologic complaints, when present, are usually mild and include abdominal pain, diarrhea, constipation, vomiting, anorexia, urticaria, and larva currens (1,7). In contrast, in immunocompromised hosts, *S. stercoralis* can cause severe, life-threatening conditions resulting from accelerated autoinfection: the hyperinfection syndrome, in which numerous larvae are confined to the autoinfective cycle (gastrointestinal tract, peritoneum, and lungs), and disseminated strongyloidiasis, which is characterized by larval migration to multiple organs beyond the range of the autoinfective cycle, including the liver, heart, kidneys, brain, and skin.

Cell-mediated immunosuppression can trigger the massive dissemination of *S. stercoralis* larvae. Several immunosuppression-related risk factors for *Strongyloides*

hyperinfection have been described, including the use of corticosteroids and other immunosuppressants, HTLV-1 infection, organ transplantation, and hematologic malignancies (1,7). Other predisposing factors are malnutrition, alcoholism, and diabetes mellitus (1,8,9). These 3 conditions were present in the patient reported. Interestingly, it has been postulated that the increased predisposition to *S. stercoralis* infection in alcoholics is related to reduced intestinal motility and increasing endogenous cortisol levels resulting in a deficient type 2 T helper cells (Th2) immune response as well as in ecdysteroid-mimicking effects (8,10).

The increased larval burden in hyperinfection syndrome explains the development or exacerbation of gastrointestinal and respiratory symptoms. Cough, dyspnea, wheezing, and hemoptysis are common. Fever and neurologic manifestations may be present and should prompt a search for sepsis and meningitis due to translocation of enteric bacteria facilitated by worm migration (7). Patients with *S. stercoralis* hyperinfection often have severe complications such as paralytic ileus, bowel obstruction, bacteremia, meningitis, respiratory failure, and multiorgan dysfunction (1). Consequently, mortality is overwhelmingly high with rates above 60% (1,7,11,12).

Diagnosis of hyperinfection syndrome requires a high level of suspicion. The detection of *S. stercoralis* filariform larvae in sputum or BAL fluid is the hallmark of hyperinfection syndrome (7). Contrary to asymptomatic and chronic forms of strongyloidiasis, microscopic examination of stool in patients with hyperinfection has increased sensitivity and often reveals numerous larvae (7,11). As seen in our case, eosinophilia is frequently absent in the hyperinfection syndrome (66-75%) (11,12).

The treatment of choice is ivermectin (200 µg/kg/day) based on its efficacy and favorable side-effect profile. Oral daily dosing is recommended for at least 2 weeks after parasite clearance from stools (7,13). Because many patients are critically ill or

experience paralytic ileus, enteral absorption may be impaired. Therefore, unorthodox administration routes (subcutaneous and rectal) have been attempted as adjunct or alternative to oral ivermectin. However, parenteral ivermectin is currently only available as a veterinary preparation and is not licensed for human use (14). There is a need for improved access to parenteral ivermectin and more data from pharmacological studies and clinical trials to guide treatment of severe strongyloidiasis.

In conclusion, *Strongyloides* hyperinfection syndrome is a medical emergency requiring a high level of suspicion. Immunocompromised patients are particularly at high risk of hyperinfection syndrome; however, malnutrition, alcoholism, and diabetes mellitus also need to be considered as predisposing factors. Since both diagnosis and treatment are challenging, patients frequently have poor outcomes. Our patient lived in an endemic area and had multiple risk factors for *Strongyloides* hyperinfection. Unfortunately, his ileus worsened shortly after the admission and the diagnosis was late, resulting in fatality despite treatment and supportive measures. This case highlights the importance of awareness and suspicion of strongyloidiasis in individuals with impaired immunity or underlying risk conditions, especially if present or past exposure to endemic areas is reported, as well as early diagnosis and treatment of hyperinfection syndrome.

Conflicts of interest

The authors declare no conflicts of interest.

Funding

The authors received no funding for this work.

References

1. Olsen A, van Lieshout L, Marti H, Polderman T, Polman K, Steinmann P, *et al.*

- Strongyloidiasis – the most neglected of the neglected tropical diseases? *Trans R Soc Trop Med Hyg.* 2009;103:967–72.
<https://doi.org/10.1016/j.trstmh.2009.02.013>
2. Bisoffi Z, Buonfrate D, Montresor A, Requena-Méndez A, Muñoz J, Krolewiecki AJ, *et al.* *Strongyloides stercoralis*: A Plea for Action. *PLoS Negl Trop Dis.* 2013;7:7-10. <https://doi.org/10.1371/journal.pntd.0002214>
 3. Guarner J, Matilde-Nava T, Villaseñor-Flores R, Sanchez-Mejorada G. Frequency of intestinal parasites in adult cancer patients in Mexico. *Arch Med Res.* 1997;28:219-22.
 4. Faulkner CT, Borrego Garcia B, Logan MH, New JC, Patton S. Prevalence of endoparasitic infection in children and its relation with cholera prevention efforts in Mexico. *Rev Panam Salud Pública.* 2003;14:31-41.
<https://doi.org/10.1590/S1020-49892003000600006>
 5. Carrada-Bravo T. *Strongyloides stercoralis*: ciclo vital, cuadros clínicos, epidemiología, patología y terapéutica. *Rev Latinoam Patol Clínica y Med Lab.* 2008;55:88-110.
 6. Viney ME, Lok JB. The biology of *Strongyloides* spp. *WormBook.* 2015;1-17.
<https://doi.org/10.1895/wormbook.1.141.2>
 7. Krolewiecki A, Nutman TB. Strongyloidiasis. *Infect Dis Clin North Am.* 2019;33:135-51. <https://doi.org/10.1016/j.idc.2018.10.006>
 8. Teixeira MCA, Pacheco FTF, Souza JN, Silva MLS, Inês EJ, Soares NM. *Strongyloides stercoralis* infection in alcoholic patients. *Biomed Res Int.* 2016;2016:4872473. <https://doi.org/10.1155/2016/4872473>
 9. McGuire E, Welch C, Melzer M. Is *Strongyloides* seropositivity associated with diabetes mellitus? A retrospective case-control study in an East London NHS

- Trust. *Trans R Soc Trop Med Hyg.* 2019;113:189-94.
<https://doi.org/10.1093/trstmh/try132>
10. Silva MLS, de J. Inês E, da S. Souza AB, dos S. Dias VM, Guimarães CM, Menezes ER, *et al.* Association between *Strongyloides stercoralis* infection and cortisol secretion in alcoholic patients. *Acta Trop.* 2016;154:133-8.
<https://doi.org/10.1016/j.actatropica.2015.11.010>
 11. Buonfrate D, Requena-Mendez A, Angheben A, Muñoz J, Gobbi F, Van Den Ende J, *et al.* Severe strongyloidiasis: a systematic review of case reports. *BMC Infect Dis.* 2013;13:78. <https://doi.org/10.1186/1471-2334-13-78>
 12. Geri G, Rabbat A, Mayaux J, Zafrani L, Chalumeau-Lemoine L, Guidet B, *et al.* *Strongyloides stercoralis* hyperinfection syndrome: a case series and a review of the literature. *Infection.* 2015;43:691-8. <https://doi.org/10.1007/s15010-015-0799-1>
 13. Henriquez-Camacho C, Gotuzzo E, Echevarria J, White AC, Terashima A, Samalvides F, *et al.* Ivermectin versus albendazole or thiabendazole for *Strongyloides stercoralis* infection. *Cochrane Database Syst Rev.* 2016;CD007745. <https://doi.org/10.1002/14651858.CD007745.pub3>
 14. Barrett J, Broderick C, Soulsby H, Wade P, Newsholme W. Subcutaneous ivermectin use in the treatment of severe *Strongyloides stercoralis* infection: Two case reports and a discussion of the literature. *J Antimicrob Chemother.* 2016;71:220-5. <https://doi.org/10.1093/jac/dkv315>

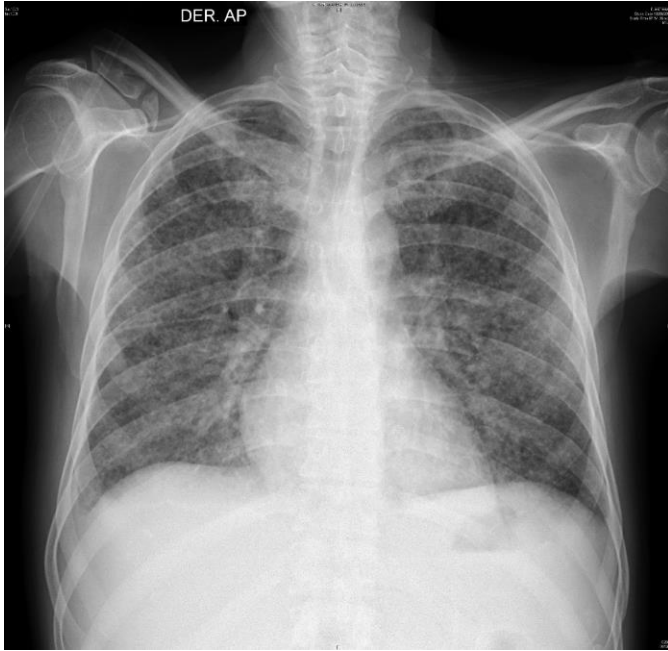


Figure 1. Chest x-ray showing bilateral diffuse interstitial infiltrates.

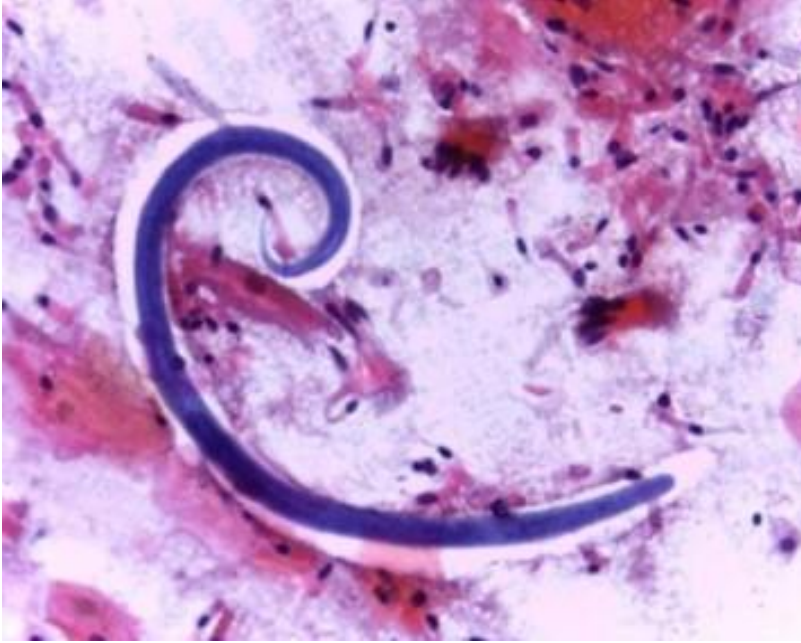

Figure 2. H&E stain on a bronchoalveolar lavage specimen showing a *Strongyloides stercoralis* filariform larva (100X).

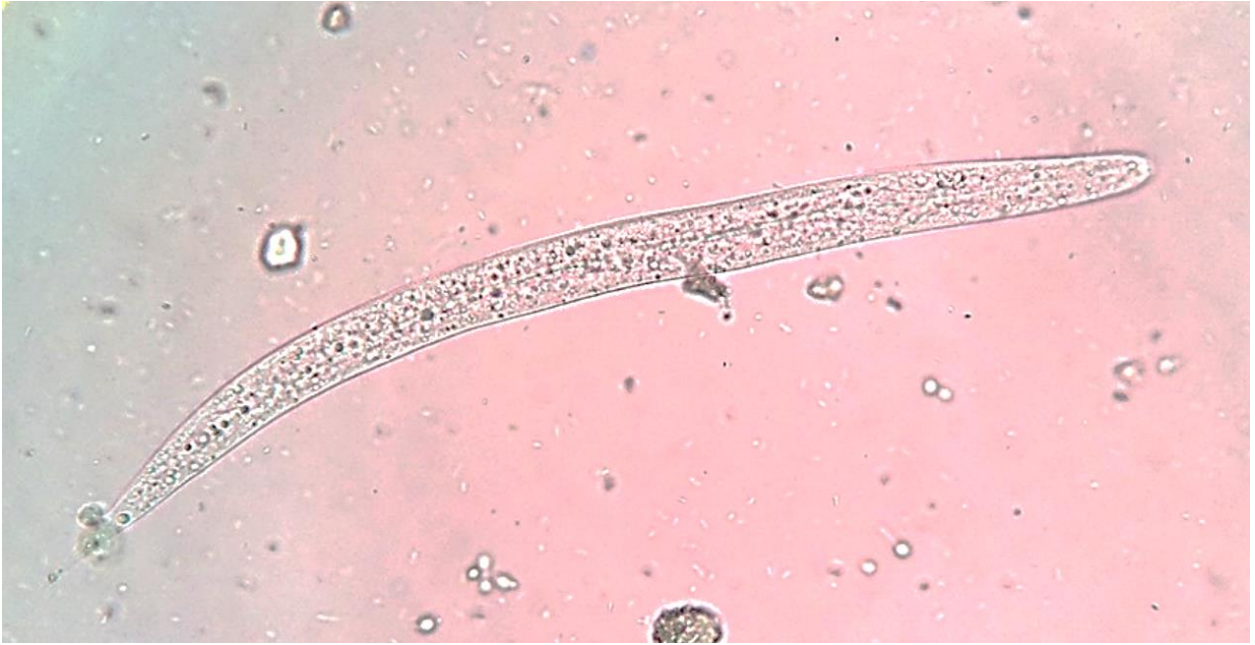

Figure 3. Wet mount of stool stained with methylene blue showing a *Strongyloides stercoralis* rhabditiform larva (100X). Rhabditoid esophagus can be appreciated.