

## CASE REPORT

### Adult onset of Immunoglobulin A vasculitis – A case report

Shusuke Yagi<sup>1,2,3</sup>, Itsuro Endo<sup>1,4</sup>, Taichi Murakami<sup>5</sup>, Tetsuya Hida<sup>1,6</sup>, Yousuke Yamamoto<sup>1</sup>, Tomohiro Soga<sup>1,3,7</sup>, Takayuki Ise<sup>2</sup>, Kenya Kusunose<sup>2</sup>, Koji Yamaguchi<sup>2</sup>, Daiju Fukuda<sup>2</sup>, Hirotsugu Yamada<sup>2</sup>, Takeshi Soeki<sup>2</sup>, Tetsuzo Wakatsuki<sup>2</sup>, Shinji Kawahito<sup>1,3,7</sup>, and Masataka Sata<sup>2</sup>

<sup>1</sup>Shikoku Central Hospital, Shikokuchuo, Ehime, Japan, <sup>2</sup>Department of Cardiovascular Medicine, Tokushima University Graduate School of Biomedical Sciences, Tokushima, Japan, <sup>3</sup>Department of Community Medicine and Human Resource Development, Tokushima University Graduate School of Biomedical Sciences, Tokushima, Japan, <sup>4</sup>Department of Hematology, Endocrinology and Metabolism, Tokushima University Graduate School of Biomedical Sciences, Tokushima, Japan, <sup>5</sup>Department of Nephrology, Tokushima University Graduate School of Biomedical Sciences, Tokushima, Japan, <sup>6</sup>Department of Dermatology, Tokushima University Graduate School of Biomedical Sciences, Tokushima, Japan, <sup>7</sup>Department of Anesthesiology, Tokushima University Graduate School of Biomedical Sciences, Tokushima, Japan

**Abstract :** Immunoglobulin A vasculitis (IgAV), formerly known as Henoch-Schönlein purpura, primarily occurs during childhood between the ages of 3 and 15 years and is the most common form of systemic vasculitis in children; its occurrence in adults has been rarely reported. Such low incidence could be attributable to either under-diagnosis or misdiagnosis. Thus, not only pediatricians but also physicians should be able to diagnose IgAV accurately to manage the patients appropriately and avoid its associated complications. In addition, treatment of adult onset IgAV with renal involvement has not been fully established yet. We describe here a case of adult onset IgAV complicated by proteinuria and pharyngitis, which was cured by no specific treatment. *J. Med. Invest.* 66:344-346, August, 2019

**Keywords :** Henoch-Schönlein purpura, palpable purpura, adult

#### INTRODUCTION

Immunoglobulin A vasculitis (IgAV), formerly known as Henoch-Schönlein purpura (1), primarily occurs during childhood between the ages of 3 and 15 years and is the most common form of systemic vasculitis in children, with it being diagnosed in over 90% of systemic vasculitis cases (1, 2, 3); its occurrence in adults has been rarely reported (4). Such low incidence could be attributable to either under-diagnosis or misdiagnosis.

Adult onset IgAV is known to be associated with worse renal outcomes in contrast to those in children, although the clinical manifestations have not been fully characterized (5, 6). Thus, not only pediatricians but also physicians should be able to diagnose IgAV accurately to manage the patients appropriately and avoid its associated complications. In addition, treatment of adult onset IgAV with renal involvement has not been fully established yet. To this end, we describe here a case of adult onset IgAV complicated by proteinuria and pharyngitis, which was cured by no specific treatment.

#### CASE

A 20-year-old man with a history of bronchial asthma presented at our hospital with nausea and had noticed skin eruptions on the lower extremities for the past 3 days (Figures 1A). He also had a sore throat for the past 5 days and fatigue in the knees and lower legs. Physical examination of the patient demonstrated palpable purpuric eruptions on the lower extremities (Figure 1) and a slight reddish throat. The patient's blood pressure was

122/68 mmHg, pulse, 98 per minute, and body temperature, 37.8°C. Blood examination indicated systemic inflammation with elevated white blood cells, 11900/μL and fibrinogen, 490 mg/dL, with a positive test for anti-streptolysin O antibody,

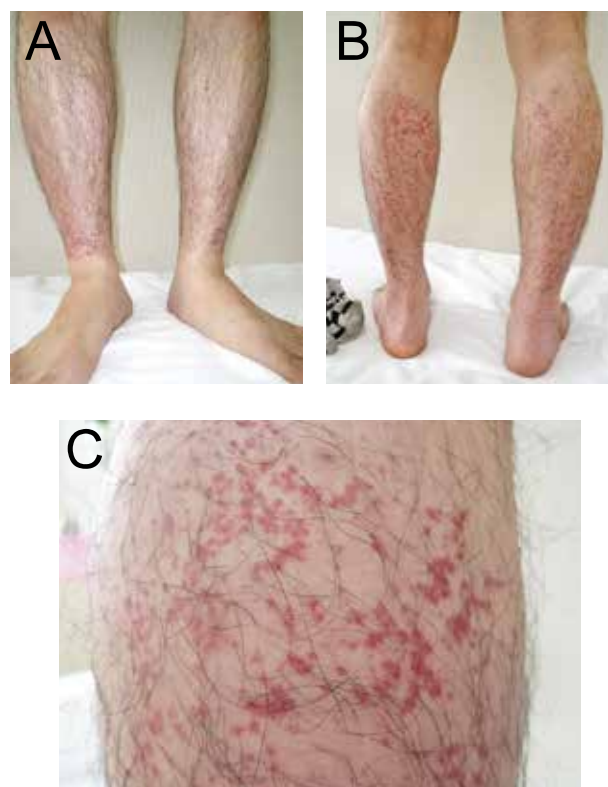

Figure 1. A : Images of palpable purpuric eruptions on the lower extremities (A : front, B: back, C : close image of a purpuric eruption)

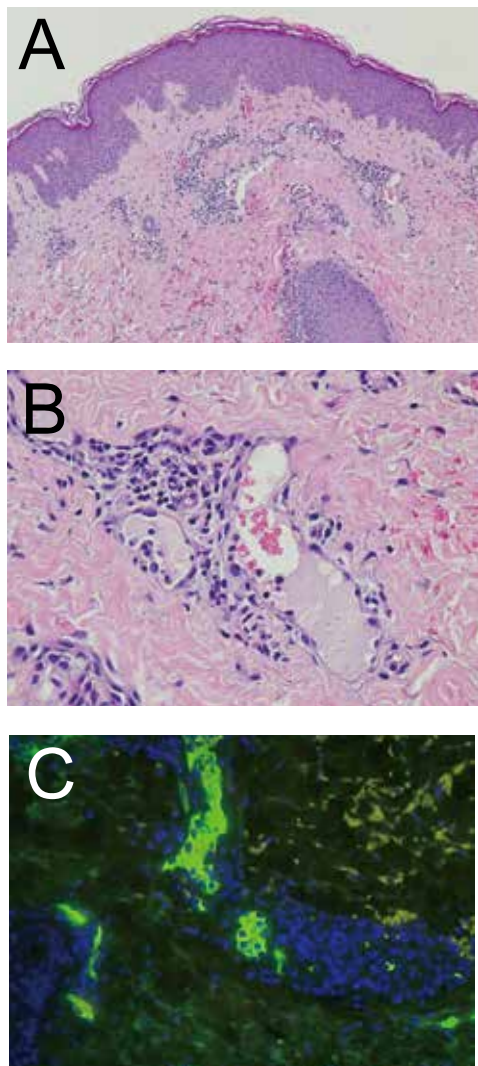
Received for publication December 6, 2018 ; accepted May 9, 2019.

Address correspondence and reprint requests to Shusuke Yagi, MD, PhD, Department of Cardiovascular Medicine, Tokushima University Graduate School of Biomedical Sciences, Tokushima, 3-18-15 Kuramoto-cho, Tokushima 770-8503, Japan and Fax : +81-88-633-7894.

suggesting bacterial infection with *Streptococcus pyogenes*, resulting in pharyngitis. Serum level of creatinine (0.7 mg/dL) was normal; however, urinalysis revealed proteinuria of 1+ without microscopic hematuria. His serum IgA levels were not elevated (317 mg/dL; normal range, 110–410 mg/dL). Factor XIII level was decreased to 43% (normal range, 70–140%). A skin biopsy showed inflammatory infiltrates around the superficial blood vessels but no nuclear dust and focal fibrinoid necrosis. Direct immunofluorescent staining of IgA showed IgA deposition in the vascular media indicating a diagnosis of IgAV.

According to the guidelines, we diagnosed him with possible IgAV due to palpable purpura with the biopsy showing granulocytes in the walls of small arterioles and venules, arthritis/arthralgia (acute onset), and renal involvement (proteinuria) although he was only 20 years of age and had not experienced any acute abdominal pain (7, 8).

He was administered 500 mg/day of acetaminophen. In 14 days, his symptoms and purpura completely disappeared, and he stopped visiting the hospital for follow-up. He reports feeling well one month after his visiting.



**Figure 2.** Microscopic findings of skin biopsy (hematoxylin and eosin staining) showing inflammatory infiltrate around the superficial blood vessels (A: low magnified image, B: high magnified image). Direct immunofluorescent staining showing IgA positive cells in the vascular media (Green: IgA deposition; Blue: nucleus stained with 4',6-diamidino-2-phenylindole)

## DISCUSSION

IgAV is a type of small vessel vasculitis mediated by IgA-immune complex deposition, which is characterized by the clinical tetrad of non-thrombocytopenic palpable purpura, abdominal pain, arthritis, and renal involvement, and is primarily a childhood disease. In a population-based study, the annual incidence was reported to be approximately 10–20 per 100,000 in children < 17 years of age, with a peak incidence of 70 per 100,000 in children between the ages of four to seven years (4, 9, 10). In contrast, IgAV is less common in adults (2.2 per 100,000) (11), although the annual incidence of IgAV in the young adults or elderly has not been completely elucidated because of heterogeneity of the study population. Recent retrospective studies showed that 25 to 30 percent of patients with IgAV were adults (5, 6), indicating that adult onset IgAV might be under-diagnosed or misdiagnosed due to its rarity.

Adult onset IgAV is associated with an increased risk for developing significant renal involvement, including higher frequency of nephrotic syndrome, hypertension, an elevated serum creatinine level, and end-stage renal disease compared with the pediatric onset IgAV (12). In particular, elderly patients were associated with a low incidence of prior infection and presence of arthritis and increased incidence of hypertension and high serum IgA levels (13, 14).

Typically, the onset of disease in pediatric patients is preceded by an upper respiratory tract infection (8). The patient experienced vasculitis symptoms 2 days after the prior infection. The incubation period may be shorter than that in usual cases. IgAV follows an infection in two-thirds of the cases, with disease onset at an average of 3–10 days after the start of the infection symptoms (15). The incubation period may depend on the patients' health condition and bacterial virulence.

The decrease in the Factor XIII levels was associated with an increased severity of complications, including nephritis and gastrointestinal involvement, and increase in the Factor XIII levels was associated with the rate of recovery (16). Factor XIII may be degraded by proteases from leukocytes or consumed around the affected vessels, resulting in decreased Factor XIII activity in IgAV patients (17). Thus, the Factor XIII level can serve as a risk assessment biomarker for IgAV. However, the difference in the degree of Factor XIII deficiency between adult and pediatric patients with IgAV has not been elucidated.

The diagnosis of IgAV with renal involvement is typically based on the clinical presentation. IgAV is confirmed on the detection of IgA deposition in the skin or kidney by immunofluorescence microscopy. Differential diagnosis of palpable purpura includes other systemic autoimmune diseases (hypersensitivity vasculitis, cryoglobulinemia, systemic lupus erythematosus, and thrombocytopenic purpura). In this case, IgAV was confirmed by skin biopsy, although we did not perform clinical laboratory tests, including testing for autoantibodies. A renal biopsy can be performed to establish the diagnosis; however, this invasive procedure is considered only for patients with uncertain diagnosis or those with more severe renal involvement (e.g., proteinuria greater than 1 g/day and/or renal function impairment; www.uptodate.com).

In contrast to other types of systemic vasculitis, IgAV is self-limiting and most patients recover from it spontaneously. Thus, the management primarily involves supportive care and includes adequate hydration, rest, and symptomatic relief of pain in the majority of cases. There has been no report evaluating the treatment approaches for adult onset IgAV, and the use of glucocorticoids or immunosuppressants is controversial based on the evidence from studies involving children (3). It has been reported that glucocorticoid therapy increases the rate of resolution of the

arthritis and abdominal pain; however, it does not appear to prevent recurrence of the disease (18). Thus, routine glucocorticoid therapy for patients with IgAV to treat symptoms or prevent renal or gastrointestinal complications is not recommended. Glucocorticoid therapy may be recommended only for patients with nephrotic syndrome and with symptoms significant enough to affect their oral intake, interfere with their ability to ambulate and perform activities of daily living, and/or require hospitalization (www.uptodate.com).

Altogether, we presented a case of adult-onset IgAV complicated by proteinuria and pharyngitis. We conclude that physicians should be aware of IgAV in the differential diagnoses of leg purpura not only in children but also adults, especially in patients with upper respiratory tract infection. Palpable purpura following upper respiratory tract infection could be a cue to suspect IgAV; thus, precise physical examination in such cases is needed.

## CONFLICT OF INTEREST

The authors have no conflicts of interest to disclose.

## REFERENCES

1. Piram M, Mahr A : Epidemiology of immunoglobulin A vasculitis (Henoch-Schonlein) : current state of knowledge. *Curr Opin Rheumatol* 25 : 171-178, 2013
2. Jithpratuck W, Elshenawy Y, Saleh H, Youngberg G, Chi DS, Krishnaswamy G : The clinical implications of adult-onset henoch-schonlein purpura. *Clin Mol Allergy* 9 : 9, 2011
3. Hong S, Ahn SM, Lim DH, Ghang B, Yang WS, Lee SK, Kim YG, Lee CK, Yoo B : Late-onset IgA vasculitis in adult patients exhibits distinct clinical characteristics and outcomes. *Clin Exp Rheumatol* 34 : S77-83, 2016
4. Gardner-Medwin JM, Dolezalova P, Cummins C, Southwood TR : Incidence of Henoch-Schonlein purpura, Kawasaki disease, and rare vasculitides in children of different ethnic origins. *Lancet* 360 : 1197-1202, 2002
5. Calvo-Rio V, Loricera J, Mata C, Martin L, Ortiz-Sanjuan F, Alvarez L, Gonzalez-Vela MC, Gonzalez-Lamuno D, Rueda-Gotor J, Fernandez-Llaca H, Gonzalez-Lopez MA, Armesto S, Peiro E, Arias M, Gonzalez-Gay MA, Blanco R : Henoch-Schonlein purpura in northern Spain : clinical spectrum of the disease in 417 patients from a single center. *Medicine (Baltimore)* 93 : 106-113, 2014
6. Kang Y, Park JS, Ha YJ, Kang MI, Park HJ, Lee SW, Lee SK, Park YB : Differences in clinical manifestations and outcomes between adult and child patients with Henoch-Schonlein purpura. *J Korean Med Sci* 29 : 198-203, 2014
7. Mills JA, Michel BA, Bloch DA, Calabrese LH, Hunder GG, Arend WP, Edworthy SM, Fauci AS, Leavitt RY, Lie JT, Lightfoot RW, Masi AT, McShane DJ, Stevens MB, Wallace SL, Zvaifler NJ : The American College of Rheumatology 1990 criteria for the classification of Henoch-Schonlein purpura. *Arthritis Rheum* 33 : 1114-1121, 1990
8. Ozen S, Ruperto N, Dillon MJ, Bagga A, Barron K, Davin JC, Kawasaki T, Lindsley C, Petty RE, Prieur AM, Ravelli A, Woo P : EULAR/PRES endorsed consensus criteria for the classification of childhood vasculitides. *Ann Rheum Dis* 65 : 936-941, 2006
9. Yang YH, Hung CF, Hsu CR, Wang LC, Chuang YH, Lin YT, Chiang BL : A nationwide survey on epidemiological characteristics of childhood Henoch-Schonlein purpura in Taiwan. *Rheumatology (Oxford)* 44 : 618-622, 2005
10. Dolezalova P, Telekesova P, Nemcova D, Hoza J : Incidence of vasculitis in children in the Czech Republic : 2-year prospective epidemiology survey. *J Rheumatol* 31 : 2295-2299, 2004
11. Tracy A, Subramanian A, Adderley NJ, Cockwell P, Ferro C, Ball S, Harper L, Nirantharakumar K : Cardiovascular, thromboembolic and renal outcomes in IgA vasculitis (Henoch-Schonlein purpura) : a retrospective cohort study using routinely collected primary care data. *Ann Rheum Dis* 78 : 261-269, 2019
12. Audemard-Verger A, Terrier B, Dechartres A, Chanal J, Amoura Z, Le Gouellec N, Cacoub P, Jourde-Chiche N, Urbanski G, Augusto JF, Moulis G, Raffray L, Deroux A, Hummel A, Lioger B, Catroux M, Faguer S, Goutte J, Martis N, Maurier F, Riviere E, Sanges S, Baldolli A, Costedoat-Chalumeau N, Roriz M, Puechal X, Andre M, Lavigne C, Bienvenu B, Mekinian A, Zagdoun E, Girard C, Berezne A, Guillevin L, Thervet E, Pillebout E, French Vasculitis Study G : Characteristics and Management of IgA Vasculitis (Henoch-Schonlein) in Adults : Data From 260 Patients Included in a French Multicenter Retrospective Survey. *Arthritis Rheumatol* 69 : 1862-1870, 2017
13. Pillebout E, Thervet E, Hill G, Alberti C, Vanhille P, Nochy D : Henoch-Schonlein Purpura in adults : outcome and prognostic factors. *J Am Soc Nephrol* 13 : 1271-1278, 2002
14. Komatsu H, Fujimoto S, Maruyama S, Mukoyama M, Sugiyama H, Tsuruya K, Sato H, Soma J, Yano J, Itano S, Nishino T, Sato T, Narita I, Yokoyama H : Distinct characteristics and outcomes in elderly-onset IgA vasculitis (Henoch-Schonlein purpura) with nephritis : Nationwide cohort study of data from the Japan Renal Biopsy Registry (J-RBR). *PLoS One* 13 : e0196955, 2018
15. Akbar DH : Fatal complication of Henoch-Schonlein purpura : case report and literature review. *Saudi J Gastroenterol* 6 : 165-168, 2000
16. Fukui H, Kamitsuji H, Nagao T, Yamada K, Akatsuka J, Inagaki M, Shike S, Kobayashi Y, Yoshioka K, Maki S, Shirahata A, Miyazaki S, Nakashima M, Tanaka S : Clinical evaluation of a pasteurized factor XIII concentrate administration in Henoch-Schonlein purpura. *Japanese Pediatric Group. Thromb Res* 56 : 667-675, 1989
17. Koshiba K, Muraoka S, Nanki T, Komatsumoto S : Successful Treatment of IgA Vasculitis Complicated with Bowel Perforation and Crescentic Glomerulonephritis by Combination Therapy of Glucocorticoid, Cyclosporine and Factor XIII Replacement. *Intern Med* 57 : 3035-3040, 2018
18. Saulsbury FT : Henoch-Schonlein purpura in children. Report of 100 patients and review of the literature. *Medicine (Baltimore)* 78 : 395-409, 1999