

CASE REPORT

Minimally invasive cervical micro-endoscopic foraminotomy for C6 radiculopathy with overlooked scapular winging - A case report -

Yoshihiro Ishihama, Fumitake Tezuka, Hiroaki Manabe, Kazuta Yamashita, Yoichiro Takata, Toshinori Sakai, Takashi Chikawa, and Koichi Sairyō

Department of Orthopedics, Tokushima University, Tokushima, Japan

Abstract : A 73-year-old woman complained of right medial side of scapular pain associated with winged scapula to miss without observing the back in minute detail. Additional treatment was required due to overlooking caused by insufficient examination. We performed micro-endoscopic foraminotomy that provided the disappearance of scapular pain and improvement of winged scapula in relatively early. It was commonly said that winged scapula is an extremely rare condition that causes dysfunction of the upper extremities. We suggest that there are the meaning of winged scapula in diagnosis and the importance of physical examination. Further studies should be required to research the morbidity of winged scapula associated with cervical disease. By sharing our experience of this attention arousing case, we provide information not to repeat the same mistakes. *J. Med. Invest.* 66:340-343, August, 2019

Keywords : *Winged scapula, Cervical radiculopathy, Minimally invasive surgery, micro-endoscopic foraminotomy*

INTRODUCTION

Winged scapula is a symptom that the medial edge of the scapula protrudes in a rearward away from the thorax. The trapezius, serratus anterior and rhomboid muscles act that the scapula doesn't depart from the thorax and are involved in movement of the scapula. Winslow originally reported the first description of winged scapula in 1723 (1). Thereafter, Velpeau first described winged scapula caused by isolated serratus anterior paralysis in 1837 (2). The neuropathy of either the long thoracic, spinal accessory or dorsal scapular nerves that innervate the serratus anterior, trapezius and rhomboid muscles is mostly the major cause of this pathogenesis (3, 4). Frequency of winged scapula due to the palsy of serratus anterior muscle and trapezius muscles is relatively high. Winged scapula may present in various disease such as acute trauma, brachial plexus, cervical spondylosis, muscular dystrophy, idiopathic, and so on.

It is hardly reported that winged scapula associated with cervical spinal disease. Here, we show minimally invasive cervical micro-endoscopic foraminotomy for C6 radiculopathy with overlooked scapular winging.

CASE REPORT

The patient was a 73-year-old woman who complained of right shoulder pain, in particular, medial side of scapula, which resulted in scapular winging on that side (Fig.1). She also had back pain and dullness of the both legs for several years. She was diagnosed as having ossification of ligamentum flavum of the thoracic spine and lumbar spinal canal stenosis, and underwent

posterior decompression and fusion surgery at local hospital (Fig.2, 3). Although, those symptoms partially improved, pain around her right scapula did not disappear. She was referred to our department for further examination and treatment in 2017. Physical examination revealed positive of the Jackson neck compression test and Spurling neck compression test. Except for the serratus anterior muscle, any other muscle weakness of the upper limb was not observed. All deep tendon reflexes were intact and no sensory deficit were observed. There were no symptoms attributable to cord compression. Parasagittal image of the MRI of the cervical spine showed no presence of spinal cord compression (Fig4). CT Scanning in the oblique axial planes and the oblique sagittal planes showed right foraminal stenosis at C5-C6

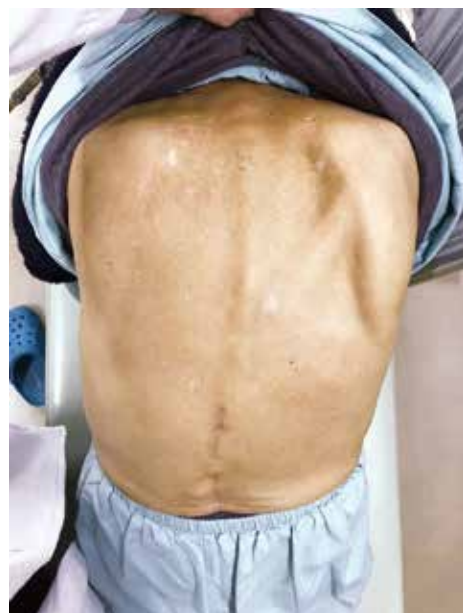

Figure 1 Medial scapular winging due to serratus anterior palsy.

Received for publication February 7, 2019 ; accepted April 25, 2019.

Address correspondence and reprint requests to Yoshihiro Ishihama, MD, Clinical Fellow, Department of Orthopedics, Tokushima University, 3-18-15 Kuramoto, Tokushima 770-8503, Japan and Fax : +81-88-633-0178.

associated with encroachment on the neural foramina by bone spur arising from the superior articular process of C6. (Fig.5). That thought to be OA change of the Luschka joint for the cause of foraminal stenosis. Cervical spinal radiculopathy of C6 was made on the basis of the temporary effect of selective nerve root

block of right C6. The patient subsequently underwent a right C5-C6 micro-endoscopic foraminotomy (Fig.6). Thereafter, pain around her right scapula disappeared in relatively early, and winged scapula almost improved in 6 months after surgery (Fig.7). The clinical results would be satisfactory.

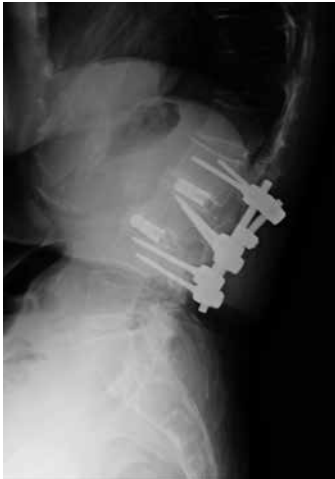
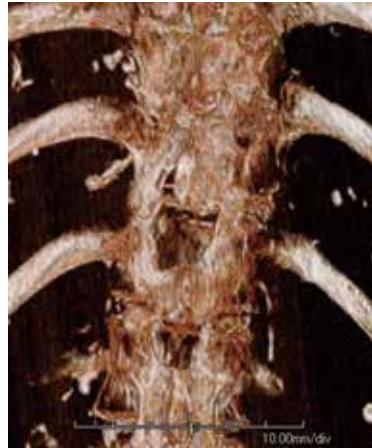
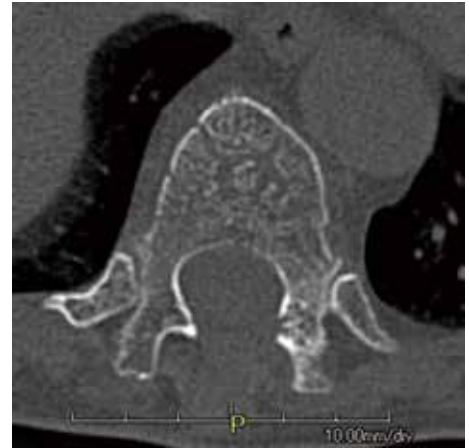Figure 2 Plain lateral radiograph after posterior lumbar interbody fusion.



3 A

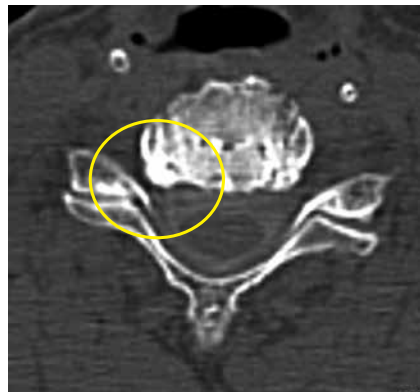


3 B

Figure 3 Postoperative 3-dimensional CT reconstruction (A) and the oblique axial view show the extension of the decompression (B).

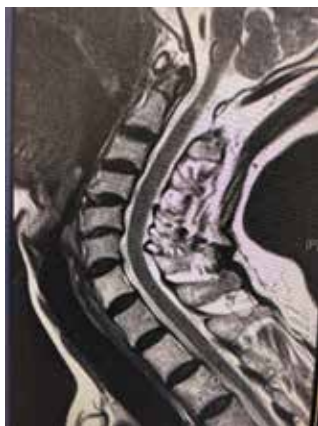

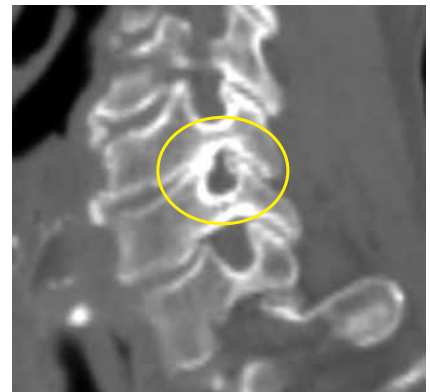Figure 4 MR images of cervical spine show no presence of spinal cord compression.

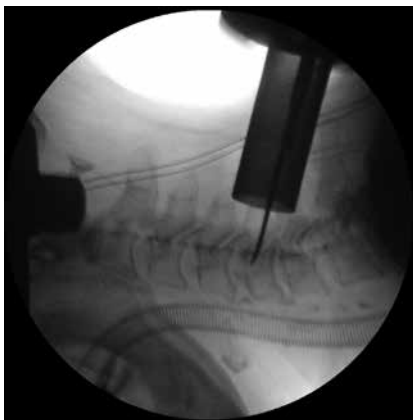

5 A

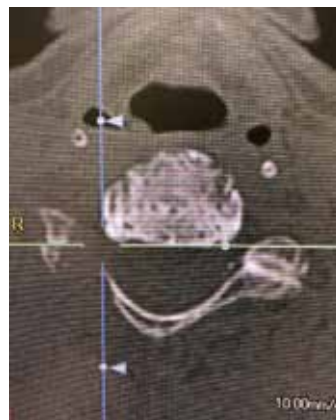


5 B

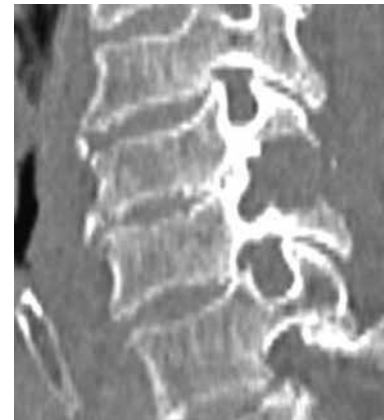Figure 5 Preoperative CT Scanning in the oblique axial plane (A) and the oblique sagittal plane(B) demonstrating the right side of foraminal stenosis at C5-C6.



6 A



6 B



6 C

Figure 6 A : Intraoperative lateral fluoroscopic image of micro-endoscopic foraminotomy.
 B : The foraminotomy on the right side of C5-C6 in the oblique axial view is shown.
 C : CT cervical spine sagittal reconstruction demonstrating the postoperative result after endoscopic foraminal decompression at C5-C6.

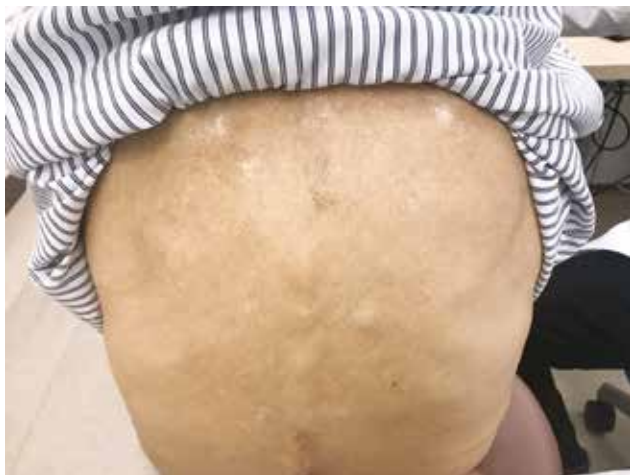

Figure 7 Improvement of winged scapula about 6 months after surgery.

DISCUSSION

Winged scapula can be missed without carefully making a physical examination. In this case, lumbar spinal canal stenosis and ossification of ligamentum flavum of thoracic spine was focused on radiological diagnosis, despite presenting winged scapula. Surgical treatment based on misdiagnosis was performed, and as a result, her symptom didn't improve satisfyingly. Necessary and sufficient information is required for spinal diagnosis and management. Overpeck and Ghormley (5) reported that winged scapula is rare disorder, which is incidence of 0.0026% at Mayo Clinic. However, there may be misdiagnosis without a sufficient and detailed observation. The prevalence of winged scapula, while still uncommon, is higher than previously believed (6). The presentation of winged scapula may help diagnosis, and furthermore, we reconfirmed the importance of physical examination. The morbidity of winged scapula as for cervical disease remains to be evaluated.

There are few reports as for winged scapula associated with cervical spinal disease. Yaguchi *et al.* (7) reported a case of unilateral scapular winging caused by weakness of the triceps muscle and the serratus anterior muscle due to cervical flexion myelopathy. Ando *et al.* (8) reported 6 cases with winged scapula associated with cervical spondylosis, which occurred mainly in C7 myelomere. Makin *et al.* (9) deduced that winged scapula would be identified as matched with a diagnosis of C7 radiculopathy. Winged scapula is caused by the neuropathy of either the long thoracic, spinal accessory or dorsal scapular nerves. The long thoracic nerve arises from the anterior rami of C5, C6 and C7 roots, the spinal accessory from eleventh cranial nerve and the dorsal scapular nerve from the ventral ramus of C5 or infrequently C4 (10-12). Therefore, C6 radiculopathy can cause winged scapula.

For the patients who do not recover well by conservative treatment, surgical treatment would be needed. The decision as for approach and surgical method is based on patient and surgeon-specific considerations. Micro-endoscopic foraminotomy for the treatment of cervical radiculopathy has been reported to be effective (13). The posterior approach is theoretically suited for unilateral radiculopathy, which direct decompression can be obtained. Moreover, it avoids the complication as related to anterior structure such as the trachea or esophagus unlike anterior approach. Furthermore, this procedure can preserve

mobility of the cervical spine without any instrumentation. The utilization of endoscopy can minimize soft tissue injury. A systematic review by Song *et al.* (14) reported clinical outcomes of micro-endoscopic foraminotomy compared with traditional open method. They identified using of micro-endoscopy have less blood loss and shorter surgical time compared to the standard open surgery. Minimally invasive cervical micro-endoscopic foraminotomy is useful for cervical foraminal stenosis as one of the treatment options.

CONCLUSION

Although it was said that winged scapula is rare, there may be a possibility of misdiagnosis without a detailed observation. Improvement of symptoms can be expected by reliable treatment based on correct diagnosis. Our report shall be the attention arousing case of C6 radiculopathy with overlooked scapular winging.

REFERENCES

1. Winslow M, Panckouke : Sur quelques mouvements extraordinaires des omoplates et des bras, et sur une nouvelle espece de muscles. Mem Acad Royale Sciences April 7 : 98-112, 1723
2. Velpeau A : Luxations de l'épaule. Arch Gen Med 14 : 269-305, 1837
3. Kuhn JE : The scapulothoracic articulation: anatomy, biomechanics, pathophysiology, and management. In: Iannotti JP, Williams GR, editors. Disorders of the shoulder : diagnosis and management. Philadelphia : Lippincott Williams & Wilkins, 1999, pp.817-845
4. Martin RM, Fish DE : Scapular winging: anatomical review, diagnosis, and treatments. Curr Rev Musculoskelet Med Mar ; 1(1) : 1-11, 2008
5. Overpeck DO, Ghormley RK : Paralysis of the serratus magnus muscle caused by lesion of the long thoracic nerve. JAMA 114 : 1994-1996, 1940.
6. Gregg JR, Labosky D, Harty M, Lotke P, Ecker M, DiStefano V, Das M : Serratus anterior paralysis in the young athlete. J Bone Joint Surg AM 61 : 825-832, 1979
7. Yaguchi H, Takahashi I, Tashiro J, Tsuji S, Yabe I, Sasaki H : Scapular winging as a symptom of cervical flexion myelopathy. Intern Med 46 : 511-513, 2007
8. Ando T, Fukatsu H, Kameyama T, Takahashi A, Yamada H : A case of flexion myelopathy presenting with reversible muscular weakness and atrophy of unilateral proximal upper limb. Rinsho Shinkeigaku 33 : 575-8, 1993 (in Japanese, abstract in English)
9. Makin G, Brouwn WF, Ebers GC : C7 radiculopathy : important of scapular winging in clinical diagnosis. J Neurol Neurosurg Psychiatry 49 : 640-644, 1986
10. Hamada J, Igarashi E, Akita K, Mochizuki T : A cadaveric study of the serratus anterior muscle and the long thoracic nerve. J Shoulder Elbow Surg 17 : 790-794, 2008
11. Lu L, Haman SP, Ebraheln NA : Vulnerability of the spinal accessory nerve in the posterior triangle of the neck: a cadaveric study. Orthopedics 25 : 71-74, 2002
12. Osterman AL, Babhulkar S : Unusual compressive neuropathies of the upper limb. Orthop Clin North Am 27 : 389-408, 1996
13. Wu PF, Liu BH, Wang B, Li YW, Dai YL, Qing YL, Lv GH : Complications of Full-endoscopic versus Microendoscopic Foraminotomy for Cervical Radiculopathy : a

- Systematic Review and Meta-analysis. World Neurosurg
114 : 217-227, 2018
14. Song Z, Zhang Z, Hao J, Shen J, Zhou N, Xu S, Ni W,
Hu Z : Microsurgery or open cervical foraminotomy for
cervical radiculopathy? A systematic review. Int Orthop.
40(6) : 1335-1343, 2016