



Case Report: Changes in Spatial Summation for Chromatic Stimuli in a Patient with Hypothyroidism Due to Autoimmune Thyroiditis Before and After Treatment with Levothyroxine

Kalina Racheva¹, Margarita Zlatkova^{1,2}, Tsvetalin Totev¹, Emil Natchev³, Ivan Hristov¹,
Milena S. Mihaylova¹, Roger S. Anderson²

¹Institute of Neurobiology, Bulgarian Academy of Sciences, Sofia, Bulgaria

²School of Biomedical Sciences, University of Ulster, Coleraine, United Kingdom

³Department of Endocrinology, Medical University, Sofia, Bulgaria

Abstract— *Introduction: Acquired hypothyroidism is associated with a wide range of deficits including visual effects. Investigating colour vision mediated by S-cones has shown potential to detect diseases such as glaucoma or diabetes, however, studies of colour vision in hypothyroidism are scarce. Case presentation: In the present study we report spatial summation data of a patient with hypothyroidism due to autoimmune thyroiditis tested with S-cone specific stimuli. The area of complete spatial summation (Ricco's area) is believed to reflect neural convergence and has been widely used to study structural changes to compensate for cell loss. We measured Ricco's area before and after treatment with levothyroxine. Colour contrast thresholds were measured as a function of stimulus area in the retinal periphery, under S-cone isolating conditions. Ricco's area was determined from the Threshold vs Area curve for either blue (S-cone increments) or yellow (S-cone decrements) stimuli. The patient's data before treatment showed enlarged Ricco's area (3 to 10 times larger) only for yellow stimuli compared to participants without hypothyroidism. After a treatment with levothyroxine and having reached euthyroidism, Ricco's area decreased significantly ($p < 0.05$) for yellow stimuli, but remained unchanged for blue stimuli ($p = 0.177$). A second subject without hypothyroidism, who participated in both experiments did not show any significant differences for either blue ($p = 0.081$) or yellow stimuli ($p = 0.78$). Conclusion: The observed increase in Ricco's area in hypothyroidism may be related to increased convergence to compensate for ganglion cell dysfunction. The results suggest that this process can be reversible after treatment. Examination of the S-cone system provides the potential to monitor this condition.*

Keywords— *Colour vision; Hashimoto's thyroiditis; Levothyroxine therapy; Ricco's area; S-cones*

Corresponding author: Kalina Ivanova Racheva, Institute of Neurobiology, Bulgarian Academy of Sciences, Acad. Georgi Bonchev Str. 23, Sofia, 1113, Bulgaria. E-mail: kalinair@abv.bg

I. INTRODUCTION

Hypothyroidism is a condition in which the thyroid gland is unable to produce enough thyroid hormones. It is known that hypothyroidism affects the central nervous system in adult subjects. Symptoms manifest as memory impairment, impaired cognitive function, attention deficit, slow reflexes etc., with these being at least partly alleviated by hormone replacement therapy [1,2,3]. The degree of reversibility of these symptoms is still a matter of discussion [4].

The reduced thyroid hormone level in adults with acquired hypothyroidism causes sensory impairment [i.e. 5], including reports of visual effects. However, the effect of hypothyroidism on human vision has been studied mainly with achromatic stimulation while its influence on human colour vision has not received sufficient attention. Most of the studies have also been on mice and rats. Colour vision in humans is mediated by three types of cones in the retina, short wavelength (S, 'blue'), medium wavelength (M, 'green') and long wavelength (L, 'red'). The specific properties of each cone type is determined by the expression of the visual

pigment opsin that makes cones sensitive to a distinct wavelength range in the visible spectrum of light. Unlike humans and most primates, mice are dichromate and have only two types of cones, S- and M- cone, that contain two types of opsin, UV/blue and green opsin [6,7]. It is well established that thyroid hormones in rats and mice participate actively in the synthesis of visual pigment opsin and that hypothyroidism suppresses the expression of M-cone opsin and activates the expression of S-cone opsin, potentially affecting colour vision. This occurs not only during perinatal development [8,9], but also in adult subjects throughout the individual's life [10]. It was suggested that the thyroid hormone levels can affect the opsin production and can reversibly change the cone spectral sensitivity. If the same mechanism controls the human cone opsin, hypothyroidism may have an effect on human colour vision. Umali et al. [11] have applied the Farnsworth-Munsell D15 colour vision test to patients with hypothyroidism and have not detected any difference in colour discrimination between patients and controls. The authors concluded that hypothyroidism does not affect human colour vision. However, it should be noted that D15 test is not sensitive enough to detect mild colour vision

impairments. Another study evaluated the effect of hypothyroidism on colour contrast sensitivity for letters in patients before and after 3 months of treatment with levothyroxine when biochemical euthyroidism has been achieved [12]. The colour contrast sensitivity was significantly lower in the hypothyroid group than in the control euthyroid group. After euthyroidism was reached, there was a significant improvement in the colour contrast sensitivity for red and green stimuli, while the significant difference between thyroid and control group for blue and yellow stimuli still persisted. The authors pointed out that a drawback of the study is using the commercial software Chromatest to study colour contrast sensitivity with isoluminant stimuli and the relatively short euthyroid period. The authors posed the question of whether a longer period of euthyroidism would contribute to the complete restoration of the blue-yellow contrast sensitivity.

The S-cones that have maximum sensitivity in the short wavelength (violet-blue) part of the spectrum, have received a lot of attention, both because of their unique role in colour vision [e.g. 13] but also because of the findings that deficits in S-cones and the neural pathways with S-cone input might be predictive for a number of retinal and systemic diseases, including glaucoma [e.g. 14,15,16] and diabetes [e.g. 17]. The S-cones are also unique regarding their connectivity to retinal ganglion cells in that far fewer neurons that react to the offset of blue light (S-cone OFF cells) have been found in monkeys retina compared to neurons reacting to the onset of blue light (S-cone ON cells) [see 18 for a review]. This asymmetry and the spatial properties of the ON- and OFF- neural mechanisms with S-cone input have been studied in series of papers by Vassilev and co-authors [19,20,21] using the paradigm of spatial summation and the area of complete spatial summation (Ricco's area). Complete spatial summation occurs when the product of stimulus area and threshold contrast is constant or in other words, when the threshold contrast is inversely proportional to stimulus area. It is generally thought that Ricco's area is related to neural convergence over a certain retinal or cortical area. The role of increased spatial summation is to improve the visual signal. The results of Vassilev et al. [19,20] showed that the area over which Ricco's law holds, was larger for S-cone OFF stimuli than for S-cone ON stimuli, a finding that suggests a higher convergence of S-cone OFF signals than S-cone ON signals, but only in the retinal periphery.

II. CASE REPORT/CASE PRESENTATION

The present case report examines the changes in Ricco's area in a patient with hypothyroidism due to autoimmune thyroiditis before and after treatment with levothyroxine, using chromatic stimuli. Emphasis is on structural changes that may occur in the neural mechanisms with S-cone input. The patient was a 41-year-old woman (Subject 1) with normal colour vision (Rabkins Colour Plates (8th edition 1985), Album Tritan de Ph. Lantony, Lineau Ophthalmologie, Paris, 1985 and City University Colour Vision Test). Since the age of 20, she has experienced significant symptoms such as increased nervous excitability, low heart rate, cold feeling, depression, impaired concentration, fatigue and weight gain.

She was referred to a psychiatrist and cardiologist where no major health problem was found. These symptoms have varied in frequency and severity over the years. Most likely, the patient was hypothyroid at the time of the baseline investigation. In 2003, at the age of 26, she participated in a study of spatial summation with stimuli that isolate S-cone ON and S-cone OFF colour vision mechanisms (Experiment 1). A modification of the two-colour threshold method of Styles, [22] was used to allow presentation of S-cone selective increments and decrements. In this modified method, low intensity blue light is added to a bright yellow background that reduced the activity of the other photoreceptor types. To preferentially activate the S-cone ON mechanism, the blue light in the stimulus increased above the blue background (S-cone increment) and for the S-cone OFF mechanism, the blue light decreases below the blue background (S-cone decrement). The details of the method have been previously described [19,20]. The stimuli used in this experiment were circular spots of varying size and they were presented at several retinal eccentricities for a duration of 100 ms on a calibrated high-resolution CRT monitor (Sony Trinitron). The subjects had to report if they see the stimulus by pressing a button ("Yes-No" method with 10% blank trials) and the threshold contrast for each stimulus size was recorded.

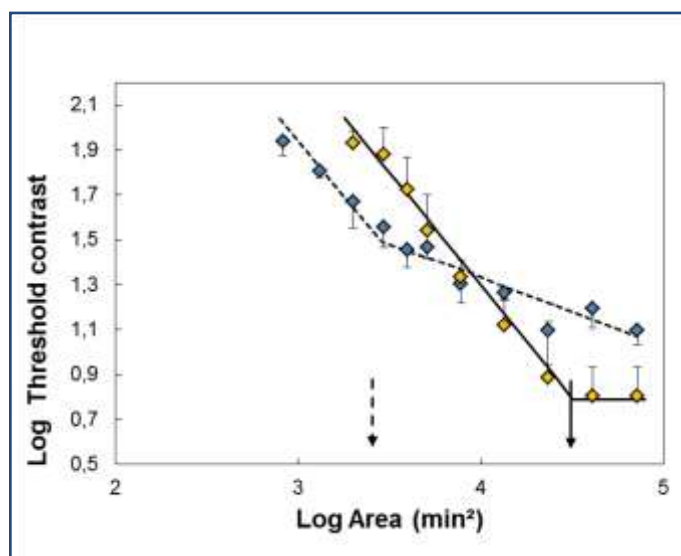


Fig. 1. Log Threshold contrast as a function of Log stimulus area at 20 deg retinal eccentricity for Subject 1, obtained before treatment (Experiment 1), Blue diamonds and dashed line – S-cone increments. Yellow diamonds and solid lines – S-cone decrements. The arrows indicate the Ricco's area in log min². The vertical lines denote the 95% confidence intervals. The lines fitted to the points were determined by piece-wise regression as explained in the text. The method of S-cone isolation is blue-on-yellow stimulation.

Figure 1 shows the summation curve, i.e. the graph of threshold contrast necessary to detect the stimulus, vs stimulus area for Subject 1 at 20° retinal eccentricity (from [20], their Figure 5). Each point in the graph is an average of 5 or 6 measurements. The threshold contrast is inversely proportional to stimulus area within Ricco's area, which in the log-log scale of the graph is represented with a line constrained to a slope of -1 (complete summation). Ricco's area was determined as an

intersection of the line with a fixed slope of -1 and a second line with a slope that was allowed to vary, using non-linear piecewise regression (IBM SPSS Statistics v.20 was used for calculations). Ricco's area for S-cone decrements was 4.5 log arcmin², with approximately 0.5 to 1 log arcmin² (3 to 10 times) larger compared to the other 3 participants (Ricco's area ranging from 3.5 to 4 log arcmin², [20], their Table 1).

We were not able to find an explanation for this considerable individual difference at the time of publishing the data. Ricco's area for S-cone increments for the same subject did not differ from that of the other participants ([20], their Table 1 and Figure 3, this report).

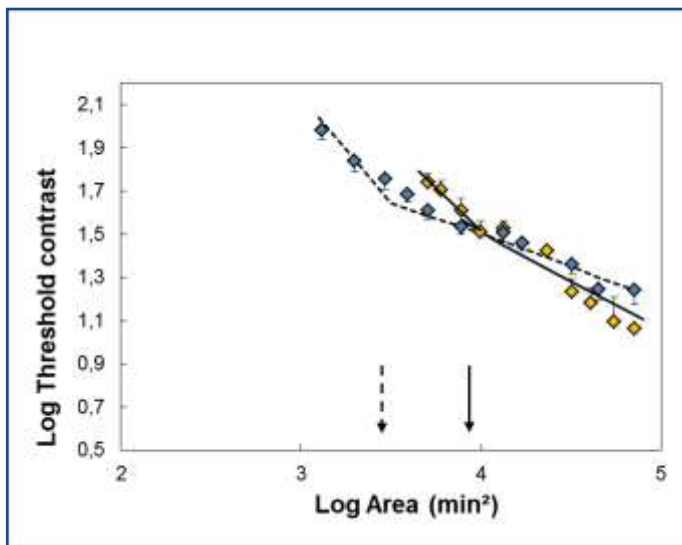


Fig. 2. Log Threshold contrast as a function of Log stimulus area at 20° retinal eccentricity for Subject 1 obtained after treatment (Experiment 2). The method of S-cone isolation is isoluminant stimulation. All other details are the same as in Figure 1.

At the age 31 Subject 1 was diagnosed with latent hypothyroidism due to autoimmune thyroiditis. Blood tests showed elevated TSH - 6.11 mIU/ml (0.27 - 4.2) ECLIA and elevated antibodies - Anty Tg At - 434.2 IU/ml (0 - 115) ECLIA and Anty TPO-At - 282.7 IU/ml (0 - 34) ECLIA. Treatment with Levothyroxin was performed because of the persisting hypothyroidism. After the publication of new research relating hypothyroidism with colour vision [10,12], it was suggested that the unusually large Ricco's area with S-cone OFF stimulation in this patient might have been caused by specific changes in the visual system related to the state of hypothyroidism. In 2018, when the patient was 41 years old, about 10 years after initiation of therapy, the experiment of spatial summation at 20 deg retinal eccentricity was repeated using similar equipment and stimulus parameters (Experiment 2). The method of S-cone isolation in this experiment differed from that used in Experiment 1 in that the stimuli varied only in their chromaticity (i.e. they were isoluminant) so that they only modulated the S-cone response, while the M- and L-cone response remained constant (silent substitution method, [23]), without using an intense yellow background. Similarly to Experiment 1, the S-cone increment stimuli were perceived as

blue, while the S-cone decrement stimuli as yellow. The details of the method are described in Vassilev et al [21].

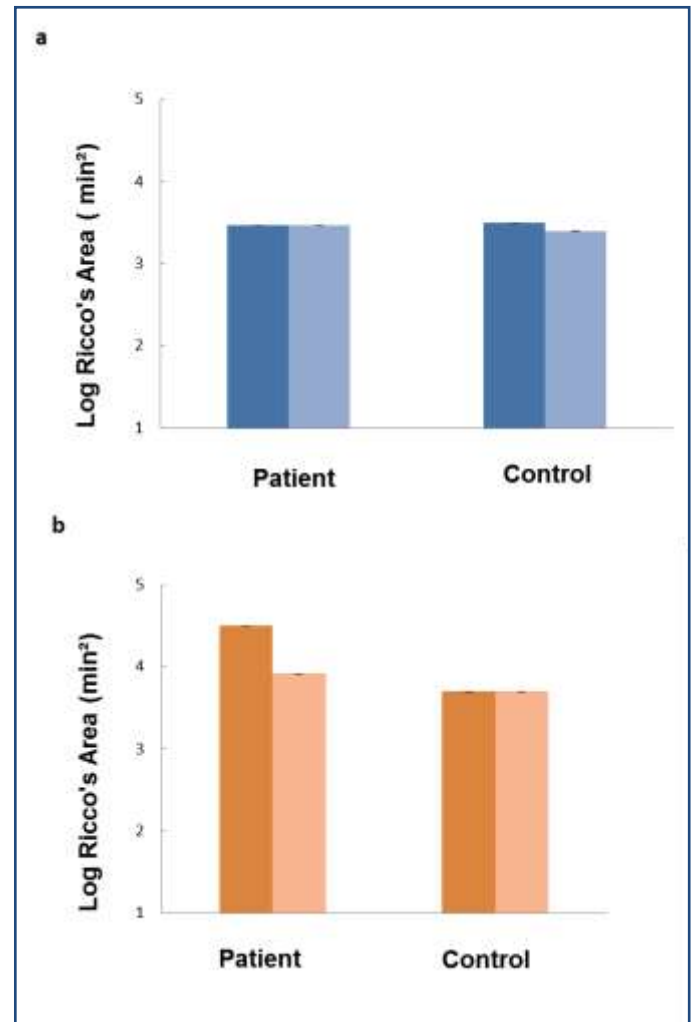


Fig. 3. Comparisons of Ricco's area between Subject 1 and Subject 2, who took part in both Experiment 1 (left columns) and Experiment 2 (right columns), for S-cone increments (a) and decrements (b). Error bars are smaller than the data point.

At the time of this experiment, the patient has been in euthyroid state for approximately 7 years. TSH was measured 0.912 mIU/ml (0.3 - 4.2), FT4 was 16.63 pmol/l (12-22). Figure 2 shows the summation curve for Subject 1, obtained in Experiment 2. The results indicate a distinct change in the summation curve for S-cone decrement stimuli, displaying a lower degree of summation in comparison with Experiment 1. Ricco's area has decreased with 0.6 log arcmin² (about 4 times) compared to its value in Experiment 1. i.e. changing from 4.5 log arcmin² to 3.9 log arcmin². The difference was statistically significant (paired t-test, t (8) = 7.8, p < 0.05), while for the S-cone increment stimuli the Ricco's area remained practically unchanged (3.49 log arcmin² vs 3.47 log arcmin², the difference was not statistically significant (t (10) = 1.454, p > 0.177). Figure 3 compares Ricco's area obtained in both Experiment 1 and 2 for Subject 1 and another healthy participant, Subject 2 without hypothyroidism, who also took

part in both experiments. Data shown are for S-cone increments (a) and S-cone decrements (b). The results of Subject 2 do not show any significant change between Experiment 1 and 2 for either S-cone increments ($t(8) = 1.999$, $p > 0.081$) or decrements ($t(8) = 0.29$, $p > 0.78$).

Although in theory the use of different methods of S-cone isolation should not affect Ricco's area, a possibility exists that the intense yellow background could unbalance the blue-yellow opponent mechanism and consequently could affect the thresholds. To check this possibility, another subject (Subject 3) who was tested using both methods (S-cone increments only), was selected from the participants in [20,21]. His results for Ricco's area were exactly the same ($3.4 \log \text{ arcmin}^2$) in both experiments, showing that the method of S-cone isolation did not have any effect on Ricco's area. To check if the long interval between the two experiments could have influenced the results, the data for S-cone increment stimuli of a fourth subject who took part in the experiments in 2005 and 2018 were included and compared. Both experiments were performed with the same method of isoluminant stimulation. Again, Ricco's area values remained unchanged ($3.2 \log \text{ arcmin}^2$), despite the long period between the experiments. The results clearly show that the only significant change was observed in Subject 1's data for S-cone decrements.

III. DISCUSSION

The present study shows that Ricco's area in a patient with autoimmune thyroiditis decreased significantly following treatment with levothyroxine and after reaching biochemical euthyroidism. This was observed only for stimuli specific for S-cone OFF colour mechanisms.

There were multiple attempts to relate Ricco's area to physiological or anatomical substrates. Glezer [24] has associated Ricco's area with the centre size of retinal ganglion neurons. Other authors have found close correspondence between the size of Ricco's area and retinal ganglion cell density [25,26] or between Ricco's area for S-cone specific stimuli and the dendritic field of the ganglion cells with S-cone ON input [21]. Others have attributed Ricco's area to cortical mechanisms [27]. Wilson [28] has suggested that the area of complete summation changes to maintain constant visual sensitivity under varying conditions. The examples for such adjustments are the consistent increase of Ricco's area at the retinal periphery [28], or in impaired areas of the visual field [27], presumably to compensate for the decreased density of the neural cells. Redmond et al [16] have shown that Ricco's area was enlarged in glaucoma to compensate for the reduced perimetric sensitivity, suggesting a recruitment of more active cells in response to ganglion cell loss. Vassilev et al. [20] have demonstrated that in the retinal periphery, beyond an eccentricity of 15 deg, Ricco's area for S-cone decrements is considerably larger than the one for S-cone increments, suggesting a different cell population with S-cone OFF input with lower density.

Irrespective of the exact physiological mechanism that underlies Ricco's area, it emerges from the studies cited above, that the alterations of Ricco's area serve as a regulatory mechanism to keep invariant sensitivity under compromised

conditions. In the first experiment in 2003, the Ricco's area of Subject 1 was much larger compared to the other participants. This could be due to loss of the functional retinal ganglion cells with S-cone OFF input. However, as the data indicate, this process must be reversible. The effect that we observed, suggests that in hypothyroidism, the cells may become temporarily dysfunctional, but this process could be reversed after successful treatment. It is still early to speculate about the exact nature of this reversible process, but one possibility is the demyelination of neurons as seen in rats [30]. Thyroid hormones are important for the growth of glial tissue and their insufficiency can lead to demyelination of neurons in the central nervous system [i.e. 31,32]. It's well known that demyelination of nerve cells is a reversible process [i.e. 33].

It is not clear if the observed changes in spatial summation are related to the changes in opsin expression reported in rodents. In mice, where there is a small number of S-opsin cones and majority of M-opsin cones, after the induced hypothyroidism S-opsin was expressed in all cones while M-opsin expression was significantly reduced. This process was particularly pronounced in rats [10]. It is not known if similar processes occur in human retina and how to relate the observed increase in the area of complete spatial summation for S-cone specific stimuli to increased expression of the S-cone opsin.

IV. CONCLUSION

The results in the present study suggest that in hypothyroidism, the spatial summation of chromatic mechanisms with S-cone input probably undergo changes which can be reversible after treatment and that examination of the S-cone pathway displays the potential for monitoring the progression or otherwise of the condition. Further research in a larger number of patients is required. A comparative study involving a sufficient number of patients before and after treatment and a group of control subjects under controlled experimental parameters will help to reveal the exact mechanisms that underlay this interesting phenomenon. Studies addressing this topic are underway.

ACKNOWLEDGMENT

We thank Prof. Angel Vassilev for helpful comments on a previous version of the manuscript.

STATEMENT OF ETHICS

The study was approved by the Institute of Neurobiology Bioethics Committee. Prior to the experiments, informed written consent was obtained from all subjects. The study was performed in accordance with the tenets of Helsinki.

CONFLICTS OF INTEREST

The authors have no conflicts of interest to declare.

FUNDING SOURCES

This study was supported by National Science Fund of Bulgaria, Grant № DN 13/11 from Dec 19 2017.

REFERENCES

- [1] D. Osterweil, K. Syndulko, S. N. Cohen, P. D. Pettler-Jennings, J. M. Hershman, J. L. Cummings, W. W. Tourtellotte, D. H. Solomon. "Cognitive function in non-demented older adults with hypothyroidism," *Journal of the American Geriatrics Society*, vol. 40, issue 4, pp. 325-335, 1992.
- [2] E. Nyström, K. Caidahl, G. Fager, C. Wikkels, P. Lundberg, G. Lindstedt. "A double-blind cross-over 12-month study of L-thyroxine treatment of women with "subclinical" hypothyroidism," *Clinical Endocrinology*, vol. 29, issue 1, pp. 63-76, 1988.
- [3] F. Monzani, C. A. Pruneti, F. De Negri, M. Simoncini, S. Neri, V. Di Bello, G. Baracchini Muratorio, L. Baschieri. "Ipotiroidismo preclinico: precoce interessamento delle funzioni mnestiche, della reattività comportamentale e della contrattilità cardiac," *Minerva Endocrinologica*, vol. 16, issue 3, pp. 113-118, 1991.
- [4] J. D. Davis, G. Tremont. "Neuropsychiatric aspects of hypothyroidism and treatment reversibility," *Minerva Endocrinologica*, vol. 32, issue 1, pp. 49-65, 2007.
- [5] I. D. Dietzel, S. Mohanasundaram, V. Niederkinkhaus, G. Hoffmann, J. W. Meyer, C. Reiners, C. Blasl, K. Bohr. "Thyroid hormone effects on sensory perception, mental speed, neuronal excitability and ion channel regulation," In: *Thyroid Hormone*, ed. First, Ch. 4, N. K. Agrawal, Ed. Croatia: In Tech, pp. 85-122, 2012.
- [6] D. Mustafi, A. H. Engel, K. Palczewski. "Structure of cone photoreceptors," *Progress in Retinal and Eye Research*; vol. 28, issue 4, 289-302, 2009.
- [7] J. K. Bowmaker, D. M. Hunt. "Evolution of vertebrate visual pigments," *Current Biology*, vol. 16, issue 13, pp. 484-489, 2006.
- [8] C. N. Pessôa, L. A. Santiago, D. A. Santiago, D. S. Machado, F. A. Rocha, D. F. Ventura, J. N. Hokoç, C. C. Pazos-Moura, F. E. Wondisford, P. F. Gardino, T. M. Ortiga-Carvalho. "Thyroid Hormone Action Is Required for Normal Cone Opsin Expression during Mouse Retinal Development," *Investigative Ophthalmology & Visual Science*, vol. 49, issue 5, pp. 2039-2045, 2008.
- [9] A. Glaschke, M. Glösmann, L. Peichl. "Developmental changes of cone opsin expression but not retinal morphology in the hypothyroid Pax8 knockout mouse," *Investigative Ophthalmology & Visual Science*, vol. 51, issue 3, pp. 1719-1727, 2010.
- [10] A. Glaschke, J. Weiland, D. Del Turco, M. Steiner, L. Peichl, M. Glösmann. "Thyroid hormone controls cone opsin expression in the retina of adult rodents," *Journal of Neuroscience*, vol. 31, issue 13, pp. 4844-4851, 2011.
- [11] A. S. Umali, A. D. Litonjua, C. N. Montano. "The Relationship Between Hypothyroidism and Colour Vision Deficiency Among Filipino Adults Seen at the Makati Medical Center," *Philippine journal of internal medicine*, vol. 52, issue 3, pp. 1-4, 2014
- [12] M. Cakir, B. T. Ozturk, E. Turan, G. Gonulalan, I. Polat, K. Gunduz. "The Effect of Hypothyroidism on Colour Contrast Sensitivity: A Prospective Study," *European Thyroid Journal*, vol. 4, issue 1, pp. 43-47, 2015.
- [13] D. J. Calkins. "Seeing with S-cones," *Progress in Retinal and Eye Research*, vol. 20, issue 3, pp. 255-287, 2001.
- [14] C. A. Johnson, A. J. Adams, E. J. Casson, J. D. Brandt. "Progression of early glaucomatous visual field loss as detected by blue-on-yellow and standard white-on-white automated perimetry," *Archives of Ophthalmology*, vol. 111, issue 5, 651-6, 1993.
- [15] F. K. Horn, J. B. Jonas, W. M. Budde, A. M. Jünemann, C. Y. Mardin, M. Korth. "Monitoring glaucoma progression with visual evoked potentials of the blue-sensitive pathway," *Investigative Ophthalmology & Visual Science*, vol. 43, issue 6, 1828-34, 2002.
- [16] T. Redmond, D. F. Garway-Heath, M. B. Zlatkova, R. S. Anderson. "Sensitivity loss in early glaucoma can be mapped to an enlargement of the area of complete spatial summation," *Investigative Ophthalmology & Visual Science*, vol. 51, issue 12 6540-6548, 2010.
- [17] V. Greenstein, B. Sarter, D. Hood, K. Noble, R. Carr. "Hue discrimination and S cone pathway sensitivity in early diabetic retinopathy". *Investigative Ophthalmology & Visual Science*, vol. 31, issue 6, pp. 1008-14, 1990.
- [18] P. R. Martin, B. B. Lee. "Distribution and specificity of S-cone ("blue cone") signals in subcortical visual pathways". *Visual Neuroscience*, vol. 31, issue 2, pp. 177-187, 2014.
- [19] A. Vassilev, M. Zlatkova, V. Manahilov, A. Krumov, M. Schaumberger. "Spatial summation of blue-on-yellow light increments and decrements in human vision," *Vision Research*, vol. 40, issue 8, pp. 989-1000, 2000.
- [20] A. Vassilev, M. S. Mihaylova, K. Racheva, M. Zlatkova, R. S. Anderson. "Spatial summation of S-cone ON and OFF signals: Effects of retinal eccentricity," *Vision Research*, vol. 43, issue 27, pp. 2875-2884, 2003.
- [21] A. Vassilev, I. Ivanov, M. Zlatkova, R. S. Anderson. "Human S-cone vision: Relationship between perceptive field and ganglion cell dendritic field," *Journal of Vision*, vol. 5, issue 10, pp. 823-833, 2005.
- [22] G. Wyszecki, W. S. Stiles. In: *Colour science*, 2nd ed, New York: John Wiley & Sons, 1982.
- [23] O. Estévez, H. Spekreijse. "The "silent substitution" method in visual research," *Vision Research*, vol. 22, issue 6, pp. 681-691, 1982.
- [24] V. D. Glezer. "The receptive fields of the retina," *Vision Research*, vol. 5, issue 9, pp. 479-525, 1965.
- [25] B. E. Scheffrin, M. L. Bieber, R. McLean, J. S. Werner. "The area of complete scotopic spatial summation enlarges with age," *Journal of the Optical Society of America A*, vol. 15, issue 2, pp. 340-348, 1998.
- [26] V. Volbrecht, E. Shrago, E. Brooke, B. Scheffrin, J. Werner. "Spatial summation in human cone mechanisms from 0° to 20° in the superior retina," *Journal of the Optical Society of America A*, vol. 17, issue 3, pp. 641-650, 2000.
- [27] W. H. Swanson, J. Feliuss, F. Pan. "Perimetric defects and ganglion cell damage: interpreting linear relations using a two-stage neural model," *Investigative Ophthalmology & Visual Science*, vol. 45, issue 2, pp. 466-472, 2004.
- [28] M. E. Wilson. "Invariant features of spatial summation with changing locus in the visual field," *Journal of Physiology*, vol. 207, issue 3, pp. 611-622, 1970
- [29] M. E. Wilson. Spatial and temporal summation in impaired regions of the visual field. *J Physiol* 1967; 189: 189-208
- [30] M. D. Pinazo-Durán, S. Pons-Vázquez, R. Gallego-Pinazo, C. Galbis Estrada, V. Zanón-Moreno, V. Vila Bou, P. Sanz Solana. "Thyroid hormone deficiency disrupts rat eye neurodevelopment," *Brain Research*, vol. 1392, pp. 16-26, 2011.
- [31] J. Bernal, J. Nunez. "Thyroid hormones and brain development," *European Journal of Endocrinology*, vol. 133, pp. 390-398, 1995.
- [32] P. Mohácsik, A. Zeöld, A. C. Antonio, B. Gereben. "Thyroid Hormone and the Neuroglia: Both Source and Target," *Journal of Thyroid Research*; Vol. 2011, Article ID 215718, 16 pages, doi: 10.4061/2011/215718.
- [33] R. J. M. Franklin, C. Ffrench-Constant. "Remyelination in the central nervous system (CNS): from biology to therapy," *Nature Reviews Neuroscience*, vol. 9, issue 11, pp. 839-855, 2008.
- [34] I. D. Papakostas, G. A. Macheras. "Thyroid hormones and peripheral nerve regeneration," *Journal of Thyroid Research*, 2013; Vol. 2013, Article ID 648395, 5 pages, doi: 10.1155/2013/648395.