

Final Report

The Expressions of Ret/PTC and p53 in Normal, Benign and Malignant Thyroid Lesions

Effat Omar, M. Madhavan, Nor Hayati Othman

USM Short Term Grant

304/PPSP/6151188

**BAHAGIAN PENYELIDIKAN & PEMBANGUNAN
CANSITORI
UNIVERSITI SAINS MALAYSIA**

Laporan Akhir Projek Penyelidikan Jangka Pendek



1) Nama Penyelidik: Professor (Dr.) Nor Hayati Othman

.....

Nama Penyelidik-Penyelidik
Lain (Jika berkaitan) :

Dr. Effat Omar @ Abdul Rahman

Assoc. Prof. M.Madhavan

.....
.....
.....
.....
.....
.....
.....
.....
.....
.....

2) Pusat Pengajian/Pusat/Unit : Pusat Pengajian Sains Perubatan

.....

3) Tajuk Projek:

To Determine the Expression of Ret/PTC and P53 Expression in Normal,
Benign and Malignant Thyroid Lesions

.....
.....

- 4) (a) Penemuan Projek/Abstrak
(Perlu disediakan maklumat di antara 100 – 200 perkataan di dalam Bahasa Malaysia dan Bahasa Inggeris. Ini kemudiannya akan dimuatkan ke dalam Laporan Tahunan Bahagian Penyelidikan & Pembangunan sebagai satu cara untuk menyampaikan dapatan projek tuan/puan kepada pihak Universiti).

Abstrak

Kadar pembengkakan kelenjar tiroid setempat terutamanya Kelantan adalah tinggi. Kajian di Hospital USM menunjukkan yang terdapat banyak kes barah yang dikesan dalam kes-kes tiroid ini. Ret/PTC adalah sejenis onkogen yang agak baru ditemui yang berkaitan hanya dengan kanser papilari tiroid. P53 pula adalah satu 'tumour suppressor gene' yang biasanya dikesan pada barah thyroid yang agresif. Bagaimanapun, kaedah imunohistokimia boleh mengesan p53 pada barah yang kurang agresif. Kami ingin mengkaji kadar mutasi ret/PTC dan p53 didalam populasi pesakit tiroid setempat dengan harapan untuk mengetahui patogenesis barah tiroid dan memberikan penjelasan tentang kenapa tingginya kadar barah ini dikawasan ini.

Buku pendaftaran Jabatan Patologi HUSM ditelaah untuk mengenalpasti 66 kes 'nodular hyperplasia' tiroid, 50 kes 'follicular adenoma' dan 53 kes barah tiroid papillary. Ujian imunohistokimia kemudian dijalankan keatas paraffin blok arkib kes-kes tersebut. Tisu tiroid normal dari 74 kes-kes tersebut digunakan sebagai control.

Kami mendapati bahwa ekspresi ret/PTC ialah 5.4% pada normal tiroid, 18% pada 'follicular adenoma', 22.7% pada 'nodular hyperplasia' dan 71.7% pada kanser papillary'. Tiada kaitan antara ekspresi ret dan umur, jantina, jangkamasa penyakit, sikap agresif barah itu dan kesudahan kehidupan pesakit berkaitan dengan barah. Ekspresi p53 dikesan pada 14% 'follicular adenoma', 16.7% 'nodular hyperplasia' dan 17% 'papillary carcinoma'. Sell tiroid yang normal tiada ekspresi p53. Seperti diatas, umur, jantina dan jangkamasa penyakit tidak mempengaruhi ekspresi p53. Walaubagaimanapun, p53 merupakan predictor yang sangat baik diatas pelanggaran kapsul dan metastasis barah ke kelenjar limfa. p53 juga mempunyai pengaruh atas kesudahan kehidupan pesakit barah tersebut.

Ret/PTC ialah mutasi yang kerap berlaku dalam populasi pesakit tiroid setempat dan adalah penting dalam pembedahan tumor tiroid tersebut. P53 pula berguna bagi meramalkan samada barah itu berpotensi untuk

menunjukkan tingkah laku agresif seperti pelanggaran kapsul dan metastasis kelenjar limfa. Ia juga berupaya meramal kesan barah keatas kesudahan penghidupan pesakit tersebut.

Abstract

Goiter is a highly prevalent problem in the local population. Studies at HUSM have found high percentage of papillary carcinoma within this lesion. Ret/PTC is a recently discovered oncogene which is solely related to papillary carcinoma. It has been proven to play a major role in the pathogenesis of this malignant lesion. P53 gene is a well known tumour suppressor gene, usually associated with the undifferentiated thyroid carcinoma. Immunohistochemistry is able to demonstrate p53 mutation in well differentiated thyroid carcinoma. This study aims to investigate the expression of ret and p53 in the local normal, benign and malignant thyroid lesions in order to shed light on the pathogenesis of papillary carcinoma and explain the high prevalence of this condition among the nodular hyperplasia (multinodular goiter) cases.

From the records of HUSM pathology department, archival blocks from 50 follicular adenomas, 66 nodular hyperplasia cases and 53 papillary carcinoma cases were retrieved. They were studied by immunohistochemistry method for the presence of ret/PTC and p53 mutant protein within the follicular cells. Normal thyroid tissues from 74 of the cases were utilized as controls.

Ret/PTC is expressed by 5.4% of normal thyroid tissue, 18% of follicular adenomas, 22.7% of nodular hyperplasia cases and 71.7% of papillary carcinomas. There is no statistically significant difference of ret expression between pure nodular hyperplasia and the ones with coexisting papillary carcinoma. Ret/PTC expression of papillary carcinoma is not associated with age, gender, duration of symptoms, tumour aggressiveness or patients' survival outcome. P53 is expressed by 14% of follicular adenomas, 16.7% of nodular hyperplasia and 17% of papillary carcinoma. Normal thyroid tissues do not harbour any p53 mutation. No association was found between p53 expression of nodular hyperplasia with or without coexisting papillary carcinoma. Age, gender, duration of symptoms and size of papillary carcinoma is not related to p53 expression. However, p53 is an excellent predictor of tumour lymph node metastasis and capsular invasion. It is also a significant prognosticator of survival outcome of papillary carcinoma patients.

Ret/PTC mutation is highly prevalent in local papillary carcinoma with low expression in the benign lesions. This indicates that ret/PTC has a significant role in the pathogenesis of the papillary carcinoma in the local population; but does not have any role subsequent tumour behaviour and survival outcome. P53 on the other hand appear to be a significant factor in predicting tumour aggressiveness and survival outcome.

USM J/P-06 - 2

(b) Senaraikan Kata Kunci yang digunakan di dalam abstrak:

<u>Bahasa Malaysia</u>	<u>Bahasa Inggeris</u>
Kelenjar tiroid	Thyroid
Goiter	Goitre
Kanser Papillary	Papillary Carcinoma
Ret/PTC	Ret/PTC
p53	p53

5) Output Dan Faedah Projek

(a) Penerbitan (termasuk laporan/kertas seminar)
(Sila nyatakan jenis, tajuk, pengarang, tahun terbitan dan di mana telah diterbitkan/dibentangkan).

- Immunohistochemical localization of RET rearrangements in a Malaysian papillary thyroid carcinoma population. E Omar, NH Othman. Med J Malaysia Vol 58 No 3 August 2003; 461-462
- Immunohistochemical localisation of RET and p53 mutant protein of thyroid lesions in a North-Eastern Malaysian population and its prognostic implications. Omar E, Madhavan M, Othman NH. Pathology. 2004 Apr;36(2):152-9.
- Ret/PTC and p53 expression in normal, benign and malignant thyroid lesions, NH Othman, E Omar, Virchows Archiv 2003; 443:(3), 258
- An Insight into the pathogenesis of Nodular Hyperplasia of the Thyroid -The study of RET and p53 expression. E.Omar, M. Madhavan, NH.Othman (abstract). Pathology International. 54 (2). Oct 2004, pg A12
- RET and p53 expression in follicular adenoma: a study on 52 cases with 14 years follow up. N Hayati Othman, E Omar N Hamdi Mahmood M Madhavan.(abstract) Pathology International. 54 (2). Oct 2004, pg. A64

LIST OF AWARDS AND PRESENTATION

- Immunohistochemical localization of RET rearrangements in a Malaysian papillary thyroid carcinoma population
E. Omar, M. Madhavan, NH Othman
2nd PADU Medical Symposium, October 2003
- **Young Investigator Award** for "Immunohistochemical localization of RET rearrangements in a Malaysian papillary thyroid carcinoma population" paper presentation.
E. Omar
2nd PADU Medical Symposium, October 2003
- RET/PTC and p53 expression in normal, benign and malignant thyroid lesions. Effat Omar, M. Madhavan and Nor Hayati Othman
IPTA Expo. Kuala Lumpur, October 2003
- An Insight into the pathogenesis of Nodular Hyperplasia of the Thyroid -The study of RET and p53 expression. **E.Omar**, M. Madhavan, NH.Othman. (Oral presentation) at the XXV International Congress of Pathology, Brisbane, Australia 10-15 October 2004
- RET and p53 expression in follicular adenoma: A study on 52 cases with 14 years follow up. N Hayati Othman, E Omar, N Hamdi Mahmood, M Madhavan. (Poster presentation) at the XXV International Congress of Pathology, Brisbane, Australia 10-15 October 2004

- (b) **Faedah-Faedah Lain Seperti Perkembangan Produk, Prospek Komersialisasi Dan Pendaftaran Paten.**
(Jika ada dan jika perlu, sila guna kertas berasingan)

.....
.....

- (c) **Latihan Gunatenaga Manusia**

- i) **Pelajar Siswazah:** Telah berjaya melatih seorang pelajar M.Med Pathology (Dr. Effat Omar)

.....
.....
.....

- ii) **Pelajar Prasiswazah:**

.....
.....
.....

- iii) **Lain-Lain :**

.....
.....
.....

6. **Peralatan Yang Telah Dibeli:**


Tiada.....
.....
.....
.....
.....

.....
.....
.....
.....
.....
.....
.....
.....

UNTUK KEGUNAAN JAWATANKUASA PENYELIDIKAN UNIVERSITI

.....
.....
.....
.....
.....
.....
.....
.....

T/TANGAN PENERUSI
J/K PENYELIDIKAN
PUSAT PENGAJIAN


Professor Zabidi A. Mohd. Hussin
Chairman of Research Ethics Committee
School of Medical Sciences
Health Campus
Universiti Sains Malaysia
16450 Kubang Kerian,
KELANTAN, MALAYSIA.

Abstract

To investigate RET and p53 expression in local thyroid lesions, in order to shed light on the pathogenesis of papillary carcinoma and explain the high prevalence of this condition among the nodular hyperplasia (multinodular goitre) cases.

Archival thyroid tissue was retrieved from HUSM (Hospital Universiti Sains Malaysia) Pathology Department files and studied by immunohistochemistry for RET and p53 mutant protein. Normal tissues from 74 cases served as controls.

Fifty follicular adenoma, 66 nodular hyperplasia and 53 papillary carcinoma cases were studied. RET was expressed in 5.4% of normal thyroid tissue, 18% of follicular adenomas, 22.7% of nodular hyperplasia cases and 71.7% of papillary carcinomas. Its expression in papillary carcinoma was not associated with the coexistence of nodular hyperplasia lesions. p53 was expressed by 17% of papillary carcinomas. No association was found between p53 expression of nodular hyperplasia with or without coexisting papillary carcinoma. p53, rather than RET, was an excellent predictor of tumour lymph node metastasis and capsular invasion. p53 was also a significant prognosticator of survival outcome.

RET expression is highly prevalent in local papillary carcinoma, indicating a significant role in the pathogenesis of this tumour; with no apparent role in tumour behaviour and survival outcome. p53 on the other hand appears

to be a significant factor in the latter events. The two genes appear to act in two different pathways; the former being an initiator, and the later a propagator of papillary carcinoma.

Key words: Thyroid, goitre, papillary carcinoma, *Ret*/PTC, p53.

INTRODUCTION

The development of a malignant lesion in a long-standing pre-existing benign condition has been documented for many tumours, including thyroid carcinoma.¹

A study of 300 thyroid specimens submitted to the University Science Malaysia Hospital Pathology Department from 1990 until 1995 revealed that multinodular goitre is the most common lesion. Examination of these multinodular goitres, where representative sections were taken from the widest cut surface as well as other solid nodules (number of blocks ranged from 4 to 10 blocks per specimen) revealed co-existing carcinoma in 34% of cases.² This is very high in comparison to other international series of sporadic goitre where only 4 to 17% of the glands were found to harbour carcinomas.³

Papillary carcinoma of the thyroid has no identifiable precursor lesion to date, compared to follicular carcinoma, which is linked to follicular adenoma.⁴ In addition, the *ret*/PTC oncogene, which was discovered relatively recently, is found to be associated with only papillary carcinoma.⁵ Most studies have found that no other follicular cell tumour expresses it.^{5,6,7} The *ret* proto-oncogene encodes a member of the tyrosine kinase family of trans-membrane receptors

and has been mapped to the region of chromosome 10q11.2.^{8,9} It consists of 21 exons¹⁰, spanning more than 60 kb of genomic DNA and encodes five major mRNA species. The proto-oncogene products are expressed as polypeptides of 1072 and 1114 amino acid residues that differ in C-terminal amino acid composition.¹⁰ The *ret* protein is a receptor for a glial cell line-derived neurotrophic factor that is normally expressed in neuroendocrine cells and also tumours of these cells.⁵ It is not present in the normal thyroid follicular cells.⁴

Sporadic papillary carcinoma of the thyroid is associated with somatic rearrangement of the *ret* gene.¹¹ This type of papillary-thyroid-carcinoma (PTC) specific mutation was first described in a lymph node with metastatic papillary thyroid carcinoma.¹¹ Consequent analyses revealed the three most frequent forms of *ret*/PTC rearrangement; known as *ret*/PTC-1, -2, and -3.^{7,12,13}

p53 is a well-studied tumour suppressor gene, located on chromosome 17p13.1. Its mutation has been reported mainly in anaplastic carcinoma, frequently involving exons 5 to 8.⁴ However in a recently published study employing immunohistochemistry, mutant *p53* protein has been detected in papillary carcinoma, as well as in follicular carcinoma.¹⁴

The wild-type *p53* protein has a short half-life, whereas the mutated protein remains within the cells for a longer time, allowing detection by immunohistochemistry. *p53* expression in papillary and follicular carcinoma has been correlated with aggressiveness, as evidenced by the presence of extra-thyroidal tumour extension in *p53*-positive tumours.¹⁴

The question is whether we have at last found a reliable marker (*ret*/PTC) to detect follicular cells with mutations that progress into papillary carcinoma. If so, then is it possible that the high incidence of papillary carcinoma seen in the nodular hyperplasia population is due to activation of this *ret*/PTC oncogene.

We were also interested in whether there is any association between *p53* and *ret* gene expression, and if these markers are useful in predicting a malignant transformation in a benign lesion. We further investigated the usefulness of *p53* and *ret*/PTC in predicting aggressiveness of papillary carcinoma, and compared them to assess them as predictors of survival.

The answers to these questions are important firstly in unravelling the pathogenesis of the papillary carcinoma in our locality and secondly in identifying the patients who are more likely to develop aggressive disease, making it possible for clinicians to tailor each patient's treatment; avoiding over or under treatment.

MATERIALS AND METHODS

Materials

Archival blocks of thyroid tissue from 1990 until 2000, which had been histologically diagnosed as multinodular goitre (nodular hyperplasia), follicular adenoma and papillary carcinoma, were retrieved from the registry of HUSM Pathology Department, Kelantan, Malaysia.

Clinical data

The clinical data of the patients including age, sex and race were recorded. Duration of symptoms for papillary carcinoma (visible neck swelling), size of tumour, duration of follow-up and survival characteristics (tumour recurrence, death due to disease or other causes) were obtained from the patients' medical records.

Histology

All histologic materials from the selected cases were reviewed by one of the authors (E.O.) to confirm that the diagnosis was in accordance with the recommendations of the World Health Organization. The presence of lymph node metastasis, capsular and extra-thyroidal invasion, as well as vascular and lymphatic invasion were determined histologically.

Immunohistochemistry for RET

Tissue blocks were sectioned at 3 microns thickness and applied to poly-l-lysine pre-coated slides. Endogenous peroxidase quenching was carried out by incubation with 3% hydrogen peroxide in methanol. Immunohistochemistry for RET was performed using a rabbit polyclonal antibody against the carboxy terminal region of RET (C-19, Santa Cruz biotechnology, Santa Cruz, CA) at a dilution of 1: 100 at room temperature for 2 hours or at 4°C for 16 hours. A streptavidin-avidin-biotin complex (DAKO, Denmark) detection system was used with diaminobenzidine employed as the substrate. The extent of staining was scored according to the method described in a previous study¹⁵: grade 0, 0%; grade 1, <25%; grade 2, 25–50%; and grade 3, > 50%. Intensity of the staining

was also noted (low, medium and high intensity). Only cytoplasmic staining was noted.

Immunohistochemistry for p53 protein

P53 was detected using a commercial monoclonal antibody (DAKO, DO-7) at a dilution of 1:50 incubated at room temperature for 2 hours. A streptavidin-avidin-biotin complex (DAKO, Denmark) detection system was used with diaminobenzidine as the substrate. The mutant p53 is concentrated in the nucleus of the cells. One hundred cells were counted and the number of positively staining nuclei noted. Using a cut-off point of 10 cells, the positivity was scored as 1+ (10–25/100 cells showing staining), 2+ (25–50cells/100) and 3+ (> 50cells/100).

Statistics

The statistical analysis—including Pearson's chi-square test, Fisher's exact test, Kaplan-Meier survival curves and Mantel-Haenszel log rank test—was performed using the SPSS software (SPSS Inc, Chicago, USA).

Results

A total of 149 cases were studied. These comprised 127 (85.2%) women and 22 (14.8%) men; giving a male: female ratio of 1:5.8. The average age at surgery was 39.7 years, with a range from 13 to 77 years and median age of 37 years. Ethnically, the majority were Malays (85.9%), followed by 19 Chinese (2.8%), 1 Indian (0.7%) and 1 Indonesian (0.7%). There were 50 cases of follicular adenomas, 66 nodular hyperplasias and 53 papillary carcinomas in this

study. Corresponding normal thyroid tissue from 74 of these cases served as controls.

The age, sex and race distribution of cases in each of the groups were comparable to the overall figures stated above.

For the papillary carcinoma group, the average age at surgery was 45.1 years, with the youngest patient being 20 years and the oldest 77 years. The duration of symptoms (noticeable neck swelling) was on average 50.9 months (4.2 years) with a range of 3 months to 30 years. The tumour size ranged from microscopic to 10 cm in the widest diameter (replacing the whole thyroid). The median size was 20 mm with no correlation between size of the tumour and the duration of symptoms ($P=0.971$).

The majority (64.1%) of the patients presented with stage I disease (according to UICC staging of thyroid carcinoma¹⁶). Of these, histological examination showed evidence of vascular and lymphatic invasion in 4 cases, while 4 others showed capsular invasion. Two of the later had extra thyroidal soft tissue tumour extension. Eighteen of 53 patients had cervical lymph node metastasis at presentation. One case had bone and 2 cases had lung metastasis at presentation (in addition to nodal disease).

The patients were followed up for an average 46.2 months with a range of 1 month after surgery up to 10 years. Follow-up records were available for 43 patients. For that period, 29 patients (67.4%) remained free of disease. Another 5 (11.6%) patients were alive with recurrent disease; 1 (2.3%) patient died of

recurrent disease 3 years after the surgery and 4 (9.3%) patients died of other causes.

Histologically, 16 of the papillary carcinomas co-existed with multinodular goitre and 3 co-existed with Hashimoto's (lymphocytic) thyroiditis. There were 8 cases of microscopic papillary carcinoma, 5 of follicular variant, 2 tall cell variant and 1 encapsulated variant. One papillary carcinoma co-existed with follicular carcinoma. One of the cases showed features of anaplastic transformation. This particular patient presented with local recurrence and multiple lymph nodes metastases 15 months after surgery.

RET immunohistochemistry

The extent and intensity of staining varied among the groups. The majority of papillary carcinoma (23/53 cases) had a higher intensity of RET staining, involving a larger number of cells (Fig. 1). In contrast normal thyroid tissues, except 4 cases, were RET negative. Most of the RET-positive follicular adenomas and nodular hyperplasia cases showed less intense staining (Fig. 2 a, b).

RET was detected in 66 cases. Four of the 74 samples (5.4%) of normal thyroid tissue were found to express RET. Among the follicular adenomas, 9 of 50 (18%) were positive whilst 15 of 66 (22.7%) nodular hyperplasias showed positivity. The papillary carcinoma group had the highest proportion (71.7%) of positivity; $P < 0.001$ (Fig. 3).

The four normal thyroid tissues with RET positivity were associated with adjacent neoplasia; one follicular adenoma and three papillary carcinomas.

RET was localised in 9 of 50 (18%) follicular adenomas, with no correlation of expression with sex ($P=1.00$) or age of the patients ($P=1.00$). Of the nodular hyperplasia cases, 15 of 66 (22.7%) were RET positive. There was no significant differences in RET expression between sexes ($P=0.188$) and age groups, ($P=0.444$).

Among the nodular hyperplasia cases with coexisting papillary carcinoma (11 cases), 8 (66.7%) cases were RET negative and 4 (33.3%) were positive (Table 1) ($P=0.461$). There was also no correlation between the size of the lesion and RET positivity ($P=0.791$).

On the whole, RET was expressed in 38 of 53 papillary carcinoma cases (71.7%). The staining pattern was diffuse in the cytoplasm and generally strong in intensity (23 cases having 3+ score).

RET was detected in 17 of 23 classical type papillary carcinoma and in 4 of 5 of the follicular variant. Both the tall cell variant carcinomas expressed RET. The carcinoma with anaplastic transformation also expressed RET. In this case, the well-differentiated area had strong diffuse staining, while the anaplastic quarter showed moderate focal staining. The encapsulated variant was negative. Two of the three cases with coexisting Hashimoto's thyroiditis expressed RET. Twelve of 19 (63.2%) of micropapillary carcinoma expressed RET. There were 33 cases of overt papillary carcinoma, and RET was detected in 78.5% (25 of 33 cases) ($P=0.359$).

There was no association between RET expression and age ($P=0.149$); duration of symptoms ($P=0.329$); gender ($P=0.418$) and size of the papillary carcinoma ($P=0.721$).

No relationship was found between tumour aggressiveness and RET expression. Kaplan-Meier survival curve and log-rank test of significance showed no difference between the survivals of RET-positive tumour patients compared to negative tumours.

p53 immunohistochemistry

Overall, p53 staining was more evenly distributed among the follicular adenoma, nodular hyperplasia and papillary carcinoma groups (Fig. 4 a,b,c). It was completely negative in normal thyroid tissue.

Of the 66 nodular hyperplasia cases studied, 11 cases (16.7%) showed p53 reactivity (Fig. 5), mostly of 1+ score. However, those 16 cases with co-existing papillary carcinoma showed no p53 expression in the nodular hyperplasia area.

Seven out of 50 (14%) cases of follicular adenoma were p53 positive (Fig. 5). Six of these cases were pure follicular adenomas and one other was oncocytic type.

p53 was detected in 9 of 53 (17%) papillary carcinoma cases (Fig. 5). Six of them showed 2+ and three showed 1+ score. Six of p53 positive cases were papillary carcinoma of classical type. None of the follicular variant expressed p53. One of two of the tall cell variant was positive. The encapsulated variant was negative. All the tumours coexisting with Hashimoto's thyroiditis were also

p53 negative. As expected, the papillary carcinoma with anaplastic transformation was p53 positive. Two of 19 (10.5%) micropapillary carcinoma were p53 positive ($P=0.458$).

Age, gender, duration of symptoms, and size of the papillary carcinoma did not have any significant correlation with p53 expression of the tumour cells ($P=1.00$; $P=0.169$; $P=0.222$; $P=1.00$ respectively)

All the tumours with distant metastasis were p53 negative. However, more tumours with lymph node metastasis showed p53 positivity compared to the non-metastasising group; $P=0.048$. Kaplan-Meier analysis and log rank test of significance showed that p53 was an excellent predictor of the ability of the tumour for capsular invasion and lymph node metastasis (Fig. 6).

Survival curve and log-rank test of p53-positive and negative tumours showed that p53 was a significant prognostic factor in the survival of papillary carcinoma patients (Fig. 7).

Association between RET and p53 expression

To investigate the relationship between RET and p53 expression in these tumours, both the markers were analysed together. In all of the groups, there was no concordance between RET and p53 expression.

Conclusion

Our papillary carcinoma population is unusual in two respects: firstly, there is a possible association with nodular hyperplasia, and secondly they are mostly contained within the thyroid and not associated with early mortality.

The RET-positive group of all the truly benign cases may represent an early molecular event in the formation of papillary carcinoma; however, this is merely speculative at this point. RET-positive cells adjacent to a papillary carcinoma may be a clone of neoplastic cells not yet showing the malignant histological characteristics.

The p53-positive RET-negative lesions may as likely end up as papillary carcinoma as any other type of malignancy e.g. follicular carcinoma etc. Further study of other mutations, for example: *ras*, *p16*, *c-erbB2* and *gsp* genes are required in order to further predict the line of transformation.

References

1. Preston-Martin S, Brenstein L, Pike MC. Thyroid cancer among young women related to prior thyroid disease and pregnancy history. *Br J Cancer* 1987; 55: 191–252.
2. Madhavan M, Nor Hayati O. Spectrum of thyroid diseases in Hospital Universiti Sains Malaysia: a study of 300 consecutive cases. *The Malaysian Journal of medical Sciences* 1996; 3:2; 58 (abstract).
3. Murray, D. The Thyroid Gland. In: Kovacs K, Asa SL, editors. *Functional Endocrine Pathology*. 2nd ed. Ottawa: Blackwell Science, 1998; 295–380.
4. Fagin JA. Molecular pathogenesis of carcinoma of follicular epithelium. In: Braverman LE, Utiger RD, editors. *Werner's and Ingbar's The Thyroid*. 8th ed. Boston: Lippincott Williams and Wilkins, 2000; 886–98.
5. Santoro M, Carlomagno F, Hay ID, *et al.* Ret oncogene activation in human thyroid neoplasms is restricted to the papillary cancer subtypes. *J Clin Invest* 1992; 89: 1517–22.

6. Jhiang SM, Mazzaferri EL. The ret/PTC oncogene in papillary thyroid carcinoma. *J Clin Invest* 1994; 123: 331–7
7. Grieco M, Santoro M, Berligieri MT, *et al.* PTC is a novel rearranged form of the RET proto-oncogene and is frequently detected *in vivo* in human papillary thyroid carcinoma. *Cell* 1990; 60: 557–63.
8. Ceccherini I, Bocciardi R, Yin L, *et al.* Exon structure and flanking intronic sequences of the human ret protooncogene. *Biochem Biophys Res Commun* 1993; 2: 247–52.
9. Gardener E, Pappi L, Easton DF. Genetic linkage studies map the multiple endocrine neoplasia type 2 loci to a small interval on chromosome 10q11.2. *Hum Mol Genet* 1993; 2: 241–6.
10. Kwok JBJ, Gardener E, Werner JP, Ponder BAJ, Mulligan LM. Structural analysis of the RET proto-oncogene using exon trapping. *Oncogene* 1993; 8: 2575–82.
11. Fusco A, Grieco M, Santoro M, *et al.* A new oncogene in human papillary thyroid carcinomas and their lymph nodal metastases. *Nature* 1987; 328: 170–2.
12. Bonzargone I, Monzini N, Borrello MG, *et al.* Molecular characterization of a thyroid tumour-specific transforming sequence formed by the fusion of RET tyrosine-kinase and the regulatory sub-unit RI alpha of cyclic AMP protein kinase A. *Molecular Cell Biology* 1993; 13: 358–66.
13. Santoro M, Dathan NA, Berligiery MT, *et al.* Molecular characterization of RET/PTC-3: a novel rearranged version of the RET proto-oncogene in a human papillary thyroid carcinoma. *Oncogene* 1994; 9: 506–16.
14. Hosal SA, Apel RL, Freeman JL, *et al.* Immunohistochemical localization of p53 in human thyroid neoplasms: correlation with biologic behavior. *Endocrine Pathology* 1997; 8(1): 21–8.

15. Mayr B, Potter E, Goretzki P, *et al.* Expression of wild type ret, ret/PTC and ret/PTC variants in papillary thyroid carcinoma in German. *Langerbeck's Arch Surg* 1999; 384: 54–9.
16. Norton JA. Endocrine tumours. In: Pollock RE, Doroshaw JS, Geraghty JG, Khayat D, Kim JP, O'Sullivan B, editors. *UICC International Union Against Cancer Manual of Clinical Oncology*. 7th ed. New York: Wiley-Liss, 1999; 359–84.

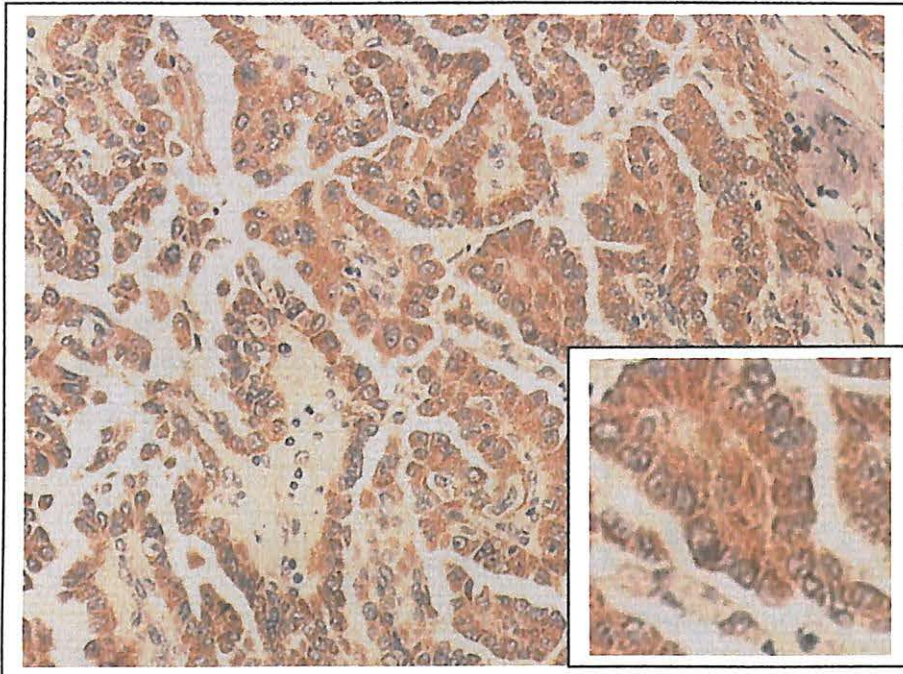


Fig. 1 Immunohistochemical positivity for RET within papillary carcinoma, strong, diffuse staining is observed in most of the cases (x10).

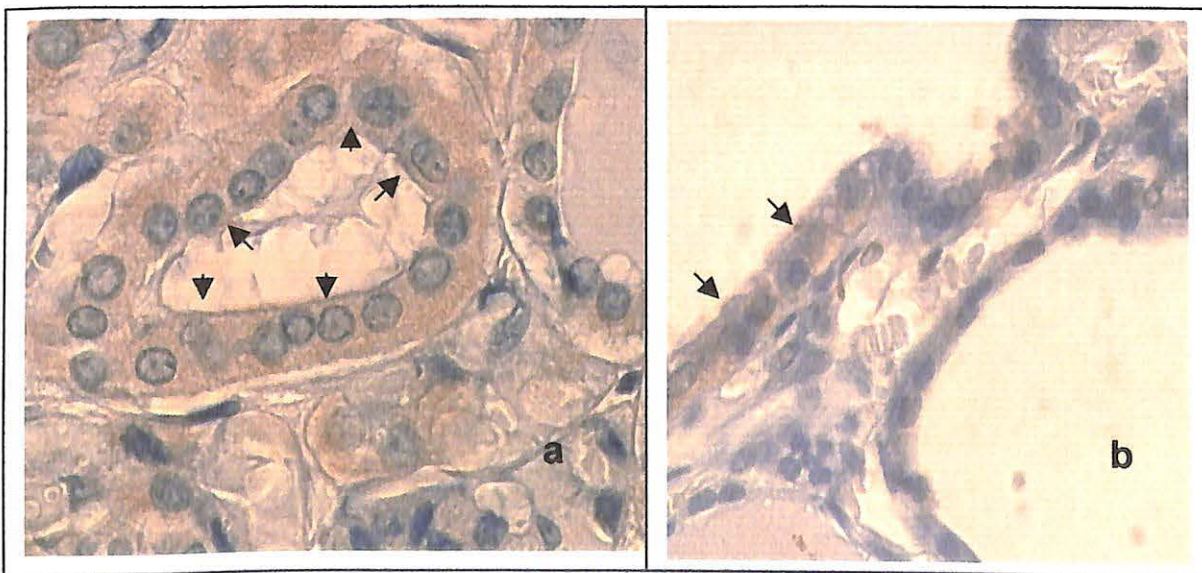


Fig. 2 RET immunohistochemistry in follicular adenoma (a: x10), and nodular hyperplasia (b: x10) showed weaker staining and patchy distribution (arrows).

Percentage of cases

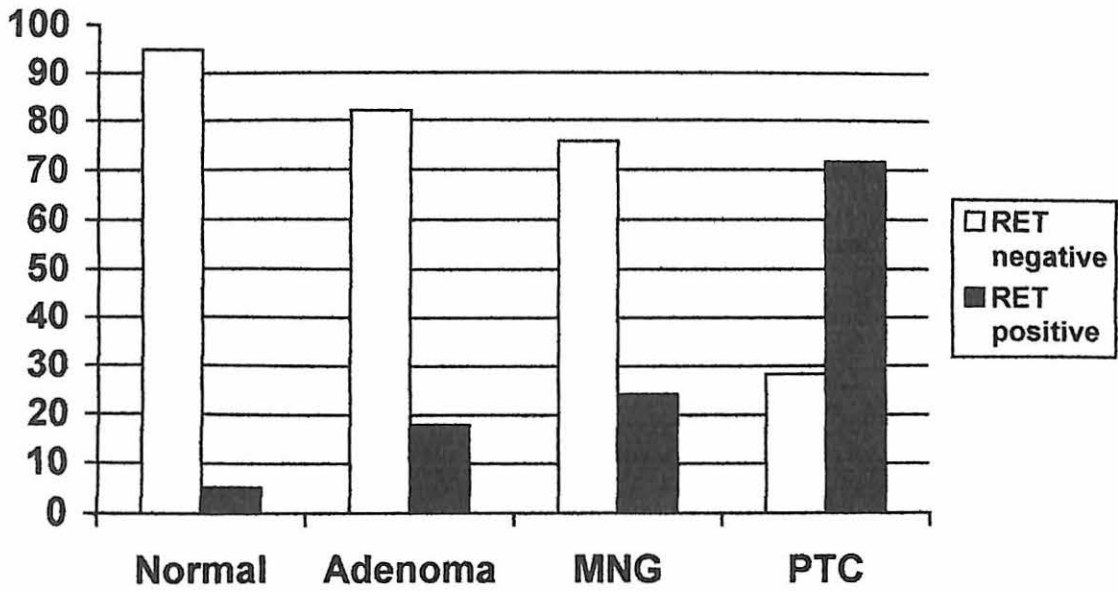


Fig. 3 Summary of RET immunohistochemistry staining result for normal thyroid tissue, follicular adenoma, nodular hyperplasia (NH) and papillary carcinoma (PTC). There was a significantly higher number of RET positive cells in the papillary carcinoma group compared to the other 3 groups; $P=0.001$.

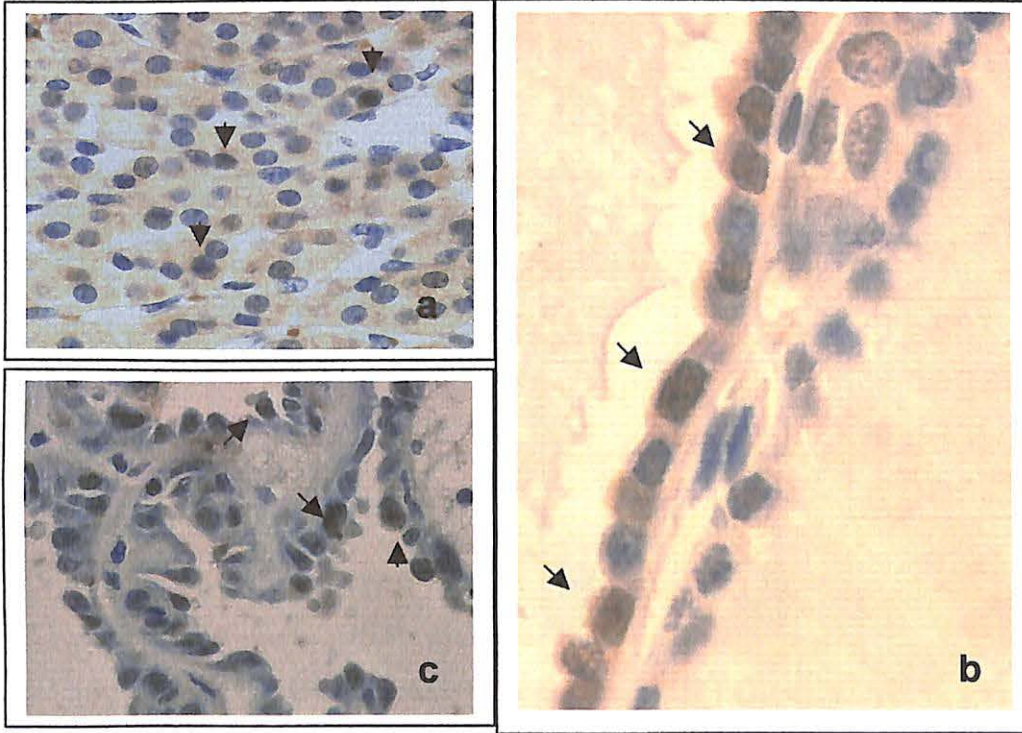


Fig. 4. p53 immunohistochemistry staining for follicular adenoma (a: x40) nodular hyperplasia (NH) (b: x40) and papillary carcinoma (PTC) (c: x40). The positive cells are marked by arrows.

Percentage of cases

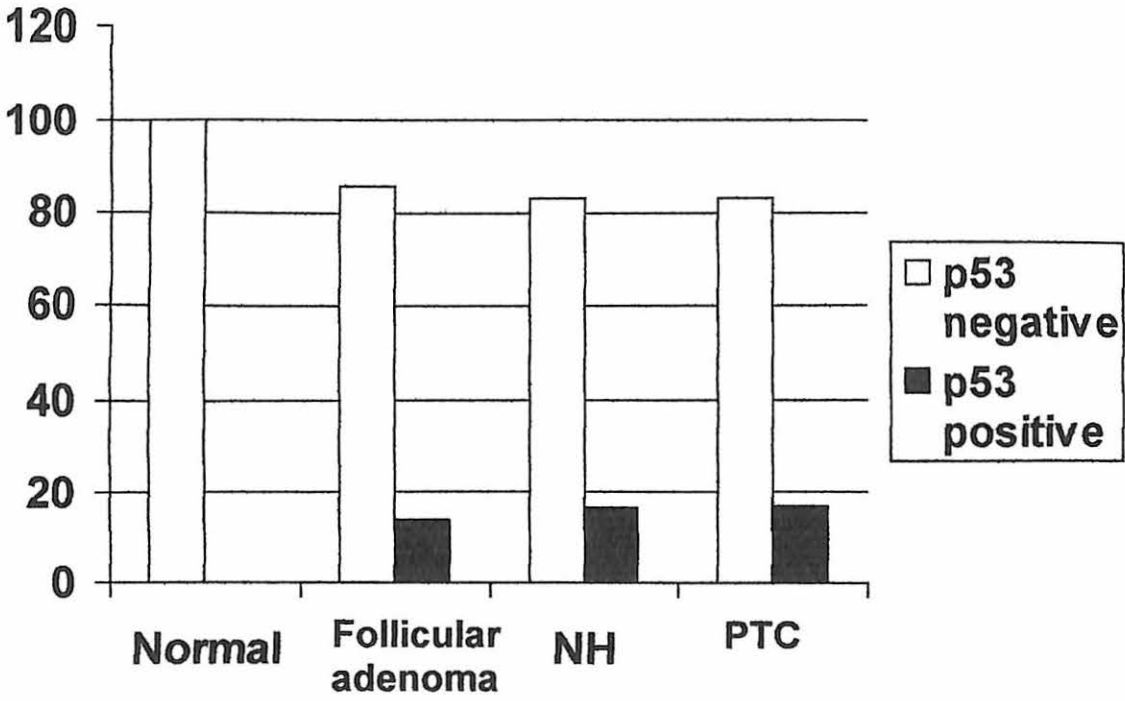


Fig. 5 Summary of p53 expression among the different groups of cases, normal thyroid, follicular adenoma, nodular hyperplasia (NH) and papillary carcinoma (PTC).

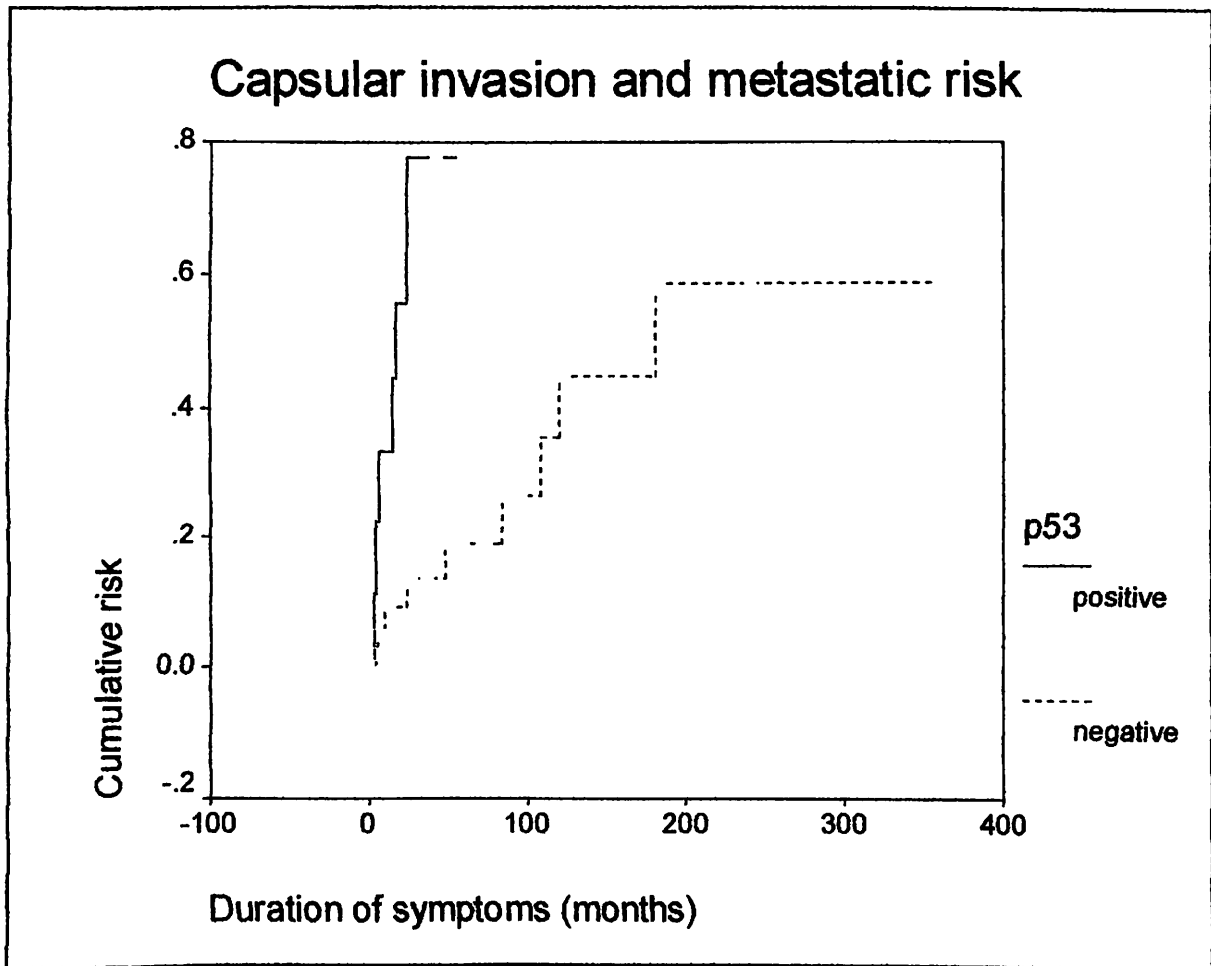


Fig. 6 Kaplan-Meier curve and log rank comparison of relative risk of lymph node metastasis and capsular invasion by p53 positive and negative tumours.

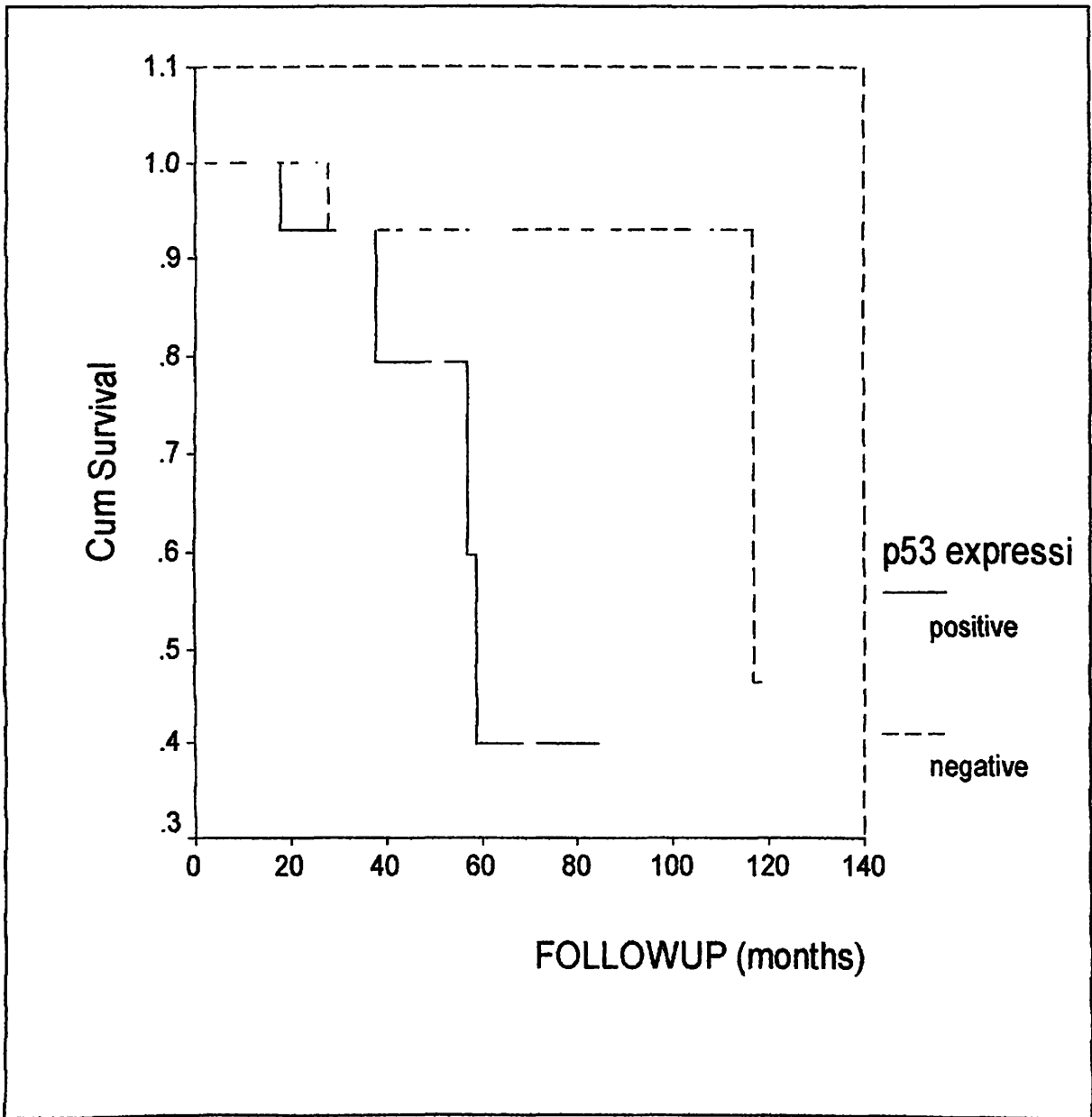


Fig. 7 Kaplan-Meier curve and log rank comparison of disease specific survival and tumour recurrence in p53 positive and negative tumours.

TABLE 1 Summary of RET expression in nodular hyperplasia with and without associated papillary carcinoma.

Nodular hyperplasia	Number of cases and its percentage				Total
	RET negative		RET positive		
Without papillary carcinoma	39	78%	11	22 %	50
With papillary carcinoma	8	66.7%	4	33.3%	12
Total	47		15		62

NB: Fisher's exact test, $P= 0.461$

ANATOMICAL PATHOLOGY

Immunohistochemical localisation of RET and p53 mutant protein of thyroid lesions in a North-Eastern Malaysian population and its prognostic implications

EFFAT OMAR, MANOHARAN MADHAVAN AND NOR HAYATI OTHMAN

Department of Pathology, School of Medical Sciences, Universiti Sains Malaysia

Summary

Aims: To investigate RET and p53 expression in local thyroid lesions, in order to shed light on the pathogenesis of papillary carcinoma and explain the high prevalence of this condition among the nodular hyperplasia (multi-nodular goitre) cases.

Methods: Archival thyroid tissue was retrieved from Hospital Universiti Sains Malaysia (HUSM) Pathology Department files and studied by immunohistochemistry for RET and p53 mutant protein. Normal tissues from 74 cases served as controls.

Results: Fifty follicular adenoma, 66 nodular hyperplasia and 53 papillary carcinoma cases were studied. RET was expressed in 5.4% of normal thyroid tissue, 18% of follicular adenomas, 22.7% of nodular hyperplasia cases and 71.7% of papillary carcinomas. Its expression in papillary carcinoma was not associated with the coexistence of nodular hyperplasia lesions. p53 was expressed by 17% of papillary carcinomas. No association was found between p53 expression of nodular hyperplasia with or without co-existing papillary carcinoma. p53, rather than RET, was an excellent predictor of tumour lymph node metastasis and capsular invasion. p53 was also a significant prognosticator of survival outcome.

Conclusions: RET expression is highly prevalent in local papillary carcinoma, indicating a significant role in the pathogenesis of this tumour, with no apparent role in tumour behaviour and survival outcome. p53 on the other hand appears to be a significant factor in the latter events. The two genes appear to act in two different pathways: the former being an initiator, and the later a propagator of papillary carcinoma.

Key words: Thyroid, nodular hyperplasia, neoplasia, RET, *ret/PTC*, p53, immunohistochemistry.

Received 22 April, revised 9 September, accepted 29 October 2003

INTRODUCTION

The development of a malignant lesion in a long-standing pre-existing benign condition has been documented for many tumours, including thyroid carcinoma.¹ A study of 300 thyroid specimens submitted to the Hospital Universiti Sains Malaysia (HUSM) Pathology Department from 1990 to 1995 revealed that multi-nodular goitre is the most common lesion. Examination of these multi-nodular goitres, where representative sections were taken from

the widest cut surface as well as other solid nodules (number of blocks ranged from 4 to 10 blocks per specimen), revealed co-existing carcinoma in 34% of cases.² This is very high in comparison with other international series of sporadic goitre where only 4-17% of the glands were found to harbour carcinomas.³

Papillary carcinoma of the thyroid has no identifiable precursor lesion to date, compared with follicular carcinoma, which is linked to follicular adenoma.⁴ In addition, the *ret/papillary-thyroid-carcinoma* (PTC) oncogene, which was discovered relatively recently, is found to be associated with only papillary carcinoma.⁵ Most studies have found that no other follicular cell tumour expresses it.⁵⁻⁷ The *ret* proto-oncogene encodes a member of the tyrosine kinase family of transmembrane receptors and has been mapped to the region of chromosome 10q11.2.^{8,9} It consists of 21 exons,¹⁰ spanning more than 60 kb of genomic DNA and encodes five major mRNA species. The proto-oncogene products are expressed as polypeptides of 1072 and 1114 amino acid residues that differ in C-terminal amino acid composition.¹⁰ The *ret* protein is a receptor for a glial cell line-derived neurotrophic factor that is normally expressed in neuroendocrine cells and also tumours of these cells.⁵ It is not present in the normal thyroid follicular cells.⁴

Sporadic papillary carcinoma of the thyroid is associated with somatic rearrangement of the *ret* gene.¹¹ This type of PTC-specific mutation was first described in a lymph node with metastatic papillary thyroid carcinoma.¹¹ Consequent analyses revealed the three most frequent forms of *ret/PTC* rearrangement, known as *ret/PTC-1*, *-2*, and *-3*.^{7,12,13}

p53 is a well-studied tumour suppressor gene, located on chromosome 17p13.1. Its mutation has been reported mainly in anaplastic carcinoma, frequently involving exons 5-8.⁴ However, in a recently published study employing immunohistochemistry, mutant p53 protein was detected in papillary carcinoma, as well as in follicular carcinoma.¹⁴

The wild-type p53 protein has a short half-life, whereas the mutated protein remains within the cells for a longer time, allowing detection by immunohistochemistry. p53 expression in papillary and follicular carcinoma has been correlated with aggressiveness, as evidenced by the presence of extra-thyroidal tumour extension in p53-positive tumours.¹⁴

The question is whether we have at last found a reliable marker (*ret/PTC*) to detect follicular cells with mutations that progress into papillary carcinoma. If so, then is it

ossible that the high incidence of papillary carcinoma in the nodular hyperplasia population is due to activation of this *ret*/PTC oncogene?

We were also interested in whether there is any association between p53 and *ret* gene expression, and these markers are useful in predicting a malignant transformation in a benign lesion. We further investigated the usefulness of p53 and *ret*/PTC in predicting aggressiveness of papillary carcinoma, and compared them to assess them as predictors of survival.

The answers to these questions are important, first in unravelling the pathogenesis of the papillary carcinoma in our locality and, second, in identifying the patients who are more likely to develop aggressive disease, making it possible for clinicians to tailor each patient's treatment, thus avoiding over- or under-treatment.

MATERIALS AND METHODS

Materials

Archival blocks of thyroid tissue from 1990 to 2000, which had been histologically diagnosed as multi-nodular goitre (nodular hyperplasia), follicular adenoma and papillary carcinoma, were retrieved from the registry of HUSM Pathology Department, Kelantan, Malaysia.

Clinical data

The clinical data of the patients, including age, sex and race, were recorded. Duration of symptoms for papillary carcinoma (visible neck swelling), size of tumour, duration of follow-up and survival characteristics (tumour recurrence, death due to disease or other causes) were obtained from the patients' medical records.

Histology

Histological materials from the selected cases were reviewed by one of the authors (EO) to confirm that the diagnosis was in accordance with the recommendations of the World Health Organization. The presence of lymph node metastasis, capsular and extra-thyroidal invasion, as well as vascular and lymphatic invasion were determined histologically.

Immunohistochemistry for RET

Tissue blocks were sectioned at 3 μ m thickness and applied to poly-L-lysine-coated slides. Endogenous peroxidase quenching was carried out by incubation with 3% hydrogen peroxide in methanol. Immunohistochemistry for RET was performed using a rabbit polyclonal antibody against the carboxy terminal region of RET (C-19; Santa Cruz Biotechnology, Santa Cruz, CA) at a dilution of 1:100 at room temperature for 2 h or at 4°C for 16 h. The streptavidin-avidin-biotin complex (Dako, Denmark) detection system was used with diaminobenzidine employed as the substrate. The extent of staining was scored according to the method described in a previous study:¹⁵ grade 0, 0%; grade 1, <25%; grade 2, 25–50%; and grade 3, >50%. Intensity of the staining was also noted (low, medium and high intensity). Only cytoplasmic staining was noted.

Immunohistochemistry for p53 protein

p53 was detected using a commercial monoclonal antibody (Dako, DO-7) at a dilution of 1:50 incubated at room temperature for 2 h. A streptavidin-avidin-biotin complex (Dako) detection system was used with diaminobenzidine as the substrate. The mutant p53 is concentrated in the nucleus of the cells. One hundred cells were counted and the number of positively staining nuclei noted. Using a cut-off point of 10 cells, the intensity was scored as 1+ (10–25/100 cells showing staining), 2+ (25–50 cells/100) and 3+ (>50 cells/100).

Statistics

The statistical analysis—including Pearson's chi-square test, Fisher's exact test, Kaplan–Meier survival curves and Mantel–Haenszel log rank test—was performed using SPSS software (SPSS Inc., USA).

RESULTS

A total of 149 cases were studied. These comprised 127 (85.2%) women and 22 (14.8%) men, giving a male–female ratio of 1:5.8. The average age at surgery was 39.7 years, with a range from 13 to 77 years and a median age of 37 years. Ethnically, the majority were Malays (85.9%), followed by 19 Chinese (2.8%), one Indian (0.7%) and one Indonesian (0.7%). There were 50 cases of follicular adenomas, 66 nodular hyperplasias and 53 papillary carcinomas in this study. Corresponding normal thyroid tissue from 74 of these cases served as controls.

The age, sex and race distribution of cases in each of the groups were comparable with the overall figures stated above.

For the papillary carcinoma group, the average age at surgery was 45.1 years, with the youngest patient being 20 years and the oldest 77 years. The duration of symptoms (noticeable neck swelling) was on average 50.9 months (4.2 years) with a range of 3 months to 30 years. The tumour size ranged from microscopic to 10 cm in the widest diameter (replacing the whole thyroid). The median size was 20 mm with no correlation between size of the tumour and the duration of symptoms ($P=0.971$).

The majority (64.1%) of the patients presented with stage I disease (according to UICC staging of thyroid carcinoma¹⁶). Of these, histological examination showed evidence of vascular and lymphatic invasion in four cases, while four others showed capsular invasion. Two of the latter had extra thyroidal soft tissue tumour extension. Eighteen of 53 patients had cervical lymph node metastasis at presentation. One case had bone and two cases had lung metastasis at presentation (in addition to nodal disease).

The patients were followed up for an average 46.2 months with a range of 1 month after surgery up to 10 years. Follow-up records were available for 43 patients. For that period, 29 patients (67.4%) remained free of disease. Another five (11.6%) patients were alive with recurrent disease; one (2.3%) patient died of recurrent disease 3 years after the surgery, and four (9.3%) patients died from other causes.

Histologically, 16 of the papillary carcinomas co-existed with multi-nodular goitre and three co-existed with Hashimoto's (lymphocytic) thyroiditis. There were eight cases of microscopic papillary carcinoma, five of follicular variant, two tall cell variant and one encapsulated variant. One papillary carcinoma co-existed with follicular carcinoma. One of the cases showed features of anaplastic transformation. This particular patient presented with local recurrence and multiple lymph nodes metastases 15 months after surgery.

RET immunohistochemistry

The extent and intensity of staining varied among the groups. The majority of papillary carcinoma (23/53 cases) had a higher intensity of RET staining, involving a larger number of cells (Fig. 1). By contrast, normal thyroid