



Repeated Oral Administration of Human Serum Albumin Protects from the Cerebral Ischemia in Rat Brain Following MCAO

Hyejin Park^{1,2}, Minyoung Hong², Gil-Ja Jhon³, Youngmi Lee³ and Minah Suh^{1,4,5,6*}

¹Center for Neuroscience Imaging Research (CNIR), Institute for Basic Science (IBS), Suwon 16419,

²Department of Biological Science, Sungkyunkwan University, Suwon 16419,

³Department of Chemistry and Nano Science, Ewha Womans University, Seoul 03760,

⁴Department of Biomedical Engineering, Sungkyunkwan University, Suwon 16419,

⁵Department of Health Sciences and Technology, SAIHST, Sungkyunkwan University, Seoul 06351,

⁶Biomedical Institute for Convergence at SKKU (BICS), Sungkyunkwan University, Suwon 16219, Korea

Albumin is known to have neuroprotective effects. The protein has a long half-life circulation, and its effects can therefore persist for a long time to aid in the recovery of brain ischemia. In the present study, we investigated the neuroprotective effects of human serum albumin (HSA) on brain hemodynamics. Albumin is administrated using repeated oral gavage to the rodents. Sprague-Dawley rats underwent middle cerebral artery occlusion procedures and served as a stroke model. Afterwards, 25% human serum albumin (1.25 g/kg) or saline (5 ml/kg) was orally administrated for 2 weeks in alternating days. After 2 weeks, the rodents were assessed for levels of brain ischemia. Our testing battery consists of behavioral tests and *in vivo* optical imaging sessions. Modified neurological severity scores (mNSS) were obtained to assess the levels of ischemia and the effects of HSA oral administration. We found that the experimental group demonstrated larger hemodynamic responses following sensory stimulation than controls that were administered with saline. HSA administration resulted in more significant changes in cerebral blood volume following direct cortical electric stimulation. In addition, the mNSS of the treatment group was lower than the control group. In particular, brain tissue staining revealed that the infarct size was also much smaller with HSA administration. This study provides support for the efficacy of HSA, and that long-term oral administration of HSA may induce neuroprotective effects against brain ischemia.

Key words: Neuroprotection, Hypoxia, MCAO (Middle cerebral artery occlusion), Human serum albumin, Optical recording of intrinsic signal

INTRODUCTION

Focal cerebral ischemia elicits various types of neuronal injuries including neurodegeneration, motor dysfunction and cognitive impairment. Necrosis takes place in neurons and supporting glia because of severe oxygen and glucose shortage [1, 2]. The penumbra is at the peripheral zone of this core injury and can be salvageable if collateral arteries provide blood into this region

Received March 24, 2017, Revised June 5, 2017,
Accepted June 12, 2017

*To whom correspondence should be addressed.
TEL: 82-31-299-4496, FAX: 82-31-299-4506
e-mail: minahsuh@skku.edu

[3]. However, if the blockage of the main cerebral artery persists, penumbral cells will undergo necrosis. The clinical point of stroke intervention is to improve neuronal injury and reduce the effects of ischemia. Once neural cells get damaged, recovery is difficult, therefore it is important to protect ischemic situations during stroke.

Human serum albumin (HSA) is produced in the liver and has multifunctional roles [4]. HSA is soluble and a monomeric human protein that transports hormones, free fatty acids and other compounds. It also works as a pH buffer and maintains osmotic pressure [5]. The role of albumin in neuroprotection has been studied over many years [6]. Much research have demonstrated the effectiveness of albumin administration in diminishing brain infarction volumes and brain edema, as well as compromise blood brain barrier permeability [7-9]. HSA also specifically inhibits endothelial cell apoptosis and histopathological damages [10, 11]. High-dose albumin therapy ameliorates neurological function and improves the reduced local perfusion of blood flow in the ischemic brain [12]. HSA is typically administered through intravenous injection (I.V.); although I.V injection is a direct and effective way of delivering materials into the body, it requires the use of needles. Thus, if oral administration of HSA is evinced to bring about similar protection effects as I.V. injections, then it can be developed into a more generalized intervention that can be applied to individuals of all ages.

In our previous study, we have shown that optical recordings of intrinsic signals (ORIS) can be utilized to monitor hemodynamic alterations in a MCAO model. We reported that the hemodynamic response of the ischemia region to electrical stimulation was drastically decreased, and ORIS measurements were tightly correlated with the severity of ischemia [13]. ORIS is a relatively easy technique to assess the levels of cerebral perfusion and is readily applicable to monitor the effects of HSA oral administration.

MATERIALS AND METHODS

Animal preparation for surgical and experimental procedures

All surgical procedures followed the guidelines of Sungkyunkwan University IACUC (SKKUIACUC). Male Sprague-Dewley rats (n=14, 280~310 g) were used for the study. Animals were anesthetized with isoflurane (3% induction of anesthesia; 2% maintenance during experiment) and laid on the bed with paper towels. Body temperatures were maintained hot pads. The surgical and experimental procedures were performed under said conditions.

Procedure for middle cerebral artery occlusion (MCAO)

The animals' bodies were fixed on the stereotaxic frame. A 0.5

mm incision was made on the right side of the midline neck to search and expose the external carotid artery (ECA), internal carotid artery (ICA) and common carotid artery (CCA). These three vessels were isolated from the tissue along with other muscles. The isolated vessels from the tissue were tied in the order of ECA, CCA and ICA with silk sutures. In order to insert the suture, the puncture was made above the knot of arteries. A 4-0 monofilament suture that with a poly-L-lysine coated tip was inserted 20 mm via the ICA into the right middle cerebral artery (MCA) (standard length insertion for a 300 g animal). The incision was then stitched up. The right MCA was occluded for 90 minutes, after which the animals were again anesthetized for reperfusion of MCA and reopening of the sealed incision. After the tail of the suture was searched, the suture was carefully pulled from the MCA and the remaining suture head, which is coated with poly-L-lysine, was left inside the ICA. When this process was over, incision was stitched up again and animals were put back to their cages.

Oral administration of albumin and saline

Animals of the MCAO model were divided into two groups, one group received human serum albumin (HSA) solution (25%, 1.25 g/kg, n=7) and another group received saline (0.9% isotonic sodium chloride solution, 5 ml/kg, n=7). The HSA solution was prepared by dissolving powdered HSA in saline. Each animal of the two groups were started on oral administration of either HSA or saline 3 hours after the onset of stroke. To alleviate animal suffering from MCAO surgery and the stress from oral dosing procedures, oral administration was only given on alternate days for 2 weeks. For oral gavages, a flexible feeding needle (Jeungdo bio, Korea) was used. Proper length of feeding needles was applied to each animal according to the animal's weight.

Neurological behavioral tests

Behavioral tests were performed for each animal from the two groups; animals were selected blindly for the behavioral tests. We graded the level of sensory motor deficits following days 1, 7 and 14 post-surgery. Modified neurological severity scores (mNSS) [14] were used for assessing sensory-motor deficits. A normal score was represented by 0 and the maximal deficit score was 14.

Optical recording of intrinsic signal (ORIS) and electrical stimulation

Fourteen days after the MCAO procedure, animals were prepared for ORIS recordings of the sensory cortex. Animals were initially anesthetized by inhalation with 3% isoflurane for induction and craniotomy and 2% isoflurane for maintenance during the experiment. Animals were laid on the bed with paper towels,

with a hot pad to keep body temperature stable. Their heads were fixed on stereotaxic frames, and the skin over their sensory cortex was cut and cranial bones were exposed. The skull from the bregma to lambda (4 mm×4 mm) was carefully removed with a dental drill to expose the dura mater. Exposed brain tissue was illuminated evenly using a halogen lamp. Direct electrical stimulation (biphasic, 1 mA, 3 Hz) was given to the brain tissue with a bipolar electrode (Plastic One, Roanoke, VA). The stimulation started 30 seconds following ORIS recording and lasted for 10 seconds. Images were simultaneously acquired with a CCD camera (Ademic, Netherlands) at 3.33 Hz through 570 nm band-pass filter, the wavelength at which cerebral blood volume is sensitive to. This stimulation elicited cerebral blood volume changes. The whole recording time was 300 seconds and data were analyzed with a program written in MATLAB.

Data analysis

Acquired images from the ORIS system were analyzed with a program written in MATLAB for calculating changes in cerebral blood volume. The frames during the initial 30 seconds before electrical stimulation were taken as baseline and the remaining frames were then normalized to this baseline. The time courses of pixel changes from regions of interest were obtained and analyzed. Divided images were carefully examined to confirm activated regions.

Triphenyl-tetrazolium chloride (TTC) staining and quantification of infarct volume

After ORIS, the brains of animals were removed from the head. The cerebrum was sectioned coronally into 6 pieces of 2 mm

thickness. The sections of the cerebrum were immediately stained with a 2% triphenyl-tetrazolium chloride solution (TTC, sigma, US) in 6-well plates for 20 minutes. The sections were then transferred in paraformaldehyde (PFA). After 24 hours, each section was photographed and the infarction size was measured using the Image J (NIH, USA) software program.

Statistical analysis

A Mann-Whitney U test was performed for the group comparison and data were expressed as the means±standard error of the means (SEM). Statistical significance were indicated at one of three levels. * $p<0.05$, ** $p<0.01$, *** $p<0.001$.

RESULTS

The effects HSA oral administration on cerebral blood volume (CBV) changes following sensory cortex stimulation in MCAO model

The effects of HSA oral administration on cerebral blood volume (CBV) change correspondingly following sensory cortex stimulation in a MCAO model. After administrating HSA and saline for two weeks, the animals underwent ORIS sessions to assess the protective effects of HSA on ischemia. The changes in CBV were calculated by selecting 6×6 pixels of the region of interest (ROI) near the stimulating electrode on the sensory cortex. Average pixel values of ROIs were calculated from individual animals and plotted over the entire time course to examine the CBV changes following electrical stimulation. Each group had 7 animals and all CBV changes were averaged (Fig. 1A). CBV of the ipsilateral hemisphere of animals that were orally administered with HSA

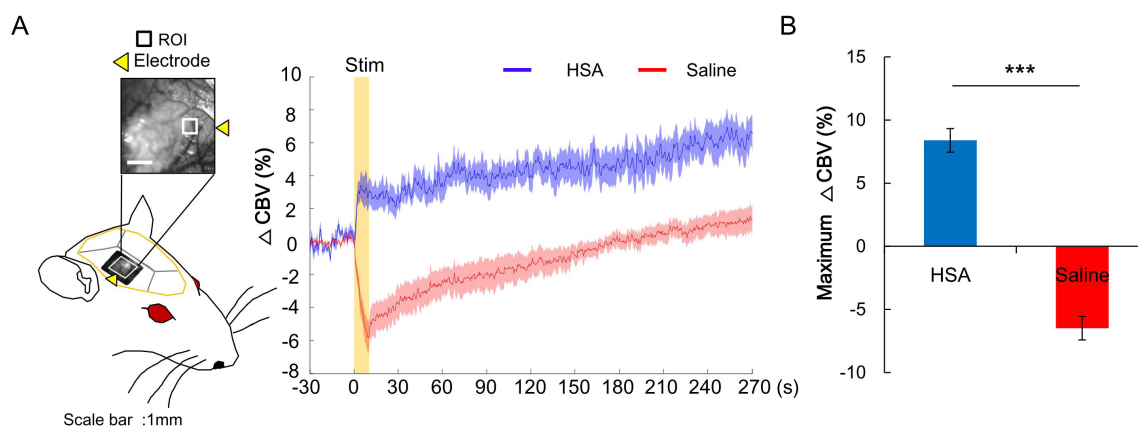


Fig. 1. Cerebral blood volume (CBV) changes of animals with oral gavage of HSA and saline. (A) CBV of ipsilateral hemisphere in an animal with oral gavage of HSA was increased gradually while the CBV of ipsilateral hemisphere in an animal with oral gavage of saline that was decreased dramatically. The CBV of HAS group ($n=7$) showed a gradual increase while the saline group exhibited a large decrease (Scale bar: 1 mm). (B) The Maximum CBV change in ipsilateral hemisphere of HSA group was significantly higher than saline groups.

gradually increased following direct electrical stimulation while those of animals given saline decreased significantly (Fig. 1A). The maximum CBV change of the HSA group was significantly higher than that of the saline group (p-value=0.0006, Fig. 1B).

The effects HSA oral administration on infarct size, neurological scores and weight changes in a MCAO model

TTC staining of the individual brains demonstrated that the ipsilateral hemisphere of animals given HSA had smaller infarction sizes than those given saline. In particular, animals on saline experienced severe atrophy compared to the treatment group. The cortex of the ipsilateral hemispheres of animals on HSA was mostly conserved and thus showed the entire cortical shape, whereas the cortex of animal on saline almost disappeared (Fig. 2A). The HSA group also had significantly smaller infarct size of the cortex than the saline group (p-value=0.0013, Fig. 2B).

We graded the animals with modified neurological severity scores (mNSS) on days 1, 7 and 14 after MCAO. mNSS of animals with HSA administration was significantly lower than the saline group on days 1 (p-value=0.0006) and 7 (p-value=0.0175) after MCAO (Fig. 2C). However, on day 14 after MCAO, the albumin

group graded higher scores. Since the weight of the albumin group increased more than the saline group, they were unable to suspend from the beam for a long time.

We weighed all animals on alternating days after the MCAO. On the 2nd day after MCAO, the saline group had a drastic decline in weight, with the weight of the HSA group declining less than the saline group. Since then, the HSA group gained weight constantly and regularly while the saline group did not. The weight changes (%) in the two groups were significantly different until the 10th day (p-values: 4 days=0.0006, 6 days=0.0006, 8 days=0.00233, 10 days=0.02622; Fig. 2D). After the 10th day, the difference between both groups became negligible.

DISCUSSION

Albumin therapy is known to reduce brain edema and improve local vascular perfusion. It acts similarly to an antioxidant and is more powerful than vitamin E [15], without any observable side effects in humans [7-9]. Additionally, albumin provides essential fatty acids to the injured brain [16, 17]. When albumin concentrations in both plasma and interstitial fluids are high, the protein

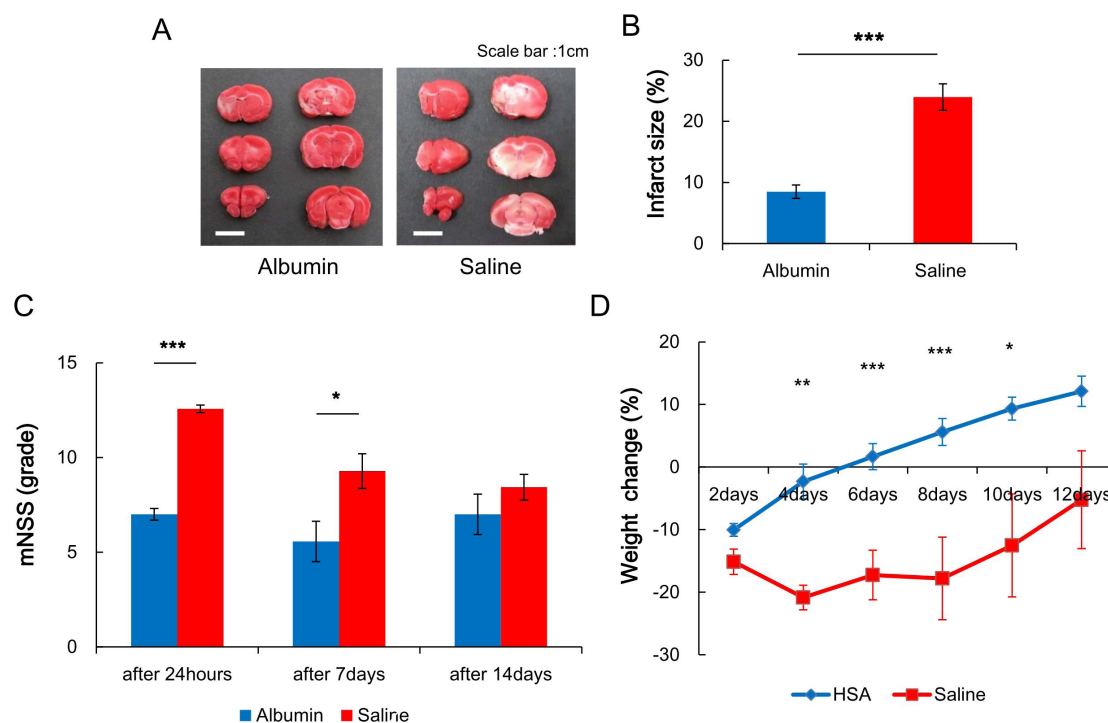


Fig. 2. Infarct size and mNSS, weight change of animals with oral gavage of HSA and saline. (A) TTC staining of the individual brain was shown that the ipsilateral hemisphere brain of an animal with oral gavage of HSA had smaller infarction than one of an animal with oral gavage of saline. (B) In average, HSA group (n=7) had smaller infarct size than saline group (n=7). (C) mNSS of HAS group (n=7) was lower than saline group (n=7) on 1 day and 7 days after MCAO. (D) After MCAO, HSA group (n=7) gained the weight constantly and regularly. But saline group (n=7) lost more weight than HSA group.

scavenge for radical oxygen and bind to free fatty acids and metal ions, thus obstructing the oxidative process of lipid peroxidation. Albumin can also inhibit copper-ion-dependent lipid peroxidation binding to copper ions. Albumin can retard the formation of highly reactive hydroxyl radical species by acting as a multiple binding site that traps free radicals [18]. In functional association with changes in redox status, the structure and beneficial antioxidant properties of albumin adjust accordingly. Albumin essentially constitutes the major plasmic target protein of oxidant stress [17]; it is the main target of reactive oxygen species (ROS) and may function to prevent oxidative damage by sequestering and reducing ROS in stroke models [19]. In addition, the ROS-sensitivity of albumin stems from its cysteine and methionine residues that have ROS-scavenging capacities [20]. These effects of albumin can thus improve reperfusion injuries in a stroke model.

Transient ischemic stroke provokes the huge loss of phospholipid-acyl groups. As such, albumin provides essential fatty acids like DHA, which can be a crucial element in facilitating neuronal membrane repair [3] and proper physical conformations of ion channels, receptors, transporters and neuroprotectin D1 (NPD1) precursors [9, 21, 22]. NPD1 is related to the reduction of neuroinflammation and activation of antiapoptotic pathways. Thus, albumin can provide protective effects to the ischemic brain.

Thus far, HSA is commonly injected intravenously to patients, including stroke patients [23]. Intravenous injections assuredly deliver materials into the vascular system, but it can be difficult in some situations such as in repeated and long term treatment. IV is an invasive method for drug medication due to its side effects such as infection [24]. On the other hand, oral administration can be easier than intravenous injections, especially if everyday treatment or preventive intervention are necessary. In addition, oral administration can be easily applied for long term medication. However, oral administration may have less availability for absorption to target sites unlike intravenous injections, such that high doses of HSA solution may be needed for MCAO models.

We found that oral administration of HSA has effects on cerebral perfusion and infarct size. We demonstrated that oral administration of HSA has neuroprotective effects on focal cerebral ischemia. MCAO animals with a two-week oral administration of HSA showed a different general spreading pattern and large maximum amplitude of cerebral blood volume (CBV) changes near the direct cortical stimulation site compared to the group given a control substance. In the normal cortex, direct electrical stimulation delivered into the cortical tissue results in notable subsequent increases in CBV along the ipsilateral hemisphere of the stimulation. In our previous study, the direct electrical stimulation caused dramatic reduction in CBV following electrical stimulation in the sensory

cortex of animals MCAO. The MCAO animal with saline administration showed similar patterns with those from our previous study that were without any given treatment [13]. However, CBV changes of the albumin group exhibited gradual increases following direct electrical stimulation, suggesting that their cortical tissue is capable of perfusing cortical blood more than the saline group. In addition, the infarction size of animals that were orally administered with HSA is significantly smaller than that of the saline group. The albumin group also showed minimal necrosis of the ipsilateral hemisphere whereas the saline group had drastic necrosis due to MCAO. These results indicate that HSA may prevent neuronal apoptosis and conserve neuronal membranes from focal cerebral ischemia. We also found that a two-week oral administration of HSA improved neurological deficits caused by MCAO. In particular, from days 4 through 10 post-MCAO, the modified NSS of the albumin group was lower than that of the saline group, suggesting that HSA delivers protective effects on multiple levels of the neurosystem, including behavior and cortical perfusion. In fact, improved cortical perfusion may lead to better cognitive function. Lastly, the gradual and stable weight gain of the albumin group may also imply less stress from focal cerebral diseases than the saline group.

The question remains as to how HSA can affect neuronal damage after the process of digestion. HAS digestion is still not well understood; it is however known to be divided at residue 307 to produce two fragments by limited pepsin digestion [25]. This degradation may result in greater exposure of the ligand domain that binds free fatty acids [20], which in turn protects neuronal cells [26]. In addition, the products from HSA degradation, such as amino acids, are harmless and can be preferentially taken in by damaged tissues for nutrition [27, 28]. Because of these properties of HSA, the protein can have beneficial effects at sites of inflammation, which are representative of the damages at focal ischemia in organ and cells [29, 30]. On the other hand, HSA that is not digested can circulate in the blood and act as neuroprotectants. Cortical neurons take up albumin directly when the blood-brain barrier is perturbed during focal ischemia. It has also been indicated that albumin may have neuroprotective effects through direct cellular uptake [31]. Given these evidence, oral administration of HSA may thus have neuroprotective effects following focal ischemia. Thus, our current study strongly suggest that a simple oral administration of HSA may have neuroprotective effects against focal cerebral ischemia in a MCAO animal model.

REFERENCES

1. Tatemichi TK, Desmond DW, Stern Y, Paik M, Sano M, Bagi-

- ella E (1994) Cognitive impairment after stroke: frequency, patterns, and relationship to functional abilities. *J Neurol Neurosurg Psychiatry* 57:202-207.
2. Mattson MP, Culmsee C, Yu ZF (2000) Apoptotic and antiapoptotic mechanisms in stroke. *Cell Tissue Res* 301:173-187.
 3. Emerson TE Jr (1989) Unique features of albumin: a brief review. *Crit Care Med* 17:690-694.
 4. Ha CE, Bhagavan NV (2013) Novel insights into the pleiotropic effects of human serum albumin in health and disease. *Biochim Biophys Acta* 1830:5486-5493.
 5. Albright AL, Latchaw RE, Robinson AG (1984) Intracranial and systemic effects of osmotic and oncotic therapy in experimental cerebral edema. *J Neurosurg* 60:481-489.
 6. Ginsberg MD (2008) Neuroprotection for ischemic stroke: past, present and future. *Neuropharmacology* 55:363-389.
 7. Belayev L, Busto R, Zhao W, Clemens JA, Ginsberg MD (1997) Effect of delayed albumin hemodilution on infarction volume and brain edema after transient middle cerebral artery occlusion in rats. *J Neurosurg* 87:595-601.
 8. Belayev L, Liu Y, Zhao W, Busto R, Ginsberg MD (2001) Human albumin therapy of acute ischemic stroke: marked neuroprotective efficacy at moderate doses and with a broad therapeutic window. *Stroke* 32:553-560.
 9. Belayev L, Marcheselli VL, Khoutorova L, Rodriguez de Turco EB, Busto R, Ginsberg MD, Bazan NG (2005) Docosahexaenoic acid complexed to albumin elicits high-grade ischemic neuroprotection. *Stroke* 36:118-123.
 10. Zoellner H, Höfler M, Beckmann R, Hufnagl P, Vanyek E, Bielek E, Wojta J, Fabry A, Lockie S, Binder BR (1996) Serum albumin is a specific inhibitor of apoptosis in human endothelial cells. *J Cell Sci* 109:2571-2580.
 11. Belayev L, Zhao W, Pattany PM, Weaver RG, Huh PW, Lin B, Busto R, Ginsberg MD, Mori S, Traystman RJ (1998) Diffusion-weighted magnetic resonance imaging confirms marked neuroprotective efficacy of albumin therapy in focal cerebral ischemia. *Stroke* 29:2587-2599.
 12. Huh PW, Belayev L, Zhao W, Busto R, Saul I, Ginsberg MD (1998) The effect of high-dose albumin therapy on local cerebral perfusion after transient focal cerebral ischemia in rats. *Brain Res* 804:105-113.
 13. Sim J, Jo A, Kang BM, Lee S, Bang OY, Heo C, Jhon GJ, Lee Y, Suh M (2016) Cerebral hemodynamics and vascular reactivity in mild and severe ischemic rodent middle cerebral artery occlusion stroke models. *Exp Neurobiol* 25:130-138.
 14. Chen J, Li Y, Wang L, Zhang Z, Lu D, Lu M, Chopp M (2001) Therapeutic benefit of intravenous administration of bone marrow stromal cells after cerebral ischemia in rats. *Stroke* 32:1005-1011.
 15. Wayner DD, Burton GW, Ingold KU, Locke S (1985) Quantitative measurement of the total, peroxy radical-trapping antioxidant capability of human blood plasma by controlled peroxidation. The important contribution made by plasma proteins. *FEBS Lett* 187:33-37.
 16. Peters T Jr (1996) All about albumin: biochemistry, genetics, and medical applications. Academic press, San Diego, CA.
 17. Roche M, Rondeau P, Singh NR, Tarnus E, Bourdon E (2008) The antioxidant properties of serum albumin. *FEBS Lett* 582:1783-1787.
 18. Halliwell B, Gutteridge JM (1990) The antioxidants of human extracellular fluids. *Arch Biochem Biophys* 280:1-8.
 19. Shin DH, Moon GJ, Bang OY (2007) Albumin therapy in acute stroke patients. *J Neurol* 254:870-878.
 20. Candiano G, Petretto A, Bruschi M, Santucci L, Dimuccio V, Prunotto M, Gusmano R, Urbani A, Ghiggeri GM (2009) The oxido-redox potential of albumin methodological approach and relevance to human diseases. *J Proteomics* 73:188-195.
 21. Belayev L, Saul I, Huh PW, Finotti N, Zhao W, Busto R, Ginsberg MD (1999) Neuroprotective effect of high-dose albumin therapy against global ischemic brain injury in rats. *Brain Res* 845:107-111.
 22. Goslinga H, Eijzenbach V, Heuvelmans JH, van der Laan de Vries E, Melis VM, Schmid-Schönbein H, Bezemer PD (1992) Custom-tailored hemodilution with albumin and crystalloids in acute ischemic stroke. *Stroke* 23:181-188.
 23. Martin RH, Yeatts SD, Hill MD, Moy CS, Ginsberg MD, Palesch YY; ALIAS Parts 1 and 2 and NETT Investigators (2016) Alias (albumin in acute ischemic stroke) trials: analysis of the combined data from parts 1 and 2. *Stroke* 47:2355-2359.
 24. O'grady NP, Alexander M, Burns LA, Dellinger EP, Garland J, Heard SO, Lipsett PA, Masur H, Mermel LA, Pearson ML, Raad II, Randolph AG, Rupp ME, Saint S; Healthcare Infection Control Practices Advisory Committee (HICPAC) (2011) Guidelines for the prevention of intravascular catheter-related infections. *Clin Infect Dis* 52:e162-e193.
 25. Heaney-Kieras J, King TP (1977) Limited pepsin digestion of human plasma albumin. *J Biol Chem* 252:4326-4329.
 26. Yoshida S, Inoh S, Asano T, Sano K, Kubota M, Shimazaki H, Ueta N (1980) Effect of transient ischemia on free fatty acids and phospholipids in the gerbil brain. Lipid peroxidation as a possible cause of postischemic injury. *J Neurosurg* 53:323-331.
 27. Kratz F, Beyer U, Schumacher P, Krüger M, Zahn H, Roth T,

- Fiebig HH, Unger C (1997) Synthesis of new maleimide derivatives of daunorubicin and biological activity of acid labile transferrin conjugates. *Bioorg Med Chem Lett* 7:617-622.
28. Rahimnejad M, Jahanshahi M, Najafpour G (2006) Production of biological nanoparticles from bovine serum albumin for drug delivery. *Afr J Biotechnol* 5:1918-1923.
29. Fasano M, Curry S, Terreno E, Galliano M, Fanali G, Narciso P, Notari S, Ascenzi P (2005) The extraordinary ligand binding properties of human serum albumin. *IUBMB Life* 57:787-796.
30. Kratz F (2008) Albumin as a drug carrier: design of prodrugs, drug conjugates and nanoparticles. *J Control Release* 132:171-183.
31. Remmers M, Schmidt-Kastner R, Belayev L, Lin B, Busto R, Ginsberg MD (1999) Protein extravasation and cellular uptake after high-dose human-albumin treatment of transient focal cerebral ischemia in rats. *Brain Res* 827:237-242.