

A RADIOLOGICAL STUDY
OF THE
INTRACRANIAL ARTERIOVENOUS MALFORMATIONS

BY

CHARLES DARGAVILLE THOMSON MACLEAN

M.B., Ch.B., (Glasgow)

M.R.C.P., (Edinburgh)

D.M.R.D., (England)

ProQuest Number: 13838678

All rights reserved

INFORMATION TO ALL USERS

The quality of this reproduction is dependent upon the quality of the copy submitted.

In the unlikely event that the author did not send a complete manuscript and there are missing pages, these will be noted. Also, if material had to be removed, a note will indicate the deletion.



ProQuest 13838678

Published by ProQuest LLC (2019). Copyright of the Dissertation is held by the Author.

All rights reserved.

This work is protected against unauthorized copying under Title 17, United States Code
Microform Edition © ProQuest LLC.

ProQuest LLC.
789 East Eisenhower Parkway
P.O. Box 1346
Ann Arbor, MI 48106 – 1346

C O N T E N T S

	<u>Page</u>
1. Introduction	1.
2. Incidence of the arteriovenous malformations	4.
3. Pathology	6.
a. Of the arteriovenous malformations	6.
b. Relation to other vascular anomalies	10.
4. The Skull. Radiographic appearances in the presence of the arteriovenous malformations	17.
a. As a result of involvement of the internal and external carotid, and the vertebral arteries	17.
b. The venous channels	21.
c. Calcification	25.
5. Ventriculography and Encephalography	29.
6. Cerebral Angiography in the diagnosis of the Intracranial Arteriovenous Malformations	31.
7. Possible increase in size of the arteriovenous malformations	45.
8. Angiographic appearances of the arteriovenous malformations	48.
a. Epilepsy	48.

	<u>Page</u>
b. Headache	49.
c. Haemorrhage	50.
d. Intracranial bruit	58.
9. Differential diagnosis	60.
10. Value of angiography in assising the possibilities and results of treatment	63.
11. Discussion	67.
12. Summary	77.
13. References	83.
14. Appendix	90.

P R E F A C E

Arteriovenous malformations, at one time considered among the rarest of intracranial lesions, have been frequently diagnosed in recent years as a result of the widespread use of cerebral angiography. Many examples have now been recorded in the literature and their pathological aspects have been extensively studied, but little attempt has been made to fully evaluate the diagnostic potentialities of radiology and especially cerebral angiography, and to correlate the radiographic appearances with the clinical findings. For example, can cerebral angiography be relied on to provide a diagnosis in every case, regardless of the size and position of the lesion? Is there any proof, for the view which is commonly held, that the lesions increase in size? Are all lesions equally liable to haemorrhage, or are there any specific features from which a lesion which bleeds can be recognised? Do lesions which present with headache and epilepsy and those which have an intracranial bruit have any special characteristics? What relationship, if any, is there between the arteriovenous malformation and the lesions

described as "venous" and "arterial" angiomas?

With this in view 32 consecutive cases have been collected from the records of the London Hospital, in all of which cerebral angiography has provided reasonable proof of the existence of an arteriovenous malformation. The pathology of the lesion and its relationship within the wider group of vascular malformations is first defined in order to understand the precise nature of the lesion, since a wide variety of titles has been used to record the same condition. There follows an account of the changes which may be seen with routine skull radiography, air-studies of the ventricular system and with cerebral angiography. Reproductions of the original radiographs are used to illustrate the particular points in the thesis as they arise. The case histories are presented in the appendix.

I am indebted to Dr. M. H. Jupe for his kind permission to reproduce the radiographs taken in his department at the London Hospital, to Sir Russell Brain and Mr. D. W. C. Northfield for access to their case records and to Professor D. S. Russell for her permission to quote relevant pathological data.

I N T R O D U C T I O N

The type of lesion, in which an arteriovenous communication is established through the medium of a mass of abnormal blood vessels, was known to Virchow (1863), but the first description of an arteriovenous malformation of the brain is credited to Steinheil in 1895 (Dandy 1928a). Vascular lesions of the brain undoubtedly of this type had been recognised earlier, as for example, the case reported by D'Arcy Power (1888), but the authors concerned failed in their studies of the morbid anatomy to recognise the essential arteriovenous nature of the lesions. The early accounts of the pathology were mainly concerned with determining the origin of the lesion, whether developmental anomaly or tumour, but no useful purpose would be served by pursuing this argument as it is now generally accepted that they are congenital. A complete review of the literature of the angiomatous lesions, to 1928, is contained in the classical monograph of Cushing and Bailey. Confirmation of the arteriovenous nature of the lesion was provided during the course of exploratory craniotomy, usually for suspected intracranial tumour, when the pulsating mass of blood vessels and the presence of arterial blood in the veins of exit left no doubt as to the presence

of an arteriovenous shunt (Cushing and Bailey 1928, Dandy 1928a). Further advance in our knowledge of the condition followed the introduction of a method of cerebral arteriography by Egaz Moniz in 1927, though some years were to elapse before the development of a percutaneous method of injection of the carotid artery (Loman and Myerson 1936, Shimidzu 1937, Engeset 1937, Lindgren 1947) and the substitution of the comparatively non-toxic diodone for thorostrast made for the wide acceptance of the method. The way was now clear for the demonstration of a lesion in the living subject and the accurate recording of its anatomical connections made possible surgical excision.

Most accounts of the intracranial arteriovenous malformations have been concerned primarily with the pathological and clinical aspects of the condition and there are few which have dealt with the radiology. Early reports emphasised the changes present on routine skull radiography (Lindblom 1936) and with ventriculography and encephalography (Ray 1941, Holmgren 1947), but these are now regarded as of secondary importance to the angiographic diagnosis. Although twenty years have passed since Egaz Moniz, d'Abreu and d'Oliveira (1932) described their first case of arteriovenous malformation demonstrated by

angiography, it is only in recent years that many cases of this type have been recorded. The earliest and most complete account of the arteriovenous malformations, in which arteriography is employed in diagnosis, is contained in the monograph of Bergstrand, Olivecrona and Tönnis (1936) who described 22 cases of the condition. This work was subsequently enlarged on by Olivecrona and Riives (1948) who added another 43 cases, making it the most complete general survey of the arteriovenous malformations to date. Mackenzie (1953) has recently published his results of a clinical study of 50 cases from the National Hospital for Nervous Diseases.

Incidence

The arteriovenous malformations have been considered among the rarest of "brain tumours" (Worster Drought and Carnegie Dickson 1927). Dandy (1928a) was able to find only 22 genuine examples in the literature, though he realised that the lesion was not as uncommon as was suggested by the small number of reported cases. Ray (1941) added six cases to the 75 he found in the literature, but up to that time angiography had not been widely used in diagnosis. Engeset (1944) found a variation in the reported incidence of 0.6 - 7.4 per cent. of the total number of brain tumours. Olivecrona and Riives (1948) reported 60 cases from a total of 3,200 brain tumours, giving an incidence of 1.84 per cent. More recent reports have recorded the number of cases in relation to the total number of angiographic examinations. Wickbom (1950) found 41 cases out of a total of 2,259 examined by angiography (1.8 per cent.) and Sutton and Hoare (1951) 70 cases from 1,500 examinations (4.7 per cent.). Mckissock (1950) stated that he had seen 39 cases in the course of his neurosurgical practice, in a period of two years. Mackenzie (1953) reported 50 cases, which amounted to one per cent. of the neurological admissions.

The present series of 32 cases was observed at the London Hospital between the years 1948-51, an average of six per year. The number of cases in relation to the total examined by angiography was 4.8 per cent., and to the number of brain tumours approximately 2.4 per cent.

Pathology

The type of lesion to be described has been recorded under a wide variety of titles. Turner (1946) lists them as follows:

Terminology	Author
Angioma arteriale	Cushing and Bailey (1928)
Cirsoid aneurysm	Uiberall (1930)
Arteriovenous angioma	Wolf and Brock (1935)
Arterio-venous aneurysm	Bergstrand et al (1936)
Aneurysmal angioma	Craig (1939)
Arterio-venous hamartoma	Turner and Kernohan (1941)

In the present context arteriovenous malformation is preferred to the above terminologies since it avoids confusion on the one hand with angioma, which may imply tumour, and on the other with aneurysm of the carotico-cavernous type.

The lesion consists of a closely woven tangle of vessels which replace the normal capillary bed and form a collecting link between artery and vein. The arteries

supplying the lesion may be much dilated and tortuous and there is marked fullness and enlargement of the efferent veins. On histological examination the vessels appear of indeterminate structure; some like arteries, others like veins. The walls show thickening of the intima and faulty development of the elastic interna. Hyaline and fatty degeneration may occur and calcium may be found in the walls of the vessels. Cushing and Bailey (1928) considered the presence of parenchymatous tissue between the vessels to be proof of the anomalous nature of the lesions. The difficulty in determining the precise structure of the vessels was responsible for much confusion in the earlier literature and led to the separate description of arterial and venous types depending on the predominant vessel present. But it is this very difficulty of interpretation which characterises the lesion (Cushing and Bailey 1928, Dandy 1928a, Sargent 1930, Butsch and Adson 1935). It has been considered by Bergstrand (1936) that any difference which exists between the two types of lesion is physiological and not pathological.

The arteriovenous malformations may be found anywhere within the brain or its coverings, though commonly they are within the distribution of the middle cerebral artery. They vary considerably in size and shape; the large

lesions are usually wedge or cone-shaped the apex of which extends towards the lateral ventricle and is sometimes partly within it. They fit into the brain substance with little or no displacement of the surrounding tissues, an argument in favour of their establishment in early foetal life (Levine 1943). It has been stated that they are invariably exposed on the surface of the brain (Cushing and Bailey 1928, Wolf and Brock 1935, Bergstrand et al 1936) but this can only apply to the large lesions. The small deeply placed lesions will however often be revealed by the engorged drainage veins coursing the surface of the brain.

Most of the lesions are found in the cerebral hemispheres, but they may also be cerebellar in site (Cushing and Bailey 1928, Bergstrand et al 1936). Mid-brain localisation also occurs and is frequently associated with a retinal vascular abnormality (Wyburn-Mason 1943). Lesions confined to the distribution of the external carotid artery are rare (Lambert Rogers 1933-34, Verbiest 1951), though external carotid artery communications with an intracerebral lesion is not so uncommon. Russell and Nevin (1940) reported two cases of an unusual type in which there was direct arterial connection with the great vein of Galen, the latter assuming aneurysmal

dimensions and causing hydrocephalus from pressure on the mid-brain. Eight cases of this type have so far been recorded in the literature (Alpers and Forster 1945, Jaeger and Forbes 1946, Oscherwitz and Davidoff 1947, Boldrey and Miller 1949).

Relation to the other Intracranial

Vascular Malformations

The arteriovenous malformation is the commonest of a group of intracranial vascular anomalies (Bergstrand 1936). Its relationship to the other lesions is of some importance since study of the group as a whole may help to explain the nature of certain lesions which have been accorded a separate identity when they are in all probability the same as the arteriovenous type.

It has been suggested by Cushing and Bailey (1928), that the type of lesion is determined by the degree of differentiation of the embryonic vascular system, at the time when the disturbance of growth responsible for its development occurs. Thus on the basis of the five arbitrary periods of development of the human brain described by Streeter (1918), the arteriovenous malformation would arise during the second period when the primordial vascular plexus resolves itself into arteries veins and capillaries. The presence of a naevus on the face or scalp together with a meningeal vascular lesion (Sturge-Weber syndrome), would be explained by an abnormal cleavage into external dural and cerebral layers in the

third period. Gross anomalies in the course of the vascular trunks would occur during the fourth period when rearrangement normally occurs.

There have been several attempts made to classify these lesions, Noran (1945) listed eight separate classifications and added one of his own. Of these, only two are sufficiently well-known to merit further description. They are the classifications of Cushing and Bailey (1928) and of Bergstrand (1936).

Classification of Cushing and Bailey

1. Vascular malformations.
 1. Telangiectasis.
 2. Angioma venosum.
 3. Angioma arteriale.
2. Haemangioblastoma.
 1. Cystic type.
 2. Solid type.

Classification of Bergstrand

1. Angioma cavernosum.
2. Angioma racemosum.
 1. Telangiectasis.
 2. Sturge-Weber syndrome.
 3. Angioma racemosum arteriale.
 4. Angioma racemosum venosum.
 5. Aneurysma arteriovenosum.

Classification of Bergstrand (Continued)

3. Angioreticuloma (Lindau).
4. Angioglioma (Roussy and Oberling).

The fundamental difference between these two classifications is the separation by Cushing and Bailey of the malformations from the haemangioblastomas, which they regard as true tumours. Bergstrand (1936) has however stated that, "All attempts to classify the haemangiomatous growths of the nervous system as either tumours in the narrow sense, or as malformations are bound to be misleading, because the two conceptions do not exclude each other. Most, perhaps all, of the true haemangiomas are malformations which have attained an autonomous growth". Both classifications may be criticised on the grounds of incompleteness. For example simple varices and the rare arteriovenous lesion in which direct communication is established between artery and vein are not mentioned. Furthermore, the inclusion by Bergstrand of a true arterial malformation in his classification is hardly justified since he has considered the existence of such a lesion to be doubtful.

Many of the reported cases of angioma venosum have clearly from their clinical and pathological descriptions been arteriovenous in type, the erroneous diagnosis being based on the predominance of veins in the lesion. In addition it has been considered that a lesion originally venous could acquire arterial connections and so become converted to the arteriovenous type (Cushing and Bailey 1928, Wolf and Brock 1935). The pathological borderline between a venous and arteriovenous lesion was therefore never clearly defined. The venous racemose angioma is, according to Lima (1950), found exclusively in the dura mater near the mid-line and a similar type of lesion has been described by Dandy (1928b) as a venous aneurysm of the sagittal sinus. Simple and complex varices of the cerebral veins have been observed by several authors and must be ascribed a separate entity (Cushing and Bailey 1928, Dandy 1928b, Schaltenbrand 1938, Noran 1945).

Consideration of the Sturge-Weber lesion as a venous angioma has only led to confusion in the literature. The characteristic feature is the sclerosis and calcification of the cerebral cortex (Krabbe 1932), and abortive forms have been recorded in which the angiomatous condition of the meninges is absent (Noran 1945).

Yakolev and Guthrie (1931) considered the condition to be a disturbance of development of the ectoderm and allied to multiple neurofibromatosis and tuberosc sclerosis. There is no evidence that an arteriovenous malformation is ever associated with the Sturge-Weber syndrome though the presence of a trigeminal naevus and an arteriovenous malformation has been recorded (Brock and Dyke 1932).

The telangiectases are small lesions of capillary structure usually occurring in the pons or brain stem (Michael and Levin 1936, Russell 1941). They are unlikely to be mistaken on pathological examination for small arteriovenous lesions unless haemorrhage (Reitzel and Brindley 1929) so obscures the area as to make accurate identification of the lesion impossible.

The cavernous angiomas are rare lesions. Grossly they appear as lobulated masses of variable size and on section they are seen to consist of small and large vascular spaces containing blood and blood clot. They may bear a superficial resemblance to an arteriovenous malformation and Noran (1945) had suggested that the cases reported by Christiansen (1921) and Yates and Paine (1930) were of this type. Histological examination shows them

to be quite distinct. They consist of a non-encapsulated system of cavernous and capillary spaces the walls of which are wholly composed of collagen and they are lined by a single layer of endothelial cells. The white matter of the cerebral hemispheres and the basal ganglia are the commonest sites for the lesion (Russell 1931). It has been suggested by Russell (1930 and 1941) that adjacent capillary loops of a telangiectasis may fuse and give rise to a cavernous lesion and in support of this hypothesis she cites a case with multiple lesions in which some appeared as telangiectases and others as cavernous angiomas. Wolf and Brock (1935) have described a lesion which they considered to be an intermediate variant between a telangiectasis and a venous angioma and Trupp and Sachs (1948) were of the opinion that imperceptible variations existed between telangiectasis and venous and arterial angioma. There is however no proof that a telangiectasis could ever develop into an arteriovenous malformation. The angioblastomas are tumours composed of angioblasts, the primitive cells which normally form the foetal blood vessels. There are no well-differentiated blood vessels in the tumour. The condition may be associated with an angioblastic tumour of the retina (von Hippel's disease)

and with various congenital lesions of other organs, such as cystic disease of the pancreas, kidneys and liver, or with tumour of the suprarenal (Lindau's disease). The tumour which shows a marked tendency to form cysts, though it may remain solid, is commonly situated in the cerebellum but it may also occur above the tentorium (Barnard and Walshe 1931, Cohen 1942). There is usually a large artery and vein supplying the lesion. No difficulty will normally arise with the pathological diagnosis though with angiography, differentiation from an arteriovenous malformation will have to be considered (vide infra).

The Skull: Radiographic features in the presence of the
Intracranial Arteriovenous Malformations

The effect of an arteriovenous shunt is to lead to dilatation and increased volume of pulsation of the feeding arteries and to engorgement and pulsation of the drainage veins. Thus foramina and grooves which transmit the hypertrophied vessels may enlarge and localised areas of rarefaction may be seen in the skull vault over the site of the malformation, or its drainage veins. A rare occurrence is thickening of the skull in response to the greatly increased vascularity of the bone. The position of the lesion may in a few cases be indicated by the presence of calcium deposits in or around it.

Bergstrand (1936) recognised three main types of arteriovenous malformation: those limited to the internal carotid artery, to the external carotid artery, or involving both. To these may be added lesions supplied by the vertebral artery.

Internal carotid artery

Most of the arteriovenous malformations are within the distribution of the internal carotid artery so that some widening of the carotid canals to accommodate the hypertrophied vessels would be expected. Lindblom (1936)

reported an increase in size of the canals in four of his cases. Both canals are usually enlarged, the contralateral one also to some degree, because of the shunt of blood through the circle of Willis to the affected hemisphere. No attempt has been made to measure the carotid canals of the present cases, since their accurate delineation in skull radiographs is not usually possible. Widening of the foramen lacerum has been recorded by Wyburn-Mason (1943) and erosion of one side of the sella turcica by Moore (1951).

The External Carotid Artery

Radiographic changes in the skull attributable to hypertrophy of branches of the external carotid artery were present in four of the present cases (13 per cent.) and were due to the meningeal arteries being additional feeding vessels to lesions within the brain. There were no examples of malformations confined to the external carotid artery distribution, as have been described by others (Lambert Rogers 1933-34, Bergstrand et al 1936, Shearer 1952). Olivecrona and Riives (1948) have also recorded involvement of the external carotid artery in 13 per cent. of their cases and they observed that the main blood supply to three intracerebral lesions came from this artery.

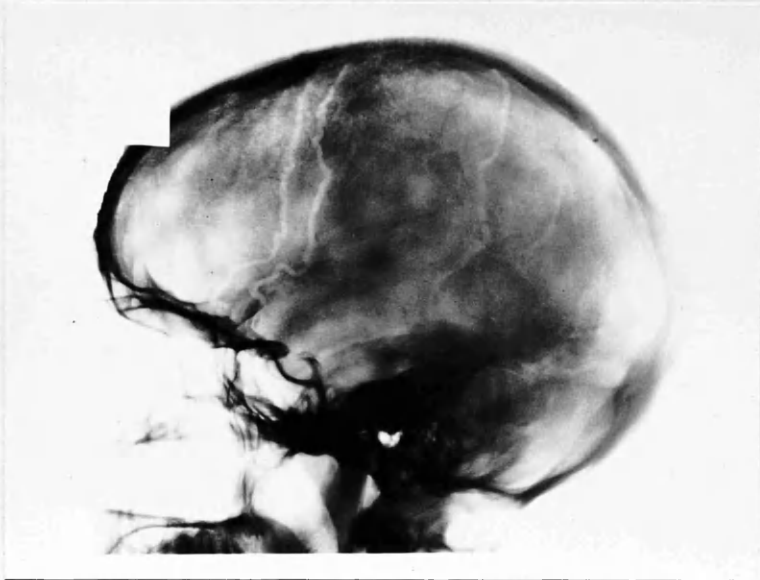

Fig. 1 Case 1
Midline Rt. parietal arteriovenous malformation.
The grooves for the meningeal arteries are prominent
and tortuous. An anomalous vascular channel is
present in the parietal region.
(see also fig. 22)

When the meningeal arteries are feeding vessels, the foramina spinosa and grooves in the skull for the arteries may become enlarged on one or both sides. Anomalous vascular channels may also appear. Prominent and tortuous meningeal artery grooves are illustrated in fig. 1. Enlargement of the meningeal vascular grooves is not always however due to hypertrophy of the artery and sometimes the vein which normally accompanies it is large and constitutes an accessory venous sinus - the meningeal sinus. This appearance may be seen on one or both sides of the skull and the uniformity of its width and lack of branches distinguish it from an arterial groove. Gross enlargement of the meningeal grooves of the "venous type" is shown in fig. 6a, though in this case hypertrophy of the accompanying arteries was most likely an associated feature.

Abnormal communications between branches of the external carotid artery in the scalp and the meningeal arteries may lead to small defects or well-defined perforations in the skull (Holmgren 1947, Shearer 1952). Numerous punctate translucencies were present in the left frontal region of Case 2 (fig. 2b) and in the parietal region of Case 3 (fig. 3a) which probably resulted from such intercommunications. Opening up of the diploic channels in the skull has been observed on several

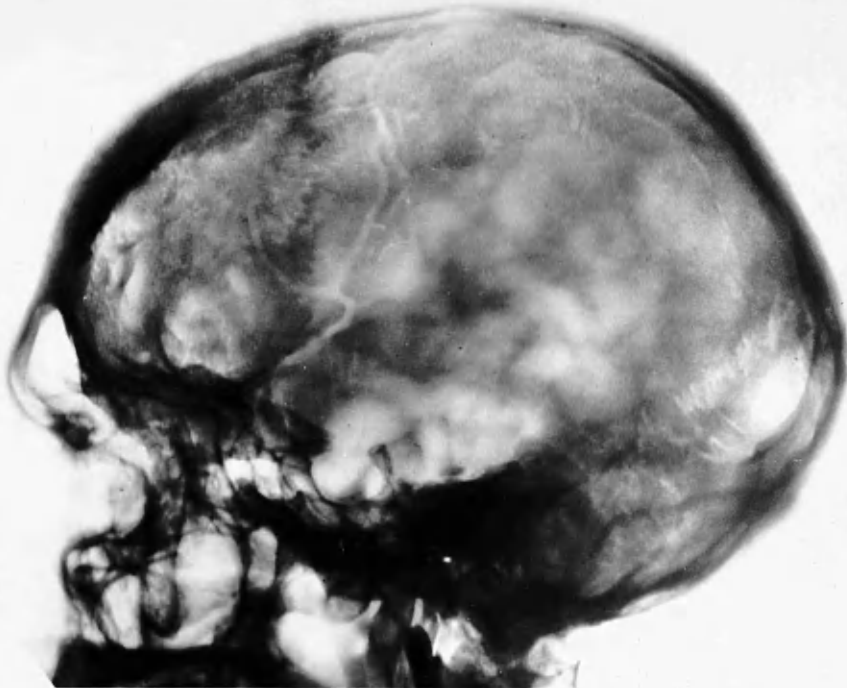


Fig. 2a Case 2
Rt. frontal arteriovenous malformation. Hypertrophic skull changes. Hyperostosis in the frontal region. Prominent meningeal vascular grooves and convolitional markings. Deep sella turcica.

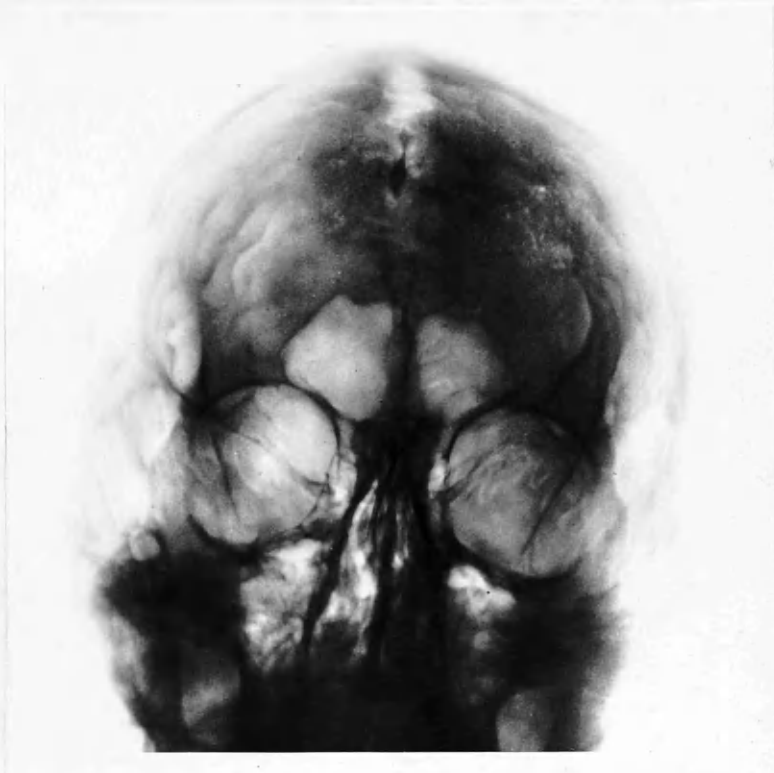


Fig. 2b Case 2
Numerous punctate translucencies in the left frontal region. Prominent superior longitudinal sinus groove. Calcification in the falx.

occasions (Cushing and Bailey 1928, Jupe 1939, Northfield 1940-41, Wyburn-Mason 1943) but was not present in the author's cases.

An unusual appearance is thickening and hypertrophy of the skull vault, which was first recorded by Brock and Dyke (1932) and subsequently by others (Ray 1941, Camp 1948, Olivecrona and Riives 1948). In the case described by Olivecrona and Riives, the hyperostosis of the skull led to a diagnosis of meningioma. Two of the present cases have shown changes of this type (Cases 2 and 3) and in one of these (Case 2) a frontal hyperostosis was present, which closely resembled at operation the hyperostosis of a meningioma. The appearances are quite distinct from the well-known condition of hyperostosis frontalis interna - the latter was present in one case (fig. 5a) but must be considered an incidental finding. An analogy for the hypertrophic skull changes is the hypertrophy of the limb bones, which may be found in some cases of congenital arteriovenous fistula. Enlargement of the sella turcica has been reported in association with an arteriovenous malformation (Cushing and Bailey 1928, Brock and Dyke 1932, Holmgren 1947). It was present in Case 2 of the present series and was probably associated with the general skull hypertrophy (see fig. 2a).

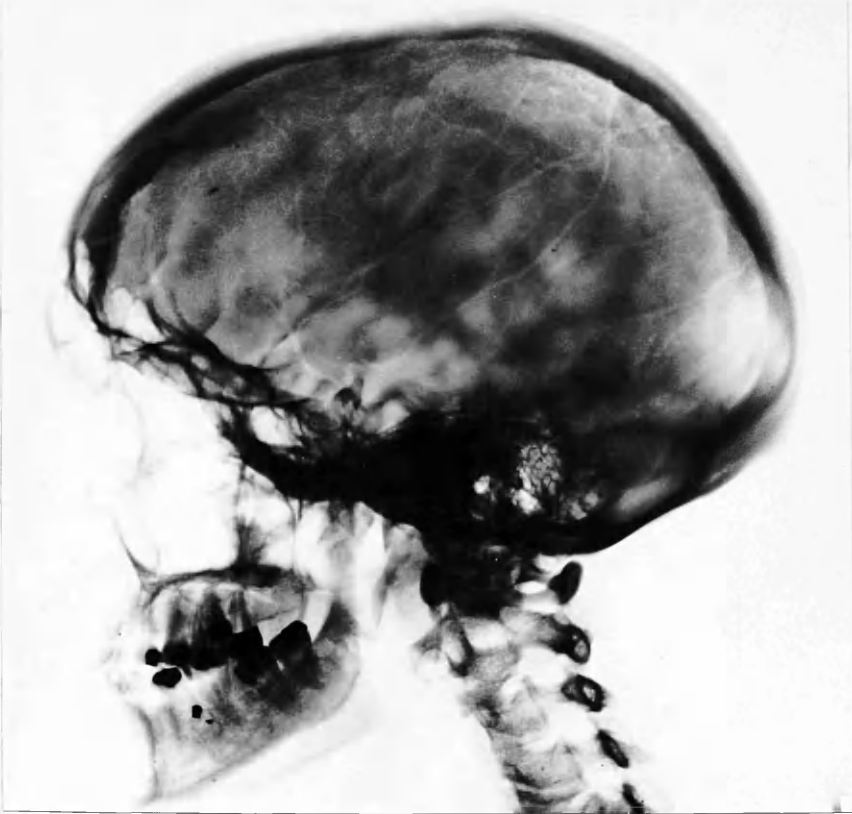


Fig. 3a Case 3

Rt. parietal arteriovenous malformation. Thick bony vault and prominent convoluted markings. Anomalous vascular channel in the parietal region. (the Rt. foramen spinosum was enlarged in the basal view).

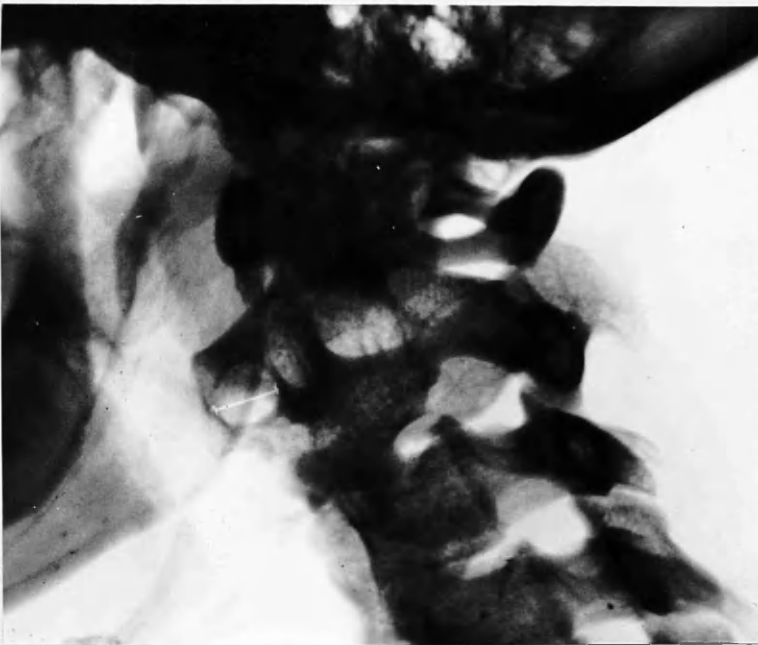


Fig. 3b Case 3

Localised view to show the enlarged foramen transversarium which measured on the film 9 mm x 8 mm. (normal max. 7 mm.)

The Vertebral Artery

Measurement of the foramen transversarium of the second cervical vertebra, which can usually be seen in the routine lateral skull radiograph, may be a useful guide to enlargement of the vertebral artery. Lindblom (1936) found a significant increase in the size of the foramen in two cases of arteriovenous malformation, as well as in two cases of cerebellar angioblastoma and two with meningioma. He gave the normal measurements as follows: minimum 3 mm., maximum 7 mm., average 5.5 mm. In one of the present cases (Case 3) the foramen measured 9 mm. by 8 mm. This degree of enlargement would suggest that there was a considerable degree of hypertrophy of the vertebral artery and if angiography of the vertebral circulation had been carried out, either additional feeding arteries from the posterior cerebral arteries or filling of the lesion through anastomosis of the circle of Willis would have been demonstrated (see fig. 3b).

The Venous Channels

Localised areas of rarefaction on the inner table of the skull due to abnormally large and pulsating drainage veins have been recorded by a number of authors (Brock and Dyke 1932, Lindblom 1936, Jentzner 1939, Ray 1941, Wyburn-Mason 1943, Turner 1946, Lima 1950) and in

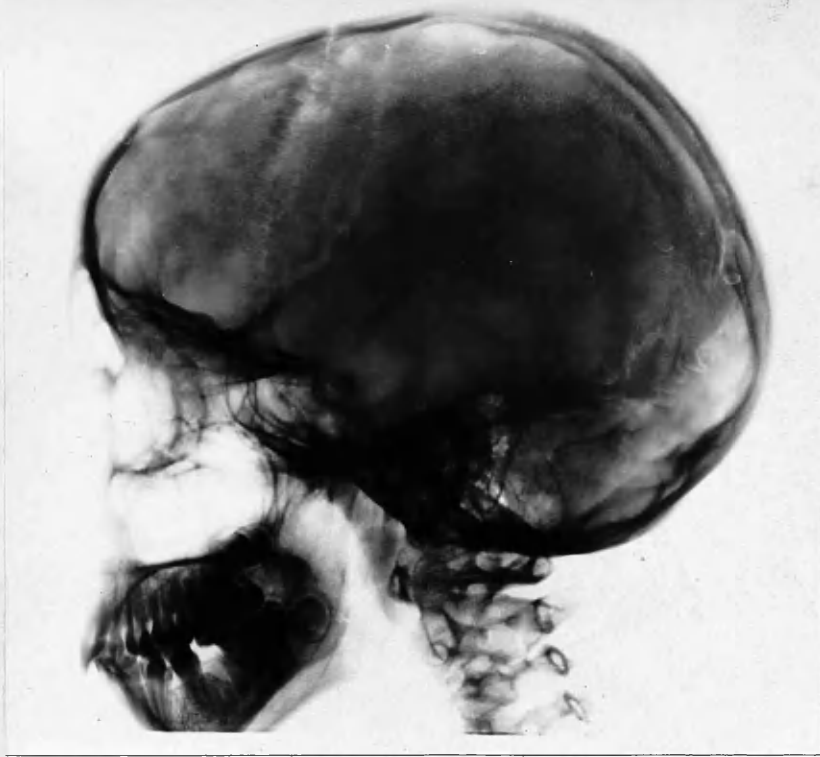

Fig. 4a Case 4
Left fronto-parietal arteriovenous malformation.
Localised areas of rarefaction are present near the
vertex of the skull.

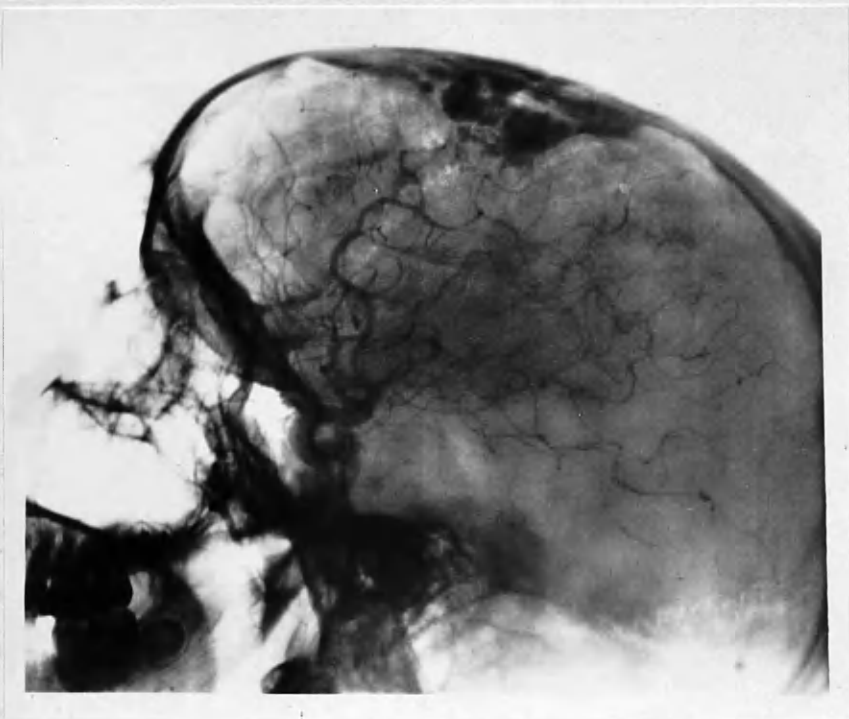


Fig. 4b Case 4
The arteriovenous malformation coincides with the
localised areas of rarefaction.

the skull radiographs of identical twins by Touraine, Golé and Sambron (1936). Only one case of the present series showed an appearance of this type (Case 4, fig. 4), though if stereoscopic radiographs had been available for all cases, the areas of rarefaction would no doubt have been recognised more often. The "beaten silver" type of appearance, which is usually associated with chronic raised intracranial pressure, was observed in the two cases which showed hypertrophic skull changes (Cases 2 and 3), probably from abnormal pulsation of the brain as a whole.

When there is a large arteriovenous shunt the venous sinuses dilate to accommodate the increased volume of blood. Raskin (1949) noted the widening of the dural sinuses, but did not comment on a corresponding increase in the size of the sinus grooves of the skull.

Olivecrona and Riives (1948) found the sulcus for the superior sagittal sinus to be enlarged in one case.

Lindblom (1936) considered that, as a normal finding, a groove for the superior sagittal sinus over any great length was unusual, though a short groove in some part of its course may be present. He gave the following measurements for the width of the groove; frontal 2 - 3 mm., parietal 6 - 8 mm., occipital 7 - 10 mm. There was no alteration in the grooves of his 12 cases of arteriovenous malformation.

Personal examination of 200 adult skull radiographs, in which there was no reason to suspect the presence of an arteriovenous lesion, showed the presence of a groove for the sagittal sinus in 76 per cent. of cases. The groove was most constantly observed in the fronto-occipital projection. The width of the groove measured directly from the films was in 90 per cent. of the cases between 7 - 11 mm. (maximum 5 - 14 mm.) and the average depth was 2.3 mm. (maximum 1 - 5 mm.) The size of the groove could not be correlated with the sex of the patient, the thickness of the skull or its vascularity, as evidenced by prominence of diploic channels or large venous lacunae. Most of the skulls in which a groove was absent belonged to the older age groups and the groove showed a tendency to decrease in depth with advancing years (3 mm. to 2 mm. between the third and the sixth decades).

Four of the present cases have shown marked widening and deepening of the sinus groove (Cases 2, 5, 6 and 24) and in ~~three~~ others (Cases 3, 7 and 11), the measurements although maximum, were still within the normal range. It is fully appreciated that the groove in the skull does not give a true representation of the cross-section of the sinus, but there can be no doubt that enlargement to the degree shown in fig. 5a (Case 5) is abnormal. This sign

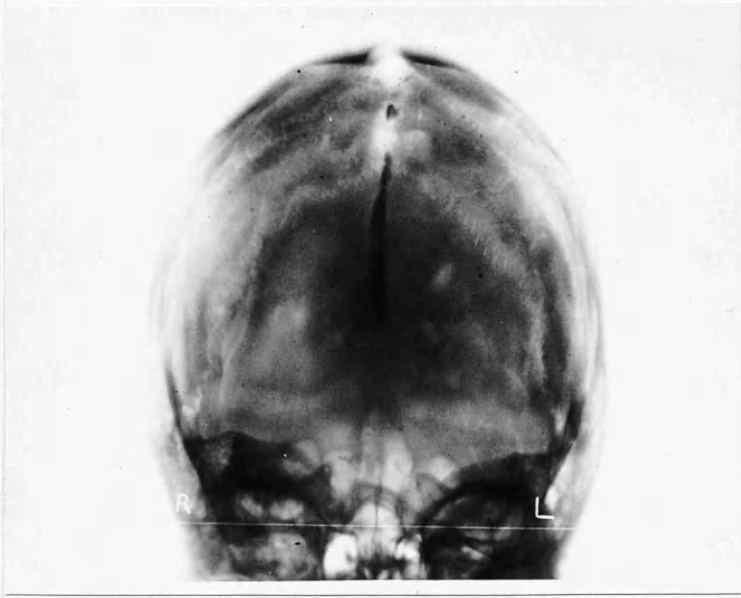


Fig. 5a Case 5
Left temporo-parietal arteriovenous malformation.
Very prominent groove for the superior longitudinal
sinus which measured 1.7 cm. x 0.6 cm.
Dense plaque of calcification in the falx.

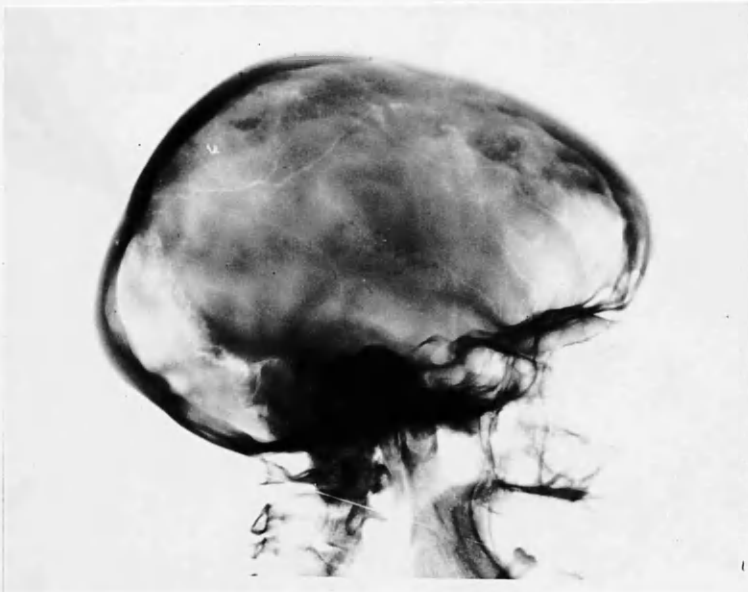

Fig. 5b Case 5
Hyperostosis frontalis interna.
Anomalous vascular channel in the parietal region.
Group of calcified opacities in the temporo-parietal region.
(see also fig. 11)

will only be positive when there is a large shunt, and the lesion is so situated that its effluents drain into the sagittal sinus. Although of limited value in diagnosis it may be useful when a lesion is confined to the intracerebral circulation, since most of the skull changes seen with routine radiography are due to involvement of the external carotid artery.

The other venous sinuses are of less help in diagnosis. The transverse sinuses produce a groove in 90 per cent. of children under 10 years of age, but in adults a groove along its whole length can be found with certainty in only 10 per cent. of cases (Lindblom 1936). This groove is not viewed tangentially in the routine skull views and the range of normal measurements is wide (4 - 17 mm., Lindblom 1936). The sigmoid sinuses are more or less clearly seen in all cases and their variation in size parallels that of the grooves for the transverse sinuses; they have no diagnostic value. The inferior petrosal sinuses are indicated in the basal view of the skull by narrow translucent strips between the clivus and the tips of the petrous pyramids. Wyburn-Mason (1943) has observed increase in size of this sinus in one case of arteriovenous malformation. The sphenoparietal sinuses run on the under surfaces of the lesser

wings of the sphenoids near their posterior edges - they may receive the middle meningeal sinuses - and when enlarged some "thinning" of the lesser wings of the sphenoid may be expected. The remaining dural sinuses cannot be satisfactorily demonstrated radiographically.

Enlargement of the jugular foramen has been reported in a case of arteriovenous malformation (Wyburn-Mason 1943), but normal variations in size are considerable and occasionally a giant jugular foramen may be present (Khoo 1946). The other foramina which transmit veins, as for example the foramen ovale would no doubt in certain cases of arteriovenous malformation enlarge, as may happen in some case of chronic raised intracranial pressure.

Calcification

The presence of calcification in an arteriovenous malformation is regarded by Nelson (1937) as a natural process of cure, and by Olivecrona and Riives (1948) as an indication of thrombosis of part of the lesion. Its incidence has varied in different reports. Bancroft and Pilcher (1946) considered that the high percentage of calcification led to easy recognition of the lesion in most cases. But this is an overstatement and of the present cases only four have shown definite calcium

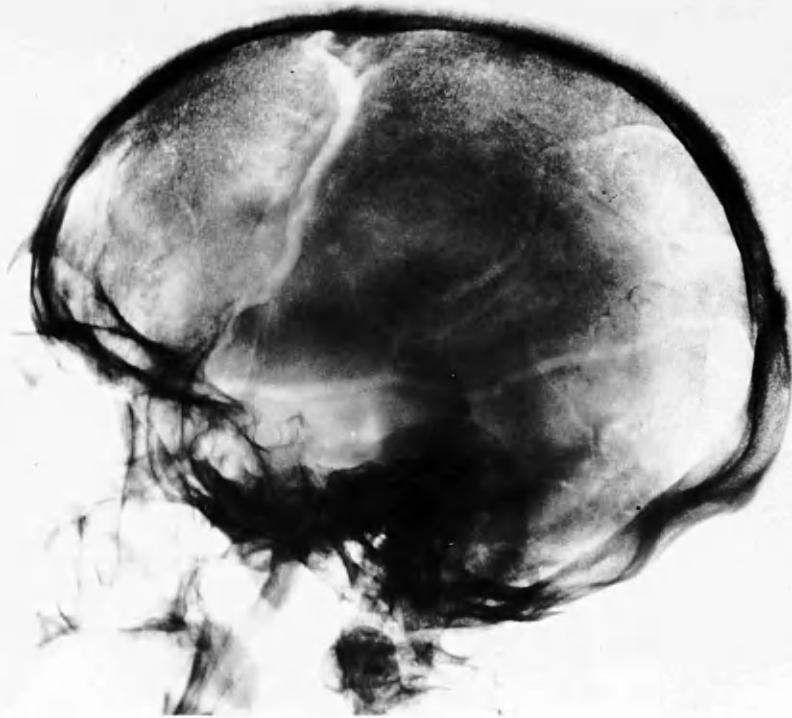

Fig. 6a Case 6

Left occipital arteriovenous malformation with calcification in the walls of the vessels.

Very prominent meningeal vascular grooves.

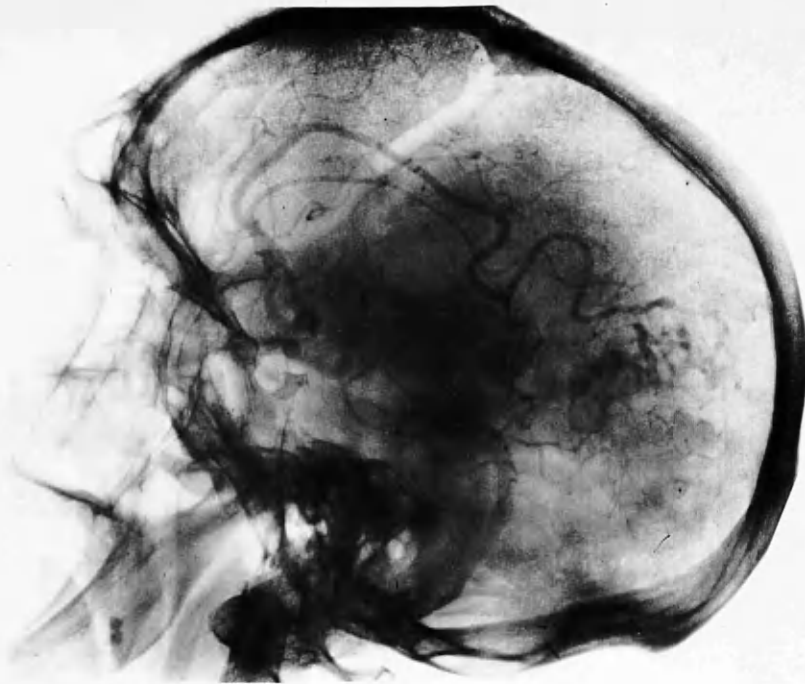


Fig. 6b Case 6

Rt. carotid arteriogram. The lesion was well filled by left carotid angiography. This view shows that the anterior cerebral artery is also a feeding vessel.

deposits (13 per cent.) This agrees fairly closely with the findings of Holmgren (1947) and Olivecrona and Riives (1948), who reported its presence in 17 and 14 per cent. of cases respectively. No doubt the pathological incidence is greater than that determined radiographically and Dandy (1928a) observed calcification in one of his cases only after the ventricle had been filled with air.

The calcification may assume various forms. When present in the walls of vessels, it may appear as circles or whorls (Dandy 1928a) or convoluted parallel lines (Schwartz 1939) and this appearance is illustrated in fig. 6a (Case 6). This type has been considered typical of vascular calcification, but Holmgren (1947) considered differentiation from a calcified oligodendroglioma to be impossible. The calcification which occurs in the cerebral cortex in the Sturge-Weber syndrome is as a rule distinctive. A sickle-shaped calcium deposit may be observed in the wall of an aneurysm and such an appearance was seen in one of the present cases (Case 20, fig. 23a). Diffuse amorphous deposits as illustrated in figs. 5a and b may occur in adjacent haematomata, as has been suggested by Northfield (1940 - 41) and Holmgren (1947). In the remaining case which showed calcification,

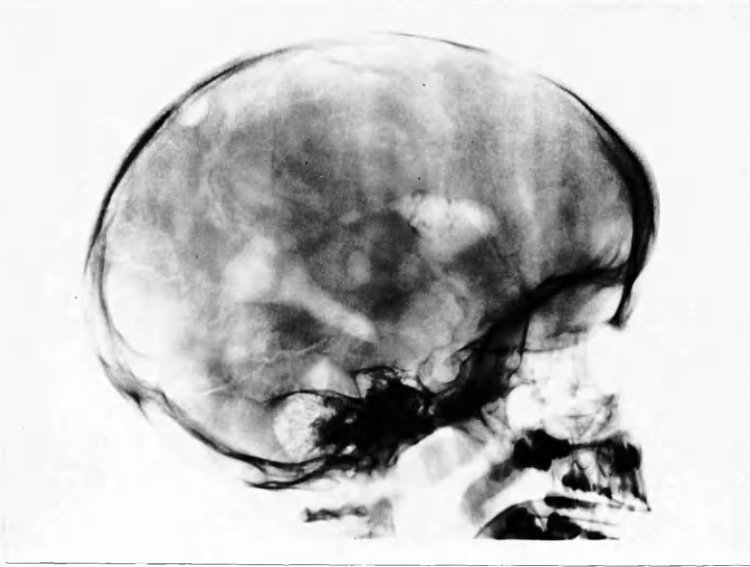

Fig. 7a Case 7
Rt. fronto-parietal arteriovenous malformation.
Air in the lateral ventricle from ventriculography.
Circumscribed area of calcification superimposed
on the frontal horn.

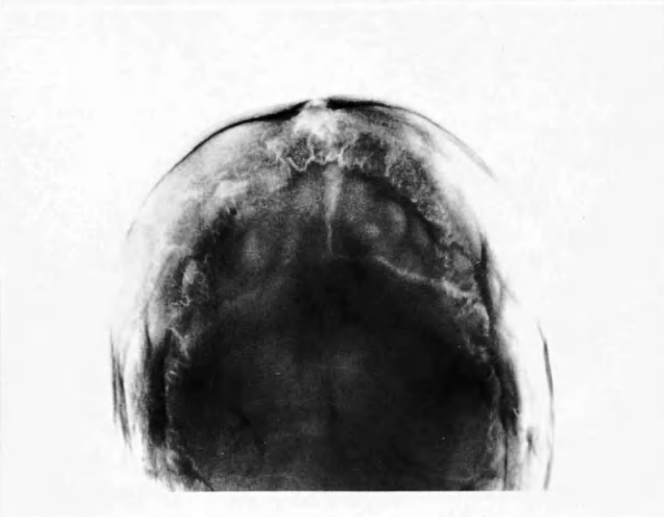

Fig. 7b Case 7
Antero-posterior view showing area of calcification.
Prominent sagittal sinus groove. (see also fig. 20)

it appeared as a circumscribed granular deposit (see fig. 7); Norlén (1949) has reported a similar appearance in one of his cases. Penfield and Ward (1949) have reported five cases of "haemangioma calcificans", in two of which the histological examination suggested that the totally calcified lesions were of the arteriovenous type. There were no special features about the calcification in these cases. Falx calcification was observed in three of the present cases but the incidence is not appreciably greater than normal, so that no particular significance can be attached to this finding.

The appearances described in the text are summarised in the accompanying table, where it can be seen that some abnormality recognisable on the skull films was present in approximately one-third of the cases. This is in agreement with Bull (1951).

TABLE I

Case No.	EXTERNAL CAROTID ARTERY			VERTEBRAL ARTERY	VENOUS CHANNELS		Calcification	
	Meningeal Grooves	Anomalous Channels	Hypertrophic Skull Changes		Perforations in vault	Enlarged Foramen Transversarium		Local Vascular Imprints
1.	+	+	-	-	-	-	-	-
2.	+	+	+	+	-	-	+	-
3.	+	+	+	?	+	-	?	-
4.	-	-	-	-	-	+	-	-
5.	-	+	-	-	+	-	+	+
6.	+	-	-	-	-	-	+	+
7.	-	-	-	-	-	-	?	+
11.	-	-	-	-	-	-	?	+
20.	-	-	-	-	-	-	-	+
24.	-	-	-	-	-	-	-	+

Ventriculography and Encephalography

The use of air as a contrast medium to outline the ventricular system of the brain, will only be employed in the diagnosis of the intracranial arteriovenous malformations, when the clinical examination and preliminary radiographs give no indication of the nature of the lesion. Holmgren (1947) used ventriculography or encephalography in 35 of his 47 cases. In seven of these the appearances were normal; 18 showed evidence of an intracranial expanding lesion and 10 had dilatation of one or both lateral ventricles. An undulating, serrated or ripple contour of the body of the lateral ventricle has been considered typical of these lesions (Hodes, Perryman and Chamberlain 1947, Wickbom 1948). Five cases of the present series were subjected to air-studies. A well-defined filling defect was present in the body, vestibule and descending horn of Case 8 (fig. 8) in the body of Case 7 and there was some flattening of the roofs of the lateral ventricles in Cases 9, 10 and 12 (see fig. 9a). There was no shift of the ventricular system.

Cerebral atrophy is a frequent finding and was general in six cases and local in 11 of the cases

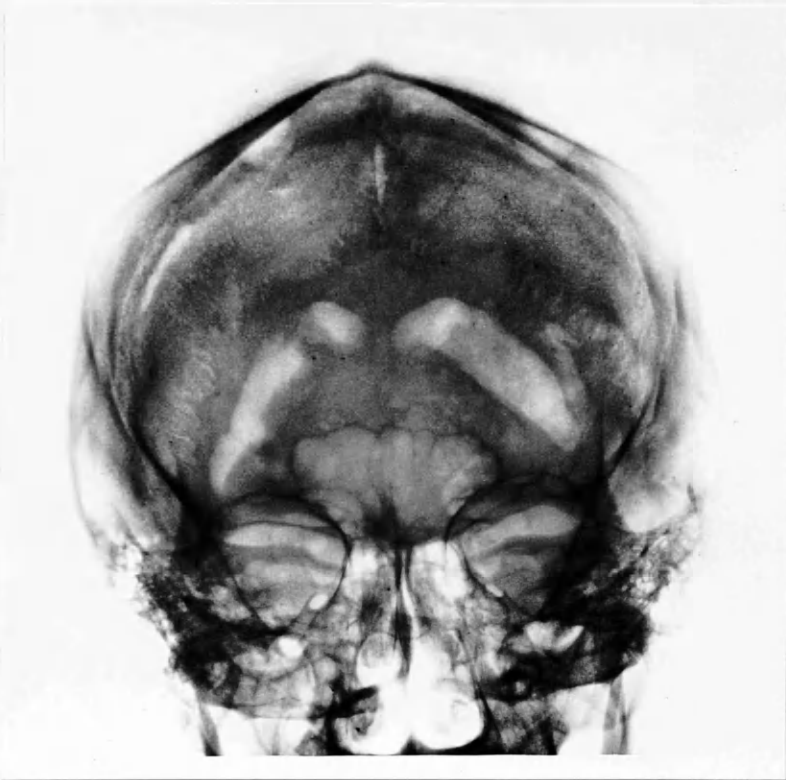


Fig. 8 Case 8
Left temporo-parietal arteriovenous malformation.
Ventriculogram P.A. view.
Filling defect near trigone of left lateral ventricle

recorded by Olivecrona and Riives (1948). Porencephalic cysts resulting from haemorrhage, may communicate with a lateral ventricle and be revealed by air-injection of the ventricles (Olivecrona and Riives 1948). Coarctation of a ventricle may result from organisation of an haematoma (Case 15). Hydrocephalus due to a small angioma which caused intermittent obstruction at the foramen of Monro has been described by Dandy (1928b) and it is of interest to note that attacks were intensified in successive pregnancies. Arteriovenous malformation of the mid-brain are particularly liable to cause hydrocephalus and Wyburn-Mason (1943) found that it was a constant autopsy finding in his series of cases. Holmgren (1947) concluded that changes may be expected in 70 per cent. of cases of arteriovenous malformation when both plain radiography and either ventriculography or encephalography are used.

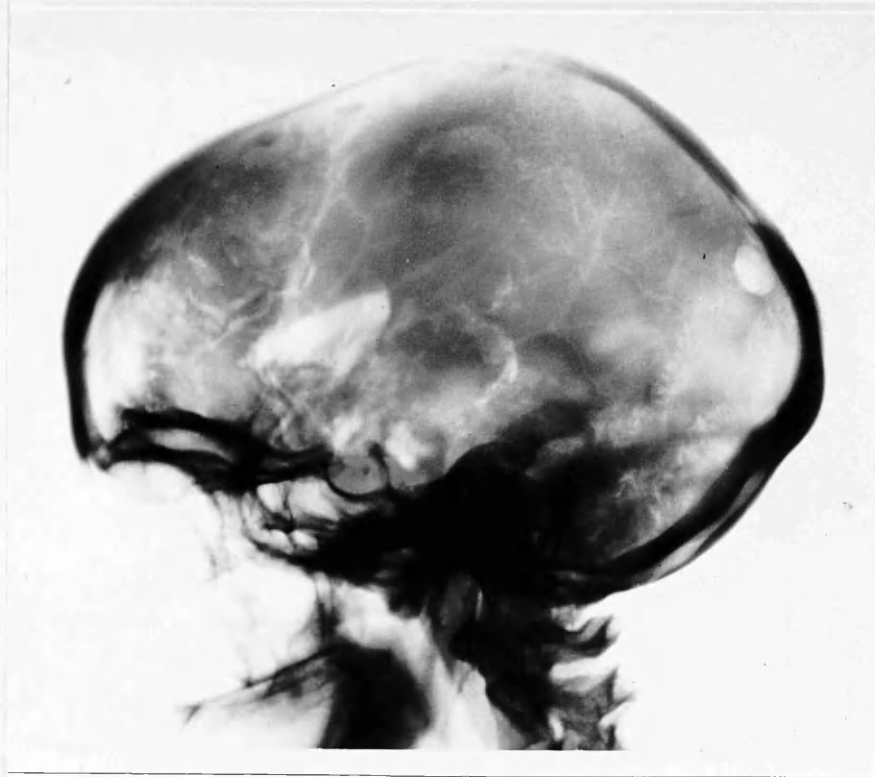

Fig. 9a Case 9
Left parietal arteriovenous malformation. There is some flattening of the roof of the anterior horn of the left lateral ventricle.

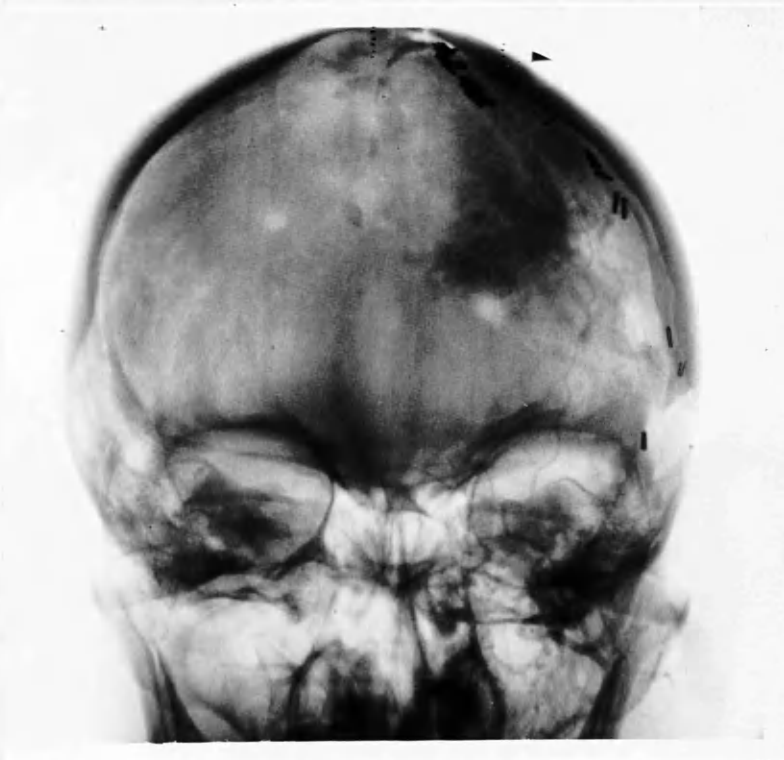


Fig. 9b Case 9
The wedge-shape of the arteriovenous malformation which extends to the lateral ventricle is clearly shown.

Cerebral Angiography in the Diagnosis of the
Intracranial Arteriovenous Malformations.

Technical Considerations.

The technique of cerebral angiography is now well-known and only those points which arise in connection with the demonstration of the arteriovenous malformations will be described. The ideal method of study would be to follow the complete course of the opaque medium through the intracerebral circulation by the use of cineradiography (Holm 1944) or failing this by the employment of rapid serial radiography as used by Curtis (1949). In most cases however, satisfactory results can be obtained by a modification of the usual standard technique, by which three radiographs are taken in the lateral position and two or three in the antero-posterior position.

The marked lowering of the peripheral resistance and the increased velocity of the blood-flow through the lesion, which may be as much as three times the normal (Shenkin, Spitz, Grant and Kety 1948), necessitate a faster rate of injection of the contrast medium, an earlier exposure of the first film and shorter intervals between the subsequent films. Wickbom (1950) recommended that the first exposure be made as early as the beginning of

the injection when the lesion is near the carotid siphon and that a series of three films be taken at 0.5 - 1 second intervals. Lombardi (1951) used 15ml. instead of the more usual 10ml. of contrast substance and exposed his first film after the injection of 6ml. But the adoption of a standard technique is not considered possible for lesions so variable in the size of their arteriovenous shunts and in the velocity of their blood flow. The experienced operator learns from the ease with which the contrast medium is injected when the first film should be exposed, and if necessary the timing can be adjusted after the first set of films have been viewed, the aim being to demonstrate the position and extent of the lesion and its vascular connections.

Although the demonstration of most arteriovenous malformations by cerebral angiography is a simple procedure, the information obtained will depend on the amount of care and attention which is paid to detail. A precise knowledge of the afferent vessels is of considerable assistance to the surgeon in assessing the operability of the lesion. A small peripheral lesion is the one most likely to be missed if the arteriogram is exposed too early, though there is a good chance that the first phlebogram will show it. Venous filling during the arterial phase should always

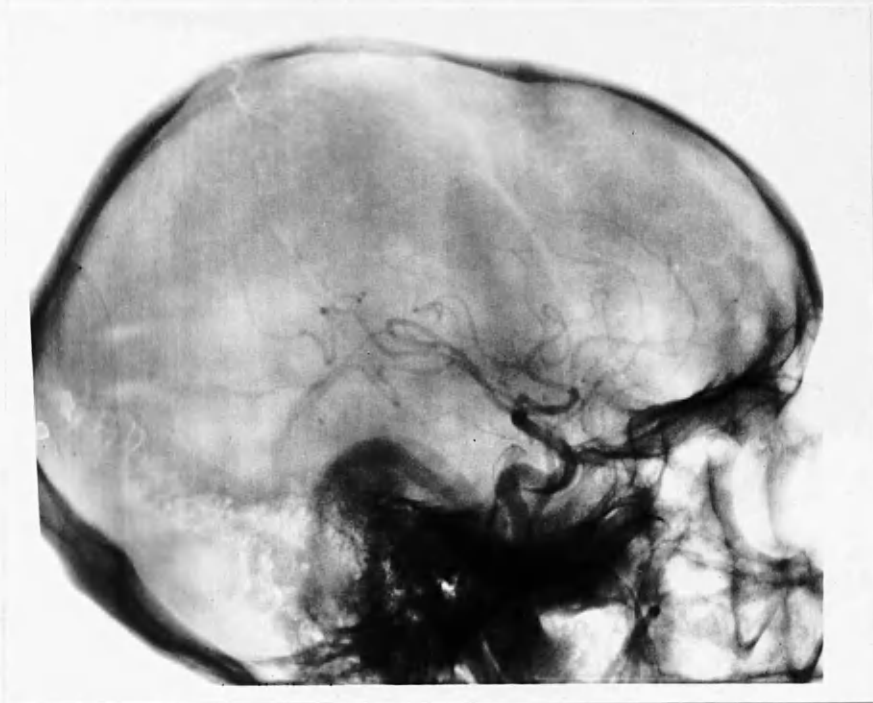


Fig. 10a Case 10
A vein is just appearing in the left posterior temporal region.

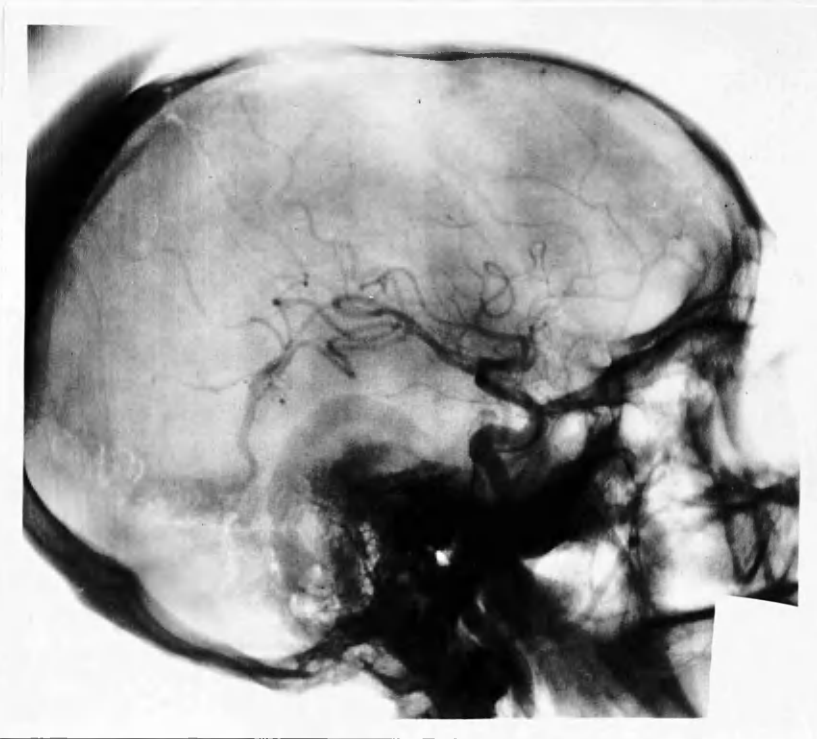

Fig. 10b Case 10
Repeat of above. Exposure made slightly later and a small
tangle of vessels due to the malformation is clearly shown.

suggest the presence of an arteriovenous malformation and may be an indication for repeating the injection. The importance of timing is demonstrated by the lesion shown in figs. 10a and b. A small arteriovenous malformation was outlined only in the second arteriogram which was exposed a fraction of a second later than the first.

The clinical localisation of the lesion will frequently determine which arteries should be injected, but usually it is advisable to carry out carotid angiography on both sides. Separate injections may also be indicated into an external carotid or vertebral artery, when a lesion is wholly or partly within their distribution. Mckissock (1950) recommended carotid and vertebral injections for temporo-parietal lesions. Hauge (1951) went so far as to consider that every arteriovenous malformation should be subjected to bilateral carotid and vertebral angiography. He has encountered a lesion situated in the frontal lobe which received some of its blood supply through the vertebral arteries by way of anastomosis through the pericallosal artery. A good example of a temporoparietal lesion demonstrated by left carotid and vertebral angiography is shown in figs. 11a and b. This lesion also showed partial filling when the right carotid artery was injected.

A lesion may only be demonstrated by vertebral

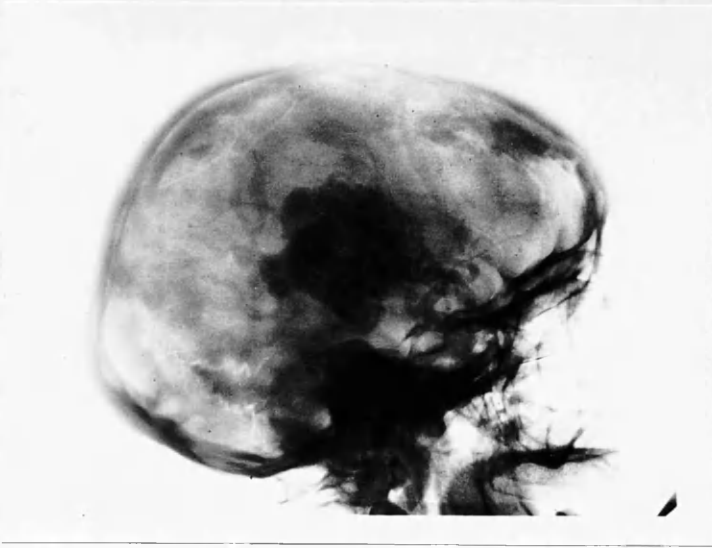

Fig. 11a Case 5
Large left temporo-parietal arteriovenous lesion demonstrated by left carotid angiography. Absent filling of the anterior cerebral artery, both filled on injection of the Rt. carotid.

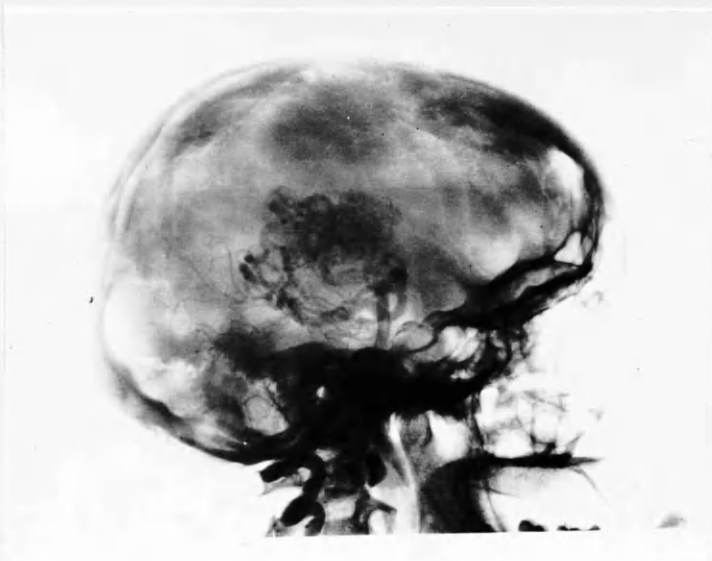

Fig. 11b Case 5
Vertebral angiography showing hypertrophied basilar and posterior cerebral arteries.

angiography, but when the feeding artery is the posterior cerebral there is usually sufficient communication through the posterior communicating artery to ensure filling by carotid injection. This was the experience of Olivecrona and Riives (1948). Case 16 (figs. 17a and b) illustrates this point and shows how a small arteriovenous malformation in the occipital region was outlined by carotid angiography. That it does not occur in every case is evidenced by the report of Radner (1951), who reported a small lesion supplied by the occipital branch of the posterior cerebral artery, which was not shown by carotid angiography.

The various anatomical and technical factors which influence the filling of the anterior cerebral arteries has been discussed in detail by Egaz Moniz (1940) and Ruggiero (1952). Ruggiero found a variation in filling of this artery in 20 per cent. of 231 normal cases studied and his figures are probably more reliable than those of Egaz Moniz as he used both antero-posterior and lateral views. In the presence of an arteriovenous malformation, variation in filling of the anterior cerebral arteries can be accounted for in most cases, by a relative difference in the intravascular pressures between the two hemispheres (Egaz Moniz 1940, Engeset 1946, Raney, Raney and Sanchez Perez 1949, Sugar 1951, Torkildsen and Koppang 1951,

Ruggiero 1952). Of the present cases, 19 (60 per cent.) showed some abnormality of filling of the anterior cerebral artery, 10 (30 per cent.) were normal and in three cases inadequate information was available due to faulty timing of the exposures. The appearances may be correlated with the position of the lesion and the size of the shunt. A large lesion will as a rule shunt most of the blood of the ipsilateral carotid artery through it. For example a lesion situated in the distribution of the middle cerebral artery will frequently shunt so much blood that non-filling of the anterior cerebral artery of the same side will fail to occur. Contralateral injection should however show it by a compensatory shunt through the anterior communicating artery. Thus bilateral carotid angiography is important, since feeding arteries from the anterior cerebral artery may not otherwise be demonstrated. A lesion near the mid-line will receive its blood supply from one or both anterior cerebral arteries, and the usual sequence of events will be, filling of the anterior cerebral on the side of the lesion and filling of both anterior cerebrals from the opposite side. There may also be branches from the middle cerebral artery of the same side. Unusual appearances may be accounted for by anatomical and technical variations.

The importance of taking both antero-posterior and lateral views must be stressed. If only a lateral view

be taken contralateral filling may lead to localisation in the wrong hemisphere. This happened in Case 10 of the series of Olivecrona and Riives (1948), when the clinical signs failed to indicate the side of the lesion. In addition to false localisation, bilateral lesions may be suspected where only one is present, if reliance is placed on lateral views alone. Case 11, one of the early cases of the present series, exemplifies how a mistake of this sort can occur. A large left parietal lesion was demonstrated by left carotid angiography; subsequent examination of the right side showed that the lesion was well-filled from this side also, but only a lateral view was taken and the appearances were interpreted as indicating a second lesion. No mistake would have been possible if the right antero-posterior view had been included. The correct diagnosis might have been suspected, had the right lateral been exposed at the correct time to demonstrate anterior cerebral filling, when both anterior cerebral arteries would almost certainly have been seen. Fig. 12b however shows that the exposure was made too late.

A further difficulty may arise, though not one met with in the present series, as a result of the different degrees of filling of a lesion from the two sides. Usually the contribution from the contralateral side is less but it may be nearly equal as in Case 22 (figs. 25a and b).

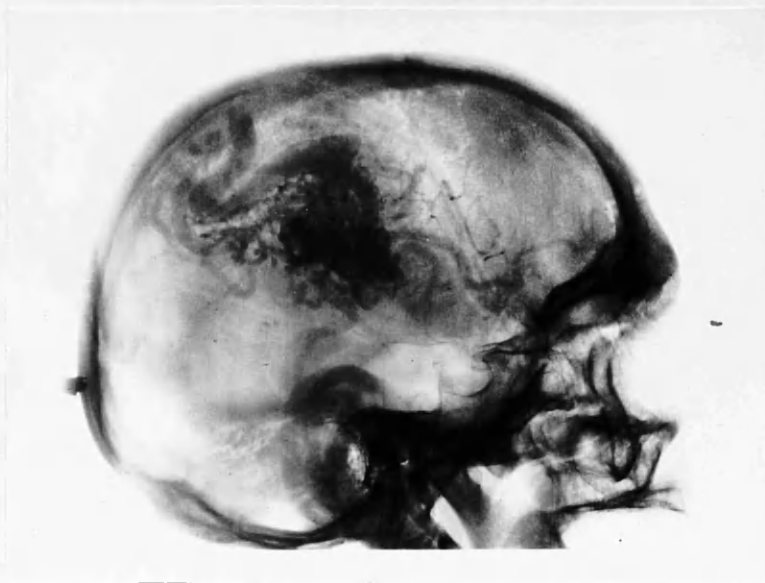

Fig. 12a Case 11
Large left parietal arteriovenous malformation with a vein passing to the sagittal sinus. Absent filling of the anterior cerebral artery.

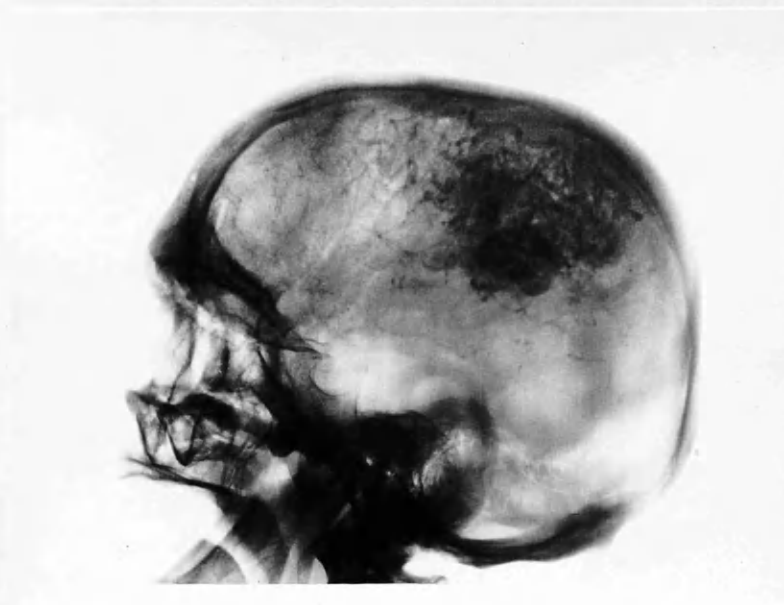

Fig. 12b Case 11
Rt. carotid angiography. The exposure is too late to show the feeding arteries.

Different parts of the lesion are filled by the separate afferent vessels, thus when only lateral views are taken lack of coincidence of the lesions may be erroneously interpreted as indicating bilateral lesions. Case 12 (figs. 13a and b) illustrates this point and shows that the segment of the lesion which filled through the left anterior cerebral artery is antero-superior in position to the main body of the malformation which filled from the right middle cerebral artery.

After successful surgical extirpation of a lesion the intravascular pressures between the two hemispheres will return to normal and normal filling of the anterior cerebral artery should be restored (Case 23, fig. 23b).

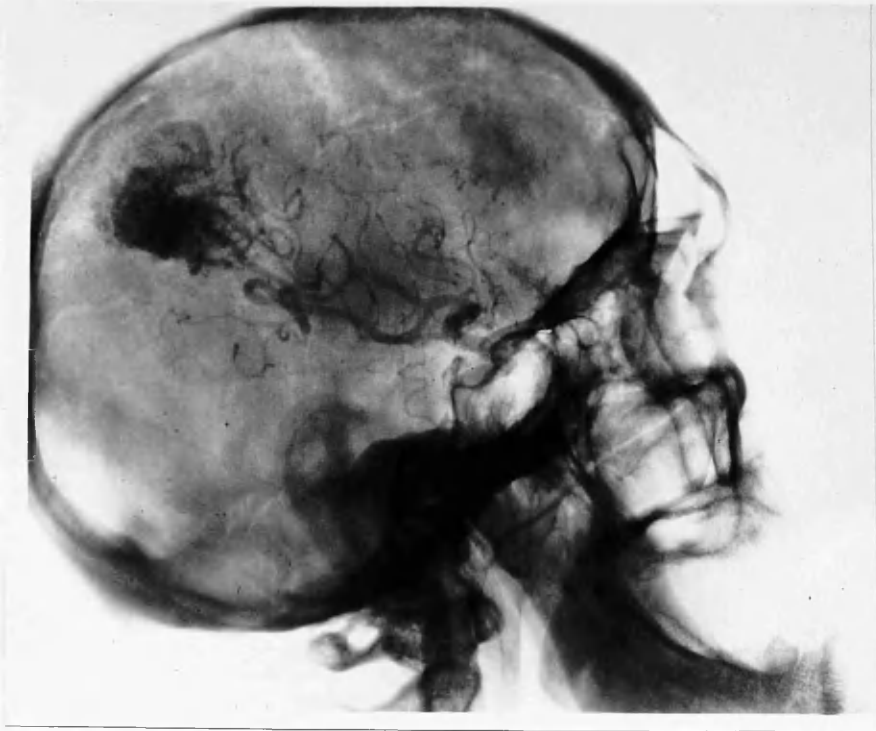

Fig. 13a Case 12
Left parietal arteriovenous malformation filling through
two enlarged branches of the middle cerebral artery.

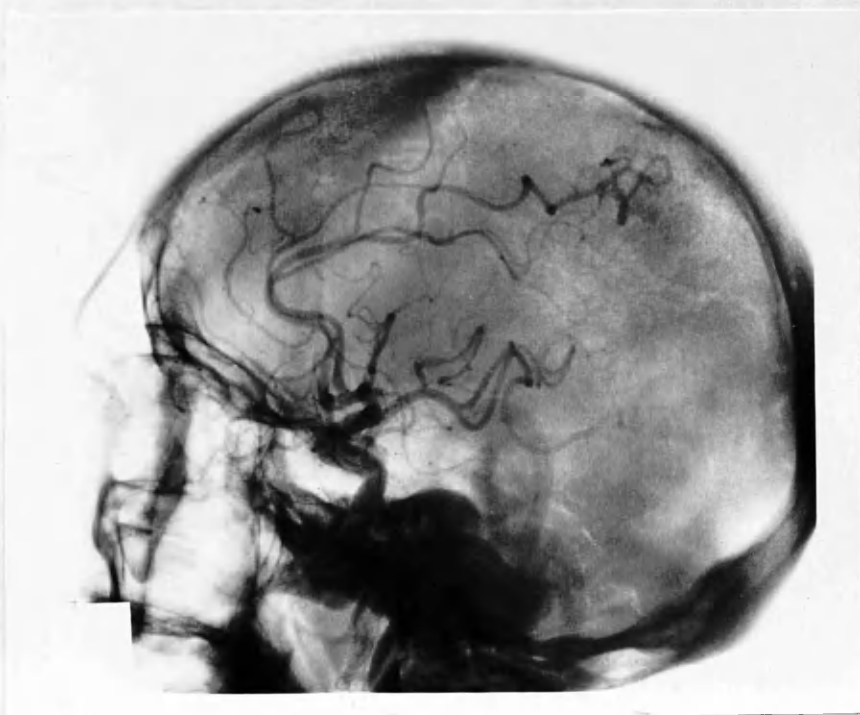


Fig. 13b Case 12
Rt. carotid angiography. Some filling has taken place through
the left anterior cerebral artery. The part of the lesion
filled does not coincide precisely with (a) above.

The Radiographic Appearances of the
Arteriovenous Malformations

The arteriovenous malformations show considerable individual variation in the angiograms, depending on their size, position and vascular connections, and the appearances are further modified by the size of the shunt and the circulatory phase in which the radiograph is exposed. They may be found anywhere within the brain or its coverings, though there is a predilection for certain areas and particular vessel groups. Some lesions appear as closely-knit tangles of vessels, others as small and large vascular spaces, or they may cast almost homogeneous shadows due to dilatation of the vessels, which in some cases reach aneurysmal dimensions.

Size

All gradations in size may be seen between the largest lesions which measure up to 10 cms. or more in diameter (Falconer 1952), and the smallest which may be no more than a few millimetres. In most of the published cases the lesion has been of considerable size. Only three of the 43 cases investigated by Olivecrona and Riives (1948) were classified as small.

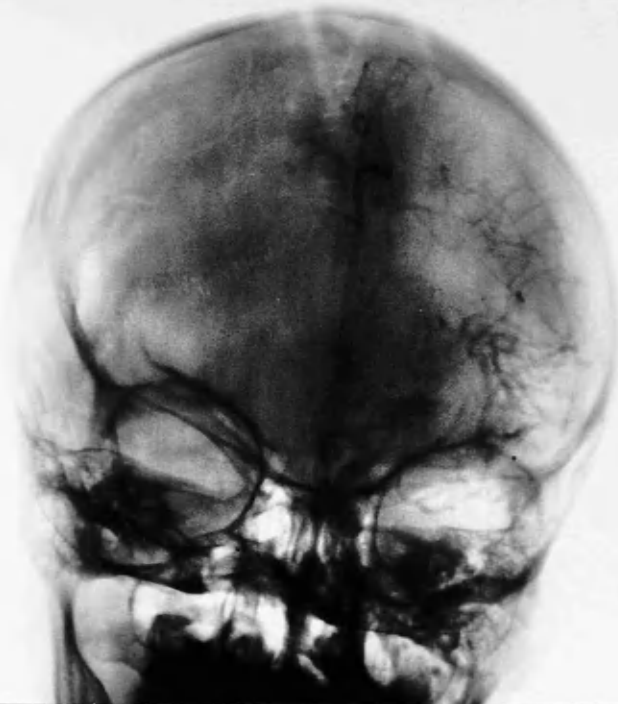

Fig. 14a Case 13

A small contrast filled area can be seen immediately above the first part of the middle cerebral artery. At autopsy a small arteriovenous malformation was found anteriorly in the left frontal lobe. There is no obvious feeding artery.

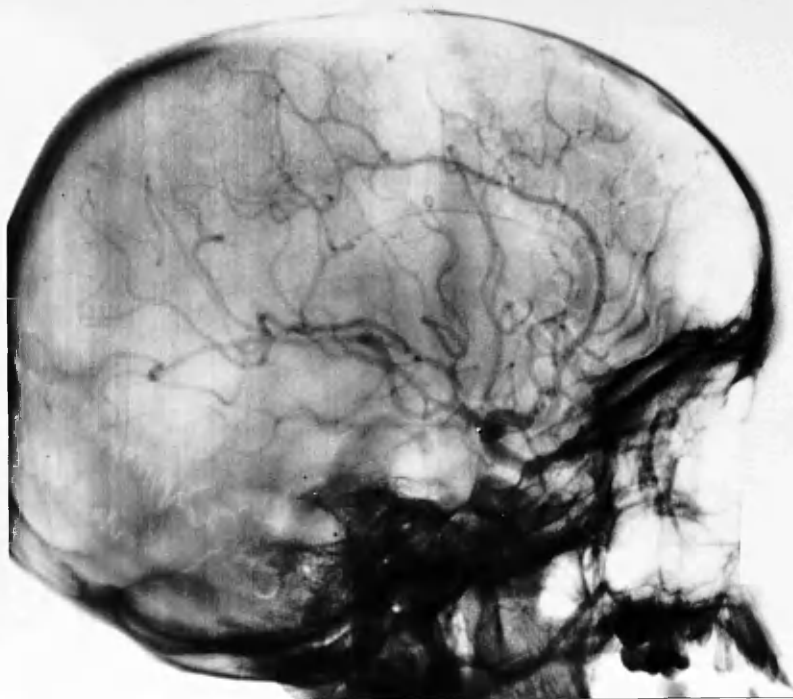


Fig. 14b Case 13

The small arteriovenous malformation cannot be seen in this view.

The present series comprise 10 small lesions, the diameter of which, measured on the film, was one centimetre or less; 17 large, unspecified as to size except that they occupied a considerable portion of a lobe or lobes, and 5 of intermediate size which could not be classified as either large or small. Mackenzie (1953) has adopted a similar method of classification and of his 50 cases he described 23 as large, 18 as moderate and 7 as small.

The majority of the small lesions appeared similar to the large ones but in miniature, their vascular nature being obvious. In two of the present cases, however, the individual vessels of the lesions were of such minute calibre that they were difficult to identify in the angiograms, and they appeared simply as small areas of increased density due to localised accumulation of contrast medium (figs. 14a and 15a). It was of considerable interest that the lesions of these two cases were only demonstrated in the antero-posterior arteriograms. Case 13 died following an intracerebral haemorrhage and at autopsy a small arteriovenous malformation was found deeply placed in the right frontal lobe. The angiographic diagnosis in Case 14 has not been confirmed but the case is included in the series because of the close resemblance of its lesion to that of Case 13.

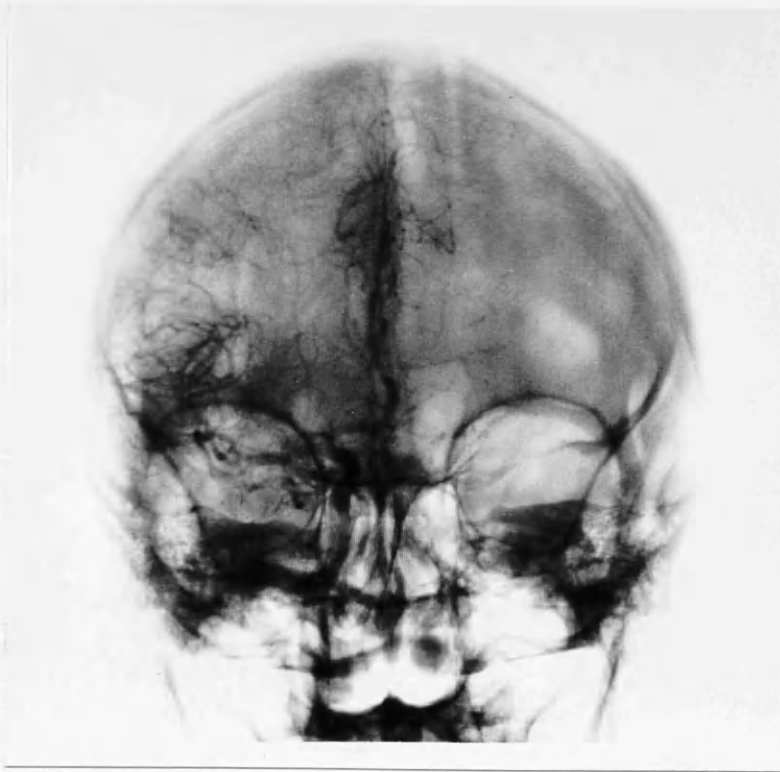

Fig. 15a Case 14

A circumscribed area immediately above the first part of the middle cerebral artery is contrast filled. The appearances are similar to those of fig. 14a.

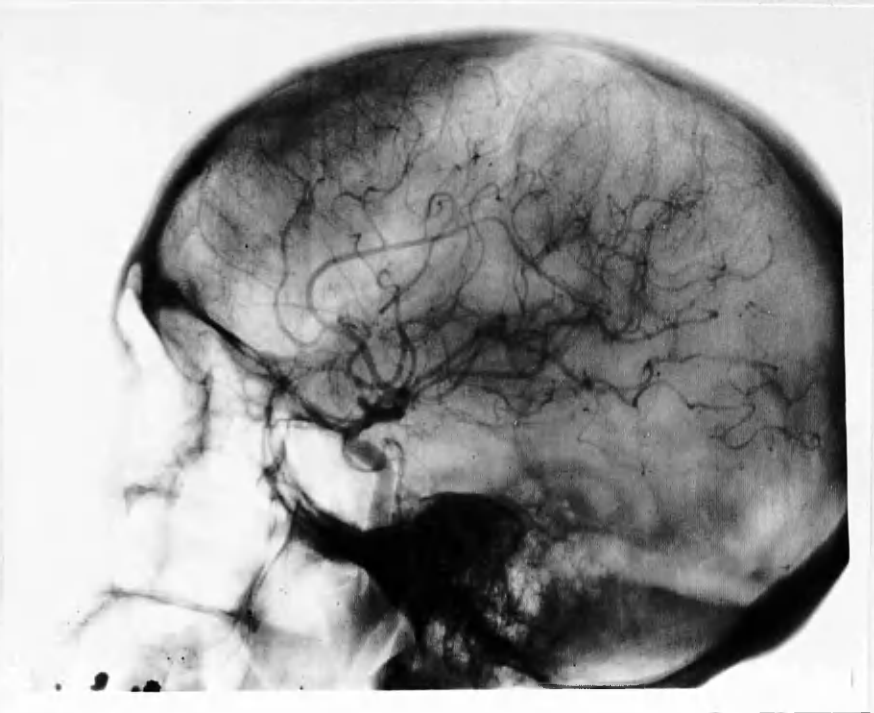

Fig. 15b Case 14

Lateral view of (a) above. No definite lesion can be seen in this view.

Shape

The shape of the cerebral arteriovenous malformations is to some extent determined by their size and position. The large lesions are frequently wedge or cone-shaped when viewed antero-posteriorly (see figs. 9b and 23b) and this appearance has been noted by most authors. The small lesions have no characteristic shape. Two lesions which were embedded in the corpus callosum (Case 1 and 15) appeared as oval enongated masses (fig. 16a).

Position

In 65 per cent. of the cases reported by Olivecrona and Riives (1948) the lesion was solely in the distribution of the middle cerebral artery. The anterior cerebral artery was a feeding vessel in addition to the middle cerebral in 7 per cent. and in 16 per cent. it was the only feeding vessel. The external carotid artery contributed to the blood-supply of an intracerebral lesion in 12 per cent. of their cases. Of the present series of cases the lesion was in the middle cerebral group in 47 per cent. (15 cases) and additional feeding vessels came from the anterior cerebral in a further 28 per cent. (9 cases).

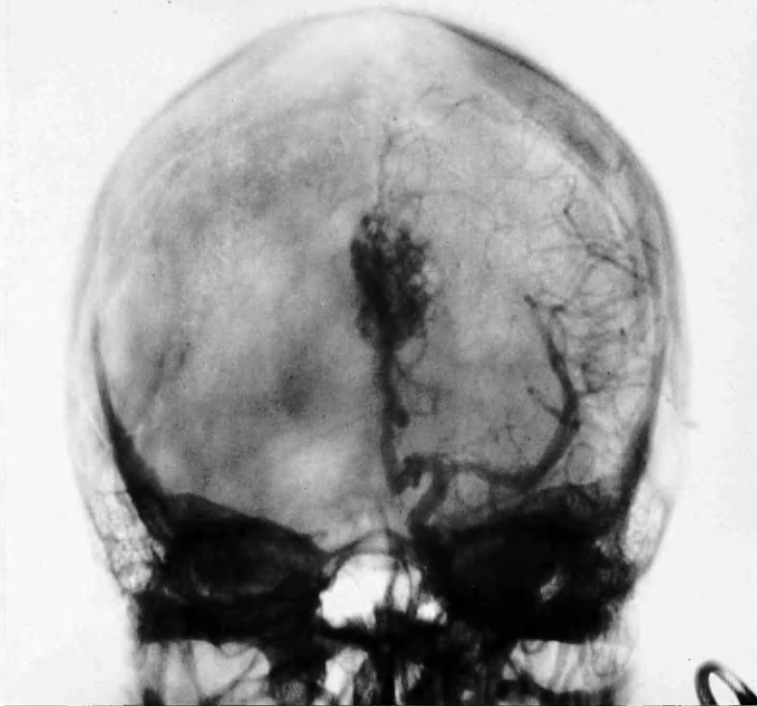

Fig. 16a Case 15
Left common carotid injection. The oval shape of the midline arteriovenous malformation which was embedded in the corpus callosum is shown.

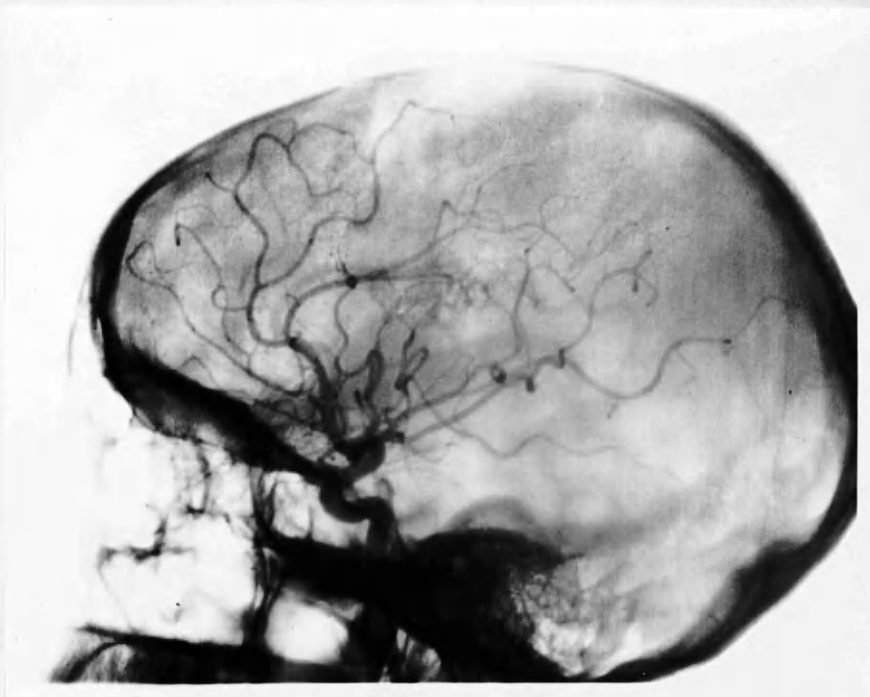

Fig. 16b Case 15
Rt. common carotid injection. The dilated left anterior cerebral artery can be seen as a ghost shadow immediately above the right, some contrast filling of the malformation is present.

Thus in approximately 75 per cent. of all cases the middle cerebral artery is the principal feeding vessel. Of the remaining lesions 16 per cent (5 cases) were supplied by the anterior cerebral artery and in one case the posterior cerebral artery was the feeding vessel.

Lobar distribution is variable. The parietal lobe was the commonest site (13 cases), next came the frontal lobe (6 cases) and the temporal and occipital lobes (3 cases each). Seven cases were in the line of the lateral fissure and so related to more than one lobe. No lesion occurred in the mid-brain, the cerebellum, or exclusively in the distribution of the external carotid artery. As would be expected from the blood supply most lesions were situated laterally in the hemispheres, but seven cases adjoined the mid-line (Cases 1, 2, 8, 15, 17, 19, 26). Ray (1950) suggested that the large lesions were found in relation to the proximal parts of the major arterial trunks, and the smaller ones to the distal branches. This was not borne out in the present series.

The Arteries

The feeding arteries may be single, or multiple, and come from the same or different vascular groups.

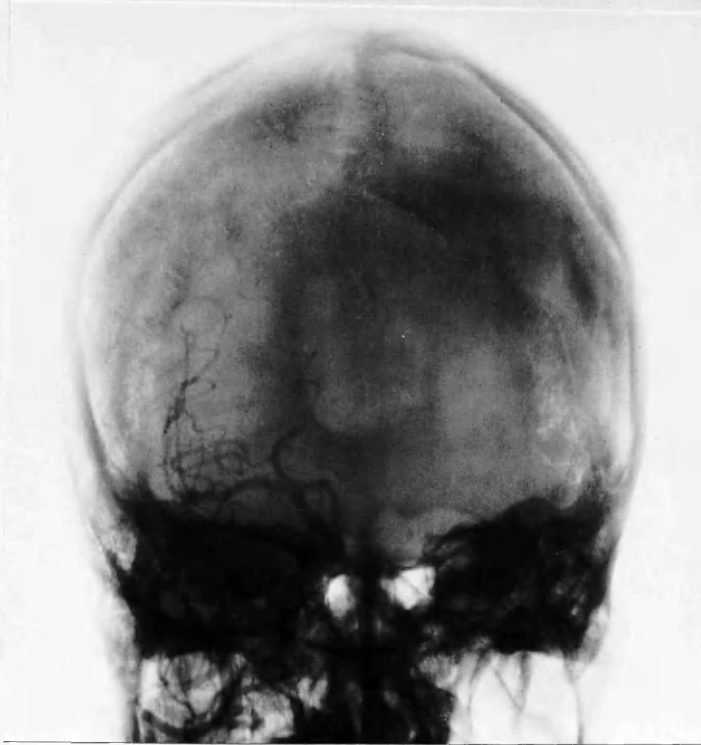

Fig. 17a Case 16
A branch of the Rt. posterior cerebral artery can be followed to a small occipital malformation. The artery tapers normally as it is traced peripherally.

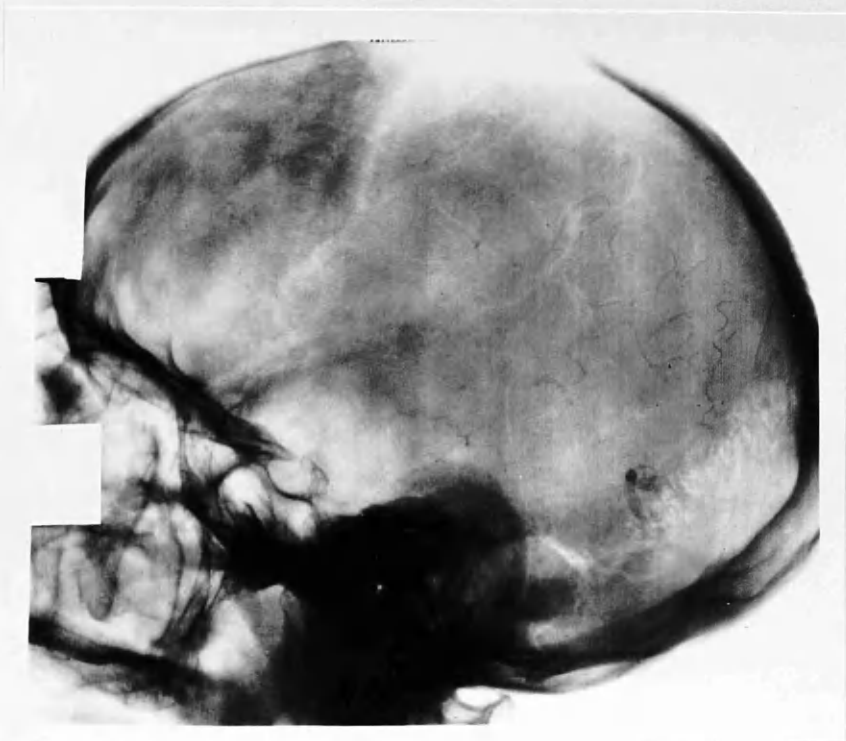


Fig. 17b Case 16
Lateral view. Late arterial and capillary phase showing the small malformation.

Most lesions occur within the distribution of the internal carotid artery, but some also receive branches from the external carotid and vertebral arteries. In three cases reported by Olivecrona and Riives (1948) the main blood supply came from the external carotid artery, although the lesions were actually within the brain. Large lesions usually have several afferent vessels, although Lima (1950) found a single vessel to be quite common.

Dilatation of the afferent vessels is present, to a degree dependant on the size of the arteriovenous shunt, and the lumen is approximately the same width from the beginning to the end of the dilatation (Bunner 1949). In the case of very small lesions, as for example Case 16 (fig. 17a), the artery may taper normally as it is traced peripherally. Tortuosity of the artery is usual, and it may pursue an unusual course or branch abnormally (Case 17 fig. 18a). The appearance of single or multiple arteries whose course can be followed until they enter a more or less discrete arteriovenous malformation is not an invariable finding. Sometimes great tortuosity and ramification of the afferent vessels is present, as in Case 18 (figs. 19a and b). In this case, multiple branches from the middle cerebral artery could be traced peripherally to the parieto-occipital region, where they turned deeply to enter the arteriovenous lesion proper.

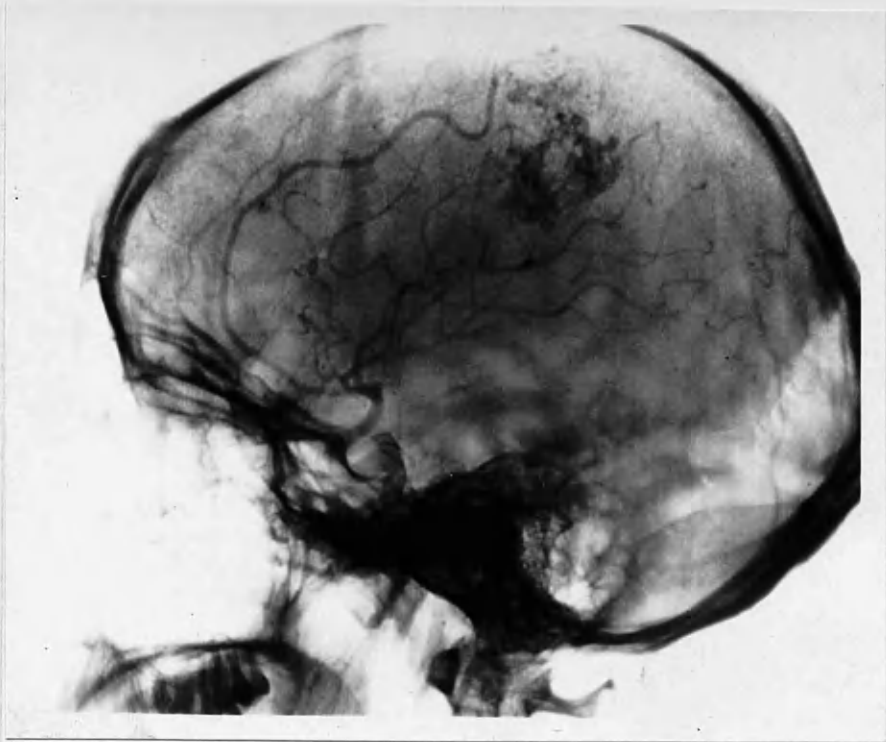

Fig. 18a Case 17
Left parietal arteriovenous malformation. The unusual course of the feeding artery which is the main trunk of the anterior cerebral artery is shown.

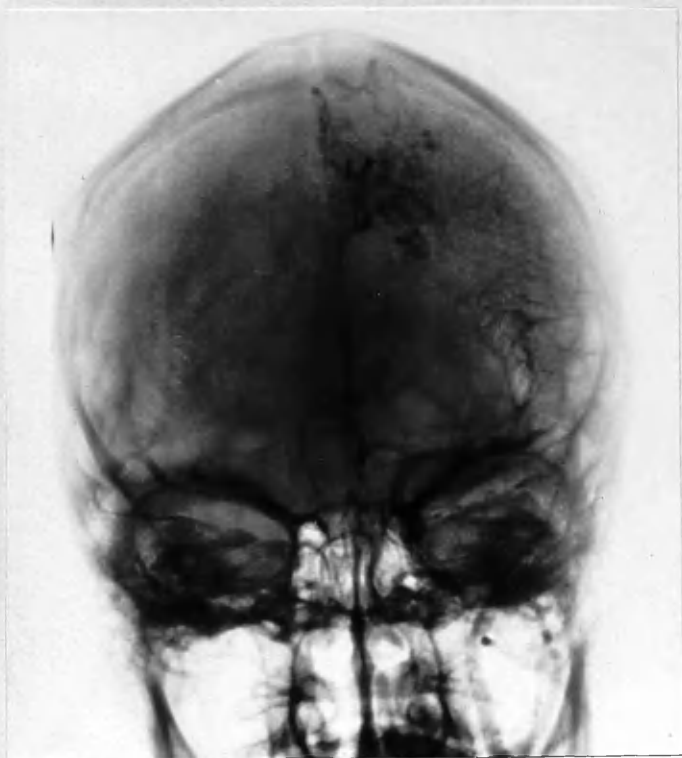

Fig. 18b Case 17
Anteroposterior view of (a) above.

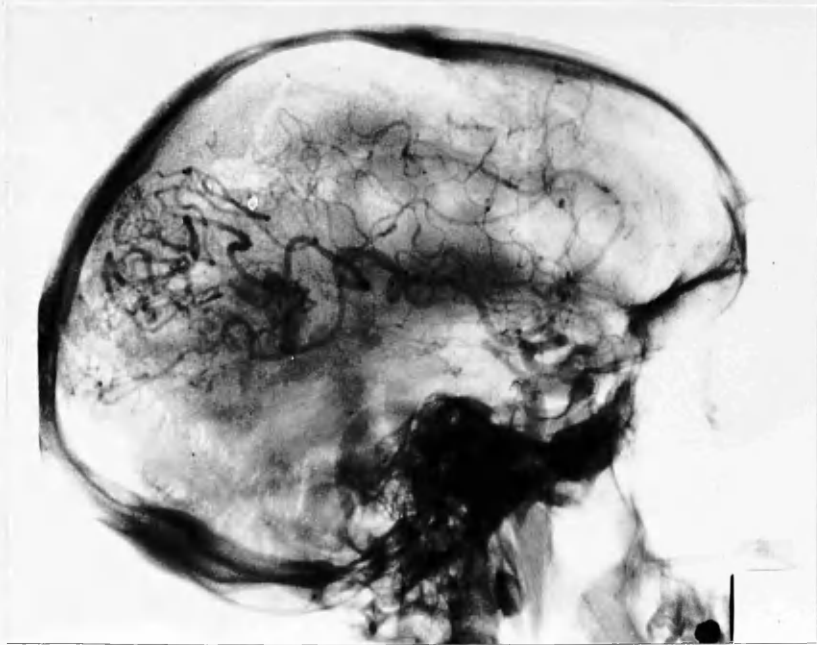


Fig. 19a Case 18
Left parieto-occipital arteriovenous malformation.
The extraordinary tortuosity and ramification of
the feeding arteries is shown.

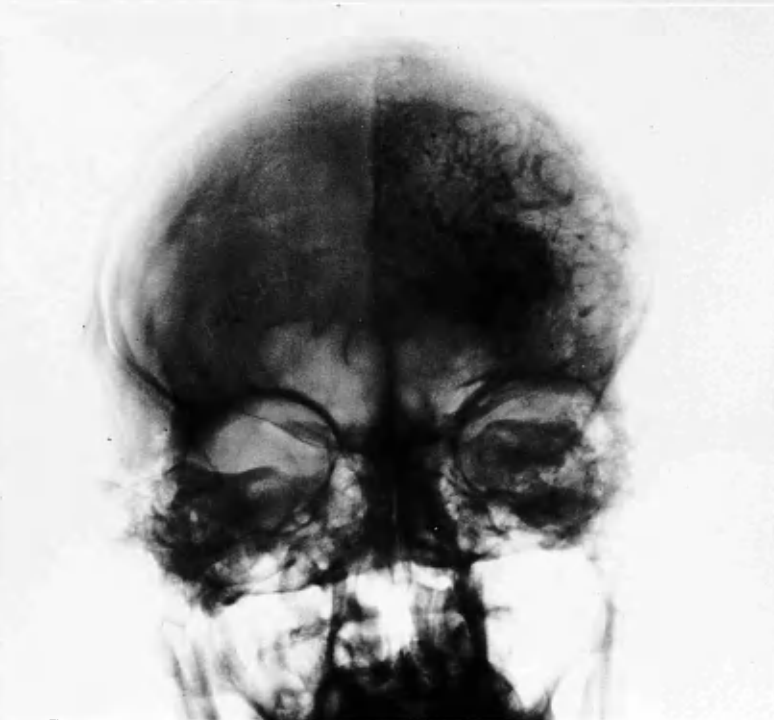

Fig. 19b Case 18
A.P. view. The arteriovenous part of the lesion
appears as a quite well-circumscribed opacity deeply
placed in the occipital region.

It is easy to imagine how a lesion of this type, at least on superficial inspection would suggest the possibility of a true arterial form of malformation. The arteries of the cerebral hemisphere not directly connected with the lesion, are poorly filled to a degree dependant on the size of the arteriovenous shunt.

The Veins

The lack of a capillary barrier results in an unusually high local venous tension and dilatation and sinuosity of the veins occur, the degree of engorgement depending on the extent of the arterial supply, and on the size of the lumina of the mass of vessels forming the arteriovenous communication. Dandy (1928) considered, that a large lesion with many vessels took some of the brunt of the arterial force off the venous channels of exit, whereas a small lesion transmitted all the arterial force to the veins indicated a small lesion, and vice versa. Arteriograms are shown in figs. 20a and b, in which the internal carotid artery, the arteriovenous malformation, a dilated and tortuous vein and the superior sagittal sinus are outlined in continuity during a half-second exposure. Such an appearance must surely indicate very wide arteriovenous communications.

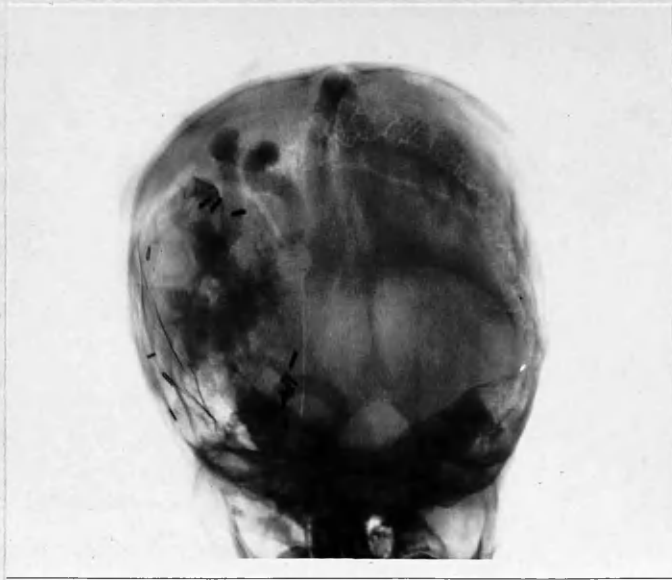

Fig. 20a Case 7
A.P. view. Arteriovenous malformation, in the Rt. lateral fissure, the internal carotid artery, the malformation, a dilated and tortuous vein and the superior longitudinal sinus are all outlined with the contrast medium.

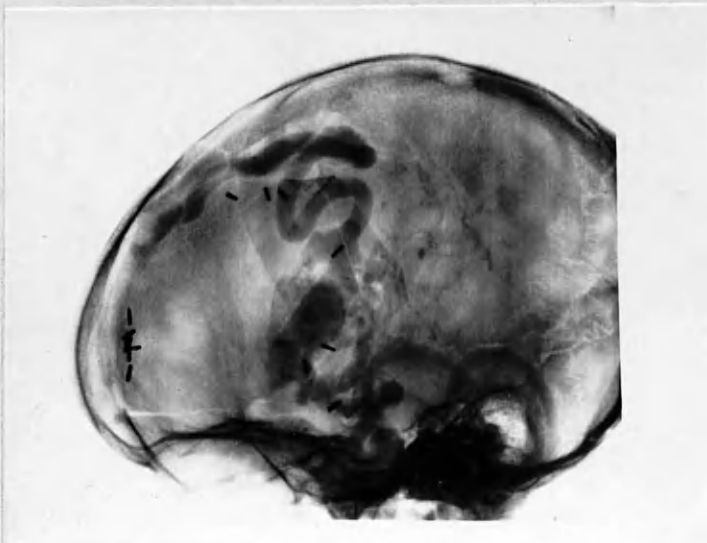


Fig. 20b Case 7
Lateral view of (a) above.

Congenital abnormality of the veins may be present and Dandy (1928b) observed a case in which the Rolandic vein arose directly out of the brain substance. In seven of the present cases some abnormality of the veins in respect of their course and connections was observed at operation (Cases 7, 9, 15, 23, 26, 27, 32). The grossly abnormal course followed by a drainage vein, which crossed the mid-line of the skull to descend to the region of the opposite jugular foramen is illustrated in figs. 21a and b. This appearance can only be interpreted as a developmental anomaly and it is probable that the vein represents a persistent portion of the primary head vein, the cephalic part of which in foetal life forms the cavernous sinus, the caudal portion joining with the part of the anterior cardinal vein which later becomes the internal jugular vein. Abnormal persistence of veins is probably a compensatory mechanism to deal with the abnormally large quantity of blood that is uncontrolled, because of the absence of the normal capillary bed (Yates and Paine 1930).

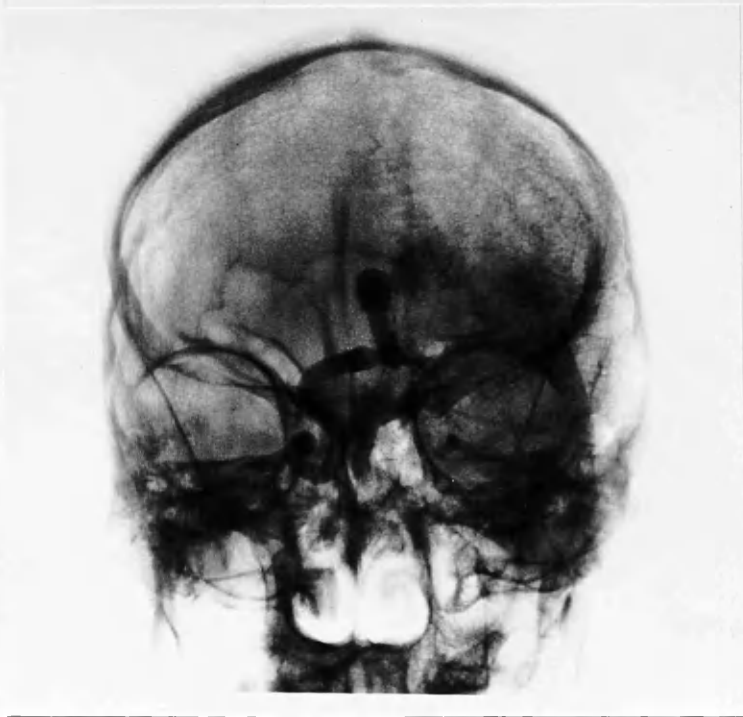

Fig. 21a Case 19

A small arteriovenous malformation is medially placed in the left fronto-parietal region. The course of the drainage vein which crosses the midline and descends to the region of the jugular foramen is shown.

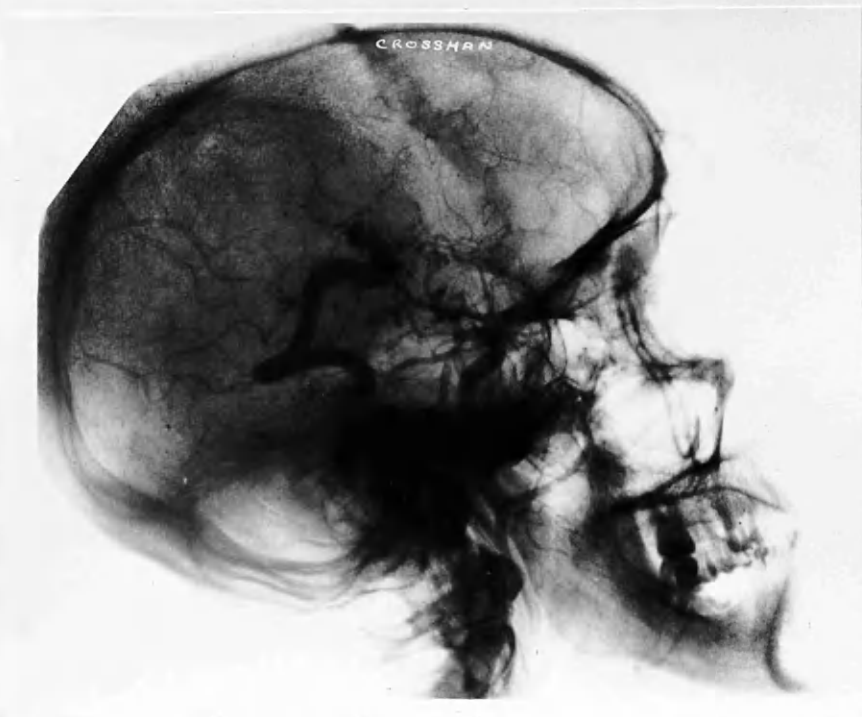


Fig. 21b Case 19

The course of the vein is shown in the lateral view. The small malformation is partially obscured by the vein.

Increase in Size of the Lesion

Increase in size of a lesion has been considered probable, as it is not until the second or third decade of life that symptoms commonly appear. A true autonomous growth is unlikely and "arterialisation" of a lesion originally venous has been suggested as a possible explanation (Cushing and Bailey 1928, Wolf and Brock 1935). Lima (1950) strongly contested this view and maintained that the arteriovenous communications were congenital in origin. Extensive thrombosis has been regarded as one of the reasons for progression of the lesion, each thrombosed vessel throwing an additional strain on the venous system and on the angiomatous mass (Dandy 1928a), but Olivecrona and Riives (1948) have never observed fresh thrombus formation at operation. Trauma is a possible factor in the opening up of new arteriovenous channels and so leading to increase in size of the lesion. Stewart and Ashby (1931) observed the appearance of veins on the forehead of a girl of 11 following injury to the head and Case 23 of the present series was symptom free until trauma led to intracerebral and subarachnoid bleeding. An exacerbation of symptoms followed the development of hypertension in one case (Case 11) and during menstruation

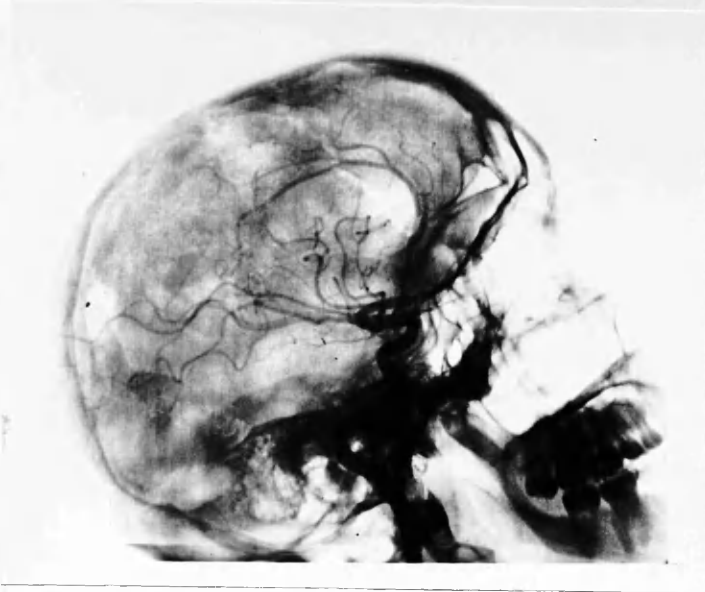


Fig. 22a Case 1
Midline Rt. parietal arteriovenous malformation in 1946.
Left carotid arteriogram.
The lesion is only just beginning to fill.

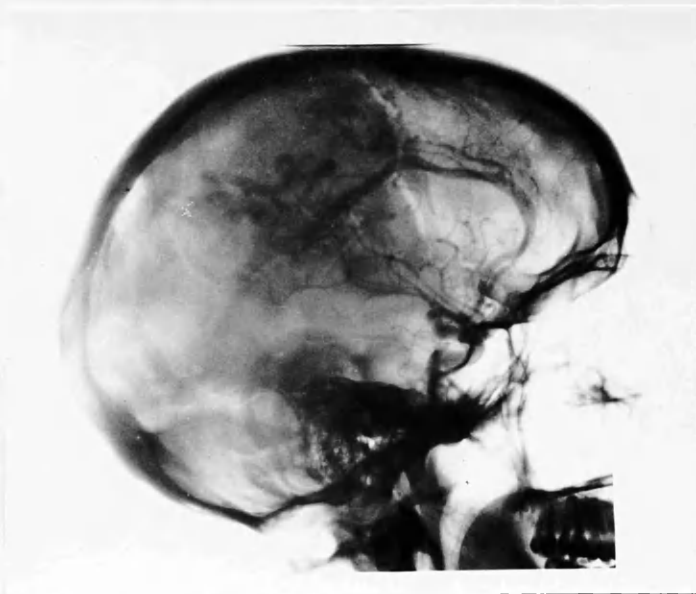


Fig. 22b Case 1
The same case in 1949.
The now much dilated anterior cerebral artery is shown.

in two cases (Cases 9 and 14). But if clinical evidence has so far favoured a probable increase in size of the lesion, angiographic proof has not so far been convincing. In Case 13 of the series of Olivecrona and Riives (1948), the calibre of the arteries was said to have increased over a period of ten years. Wickbom (1950) stated that he was following up a few small arteriovenous malformations, which had not been operated on, in an attempt to decide whether or not increase in size occurred, but so far he has not published his conclusions.

One of the present cases, which was examined by arteriography on two occasions, provides convincing evidence of a true increase in size of the feeding arteries of a lesion. The second examination, carried out three years after the first, clearly showed that the calibre of the anterior cerebral artery had increased during this period (figs. 22a and b). It was remarkable in this case that both the anterior cerebral arteries were filled during left carotid angiography and neither from the right side despite the fact that the lesion was situated to the right of the mid-line. The probable explanation of this finding is that both the anterior cerebral arteries arose from the left carotid artery and

this unilateral origin has been observed in 3.4 per cent. of the cases examined by Ruggiero (1952).

Another way by which an arteriovenous malformation can increase in size, is by the formation of an aneurysmal dilatation (Mckissock 1950, Wickbom 1950, Gillingham 1952). This appearance is illustrated in fig. 23a (Case 20).

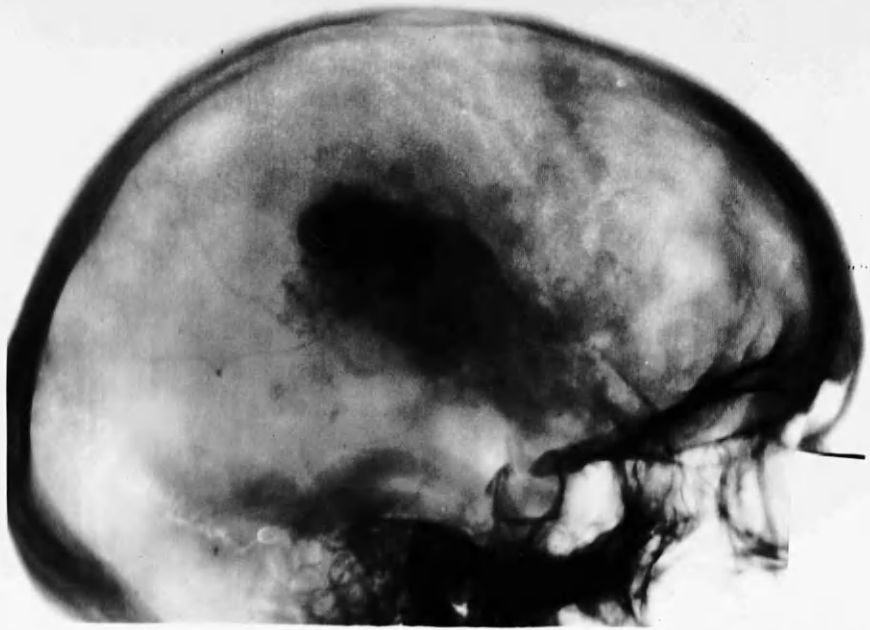


Fig. 23a Case 20
Left fronto-parietal arteriovenous malformation. An aneurysmal dilatation is present and the posterior part of the sac is partially outlined with calcium deposits.

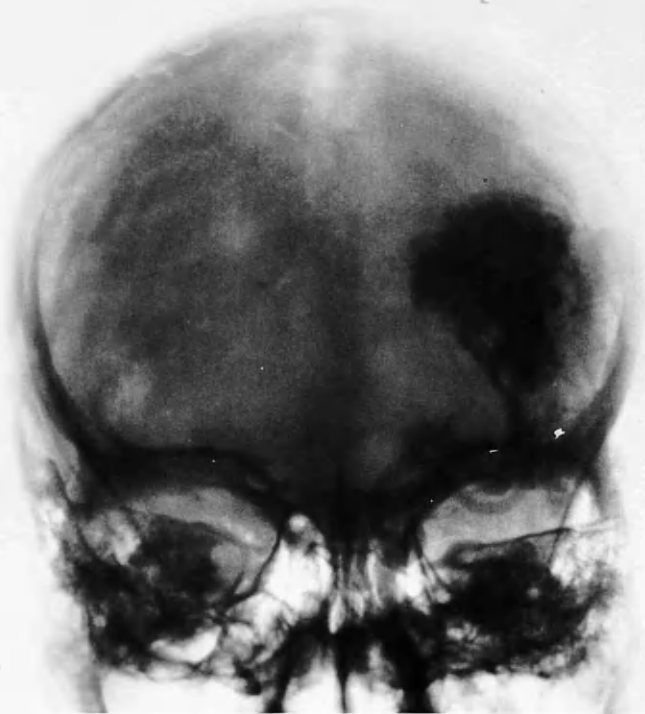

Fig. 23b Case 20
The typical wedge-shape of the lesion is shown in the frontal projection.

The Angiographic Appearances of the Arteriovenous
Malformations in relation to the Clinical Findings

Epilepsy

Epilepsy is one of the commonest symptoms of the intracranial arteriovenous malformations, and is usually Jacksonian or sensory in type. It was the presenting feature, in approximately 50 per cent. - and present eventually in 70 per cent. - of the cases reported by Olivecrona and Riives (1948) and in 32 per cent. of Mackenzie's (1953) cases. Mackenzie commented on the focal onset of the attacks in all but one of his cases. Of the present cases, 8 (25 per cent.) presented with epilepsy and a further six were subsequently affected (a total of 44 per cent.). The high incidence of focal epilepsy is hardly surprising in view of the common involvement of the middle cerebral and the predominant situation of the lesion in relation to the pre- and post-central areas of the cerebral cortex. Mackenzie observed that in all his cases presenting with epilepsy, the lesions were fronto-parietal, except, one which was fronto-temporal and another temporal in position, the latter giving rise to "temporal lobe attacks".

Of the 8 cases (25 per cent.) of the author's series which presented with epilepsy, there were 6 with

large fronto-parietal lesions and two with small lesions, one frontal (Case 14) and the other occipital in position (Case 16); the latter also suffered from attacks of petit mal. The six cases who later developed epilepsy had all previously had intracerebral bleeding. In only one of them (Case 7) was the lesion in a position usually associated with epilepsy as a presenting symptom. Mackenzie (1953) has also commented on this association of haemorrhage and epilepsy in four of his cases and he was of the opinion, that the bleeding was a significant factor in the production of the attacks.

Headache

Headache, in the presence of an intracranial arteriovenous malformation, may be due to haemorrhage, a convulsion or raised intracranial pressure, but it may also be the principle symptom and the presenting feature of the condition. Of the present cases, it was the initial symptom in 14 (44 per cent.). The headaches were migrainous in type in 6 cases, 3 in the occipital lobe and 3 in close relation to it. Eleven (of 17) large lesions gave rise to headaches, but only 3 (of 10) small and they were occipital in position, the headaches being migrainous in type. This association of headaches with the large lesions would support the contention of Olivecrona and

Riives (1948) that anoxaemia of the brain is responsible for this symptom, the shunting of blood away from the brain leading to dilatation of the cerebral vessels. Ray's (1941) view that the headaches were due to dilatation of the meningeal vessels may also be correct and headache was a feature in 4 cases showing obvious clinical or radiographic evidence of involvement of the external carotid artery. It is of interest to note, that a bruit was heard on auscultation of the skull in 7 of 11 large lesions in which headache was a symptom. This is in agreement with Mackenzie (1953) who recorded a bruit in 8 of 12 of his cases suffering from headache.

Haemorrhage

Spontaneous intracranial haemorrhage is a common complication of the arteriovenous malformations. The bleeding may be intracerebral, subarachnoid, or both and as a cause of subarachnoid haemorrhage it accounts for 5-10 per cent. of all cases (Richardson and Hyland 1941). The onset of symptoms may be indistinguishable from rupture of an intracranial aneurysm but is usually less severe. Recurrent haemorrhage is a common occurrence (42 per cent. of the present cases which bled) and in the opinion of Wechsler and Gross (1948) is more likely to be associated with an arteriovenous malformation

than an aneurysm. As many as 11 attacks of subarachnoid haemorrhage have been recorded in a single case (Barlow 1943). Olivecrona and Riives (1948) observed subarachnoid haemorrhage in 20 per cent. of their cases and a further 20 per cent. had cerebral haemorrhage and hemiplegia. Mackenzie (1953) recorded haemorrhage in 30 per cent of his cases (12 with subarachnoid and 3 with intracerebral bleeding). The present series includes 19 cases (60 per cent.) in which there was evidence of subarachnoid, intracerebral haemorrhage or both. Of these 19 cases there were 7 with hemiplegia of sudden onset, in whom cerebral haemorrhage has been assumed to be the probable aetiological factor. No attempt is made to separate cases with intracerebral and subarachnoid haemorrhage as the two conditions were frequently associated.

It would be of considerable value in prognosis and treatment, if an arteriovenous malformation possessed any specific angiographic features from which its liability to haemorrhage could be forecast. With this aim in view, the angiograms of the present cases have been examined in relation to the size, position, and vascular connections of the lesions. It is realised that strict limitations must apply to an analysis of this type, since the period of observation may be short and no account is

taken of such factors as trauma, or alteration of the circulatory dynamics due to a raised blood pressure or to changes in the blood volume, which might be expected to influence the lesion.

Size

Study of the present cases has shown that a disproportionately large number of small lesions have bled. Olivecrona and Riives (1948) wrote, "At the time that the diagnosis is first made, most arteriovenous aneurysms have reached considerable dimensions..... Occasionally, small aneurysms are encountered. They are usually in cases in which early haemorrhage draws attention to the lesion". In only 3 of their 43 cases was the lesion classified as small. Mackenzie (1953) found 7 small lesions in his series of 50 cases and of these 6 revealed themselves by haemorrhage and the 7th bled four years later. Comparison of the present cases with those in the literature, in relation to the size of the lesion and the presence or absence of haemorrhage, has proved to be impracticable since in the recorded cases the size of the lesion has not always been stated, nor have the angiograms been reproduced in every case.

The incidence of haemorrhage in relation to the size of the lesion, as it affects the present series of

cases, is shown in the accompanying table. It can be seen that all the lesions of medium size, 70 per cent. of the small lesions and 41 per cent. of the large lesions bled.

Table II

Size	No. of cases	No bleeding	Bleeding present	Single bleed	Recurrent bleeding
Small	10	3	7	5	2
Medium	5	0	5	2	3
Large	17	10	7	4	3
TOTAL	32	13	19	11	8

Although at first it would seem reasonable to conclude that haemorrhage is more likely to occur with the small than with the large lesions, further consideration shows that this conclusion is not necessarily justifiable. Small lesions tend to cause few if any symptoms until they bleed, consequently the incidence of haemorrhage must inevitably be high. With large lesions, on the other hand, symptoms such as headache and epilepsy are common and many cases will be diagnosed as a result of investigation of these symptoms. The frequency of haemorrhage in this

latter group will therefore only appear to be lower.

The effects of haemorrhage will naturally be more severe, when a lesion is deeply placed in the brain and has no surface connections since bleeding will then be intracerebral and a large haematoma may form as in Case 21 (fig. 24a) and behave as a space-occupying lesion. The haemorrhage may however rupture through the brain substance into the subarachnoid space and in three of the present cases rupture into a lateral ventricle was found at operation (Cases 25, 26 and 27). These findings conflict with the experience of Turner (1946) who in reporting a single case with an intracerebral haematoma, stated that he was unable to find any other reported case of haematoma due to arteriovenous malformation. Bleeding from even a very small malformation may then be of a serious nature and of two deaths due to spontaneous haemorrhage one was from a lesion so small that its identification in the angiograms was difficult (Case 13) and the other from a small residual portion of a malformation, following incomplete excision (Case 32).

Large lesions usually present on the surface of the brain and minor degrees of bleeding may be associated with no more than a severe headache. Thus the patient may survive many attacks; the largest number occurring in

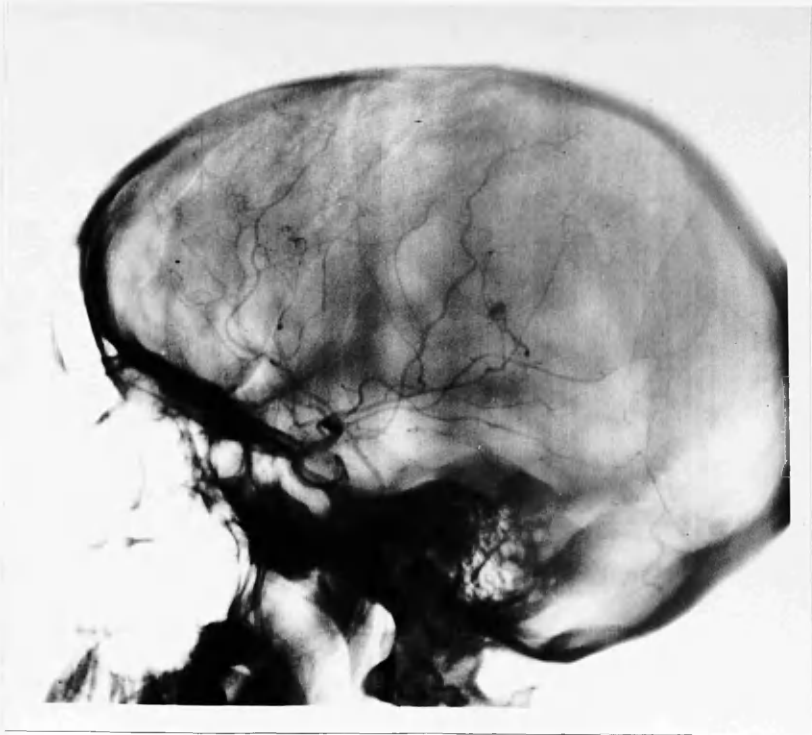

Fig. 24a Case 21
Small Rt. parietal arteriovenous malformation with large intracerebral haematoma. There is stretching of the vessels of the middle cerebral group.

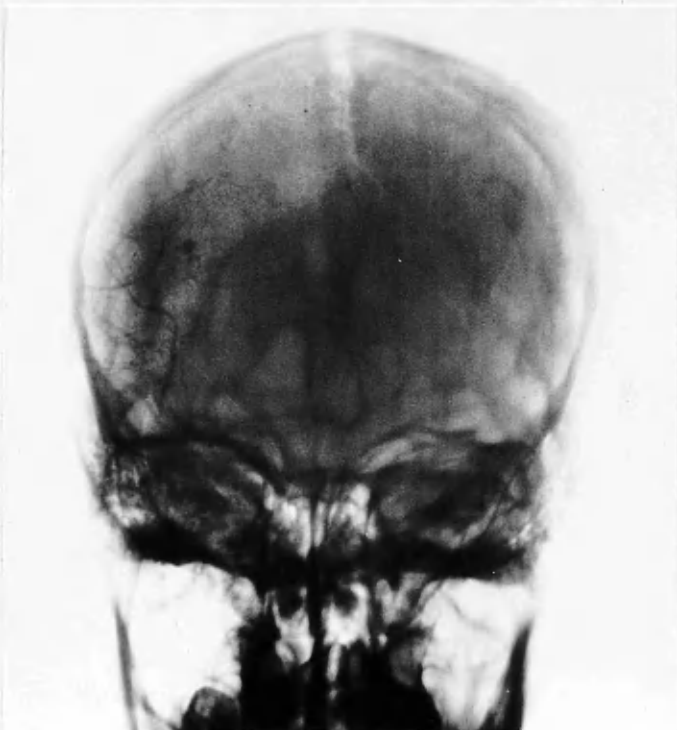

Fig. 24b Case 21
Anteroposterior view. The anterior cerebral artery is dislocated to the left.

any case of the present series was six (Case 5). Analysis of the author's cases would support the view that a comparatively benign course in respect of haemorrhage is usual with the largest lesions. Thus of the seven large lesions which bled:

(a) Bleeding followed severe trauma in one case (Case 23).

(b) In three cases which presented as hemiplegia (Cases 2, 9, and 12) no further bleeding occurred. The period which had elapsed from the onset of the initial symptom being 22, 15 and 29 years respectively.

(c) Three cases have suffered recurrent attacks of haemorrhage (Cases 1, 5 and 15).

Position

There is no reason to believe, that either the frequency or the liability of a lesion, to bleed is related to cerebral localisation. Haemorrhage occurred from all of the present cases situated near the mid-line (Cases 1, 2, 8, 15, and 19) and in three of these (Cases 1, 8, and 15) there were recurrent attacks, but no conclusions can be drawn from these few cases. Neither did the incidence of haemorrhage appear to be related to the position of the lesion on the course of the internal

carotid artery. There were five lesions in the lateral fissure, in fairly close relationship to the origin of the middle cerebral artery, but only two of these bled (Cases 5, and 32).

The Arterial Connections

The precise number of feeding vessels cannot be stated in all cases as injection of the contralateral carotid and vertebral artery was not carried out as a routine procedure. No difference however could be established in the incidence of haemorrhage, between those with multiple and those with single feeding arteries. It would be tempting to assume that the size of the lumina of the feeding vessels is related to the blood flow through the lesion and therefore to the stress imposed on the vessels of the lesion, thus it would be assumed that malformations with large feeding vessels would be more liable to haemorrhage. This was not borne out in the present series of cases. Of 11 arteriovenous malformations which bled, the arteriograms showed dilatation of the feeding arteries in all cases and was most marked in five who had recurrent attacks of haemorrhage (Cases 1, 5, 15, 18 and 30). Any possible significance of this finding is however refuted by the observation of considerable dilatation of the afferent vessels of six of eight large

lesions, which had never bled. Case 22 provides a good example of a lesion with very dilated feeding vessels; symptoms had been present for more than twenty years but it had never bled (figs. 25a and b). Conversely, absence of dilatation of the feeding vessels does not infer freedom from haemorrhage. There was no dilatation of the feeding artery in Case 8, who had four attacks of subarachnoid haemorrhage, nor in Case 21, though in the latter instance the vessels may have been compressed by the intracerebral haematoma (figs. 24a and b).

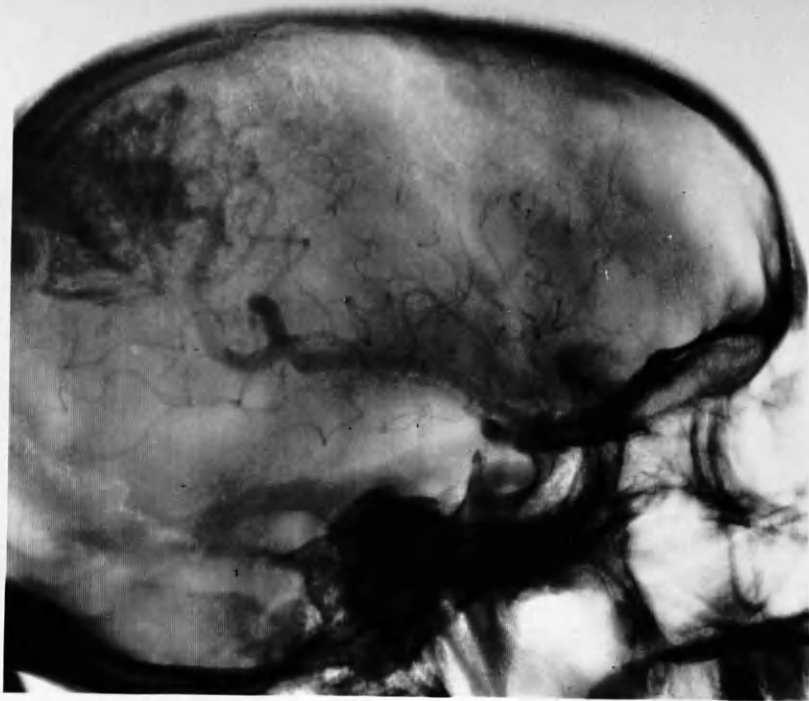


Fig. 25a Case 22

Large left parietal arteriovenous malformation with a much dilated feeding vessel from the middle cerebral artery. Non-filling of the anterior cerebral artery. Poor filling of the arteries elsewhere in the hemisphere.

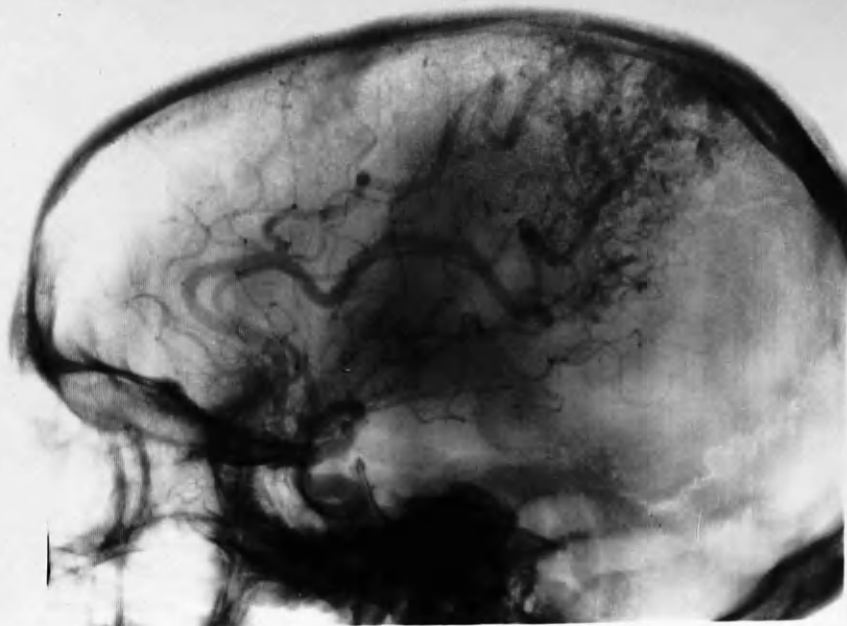


Fig. 25b Case 22

Rt. lateral view. The lesion is also supplied by an enlarged anterior cerebral artery which fills from the right side. The artery shows an unusual bifurcation in its course.

Bruit

Much importance has been attached to the presence of a systolic bruit on auscultation of the skull in the diagnosis of the intracranial malformations. Although the sign is not pathognomonic since it may occasionally be present with a very vascular tumour such as a meningioma, an arteriovenous fistula or even a saccular aneurysm, it is nevertheless most commonly found with the arteriovenous malformations. It was a sign relied on for diagnosis before the introduction of cerebral angiography and the early case reports contain many in which the sign was positive. Cushing and Bailey (1928) noted its presence in 8 of their 9 cases, Bergstrand, Olivecrona and Tönnis (1936) in 25 per cent. (of 22 cases) and Olivecrona and Riives (1948) in 19 per cent. (of 43 cases). Mackenzie (1953) reported a bruit in 23 of his 50 cases (46 per cent). The unusually high incidence in Mackenzie's series, was in all probability accounted for by his awareness of its inconstancy, and the careful and repeated search he made for its presence. He remarked on the fact that a bruit was heard in only one of his 14 cases with haemorrhage and he suggested that a possible reason for this discrepancy was the deep situation of the lesions which bled, in comparison for example with the superficial position of those with epilepsy.

A bruit was heard in 8 (25 per cent.) of the present series of cases: Cases 1 and 8 had repeated attacks of subarachnoid haemorrhage, Cases 7 and 23 intracerebral haemorrhage and Case 2 a hemiplegia. Only three of the cases had never bled (Cases, 3, 22 and 31). Two of the lesions were near the mid-line, two in the parietal region and four in the lateral fissure. This association of haemorrhage and a bruit in the present series does not therefore support Mackenzie's findings. It is to be noted however, that 7 of his 14 cases which bled were small lesions, so that the presence of a bruit in any event would have been unusual. It would not however be unreasonable to expect some alteration of the circulatory dynamics after an intracranial haemorrhage, especially when a large intracerebral haematoma develops, and that a bruit would at least temporarily disappear. Five of the 8 cases of the present series with a bruit had clinical or radiographic evidence of involvement of the external carotid artery, suggesting that it is a common occurrence when this artery is a feeding vessel.

Differential Diagnosis

Although in most instances the diagnosis of the arteriovenous malformations is straightforward, difficulty may occasionally arise with highly vascular tumours.

The glioblastoma multiforme is the tumour most likely to lead to confusion as it forms true arteriovenous communications. Wickbom (1950) has discussed the diagnostic difficulties which may occur. The tumour vessels and those of the arteriovenous malformation may closely resemble one another, but usually the feeding vessels are larger and the circulation more rapid in the latter. The converse occasionally applies and he has observed an arteriovenous malformation with a slow circulation and no dilatation of the feeding arteries. Evidence of expansion cannot be taken as a certain criterion of tumour, as an intracerebral haematoma may dislocate the vessels in the vicinity of an arteriovenous malformation. Wide veins may drain the lesion in both conditions, but dilatation is usually greater with the arteriovenous malformations. A venous channel which followed an anomalous course would favour the diagnosis of an arteriovenous malformation.

Differentiation between a meningioma and an arteriovenous malformation may be difficult from the routine skull radiographs, since both may show enlarged meningeal grooves and even a hyperostosis may be present with an arteriovenous malformation (fig. 2a). Cerebral angiography will in most cases resolve any doubt. The tumour vessels of the meningioma are arranged more uniformly and are reasonably well-defined. The circulation is frequently slow so that a "blush" may be seen in the late arterial, capillary and early venous phases of the angiogram. No arteriovenous communications occur. With some meningiomas however thin-walled vascular channels of larger calibre may be seen and the lesion has then been described as an haemangiomatous meningioma (Globus 1935).

Of the vascular lesions other than the arteriovenous malformations the haemangioblastoma is the only one likely to be demonstrated during the arterial phase of the angiogram. Cases demonstrated by angiography have been described by Egaz Moniz and d'Abreu (1946) and by Radner (1951). This lesion is usually situated in the cerebellum but may be supratentorial (Barnard and Walshe 1931, Green and Arana 1948) and it is in this latter position that confusion with the arteriovenous malformations would be most likely to occur.

Differentiation would depend on the demonstration of blood vessels of adult structure in the arteriovenous malformation, as opposed to the embryonic vascular channels of the haemangioblastoma.

During the period covered by the present investigation many cases of meningioma and glioblastoma multiforme with widely varying angiographic appearances were encountered and in spite of the theoretical difficulties referred to above no diagnostic errors in this respect occurred.

Value of Cerebral Angiography in Assessing
the Possibilities and Results of Treatment

Cerebral angiography is of considerable value in deciding the nature of the treatment to be followed and in assessing its results. Various forms of treatment have been advocated and favourable results have been claimed for them all. Dott (1932-33) described how in one case the "tumour" had shrunk into a fibrous mass following X-ray therapy. Olivecrona and Riives (1948) advised removal of the lesion where possible and failing this considered that treatment should be expectant - decompression, carotid ligation and X-ray therapy having been unsuccessful in their experience. In their Case 13, the lesion was said to have increased in size during the course of X-ray therapy. Although in the present series actual progression of the lesion following X-ray therapy has not been seen, two of six cases treated in this way were subsequently explored at operation (Cases 1 and 2) and there was no evidence to suggest that the lesion had been modified in any way. No definite benefit could be claimed for the remaining cases, and one of them (Case 8) had a subarachnoid haemorrhage some months after a course of therapy.

Carotid ligation was used in three cases (Case 2, 8 and 31) but benefit if any was only of a temporary nature. The danger of hemiplegia following this method of treatment has been emphasised by Olivecrona and Riives (1948). Butsch and Adson (1935) have employed electro-coagulation of the vessels exposed at operation, but this is an inferior method, and in the case of large lesions it is difficult to see how it can deal adequately with more than the surface vessels.

The first successful excision of an arteriovenous malformation was performed in Stockholm in 1932 by Olivecrona, since when he has operated on 47 of 98 cases observed between 1923-1948, with a mortality of 8.5 per cent. (Olivecrona 1949). Norlén (1949) has recorded a further 10 cases of successful excision of the lesion. Operation was carried out on 13 cases of the present series: in 10 total excision was possible, in one the lesion proved too extensive for removal (Case 1) and the patient died after operation, another patient died from haemorrhage from a small residual portion of the malformation following incomplete excision (Case 32) and the remaining case died after an attempt had been made to place a silver clip on the intracranial portion of the internal carotid artery (Case 31).

An example of the way in which cerebral angiography can assist in determining the suitability of a case for operation is exemplified by Case 23. The patient had been quite well until, following an injury to his head, he developed signs of intracerebral and subarachnoid haemorrhage. Exploratory burr holes failed to reveal evidence of subdural haematoma. Craniotomy was performed and a clot evacuated from the right temporal lobe and at the same time an unsuspected arteriovenous malformation was disclosed. No attempt was made to remove the lesion until cerebral angiography had revealed its full extent. In the arteriogram the malformation appeared to lie beyond the point of division of the middle cerebral artery and as its branches particularly the frontal and parietal could be seen beyond the lesion, it was considered that the arterial supply from the posterior temporal artery and that removal of the lesion might be accomplished without any severe disability. This proved to be correct, and the only residual abnormality was a left inferior quadrantic visual field defect. Finally a post-operative arteriogram showed the calibre of the internal carotid artery to be less, filling of the anterior cerebral artery to be restored and better filling of the parietal and frontal branches.

The importance of carrying out routine post-operative angiography is illustrated by Case 32, in whom excision of the main-body of the malformation from the territory of the middle cerebral artery was performed, but a small residual portion fed by the posterior cerebral artery was left behind.

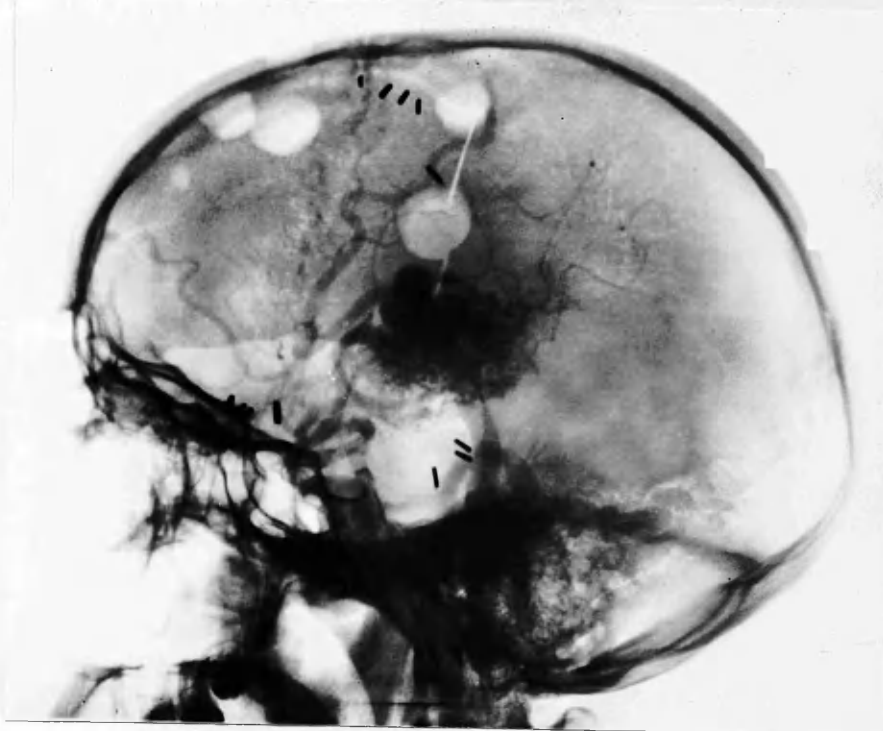


Fig. 26a Case 23
Large arteriovenous malformation in the Rt. lateral fissure.
Peripheral filling of frontal and parietal branches can be seen.
A vein extends to the sagittal sinus. The craniotomy flap is shown.

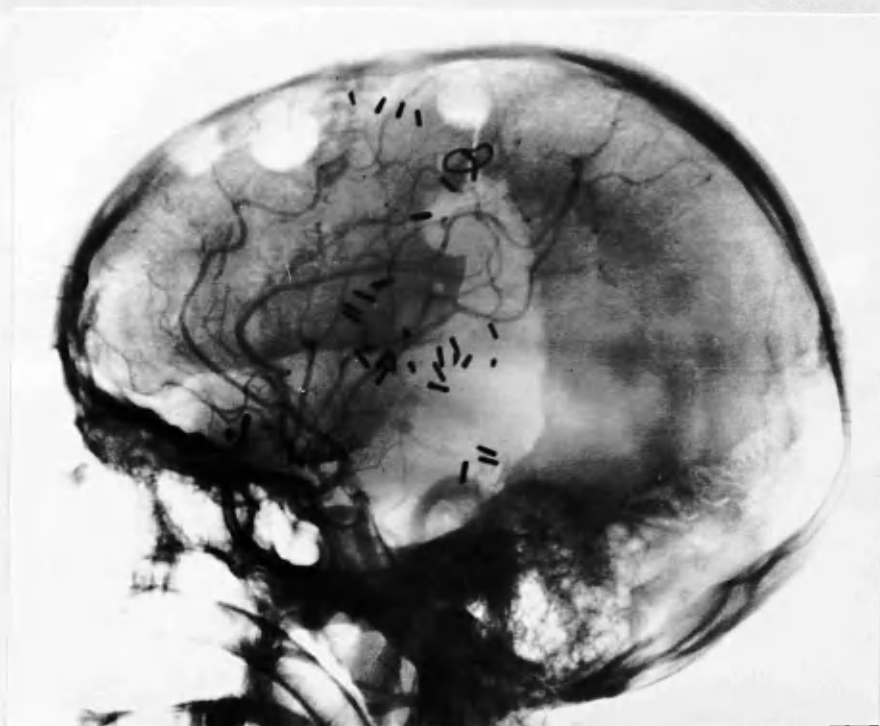


Fig. 26b Case 23
After excision of the lesion there is greatly improved
peripheral filling and filling of the anterior cerebral
artery has been restored.

D I S C U S S I O N

The diagnosis of the large arteriovenous malformations by means of cerebral angiography is, as a rule, easy and mistakes will only occur with poor technique. The importance of taking both antero-posterior and lateral views has been stressed; if this is not carried out a shunt through the circle of Willis may lead to localisation in the wrong hemisphere or to the suspicion of bilateral lesions where only one exists. A lesion supplied by the posterior cerebral artery will usually show up with carotid angiography unless it is very small, when a separate injection into the vertebral circulation will be required. The latter is technically a much more difficult procedure, by percutaneous injection, and except in the hands of a few experts (Lindgren 1950, Sjögren 1952) a high failure rate is inevitable. Catheterisation of the vertebral artery through the radial artery, a procedure introduced by Radner (1951), has given a high percentage of success but has not been widely adopted in this country. It follows from this that complete visualisation of the intracerebral circulation is not obtained in every case and failure in diagnosis is more likely to occur with the small than with the large lesions.

If we assume a thorough investigation with the production of technically satisfactory radiographs, is it still possible that a small lesion may not be demonstrated? From consideration of two small malformations (Cases 13 and 14), which appeared only in the antero-posterior radiographs, it would seem that a complete failure to show a lesion in which the vessels are of minute calibre is a definite possibility. There are several reasons why a lesion may fail to show up on angiography.

a. A small lesion is more likely to be recognised when centrally placed in relation to the internal carotid artery and its major branches, since the duration of the radiographic exposure (0.5 second) would favour its demonstration more than one at the periphery of the arterial tree. A technique employing multiple serial radiographs would overcome this difficulty.

b. A bony prominence may completely obscure a small lesion, in one or both of the two routine projections. For example, in the lateral view a lesion medially placed in the frontal region may be invisible because of the shadows cast by the floors of the anterior fossae.

c. Variation in filling of an artery, particularly the anterior cerebral artery, is well-known to those

practising cerebral angiography. On this analogy, it is possible that a small lesion may fill well at one injection, but fail to show at another carried out under apparently identical conditions.

d. Arterial spasm is known to occur in the vicinity of small aneurysms which have recently leaked and it is reasonable to suppose that the same would occur with a small arteriovenous malformation and so effectively block the entry of contrast medium. General anaesthesia may successfully relax the spasm in these cases and allow of good filling of the arterial tree. An alternative method would be to produce cerebral vasodilatation by the use of a drug such as "priscol" (2-benzyl-imidazoline hydrochloride), or by ganglionic block of the cervical sympathetic.

Appearances of the lesion in relation to symptoms.

The frequent occurrence of Jacksonian or sensory epilepsy, as a presenting symptom, is undoubtedly due to the high incidence (75 per cent.) of lesions in the territory of the middle cerebral artery and their localisation in the frontal and parietal lobes. Cases which develop epileptic attacks subsequent to cerebral haemorrhage are usually situated elsewhere in the hemispheres (Mackenzie 1953).

Headaches were more often associated with the large than the small lesions and a possible explanation is that the shunting of blood through the lesion leads to anoxaemia and to dilatation of the cerebral vessels (Olivecrona and Riives 1948). Small lesions which gave rise to headaches were usually in the occipital region and the headaches were then of a migrainous type.

There were no characteristic angiographic features from which it was possible to forecast the liability to haemorrhage. Bleeding occurred regardless of the position of the lesion in the brain and its relationship to the main arterial trunks. A lesion with many dilated feeding arteries appeared no more liable to haemorrhage than one with a single small artery of supply. The frequency of haemorrhage from the small and medium-sized malformations as compared with the large, has been commented on, but it would be inadvisable at this stage to conclude that the small lesions are more liable to bleed than the large, since the relative number of cases at risk is not known. An example of a malformation (Case 32) which was incompletely excised is of particular interest in this respect, as it was the small residual portion of the lesion which led to a fatal haemorrhage a few months after operation.

If it were assumed that the small lesions are more liable to haemorrhage, then a possible explanation would be, that the full force of the arterial pressure is communicated directly to the vessels of the small malformations, whereas it is effectively dissipated in the wide vascular spaces of the large ones. Further study of the relationship of the size of the lesion to haemorrhage would seem to be worthwhile. Evidence in favour of the view that spontaneous cerebral haemorrhage of unknown origin is due in some cases to small angiomatous malformations is advanced by Margolis, Odom, Woodhal and Bloor (1951).

Increase in size

Evidence in favour of an increase in size of a lesion is provided by Case 1, in which the feeding arteries were seen to have dilated over a period of three years. It is remarkable, perhaps, that an observation of this sort has not been made more often and a possible explanation is that the enlargement has already occurred by the time angiography is carried out and that any further increase in size is uncommon. The amount a given lesion can enlarge is obviously related to its initial size and to the size of the blood vessels comprising it. Aneurysmal dilatations may occur in some cases.

The view, that a lesion originally venous enlarged by acquiring arterial connections is almost certainly wrong and Lima's (1950) contention that the lesions are arteriovenous from the beginning is probably correct. The various factors which affect the progress of a lesion are unknown, though trauma appears to play a part in a few cases. It is not yet known whether all arteriovenous malformations ultimately progress and produce symptoms, or whether in the case of some small malformations the arteriovenous communications close and the lesion, at least in so far as its vascular effects are concerned, become quiescent. The report of Penfield and Ward (1948) is of interest in this respect as it would suggest that an abortive form of lesion exists and may as in two of their cases, in which the histology suggested arteriovenous malformation, completely calcify.

Relation to other vascular malformations

Doubt has already been cast on the existence of a pure arterial form of malformation and so far there are no records of a lesion of this type having been demonstrated by angiography. The feeding arteries to some arteriovenous malformations show great tortuosity and complexity of their branches (see Case 18, fig. 19a) and it is probable

that this type of lesion has been mistaken in the early literature for a true arterial malformation.

Venous anomalies certainly occur, though it seems likely that most cases described as "venous angiomata" from their morbid and operative appearances were in fact arteriovenous malformations - for example the five cases described by Cushing and Bailey (1928). A possible source of error in the interpretation of varices exposed on the surface of the cerebral hemispheres may have arisen from failure to recognise that the anomalous veins were, at least in some cases, the surface expression of small deeply placed arteriovenous malformations. Although pulsation and the presence of arterial blood in the vein would indicate an arteriovenous shunt, changes of this nature must be a matter of degree and with the smallest lesions, may not be present. An anomalous course followed by the drainage veins is certainly a common observation at operation in cases of arteriovenous malformations. One case (Case 19, figs. 21a and b) was of particular interest because the drainage vein crossed to the opposite side of the skull, an appearance which must surely indicate persistence of embryonic venous channels.

Isolated venous anomalies such as varices should in theory be demonstrable by angiography, but have not so far been recorded.

An angiomatous appearance in relation to the calcified occipital cortex has been observed by Furtado (1936) in a child of five, with the Sturge-Weber syndrome, after injection of thorocontrast. Lima (1950) considered that the angiomatous condition of the meninges is gradually obliterated and this would explain the absence of a vascular lesion when angiography is carried out in adult life.

Telangiectases are small capillary lesions and it seems unlikely that they would ever be demonstrable by angiography. This diagnosis was considered but finally rejected in Case 13, in which a small lesion appeared in the arteriogram as a diffuse area of contrast accumulation without obvious vessels. The site of the lesion was atypical and its appearance during the arterial phase of the angiogram favoured the diagnosis of an arteriovenous malformation; this was borne out by subsequent histological examination of the specimen (see fig. 14a).

The diagnosis of a cavernous angioma by angiography, was suggested by Curtis (1948) in a case in which a small collection of contrast together with a drainage vein appeared first at four seconds but more clearly in later films, but has not yet been confirmed.

The circulation of the haemangioblastoma is demonstrable during the arterial phase of the angiogram and its features have been considered in the discussion on differential diagnosis.

Routine skull radiography

Preliminary radiographic examination of the skull plays only a subsidiary role in the diagnosis of the arteriovenous malformations and its main function when positive evidence is obtained is to indicate angiography as the next line of investigation. The changes, which may be seen in the cranium, are for the most part related to the frequency of involvement of the external carotid artery, though localised areas of rarefaction in the skull vault due to the lesion or its veins also occur and calcification may be demonstrated in the vessels of the lesion or in an adjacent haematoma. Whereas the earlier reported series contained a high percentage of cases in which changes were observed in the skull radiographs, the incidence in the present series is less than 30 per cent. Evidence of an enlarged groove for the superior sagittal sinus is suggested as a sign of possible diagnostic significance, since it may be present when a lesion is confined to the intracerebral circulation.

It was present in four cases and if a further three borderline cases are included, then it was the commonest single radiographic appearance affecting the skull vault. Apart from a casual mention of enlargement of the groove in one case by Olivecrona and Riives (1948), no particular attention has been paid to this sign in the literature.

It may be concluded that the contribution of radiology to the study of the intracranial arteriovenous malformations has been of the greatest importance. Cerebral angiography in particular has led to a more complete understanding of the pathology of the lesion, its natural history and its relationship to the other vascular anomalies. Many small lesions have been demonstrated and their importance in relation to intra-cerebral haemorrhage has been emphasised. Angiography by providing an exact diagnosis has led to a correct evaluation of the clinical findings associated with these lesions, which are not nearly as uncommon, as was at first thought. But finally, and most important, it has brought a potentially dangerous lesion within the scope of neurosurgical technique.

S U M M A R Y

- (1) A series of 32 cases form the basis of a radiological investigation of the intracranial arteriovenous malformations.
- (2) The incidence of the intracranial arteriovenous malformations has been estimated at one per cent. of the neurological admissions to hospital (Mackenzie 1953). They comprise two to five per cent. of the reported cases examined by cerebral angiography (4.8 per cent. in the present series).
- (3) The pathology of the lesion is described and its relationship to the other vascular anomalies is defined. Arteriovenous malformation is considered to be the most suitable terminology.
- (4) Abnormal appearances in the preliminary skull radiographs, attributable to the presence of an arteriovenous malformation, may be seen in approximately 30 per cent. of the cases. They are as follows:-
 - (a) Enlargement of foramina and grooves for the meningeal vessels and occasionally anomalous vascular channels. Perforations in the skull due to communications between branches of the external carotid artery in the scalp and the meningeal vessels.

Thickening of the skull, when the vascularity of the bone is greatly increased, which may simulate the hyperostosis of a meningioma.

(b) Enlarged and pulsating drainage veins or the malformation itself may lead to localised areas of erosion of the inner table of the skull. Enlargement of the sagittal sinus groove may be demonstrable when there is a large shunt situated so that its effluents drain into the sinus. This observation may be of some value, since it may be the only visible radiographic change occurring with a lesion confined to the intracerebral circulation. Four of the present cases showed marked widening and deepening of the sinus groove and in three others enlargement was probable.

(c) Calcification may be found in the walls of the vessels of the malformation or in adjacent haematomata. It is present in approximately 15 per cent. of cases.

(5) Ventriculography and encephalography have been superseded by cerebral angiography in the investigation of intracranial vascular lesions. In approximately 70 per cent. of cases of arteriovenous malformation

plain radiography and ventriculography combined show some abnormality. An undulating, serrated or ripple contour of the walls of the lateral ventricle, without shift of the ventricular system has been considered typical of the conditions. Other changes result from cerebral atrophy, organisation of blood clot in the ventricle leading to coarctation, or to filling of a porencephalic cyst with air. Hydrocephalus commonly occurs with mid-brain lesions.

- (6) The technique of cerebral angiography as it applies to the demonstration of the arteriovenous malformations is described. Possible pitfalls in diagnosis are considered.
- (7) The angiographic appearances of the arteriovenous malformations, their feeding arteries and drainage veins are described. There were 17 large lesions, 10 small and 5 of intermediate size. The middle cerebral artery was the feeding vessel in 75 per cent. of cases.
- (8) A case is presented to support the hypothesis that a true increase in size of the arteriovenous malformations occurs.
- (9) Epilepsy was the presenting symptom in 25 per cent. and present eventually in 44 per cent. of the present cases. The attacks were mainly focal in type and in

those presenting with epilepsy the common situation of the lesion was fronto-parietal. If haemorrhage preceded the onset of the attacks the lesion was elsewhere in the brain.

(10) Headache was a presenting feature in 44 per cent. of the cases. It was commoner with the large (11 of 17 cases) than with the small (3 of 10 cases). Six lesions in relation to the occipital lobe were associated with headache of a migrainous type.

(11) Haemorrhage occurred from 41 per cent. of the large, 70 per cent. of the small and all 5 lesions of medium size. It is suggested that the difference in incidence in bleeding from the small and large malformations, is due to the fact that the large ones are found during the course of investigation for symptoms such as headache and epilepsy, whereas small lesions are frequently asymptomatic until bleeding occurs. The relative liability of the small and large lesions to bleed cannot however be assessed until the number of small lesions at risk is known. The possibility that the small lesions are in fact more liable to haemorrhage than the large is not excluded. There are no characteristic angiographic

features whereby the liability of a particular lesion to haemorrhage can be forecast.

- (12) The frequency with which an intracranial bruit can be heard on auscultation of the skull has varied widely in different reports. It was present in 8 cases (25 per cent.), all large lesions, of the author's series. In 5 of the cases there was clinical or radiographic evidence of hypertrophy of branches of the external carotid artery.
- (13) The differentiating features between highly vascular tumours such as glioblastoma multiforme and meningioma and the arteriovenous malformations are described. There were no difficulties of this type in the present series of cases.
- (14) The value of cerebral angiography in the assessment of the operability of a lesion and in showing the results of excision are exemplified.
- (15) The limitations of cerebral angiography in the diagnosis of small arteriovenous malformations are discussed. It is considered possible that some very small lesions may fail to be demonstrated by this method.

(16) The relation of the arteriovenous malformations to the other vascular anomalies is considered. The view is expressed, that the lesion classified as a true arterial anomaly was in all probability an arteriovenous malformation with extreme tortuosity and ramification of its afferent arteries. Similarly cases diagnosed from their morbid and operative appearances as cerebral venous angiomas have in most cases had unrecognised arterial connections.

(17) It is concluded that cerebral angiography is a most successful method in the diagnosis of the arteriovenous malformations.

R E F E R E N C E S

- Alpers, B.J., Forster, F.M. (1945) Arch. Neurol. Psychiat.,
Chicago, 54, 181.
- Bancroft, F.W., Pilcher, C. (1946) Surgical Treatment of
the Nervous System. Philadelphia & London,
J.B. Lippincott & Co.
- Barlow, H.C. (1943) Clin. J., 72, 177.
- Barnard, W.C., Walshe, F.M.R. (1931) J.Path. Bact., 34, 385.
- Basset, R.C. (1951) J.Neurosurg., 8, 59.,
- Bergstrand, H. (1936) Acta path. microbiol, scand., Suppl.
26, 89.
- Olivecrona, H., Tönnis, W. (1936)
Gefassmissbildungen und Gefässgeschwulste des
Gehirns. Leipzig, Georg Thieme.
- Boldrey, E., Miller, E.R. (1949) Arch. Neurol. Psychiat.,
Chicago, 62, 778.
- Brock, S., Dyke, C.G. (1932) Bull. Neurol. Inst. N.Y.,
2, 247.
- Bull, J. (1951) In, Modern Trends in Neurology. London
Butterworth & Co. Ltd.
- Bunner, R. (1949) Acta radiol., Stockh., 31, 233.

- Butsch, W.L., Adson, A.W. (1935) Surg. Clin. N.Amer.,
15, 1317.
- Camp, J.D. (1948) J.Amer. med. Ass., 137, 1023.
- Cohen, I. (1942) J.Mt.Sinai Hosp., 9, 354.
- Cushing, H., Bailey, P. (1928) Tumors Arising from the
Blood-vessels of the Brain. Springfield
Illinois, C.C. Thomas.
- Curtis, J.B. (1949) J. Neurol. Neurosurg. Psychiat.,
12, 167
--- (1951) Brit. J. Surg., 38, 295.
- Christophe, I. (1950) Acta neurol, Psychiat. belg.,
50, 465.
- Dandy, W.E. (1928a) Arch. Surg., Chicago, 17, 190.
--- (1928b) Ibid, p. 715.
- Dott, N.M. (1932-33) Trans. med-chir. Soc., Edingburgh,
47, 24.
- Egaz Moniz, d'Abreu, C., D'Oliveira, C. (1932) Rev.
neurol., 39, 165.
--- (1940) Die Cerebrale Arteriographie und
Phlebographie, Berlin, Springer.
--- --- (1946) Praxis, 33, 140.

- Engeset, A. (1944) Acta radiol., Stockh., 56, 162.
- Falconer, M.A. (1952) Lancet, 2, 945.
- Furtado, D. (1936) Rev. neurol., 65, 640.
- Gillingham, F.J. (1952) J.Fac. Radiol., Lond., 3, 254.
- Globus, J.H. (1935) Tumours of the Nervous System. Assoc. for Research in Nervous and Mental Diseases, 16, 210.
- Green, J.R., Arana, R. (1948) Amer. J. Roentgenol., 59, 617.
- Hauge, T. (1951) cited by Engeset, A., Kristiansen, K.
(1953) In Modern Trends in Diagnostic Radiology.
2nd. series, London, Butterworth & Co. Ltd.
- Hodes, P.J., Perryman, C.R., Chamberlain, R.H. (1947)
Amer. J. Roentgenol., 58, 543.
- Holm, O.F. (1944) Acta radiol., Stockh., 25, 163.
- Holmgren, B.S. (1947) Acta psychiat., Kbh., Suppl., 46, 165.
- Jaeger, R., Forbes, R.P. (1946) Arch. Neurol. Psychiat., Chicago, 55, 591.
- Jentzner, M.A. (1939) Rev. Oto-neuro-optal., 17, 118.
- Jupe, M.H. (1939) In A Text-Book of X-ray Diagnosis,
1st. ed., Vol. 3. London, H.K. Lewis & Co. Ltd.
- Khoo, F.Y. (1946) Amer. J. Roentgenol., 55, 333.

- Krabbe, K.H. (1932) Rev. neurol., 39, 1394.
- Levine, V. (1943) Trans. Chicago path. Soc., 14, 107.
- Lima, P. Almeida, (1950) Cerebral Angiography. London
Oxford University Press.
- Lindblom, K. (1936) Acta radiol., Stockh., Suppl., 30.
- Lindgren, E. (1950) Acta radiolog., Stockh., 33, 389.
- Loman, J., Myerson, A. (1936) Amer. J. Roentgenol., 35, 188.
- Lombardi, G. (1951) Radiol. med. Torino, 37, 16.
- Mackenzie, I. (1953) Brain, 76, 184.
- Mckissock, W. (1950) Ann. R. Coll. Surg. Engl., 4, 472.
- Margolis, G., Odom, G.L., Woodhal, B., Bloor, B.M. (1951)
J. Neurosurg., 8, 564.
- Michael, J.C., Levin, P.M. (1936) Arch. Neurol. Psychiat.,
Chicago, 36, 514.
- Moore, R.C. (1951) Radiology, 57, 487.
- Nelson, T.Y. (1937) Aust. N.Z. J. Surg., 7, 137.
- Noran, H.H. (1945) Arch. Path. (Lab. Med.), 39, 393.
- Northfield, D.W.C. (1940-41) Guy's Hosp. Rep., 90, 149.
- Norlén, G. (1949) J. Neurosurg., 6, 475.
- Olivecrona, H., Riives, J. (1948) Arch. Neurol. Psychiat.,
Chicago, 59, 567.

- (1949) Nord. med., 41, 843.
- Oscherwitz, D., Davidoff, L.M. (1947) J. Neurosurg., 4, 539.
- Penfield, W., Ward, A. (1948) Arch. Neurol. Psychiat.,
Chicago, 60, 20.
- Power, D'Arcy, (1888) Tr. Path. Soc. Lond., 39, 4.
- Radner, S. (1951) Acta radiol., Stockh., Suppl., 87
- Raney, R., Raney, A.A., Sanchez-Perez, J.M. (1949)
J. Neurosurg., 6, 222.
- Raskin, N. (1949) J. Neuropath., 8, 326.
- Ray, B.S. (1941) Surg. Gynec. Obst., 73, 615.
- Reitzel, R.J., Brindley, P. (1929) Am. J. Med. Sci.,
178, 689.
- Richardson, J.C., Hyland, H.H. (1941) Medicine, Baltimore,
20, 1.
- Rogers, Lambert. (1933-34) Brit. J. Surg., 21, 229.
- Ruggiero, G. (1952) Acta radiol., Stockh., 37, 87.
- Russell, D.S. (1930) Proc. R. Soc. Med., 24, 383.
- Nevin, S. (1940) J. Path. Bact., 51, 375.
- (1941) Actas esp. neurol., 2, 133.
- Sargent, P. (1930) Proc. R. Soc. Med., 24, 370.

- Schaltenbrand, W., cited by Noran, H.H. (1945) Arch. Path.
(Lab. Med), 39, 393.
- Schwartz, C.W. (1939) Amer. J. Roentgenol., 41, 881.
- Shearer, W.S. (1952) J. Fac. Radiol., Lond., 3, 248.
- Shenkin, A., Spitz, F.C., Grant, F.C., Kety, S.S. (1948)
J. Neurosurg., 5, 165.
- Shimidzu, K. (1937) Arch. klin. Chir., 188, 295.
- Sjögren, S.E. (1952) Proceedings 3 Symposium Neuroradiolo-
gicum, Stockholm.
- Stewart, R.M., Ashby, W.R. (1931) J. Neurol. Psychopath.,
11, 289.
- Steinheil, S.O. cited by Dandy, W.E. (1928a) Arch. Surg.,
17, 190.
- Streeter, G.L. (1918) Contributions to Embryology.
Carnegie Publications, 8, 24.
- Sugar, O. (1951) J. Neurosurg., 1, 3.
- Sutton, D., Hoare, R.D. (1951) Brit. J. Radiol., 24., 589.
- Torkildsen, A., Koppang, K. (1951) J. Neurosurg., 8, 269.
- Touraine, A., Golé, L., Sambron, J. (1936) Bull. Soc.
franc. Derm. Syph., 43, 618.
- Trupp, M., Sachs, E., (1948) J. Neurosurg., 4, 354.

- Turner, O.A. (1946) Ibid, 3, 542.
- Verbiest, M.H. (1951) Rev. neurol., 85, 189.
- Virchow, R. (1863) Die krankhaften Geschwülste, Berlin,
A. Hirschwald.
- Wechsler, I.S., Gross, S.W. (1948) J. Amer. med. Ass.,
136, 517.
- Wickbom, I. (1948) Acta Radiol., Stockh., Suppl., 72.
--- (1950) Acta Radiol., Stockh., 34, 385.
- Wolf, A., Brock, S. (1935) Bull. Neurol. Inst. N.Y.,
4, 144.
- Worster-Drought, C., Carnegie, Dickson, W.E. (1927)
J. Neurol. Psychopath., 8, 19.
- Wyburn-Mason, M. (1943) Brain, 66, 163.
- Yakolev, P.I., Guthrie, R.H. (1931) Arch. Neurol. Psychiat.,
Chicago, 26, 1145.
- Yates, Gurney, A., Paine, C.G. (1930) Brain, 53, 38.

APPENDIX

Case 1

M. T. a female aged 26 was admitted to the London Hospital on 29.6.49.

She gave a history of attacks of subarachnoid haemorrhage, in 1936, 1940 and 1945. In 1940 when she was a patient in Chase Farm Hospital ventriculography was attempted, but given up when a right parietal burr hole showed leashes of tortuous vessels considered to be due to an arteriovenous malformation. Her only complaint was of moderately severe headaches. In 1946 cerebral angiography was carried out and showed a large parietal arteriovenous malformation. Following this she received a course of X-ray therapy and remained well until a further subarachnoid haemorrhage led to her present admission.

On examination, the carotid pulses were found to be of full but equal volume; there were audible bruits in both temporal regions. There was a left lower quadrantic homonymous hemianopia and nystagmus on looking to the right. The deep reflexes on the left side were slightly increased and the left plantar response was equivocal.

Skull radiographs showed prominent and tortuous grooves for the meningeal arteries and an anomalous vascular channel in the parietal region. Cerebral angiography confirmed the presence of an arteriovenous malformation and also demonstrated that the feeding arteries were enlarged in comparison with the previous angiograms of 1946.

Operation was carried out on 6.7.49 and the malformation was seen to be lying at the anterior end of the calcarine fissure and extending over the splenium into the right lateral ventricle. An attempt was made to excise the lesion but was abandoned because of loss of blood. Her post-operative course was characterised by a left hemiparesis and sensory loss of a cortical type. On 28.7.49, a further attempt was made to remove the lesion, but it was eventually decided that it was too extensive. She remained stuporose after the operation and died a few days later.

Post-mortem examination showed the cavity of the right lateral ventricle to be filled by a mass consisting of enormously dilated blood vessels. The corpus callosum was destroyed on the right side. Extensive areas of blood clot were found in the right cerebral hemisphere and occupying almost the whole of the internal capsule.

Case 2

R. K. a male aged 31 was admitted to the London Hospital on 26.4.49.

At the age of 9 he had a sudden attack of loss of consciousness and on awakening found that the left side of his body was paralysed. He attended school in the normal way and was considered to be of average intelligence. In 1942 at the age of 24 he complained of severe headaches and giddiness and was admitted to Chase Farm Hospital, where cerebral angiography was carried out and a right frontal arteriovenous malformation diagnosed. The right internal carotid artery was ligated and some improvement in his headaches and giddiness resulted. This treatment was followed-up by a course of X-ray therapy at the Middlesex Hospital. During the next 7 years he suffered from attacks which were characterised by twitching of the left leg and a Jacksonian march to the upper limb and side of the face.

On examination, he was found to have increased volume of pulsation of the carotid and superficial temporal arteries; there was an audible bruit on the right side of the skull. The disc edges were blurred and there was increased tortuosity of the fundal vessels. A left-sided

hemiplegia was present.

X-ray examination of the skull revealed a thick bony vault and a generalised increase of the convolutional markings; a hyperostosis was present in the frontal region; the sella was deeper than average. The sulcus for the sagittal sinus was enlarged. Cerebral angiography was repeated and the malformation was seen to be situated in the mid-line in the frontal region more on the right than the left side.

Operation was carried out on 19.5.49, but there was so much bleeding from the osteoplastic flap that further procedure was postponed until 9.6.49, when the arteriovenous malformation was removed together with the anterior quarter of the right cerebral hemisphere. The post-operative course was characterised by paresis of the right lower limb, but he made a good recovery and it was not evident a month later.

He last attended on 21.7.50, when he looked and felt well and he was able to get about despite his hemiplegia. There had been occasional attacks of giddiness but no loss of consciousness.

Case 3

M. A. a female aged 30 was admitted to the London Hospital on 4.3.51.

She complained of attacks of numbness of the left hand, headaches of moderate severity and giddiness, for the past ten years. A few weeks before she had an epileptic fit which was preceded by twitching of her left upper limb and side of her face.

On examination there was conspicuous pulsation in her neck and increased volume of the right carotid pulse. A bruit was audible and was maximal over the right temple. A slight right lower facial weakness was noted and the left knee jerk was increased. She is left-handed.

X-ray examination of the skull showed a thick bony vault and increased convolitional markings. The meningeal grooves were prominent and the right foramen spinosum was larger than the left. The foramen transversarium of the second cervical vertebra measured 9mm. by 8mm. (normal maximum according to Lindblom 7mm.). Cerebral angiography demonstrated a large arteriovenous malformation in the right parietal region.

No active treatment was advised because of the size of the lesion and its situation in the dominant hemisphere. She last attended on 17.12.52, when she was well and there had been no further fits.

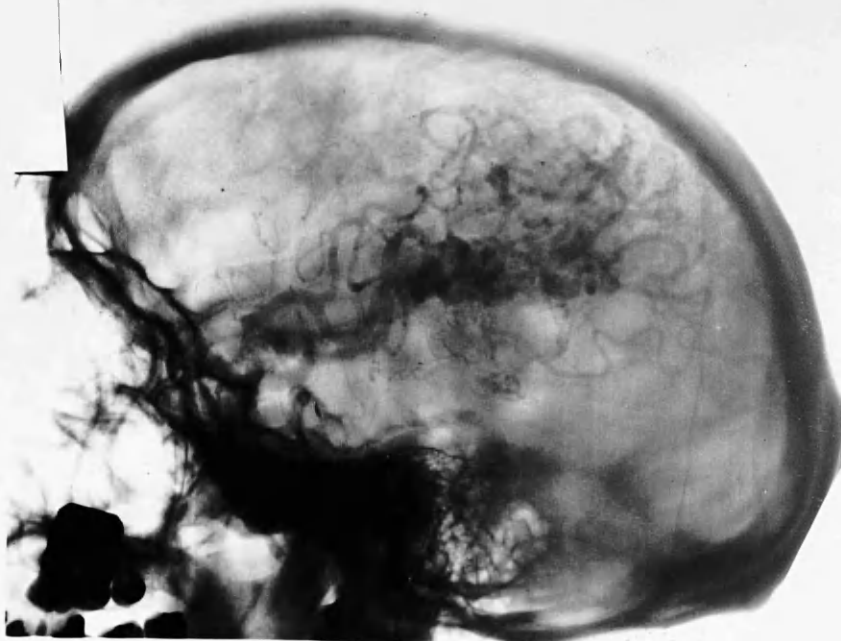


Fig. 27a Case 3
Extensive Rt. parietal arteriovenous malformation showing great torousity of the feeding arteries. Absent filling of the anterior cerebral artery.

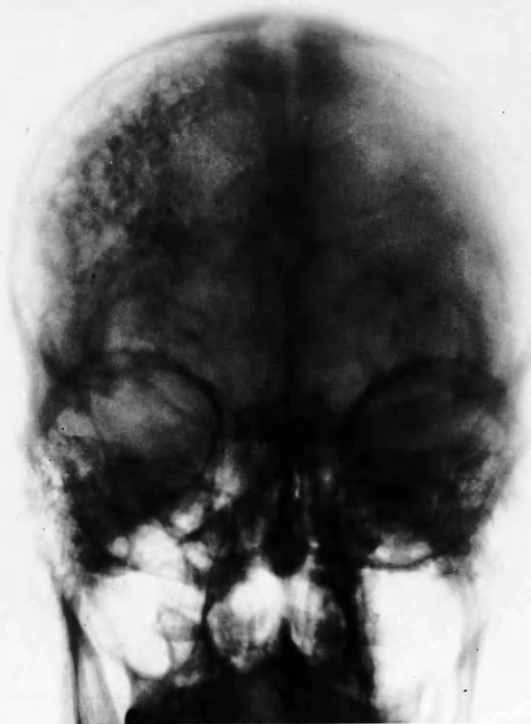

Fig. 27b Case 3
A.P. view of (a) above.

Case 4

S. A. a female aged 13 was admitted to the London Hospital on 12.11.50.

Four months before she was admitted to hospital in coma and the diagnosis of subarachnoid haemorrhage was confirmed by the finding of blood in the C.S.F. She made a complete recovery and there were no present complaints.

X-ray examination of the skull showed a localised area of rarefaction in the left para-sagittal region and cerebral angiography an arteriovenous malformation which coincided with this area.

Operation was performed on 19.11.50 and the lesion was successfully excised. It was noted at operation that the main arterial supply came from a large vessel on the medial side of the cerebral hemisphere, a branch of the anterior cerebral artery. Post-operatively she developed a right sided hemiparesis and dysphasia, but this slowly recovered and there was no evidence of it on her last attendance on 19.1.51.

Histo-pathological examination of the excised specimen confirmed the diagnosis of arteriovenous malformation.

Case 5

G. O. a female aged 42 was admitted to the London Hospital on 26.9.46.

She gave a history of a gradual onset of weakness affecting the right side of her body, from the age of 9. Her general health was otherwise satisfactory and she was able to continue in her employment as an office clerk. When 36 years old she had an attack of severe headache and neck stiffness but did not lose consciousness. In the following years she has had five more attacks of this type, the last, three months ago when she lost consciousness. She has complained of severe headaches for the past year and is now unable to perform any skilful movements with her right arm.

On examination the carotid pulses were full but equal on both sides. The right eyeball was slightly proptosed and a few enlarged veins were present on the upper lid, the fundal veins showed some tortuosity, there was a right homonymous hemianopia. A severe right-sided hemiparesis was present and was associated with some impairment of postural sensibility and tactile localisation.

X-ray examination of the skull showed evidence of hyperostosis frontalis interna; an anomalous vascular

groove crossed the left parietal region; a group of amorphous deposits of calcium density were present in the left temporo-parietal region. The sagittal sinus groove was enlarged. Cerebral angiography outlined a left parietal arteriovenous malformation, which filled mainly from the left carotid and vertebral arteries and also through the circle of Willis when the right carotid was injected.

No active treatment was advised. She has not attended the London Hospital for further examination.

Case 6

W. C. a male aged 53 was admitted to the London Hospital on 5.3.48.

From the age of 16 he had suffered from migrainous headaches occurring at intervals of a few weeks. When 27 years of age he had a severe headache which was followed by loss of consciousness and in the past year he had three similar attacks. In one of these he had dysphasia and lost the use of his right arm for thirty minutes and following the last attack he noticed that vision was defective on the right side. Neck rigidity was never associated with the attacks.

On examination there was a right homonymous hemianopia and some weakness of the right arm and leg. No record was made of the presence or absence of an intracranial bruit.

X-ray examination of the skull showed enlarged meningeal vascular channels and tortuous parallel lines of calcification in the left parieto-occipital region. Cerebral angiography demonstrated an arteriovenous malformation in relation to the areas of calcification.

His subsequent course was characterised by the development of a glaucoma in the right eye, which became

blind. He developed a carcinoma of the rectum and died on 16.2.49 having refused treatment.

Case 7

H. K. a female child aged 2 was admitted to the London Hospital on 14.4.49.

Her development had been normal until 9 months ago, when she had a severe convulsion associated with left-sided clonic spasms. She was admitted to the Queen Elizabeth Hospital, Hackney, where on regaining consciousness she was found to have a left-sided hemiplegia. There have been no further fits; the hemiplegia has persisted.

On examination, the left side of the forehead was seen to be more prominent than the right and there were two dilated veins over the bridge of the nose. There was no cephalic bruit though this had been observed previously at the Queen Elizabeth Hospital.

X-ray examination of the skull showed a round irregular opacity of calcium density deep in the right frontal region. Ventriculography revealed a filling defect in the body of the right lateral ventricle without displacement of the ventricular system. Cerebral angiography outlined the arteriovenous malformation in the right lateral fissure.

No active treatment was advised. On her last attendance there had only been two fits since her discharge from hospital; there was a mild spastic hemiparesis.

Case 8

A. W. a male aged 25 was admitted to the London Hospital on 8.7.44.

He had been quite well until January 1943 when he suddenly developed a severe bifrontal and occipital headache, associated with neck stiffness, but without loss of consciousness. The diagnosis of subarachnoid haemorrhage was confirmed by the finding of blood in the C.S.F. Three further attacks followed, the last three months ago.

On examination there was some residual neck stiffness and a moderate degree of papilloedema. The right arm and leg showed some weakness and the deep reflexes were increased. Kernig's sign was positive.

The left common carotid artery was ligated. He was re-admitted to the London Hospital on 1.12.47 for carotid angiography and an arteriovenous malformation was demonstrated in the left temporo-parietal region. He received a course of X-ray therapy and was apparently benefited by it, but on 2.5.48 he had a further haemorrhage. Ventriculography carried out at this time showed a filling defect in the left lateral ventricle just anterior to the trigone.

No further treatment was considered advisable. He last attended on 17.10.52, when his only complaint was of headaches of moderate severity lasting a few hours at a time.

Case 9

W. M. a female aged 54 was admitted to the London Hospital on 9.2.49.

In 1934 she started having epileptic attacks which were preceded by numbness in her right hand. A year later on regaining consciousness from one of these attacks she was found to have a right-sided hemiplegia and dysphasia. In 1940 she was admitted to Chase Farm Hospital, where ventriculography was performed and showed some flattening of the anterior horn of the left lateral ventricle, and craniotomy disclosed an arteriovenous malformation. No attempt was made to remove the lesion. The attacks have continued at intervals of six weeks to three months and are worse during her periods or else when she is emotionally upset.

On examination there was evidence of intellectual deterioration and she was euphoric. A marked degree of aphasia was present. The presence of a right-sided hemiplegia was confirmed.

Cerebral angiography was carried out and a left-sided arteriovenous malformation demonstrated.

The lesion was successfully excised on 1.3.49.

She last attended on 20.6.51 when she had continued to have three or four generalised epileptiform attacks every year.

Case 10

J. S. a male aged 49 was admitted to the London Hospital on 17.5.50.

Two months before he had a sudden attack of teichopsia followed by blindness for thirty minutes and a severe bifrontal headache which lasted five days. There have been two further attacks the last a month ago. He also complained of numbness of the left side of his face and of occasional high pitched noises in the left ear.

On examination he was found to have a brisk right knee jerk and an equivocal right plantar response. Physical examination was otherwise negative.

Skull radiography and air encephalography were normal. Cerebral angiography demonstrated a small arteriovenous malformation in the left posterior temporal region.

No active treatment was advised and he was discharged home on 7.6.50. When he last attended on 19.12.51, he was well and had no further attacks.

Case 11

L. B. a male aged 45 was admitted to the London Hospital on 14.1.48.

He gave a history of epileptiform attacks of varying types for the past 17 years. There have been right-sided focal, motor, sensory and inhibitory attacks, without loss of consciousness and also generalised seizures preceded by visual aura. Weakness and clumsiness of the right hand have gradually developed and are now severe and during the past three months his right foot has begun to drag.

He is left-handed. On examination carotid pulsation was found to be greater on the left side. Bruits were audible over the carotid arteries but not over the skull. There was a right-sided hemiplegia and some loss of postural sensibility and of two-point discrimination, in his right hand.

Skull radiographs showed a deep groove for the sagittal sinus. Cerebral angiography demonstrated a large left-sided fronto-parietal arteriovenous malformation. The lesion filled also when the right artery was injected.

A course of X-ray therapy was given, but without obvious benefit. He last attended on 8.11.49, when his hemiplegia was more marked.

Case 12

W. S. a male aged 47 was admitted to the London Hospital on 14.9.48.

Twenty-five years before he suddenly developed a right-sided hemiplegia, from which he made a good recovery. Ten years ago he began having cramp in his right wrist and spreading up to his face, each attack lasting about three minutes. Four weeks ago he had a minor head injury, without loss of consciousness, and a week later he had a series of generalised convulsions. Recently his sight has deteriorated and his hearing is poor especially on the left side.

On examination the right pupil was larger than the left, but showed normal reactions. There was minimal weakness of the right upper limb and some increase of the deep reflexes. Postural sensation, vibration and two-point discrimination were impaired in the right hand. The peripheral vessels showed evidence of arteriosclerosis. The B.P. was 220/140. He is left-handed.

Skull radiographs were normal. Air encephalography showed a depression of the roof of the left lateral ventricle. Cerebral angiography demonstrated an arteriovenous malformation in the left parietal region.

It was considered that his recent exacerbation of symptoms might be associated with the onset of hypertension and that there was no indication for treatment. At his last attendance on 26.8.52 he was well and had had only one fit since his discharge from hospital.

Case 13

R. T. a male aged 12 was admitted to the London Hospital on 8.6.49.

Three years before he had a sudden onset of headache and neck rigidity lasting for two days. Three months ago he had an attack of intense headache and vomiting and was admitted to Worthing Hospital where lumbar puncture revealed blood in the C.S.F. There were no present symptoms. A naevus had been removed from his skull at birth.

On examination there was slight distension of the fundal vessels. Physical examination was otherwise negative.

Skull radiographs were normal. Left carotid angiography outlined a small arteriovenous malformation visible only in the antero-posterior view, in the left frontal region. He was unconscious for some hours after angiography and on awakening was found to have a complete right-sided hemiplegia and aphasia. He made a gradual recovery, but on 21.7.49 he had a further haemorrhage, became unconscious and died within an hour.

An autopsy there was extensive bleeding over the surface of the brain which came from a massive haemorrhage

in the frontal lobe. After fixation of the brain a small arteriovenous malformation was identified near the frontal pole inferiorly. Areas of infarction and two cavities were present in the white matter of the frontal lobe. Histo-pathological examination showed the characteristic features of an arteriovenous malformation.

Case 14

D. H. a female aged 36 was admitted to the London Hospital on 22.6.49.

Three months before during a menstrual period, she had a feeling of giddiness and shortly afterwards felt her left arm become numb and movements clumsy. She has had three similar attacks and in one of these was unconscious. She had been subject to severe headaches during menstruation. Her general health has otherwise been good.

Her mother and one brother suffer from migraine.

Physical examination was negative.

Skull radiographs were normal. Right carotid angiography demonstrated a small collection of abnormal vessels in the antero-posterior arteriogram, which were seen immediately above the first part of the middle cerebral artery and although probably frontal in position, they could not be identified in the lateral view to provide a precise localisation. Arteriovenous malformation was considered to be the most likely diagnosis.

No active treatment was advised. At her last attendance on 8.6.51 she had continued to have headaches associated with giddiness and general malaise. There had been no further fits.

Case 15

M. S. a female aged 16 was admitted to the London Hospital on 25.10.51.

Five years before she had a severe headache which lasted for three weeks and was followed shortly afterwards by another attack for which she was admitted to Brentwood and District Hospital, where the diagnosis of subarachnoid haemorrhage was confirmed by the finding of blood in the C.S.F. She had a further attack two weeks before her present admission.

On examination there was an equivocal left plantar response. Physical examination was otherwise negative.

Skull X-rays were normal. Cerebral angiography showed a mid-line arteriovenous malformation extending more to the left than the right side.

Operation was carried out on 9.2.49 and the lesion was successfully excised. The malformation was situated in the corpus callosum and attached across the body of the ventricle to the floor on the left side; it measured three centimetres in length. Haemorrhage into the ventricle was organising to form a coarctation. Histo-pathological examination confirmed the diagnosis of a

typical arteriovenous malformation.

She made a good recovery and on 5.9.52 was back at work. There was no difficulty with memory or concentration, but she made errors with simple arithmetic.

Case 16

E. P. a male aged 47 was admitted to the London Hospital on 24.4.51.

He complained of epileptic attacks and migraine from the age of 16. The latter occurred at weekly intervals and was characterised by flashes of light on the left side of his field of vision and paraesthesiae in his left arm and leg. These attacks gradually became less frequent and he has had complete freedom from them for six months, but they have been replaced by severe headaches unassociated with visual phenomena and by attacks of petit mal two or three times every week.

On examination he had nystagmus on looking to either side. He was deaf in his left ear. The left plantar response was equivocal. Physical examination was otherwise negative.

The C.S.F. contained 80mgms. protein per 100cc.

Skull radiographs were negative. Cerebral angiography showed a small arteriovenous malformation in the right occipital region.

No active treatment was advised and he was discharged from hospital on 12.5.51. On his last attendance he had continued to have several minor attacks.

Case 17

J. B. a female aged 16 years was admitted to the London Hospital on 24.11.50.

Eight years before she awoke one morning with a severe headache and shortly afterwards became unconscious. She remained so until the following day when she was found to be aphasic and to have a right-sided hemiplegia. She was treated in Addenbrooke's Hospital, where the diagnosis of subarachnoid haemorrhage was made. The aphasia cleared up in two weeks, but the weakness of her right arm and leg has persisted.

On examination there was evidence of a right-sided spastic hemiplegia. There were no other abnormal physical signs.

Skull radiographs were normal. Cerebral angiography demonstrated a moderate sized arteriovenous malformation in the left parietal region, in the territory of the anterior cerebral artery.

No active treatment was advised and she was discharged from hospital on 3.12.50.

Case 18

A. D. a male aged 27 was admitted to the London Hospital on 19.8.48.

Sixteen years ago he began to have migrainous attacks. These attacks persisted unchanged for five years when they became more frequent and he started having fits, about two or three a year, preceded by a right-sided visual aura of coloured lights. Eight years ago he was admitted to the Mile End Hospital where a diagnosis of subarachnoid haemorrhage was made. Three years ago he had a further attack of haemorrhage and was in Chase Farm Hospital where a left occipital arterio-venous malformation was diagnosed and X-ray therapy instituted. The fits became less frequent following this but the visual disturbances were now almost continuous. He also complained of inability to see objects on the right half of his field of vision.

On examination he was found to have a right homonymous hemianopia. There was a slight defect of two-point discrimination in the right thumb. There was no audible cephalic bruit though this finding had been recorded at a previous admission.

Skull radiographs were normal. Cerebral angiography outlined a large arteriovenous malformation in the left occipital region.

He was given a further course of X-ray therapy with no obvious benefit. He last attended on 24.10.52 when he complained of mild headaches and persistence of the visual hallucinations.

Case 19

V. W. a female aged 39 was admitted to the London Hospital on 22.4.48.

Three years ago she suddenly lost consciousness and was admitted to Chase Farm Hospital where a diagnosis of subarachnoid haemorrhage was established by the finding of blood in the C.S.F. She made a good recovery and was well until six months ago, when she noticed that her left pupil was larger than the right.

On examination the left pupil was almost fully dilated and reacted sluggishly to light and accommodation. There was no ptosis. The volume of pulsation of the left carotid artery was greater than the right.

Skull X-rays were negative. Cerebral angiography demonstrated a small arteriovenous malformation deep in the left frontal region and leading from it an enlarged and tortuous vein pursued an abnormal course to the base of the skull on the opposite side.

No active treatment was advised. She last attended on 17.10.52, when there was no change in her condition.

Case 20

R.W. a female aged 37 was admitted to the London Hospital on 18.9.50.

Seven years ago, about once a month, she began having attacks of numbness starting in her right arm and spreading upwards to involve the right side of her face and tongue. There were two generalised convulsions recently. She was involved in a car accident, when she was 17 years of age, and was unconscious for about half an hour.

On examination the volume of pulsation of the left carotid artery was increased. Fine nystagmus was present on looking to the left. There was a mild hemiparesis on the right side, not associated with sensory loss.

Skull radiographs showed a group of calcified opacities in the left temporo-parietal region with a sickle-shaped opacity above and anterior to these. Cerebral angiography demonstrated a large arteriovenous malformation in the left fronto-parietal region, the posterior part of which had formed an aneurysmal sac.

No active treatment was advised. She last attended on 13.1.53, when she had continued to have fairly frequent attacks. On examination there was some blurring of the edges of her optic discs but no other change in her condition.

Case 21

M.B. a female aged 16 was admitted to the London Hospital on 16.9.51.

Three weeks ago she awoke one morning to find the left side of her body paralysed and about twenty minutes later became unconscious. She was admitted to Whipp's Cross Hospital, where it was noted that she had conjugate deviation of her eyes to the right side, neck rigidity and a left-sided hemiplegia. The C.S.F. was blood stained.

On examination she was found to be well-orientated. The optic discs showed a swelling of two dioptries. There was a left-sided hemiparesis associated with some loss of sensation of a cortical type in the left hand and foot.

Skull radiographs were normal. Cerebral angiography outlined a small arteriovenous malformation near the posterior end of the right lateral fissure, which was associated with dislocation of the adjacent branches of the middle cerebral artery and of the anterior cerebral artery to the opposite side.

The lesion was successfully excised on 25.9.51 and an haematoma the size of a tangerine evacuated from the affected hemisphere.

She was discharged from hospital on 4.1.52 when she was found to have gross postural loss and severe loss of tactile localisation in the left upper limb; power in the lower limb was fair but dorsiflexion of the foot was absent.

Case 22

O.H. a female aged 34 was admitted to the London Hospital on 18.1.49.

From the age of 12 she has had attacks of numbness in her right arm, which lasted about five minutes and were followed by headaches of a migrainous type. Dysphasia was also a feature of the attacks. At first the attacks occurred about every six weeks, but recently they have been less frequent and there have only been two in the last three years. Three months ago she had an epileptic fit the day before the onset of her menstrual period, which was generalised and associated with loss of consciousness.

On examination a bruit was audible on auscultation of the skull in both temporal and parietal regions. The volume of pulsation of the left carotid artery was greater than the right. Physical examination was otherwise negative.

Skull radiographs were normal. Cerebral angiography showed a large arteriovenous malformation in the left posterior parietal region.

In view of the quiescence of the lesion, no active treatment was advised. On her last attendance on 10.9.42 there was no deterioration in her condition.

Case 23

A.S. a male aged 17 was admitted to the London Hospital on 28.2.51.

Four months ago he injured his head in a bicycle accident. There was no loss of consciousness, but he had severe headaches and nausea for 24 hours. A week or two later he began having headaches, which have gradually increased in frequency and severity until on 21.2.51 he was admitted to the East Suffolk and Ipswich Hospital. There the skull was trephined, but there was no evidence of extra or subdural blood clot. He was transferred to the London Hospital.

On examination the left corneal reflex was found to be diminished. Neck rigidity was present. There was a left sided hemiplegia associated with some analgesia over the left side of the body.

Operation was carried out and an haematoma evacuated from the right temporal lobe. At operation it was noted that two abnormal veins carried red blood, thus indicating an arteriovenous fistula - no attempt was made to explore the lesion until cerebral angiography had revealed its full extent.

A bruit was audible in the right temporal region following craniotomy. A second operation was performed on 28.2.51 and the lesion which was situated in the right lateral fissure was successfully excised. He made a good recovery and on 22.6.51 the only abnormality noted was a left inferior quadrantic field defect.

Case 24

F.H. a male aged 35 was admitted to the London Hospital on 17.9.51.

Twelve years before he began having attacks of numbness in the left arm which were occasionally associated with epigastric discomfort. These attacks disappeared completely during 1941-45 when he was in the Army, but they returned again five years ago. Recently he has had a generalised convulsion, which was preceded by clonic movements of the left upper limb and since then the attacks have been more frequent.

On examination, bruits were audible over the carotid arteries, but not over the skull. There was some weakness of the left arm particularly at the wrist and there was an intention tremor. The deep reflexes were increased on the left side.

Skull radiographs were normal. Cerebral angiography demonstrated an arteriovenous malformation in the right parietal region.

No active treatment was advised. He last attended on 30.1.53, when he had continued to have occasional attacks.

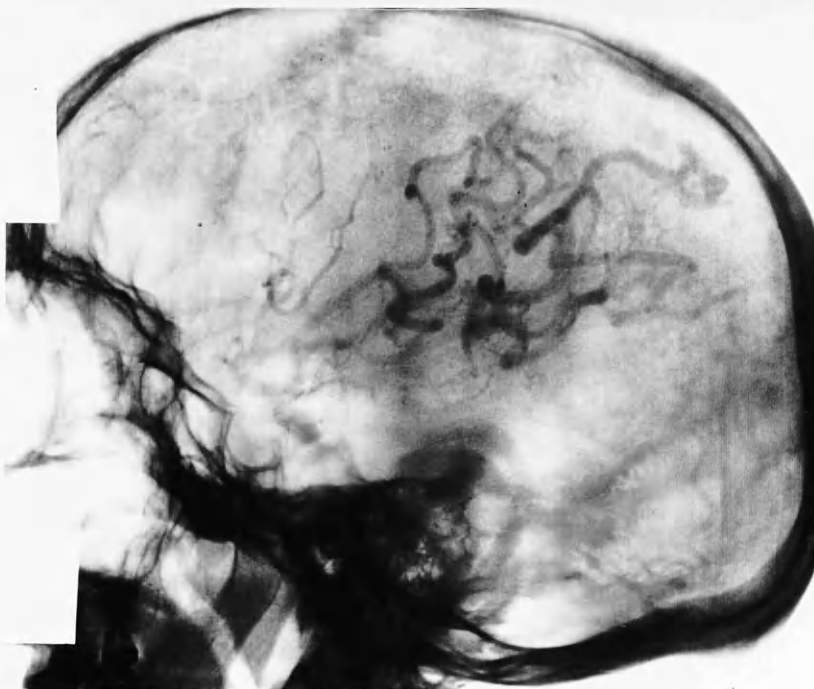


Fig. 28a Case 24
Rt. parietal arteriovenous malformation showing great tortuosity of the feeding arteries and absent filling of the anterior cerebral artery.

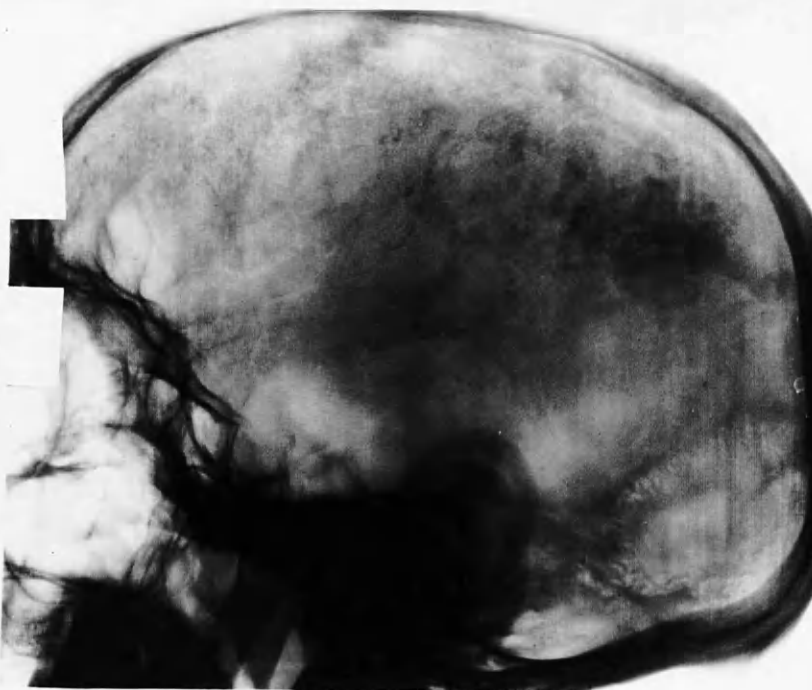

Fig. 28b Case 24
A later phase than (a) above. The contrast medium is contained within the arteriovenous part of the lesion.

Case 25

D.B. a male aged 10 was admitted to the London Hospital on 20.4.49.

Two months ago he had a sudden onset of headache and vomiting and was admitted to the Tunbridge Wells and District Hospital where a diagnosis of subarachnoid haemorrhage was made. He made a good recovery and is at present symptom free.

On examination carotid pulsation was considered to be more forceful on the right than the left side. Physical examination was otherwise negative. He is left-handed.

Skull X-rays showed prominent meningeal sinus grooves which were equal on both sides and within the limits of normal. Cerebral angiography demonstrated a small arteriovenous malformation in the left frontal region supplied by a branch of the middle cerebral artery.

On 16.5.49 the lesion which was situated in the middle of the left inferior frontal convolution was successfully excised.

A slit-like cavity due to haemorrhage communicated with the lateral ventricle. The post-operative course was characterised by a transient attack of aphasia but was otherwise uneventful.

He last attended on 14.7.50, when he was well and there were no abnormal physical signs.

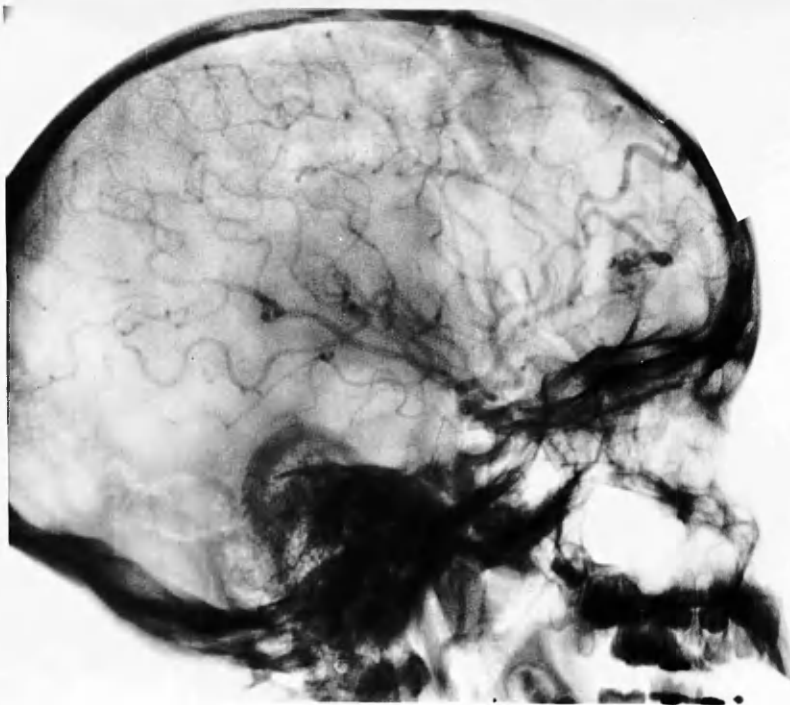


Fig. 29a Case 25
Small left frontal arteriovenous malformation with
vein leading to superior longitudinal sinus.

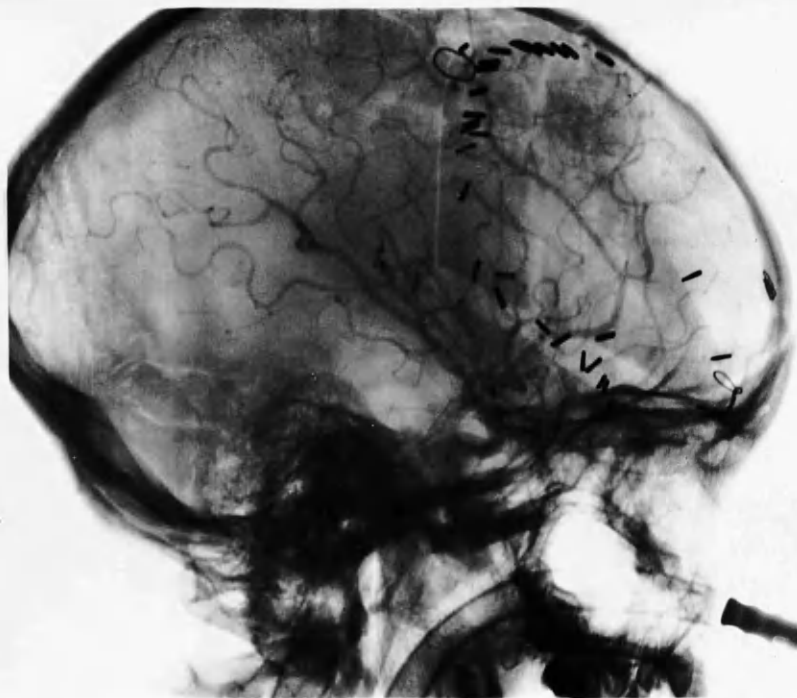


Fig. 29b Case 25
Successful excision of the lesion.

Case 26

A.S. a male aged 19 was admitted to the London Hospital on 2.6.50.

He had been quite well until the morning of admission, when he developed an aching pain in his right eye and felt faint. He stopped work to rest and then noticed that his left leg was weak. He did not lose consciousness.

On examination there was slight weakness on the left arm and marked weakness of the leg, tone was increased in the lower limb and the deep reflexes were exaggerated. The plantar response was extensor. There was complete loss of postural sensation and a relative loss to pin-prick on the left side of the body. Lumbar puncture showed a blood-stained C.S.F.

Skull radiographs were normal. Cerebral angiography demonstrated a small arteriovenous malformation in the right parietal region.

Operation was performed on 29.6.50 and the malformation which was situated in the medial wall of a cystic cavity filled with blood clot, was successfully excised.

The cavity lay close to the mid-line and extended about ten centimetres in an anteroposterior direction.

His post-operative course was uneventful and he was discharged from hospital on 21.7.50. He last attended on 9.2.51 when his only complaint was of occasional mild headache.

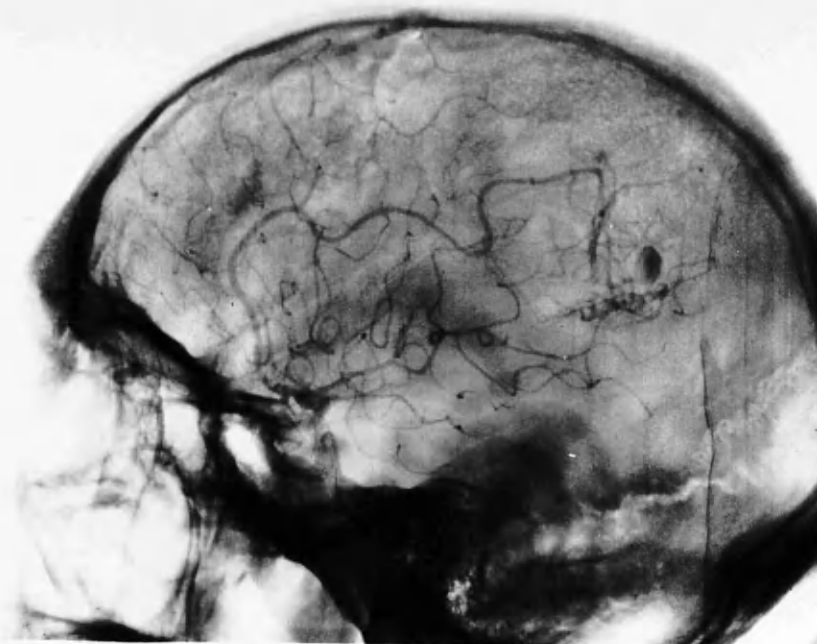


Fig. 30a Case 26
Rt. lateral view. Small parietal arteriovenous malformation
with a tortuous and dilated anterior cerebral artery leading
to it.

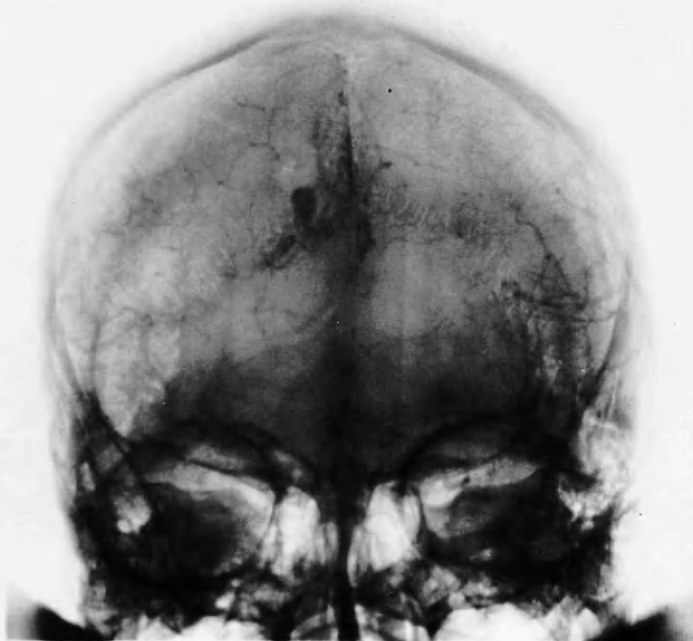


Fig 30b Case 26
A.P. view of (a) above.

Case 27

D.B. a male aged 13 was admitted to the London Hospital on 6.12.49.

Six months before he suddenly developed a severe headache and became unconscious. He was admitted to the Ipswich Borough General Hospital where the diagnosis of subarachnoid haemorrhage was made. When he regained consciousness he was found to have some dysphasia and also difficulty in using his right hand, but he made a good recovery and was back at school in three months.

On examination speech was found to be normal. The left pupil was larger than the right but reacted normally. There was some increase of tone and of the deep reflexes on the right side of the body and also a mild dysmetria and intention tremor.

Skull radiographs were normal. Cerebral angiography demonstrated a small arteriovenous malformation in the left parietal region.

Operation was carried out on 4.1.50 and the lesion which was situated in the superior and medial wall of a cyst which communicated with the lateral ventricle was excised.

His post-operative course was characterised by a motor aphasia and some spastic weakness on the right side. On 28.7.50 his speech was only slightly hesitant, there was some loss of sensation of a cortical type in the right arm; power and sensation in the lower limb were normal.

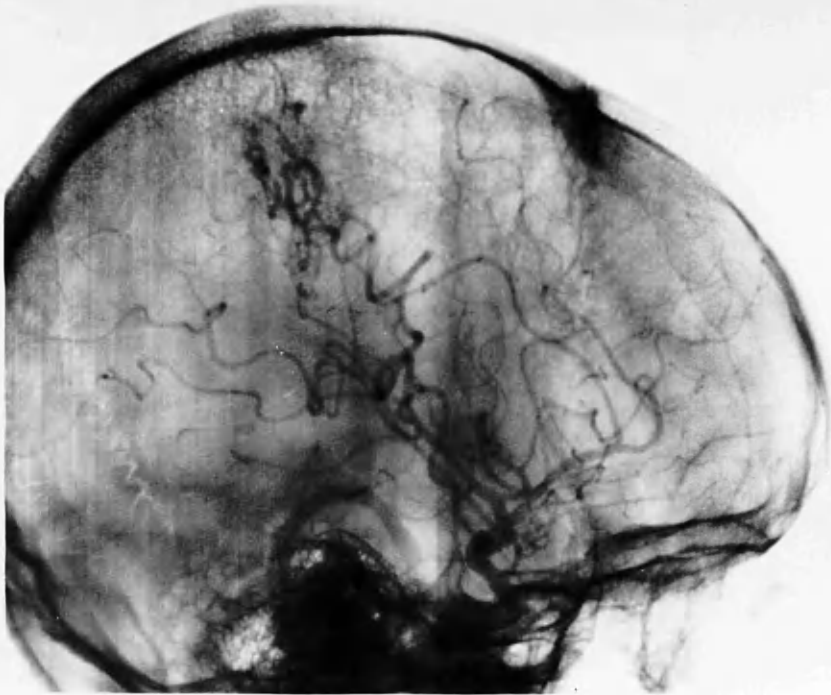


Fig. 31a Case 27
Small parietal arteriovenous malformation. The feeding
arteries come from both the anterior and middle cerebral arteries.

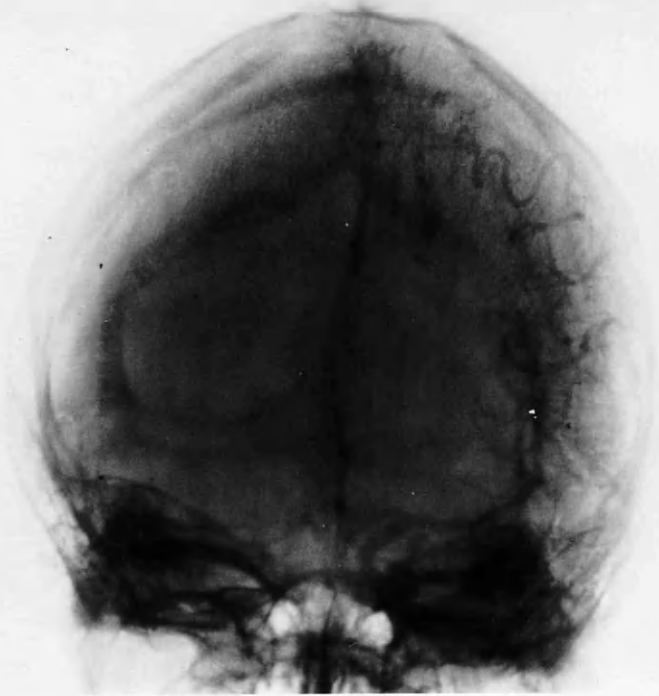


Fig. 31b Case 27
A.P. view of (a) above.

Case 28

E.H. a male aged 39 was admitted to the London Hospital on 9.5.48.

Nine years before he suddenly lost consciousness and on awakening he had a severe headache which lasted two days. He then began having headaches of a migrainous type, at first at weekly intervals, but later only a few per year. He also complained of giddiness and tinnitus in the right ear and recently he had become anxious and depressed and found it difficult to concentrate. He had a head injury in 1943 but did not remember any details.

Physical examination was negative and he was discharged from hospital on 30.5.48.

There was no change in his condition until September 1950, when he had a generalised convulsion and subsequently began having attacks of involuntary flexion in his right arm and numbness in his right arm and leg. He attended the Aural Department for an opinion regarding his tinnitus, but this was considered to be functional in origin, despite the fact that he himself has found that he can control it by pressure over the carotid artery. Intelligence tests showed evidence of intellectual deterioration.

Cerebral angiography was carried out on 8.11.50 and a large arteriovenous malformation was demonstrated in the left lateral fissure. No active treatment was advised. On his last attendance on 28.1.53 there was no change in his general condition.

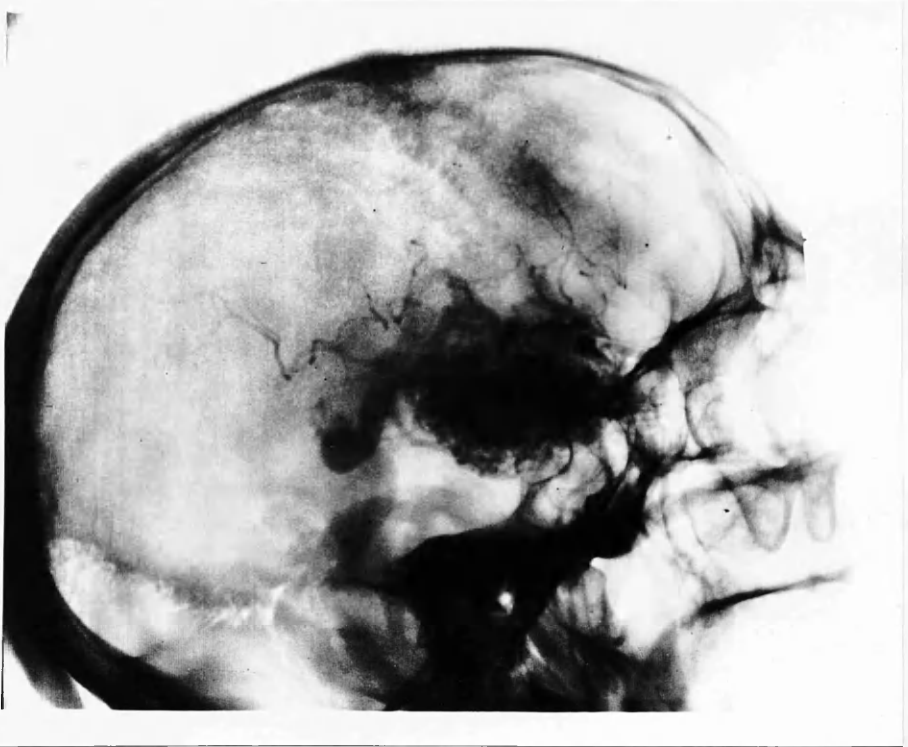

Fig. 32 Case 28
Large arteriovenous malformation in the left lateral fissure.

Case 29

M.B. a male aged 29 was admitted to the London Hospital on 29.11.48.

For three years he had suffered from occasional frontal headaches. Three weeks before following a very severe headache he became blind on the right side of his visual field. There was no loss of consciousness. On direct questioning, he recalled slight difficulty in finding the names of people. He has had two minor head injuries, the last one three years ago was associated with vomiting and vertigo for a week.

He is right-handed. On examination there was a right homonymous hemianopia. Physical examination was otherwise negative. The protein content of the C.S.F. was raised to 80mgms. per 100cc.

Skull radiographs were normal. Cerebral angiography outlined a large arteriovenous malformation in the left temporal region.

No active treatment was advised. On his last attendance on 16.11.52, he had had a generalised convulsion; there was no other change in his condition.

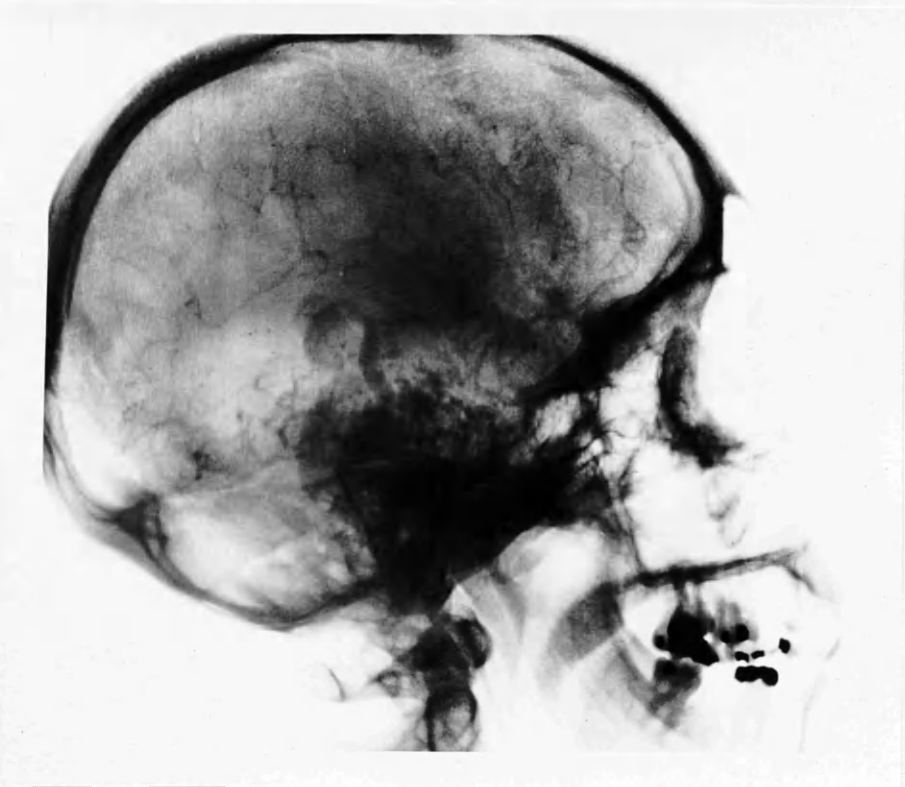


Fig. 33 Case 29
Left temporal arteriovenous malformation.

Case 30

E.M. a male aged 28 was admitted to the London Hospital on 20.8.49.

Eleven years ago he had a very severe headache which lasted for a week. He made a full recovery, but four years later there was a similar attack. There have been two further attacks, the last one two months ago, when he was unconscious for nine hours and was admitted to St. George's in the East Hospital where a diagnosis of subarachnoid haemorrhage was established by the finding of blood in the C.S.F.

On examination the left disc showed evidence of primary optic atrophy. Physical examination was otherwise negative.

Skull radiographs were normal. Cerebral angiography demonstrated an arteriovenous malformation in the left temporo-parietal region.

He was discharged symptom free on 31.8.49 and attended as an out-patient for a course of X-ray therapy. On his last attendance on 4.4.52 he looked and felt well.

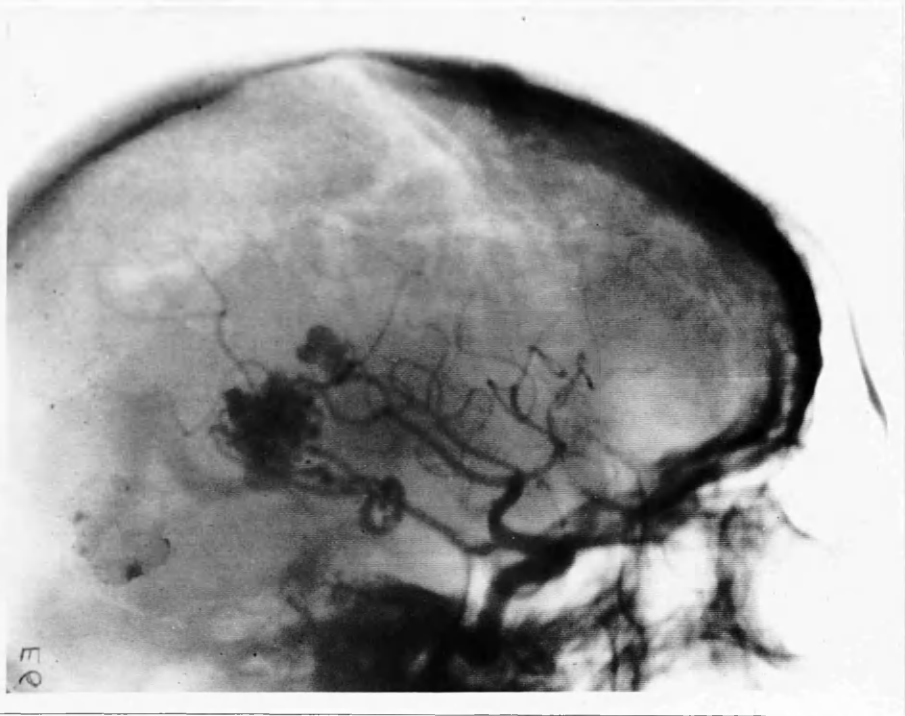


Fig. 34 Case 30
Arteriovenous malformation which appears to consist
of two comparatively discrete lesions.
The larger part is supplied by a much enlarged
posterior cerebral artery.

Case 31

A.J. a female aged 37 was admitted to Chase Farm Hospital on 13.5.46.

Eight months before following a bout of crying the right eye became blue, swollen and painful and she developed an occipital headache which has persisted to the present time. Her only other complaint was dyspnoea on exertion.

On examination the supratrochlear and supraorbital arteries were prominent and there was varicosity of the right frontal veins. A high pitched bruit was audible in the right frontal region. A marked degree of proptosis of the right eye was present. There was increased tortuosity of the arteries and fullness of the veins of the optic fundus. In addition there was evidence of mitral stenosis, aortic incompetence and auricular fibrillation.

Skull radiographs were normal. Cerebral angiography demonstrated a large arteriovenous malformation in the right temporal region.

The right common carotid artery was ligated on 13.8.46 and the internal carotid ten days later. She was well until January 1948, when the headache started again,

the proptosis had increased and she had nose-bleeds every ten to fourteen days. At a further operation an attempt was made to place a silver clip on the supraclinoid portion of the internal carotid artery, but she did not regain consciousness. Necropsy confirmed the presence of an arteriovenous malformation in the right temporal region.

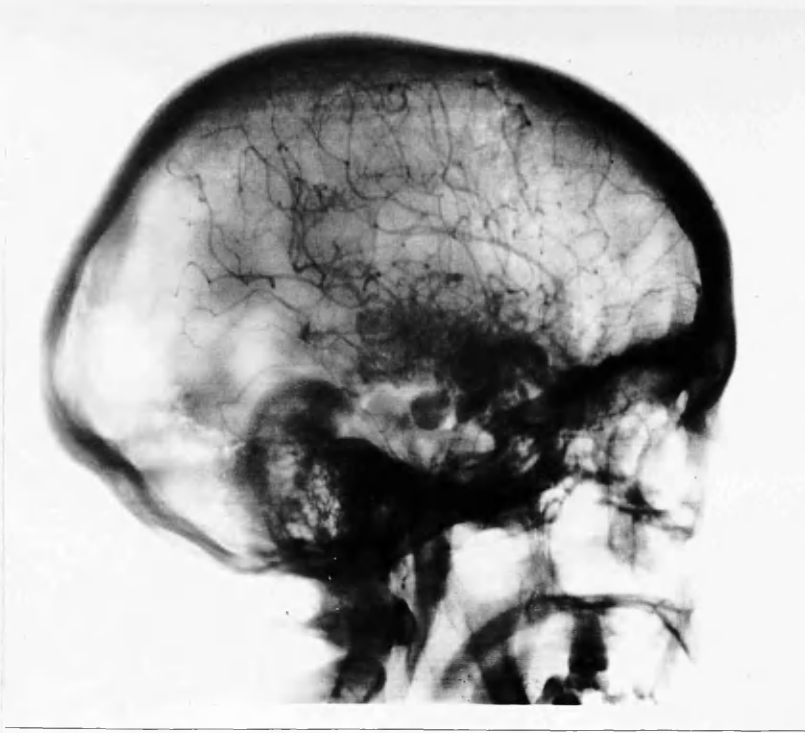

Fig. 35a Case 31

Arteriovenous malformation in the Rt. lateral fissure.

An aneurysmal dilatation extends from it postero- inferiorly.

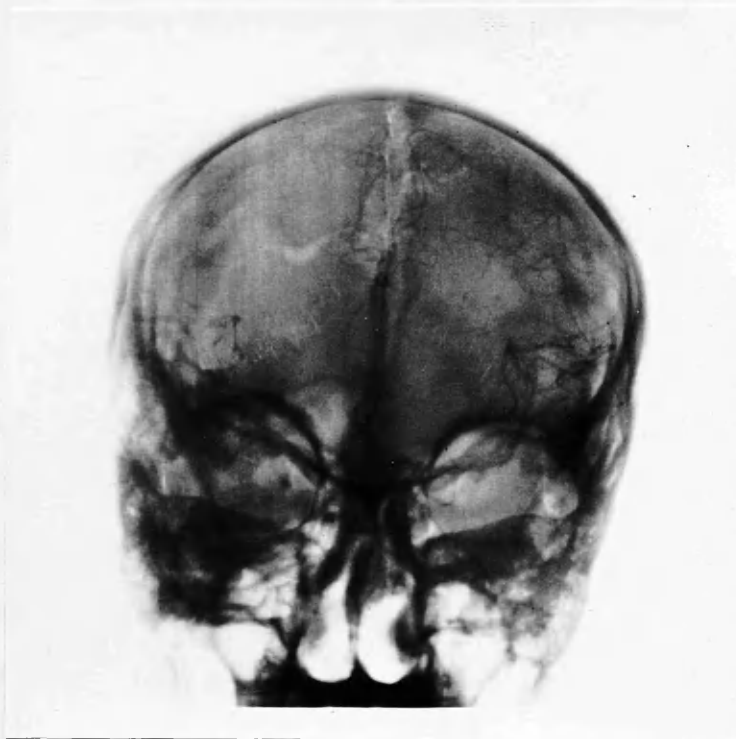

Fig. 35b Case 31

A.P. view. Compression of the contralateral carotid artery

has been employed so that both anterior cerebral arteries

and the middle cerebral artery of the opposite side are filled.

Case 32

P.P. a female aged 17 was admitted to the London Hospital on 31.12.50.

She complained of occasional bifrontal headaches for the past eight months. Three months ago there was a sudden onset of severe headache, vomiting and loss of consciousness. She was admitted to the East Suffolk and Ipswich Hospital where subarachnoid haemorrhage was diagnosed. She made a good recovery and was symptom free on discharge from hospital five weeks later.

On examination there was some increase of the deep reflexes on the left side, but no other abnormal physical signs.

X-ray examination of the skull was negative. Cerebral angiography demonstrated a moderate sized arteriovenous malformation in the right temporal region.

No active treatment was advised and she was discharged from hospital on 7.1.51. Her condition remained unchanged until 23.12.52 when she was re-admitted to the London Hospital because of a further haemorrhage. Angiography was repeated but there was no change in the appearance of the malformation. Operation was carried out on 14.1.53 and the malformation which lay deep to the superior temporal convolution was excised. The feeding vessels came from

the middle cerebral artery. A vein led from the posterior part of the lesion into the lateral ventricle and eventually joined the internal cerebral vein and another abnormal vein coursed the surface of the hemisphere from the Sylvian vein to the tip of the temporal lobe before turning onto the under-surface of the temporal lobe to reach the transverse sinus. There were two cavities in the brain, a large one containing yellow fluid, lateral to the lesion and one due to fresh haemorrhage deep to the posterior end of the malformation.

She made a good recovery from the operation. On 3.2.53 angiography was carried out and showed a small collection of angiomatous vessels at the site of the original lesion, supplied by the posterior cerebral artery.

On examination prior to her discharge from hospital on 7.2.53, she had a partial left homonymous hemianopia. There was some increase of the tendon jerks in the left upper limb and some weakness of dorsi-flexion of the wrist. Minimal dysmetria and ataxia were present. The lower limb showed slight weakness and some increase of tone.

The patient died in October 1953, in Ipswich. The brain was obtained for section and showed the cause of death to be due to intracerebral haemorrhage arising from the small residual portion of the malformation. No additional details are as yet available.

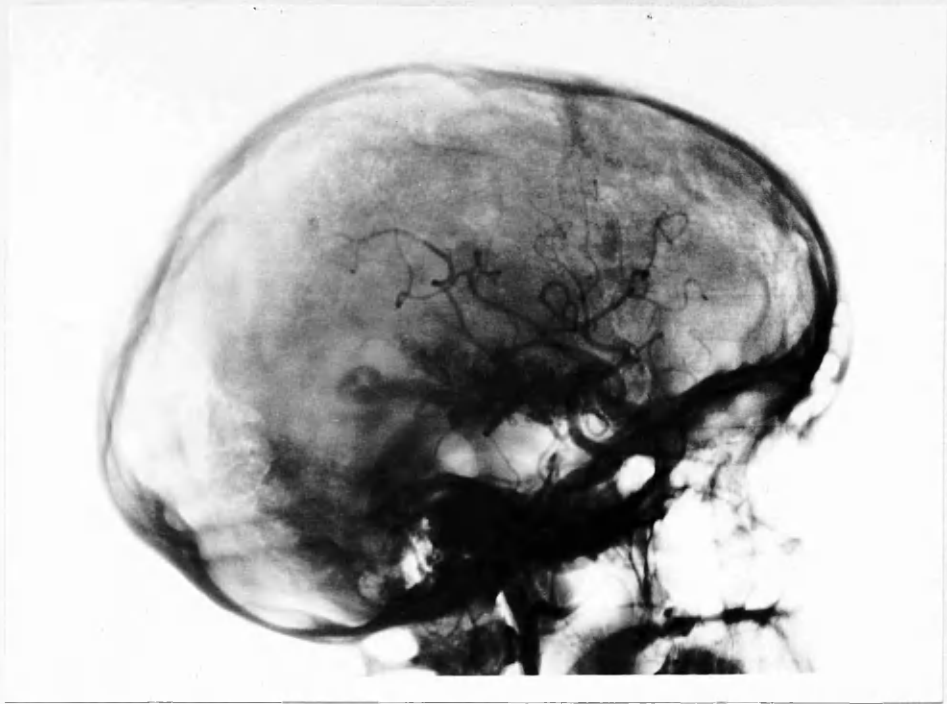


Fig. 36a Case 32
Arteriovenous malformation in the Rt. Temporal region.
Absent filling of the anterior cerebral artery.
A vein extends posteriorly from the lesion.

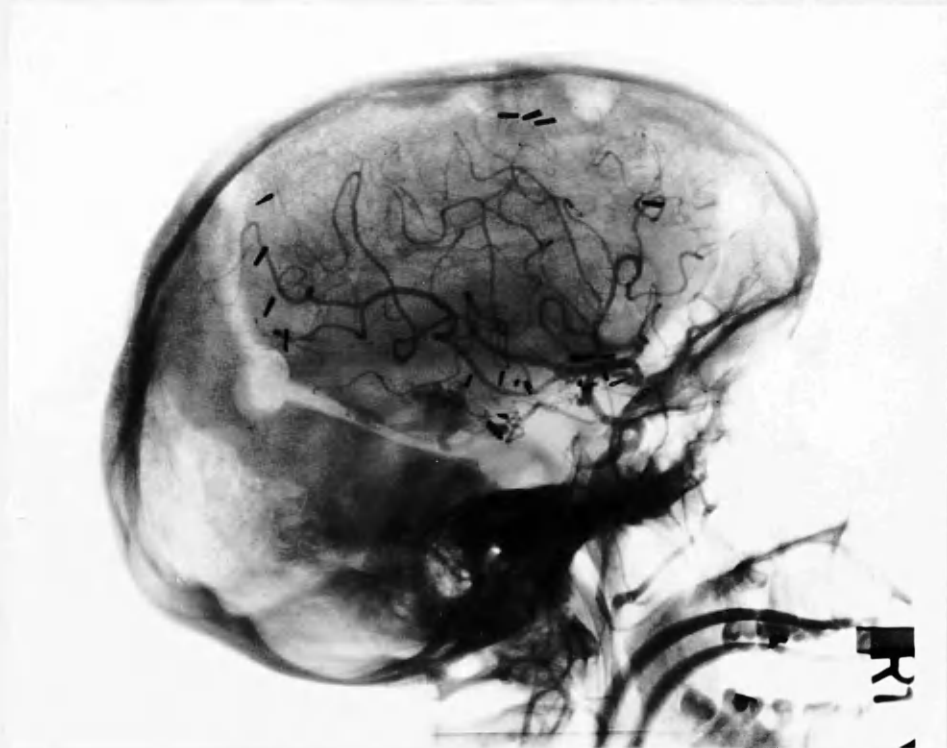


Fig. 36b Case 32
After excision of the main part of the malformation,
there is still a small residual portion supplied by
the posterior cerebral artery.