

Histological Studies of the Gastric Mucosa in
Peptic Ulceration and Gastric Carcinoma, and
Analysis of Post-Mortem Records in Relation to
Peptic Ulceration.

T H E S I S

submitted for the Degree of M.D.

at Glasgow University

by

Henry Thompson, M.B., Ch.B. 1945

September, 1953.

ProQuest Number: 13838665

All rights reserved

INFORMATION TO ALL USERS

The quality of this reproduction is dependent upon the quality of the copy submitted.

In the unlikely event that the author did not send a complete manuscript and there are missing pages, these will be noted. Also, if material had to be removed, a note will indicate the deletion.



ProQuest 13838665

Published by ProQuest LLC (2019). Copyright of the Dissertation is held by the Author.

All rights reserved.

This work is protected against unauthorized copying under Title 17, United States Code
Microform Edition © ProQuest LLC.

ProQuest LLC.
789 East Eisenhower Parkway
P.O. Box 1346
Ann Arbor, MI 48106 – 1346

Book I

Part 1. Study of the changes in the mucous membrane of the stomach in peptic ulcer and gastric carcinoma.

Part 2. Investigation into the post-mortem incidence of peptic ulcers and erosions.

Book II. Microphotographs.

C o n t e n t s

	<u>Page</u>
<u>PART 1.</u>	
Introduction	2
Material	4
Methods	6
Results	9
I Gastritis	11
1. Acute	13
2. Subacute	18
3. Chronic	19
4. Chronic atrophic diffuse	25
5. Duodenitis	27
II Erosions	28
III Intestinal Metaplasia	31
IV Miscellaneous Findings	34
Discussion	38
Gastritis	39
État Mammellonné	49
Erosions	51
Intestinal Metaplasia	57
Summary	61
References	62

PART 2.

Introduction	69
Material	71
Results				
A. Peptic ulceration in adult population				72
B. Peptic ulceration in the population under Age 10	79
C. Erosions	79
Discussion	81
Summary	84
Acknowledgments	85
References	86.

Part 1.

Study of the changes in the mucous
membrane of the stomach in peptic ulcer
and gastric carcinoma.

Introduction.

Histological examination of specimens obtained at partial gastrectomy for peptic ulceration and gastric carcinoma was made in search of lesions which might be concerned in their pathogenesis. It was soon realised that such material contained sufficient pyloric mucosa for the purpose of the investigation but provided an inadequate amount of the body mucosa for study on a comparable scale. The scope of the investigation was therefore widened to include an additional number of biopsies of the body mucosa taken at the operations of partial gastrectomy and gastroenterostomy.

A survey of the relevant literature showed that there was widespread disagreement regarding not only the findings in an investigation of this nature but also in their interpretation. Histological workers (Konjetzny (1923, 1928), Faber (1935) and Magnus (1946)) have advanced claims that gastritis is invariably present in peptic ulcer cases and have suggested that the erosions associated with it may develop into acute and chronic peptic ulcers. Gastroscopists (Schindler (1926, 1950), Moutier (1935) etc.) as a result of their studies on the living gastric mucosa have, however, been unable to confirm these claims. Experimental workers (Schindler, Nechelles and Gold (1939) and

Sanders and Mecray (1941)) have questioned, moreover, the presence of an "erosive" gastritis in the partial gastrectomy specimens before resection. They maintain that the lesions found are produced by corrosive action of the acid gastric contents during the period of interrupted blood supply in the course of the operation together with autolysis before fixation.

Konjetzny and Faber further claimed that gastritis was invariably present in cases of gastric carcinoma and was a precancerous condition. Magnus was unable to confirm the latter claim histologically, but gastroscopists such as Schindler etc. support Konjetzny's and Faber's views as a result of their own observations.

During this investigation attention was focussed on the incidence and appearances of gastritis occurring in the material but a careful search was made for other lesions which might be of importance.

The post-mortem incidence of peptic ulceration and erosions was determined while the histological investigation was in progress. The results obtained over a sufficiently large series were considered to be of significance and are included in the present thesis.

Material

A. Partial Gastrectomy Specimens.

The basic material consisted of 68 specimens obtained at partial gastrectomy performed for peptic ulceration or gastric carcinoma. These specimens were collected during a period of $2\frac{1}{2}$ years from several hospitals and all were received in the laboratory within 1 hour of operation. The specimens varied in size and shape but all were at least 5" in length.

Analysis of the specimens and the relevant case histories gave the following information:

Site and nature of the lesion

Gastric ulcer or scar	20
Duodenal - - -	23
Both gastric and duodenal ulcer or scar	6
Jejunal ulcer and duodenal scar	<u>1</u>
Specimens with peptic ulceration	50
- - - gastric carcinoma	17
- - - ulcer cancer	<u>1</u>
	<u>68</u>

Sex composition of the series

	<u>Male</u>	<u>Female</u>
Peptic ulcer	40	10
Gastric carcinoma	10	7
Ulcer cancer	1	0

Age composition of the series.

<u>Age group</u>	<u>Peptic ulcer</u>	<u>Gastric carcinoma</u>	<u>Ulcer cancer</u>
20 - 29	3	0	0
30 - 39	10	1	0
40 - 49	19	2	0
50 - 59	13	5	0
60 +	5	9	1

B. Biopsy Specimens.

Since partial gastrectomy specimens consisted mainly of pyloric mucosa and a small portion of the body of the stomach, only a little of the latter could be studied. Additional material obtained at gastro-enterostomy and partial gastrectomy which consisted mainly of mucosa from the body of the stomach was therefore taken into consideration. Sections and paraffin blocks from 63 such specimens collected over a period of 3 years and retained in the routine histological files at Stobhill Hospital were available for study.

Methods

A. Partial Gastrectomy Specimens.

The specimens were opened along the greater curvature and examined for the presence and exact situation of ulcers, scars, tumours, erosions and other abnormalities. After examination the specimens were fixed in formol-saline for 24 - 48 hours.

From each specimen 10 - 15 portions of tissue were taken representative of the body, the lesser curvature, the greater curvature, the pyloric region, the pyloro-duodenal junction and the duodenum when present. In a few cases 20 - 30 portions were taken in search of erosions and intestinal metaplasia. The tissues were fixed in formol-saline and then in formol-corrosive, dehydrated in spirit and alcohol, cleared in chloroform and embedded in paraffin.

On account of the different consistencies of the various layers of the stomach wall, 4% phenol in water and in the lower alcohols (Lendrum, 1935) was used to soften the harder layers of the stomach wall, thus facilitating section-cutting without disturbing the architecture, histological appearances or staining characteristics.

The stains employed in this investigation were as follows:-

Haemalum and eosin : standard stain showing nuclei and cytoplasm.

Van Gieson's stain : to show extent and distribution of fibrosis.

Heidenhain's iron alum haematoxylin : to show nuclear structure.

Mucicarmine : for mucin and also to differentiate types of mucin.

Mallory's phosphotungstic acid haematoxylin : for Paneth cells and pepsinogen granules.

Jacobson's stain : for argentaffine cells.

Gram's stain : for fibrin.

Weigert and carmalum : for elastic tissue.

Mallory's connective tissue stain : in ulcer cancer.

In the first ten specimens sections from each block were stained with all the special staining methods, but thereafter these stains were employed only where indicated. One section from each block was stained with haemalum and eosin. Serial sections to elucidate various points in the investigation were similarly stained.

B. Biopsy Specimens.

The blocks from the biopsy material had been treated in the same way as the specimens forming the main part of the series apart from the use of 4% phenol in water and the lower alcohols. Sections from the biopsies were as a rule stained only with haemalum and eosin.

Results.

Macroscopic examination of the specimens was found to be of limited value. Gross lesions only, viz. open ulcers, scars, tumours, état mammellonné and occasionally erosions, could be identified with certainty. As will be shown later, most of the erosions found in the series were microscopic in size and only a few could be distinguished naked eye. Signs used in the gastroscopic diagnosis of gastritis, viz. patchy reddening, oedema and adherent mucus, proved unsatisfactory as guides to the underlying histological changes in the resected specimens.

Microscopical examination revealed the occurrence of three main abnormalities whose histological features could be clearly defined apart from the condition for which operation had been performed. These were respectively, gastritis, erosions and intestinal metaplasia, and their possible relationship to the development of peptic ulceration and gastric carcinoma necessitated the attention given to them in this investigation.

No other macroscopic or microscopic lesions which might play a part in the development of peptic ulceration and gastric carcinoma were noted in the material examined.

The main findings of this investigation will be described in greater detail under the following headings:-

I Gastritis

II Erosions

III Intestinal Metaplasia

IV Miscellaneous Findings.

was as follows:-

Special Instructions
Continued

Toronto, Ontario, Canada

Division of Health Services

Department of Health and Welfare

I. Gastritis.

Detailed study of the material used in the investigation showed that the most common abnormality was a non-specific inflammation of the gastric mucosa, i.e., a gastritis. This was classified according to the type of inflammation present and its localisation. In view of the restricted types of case from which the material was obtained, specific forms of gastritis such as acute phlegmenous and diphtheritic varieties were not encountered.

The incidence of gastritis in the material examined was as follows:-

	<u>Partial Gastrectomy</u> <u>Specimens</u>	<u>Biopsy</u> <u>Specimens</u>
Acute gastritis	3	2
Subacute gastritis	15	11
Chronic gastritis	46	33
Chronic atrophic diffuse gastritis	4	0
	68	46
Total No. of cases showing gastritis		
Total No. of cases histologically normal	0	17
Total No. of cases examined	68	63

Although the incidence of acute gastritis in the series is low, the changes occurring in it are so important that they demand early consideration. It is, therefore,

convenient to describe the various histological types of gastritis in the same order as they appear in the table above, followed by a brief account of duodenitis as it occurred in the material available.

1. Acute Gastritis

In the present investigation acute gastritis was encountered in the peptic ulcer series only and not in the carcinoma group. Four specimens of the partial gastrectomy series and two of the gastric biopsies showed numerous foci of acute inflammatory reaction with a few comparatively unaffected areas of mucosa between them. The inflammatory changes were less severe and more superficial in the body of the stomach and in two of the four cases in the partial gastrectomy series involvement was limited to the portion of the body mucosa immediately adjacent to the pyloric region. The inflamed areas in both regions showed acute inflammatory exudation, epithelial changes and erosions and these will now be described in turn.

(a) Acute inflammatory exudation.

An acute inflammatory exudate (Figs. 1 - 5) with oedema fluid, numerous polymorphs, a few eosinophils and lymphocytes was present in the interstitial tissue of the mucosa sometimes involving the muscularis mucosa and even the submucosa (Fig.6) in a few cases. This exudate is also seen on the surface of the affected areas (Figs.1, 2) and in the ducts (Fig.7). Isolated foci are found in the body of the stomach and may occur at the base of the mucosa (Fig.6).

The oedema fluid varied in its fibrin content. Congestion of the small vessels with pavementation and diapedesis was present in the mucosa and submucosa. Small focal accumulations of polymorphs like tiny abscesses were occasionally seen (Fig.5).

(b) Epithelial changes.

These affected the surface, duct and gland epithelium in slightly different ways.

The surface epithelial cells were small, cuboidal or syncytial in character. Their cytoplasm was darker than normal and their nuclei were frequently hyperchromatic or showed mitotic figures, while other cell nuclei were indistinct and pale. Some of these surface epithelial changes are shown in Figs.1, 2, 3 and 8, and may be compared with normal surface epithelium seen in Fig.9. Polymorphs and occasional round cells were seen emigrating through the surface epithelium via intercellular vacuoles (Figs. 2 and 3). This process of polymorphonuclear emigration is a marked feature and emphasises the acute inflammatory character of the condition. Numerous polymorphs which have tracked through are seen lying on the surface (Figs.2 and 3). Mitotic figures were specially numerous in the foveolae gastricae, suggesting regeneration from there.

The duct epithelium showed changes similar to the

surface epithelium and mitotic figures were just as numerous, especially at the necks of the ducts, suggesting that regeneration was taking place from these areas.

The gland epithelium showed emigration of polymorphs, occasional desquamation or change to a dark cuboidal epithelium resembling that of the ducts. Occasional glands showed complete disintegration with acute inflammatory exudation around them (Fig.10).

(c) Erosions.

Ivy, Grossman and Bachrach (1950) have suggested that the term erosion should be confined to a breach of the mucosa which does not penetrate the muscularis mucosa. If the muscularis mucosa is penetrated then the lesion becomes a peptic ulcer. This definition has been accepted in the present histological investigation.

Numerous inflammatory erosions at various stages of development were present in the specimens with acute gastritis. The earliest erosions (Figs.1, 11, 12, 13) consisted of a gap in the epithelium with an acute inflammatory exudate of fibrin and leucocytes projecting from the interstitial tissue on to the free surface. This smoke-stack exudate gives the impression of activity and it seems as if the fibrino-leucocytic exudate is streaming out of the interstitial tissues on to the free surface. The epi-

thelium at the edges showed the inflammatory and regenerative changes mentioned in 1(b), but in a few cases these were absent and the epithelium was interrupted abruptly.

A group of these erosions occurring in a case of acute gastritis is seen in Fig.1 and higher magnifications of the lesions (Figs.11, 12 and 13) demonstrate clearly their exudative character. A similar process is shown in Fig.14, although in this case fewer polymorphs were being discharged. These erosions occurred mainly in the surface epithelium at the tips of the gastric processes and in the faveolae gastricae, but were occasionally found affecting duct and gland epithelium (Fig.15). Erosions of this type were encountered also in the duodenum (Fig.16) and over ulcer scars (Fig.17).

Most of these erosions were minute and showed little appreciable loss of substance (Figs.1, 11, 12 and 13). Larger erosions occurred showing a defect in the mucosa due to loss of tissue (Figs.18, 19, 20, 21). In fact, angular portions were occasionally seen at the edge of an erosion as if being undermined and nipped off (Fig.22).

Other erosions were found which did not show a projecting exudate but possessed a floor composed of necrotic fibrinoid material on a base of polymorphs, lymphocytes and plasma cells (Fig.18). These appear to be a later stage

of the erosion described above.

Healing erosions with dark staining epithelium growing over their floor (Figs.19, 20, 21 and 23) were also met with in acute gastritis and some of them showed a recrudescence of inflammation (Fig.21) with the epithelial changes described in 1(b). Regeneration of mucus secreting glands was apparent in a few cases at the edges of the erosions (Fig.19). Fibrosis associated with the healing process was minimal in amount.

Lymph follicles were occasionally noted in the base of erosions (Fig.19) and appeared to be due to the coincident chronic gastritis. Follicular erosions due to abscess formation in lymph follicles with subsequent rupture on to the surface were not found in any of the specimens examined.

2. Subacute Gastritis.

Specimens showing subacute gastritis occurred in both peptic ulcer and carcinoma groups. Altogether fifteen of the partial gastrectomy series and eleven of the biopsy series came under this classification. As in acute gastritis, the pyloric region was more severely affected than the body of the stomach which was involved in only four of the partial gastrectomy series.

The inflammatory changes (inflammatory exudation, epithelial changes and erosions) seen in acute gastritis were found in nearly every case, but were not so pronounced nor so extensive (Figs.6, 15, 18, 21, 24-26). The inflammatory exudate contained a greater preponderance of eosinophils, lymphocytes and plasma cells (Figs.25 and 26) and the epithelial changes were as a rule more of a regenerative and proliferative character with round cell emigration (Fig.25). Marked interstitial oedema (Fig.26) was nearly always present and was specially characteristic of the subacute stage. Proliferation of the duct epithelium was particularly noticeable and the hyperchromatic staining of their nuclei gave the mucosa a bluish appearance.

Chronic Gastritis.

The term chronic gastritis refers to a condition of the mucosa in which epithelial changes, cellular infiltration, fibrosis and other less obvious structural changes were evident. It occurred in all the partial gastrectomy specimens and in most of the biopsy series. The pyloric region was more frequently and more severely affected than the body where the inflammatory changes were mainly superficial, the glands being only slightly involved. More detailed description of the histological changes mentioned above is given below.

(a) Epithelial changes.

These will be described under various headings.

(i) Inflammatory.

These were minimal and represented slight degrees of the changes observed in acute gastritis. Occasional polymorphs and round cells were seen emigrating through surface, duct and gland epithelium and this was usually most marked in the foveolar region where there were numerous mitotic figures indicating active regeneration. Occasional degenerating glands were surrounded by inflammatory cells and a few ducts contained polymorphs.

(ii) Atrophic-hypertrophic changes.

These can be patchy or diffuse and both were frequently present in the same specimen. The surface, duct or gland epithelium can be affected together or separately.

Surface epithelium.

The normal tall columnar mucin-secreting cells were sometimes replaced by cuboidal undifferentiated epithelial cells. Another change occasionally occurs where the mucus-secreting cells become long and tapering with their upper ends embedded in a layer of surface mucus. Depression of the nucleus towards the base in cells filled with mucus was frequently noted. American writers (Schindler and Ort-mayer (1936)) have stressed this as a sign of gastritis, but all available evidence in the present investigation tends to minimise its importance. Hyperplasia of the surface epithelial cells with branching was observed in a few specimens giving the mucosa a hypertrophic appearance (Fig.27). On the other hand, the foveolar cells in some cases showed hyperplasia in a downward direction to replace glands which had undergone atrophy.

Ducts.

Proliferation in a downward direction was seen associated with glandular atrophy (Fig.28) and heterotopia (Fig.27). Proliferative changes also occurred upwards

producing a hypertrophic appearance of the mucosa (Fig.29).

Glands.

Glandular atrophy of varying severity was frequently present and could be almost complete as in Figs.27, 28, 30-32, or slight in degree, Figs.33 and 34. Comparison of these figures with the normal appearance of the pyloric mucosa (Fig.35) emphasises the importance of glandular atrophy in chronic gastritis. Hyperplasia and lobulation of the pyloric glands were also seen (Fig.36) and could cause alone or in association with the duct and surface epithelial proliferation hypertrophic appearances of the mucosa (Fig.37). Atrophy and hyperplasia were frequently present in different parts of the same specimen.

(iii) Heterotopia.

Glands, ducts and cysts were sometimes found in the muscularis mucosa^e or submucosa and appear to have been formed by proliferation of the ducts in a downward direction through the muscularis mucosa^c (Figs.27, 36 and 38).

(iv) Cystic changes.

Cysts varying in number and size formed from surface, duct or gland epithelium were seen at various levels of the mucosa (Fig.39). They contained clear or mucoid fluid and frequently showed desquamated cells, polymorphs or other inflammatory cells in a degenerate state.

(v) Metaplasia.

This will be described later as the third main finding in this investigation (see page 31).

(b) Cellular infiltration.

This consisted of numerous lymphocytes and plasma cells with a few eosinophils and polymorphs (Figs.33 and 40). The plasma cells were found as a rule in the upper part of the mucosa (Fig.40) and the lymphocytes in the lower part. Eosinophils were usually located just above the muscularis mucosa. Lymph follicles were more frequent than in the normal mucosa and were sometimes so numerous that the descriptive term "follicular gastritis" could be applied (Fig.31). They were seen at any level of the mucosa and frequently showed germ centres. Oedema was present to varying extent either in the upper part of the mucosa in the tips of the gastric processes or focally at the base.

Strongly eosinophilic ovoid or irregularly shaped bodies, 14-30 μ in size usually with, but occasionally without, a deep staining eccentric nucleus were seen in the upper part of the mucosa in many cases (Fig.41).

These are known as Russel's Bodies and require to be distinguished from plasma cells, oxyntic cells or engorged capillaries. They appear to be derived from degenerate

plasma cells (Maximow and Bloom, 1942).

(c) Fibrosis.

This was variable in amount and tended to occur immediately above the muscularis mucosa (Fig.30). Triangular areas of fibrosis with the base on the muscularis mucosa were sometimes seen at the points of entry of vessels from the submucosa into the mucosa.

(d) Other changes.

Erosions.

These were seen only occasionally in chronic gastritis and were difficult to find.

Muscularis mucosa

This can appear normal or be hypertrophied. Frequently, however, it was infiltrated with inflammatory cells and lymph follicles and showed varying degrees of fibrosis (Figs. 30 and 37). Rarely bands of smooth muscle were seen running above and between the gastric glands through the lamina propria (Fig.36) similar to those noted by Lattes (1947).

Submucosa.

Inflammatory changes and fibrosis were seen here also but when these were pronounced an old scar was usually found in the immediate vicinity. Another change which was present in four cases was a myxomatous degeneration involving

the whole of the submucous fibrous tissue over a considerable area mainly in the pyloric region (Fig.42). No reason was found to account for this apart from the fact that gastric ulceration had once been present. No evidence of malignancy was seen in these specimens although a careful search was made.

4. Chronic Atrophic Diffuse Gastritis.

The term chronic atrophic diffuse gastritis refers to a condition of the gastric mucosa in which there is a marked loss of the specialised oxyntic and zymogenic cells in the glands of the body and which is associated clinically with achlorhydria or hypochlorhydria. It is, in other words, a severe chronic gastritis which is not limited to the pyloric region but affects also the body of the stomach with marked atrophic changes.

This condition (Fig.43) was found in four cases of the carcinoma series but not in the ulcer group. In these, the glands of the body of the stomach showed marked atrophy and loss of the oxyntic and zymogenic cells. These specialised cells had been replaced by mucus secreting cells resembling those found in the pyloric glands and probably derived from the mucus neck cells of the body with the formation of pseudopyloric glands. A few zymogenic-oxyntic cell glands still remained but were in an atrophic condition. Numerous islets and tracts of intestinal epithelium were scattered throughout the mucosa in both the pyloric region and the body of the stomach. It is noteworthy that in the present investigation widespread intestinal metaplasia was found in the body of the stomach only in the four specimens showing atrophic diffuse gastritis.

Chronic inflammatory changes as already described in chronic gastritis (3) were present in both pyloric region and body of the stomach but gave the impression that they were mainly residual.

Most of the changes mentioned above are shown in (Figs.43 and 44) and their severity can be assessed by comparison with the normal body mucosa seen in Figs.45 and 46. It will be noted from these figures that the term atrophic refers to the glands and not to the thickness of the mucosa.

5. Duodenitis.

Representative portions of the duodenum were not included in all specimens but when present acute, subacute and chronic inflammation with changes somewhat similar to those of gastritis were found. Inflammatory exudation, epithelial changes and erosions (Figs.16 and 23) were encountered, but it was noted that glandular involvement and metaplasia were not found in any of the portions examined. In view of the limited material available, detailed consideration of these findings will not be undertaken.

II. Erosions.

Two distinct types of erosions were found and their incidence in the series was:-

	<u>Partial Gastrectomy Series</u>	<u>Biopsy Series</u>
1. Inflammatory	12	2
2. Haemorrhagic	4	2

The higher incidence of erosions in the partial gastrectomy specimens as compared to the biopsy series can be explained in two ways. Firstly, wider areas of mucosa were examined in the partial gastrectomy specimens and secondly, the inflammatory changes of gastritis were less extensive in the body mucosa than in the pyloric region.

The two types of erosions will now be described separately.

1. Inflammatory Erosions.

The morphology of this type of erosion has already been described under acute gastritis (I(c)) and illustrated in Figs.1, 11-23. They were found in ten ulcer specimens and in two carcinoma specimens. The majority occurred in the peptic ulcer group suggesting that their presence was more than just incidental. Inflammatory erosions were present in every specimen with acute gastritis where they were in an acute and active stage (Figs.1, 11-14 and 22). Most of the specimens with subacute gastritis showed in-

flamatory erosions which were usually in a healing or less active stage (Figs.18 and 21). Only rarely were erosions found in specimens with chronic gastritis. One of the carcinoma specimens showed very minute erosions, while the other showed one well developed erosion with carcinoma cells in its floor (Fig.47).

A matter of definition p. 150
 → The fully developed erosions showed histological appearances very similar to those of acute peptic ulcers. In only two respects could differences be distinguished. Firstly, erosions did not involve the muscularis mucosa while acute peptic ulcers penetrated the muscularis mucosa. This is a difference in depth or size only by definition of the terms. Secondly, in erosions there were no signs of chronicity such as are found in peptic ulcers, viz., fibrosis, endarteritis obliterans and thrombosis of vessels. These are signs chiefly of the duration of the ulcer and depend on how soon an acute peptic ulcer can be obtained for histological examination. In fact, it is strongly suggested from these studies that the lesions are similar and differ only in degree.

Comparison of the acute peptic ulcer (Fig.48) with some of the erosions found in the investigation (Figs.1, 11-23) emphasises that the lesions are similar. The smoke-stack exudate issuing from the ulcer resembles the exudate projecting from the erosions seen in Figs.11-16. The

ulcer, however, shows a breach of the muscularis mucosa and there are lymphoid accumulations with early fibrosis in its base, indicating the development of signs of chronicity. The appearances nevertheless suggest that the lesion (Fig.48) represents a transition stage between erosions and peptic ulcers.

2. Haemorrhagic Erosions.

The characteristics of such an erosion are as follows:-

- (a) There is a defect in the mucosa.
- (b) The edges of the defect are abrupt. No inflammatory process is seen in the immediate vicinity.
- (c) Blood is present in the defect or at its base and edge.

These erosions were scanty and were observed in only four specimens (Figs.49-51). They occurred at various levels of the mucosa and sometimes disrupted the muscularis mucosa (Fig.50). In a few cases the missing portion of mucosa was visible just above the defect or lying free in it (Fig.50) and no acute inflammatory changes were evident in it. The blood vessel from which haemorrhage had taken place was sometimes visible in the floor or edge of the erosion.

III. Intestinal Metaplasia.

In the specimens examined intestinal epithelium was found in the gastric mucosa in varying quantity in a high proportion of cases.

The characteristics of such epithelium are as follows:-

1. Surface Epithelium.

This is a simple columnar non mucus-secreting epithelium with a striated border. Goblet cells (not present in normal gastric mucosa) are scattered among the cells of the epithelium in variable proportion.

2. Crypts of Lieberkuhn.

These are lined by a low columnar epithelium and may show goblet cells, argentaffine cells and Paneth cells.

Goblet cells lead to the identification of intestinal epithelium as they are easily recognised by:-

- (a) Their characteristic goblet shape seen in H and E sections
- (b) Mucicarmine. This stains their mucin a deep red while staining a light pink the other mucin secreting cells of the stomach and duodenum, viz. the surface epithelial cells of the stomach, the pyloric glands and Brunner's duodenal glands (Fig.52).

Argentaffine cells were identified by Jacobson's stain (1939), a modification of Masson's method. The

normal stomach contains very few argentaffine cells but they are quite numerous in the islets of intestinal epithelium, especially in the crypts of Lieberkühn (Figs. 53 and 54).

Paneth cells were demonstrated in the islets by Mallory's phosphotungstic acid haematoxylin (Figs. 55 and 56). These cells are not found in the normal stomach but occur in intestinal epithelium at the base of the crypts of Lieberkühn.

Brunner's glands were not noted in association with the ectopic epithelium.

Intestinal epithelium was found in the gastric mucosa as tracts, islets or even as a single duct or segment of a duct showing differentiated goblet cells and intestinal type of non-mucus-secreting cells; it occurred most frequently, however, as islets. These islets were most numerous towards the pyloric end of the stomach and occurred in the body only when the gastritis was of the diffuse atrophic type. The total amount present varied from one islet in one section to many islets in every section of a specimen. In many cases the amount present was directly proportional to the amount of glandular atrophy, but this was not always the case.

Intestinal metaplasia occurred in 56 (82.4%) of the partial gastrectomy series, distributed thus:-

in simple ulcer	-	39	(78%)
in carcinoma	-	16	(94.1%)
in ulcer cancer	-	1.	

The following table shows the results of the study of the 56 specimens which were killed in the laboratory of the Department of Pathology. Chronic ulcers and cancer ulcers were found, but acute (Figs. 20 and 21) and cancer ulcers were also found. Although signs of ulcer were observed in 10 of the partial gastrectomy studies of the operation notes and 7-ray films, the diagnosis of ulcer was present in these cases but not reported.

The specimens which were not reported as having ulcers were chronic ulcers and cancer ulcers. The ulcers present in the specimens were of the following types:

1. Chronic ulcers of the partial gastrectomy specimens. 2. Acute ulcers of the gastric biopsy. 3. Cancer ulcers of the gastric biopsy. 4. Cancer ulcers of the gastric biopsy.

IV. Miscellaneous Findings.

1. Ulcers.

Peptic ulcers and scars were found in 33 of the partial gastrectomy specimens and in some of the biopsy specimens. Most of the ulcers were situated in the stomach and duodenum, only one being encountered in the jejunum. Chronic ulcers and scars (Figs.57 - 59) predominated, but acute (Figs.48 and 60) and subacute (Fig.61) ulcers were also found. Although signs of ulceration were not observed in 10 of the partial gastrectomy specimens, study of the operation notes and X-ray films showed that a duodenal ulcer was present in these cases but had not been removed.

All the specimens with acute and subacute gastritis and a few of those with chronic gastritis showed an acute exacerbation of the ulcer present in the specimen.

2. Carcinoma.

This was found in 15 of the partial gastrectomy specimens and in several of the gastric biopsies. Both scirrhous and encephaloid types were seen and one of the specimens was a leather bottle stomach. Some of the specimens showed adeno-carcinoma with mucin formation, while others showed little differentiation. Squamous metaplasia

was observed in one case. Lymphatic spread was a marked feature and cancer cells were often found at a distance from the primary. One specimen showed carcinomatous infiltration of the duodenum. Secondary infection of the tumour infiltrated areas was noted in many cases.

Ulcer cancer conforming to the type described by Stewart (1931) occurred in one specimen only. In this case a typical chronic peptic ulcer was present which showed early carcinomatous invasion at the one edge.

3. État Mammellonné.

This term denotes a mammillated condition of the gastric mucosa which has been erroneously regarded by some workers as a sign of gastritis. Two varieties of mammillated mucosae were distinguished in the present investigation and they appeared to be different not only in morphology but also in aetiology.

In the first type the gastric mucosa was regularly mammillated throughout its entire extent and the mammillations were most pronounced in the body of the stomach. The individual mammillations corresponded to the *areae gastricae* - the innumerable small elevations present in the normal gastric mucosa. Accordingly the diffuse variety of *état mammellonné* represented an exaggeration of the normal

mucosal pattern. Examples of the condition are seen in Figs.34, 62 - 64 and may be compared with normal gastric mucosa at the same magnification (Fig.45). One of the specimens showed no evidence of ~~the~~ gastritis in the body of the stomach where the mammillations were most marked (Fig.62). Gastritis was superimposed in the other specimens (Figs.34, 63 and 64), but did not seem to be the cause of the condition.

In the second type of *état mammellonné* the mammillations occurred irregularly in the mucosa and were confined to the pyloric region. Histologically the affected parts showed alternating areas of mucosal atrophy and hypertrophy due to an underlying chronic gastritis. An example of this variety is shown in Fig.29 where the mammillations were mainly due to hyperplasia of the ducts.

4. Vascular lesions.

Endarteritis obliterans, thrombosis and organisation of vessels were seen frequently in the base or in the immediate vicinity of peptic ulcers and scars, but were not found elsewhere in the mucosa.

5. Dilated ducts in the body of the stomach.

These have been observed in several cases at various levels of the mucosa frequently without obvious inflammatory

changes in the neighbourhood. The degree to which this occurred varied considerably, being abundant in only three cases but in 50% of the cases at least, one or two dilated ducts were found.

6. Epithelial defects.

In many cases epithelial defects with loss of a varying amount of mucosal tissue were seen, but no immediate inflammatory reaction was associated with them. These were taken to be artefacts and early autolytic changes.

7. Mucosal haemorrhages.

Small haemorrhages were frequently found in the mucosa, submucosa, subserosa and occasionally in the muscularis mucosa, but since none showed surrounding inflammatory reaction, all were attributed to trauma from handling during the operation.

Discussion

The present study of the gastric mucosa in peptic ulceration and gastric carcinoma revealed three main abnormalities, viz., gastritis, erosions and intestinal metaplasia, apart from the condition for which operation was performed. The frequency with which gastritis and intestinal metaplasia were met and the similarity of erosions to ulcers justifies their more detailed and separate consideration below.

Blood vessel changes, viz., endarteritis obliterans, thrombosis and organisation of vessels were found only related to peptic ulcers where their presence is probably secondary, but were not found elsewhere in the mucosa. No importance could therefore be attached to them in the causation of ulcers.

A thorough examination was made for other changes in the gastric mucosa in its blood vessels and nerves which might play a part in the development of peptic ulcer or carcinoma, but none were found.

Gastritis

The conception of a normal stomach in this work has been taken to be one free from the changes described under gastritis. The presence of slight cellular infiltration alone consisting of plasma cells, lymphocytes and occasional polymorphs has been considered to be within the bounds of normality. Several studies on the normal histology of the gastric mucosa have been made by other workers (Bensley (1932), Plenk (1932), Schindler (1947) and Palmer (1952)) and there is now general agreement that the above view is correct.

The results of the investigation undertaken on the present material confirm claims made by Konjetzny (1923, 1928) that chronic gastritis is invariably present in cases of peptic ulcer and gastric carcinoma and that acute gastritis with erosions occurs in peptic ulcer specimens. No case of simple acute gastritis was found, but all the specimens showed chronic gastritis and a significant proportion had acute or subacute exacerbations. Accordingly, it is suggested that acute gastritis precedes the development of chronic gastritis and punctuates its course with acute and subacute exacerbations.

It is believed from study of the literature and illustrations of published cases of simple acute gastritis

that it is identical histologically with the acute exacerbations found in this investigation. The essential pathology involved is an acute focal inflammation of the gastric mucosa with exudation, erosions, glandular destruction and epithelial regenerative processes. The extent to which these are present (Figs.1 - 14) and the occurrence of healing erosions (Figs.19 - 23) provide indisputable proof of the existence of the condition prior to resection. Interference with the blood supply, trauma from manipulation and early autolytic changes during the course of the operation could not possibly have caused these lesions as has been suggested by Schindler, Nechelles and Gold (1939) and Sanders and Mecray (1941). These workers claim to have produced an "erosive" gastritis in animals by partial gastrectomy and the administration of hydrochloric acid and they believe it to be identical to that found in partial gastrectomy specimens. They did succeed, it is true, in obtaining a condition of the mucosa which resembles acute gastritis macroscopically but, as has already been pointed out in this investigation, macroscopic appearances alone are unreliable in resected specimens and only microscopical evidence is acceptable. Their microphotographs showing erosions and early inflammatory exudation are not at all convincing. The erosions illustrated

by them constituted epithelial defects which did not have the structure of erosions as found in this investigation. The very early inflammatory exudation pointed out by them contained few polymorphs and was not at all comparable in extent to what was found in this series. No signs of epithelial regeneration, moreover, could be discerned in their microphotographs - in fact much of the epithelium showed autolytic changes. Consideration of these facts leads to the inevitable conclusion that acute gastritis with erosions does exist in the specimens prior to operation.

While acute gastritis was found only in the peptic ulcer series, subacute gastritis was encountered in both peptic ulcer and carcinoma specimens. This type represents a transition stage between the acute and chronic forms. Regenerative changes predominate and polymorphs are not as numerous in the inflammatory exudate. Proliferative changes are marked and it is believed that the hypertrophic changes of chronic gastritis have their origin in this stage.

Chronic gastritis in the form of a low grade inflammation of the gastric mucosa also affected both peptic ulcer and carcinoma specimens. Cellular infiltration of the chronic type with plasma cells, lymphocytes, eosinophils and few polymorphs was the most constant feature and

was associated in many of the specimens with numerous lymph follicles and fibrosis. A variety of changes affected the surface, duct and gland epithelium, the most important of which were glandular atrophy, hypertrophic and cystic changes, heterotopia and metaplasia. Study of these structural abnormalities in the gastric mucosa indicated that gastritis had been present for a considerable time. It is believed that they arise from the destructive and regenerative processes of acute and subacute gastritis and also as a result of compression and irritation by stromal infiltration and lymph follicle formation in chronic gastritis. Some of the specimens showed slight inflammatory and epithelial activity while others were relatively quiescent, implying that the aetiological agents were not always at work.

The severity of all three kinds of gastritis was maximal in the pyloric region and in the first two inches of the body of the stomach immediately adjacent to it. Minimal involvement of the glands of the body explained why acid secretion in the majority of cases was not diminished. Normal acidity and hyperacidity was the rule in all the peptic ulcer cases. The fact that the pyloric region was more severely affected fits in with the theory of other workers that exogenous irritants are involved in its production.

Chronic atrophic diffuse gastritis occurred in four cases of the carcinoma group and it is not known yet whether this condition (associated clinically with hypochlorhydria and achlorhydria) is the result of:-

- (1) Acute diffuse gastritis such as occurs in the specific fevers at an early age.
- (2) Chronic gastritis progressing with loss of specialised glandular tissues in the body of the stomach.
- (3) Congenital abnormality.
- (4) Simple atrophy due to unknown causes.

The presence of inflammatory changes in the four cases mentioned makes it improbable that causes (3) and (4) are responsible.

Study of the current literature on gastritis suggests that it is a very common subclinical condition which is not confined to peptic ulcer and carcinoma patients (Williams (1950), Schindler (1950) etc.). During this investigation one stomach showing no signs of peptic ulceration or gastric carcinoma was obtained, by special technique*, from a patient

* A stomach tube was passed in this case within half an hour of death and the gastric contents aspirated; 500 cc. of formol saline were then introduced and the oesophagus plugged with cotton wool. By this means the stomach and first part of the duodenum were obtained free of autolysis at the post mortem carried out a few hours later. This technique was first described by Damaschino (1880) and was later modified by Chauffard (1882), Hayem (1892-3) and Faber (1935).

who had no ulcer history. Chronic gastritis was found in this specimen with the same distribution as found in the partial gastrectomy series, although no acute lesions were seen. The fact, however, that cases of peptic ulcer and gastric carcinoma always show chronic gastritis and the high incidence of acute and subacute exacerbations among them suggests that there is a connection between them.

Konjetzny, Faber and Magnus have suggested from their studies in human pathological anatomy that erosions are the connecting link between gastritis and peptic ulceration. They assert that the erosions found in acute and subacute gastritis may progress to acute and chronic ulcers and they were able to point to transition stages of this process. Confirmatory evidence of the close association between gastritis with erosions and peptic ulceration was obtained by researches in veterinary pathology. Konjetzny and Puhl (1926) showed that the development of peptic ulcers in calves when they are weaned at 6 weeks was accompanied by acute gastritis with erosions which was comparable to that found in human partial gastrectomy specimens. More recently Simonds (1938), reporting on the development of the cincophen ulcer in dogs, revealed that gastritis with erosions preceded the formation of ulcers. In the present investigation on human partial gastrectomy

specimens, acute and subacute gastritis occurred in 20% of the peptic ulcer series and this high figure, together with the remarkable resemblance between erosions and acute ulcers, gives much support to the theory propounded above.

Although Konjetzny's work on partial gastrectomy specimens has been confirmed by many other histologists (Kalima (1924), Puhl (1930), Buchner (1931), Faber (1935), Hebbel (1943) and Magnus (1946)), his claims have not yet been generally accepted. Gastroscopists and experimental workers have attempted to discredit Konjetzny's findings and to dispute the role of gastritis in the development of peptic ulceration.

Schindler (1926, 1950), Moutier (1935) and other gastroscopists have failed to find a high incidence of gastritis with erosions in peptic ulcer cases. Their method of examination, however, is macroscopic and is thus an unreliable guide to the underlying histological changes. The present investigation has shown, moreover, that gastric biopsies are not equivalent to detailed histological examination of a resected specimen. Another disadvantage of gastroscopy is that poor visualisation of the pyloric region is obtained and this is the part most severely affected by gastritis in ulcer cases.

In support of his views, Schindler calls attention to an investigation on resected specimens by Walters and Sebening (1932) which did not confirm Konjetzny's work. Reference to their publication, however, reveals that the results were obtained by macroscopic examination of the material and not by detailed histological examination. This invalidates their conclusions considerably.

Schindler has pointed out also that Konjetzny's patients received preoperative treatment with hydrochloric acid and he alleged that this probably contributed to the occurrence of lesions in the related specimens. This criticism cannot be directed against the present investigation since none of the cases received hydrochloric acid as a therapeutic measure before operation.

The experimental investigations of Schindler, Nechelles and Gold and Sanders and Mecray, discussed earlier in this section, represented an attempt to reconcile the views of histologists and gastroscopists. As has already been pointed out, however, the autolytic changes obtained differed microscopically from the inflammatory lesions found in resected specimens. The experiments demonstrate, nevertheless, the unreliability of macroscopic examination of resected material. Only detailed histological examination of resected specimens is of value and this as yet

appears to have been omitted by Schindler and his co-workers.

Konjetzny's claims that "erosive" gastritis occurs in peptic ulcer specimens have been confirmed in this investigation and it is my contention that these claims can neither be ignored nor discredited.

The relationship of gastritis to gastric carcinoma is believed to be the same as that of any chronically inflamed epithelium. No specific precancerous changes were seen in the carcinoma group even in the mucosa immediately adjacent to the tumour and slight changes, e.g., proliferative and cystic changes, were encountered just as frequently in the peptic ulcer group as in the carcinoma series.

État Mammellonné.

A term which has given rise to much confusion in the literature is "état mammellonné". This was introduced by Louis (1824) to indicate a mammillated state of the body of the stomach which he believed to be a sign of gastritis. Konjetzny (1928), however, pointed out that this mammillated state was the normal appearance of the mucosa of the stomach which was divided into innumerable small elevated areas known as the *areae gastricae* and that formalin fixation accentuated this mucosal pattern. On the other hand, he suggested that the term should be retained to indicate the irregularly mammillated state produced by atrophic-hypertrophic gastritis in the pyloric region. Schindler (1950), in his gastroscopic classification of gastritis, describes a chronic hypertrophic gastritis which corresponds to a mammillated state of the body of the stomach and he subdivides it into two types, an interstitial and a parenchymatous (glandular).

The present investigation suggests that the *areae gastricae* are part of a normal mucosal pattern which may be slight or absent in some cases. Exaggeration of this mucosal pattern results in a mammillated condition and it is believed that this represents either a normal variation or a true hypertrophy of the mucosa due to factors not

established by the investigation. A regularly mammillated mucosa, therefore, does not mean that gastritis is present. Gastritis may be superimposed on this condition, however, and produce irregularity of the pattern due to inflammatory changes. Gastritis may also cause a mammillated appearance due to atrophic-hypertrophic changes when it affects a mucosa where the *areae gastricae* were not normally accentuated. The term *état mammellonné* is thus purely descriptive, meaning mammillated state and does not mean that gastritis in the inflammatory sense is present in the affected mucosa. Magnus and Rodgers (1938) have expressed similar views, differing only in that they believe the condition is not hypertrophic.

Erosions.

Erosions were found in the gastric mucosa in 23.5% of the partial gastrectomy specimens. The inflammatory type of erosion was found most frequently and will be discussed first.

Acute inflammatory erosions are part of a disturbance which was found to affect the surface, duct and glandular epithelium in acute and subacute gastritis. The erosions varied in size and some were associated with a loss of mucosal tissue. The earliest and smallest erosions showed a fibrino-leucocytic exudate streaming out of the lamina propria through a gap in the epithelium. This appearance suggests that they are formed by acute inflammatory exudate collecting in the interstitial tissue and rupturing through the covering epithelium or exuding through it to such an extent that the epithelium is destroyed or cast off. Enlargement of the erosion appears to take place by coalescence of several associated erosions or by undermining and sloughing of a portion of mucosa at its edge. The lesion extends in depth with atrophy, degeneration or necrosis of the glands below it as the exudative process continues or possibly even by haemorrhage. It is probable that exposure to gastric juice increases the size and depth of the lesion also by its digestive action on tissue not covered by epithelium. Some

of the erosions may have been primarily traumatic (i.e., caused by destruction of the surface epithelium by mechanical, thermal and chemical agents) or haemorrhagic in origin with secondary inflammatory reaction, but this could not be proved although both haemorrhagic erosions and epithelial defects (indistinguishable from artefacts) were seen.

These histological features are in agreement with those of Konjetzny (1928), Puhl (1930), etc., who first described them in partial gastrectomy specimens, and these seem of fundamental importance in the development of peptic ulceration.

The occurrence of inflammatory erosions associated with ulcers is supported by certain investigations in animals. Konjetzny and Puhl (1926) found inflammatory erosions and ulcers in calves weaned at 6 weeks and killed at 10 weeks. Simonds (1938), reporting on the cincophen ulcer in dogs, found histologically a gastritis with inflammatory erosions.

The haemorrhagic erosions found in the present series could have been produced during the operation itself, especially since the undigested portion of the mucosa or intact blood cells were usually visible in the gap, suggesting a recent origin. Study of these lesions is, however, necessary since similar mechanisms may be at work in the

development of haemorrhagic erosions in general. The erosions studied showed no obvious evidence of having been produced by direct trauma, as there was no compression of the tissues in the immediate vicinity. The mechanism involved appeared to be rupture of a vessel, probably a venule just above or in the muscularis mucosa. Since they always occurred in a mucosa affected by gastritis, it is probable that the inflammatory process predisposes to their development. When the inflammation is no longer acute, gastritis may produce a weakness of the vessel wall so that slight trauma insufficient to cause compression or loss of tissue results in a small haemorrhage.

It is of value to consider briefly here the mechanisms of production of erosions for which some proof has been advanced by other workers.

1. Haemorrhage
 - (a) Specific fevers
 - (b) Blood conditions purpura, etc.
 - (c) Chronic venous congestion
 - (d) Trauma
 - (e) Gastritis.
2. Ischaemia
 - (a) Vascular spasm
 - (b) Thrombosis.

3. Inflammatory exudation (a) Gastritis
(b) Rupture of inflamed lymph
follicles.
4. Necrosis and loss of tissue in trauma (mechanical,
thermal, chemical, etc.).

The present investigation confirms the occurrence of inflammatory and haemorrhagic erosions associated with gastritis. No evidence for the other mechanisms suggested in the production of erosions and acute peptic ulcers has been found in the present investigation.

Schindler (1950), in his gastroscopic work, has encountered two types of erosions which appear to be similar to the inflammatory and haemorrhagic erosions described in this thesis, and he believes they are due to gastritis (both gastritis and erosions have been seen by Schindler in non-ulcer cases and while the present investigation shows that gastritis is invariably present in peptic ulcer cases, no claim is made that the reverse is always true).

Inflammatory erosions were found in 20% of the peptic ulcer specimens and the presence of all sizes of erosions together with the occurrence of acute, subacute and chronic ulcers lends much support to the theory that transition from erosions to ulcers takes place. An early acute peptic

ulcer (Fig.48) was encountered which closely resembled the inflammatory type of erosions in structure and differed only in that it penetrated the muscularis mucosa and showed early submucosal fibrosis. Neither of these differences indicates a separate pathological process and they may be interpreted as differences in the depth and duration of the lesion. It should be remembered that erosions and ulcers have been distinguished by definition on an anatomical basis, viz., by the depth of the lesion and not on histopathological grounds. Such distinction has seemed desirable only because doubt still exists about their relationship. The acute peptic ulcer referred to above appears to represent a transition stage between erosions and peptic ulcers.

The findings of the investigation strongly suggest that an erosion may develop into an acute peptic ulcer when the muscularis mucosa is penetrated or, in other words, that acute and subacute gastritis may act as a trigger mechanism via erosions for starting off peptic ulcers in some cases. The erosions of acute and subacute gastritis, however, are multiple and show a marked healing tendency, while peptic ulcers are single or few in number and are notoriously slow to heal. Other factors, therefore, appear to be involved in the progression of erosions to acute and

chronic ulcers and to the persistence of the latter lesions - possibly secretory anomalies, anatomical factors or other unknown mechanisms. Thrombosis of vessels in the base of ulcers may play a part in the persistence of some chronic ulcers, but not in their original development.

Intestinal Metaplasia.

The occurrence of intestinal metaplasia in the gastric mucosa in the partial gastrectomy specimens is a common finding. The theories relating to its presence are:-

1. Regeneration Theory. Production of cell types in the regenerative processes of acute and chronic gastritis which are capable of forming either gastric or intestinal epithelium - a metaplasia due to gastritis.

Sachs 1887-88 Schmidt 1896 Faber and Lange 1908
 Chuma 1923 Konjetzny 1928 Hamperl 1928
 Magnus 1937.

2. Congenital Heterotopia. This is a developmental abnormality of little pathological importance in which a tissue is found in an abnormal location.

Taylor (1927) believes that there are two types, viz:- Congenital and Acquired, but his investigations were made only in diseased stomachs (resected for ulcer or carcinoma) and his criteria for differentiation have not yet been confirmed.

Stewart (1929) also supports this theory and states that he has seen it in a normal stomach free from gastritis.

Of interest in this connection are the findings of Saltzmann (1913), Chuma (1923) and Magnus (1937), who could

find no trace of it in foetal stomachs, although Clar found it in foetal stomachs up to the 7th month, after which it disappeared.

3. Simple Metaplasia due to metabolic deficiency or other unknown factors, e.g., pernicious anaemia.

I have considered two other possible mechanisms to account for the presence of intestinal epithelium in the gastric mucosa, but have found no support for them.

They are respectively:-

4. Spread upwards of intestinal epithelium over the pyloroduodenal junction by direct continuity, possibly via erosions. Such continuity could not be demonstrated as the ectopic epithelium occurred as islets and isolated areas.

5. Grafting of free intestinal epithelial cells present in regurgitated duodenal contents on to erosions in the stomach. The extent to which metaplasia was present, however, and the depth to which it reached make this possibility very improbable.

The incidence of the abnormality in resected specimens as found by various investigators is:-

Heyrovsky 1912	- in stomachs resected for ulcer Amount of mucosa examined unknown.	14.2%
Chuma 1923	- in 38 stomachs resected for ulcer cancer. Large areas examined.	70%
Puhl 1926	- 140 ulcer specimens. Large areas examined.	100%
Taylor 1927	- simple ulcer specimens - in- testinal epithelium in neighbour- hood of gastric ulcer.	11%
Konjetzny 1928	- specimens resected for carcino- ma. Large areas examined.	100%
Magnus 1937	- 100 specimens resected for ulcer and cancer. Large areas examined. 10 post mortem specimens - large areas examined.	59% 80%

The incidence in the present series is 82.4%.

The present investigation confirms its very frequent occurrence in chronic gastritis and its tendency to be more extensive in the severe cases. It has also been pointed out that it was usually confined to the pyloric region which was principally affected by the gastritis in the majority of specimens; it was found in the body of the stomach only when chronic gastritis extended there, especially in chronic atrophic diffuse gastritis. These factors

all combine to suggest that the occurrence of intestinal epithelium in stomachs showing peptic ulceration or carcinoma is a result of metaplasia due to the underlying chronic gastritis.

... in over 40% of the ...
 ... and the investigation suggested that ...
 ... leading finally to ...

Inflammatory and degenerative erosions ...
 ... peptic ulcer and carcinoma ...
 ... In the peptic ...
 ... inflammatory ...
 ... junction between erosion and chronic ...
 ... It is believed that such ...
 ... that gastric ...
 ... via erosions for ...

... cases ...
 ...

Summary.

1. 68 partial gastrectomy specimens and 63 biopsy specimens of the body mucosa obtained from patients suffering from peptic ulceration or gastric carcinoma were examined for associated lesions.
2. Chronic gastritis was present in all the partial gastrectomy specimens and in over 50% of the biopsies. A considerable number also showed acute and subacute gastritis and the investigation suggested that these occurred as recurrent episodes leading finally to chronic gastritis.
3. Inflammatory and haemorrhagic erosions were observed in both peptic ulcer and carcinoma specimens associated with the gastritis. In the peptic ulcer series 20% of the specimens showed inflammatory erosions and all stages of lesion between erosion and chronic peptic ulcer were encountered. It is believed that such a transition from erosion to ulcer occurs and that gastritis acts as a trigger mechanism via erosions for starting off peptic ulcers in some cases.
4. Intestinal epithelium occurred in the gastric mucosa in 82.4% of the partial gastrectomy series and it appeared to be the result of metaplasia due to the coincident gastritis.

References

- Bensley, R.R. (1932) The Gastric Glands. In Cowdry, E.V. Special Cytology, Vol.1. New York. Hoeber 1932.
- Buchner, F. (1931) D. Pathogenese d. peptischen Veränderungen Jena. Fischer.
- Chauffard, A. (1902) Étude sur les déterminations gastrique de la fièvre typhoïde. Thèse de Paris.
- Chuma, M. (1923) Arch.Path.Anat., 247, 236.
- Clar, F. (1934) Beitr.klin.Chir., 140, 145.
- Damaschino (1880) Note sur un nouveau procédé pour l'étude des lésions de l'estomac. Gaz.med., Nr.6.
- Faber, K. (1935) Gastritis and its Consequences. Oxford University Press. London.
- Faber, K. & Lange, G. (1908) Z.klin.Med., 66, 247.
- Hamperl, H. (1928) Beitr.Path.Anat., 80, 307.
- Hayem, G. (1892/93) Résumé de l'anatomie pathologique de la gastrite chronique. Gaz. hebdom.
- Hebbel, R. (1943) Chronic Gastritis. Its relation to Gastric and Duodenal Ulcer and to Gastric Carcinoma. Am.J.Path., 19, 43.

- Heyrovsky, H. (1912) Wein, klin. Wschr., 25, 80.
- Ivy, Grossman & Bachrach (1950) Peptic Ulcer. J.S.A. Churchill. London.
- Jacobson, W. (1939) Journal of Path. & Bact., 49, 1/19.
- Kalima, T. (1924) Pathologisch-anatomische Studien über die Gastritis des Ulkusmagens nebst einigen Bemerkungen zur Pathogenese und pathologischen Anatomie des Magengeschwurs.
Virchows Arch. Bd. 128.
- Konjetzny, G.E. (1923) Chronische Gastritis und Duodenitis als ursache des Magenduenalgeschwurs.
Beitr.z.pathol.Anat. u.z. allg. Pathol. Bd.71.
(1928) In Henke & Lubarsch's Handbuch der speziellen pathologischen Anatomie und Histologie.
Berlin. Bd.IV, T2, p.268.
- Konjetzny, G.E. & Puhl, H. (1926) Das sog. Ulcus pepticum des Magens der Absatzkalber.
Virchows Arch. Bd.262.
- Lattes, R. (1947) Am.J.Path., 23, 501.
- Lendrum, A.C. (1935) J.Path. & Bact., 40, 416.

- Louis, P.Ch.A. (1924) Arch.gener.de mèd., 5, 1.
- Magnus, H.A. (1937) J.Path. & Bact., 44, 2, 389.
(1947) Ibid., 58, 3, 431.
- Magnus, H.A. & Rodgers, H.W. (1938) St.Bart.Hosp.Reports,
71, 129.
- Maximow, A.A. & Bloom, W. (1942) A Textbook of Histology.
4th Ed.
- Moutier, F. (1935) Traité de gastroscopie et de
pathologie endoscopique de l'estomac.
Paris. Masson et Cie.
- Palmer, E.D. (1952) Gastroenterology, 21, 1, 12.
- Plenk, H. (1932) Der Magen. In Moellendorf
Handbuch d. mikr. Anatomie d. Menschen
5 Teil 2. Berlin. Springer.
- Puhl, H. (1926) Uber d. Bedeutung entz. Prozesse
f.d. Entstehung d. Ulkus ventriculi et
duodeni Virchows
Arch.f.path.Anat., Bd.260.
(1930) Uber d. Entstehung u. Entwick-
lung d. chron. Magen u. Duodenalge-
schwurs.
Arch.f.klin.Chir., 158, 1.
- Sachs, A. (1887/8) Arch.exp.Pathol. und Phar-
makol., 24, 109.

- Saltzman, F. (1913) Arb.Path.Inst.Univ.Helsingf.
Jena.
- Sanders, G.B. & Mecray, P.M. (1941) Annals of Surgery,
114, 986.
- Schindler, R. (1926) Discussion to "Gastritis"
Verhandl.d.Geselsch.f.Verdaunungs. - u.
Stoffwechselkr.
6 Tg. Leipzig. Thieme p.108.
(1947) Gastritis. William Heineman
Ltd., London.
(1950) Gastroscopy. University of
Chicago. Press. 2nd Edition.
- Schindler, R., Nechelles, H. & Gold, R.L. (1939) Surg.
Gynec. and Obstet., 69, 281.
- Schindler, R. & Ortmayer, M. (1936) Classification of
Chronic Gastritis.
Arch.Inst.Med., 57, 959.
- Schmidt, A. (1896) Arch.Path.Anat., 143, 477.
- Simonds, J.P. (1938) Arch.Path., 26, 44.
- Stewart, M.J. (1929) Hurst & Stewart's Gastric and
Duodenal Ulcer. London, p.131.
(1931) Lancet, 2, 565, 617, 669.
- Taylor, H.L. (1927) J.Path. & Bact., 30, 415.

Walters, W. & Sebening, W. (1932) A comparison of lesions
associated with Duodenal Ulcer in
Germany and in the U.S.

Minnesota Med., 15, 579.

Williams, W. (1950) British Medical Journal, 1, 102.

Part 4

Verification from the postmaster is

required for all mailings

... material was available in the records of the ...
 ... clinical and autopsy figures. At present
 ... the incidence of this ...

Part 2.

Investigation into the post-mortem incidence of peptic ulcers and erosions.

...
 ...
 ... ulcers should not be included in the ...
 ... but detailed separately,
 ... of the investigation should be ...

Introduction.

An investigation into the post-mortem incidence of peptic ulceration and erosions was made, since sufficient suitable material was available for the results to be compared with other clinical and autopsy figures. At present there is only one important investigation of this nature in Britain, viz., M.J. Stewart's series at Leeds, 1929, and it was therefore thought that another survey in a different centre would be of value. Ivy, Grossman & Bachrach (1950), who undertook an extensive review of this subject, pointed out the need for such investigations and specified certain essentials for the selection of suitable material. These may be briefly summarised thus:-

1. The autopsy series should consist of at least 1,000 cases.
2. The autopsy material should be representative of the population at large.
3. Erosions and specific lesions such as tuberculous and malignant ulcers should not be included in the category of peptic ulcers but detailed separately.
4. Shortcomings of the investigation should be pointed out if present.
5. The data should be presented clearly.
6. The age and sex composition of the material should be stated.
7. The incidence and ratios should be calculated with refer-

ence to the adult population over Age 10.

The significance of distinguishing between ulcers and erosions has not always been realised in the past, but is justified by the fact that the occurrence of erosions is not confined to peptic ulcer patients.

Material.

Comprehensive post-mortem reports from the Stobhill and Southern General Group of hospitals from 1948 - 51 provided suitable material for investigation and fulfilled the criteria mentioned above. Accordingly 1,509 consecutive reports comprising 1,000 adults over Age 10 and 509 children under Age 10 were analysed and the results shown in the following tables were obtained.

Category	Number	Percentage
Number of ulcers	114	11.4
Number of gastric ulcers	42	4.2
Number of duodenal ulcers	72	7.2
Number of combined ulcers	100	10.0

It is seen that the total incidence of ulcers in the adult population was 11.4% in 1948-51.

Results.

A. Peptic Ulceration in the Adult Population

Composition of the population

Total No. of adult post-mortems over Age 10		1,000
Sex distribution	Male	583
	Female	417.

In view of the disparity in numbers between males and females and the increased incidence of ulcers in the former, the more important percentages and ratios have also been given after recalculation to allow for this disproportion.

The population of the series was mainly drawn from social classes 3, 4 and 5, viz., skilled, semiskilled and unskilled workers (Doll & Jones 1951).

Incidence of ulcers and scars

	<u>No.</u>	<u>%</u>	<u>% corrected for sex disproportion</u>
Incidence of open ulcers	114	11.4	10.93
" " " scars	69	6.9	6.57
Total incidence of ulcers and scars	<u>183</u>	<u>18.3</u>	<u>17.5</u>

Thus it is seen that the total incidence of ulcers and scars in the adult population was 18.3% or 17.5% after correction for sex disproportion. This is a high figure and means roughly that in more than one in every six post-mortems an active peptic ulcer or scar resulting from a

previous ulcer was present as a definite recognisable lesion. The incidence of open ulcers, 11.4% (10.93% corrected), is also high and the lower incidence of scars, 6.9% (6.57% corrected), leaves the analysis immune from criticisms directed at other investigators who included a disproportionately high percentage of dubious scars.

Site of ulcers and scars

	<u>No.</u>	<u>%</u>
Oesophageal	2	0.2%
Gastric (including 14 pyloric cases)	91	9.1%
Duodenal (including 4 juxta pyloric cases)	107	10.7%
Combined gastric and duodenal ulceration	18	1.8%

Duodenal ulcers were encountered more frequently than gastric ulcers and combined gastric and duodenal ulceration was found in almost 10% of the ulcer cases. Some difficulty was experienced with specimens showing pyloric ulceration (10% of the ulcer population) in deciding whether the ulcer had been gastric or duodenal in origin.

Ratio of gastric to duodenal ulcers

		<u>Ratio</u>	<u>Ratio corrected for sex disproportion</u>
	<u>G.U.</u>	= $\frac{1}{1.18}$	$\frac{1}{1.14}$
	<u>D.U.</u>		
In males	<u>G.U.</u>	= $\frac{3}{4}$	approx.
	<u>D.U.</u>		
In females	<u>G.U.</u>	= $\frac{3}{2}$	approx.
	<u>D.U.</u>		

The G.U. : D.U. ratio again reflects the higher frequency of duodenal ulcers as compared to gastric ulcers in the total adult population, but shows that this is true only for the male population. The ratio obtained for the female population shows that gastric ulcers are more frequent than duodenal ulcers in the proportion of 3 : 2.

Sex ratios

		<u>Ratio</u>	<u>Ratio corrected for sex disproportion</u>
Gastric ulcers and scars	$\frac{M}{F}$	= $\frac{2}{1}$	$\frac{1.4}{1}$
Duodenal ulcers and scars	$\frac{M}{F}$	= $\frac{3.9}{1}$	$\frac{2.82}{1}$
All ulcers and scars	$\frac{M}{F}$	= $\frac{2.52}{1}$	$\frac{1.8}{1}$

The study of these figures reveals that men suffer more frequently from peptic ulcers than women. Gastric ulcers occur twice as often in men as in women and duodenal ulcers almost three times as often.

Age incidence of ulcer cases

The age incidence of gastric and duodenal ulcers as compared to the total adult population is shown in Graphs 1 and 2 at the end of Book I.

The incidence of gastric and duodenal ulcers in the various age groups of this investigation has been more accurately expressed in the table below as a percentage of the number of post-mortems occurring in the different decades.

<u>Age Group</u>	<u>% with Gastric Ulcers</u>	<u>% with Duodenal Ulcers</u>
10 - 19	0	0
20 - 29	3.1	4
30 - 39	12	10
40 - 49	7	11.5
50 - 59	11.5	11.5
60 - 69	7.9	13
70 - 79	10.7	10.6
80 ⁺	15.9	5.3

Reference to the graphs and to the table above shows that gastric ulcers in this investigation were most common in the fourth and sixth decades and in old people over 70 years of age. Duodenal ulcers, on the other hand, occurred most frequently in the age groups which showed the highest mortality rate, viz., the fifth, sixth and seventh decades.

Occurrence of dyspeptic symptoms in ulcer cases

An analysis of available case records was undertaken to find if gastric ulcers were more frequently silent than duodenal and therefore less frequently diagnosed.

(1) No. of cases with silent ulcers.

	<u>Ulcers and scars</u>	<u>Open ulcers</u>
Gastric	25	17
Duodenal	35	20
Gastric and duodenal	<u>1</u>	<u>1</u>
Total	61	38

(2) No. of cases with dyspeptic symptoms including cases where haemorrhage, perforation or other complication was the first and only indication of peptic ulceration

110	70
-----	----

(3) No. of cases with no dyspeptic symptoms but with inadequate case histories, e.g., patients admitted in coma, etc.

<u>12</u>	<u>6</u>
-----------	----------

Totals	<u>183</u>	<u>114</u>
--------	------------	------------

The above figures do not give any support to the suggestion that gastric ulcers are more frequently silent than duodenal. In at least one third ($33\frac{1}{3}\%$) of the ulcer

series, peptic ulceration had been completely unsuspected until disclosed at autopsy.

Association of peptic ulceration and other diseases

Analysis of the post-mortem records was made to find if some of the common diseases showed a higher incidence of peptic ulceration than the rest of the population.

	<u>Total No. of</u> <u>cases</u>	<u>Cases with</u> <u>ulcer</u>	<u>%</u>
Rheumatic heart disease	76	19	25
Malignant tumour	245	34	13.9
Tuberculosis	117	26	22.2
Atheroma (slight)	358	65	18.2
(severe)	265	42	15.9
Hypertension	115	22	19.1
Coronary thrombosis	108	16	14.8

Comparing these figures with the average incidence obtained for the series, viz., 18.3%, rheumatic heart disease was the only condition in which a difference of over 5% was found. Peptic ulceration was present in 25% of patients with rheumatic heart disease and this high figure could not be explained on the basis of sex disproportion because the group contained 36 males and 45 females. Correction could only increase the figure of 25% because, as already shown, ulceration is more frequent in males than in females.

Mortality rate

Peptic ulceration was the cause of death in 36 cases, i.e., 3.6% of the total adult population or 19.7% of the total ulcer cases.

The incidence of the various complications which led to a fatal result is given below.

	<u>No. of cases</u>
Perforation	18
Haemorrhage	11
Perforation and haemorrhage	2
Post operative complication	4
Malnutrition due to pyloric stenosis	<u>1</u>
	<u>36</u>

Perforation and haemorrhage were more frequently fatal than any of the other complications.

B. Peptic Ulceration in the Population under Age 10.

Analysis of 509 post-mortems under Age 10 carried out during the same period, 1948-51, showed 5 cases of gastric ulcer, giving an incidence of 1%. No duodenal ulcers were observed within this series, but have been encountered apart from it.

C. Erosions.

	<u>Total</u>	<u>With erosions</u>	<u>%</u>
Post-mortems over Age 10	1,000	130	13%
" " under Age 10	509	33	6.4%
All post-mortems	1,509	163	10.8%

The identification of erosions was macroscopic, the criteria for their recognition being their minuteness and multiplicity. Working on this basis, it was found that certain so-called "erosions" extended through the muscularis mucosa (compare Figs. 65 and 66), coming within the class of peptic ulcers according to the definition of Ivy, Grossman and Bachrach which is as follows:- "A circumscribed defect in the mucosa of the stomach, duodenum and jejunum is called an ulcer only when the defect extends through the muscularis mucosa".

Nevertheless, I believe it is better for the purposes of research to list all specimens with multiple,

minute defects in the gastric mucosa as cases with erosions even though some of these lesions prove to be acute ulcers microscopically (Fig.66). If, however, the lesion resembles the ulcers shown in Fig.48 or Fig.60 microscopically and has well established inflammatory reaction round it, then the specimen should be classed as showing peptic ulceration. Both erosions and peptic ulceration may occur in the same specimen. This practice has been followed as far as possible in the present investigation into post-mortem records.

Since every specimen was not examined microscopically, it was not possible to say whether the erosions were inflammatory or haemorrhagic in type. Macroscopically, however, the majority appeared to be haemorrhagic erosions and this is supported by the fact that textbooks of Pathology refer to the erosions found in the stomach at post-mortem as haemorrhagic erosions.

Erosions were found twice as frequently in adults as in children under Age 10. In the adult population the incidence of erosions (13%) was lower than that of peptic ulceration (18.3%), and it was noted with surprise that only 5.4% of the cases with peptic ulcers showed erosions. The incidence of erosions in the population under Age 10 greatly exceeded that of peptic ulceration.

The location of erosions was nearly always gastric and only occasionally were duodenal and oesophageal erosions seen. The oesophageal erosions have not been included in the above figures. The sex incidence of the erosions was approximately equal.

Discussion

The incidence of peptic ulcer in adults over Age 10 was 18.3% in the present series. Correction for the unequal sex composition of the series reduces this figure to 17.5%. These figures are high compared with others, except those of Lehman (1925) who recorded an incidence of 20.2% in Vienna and Grunfeld (1882) who, according to Welch, found an incidence of 20% in Europe. The highest figure found in Britain has been 18.23% from M.J. Stewart's investigations at Leeds published by Watkinson (1950), but erosions were classed as ulcers and not assessed separately.

The average incidence of peptic ulceration in the general population is given as being between 5 and 10% by Ivy et al., a figure derived from a survey of both clinical and post-mortem statistics. It should be remembered that several factors appear to affect the incidence, e.g., age, sex, social status and geographical location.

The incidence of open ulcers 11.4% (10.92% corrected for sex disproportion) is higher than that of other observers in comparable investigations.

The G.U. : D.U. ratio 1 : 1.18 (corrected for sex disproportion 1 : 1.14) differs slightly from the average 1.2 : 1 (Ivy et al.) based on figures published up to 1929, but is quite compatible with the general trend of increasing

frequency of duodenal ulcers as compared to gastric ulcers which has been noted by clinical observers. Jamieson, Smith and Scott (1949), in a clinical series of 3,258 ulcer patients at the Western Infirmary, Glasgow, found the ratio G.U. : D.U. to be 1 : 7.7. The discrepancy between the clinical figures and my own post-mortem figures is in keeping with the findings of other investigations which show the same discrepancy (Stewart 1929, Ivy et al. 1950). The factors responsible for this are not definitely established, but other workers have suggested that the following play a part:-

1. Constitution of the population investigated regarding age, sex, social class of the individuals in the series.
2. Gastric ulcers may more frequently be silent than duodenal.
3. Ulcers in the region of the pylorus may be classified as duodenal or gastric according to the custom of the surgeon, pathologist or radiologist.
4. Radiological errors in diagnosing duodenal ulcers without subsequent confirmation.

The present investigation suggests that all these may play a part, with the exception of the suggestion that gastric ulcers are more frequently silent than duodenal. No confirmation of this theory was found, as the results have shown.

In women, gastric ulcers were slightly more frequent than duodenal, while the latter were more common than gastric ulcers in men. This and other figures and ratios in connection with site and sex do not differ materially from those usually quoted and adequately discussed by Ivy et al.

A higher incidence of ulcer in patients with rheumatic heart disease, viz., 25% compared to the average 17.5% in the series, has been noted, but it is felt that the numbers involved are insufficient for the finding to have any real significance.

The incidence of erosions in the present series in all post-mortems, 10.8%, is much higher than the highest figure occurring in literature, viz., 3.5% by Dittrich. The observation and recording of erosions is more liable to personal variation than the occurrence of peptic ulceration and may be vitiated by the co-existence of post-mortem change.

Summary.

1. The incidence of peptic ulceration in a series of 1,000 adult post-mortems over Age 10 was 17.5%, and in 509 children under that age it was 1%. There is a correspondingly high incidence of open lesions in adults, viz., 10.93%.
2. The G.U. : D.U. ratio was 1 : 1.14. The male : female ratio for all ulcers and scars was 1.8 : 1.
3. More than $33\frac{1}{3}\%$ of the ulcers were not diagnosed before death. In these cases peptic ulceration was an incidental finding at post-mortem.
4. A slightly higher incidence, viz., 25%, of peptic ulceration has been noted in cases of rheumatic heart disease.
5. The incidence of erosions in the series of 1,509 post-mortems of all ages was 10.8%.

Acknowledgments.

The investigations which form the basis of this thesis were carried out during the tenure of a McCunn Scholarship, 1949 - 1951. I wish to record my sincere thanks to the following: the Board of Management for Glasgow Northern Hospitals who granted me laboratory facilities at Stobhill General Hospital; Dr. J.C. Dick, Senior Pathologist to Glasgow Northern Hospitals for his helpful advice and criticism; Mr. H.W. Boot, lately Chief Technician in the Department of Pathology, Stobhill General Hospital, for invaluable technical advice, and to various clinicians and pathologists who provided the pathological material.

References.

- Brinkman, F. (1915) Beitrag zur statistik des runden Magengeschwurs.
Inang. Diss. Kiel.
- Dittrich (1847) Viertel Jahrschr.f.d. parkt. Heilk. Prag., 14, 167.
- Doll, R. & Jones, A.J. (1951) Occupational Factors in the Aetiology of Gastric and Duodenal Ulcers.
Medical Research Council Special Report Series No.276.
- Gruber, G.B. (1911) Munchen med. Wehnschr., 58, 1668 and 1730.
- Hurst, A.F. & Stewart, M.J. (1929) Gastric and Duodenal Ulcer. London. Oxford University Press.
- Ivy, A.C., Grossman, M.I. & Bachrach, W.H. (1950) Peptic Ulcer. J.S.A. Churchill. London.
- Jamieson, R.A., Smith, W.E. & Scott, L.D.W. (1949) British Medical Journal, 1, 298.
- Lehman, H. (1926) Mitt. a.d. Grenzgeb. d. Med. u. Chir., 39, 185.
- Musa, G. (1922) Arch.f.Verdaunungsschr., 29, 303.

Rutimeyer, L.

(1906) Über die geographische
Verbreitung und die Diagnose des
Ulcus Ventriculi Rotundum.

Wiesbaden.

Watkinson, G.

(1950/51) Gastroenterologia.

76, 6, 325.

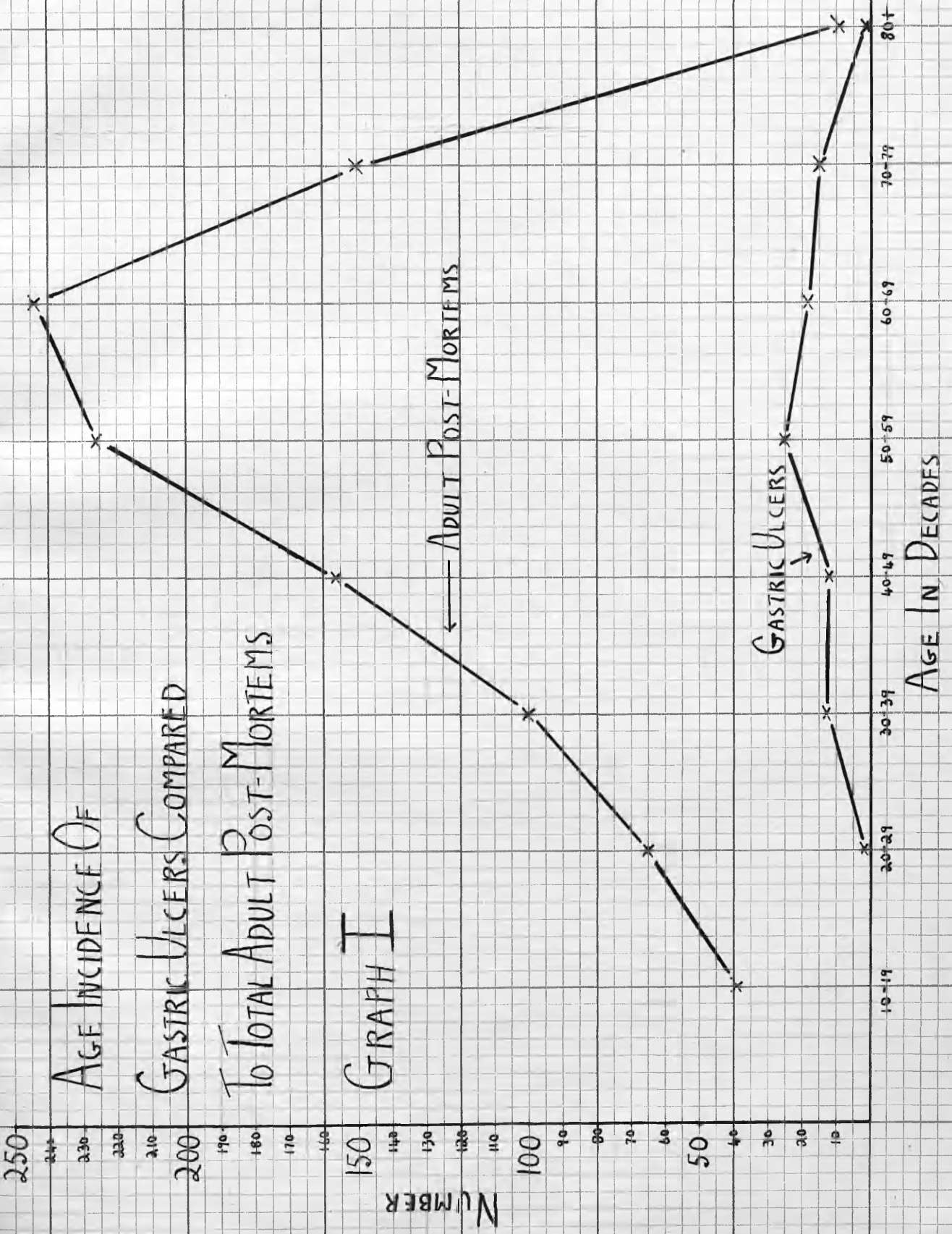
Welch, W.H.

(1894) Pepper's System of
Medicine. Philadelphia.

W.B. Saunders & Co., p.761.

AGE INCIDENCE OF GASTRIC ULCERS COMPARED TO TOTAL ADULT POST-MORTEMS

GRAPH I



250

240

230

220

210

200

190

180

170

160

150

140

130

120

110

100

90

80

70

60

50

40

30

20

10

NUMBER

AGE INCIDENCE OF DUODENAL ULCERS COMPARED TO TOTAL ADULT POST-MORTEMS

GRAPH II

← ADULT POST-MORTEMS

DUODENAL ULCERS



10-14

20-29

30-39

40-49

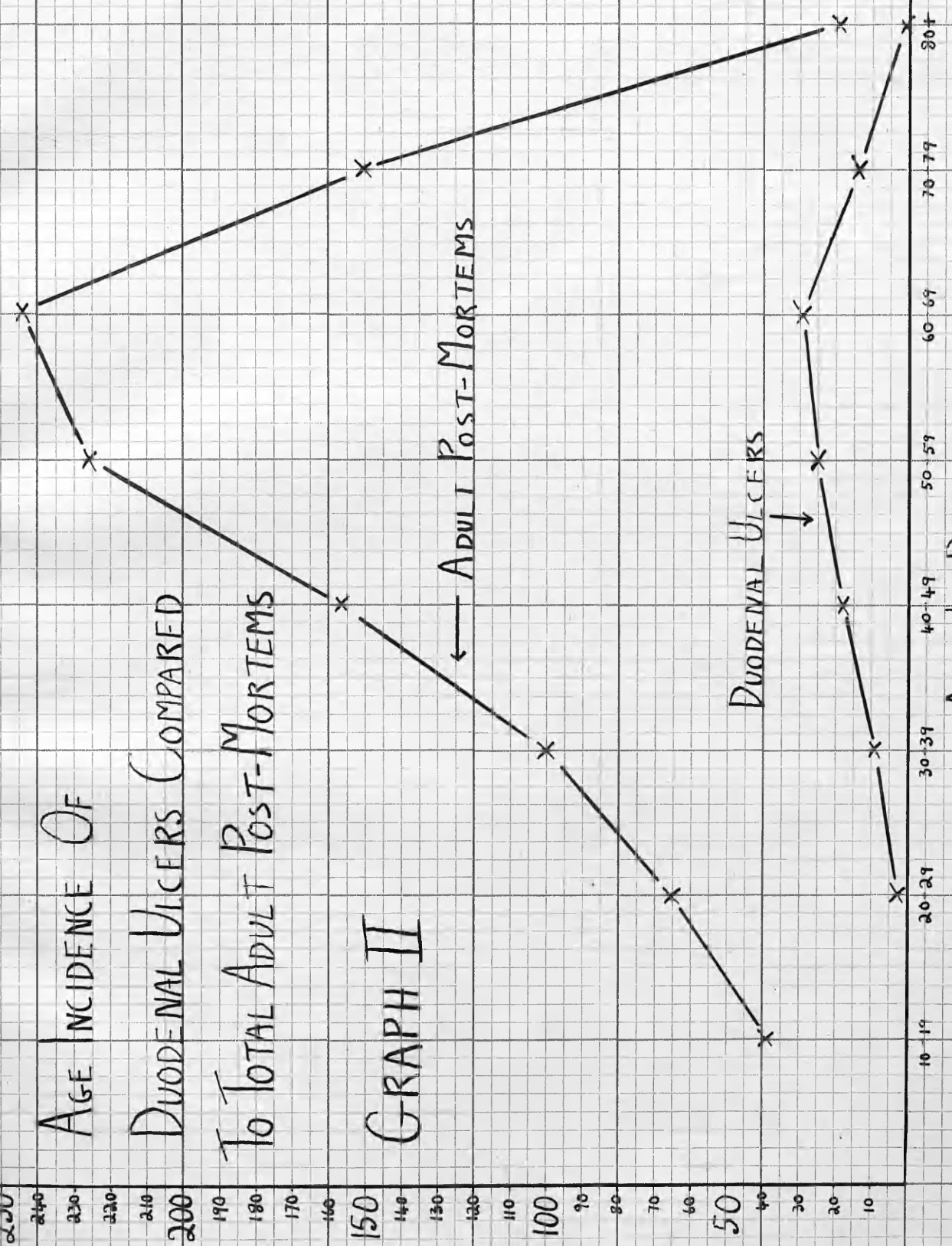
50-59

60-69

70-79

80+

AGE IN DECADES



Histological Studies of the Gastric Mucosa in
Peptic Ulceration and Gastric Carcinoma, and
Analysis of Post-Mortem Records in Relation
to Peptic Ulceration.

T H E S I S

submitted for the Degree of M.D.

at Glasgow University

by

Henry Thompson, M.B., Ch.B.

September, 1953.

Book II.

Microphotographs.

Microphotographs.

(Stain H. & E. except where otherwise
stated).

Fig.1.

Surface epithelium in case of acute gastritis showing several early inflammatory erosions with fibrino-leucocytic exudate streaming out from them. The lamina propria is filled with an acute inflammatory exudate containing a high proportion of polymorphs.

Specimen 184/51. Magnification 75.

Fig.2.

Acute gastritis showing marked surface epithelial changes and acute inflammatory infiltration into the lamina propria. One small erosion is also present.

Specimen 1204/50. Magnification 100.

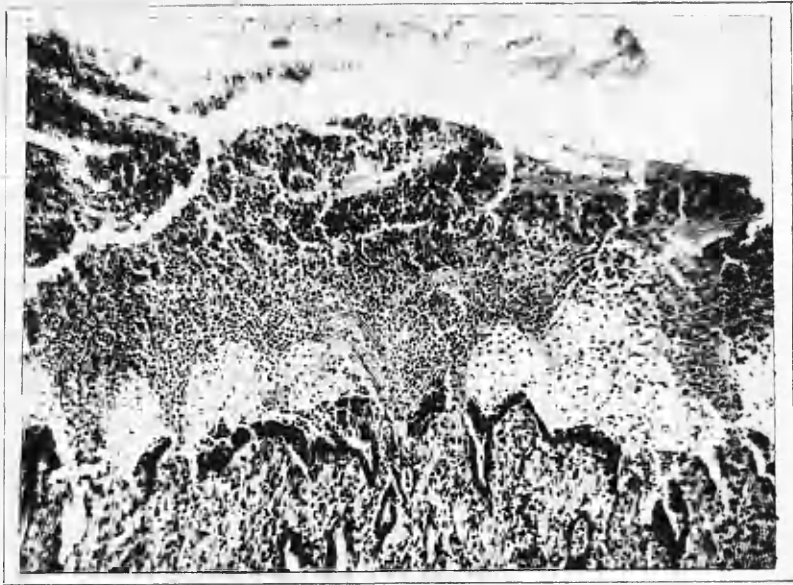


Fig. 1

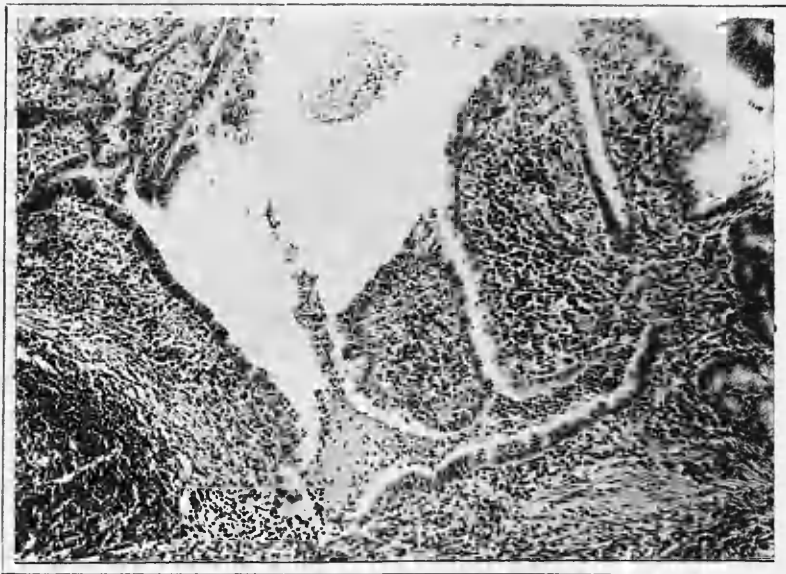


Fig 2

Fig.3.

Higher magnification of Fig.2 showing surface epithelial changes, particularly polymorphonuclear exudation.

Specimen 1204/50. Magnification 450.

Fig.4.

Interstitial inflammatory exudate in acute gastritis showing a high proportion of polymorphs.

Specimen 1076/51. Magnification 400.

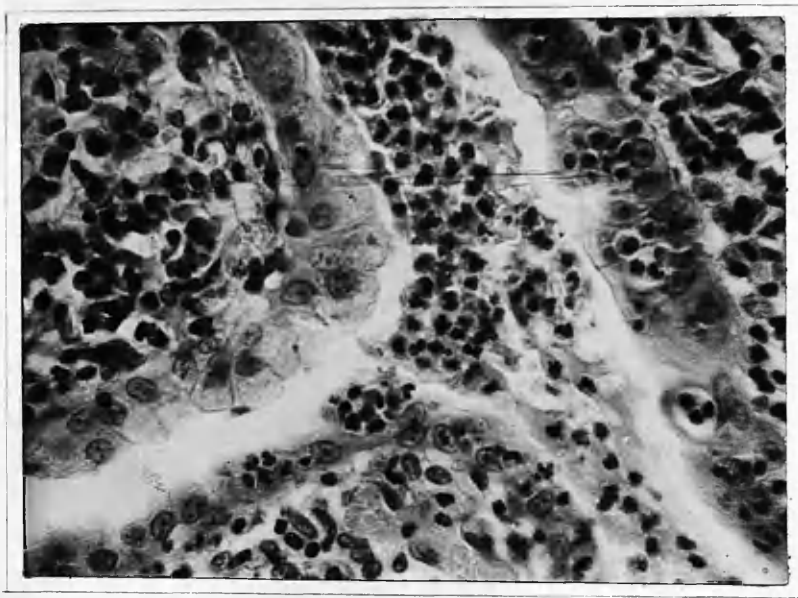


FIG. 3

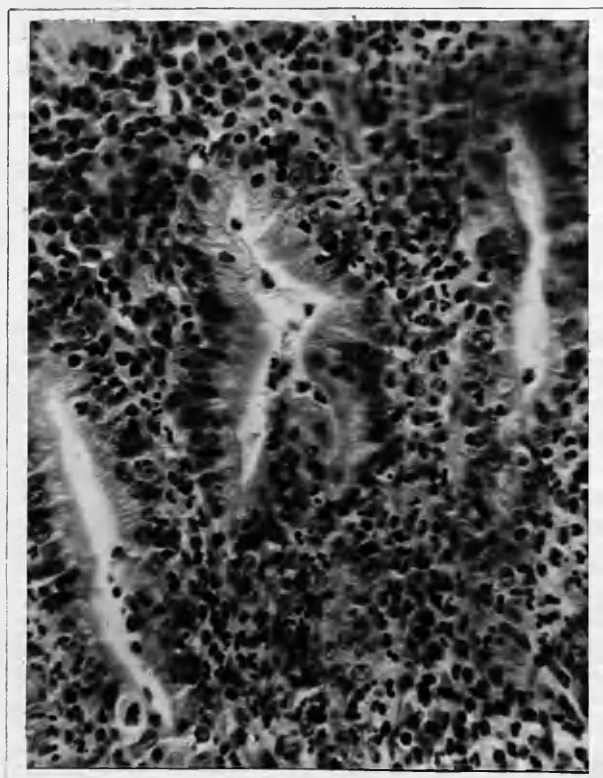


FIG. 4

Fig.5.

Focal accumulation of polymorphs like a tiny abscess occurring in the interstitial tissue in acute gastritis.

Specimen 1293/51. Magnification 400.

Fig.6.

Focal inflammatory infiltration at the base of the body mucosa in subacute gastritis. Note also acute inflammatory changes in muscularis mucosa and submucosa.

Specimen 1660/51. Magnification 100.

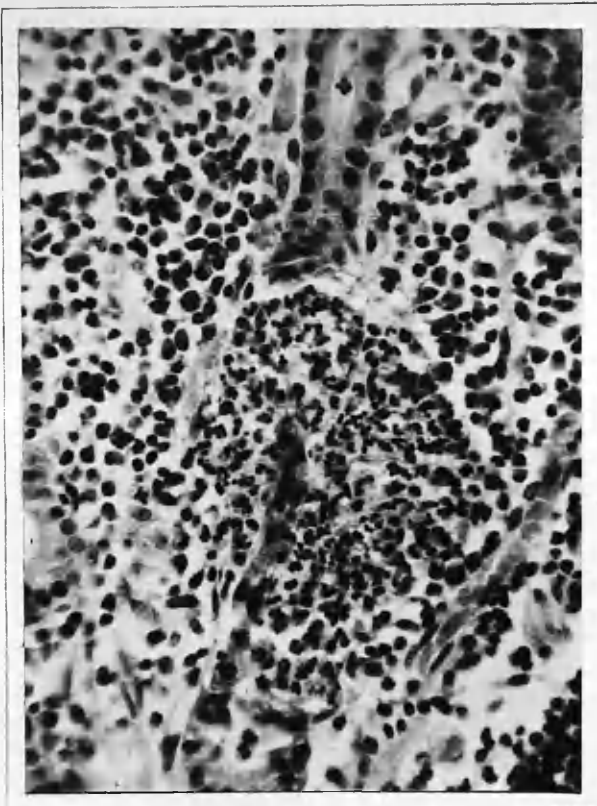


Fig. 5

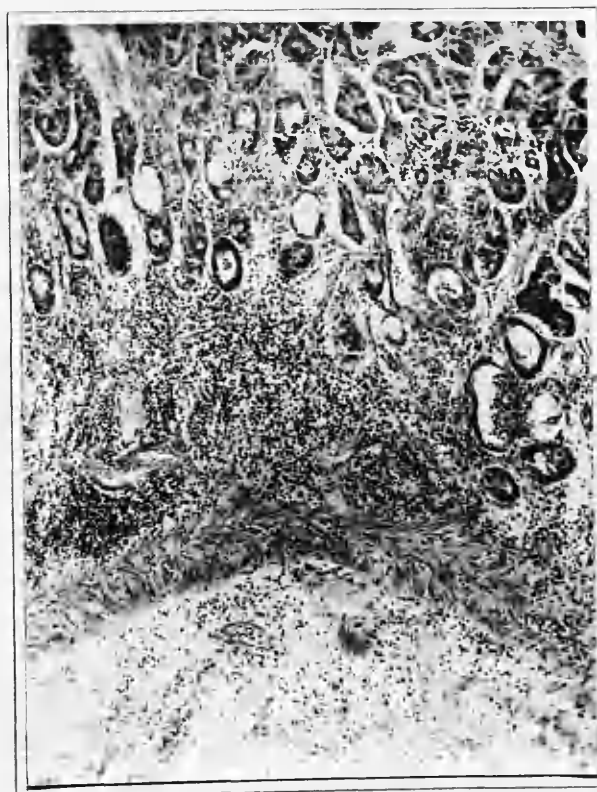

Fig. 6

Fig.7.

Polymorphs in ducts in case of acute gastritis.

Specimen 184/51. Magnification 100.

Fig.8.

Reduplication and syncytial appearance of the surface epithelium in case of acute gastritis.

Specimen 1204/50. Magnification 400.

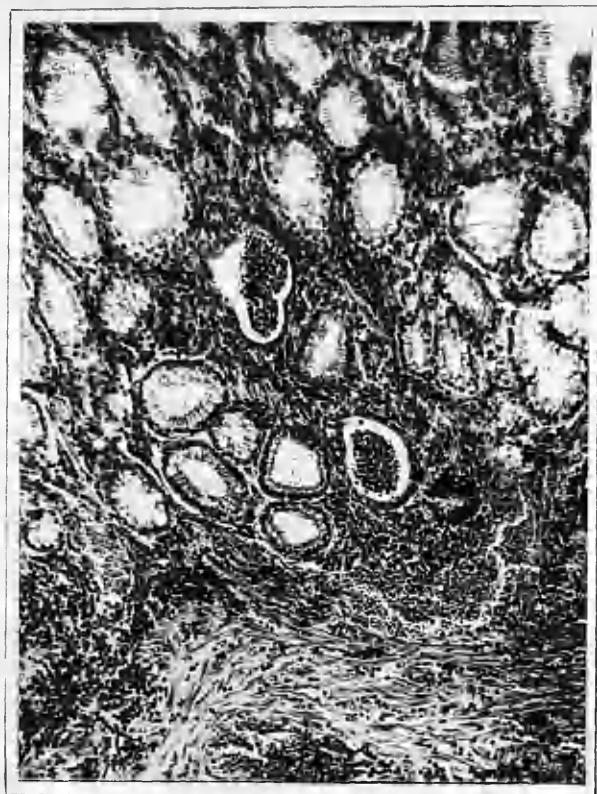

Fig. 7

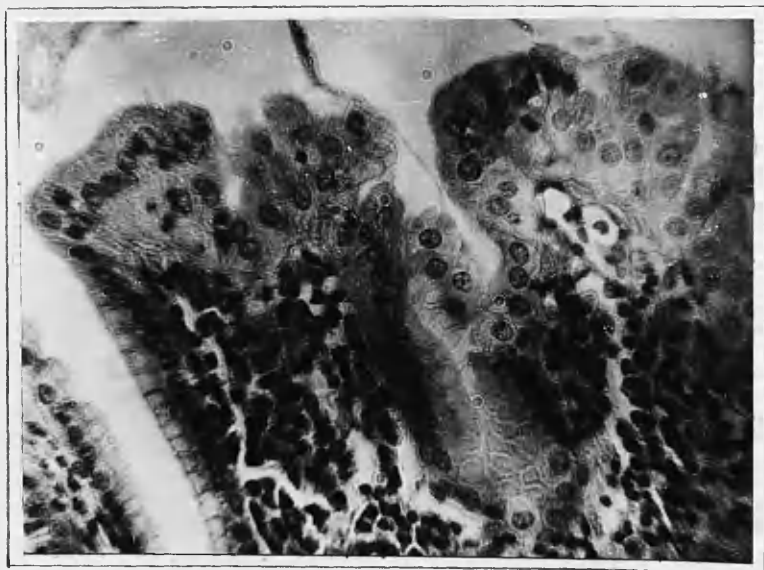


Fig. 8

Fig.9.

Normal surface epithelium of the stomach present in both the body and the pyloric region.

Specimen 1382/50. Magnification 400.

Fig.10.

A portion of degenerate epithelium of gland or duct origin is seen here surrounded by polymorphs and other inflammatory cells in case of acute gastritis.

Specimen 184/51. Magnification 100.

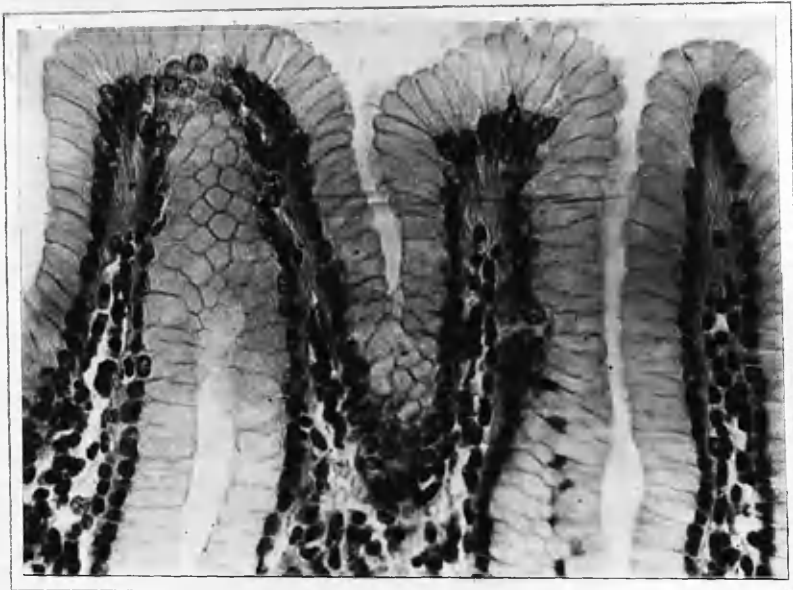


Fig. 9



Fig. 10

Figs.11 and 12.

Higher magnifications of erosions seen in Fig.1 to show the exudate of fibrin and leucocytes streaming out from the interstitial tissues through a defect in the surface epithelium.

Specimen 184/51. Magnification 400.

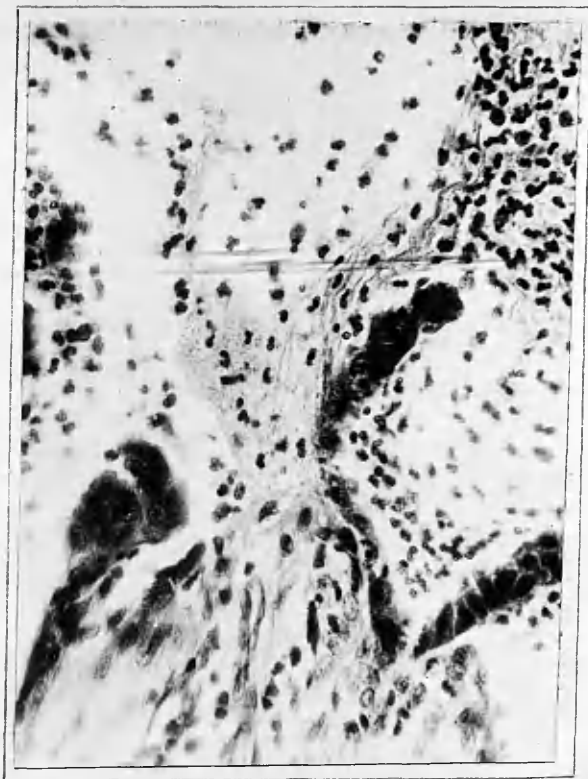

Fig. 11




Fig. 12

Fig.13.

Higher magnification of erosions seen in Fig.1 to show the exudate of fibrin and leucocytes streaming out from the interstitial tissues through a defect in the surface epithelium.

Specimen 184/51. Magnification 400.

Fig.14.

Two early inflammatory erosions in case of acute gastritis showing slight loss of tissue. The exudate contains fewer polymorphs than the previous examples.

Specimen 1076/51. Magnification 50.

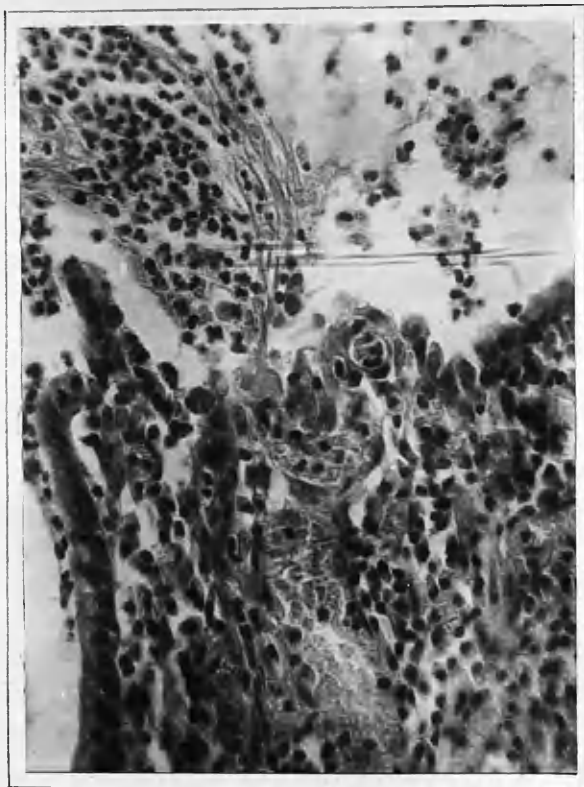


Fig. 13

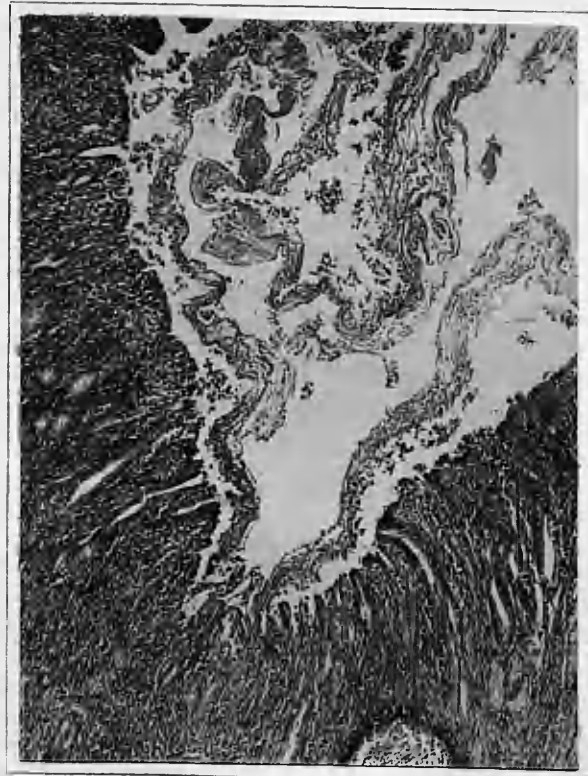

Fig. 14

Fig.15.

An acute inflammatory erosion occurring in a large duct in a case of subacute gastritis.

Specimen 49/51. Magnification 100.

Fig.16.

Acute inflammatory erosion occurring in the duodenum with loss of mucosal tissue.

Specimen 526/49. Magnification 100.

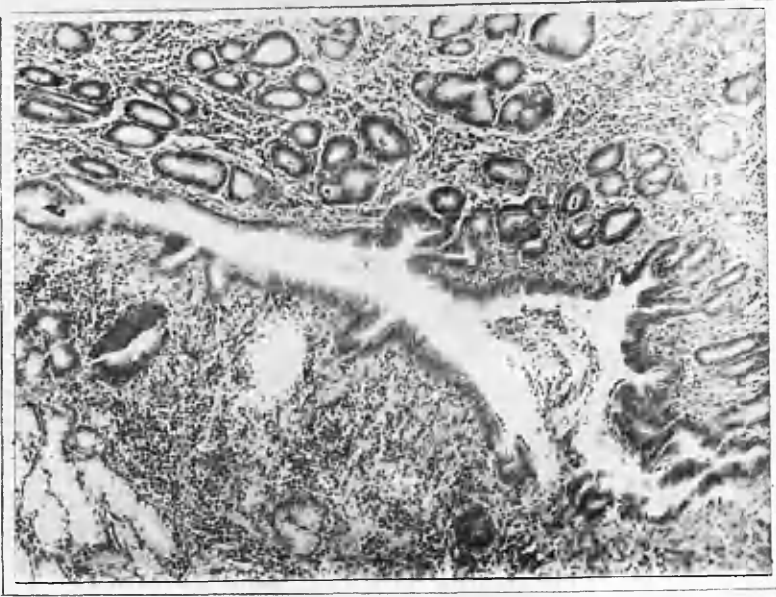


Fig. 15

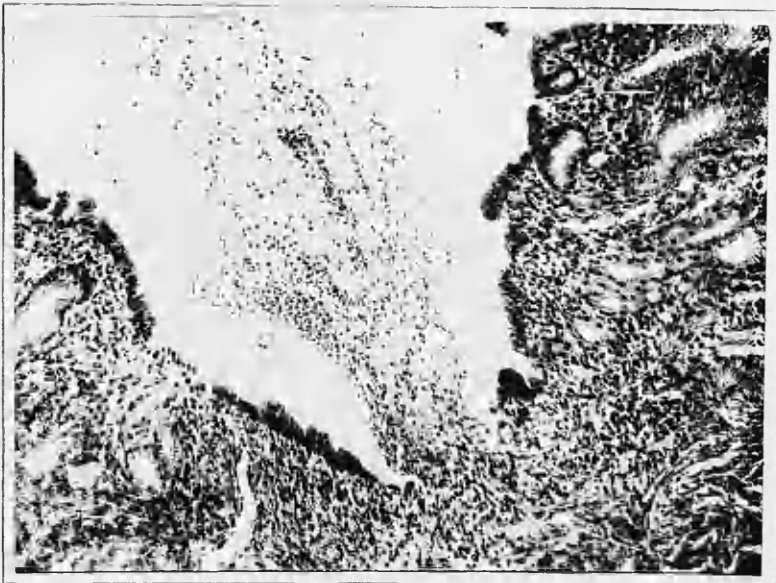


Fig. 16

Fig.17.

Acute inflammatory erosion occurring over a gastric ulcer scar (not visible in photograph) indicating repetition of events.

Specimen 888/48. Magnification 400.

Fig.18.

Inflammatory erosion in case of subacute gastritis showing fibrinoid exudate and cellular infiltration in its floor. A loose inverted portion of mucosa is also seen overlying the lesion.

Specimen 2468/49. Magnification 50.

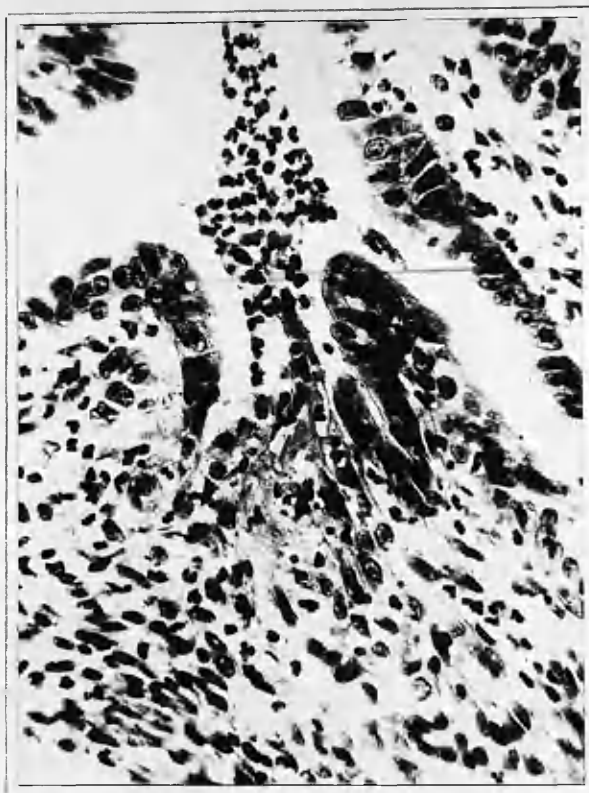

Fig. 17

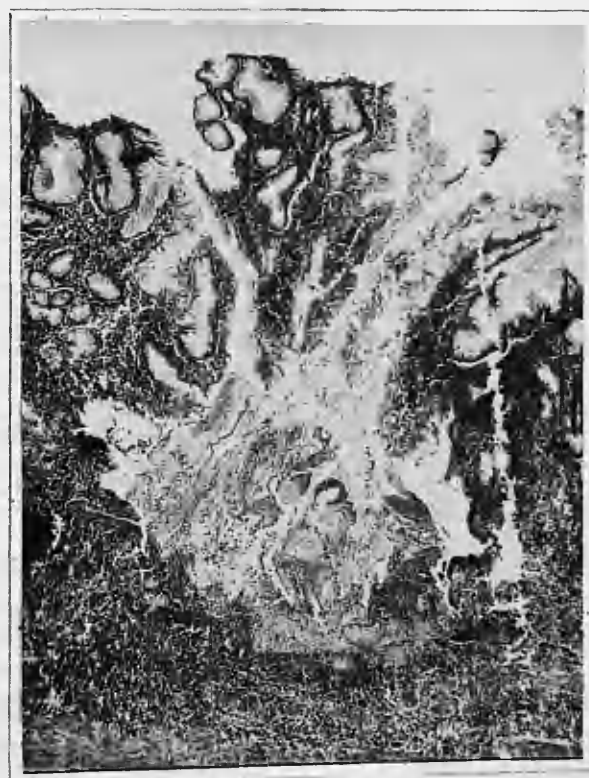

Fig. 18

Fig.19.

Healing erosion of the pyloric end of the stomach in case of acute gastritis with regenerating epithelium partially covering its floor. All the glands in the base of the erosion have been destroyed by the inflammatory process and only one duct remains. Regenerating mucous glands are present at the edges of the erosion.

Specimen 1141/50. Magnification 50.

Fig.20.

Healing erosion of pyloric end of stomach in acute gastritis.

Specimen 184/51. Magnification 75.



Fig. 19



Fig. 20

Fig.21.

Healed erosion in case of subacute gastritis
with recrudescence of inflammation.

Specimen 2344/49. Magnification 75.

Fig.22.

An erosion of the body of the stomach in case
of acute gastritis showing activity at the left
hand side and an undermined portion of the
mucosa in the centre.

Specimen 1076/51. Magnification 25.

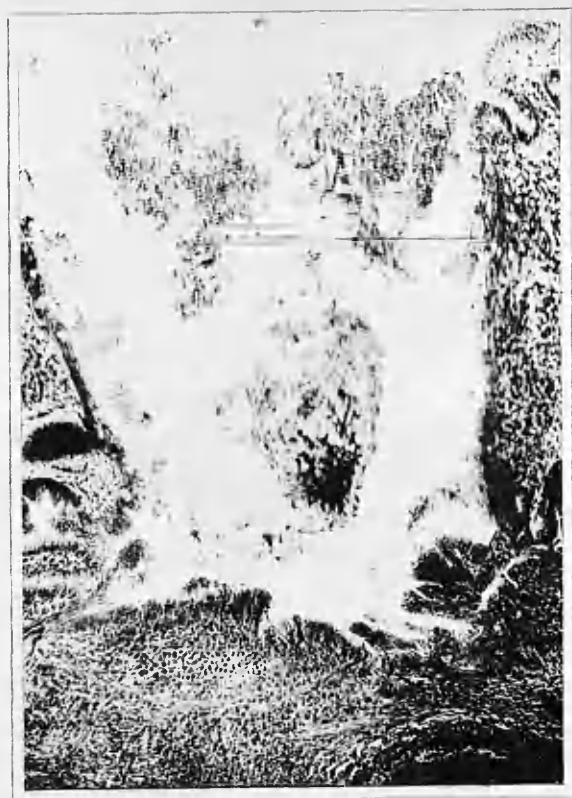

Fig. 21




Fig. 2.2

Fig.23.

An erosion in the duodenum in case of acute gastritis showing early healing stage; activity is still seen at the left hand side of the lesion.

Specimen 1076/51. Magnification 75.

Fig.24.

Subacute gastritis in body of the stomach with marked cellular infiltration and oedema, especially in the gastric processes. Note slight oedema in submucosa also.

Specimen 1266/50. Magnification 75.

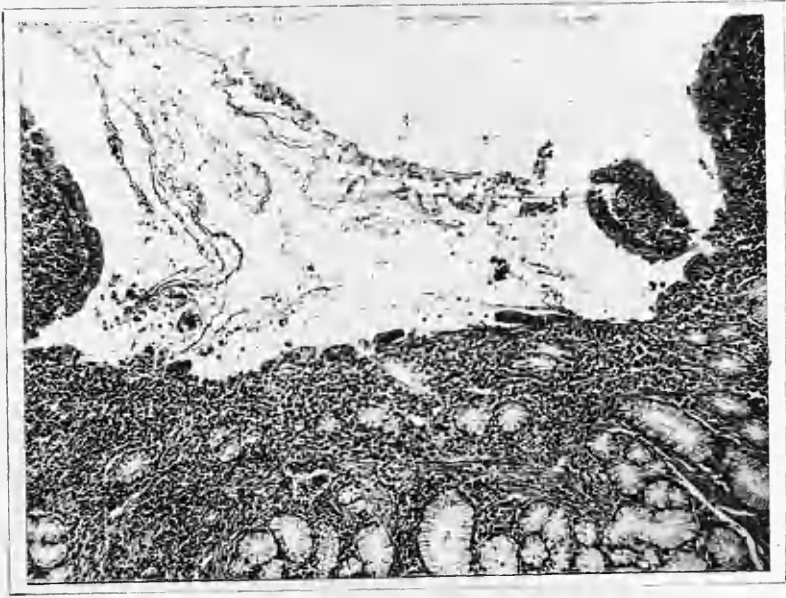

FIG. 23

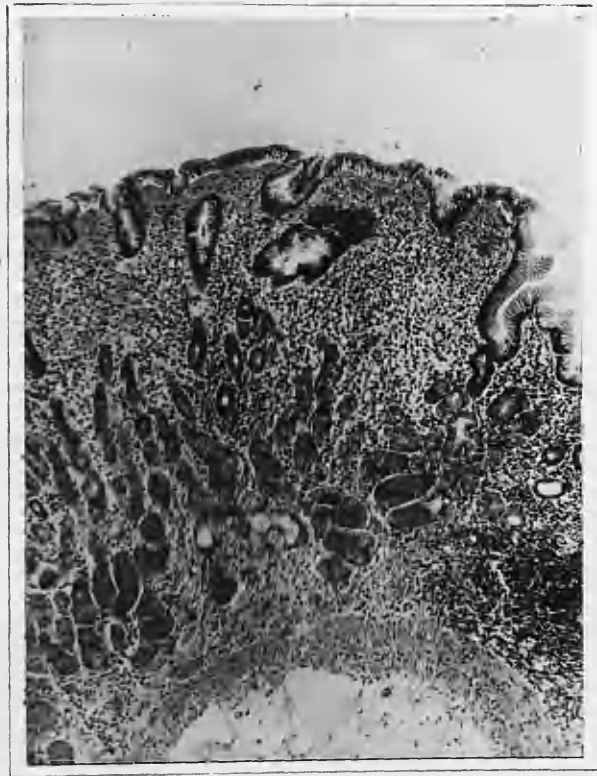


FIG. 24

Fig.25.

Epithelial changes and subepithelial cellular infiltration in case of subacute gastritis. Surface epithelium is cuboidal and shows emigration of round cells and occasional polymorphs. The cellular infiltration consists of lymphocytes, plasma cells, polymorphs and eosinophils.

Specimen 2629/49. Magnification 400.

Fig.26.

Oedema, epithelial changes and subepithelial cellular infiltration in subacute gastritis.

Specimen 1498/49. Magnification 400.

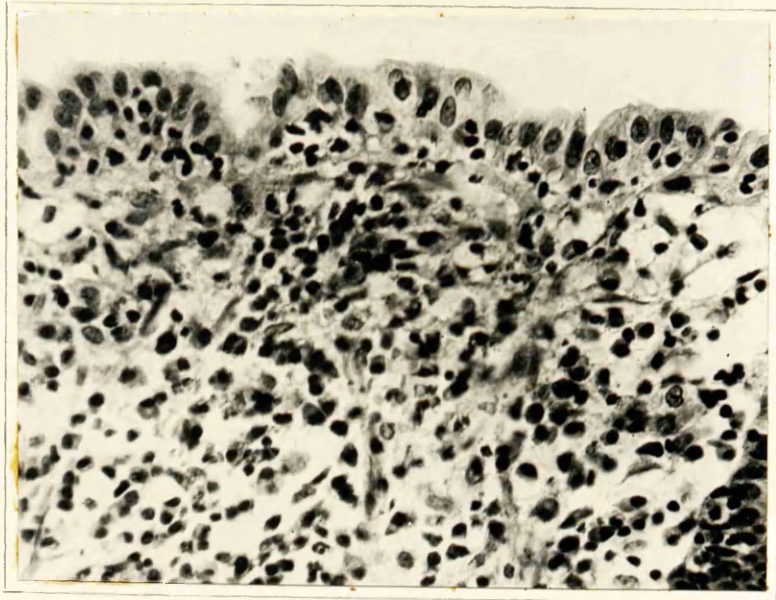


Fig. 25

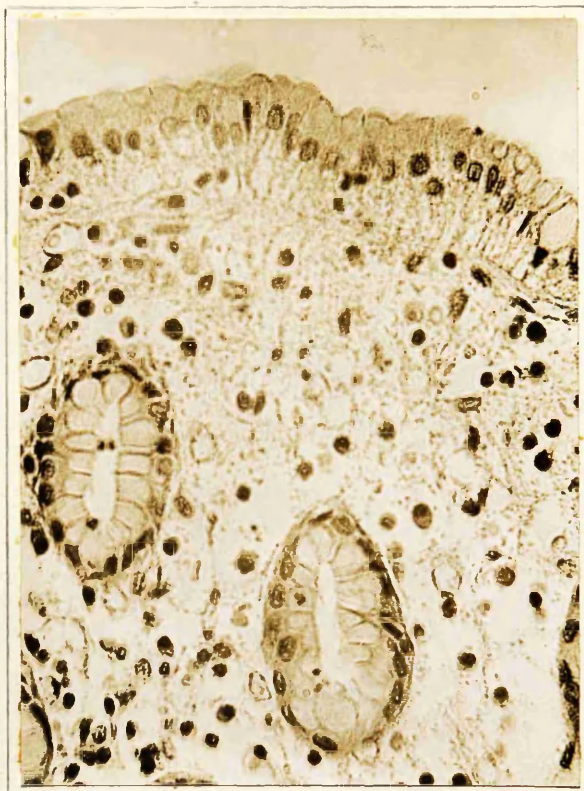

Fig. 26

Fig.27.

Chronic gastritis showing heterotopia, marked glandular atrophy and papillomatous surface epithelial proliferation. The heterotopia consists in the presence of cysts in the mucosa, muscularis mucosa and submucosa.

Specimen 434/51. Magnification 50.

Fig.28.

Chronic gastritis showing almost complete glandular atrophy, intestinal metaplasia and slight hypertrophic changes.

Specimen 1233/50. Magnification 25.

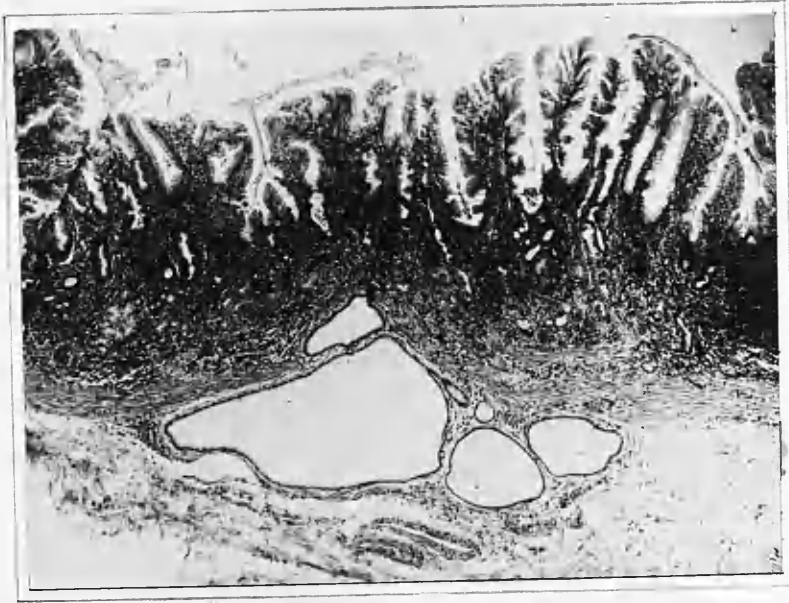


Fig. 27

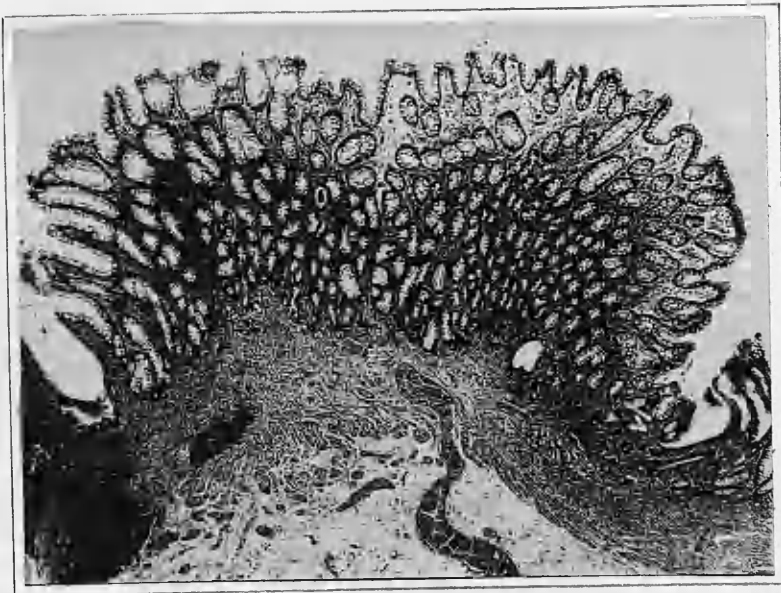


Fig. 28

Fig.29.

Chronic gastritis with localised hypertrophic changes in the surface epithelium and ducts of the pyloric region. This is a form of état mammellonné.

Specimen 456/51. Magnification 25.

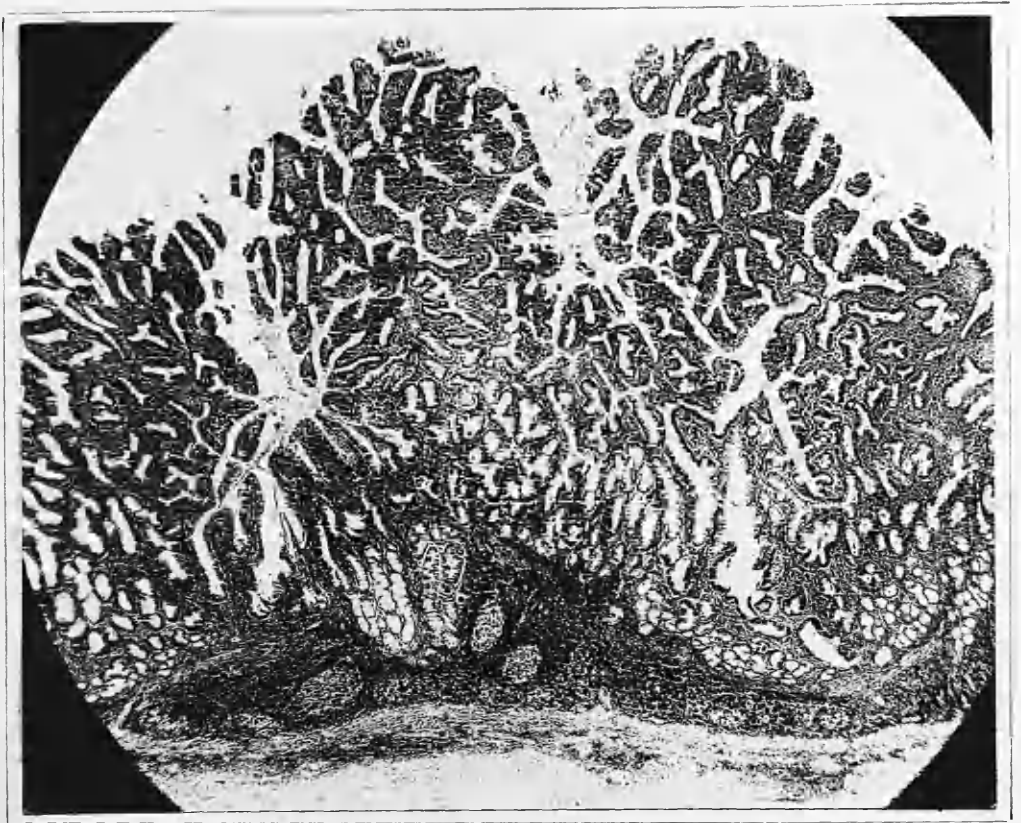


Fig. 29

Fig.30.

Chronic gastritis showing complete glandular atrophy with replacement fibrosis in the region previously occupied by pyloric glands.

Specimen 620/51. Magnification 25.

Fig.31.

Chronic gastritis showing severe glandular atrophy, marked cellular infiltration and numerous lymph follicles.

Specimen 1298/49. Magnification 25.



Fig. 30




Fig. 31

Fig.32.

Chronic gastritis with marked glandular atrophy and intestinal metaplasia.

Specimen 73/51. Magnification 25.

Fig.33.

Chronic gastritis showing marked cellular infiltration and numerous lymph follicles.

Specimen 0284/51. Magnification 25.

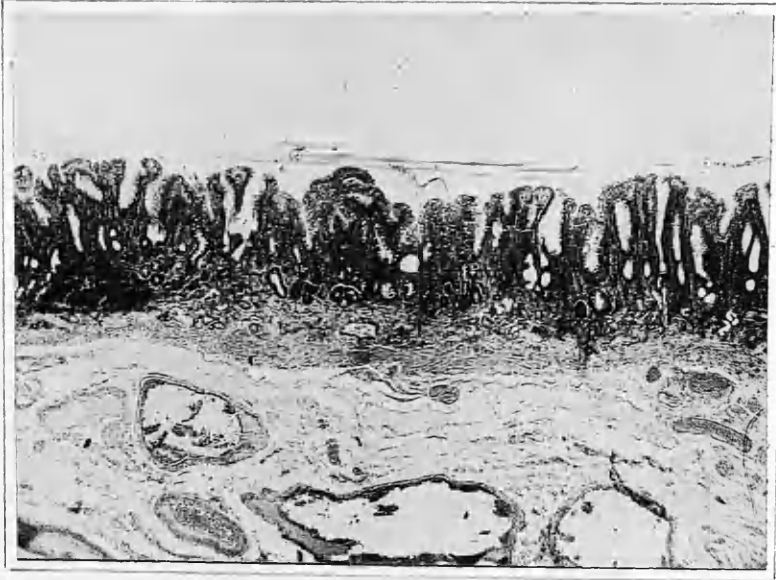

FIG. 32




FIG. 33

Fig.34.

Chronic gastritis with état mammellonné of the diffuse type in the pyloric region. Slight glandular atrophy is also present.

Specimen 2629/49. Magnification 25.

Fig.35.

Pyloric region of stomach showing normal distribution of pyloric glands.

Specimen 165/51. Magnification 25.

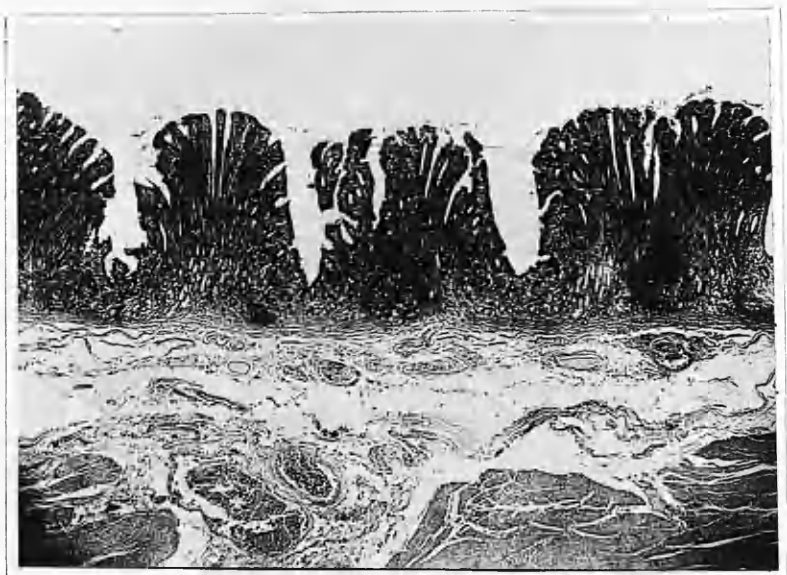


FIG. 34

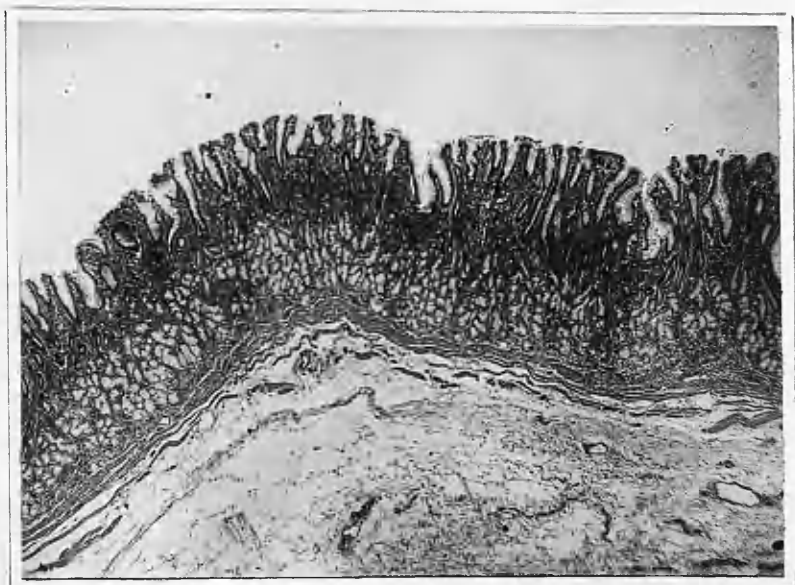


FIG. 35

Fig.36.

Chronic gastritis with marked cellular infiltration, lobulation of pyloric glands and heterotopia. The arrangement of the glands gives the mucosa a duodenal appearance.

Specimen 1204/50. Magnification 25.

Fig.37.

Chronic gastritis with diffuse hypertrophic changes in the pyloric region. Marked cellular infiltration, numerous lymph follicles, hyperplasia of duct and gland epithelium combine to produce a hypertrophic appearance of the mucosa. Cellular infiltration and early fibrosis of the muscularis mucosa[^] are also present.

Specimen 456/51. Magnification 25.



FIG 36

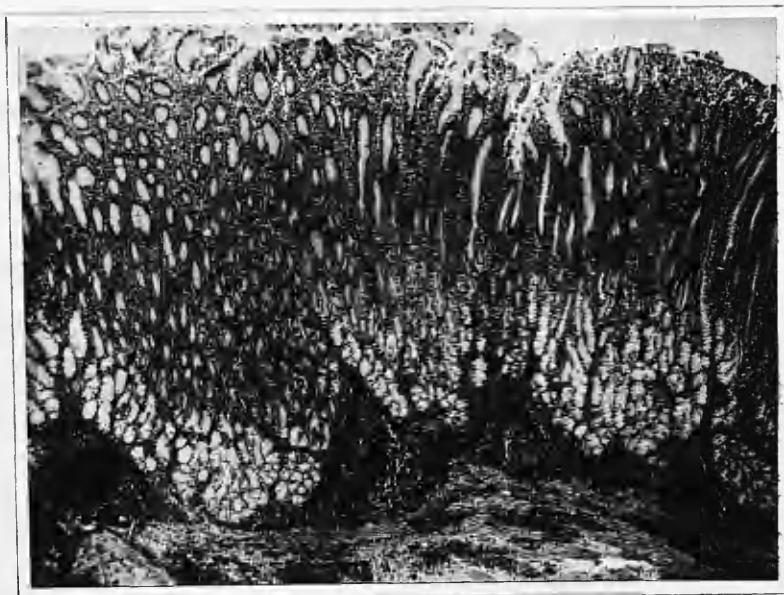


FIG. 37

Fig.38.

Glandular heterotopia in chronic gastritis with a lobule of pyloric glands in the submucosa.

Specimen 434/51. Magnification 50.

Fig.39.

Chronic gastritis with cysts of the ducts and glands.

Specimen 434/51. Magnification 50. 25.

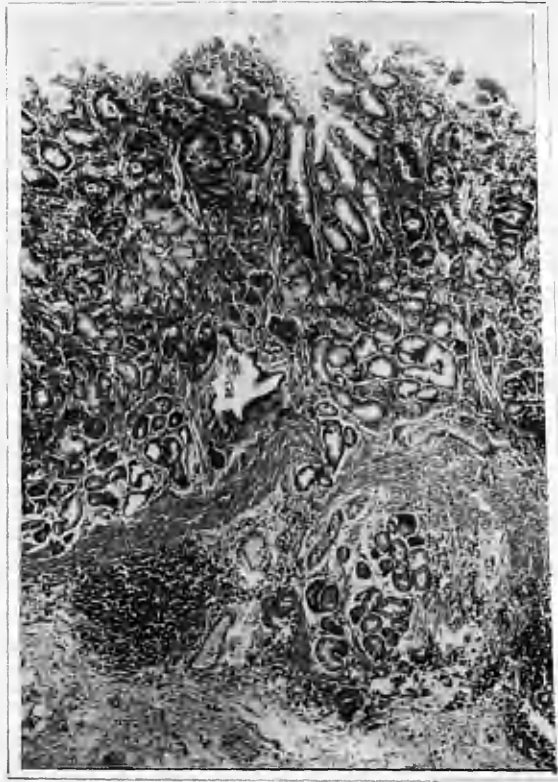


FIG. 38

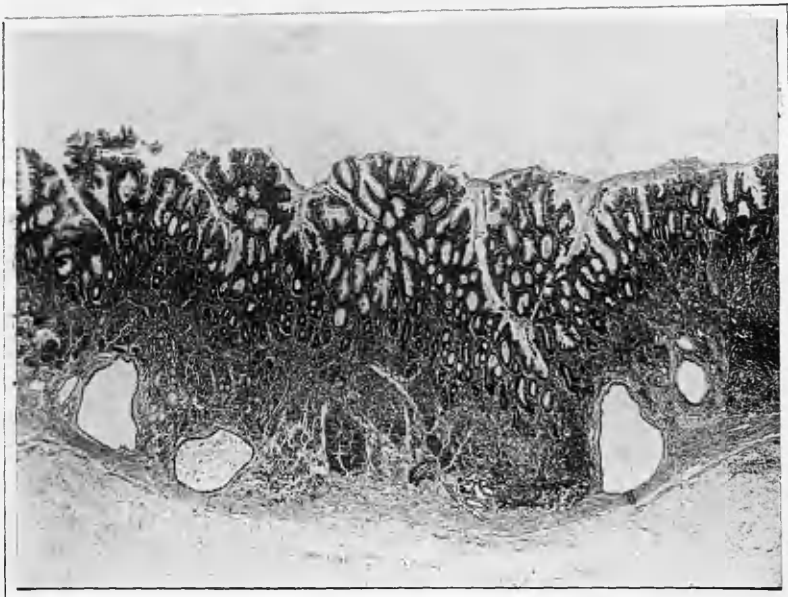


FIG. 39

Fig.40.

Cellular infiltration in chronic gastritis.
Note predominance of plasma cells and
lymphocytes.

Specimen 2469/50. Magnification 400.

Fig.41.

Russel's bodies in case of chronic gastritis.

Specimen 2438/49. Magnification 400.

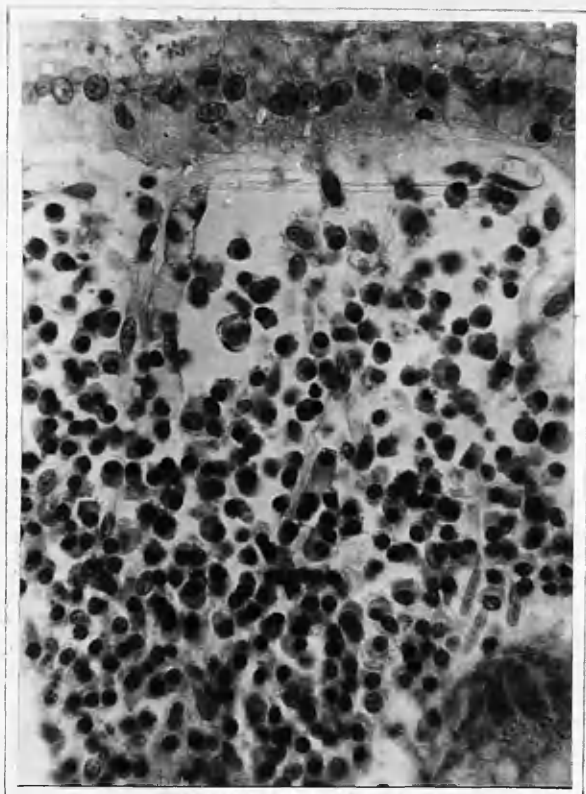


Fig. 40

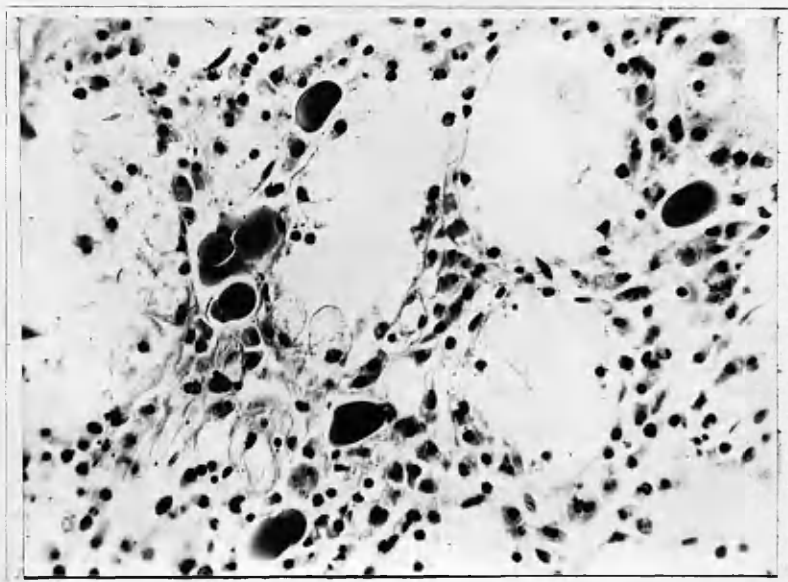


Fig. 41

Fig.42.

Chronic gastritis with submucous fibrosis
and myxomatous change.

Specimen 1204/50. Magnification 5.

Fig.43.

Chronic atrophic diffuse gastritis showing
atrophy of the specialised zymogenic-
oxyntic cell glands, replacement by pseudo-
pyloric glands and intestinal metaplasia.

Specimen 2624/49. Magnification 25.

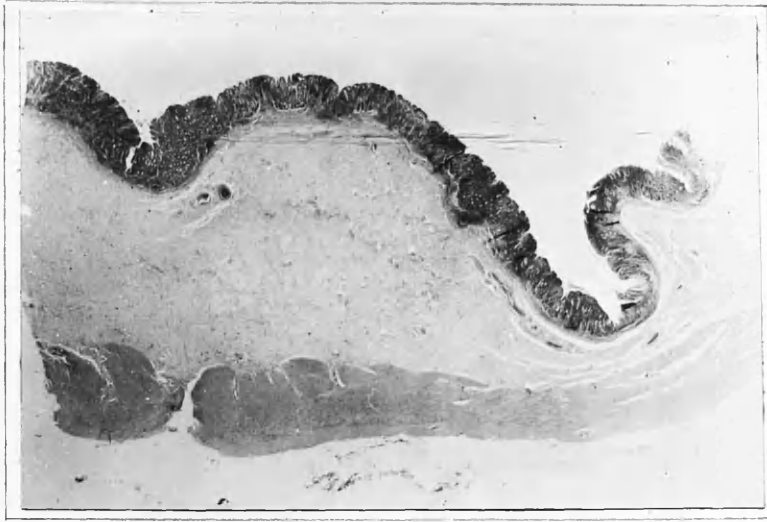


FIG. 42

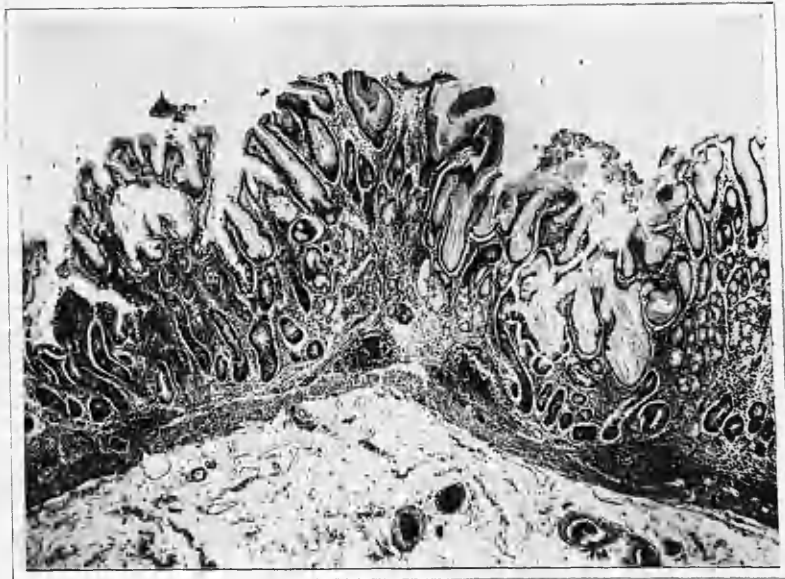


FIG. 43

Fig.44.

Higher magnification of Fig.43 emphasising the severe glandular atrophy.

Specimen 2624/49. Magnification 50.

Fig.45.

Normal structure of the body of the stomach showing tubular glands, occasional lymph follicles and minimal cellular infiltration.

Specimen 2202/49. Magnification 25.

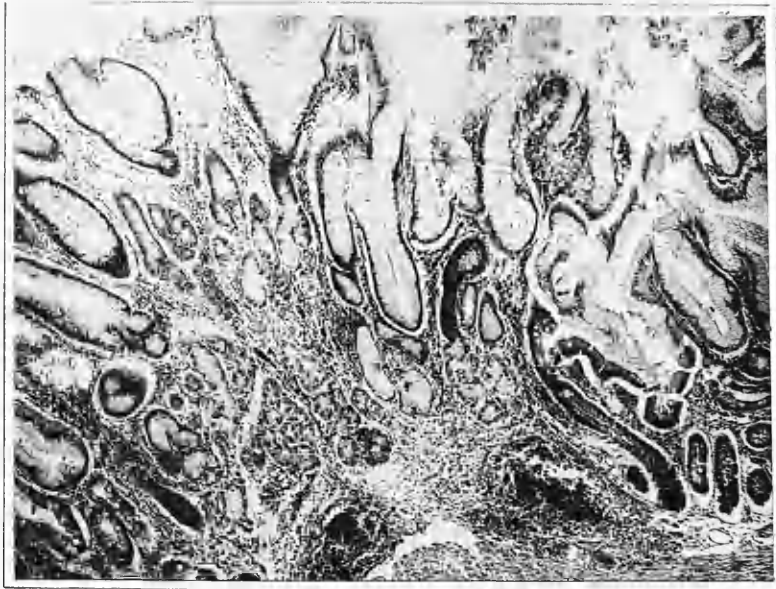

FIG. 44

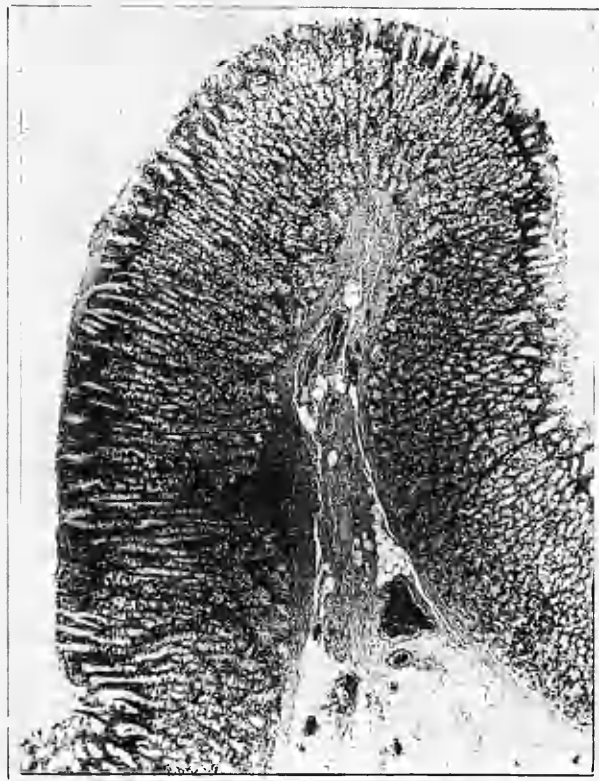


FIG. 45

Fig.46.

Higher magnification of Fig.45 showing tubular glands with oxyntic cells in the upper parts and zymogenic cells at the base.

Specimen 2202/49. Magnification 75.

Fig.47.

Acute inflammatory erosion occurring in case of gastric carcinoma. Mucus secreting adenocarcinoma cells are seen in the base of the erosion.

Specimen 1089/51. Magnification 75.



FIG. 46

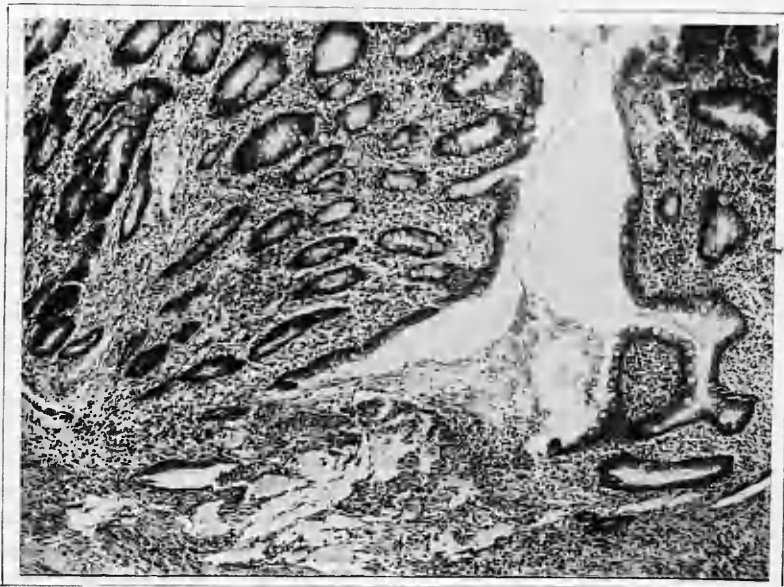


FIG. 47

Fig.48.

Acute gastric ulcer showing a breach of mucosa involving the muscularis mucosa with a fibrino-leucocytic exudate streaming out from the ulcer floor. This is a transition stage between an erosion and an acute peptic ulcer.

Specimen 1340/50. Magnification 25.

Fig.49.

Haemorrhagic erosion of the body of the stomach with recent blood clot in the mucosal defect. No inflammatory cellular infiltration is present in the immediate vicinity of the lesion.

Specimen 63/49. Magnification 75.



FIG. 48



FIG. 49

Fig.50.

Haemorrhagic erosion with blood clot and loose portion of mucosa in the resulting defect.

Specimen 453/49. Magnification 25.

Fig.51.

Haemorrhagic erosion showing defect in the mucosa and a few red blood cells at the edges.

Specimen 2202/49. Magnification 75.

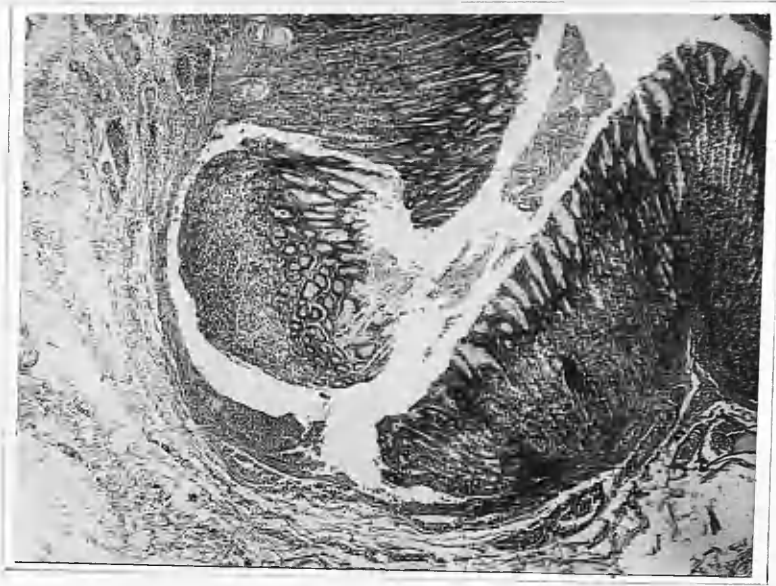


FIG. 50



FIG. 51

Fig. 52.

Goblet cells in area of intestinal metaplasia.
Note absence of these cells in normal mucosa
at the left side. (MUCICARMINE.)

Specimen 2468/49. Magnification 25. 75.

Fig. 53.

Islet of intestinal metaplasia with argentaffine
cells. (JACOBSON'S STAIN.)

Specimen 1233/50. Magnification 75.




Fig. 52

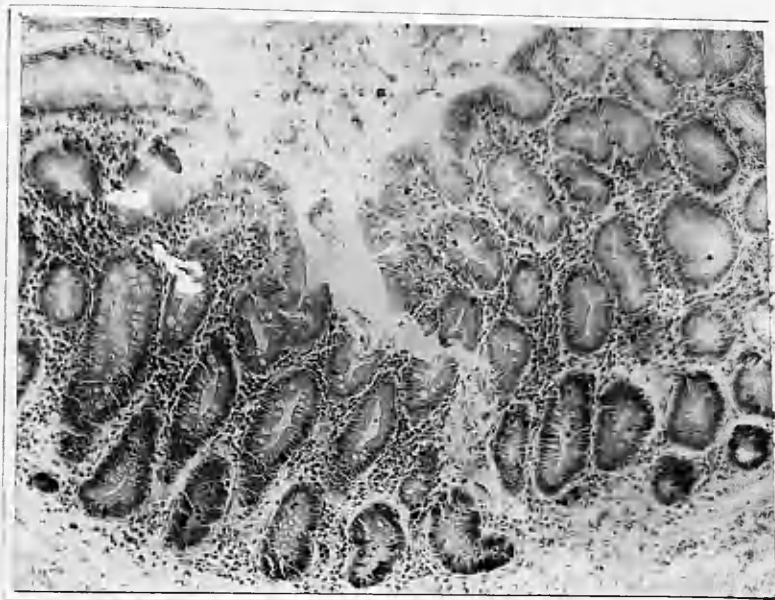

Fig. 53

Fig.54.

Higher magnification of argentaffine cells.
Note fine subnuclear granules. (JACOBSON'S STAIN)

Specimen 2468/49. Magnification 400.

Fig.55.

Islet of intestinal metaplasia with Paneth
cells distributed at the base as in crypts
of Lieberkuhn. (MALLORY'S PHOSPHOTUNGSTIC ACID HAEMATOXYLIN)

Specimen 620/51. Magnification 100.

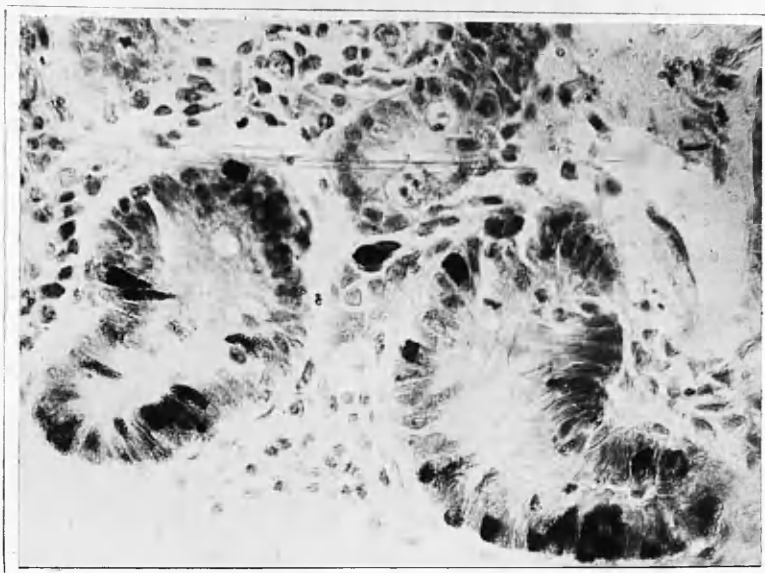


Fig. 54

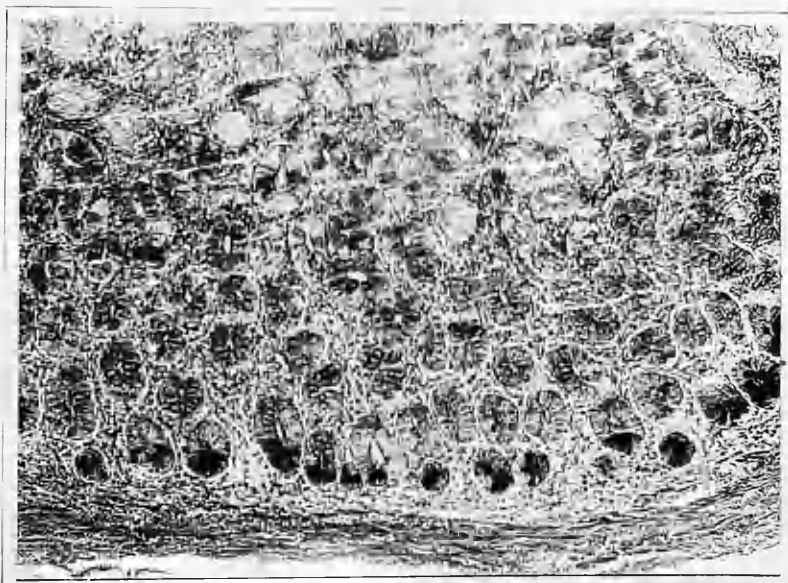


Fig. 55

Fig.56.

Higher magnification of Paneth cells in an islet of intestinal metaplasia. Note large dense supranuclear granules. (MALLORY'S PHOSPHOTUNGSTIC ACID HAEMATOXYLIN)

Specimen 921/49. Magnification 500.

Fig.57.

Chronic gastric ulcer showing gap in muscle layer and well formed peritoneal adhesion.

Specimen 2437/49. Magnification 5.

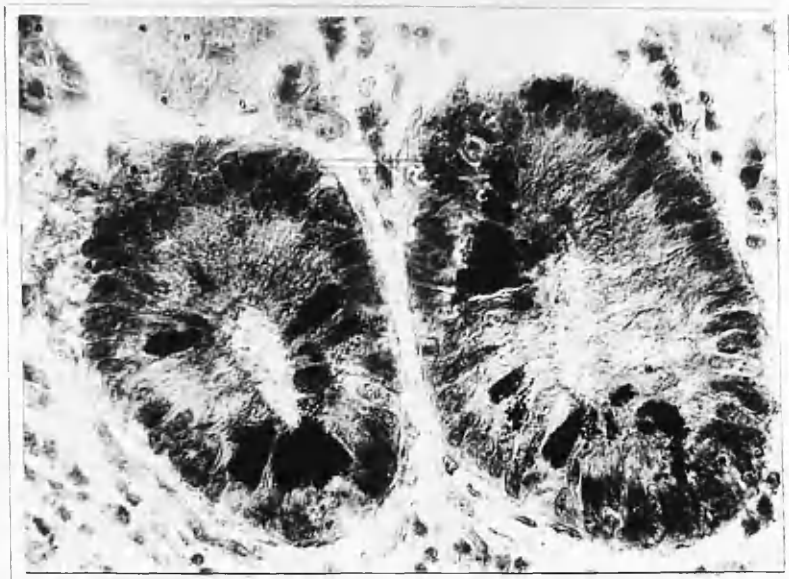

Fig. 56

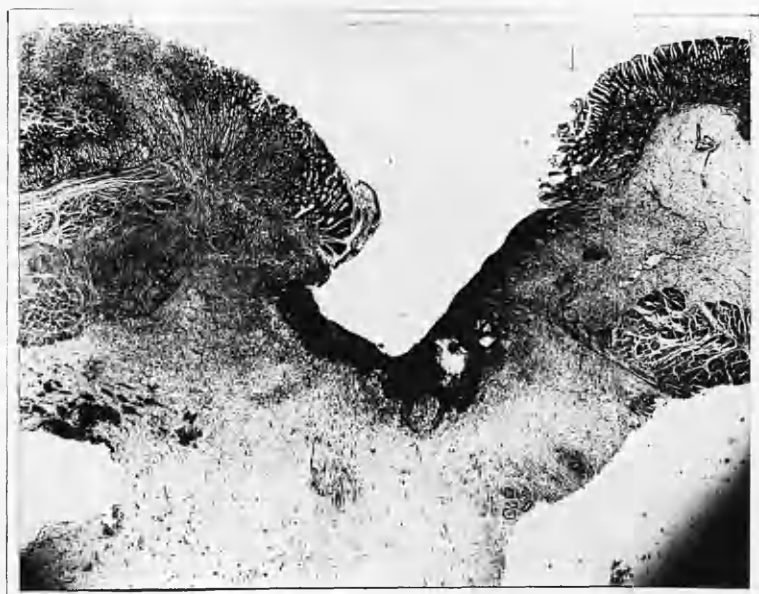


Fig. 57

Fig.58.

Chronic duodenal ulcer showing penetration of the muscle layer and thickening of the peritoneum. The pyloric muscle is at the right side, the ulcer being just beyond it.

Specimen 2660/49. Magnification 5.

Fig.59.

Chronic gastric ulcer scar showing a defect in the muscle layer replaced by fibrous tissue. A small mucosal polyp is present on the surface.

Specimen 184/51. Magnification 5.

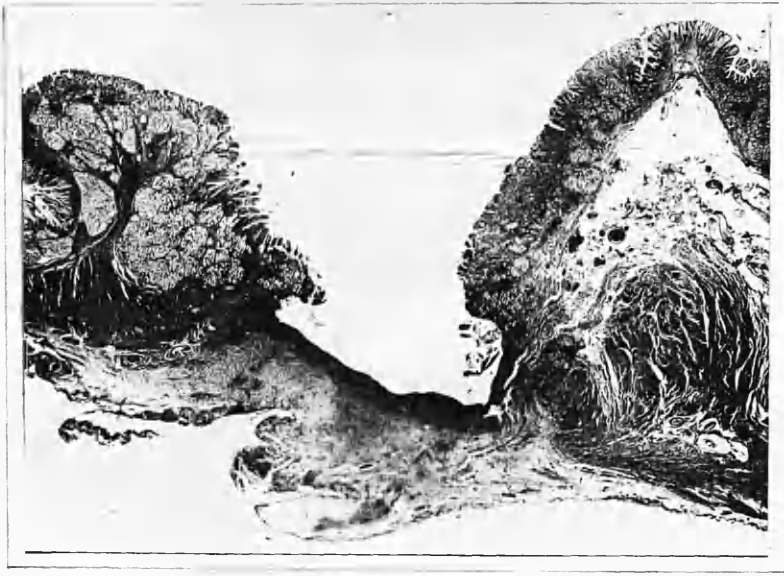


Fig. 58



Fig. 59

Fig.60.

Acute jejunal ulcer. This ulcer is in a more advanced stage than the one shown in Fig.48.

Specimen 1147/51. Magnification 25.

Fig.61.

Subacute gastric ulcer showing fibrosis in the submucosa and an intact muscle layer.

Specimen 1141/50. Magnification 25 (APPROX.)

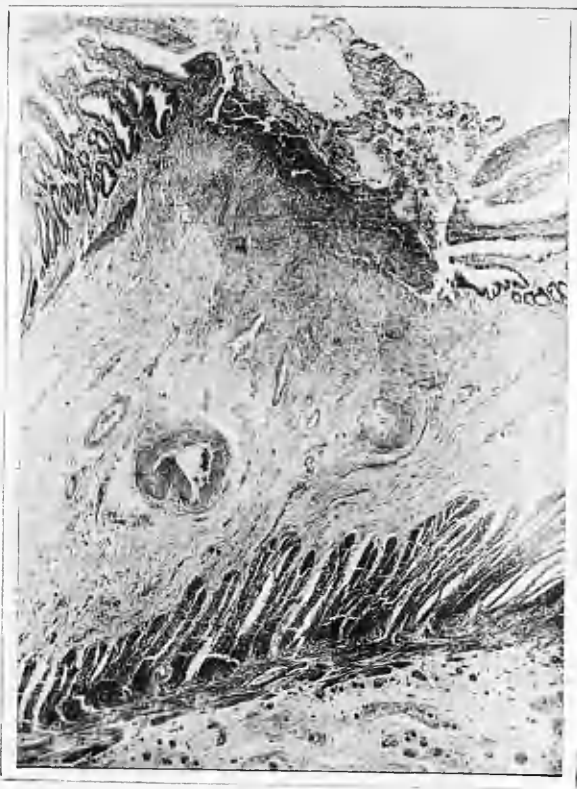

Fig. 60

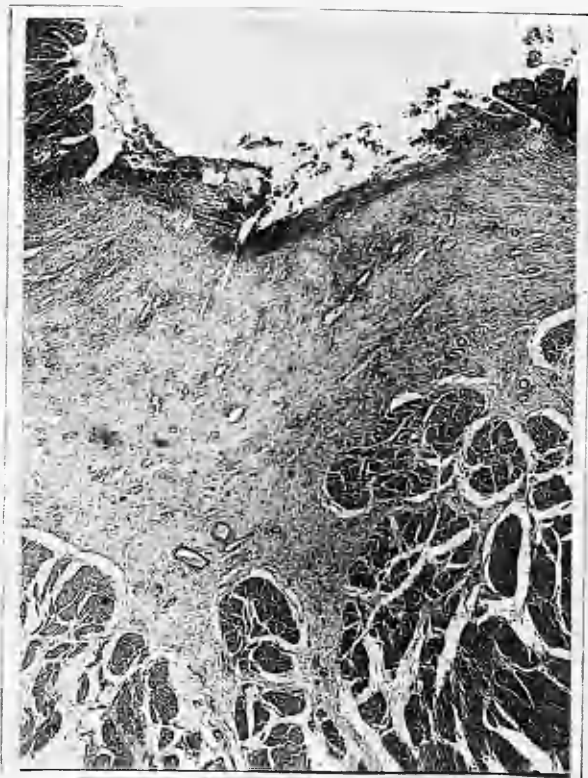

Fig. 61

Fig.62.

État mammellonné in the body of the stomach
without inflammatory changes.

Specimen 2564/49. Magnification 25.

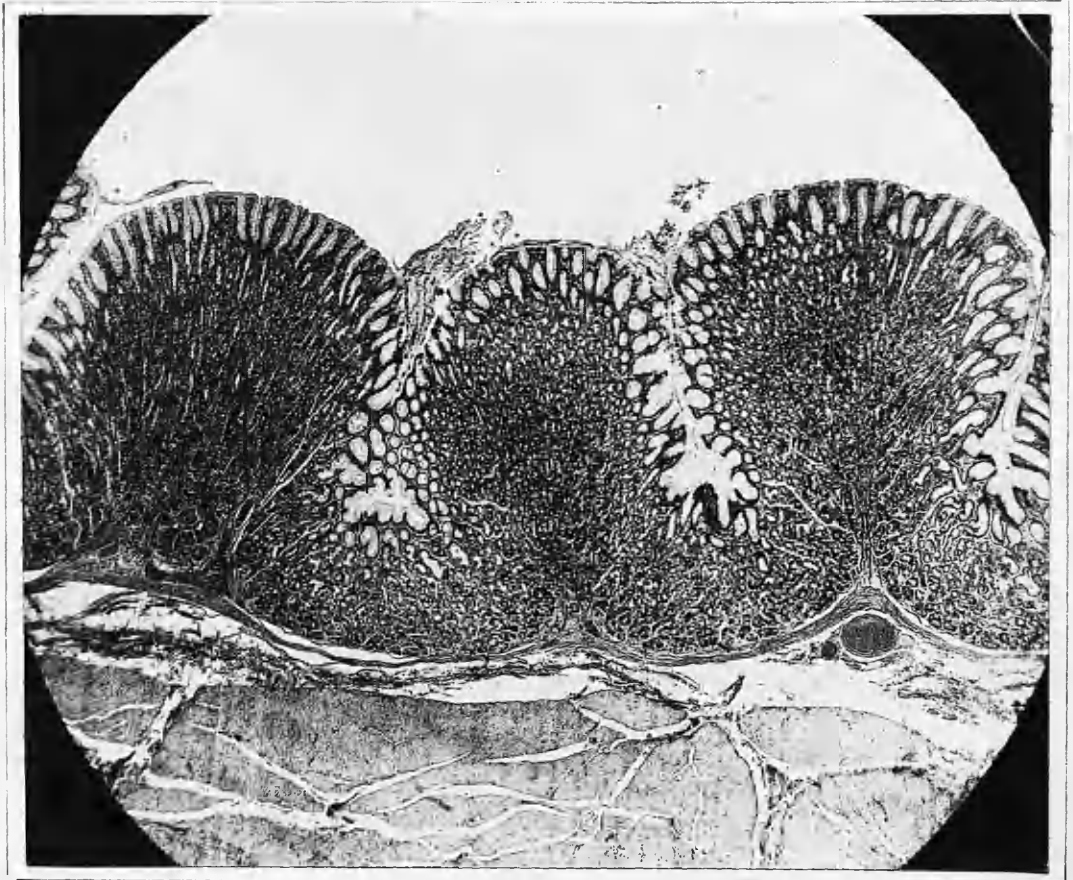


FIG. 62

Fig. 63.

État mammellonné in the body of the stomach with slight inflammatory changes. Cellular infiltration and oedema are present at the tips of the area gastricae but no glandular atrophy is present.

Specimen 1498/49. Magnification 25.

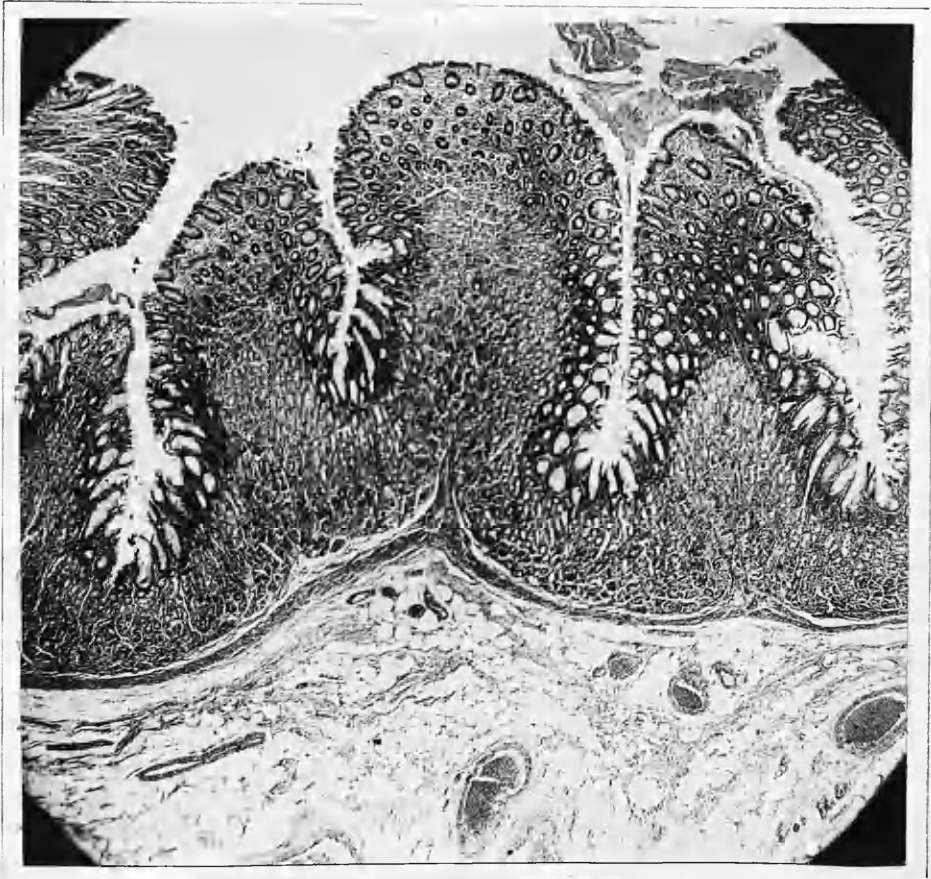

FIG. 63

Fig.64.

État mammellonné with superficial inflammatory changes.

Specimen 184/51. Magnification 25.

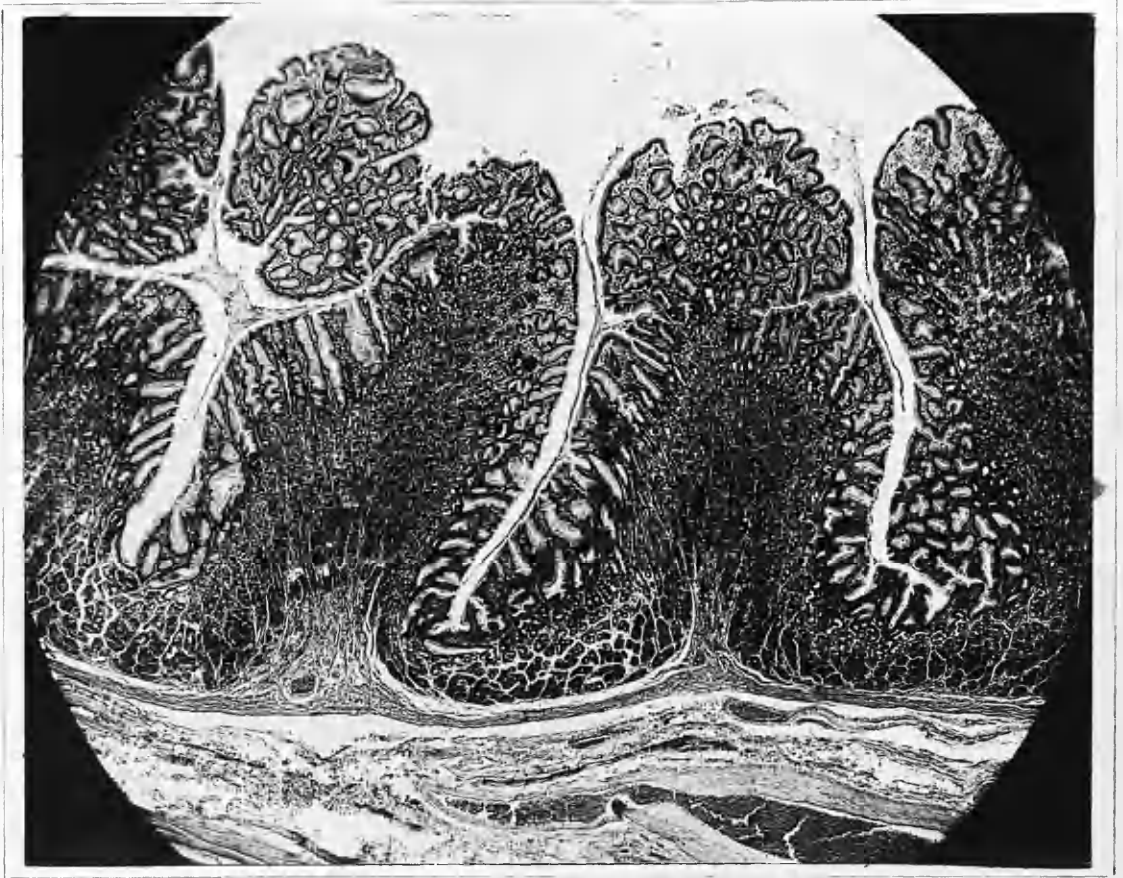


FIG. 64

Fig.65.

Post-mortem haemorrhagic erosion in which the muscularis mucosa is not penetrated but which shows haemorrhage into the mucosa and submucosa.

Specimen 418/50. Magnification 25.

Fig.66.

Post-mortem haemorrhagic erosion which is microscopically a reactionless acute peptic ulcer since the muscularis mucosa has been penetrated.

Specimen 196/50. Magnification 25.

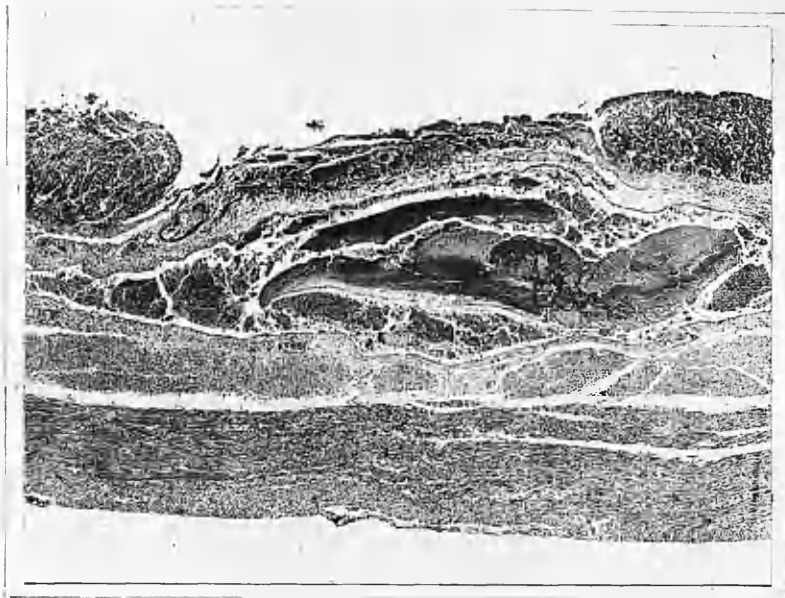


Fig. 65

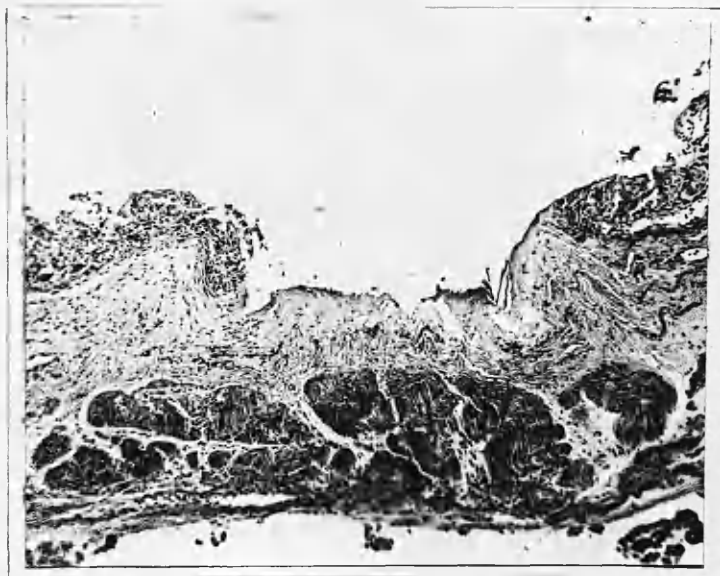


Fig. 66