



<https://theses.gla.ac.uk/>

Theses Digitisation:

<https://www.gla.ac.uk/myglasgow/research/enlighten/theses/digitisation/>

This is a digitised version of the original print thesis.

Copyright and moral rights for this work are retained by the author

A copy can be downloaded for personal non-commercial research or study,
without prior permission or charge

This work cannot be reproduced or quoted extensively from without first
obtaining permission in writing from the author

The content must not be changed in any way or sold commercially in any
format or medium without the formal permission of the author

When referring to this work, full bibliographic details including the author,
title, awarding institution and date of the thesis must be given

Enlighten: Theses

<https://theses.gla.ac.uk/>
research-enlighten@glasgow.ac.uk

**The Blood Supply of the Human Velum and Pharynx.
Some Implications for Cleft Palate Surgery.
(Two Volumes)**

Volume 1

Eric Freedlander

B.Sc. (Hons.), M.B., Ch.B., F.R.C.S. Glasg., F.R.C.S. (Plast.) Ed.

Thesis submitted for the degree of M.D. of the University of Glasgow

Department of Anatomy, University of Glasgow

April, 1991

© E. Freedlander, 1991 Vol. 1

ProQuest Number: 11008029

All rights reserved

INFORMATION TO ALL USERS

The quality of this reproduction is dependent upon the quality of the copy submitted.

In the unlikely event that the author did not send a complete manuscript and there are missing pages, these will be noted. Also, if material had to be removed, a note will indicate the deletion.



ProQuest 11008029

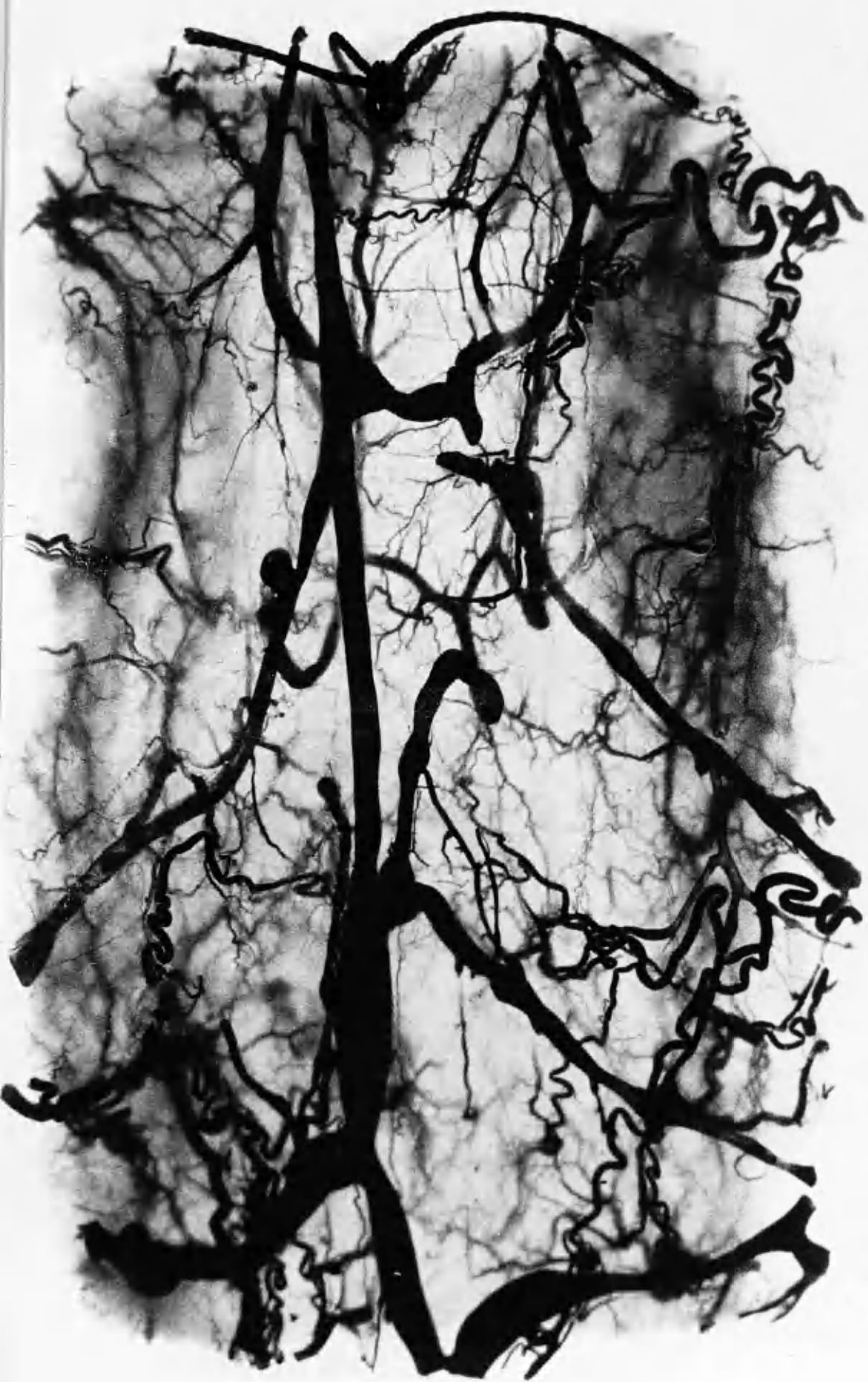
Published by ProQuest LLC (2018). Copyright of the Dissertation is held by the Author.

All rights reserved.

This work is protected against unauthorized copying under Title 17, United States Code
Microform Edition © ProQuest LLC.

ProQuest LLC.
789 East Eisenhower Parkway
P.O. Box 1346
Ann Arbor, MI 48106 – 1346

Frontispiece: Upper portion posterior pharyngeal wall. Cleared specimen adult cadaver. Indian ink / latex injection.



Contents

Volume 1

	Page
Acknowledgements	13
Declaration	15
Summary	17
Abbreviations	19
General Introduction	21
Aims of Thesis	22
Chapter 1	Cleft Palate Surgery 24
1.1	Milestones in Cleft Palate Surgery 24
1.2	Summary of Current Philosophy 27
Chapter 2	Human Palatal Development 30
2.1	Normal Palatal Development 30
2.2	Abnormal Palatal Development 34
Chapter 3	Palatal Anatomy 39
3.1	Normal Palatal Anatomy 39
3.2	Cleft Palate Anatomy 47
Chapter 4	Blood Supply of the Palate 52
4.1.1	Embryological Aspects 52
4.1.2	Normal Hard Palate Arterial Anatomy 53
4.1.3	Previous Research 53
4.2	Blood Supply of the Posterior Pharyngeal Wall 59
Materials and Methods	60

Chapter	5.1	Specimens	61
	5.2	Specimens for Scanning Electron Microscopy	62
	5.3	Injection Media	63
	5.4	Injection Technique	66
Chapter	6	Dissection Procedure	69
	6.1	Adult Cadavers	69
	6.2	Fetuses	72
	6.3	Raising Pharyngeal Flaps	73
Chapter	7	Other Methods of Investigation	74
	7.1	Radiology	74
	7.2	Clearing Techniques	75
	7.3	Histology	76
	7.4	Histochemistry	77
	7.5	Scanning Electron Microscopy	78
	7.6	Skull Examination	79
	7.7	Photography	80
	7.8	Clinical Material	80
Observations			81
General Comments on Injection Results			82
Chapter	8	Identification of Extrapalatal Blood Supply of Levator and Tensor Veli Palatini Muscles	83
	8.1	Normal Fetal Specimens	83
	8.2	Adult Cadavers	85
Chapter	9	Palatal Dissections	88
	9.1	Normal Fetal Intrapalatal Soft Palate Dissections	88
	9.2	Adult Cadaver Intrapalatal Dissections	90
Chapter	10	Palatal Blood Supply of Cleft Specimens	91
	10.1	Extrapalatal Blood Supply of Levator and Tensor in Cleft Specimens Dissected	91
	10.2	Intrapalatal Cleft Palate Dissections	93
	10.3	Findings in Serially Sectioned Fetal Heads	95
Chapter	11	Posterior Pharyngeal Wall Dissections	96

	11.1	Specimens with Normal Palates	96
	11.2	Cleft Palate Fetuses	97
	11.3	Pharyngoplasties	98
Chapter	12	Relevant Anatomical Findings in Normal and Cleft Palate Specimens	100
	12.1	Normal Palates	100
	12.2	Cleft Palate Specimens	102
	12.3	Observations on Nerve Supply to Palatal Muscles	104
	12.4	Anatomical Findings of Cleft Palate Specimens Examined Histologically	105
Chapter	13	Histochemical Findings	106
	13.1	Intramuscular Vascular Patterns	106
	13.2	Identification of Muscle Fibre Type	106
Chapter	14	Skull Observations	108
	14.1	Measurements	108
		General Discussion	109
Chapter	15.1	General Comments	110
	15.2	Dissection Findings Related to Blood Supply	110
	15.3	Discussion on Anatomical Findings	114
	15.4	Discussion on Histochemical Findings	117
	15.5	Surgical Implications of Soft Palate Dissections	118
	15.6	Surgical Implications of Posterior Pharyngeal Wall Dissections for Pharyngoplasty	126
	15.7	Proposals for Cleft Palate Closure	128
	15.8	Description of Cleft Palate Closure	131
		Appendices	133
Appendix	1		134
	2		135
	3		138
	4		138
	5		139

4	138
5	139
6	140
7	142
Bibliography	143

Tables

Table 1	Arterial Supply of Levator Veli Palatini Normal Palates	86
Table 2	Arterial Supply of Tensor Veli Palatini Normal Palates	86
Table 3	Arterial Supply of Levator Veli Palatini Cleft Palate Specimens	92
Table 4	Arterial Supply of Tensor Veli Palatini Cleft Palate Specimens	92
Table 5	Percentage of Fibre Types in Palatal Muscles	106

Contents

Volume 2

	Page
Abbreviations	7
Illustrations	9
Fig. 1 von Graefe's instruments	10
2 Veau flaps	11
3 von Langenbeck flaps	11
4 Furlow's double opposing Z-plasty	12
5 Drawing of face of 6-week embryo	13
6 Scanning electron micrograph (SEM) of stomatodeal chamber of 7-week embryo	14
7 SEM of palatal shelves	14
8 SEM of palatal shelves	15
9 SEM of palatal shelves	15
10a SEM of medial edge epithelium	16
10b Higher magnification of medial edge epithelium	16
11 Palate of 9-week fetus	17
12 Palate of 22-week fetus showing midline cysts	18
13 Palate of 20-week fetus showing bone formation	18
14 Normal adult bony palate	19
15 Bony origins of levator and tensor veli palatini muscles	20
16 SEM of soft palate of embryo	21
17 SEM of soft palate of embryo	21
18 Drawing from Veau's book	22
19 18-week fetus with right cleft lip and palate	23
20 22-week fetus with "median" cleft lip and bilateral cleft palate	23
21 20-week fetus with cleft secondary palate	24

Fig. 22	Argyle Medicut trochar and cannula	24
23	Lateral view of adult skull showing osteotomy cuts	25
24	Inner aspect of adult skull	25
25	Dissection microscope	26
26	Posterior pharyngeal wall in 26-week fetus	27
27	Posterior pharyngeal wall in adult cadaver	27
28a	Right lateral view of fetal head	28
28b	Sketch of fetal head	28
28c	Right lateral view of fetal head	28
29	Right lateral view of fetal head	29
30	Left lateral view of fetal head	29
31	Left lateral view of fetal head	30
32	Right lateral view of fetal head	30
33	Right lateral view of fetal head	31
34a	Drawing of oral surface of fetal palate	31
34b	Extrapalatal muscles of fetal palate	31
35	Left lateral view of fetal head	32
36	Right lateral view of tensor veli palatini muscle	32
37	Right lateral view of fetal head	33
38a	Inferior view of fetal palatal muscles	33
38b	Drawing of oral surface of palate	33
39	Left lateral view of head of adult cadaver	34
40	Venous plexus on lateral surface of adult tensor muscle	34
41	Oral surface of fetal soft palate	35
42	Oral surface of fetal soft palate	35
43	Oral mucosa of fetal soft palate	36
44	Oral view of fetal soft palate	37
45	Oral view of fetal soft palate	37
46a	Oral view of fetal soft palate	38
46b	Oral view of fetal soft palate	38
47a	Ascending palatine artery entering fetal soft palate	39
47b	Drawing of fetal palate	39
47c	Ascending palatine artery and levator veli palatini muscle	39
47d	Ascending palatine artery in relation to hamulus	40

Fig. 48a	Oral surface of fetal palate	41
48b	Drawing of fetal palate	41
48c	Palatopharyngeus muscle dissected off aponeurosis	41
48d	Ascending palatine artery passing through levator	42
49a	Oral surface of palate of 25-week fetus	43
49b	Drawing of fetal palate	43
49c	Further dissection of palate	43
49d	Ascending palatine artery passing deep to levator	44
49e	Ascending palatine artery reaching musculus uvulae	44
50	Cleared palate of adult cadaver	45
51	Oral view of adult palate	45
52	Ascending palatine artery of adult palate	46
53	Xray of adult palate	46
54	Xray of adult palate	47
55	Cleared adult soft palate	47
56a	Left lateral view of fetal head (cleft secondary palate)	48
56b	Drawing of lateral view of fetal head	48
57a	Right lateral view of fetal head (cleft primary and secondary palate)	48
57b	Further dissection	49
58a	Left lateral view of fetal head (cleft primary and secondary palate)	49
58b	Drawing of dissected fetal head	49
59	Oral surface of fetal cleft palate	50
60a	Montage of right side of fetal cleft palate	50
60b	Montage of further dissection	51
61	Inferior view of fetal cleft palate	51
62	Drawing of mucosal blood supply of soft palate	52
63	Coronal section of 18-week fetal head (normal palate)	53
64	Coronal section of 18-week fetal head	53
65a,b	Coronal sections of 16-week fetus with cleft primary palate	54
66	Coronal section of 19-week fetus with cleft secondary palate	55

Fig. 67a,b	Coronal sections of 19-week fetus with cleft secondary palate	56
68	Coronal section of 19-week fetus with cleft secondary palate	57
69	Coronal section of 17-week fetus with cleft primary, secondary palate	57
70	Coronal section of 17-week fetus with cleft primary, secondary palate	58
71a	Posterior pharyngeal wall of adult cadaver	59
71b	Posterior pharyngeal wall of adult cadaver	59
72a	Posterior pharyngeal wall of adult cadaver	60
72b	Close-up view of posterior pharyngeal wall	60
73 & Frontispiece	Posterior pharyngeal wall of cleared specimen adult cadaver	61
74	Xray of posterior pharyngeal wall of adult cadaver	61
75	Posterior pharyngeal wall of adult cadaver	62
76	Posterior pharyngeal wall of cleared specimen	62
77	Transverse section posterior pharyngeal wall of adult surgical specimen	63
78	Posterior pharyngeal wall of 20-week fetus	64
79	Superiorly based pharyngeal flap	64
80a	Montage of posterior pharyngeal wall of 24-week fetus	64
80b	Inferiorly based pharyngeal flap	65
81a	Posterior pharyngeal wall of 20-week fetus showing Kapetansky flap	66
81b	Kapetansky flap elevated	66
82	Left palatopharyngeal arch of cleared specimen	67
83	Oral surface of palate of 27-week fetus	68
84	Oral surface of right hemipalate in 25-week fetus	68
85a	Left soft hemipalate of fetus with cleft palate	69
85b	Left levator veli palatini muscle	69
85c	Levator muscle inserting into aponeurosis	70
86	Left soft hemipalate of 20-week fetus with cleft palate	70

Fig. 87a	Montage of dissected soft palate of fetus with cleft secondary palate	71
87b	Dissected right soft hemipalate	71
87c	Left soft hemipalate	72
88	Drawing of insertions levator veli palatini muscle	73
89	Drawing of insertions palatopharyngeus, superior constrictor and levator muscles	73
90	Left lateral view of 22-week fetus with cleft palate	74
91	Left extrapalatal muscles of fetus with cleft palate	74
92a	Coronal section through hemipalate of 19-week fetus with cleft secondary palate	75
92b	Coronal section through hemipalate showing aponeurosis	75
92c	Coronal section through soft hemipalate	76
92d	Levator veli palatini muscle fibres	76
93a	Coronal section of soft hemipalate of cleft specimen	77
93b	Coronal section through hemiuvula	78
93c	Coronal section through hemiuvula	78
94a	Transverse section through upper portion levator muscle	79
94b	Transverse section through mid portion levator	79
94c	Transverse section through medial portion levator	80
95a	Transverse section through levator muscle	80
95b	Transverse section through mid portion levator	81
95c	Transverse section through medial portion levator	81
96	Frozen section of levator	82
97	Frozen section of musculus uvulae	82
98	Frozen section of musculus uvulae	83
99	Frozen section of palatopharyngeus	83
100	High power view of frozen section of levator	84
101a-c	Lateral views of infant, child and adult skulls	85
102A-D	Patterns of arterial supply to levator veli palatini	86
103a,b	Drawings of levator and palatopharyngeus insertions	87
104a,b	Drawings of levator and palatopharyngeus insertions	88
105a	Intraoperative photograph of cleft palate	89
105b	Cleft edges marked	89

Fig. 105c	Cleft edges incised	89
105d	Nasal mucosal closure completed	90
105e	Oral closure completed on soft palate	90
105f	Oral closure completed over hard palate	90

Acknowledgements

In the busy clinical post that I was holding it would have been almost impossible to carry out all aspects of the studies described on my own. Many people have helped me to complete this thesis.

The specimens used in these studies have come from a number of sources. As a result I am indebted to a number of people for allowing me access to their departments to collect them. Dr. W. Spilg and Dr. F. Lee, both Consultant Pathologists, enabled me to obtain fresh palatal tissue from their respective departments at the Royal Infirmary and Victoria Infirmary, Glasgow.

The great majority of the fetal specimens were obtained from the Pathology Department at the Royal Hospital for Sick Children, Glasgow. The consultants, Dr.A.A.M. Gibson and Dr. W.J.A. Patrick very kindly allowed me to carry out my injection studies there and gave me permission to perform the dissections. A number of fixed fetal specimens were also given to me to study by Dr.J.Bell, Consultant Neuropathologist, Western General Hospital, Edinburgh. These were extremely useful particularly as they included cleft specimens.

The specimens used to illustrate different stages of palatal development were made available by Dr.W.R. Chatfield, Consultant Obstetrician, Glasgow and my thanks are due to him. Fetal and child skulls were provided for study by Dr. M. Watt, Dept. of Oral Biology, Glasgow Dental Hospital, and I am grateful to her for ageing them for me.

The Plastic Surgical Consultant Staff, Canniesburn Hospital, Glasgow are to be thanked for allowing me to carry out dissections on the cadavers used on the Canniesburn Flap Courses.

The practical work described in this thesis was almost all carried out in the Department of Anatomy, University of Glasgow. I wish to acknowledge my debt to Professor R.J. Scothorne for allowing me to use the facilities of his department and for the helpful advice he gave me while I was there. There were also several people on his staff who gave me invaluable practical support. Mr. J. McGadey, M.I.Biol., helped me prepare the

specimens for scanning electron microscopy and assisted me in photographing them. He very kindly carried out the histochemistry on the fresh palatal specimens. Mr. A. Lockhart, H.N.C., was responsible for the histological preparation of the serial sections of fetal heads and for the clearing of palatal and pharyngeal specimens. Miss Margaret Hughes gave me help with photography and special thanks are due to Miss Caroline Morris for some excellent drawings.

Mr. D. Andrews, Department of German, Glasgow University, kindly translated several articles for me.

The Photographic Department at Canniesburn Hospital as always were helpful with advice and practical assistance and my thanks are particularly due to Mrs. Margaret Murray.

My wife, Tina, and my family have had to become used to the many hours when I was engaged in either the practical work for, or the writing of, this thesis. I thank them for their patience. In addition to this my wife has had a very real part to play in this work in that she has contributed a number of illustrations.

Finally, I wish to acknowledge the support I have received from my Adviser, Dr. John Shaw-Dunn. He encouraged me at the outset when I first approached him about carrying out these studies, and this encouragement peppered with sound advice has continued to be available to me whenever I have required it. I am very grateful for all his help.

Declaration

The great part of the work presented in this thesis has been carried out solely by the author. In certain areas assistance was received from several individuals. Mr. J. McGadey performed the histochemistry and assisted me with scanning electron microscopy. Mr. A. Lockhart prepared the histological sections and cleared various specimens. Dr. J. Shaw-Dunn carried out the injections on fixed adult cadavers. The writing of the thesis was done entirely by the author.

A number of scientific presentations have been given by the author to various societies and associations, relating to different aspects of these studies. These are as follows:

1. The embryology of the human palate. British Association of Plastic Surgeons, Summer Meeting, Durham, 1988.
2. The blood supply of the tensor and levator veli palatini muscles. British Association of Clinical Anatomists, Summer Meeting, St. Andrews, 1988.
3. The blood supply of the human normal and cleft soft palate and palatal muscles. British Association of Plastic Surgeons, Winter Meeting, London, 1988.
4. The vascular anatomy of the levator veli palatini with relevance to intravelar veloplasty. American Cleft Palate-Craniofacial Association Annual Meeting, Hilton Head, South Carolina, 1991.

In addition, the following publications contain material from the findings described in the thesis:

1. Freedlander, E. (1988) The blood supply of the levator and tensor veli palatini muscles. Clinical Anatomy, 1,300 (abstr.).

2. Freedlander, E. & Jackson, I. T. (1989) The fate of buccal mucosal flaps in primary palatal repair. Cleft Palate Journal, 26, 110-112.
3. Boorman, J. G. & Freedlander, E. (1991) Chapter in Recent Advances in Plastic Surgery 4, Surgical Anatomy of the Velum and Pharynx Edinburgh: Churchill Livingstone, in press.
4. Freedlander, E. (1991) The blood supply of the human levator and tensor veli palatini muscles. Clinical Anatomy, in press.

Summary

This thesis has described in detail the blood supply of the soft palate and posterior pharyngeal wall in a series of dissections performed on human fetuses and cadavers. A variety of injection media were used in both fresh and fixed specimens to demonstrate the vascular anatomy. Adult cadavers were dissected by conventional methods. For the fetuses a dissection microscope and microsurgical instruments were required. Radiology and clearing techniques have also been used.

It was found that three arteries are important in the supply of the normal soft palate - the ascending palatine, ascending pharyngeal and accessory meningeal arteries. The posterior pharyngeal wall was normally supplied by branches of the ascending pharyngeal and superior thyroid arteries.

A small series of dissections has also been carried out on fetuses with cleft palate and the vascular anatomy shown to be similar to normal cases with some minor variations. This finding was confirmed by histological studies performed on several fetal heads.

Detailed findings have been given of the blood supply of the velar muscles, in particular levator veli palatini and tensor veli palatini. Both these muscles were normally shown to have a dual arterial supply. The most common pattern observed was the levator receiving branches from the ascending palatine and ascending pharyngeal vessels and the tensor from the ascending palatine and accessory meningeal.

Several velar muscles were also examined histochemically in a number of fresh specimens both to study the intramuscular vascular anatomy and to identify fibre types. In no case of levator was any large vessel seen entering the upper lateral portion of the muscle. In each muscle both type I and type IIb fibres were identified, with the levator appearing to have the highest proportion of fast twitch IIb fibres.

The anatomical observations made have been related to cleft palate surgery including pharyngoplasty. It was observed that of different types of pharyngoplasty performed, laterally based flaps appeared to have the richest blood supply. The finding of dual blood supply of the levator and tensor veli palatini suggests that if careful cleft palate closure is

performed these muscles should not suffer ischaemic damage. On the other hand, anatomical observations together with skull measurements made on a series of child and adult skulls point to the possibility that two manoeuvres commonly performed in cleft closure could be damaging to the levator and render a portion of it ischaemic: these are intravelar veloplasty and dissection posterior to the maxillary tuberosity. The author believes that extensive intravelar veloplasty, especially if carried out together with a deep lateral dissection behind the maxillary tuberosity, should be avoided.

Dissection and histological findings in fetuses with cleft palates also showed that the levator has a tripartite insertion: into the cleft soft palate edge, the tensor tendon or aponeurosis, and the posterior aspect of the hard palatal shelf. Extensive intravelar veloplasty is often therefore not required on anatomical grounds as many of the fibres run in a normal direction. On the basis of observations made, a sequential series of steps is suggested for cleft palate closure in order to minimise risk of vascular damage to the palatal muscles.

Abbreviations

A	aponeurosis
Alv	alveolus
a m	accessory meningeal artery
a p	ascending palatine "
a ph	ascending pharyngeal "
aud t	auditory tube
c c	common carotid artery
D	digastric muscle (posterior belly)
e c	external carotid artery
EP	epithelial pearl
f	facial artery
gl	glandular elements
GPF	greater palatine foramen
H	pterygoid hamulus
HP	hard palate
Hy	greater cornu hyoid bone
Hyp N	hypoglossal nerve
i c	internal carotid artery
IF	incisive fossa
L	lip
LN	lingual nerve
LPF	lesser palatine foramen
L Pt	lateral pterygoid muscle
L Pt P	lateral pterygoid plate
LVP	levator veli palatini muscle
m	maxillary artery
M	mandible
m m	middle meningeal artery
MN	mandibular nerve
MPS	midpalatal suture
M Pt	medial pterygoid muscle
M Pt P	medial pterygoid plate

MU	musculus uvulae
N	nerve
NP	nasopharynx
NS	nasal septum
OP	oropharynx
PB	horizontal plate of palatine bone
PBF	pharyngobasilar fascia
Pet T	petrous temporal bone
PMS	premaxillary "suture"
Pph	palatopharyngeus muscle
PPM	palatine process maxilla
PPW	posterior pharyngeal wall
PS	secondary palatal shelf
S	styloid process
SC	superior constrictor muscle
SG	styloglossus muscle
SH	stylohyoid muscle
SMG	submandibular gland
SP	soft palate
SPh	stylopharyngeus muscle
Sp Sph	spine of sphenoid bone
s thy	superior thyroid artery
T	tongue
TG	tooth germ
Thy	thyroid gland
TVP	tensor veli palatini muscle
U	uvula

General Introduction.

Cleft palate is a common congenital condition, known to man at least since ancient Egyptian times (Dorrance, 1933). Occurring alone, it has an overall approximate incidence in the population of 1:2,000 live births (Dronamraju, 1986), rising to 1:1,300 live births when present together with a cleft of the lip (Millard, 1976). Racial differences are well recognised with, for example, cleft palate alone being relatively more common in American Negroes than Caucasians (Millard, 1976).

Surgery to close a cleft palate has been practised for over one hundred and fifty years (Rogers, 1967) and with increasing success. Nowadays the large majority of children having the operation will develop normal or acceptable speech, without any further surgical intervention being required. However, a problem remains as in every reported series there is a number, perhaps 20-30% of patients, with unsatisfactory speech (Whitaker et al, 1972, Watson, 1980). More precisely, the operation may result in persisting velopharyngeal incompetence.

There are many reasons for this. Factors unrelated to palatal anatomy and function include: significant hearing loss (Bluestone, 1971); delayed operation (Edwards, 1980); and low I.Q. (Watson, 1980). Anatomical factors can involve lack of palatal length and mobility. This thesis explores the possibility that impaired palatal movement can be the result of damage to the palatal blood supply, and particularly that of the palatal muscles, due to surgical trauma.

Although the literature on cleft palate is extensive, there have been very few studies exploring the detailed blood supply of the human velopharynx. More specifically, the detailed blood supply of the soft palate and palatal musculature has received virtually no attention. This is the more surprising when one considers that, although in recent years the tendency has been to promote less radical surgery to close the hard palate recognizing that this inhibits the forward development of the maxilla and dentoalveolar process (Ross, 1987), at the same time, in many centres, more extensive soft palatal dissection is

advocated in an attempt to restore the normal muscle anatomy (Kriens,1969; Braithwaite & Maurice,1968; Fára & Dvorak, 1970; Dreyer & Trier, 1984).

A series of studies was undertaken to investigate the blood supply of the human velopharynx in both normal and cleft cases, and to consider the implications for surgery.

Aims of Thesis

The purpose of the present studies was essentially fourfold:

1. To examine the blood supply of the normal and cleft soft palate and the posterior pharyngeal wall.
2. To identify differences between normal and cleft palate anatomy.
3. To investigate whether the blood supply of the muscular and mucosal components of the soft palate could be significantly damaged during cleft palate closure, and determine the adequacy of the blood supply of the various flaps raised during the procedure of pharyngoplasty.
4. To establish various proposals to further improve the surgical results obtained in cleft palate surgery.

Brief Note on Specimens Used to Illustrate Introduction

Various stages of palatal development have been illustrated using the author's own material. This consists of scanning electron micrographs and photographs of fetal palatal dissections. Full descriptions of the methods used to process specimens are found in the Materials and Methods section.

In summary, for scanning electron microscopy, human embryos were obtained following suction termination of pregnancy. The developing palates were fixed overnight in gluteraldehyde and then prepared for S.E.M. as described on p.78.

Human fetuses were obtained following spontaneous or therapeutic abortions. Following fixation, the palates were dissected with microsurgical instruments using a dissection microscope.

To avoid repeated turning of pages to view the illustrations during reading of the text, these have been bound separately in Volume 2. A card listing abbreviations is enclosed with Vol. 2 separately.

The reason for embarking on the anatomical studies described in this thesis was to relate findings to clinical practice. It was thus felt appropriate to begin with a brief history summarizing the development of cleft palate surgery to the present day.

1.1 Milestones in the History of Cleft Palate Surgery.

According to Rogers (1967) the earliest definite reference to cleft palate of congenital origin was made in the mid sixteenth century by Franco, a Huguenot surgeon. Syphilitic perforation of the palate was common at this time and was probably confused with congenital cases. As the former condition had no known cure this probably delayed the development of cleft palate surgery for the next two centuries. John Stephenson, who was the first patient to be operated on by Roux (see below) for cleft palate, and who became a leading surgeon of his day, remarked on this long-standing mistake in his thesis of 1820 where he described his own operation (trans. Francis, 1971). The situation with cleft palate was in contradistinction to that with cleft lip where repairs had been carried out for many hundreds of years before this (Rogers, 1967).

Although, therefore, a few surgeons had attempted operating on clefts in the palate of syphilitic origin from the sixteenth century onwards, the earliest reference in the literature to a successful cleft palate closure appears to be that of a French dentist, Le Monnier of Rouen. He was reported by Robert to have carried out the operation on a child with a complete palatal cleft in the early 1760's (trans. M^c Dowell, 1971). After placing a few sutures to approximate the cleft edges, hot cautery was applied. The resulting inflammation and infection was followed by complete healing.

Sixty years or so later, still at a time when no anaesthesia was available, and within a three year period, paring of the cleft soft palate edges followed by suture approximation was carried out both by von Graefe in Berlin in 1816 (trans. Schuchardt, 1971; May, 1971) (Fig.1) and Roux in Paris in 1819 (trans. Morel-Fatio, 1971). International

surgical rivalry was evident between these two men as Roux tried to take the credit from the German for being the first to describe a successful operation for soft palate closure.

Not long afterwards, in 1826, another German, Dieffenbach, suggested the important new concept that clefts of the hard palate could be closed by separating palatal mucosa from bone (trans. Schmid, 1971). In the same year he also recommended lateral relaxation incisions in the soft tissue of the hard palate to close clefts of the velum and hard palate. This author did not hesitate to divide soft tissue and muscle connections with the palatopharyngeal arches laterally to facilitate closure in wide clefts. Dieffenbach was also the first to propose palatal bone osteotomy as a method of bringing the edges of the hard palate together (trans. Schmid, 1971). This was successfully carried out by another surgeon eight years later.

Disruption of cleft palate repairs remained a major problem. The method of von Langenbeck (1861a) (trans. 1972) was a very significant advance in which he showed how periosteum could be elevated with the palatal mucosa as a single mucoperiosteal flap. Following this contribution, and with his description of bipediced flaps (trans. 1972; von Langenbeck, 1861b) anatomical closure of the entire cleft, both hard and soft, became more successful. It is interesting that in the operation he described the levator veli palatini muscles were deliberately divided, a manoeuvre that is hardly encouraged today!

Billroth in 1889 (trans. Clodius, 1972) was one of the first surgeons to discuss the problems of improving speech following cleft palate repair, and encouraged the use of speech therapy. He deliberately avoided dividing the levators through lateral incisions, and instead gained mobility by fracturing the medial pterygoid plate bearing the hamulus. Even earlier, apparently Passavant in 1861 was also aware of speech problems and designed pharyngoplasties to improve this (Watson, 1980).

Ganzer (1920) was the first to describe repositioning of the palate by the so-called V-Y procedure, using mucoperiosteal flaps. This was also advocated by Dorrance (1925) to achieve palatal lengthening via a procedure he termed a "pushback". Veau in Paris, in his book of 1931, included these flaps and described the vomerine mucoperiosteal flap. Veau is also generally given credit for being the first to recognize the abnormal muscle

insertions in cleft palate and described palatal muscle repositioning and suture. Wardill and Kilner in England both described refinements to the V-Y procedure in 1937, but whereas the former divided the greater palatine vessels the latter preserved them.

By this time various types of pharyngoplasties were becoming common. These were either superiorly or inferiorly based pharyngeal flaps. This procedure had first been described by Schoenborn in 1876 (trans. Stellmach, 1972). More recently, tissue has been utilised from the lateral pharyngeal area (Hynes, 1950) and posterior palatopharyngeal arch (Orticochea, 1968,1970).

With advances in anaesthesia, longer and more complicated procedures could be performed safely. Braithwaite in Newcastle was the first surgeon in this country to describe the creation of a muscular sling across the midline after taking the insertion of the muscles off the back of the hard palate (Braithwaite 1964; Braithwaite & Maurice, 1968). Kriens (1967, 1969, 1970) in Germany published anatomical dissection findings of what he believed to be the abnormal muscle insertions in cleft palate as well as describing an operation to reposition these muscles - an intravelar veloplasty.

One of the continuing controversies in cleft palate surgery has been deciding the optimum age for palate closure. As many of the early procedures produced gross palatal and maxillary deformities, such as that advocated by Brophy (1927) using silver wire sutures, many surgeons abandoned early operation and waited for several years until most palatal growth had been completed. Others suggested a two stage procedure with the soft palate closed in the first year of life and hard palate closure deferred for a number of years (Dingman & Grabb, 1971; Hotz & Gnoinski, 1976, 1978; Schweckendiek, 1978). This was found to have a deleterious effect on speech development (Fara & Brousilova, 1969; Cosman & Falk, 1980; Jackson et al, 1983) and so this regimen has lost popularity.

1.2 Summary of Current Philosophy in Cleft Palate Surgery.

1.2.i Timing of operation

It is a measure of the complexity of all the factors involved in cleft palate surgery that there is still considerable disagreement among surgeons as to the optimum time to close the cleft. Consideration must be given to the effects that the timing of surgery has on facial growth, dentition and speech. This stated there is undoubtedly a tendency at the present time towards earlier closure. The reasons mainly stem from the realization that the earlier the repair the better the speech (Jolleys,1954; Holdsworth,1954; Bill et al,1956; Evans & Renfrew,1974; Trusler et al 1955). There are advocates for closure as early as three or four months (Kaplan,1981; Desai,1983). In infants by twelve months of age patterns of sound production are beginning to be well established. Beyond the age of two in some cases they have become so entrenched that surgery to restore a normal velopharyngeal valve may fail as previously learned habits prove difficult to break (Ortiz-Monasterio et al, 1974; Watson, 1980). If a two-stage operation is not being performed then the great majority of surgeons close the palate before 18 months for this reason, and normally by twelve months.

On the other hand some surgeons, though still agreeing that soft palate closure should be early, delay hard palate surgery as already indicated. Malek (Malek & Psaume,1983) carries out soft palate closure at three months, before lip repair has been carried out. He argues that an advantage of this approach is the unrivalled access that this allows to the soft palate. The hard palate and lip are closed at six months.

1.2.ii Commonly used procedures Hard palate

Classical mucoperiosteal flaps as described by Veau (1931) (Fig.2), Wardill (1937), and Kilner (1937) are still in common use at the present time. They are often raised incorporating the V-Y advancement principle, to lengthen the oral layer of the palate.

Following the pushback these flaps leave denuded bone behind the alveolus. These areas which heal by secondary intention with resulting scarring are felt to have an adverse effect on maxillary growth (Graber, 1949). This, however, is a controversial area and some studies show that cleft lip closure is a more potent cause of mid facial retrusion (Kaplan, 1981). Significant raw areas on the anterior oral surface of the palate are best avoided and for this reason there has been a return to the von Langenbeck method where the anterior attachment of the flap is left intact (Fig.3).

A further common approach to closure of the hard palate cleft is to utilise a vomer flap (Veau, 1931)) as a preliminary procedure at the time of lip repair. Other surgeons avoid this as it has been felt that early vomerine surgery may contribute to mid facial retrusion (Friede et al, 1987).

1.2.iii Soft Palate Intravelar veloplasty

Soft palate closure whether carried out alone or in conjunction with a procedure on the hard palate can be either conservative or radical. Since the observations of Veau (1931) and Kriens (1969,1970), together with the work of Braithwaite (Braithwaite & Maurice, 1968) the majority of surgeons carry out some kind of intravelar veloplasty. This may mean simply dividing the insertion of muscle fibres into the posterior aspect of the bony palatal shelves and, by means of a fairly minimal dissection, suturing the two bundles of fibres together across the midline. (Dingman & Argenta, 1985; Trier, 1985b). On the other hand a much more radical dissection may be undertaken. Sommerlad (Boorman & Sommerlad, 1985a) not only dissects muscle from off the hard palate but very extensively follows this back laterally for a considerable distance. Only then are the two muscles united across the midline. It is almost universally stated by advocates of intravelar veloplasty that the muscle that is being dissected off the hard palate is the levator veli palatini.

A technique of intravelar veloplasty which has been described recently and is enjoying some popularity in this country and the United States is that of Furlow (1986). In this procedure double opposed Z-plasties are raised in such a way as to retrodisplace and realign the levator muscles (Fig.4).

1.2.iv Pharyngoplasty

There is a belief in some quarters that if the cleft palate is obviously short at the time of closure then a primary pharyngoplasty should be performed. This was first popularized by Stark and De Haan (1960). Pharyngeal flaps can result in significant complications such as snoring and particularly sleep apnoea (Thurston et al, 1980) and may reduce anterior maxillary growth (Subtelny & Nieto, 1978), though a recent well planned study disputes this (Semb & Shaw, 1990). Also, if they are used in every case primarily they will often have been unnecessary. For this reason the idea of primary pharyngoplasty has never gained popularity in this country.

The current consensus is to wait and see whether a child develops velopharyngeal incompetence following repair. This can be investigated radiologically (Skolnick, 1969) and nasendoscopically (Pigott, 1969b,1980). Information can be recorded about the dynamics of the velopharyngeal isthmus during speech and whether failure to close this isthmus lies in the sagittal or coronal plane. Minor degrees of incompetence or variable incompetence may respond to speech therapy. More marked incompetence normally requires a pharyngoplasty but, if appropriate, palatal re-exploration may be preferred in order to carry out an intravelar veloplasty (Randall,1980).

It is now normal for the progress of patients with cleft palate to be followed at specialised cleft palate clinics (Pigott,1980; Trier,1985c) where they are assessed at regular intervals by various specialists (plastic surgeon, orthodontist, speech therapist, maxillofacial surgeon, ear nose and throat surgeon). Appropriate interventional steps are taken as the need arises.

Chapter 2 HUMAN PALATAL DEVELOPMENT

2.1 Normal Palatal Development

The main events in the embryological development of the human palate are well established and can be found in standard texts. (Hamilton et al,1972; Fitzgerald, 1978; Sperber,1989). Regionalisation of growth in the head region of the embryo in the early part of the somite stage, 21st to 31st days, results in the formation of facial prominences (Fig.5). Neural crest cells, after migrating laterally and ventrally under the surface ectoderm (Weston, 1970) give rise to these centres of growth and subsequently form most of the facial tissues including those forming the lip and palate (Johnston & Millicovsky, 1985). The maxillary processes therefore contains mesenchyme largely derived from these neural crest cell populations (Greene & Pratt,1976).

2.1.i Growth and Elevation of the Palatal Shelves

At day 45 of embryonic development medially directed projections or shelves form from the maxillary processes, derived from the first branchial arches, bounding the stomatodeum or primitive mouth (Ferguson,1988). These so-called secondary palatal shelves eventually form most of the hard and all of the soft palate. As the developing tongue is growing rapidly at this time and completely fills the oronasal chamber, these palatal shelves are initially turned downwards on either side of it (Fig. 6). Interestingly, Ferguson (1988) has recently questioned whether such a purely spacial relationship can completely account for this vertical growth. In the eighth week, with differential head growth and as the stomatodeal chamber enlarges, the tongue is withdrawn from between these shelves. This process is probably aided by rapid growth in Meckel's cartilage which causes the vertical dimension in the oronasal cavity to increase (Diewert,1980, 1986) and allows the shelves to turn up from a vertical to horizontal plane. This process

takes place in a wave-like fashion, as can be seen in Fig.7, with the anterior portion becoming horizontal before the posterior portion. (Burdi & Faist, 1967). The anterior portion may become horizontal via rotation whereas posterior elevation may be by means of remodelling (Greene & Pratt,1976). It is believed the process is completed within hours.

Mouth opening reflexes first develop around this time (Humphrey, 1969) and the mechanical effect of having the tongue withdrawn from between the shelves possibly together with growth and straightening of the cranial base, provides the necessary environment for intrinsic forces involved in shelf elevation to come into play. The role of these external factors is not yet clarified. Shelf elevation occurs a few days earlier in male than female embryos (Sperber, 1989).

As opposed to research in the past which dealt mainly with morphological aspects of palatal shelf elevation, current work is focused on the various intrinsic molecular and biochemical factors involved. Most of this work has been performed on animals. Several mechanisms contribute:

1. A number of studies have suggested that accumulation and hydration of hyaluronic acid and other glycosaminoglycans is important in increasing the tissue turgor within the shelf matrix (Larsson et al,1959; Anderson & Mathiesson,1967; Pratt et al, 1973).
2. The presence of contractile elements has been demonstrated within the palatal mesenchyme in the fetal mouse (Lessard et al,1974). Mesenchymal cells have been shown to secrete neurotransmitters such as serotonin and acetylcholine (Zimmerman and Wee, 1984) and these effect both cell contractility and glycosaminoglycan degradation. By doing so these neurotransmitters could have a regulatory role in shelf elevation.
3. Finally, the distribution of various molecules such as type IX collagen, tenascin, epidermal growth factor, transforming growth factors alpha and beta, within the shelf matrix is believed to be important (Ferguson, 1988). It should be noted, however, that all the factors implicated above in aiding shelf elevation have also been found in the alligator fetus where palatal shelves form and grow horizontally from the outset (Ferguson, 1981) and so cause and effect relationships have not definitely been

established.

2.1.ii Palatal Shelf Fusion

Following elevation, the palatal shelves grow towards each other. Fig. 8 shows a fetal specimen just before the apposing shelves come into contact. DNA synthesis at the medial edge of the palatal shelves ceases about 24 hours before fusion takes place (Greene & Pratt, 1976), and few blood vessels are found in this area (Luke, 1976). Glycoproteins have been found at the epithelial surface and these may enhance shelf adherence (Pratt & Hassell, 1975). The medial edge epithelium (Fig. 9) then undergoes degeneration, with surface cell desquamation (Fig. 10 a,b). This programmed cell death has been known for some time to be due to interaction between the epithelium and the underlying mesenchyme. (Pourtois, 1969; Tyler & Koch, 1974). It is now believed that not only this medial edge cell death but differentiation of the palatal epithelium into either nasal pseudostratified ciliated columnar cells or oral stratified squamous cells is signalled by the mesenchyme via interaction of the matrix molecules and growth factors already mentioned (Ferguson, 1988).

The elongated medial edge epithelial cells seen in Fig. 10b have been reported by Waterman & Meller (1974). Passive stretching due to underlying mesenchyme accumulating, or cellular migration away from the medial edge have been suggested for this appearance.

Following shelf contact and the breakdown of the epithelium, shelf fusion proceeds commencing at about the junction of the anterior and middle third. It then extends anteriorly and posteriorly. Anteriorly the lateral shelves fuse with the primary palate derived from the fused medial nasal processes (globular process). The nasal septum also fuses to the palatal shelves. Fig. 11 shows a specimen where the hard palate has fused but the process has not extended into the soft palate. Fusion commences in the 8th week and is normally completed by the eleventh or twelfth week (Burdi, 1968).

Some epithelial remnants trapped in the line of fusion may persist giving rise to cysts known as epithelial pearls (Wood & Kraus, 1962; Kraus et al, 1966; Burke et al, 1966).

They occur along the median raphe of the hard palate and at the junction of the hard and soft palate. Examples are shown in Fig.12.

In the posterior area destined to become the soft palate and uvula, Burdi and Faist (1967) proposed that here fusion does not take place but rather a merging of the two sides due to invading mesenchyme. In this portion of the palate they could not find any evidence of inclusion cysts. More recent evidence suggests that fusion may occur in most of the soft palate apart from the posterior portion and uvular area. (Mato et al, 1972a,b).

2.1.iii Ossification and muscle development

Ossification of the anterior portion of the future hard palate begins during the eighth week (Sperber, 1989). Bone spreads into the mesenchyme of the fused lateral palatal shelves and from centres in the primary palate and premaxilla. Fig.13 shows a fetus of 20 weeks' gestation where intramembranous premaxillary bone can be seen. The premaxilla becomes overgrown by maxillary bone. Posteriorly the hard palate is ossified by a single ossification centre appearing in each of the developing palatine bones.

In the region of the soft palate, there is migration of myogenic mesenchyme from the first, second and fourth branchial arches and this gives rise to the muscles of the soft palate and palatopharyngeal arches. The tensor veli palatini muscle, forming myoblasts at 40 days (Sperber, 1989) is the first to appear (Doménech-Ratto,1977). It is established as being derived from the first arch. The levator veli palatini and musculus uvulae are probably derived from the second arch and the palatopharyngeus and palatoglossus from the fourth (Sperber,1989).

In early prenatal life the palate is relatively long, but from the fourth month onwards as a result of midpalatal sutural growth and appositional growth along the lateral alveolar margins, width increases until at birth the length and breadth of the hard palate are almost equal (Sperber, 1989).

2.2 Abnormal Palatal Development

2.2.i Causes of Cleft Palate Mechanisms

Normal palatal morphogenesis consists of a complex series of synchronised steps. Failure of any of these steps to take place at the correct time or the presence of any adverse agent may result in a cleft of the palate. Defective shelf growth, elevation and fusion can all occur. Several theories have been proposed to account for clefting in general terms.

Sanvenero-Roselli (1953) suggested that a facial cleft may result from a vascular disturbance or abnormality. He postulated that the time of reabsorption of the stapedia artery, towards the end of the eighth week, with redistribution of supply of its terminal branches via the external carotid was around the critical time of fusion of the facial processes. Any disturbance to the supply at this time, he proposed, could result in a cleft. A high incidence of cardiac abnormalities was seen in a group of 30 fetuses with clefts examined by Kitamura and Kraus (1964). These workers suggested that the presence of a cardiac or vascular defect could be a factor in cleft formation, but thought that it was unlikely to be the only one.

Kraus (1970) proposed that clefts of the secondary palate resulted after initial fusion between the secondary palatal shelves had taken place and before bony ingrowth was complete. Degeneration of palatal tissue plus a rapid increase in facial breadth caused post fusion rupturing of the palate and consequent clefting.

Stark (1973), who examined human embryos, has described clefting of the primary palate in terms of mesodermal deficiency. Mesodermal inflow (from migrating neural crest cells) to the area of the developing upper lip must occur in sufficient quantities and at the right time. If the cells do not arrive at all on one side, a cleft will extend back to the incisive foramen. If lateral inflow fails on both sides, a bilateral complete cleft results. If ventral migration to the central portion does not take place, a median cleft arises. Correspondingly, deficiencies of varying degree result in varying malformations. A

minimal deficiency may allow normal development of the alveolar area but could result in deformity of the lip such as notching of the vermilion. Evidence that deficiency in the numbers of neural crest cells reaching the maxillary process could result in a cleft of the lip and palate was obtained by van Limborgh et al (1983). They destroyed the mesencephalic neural crest in chick embryos by irradiation and noted subsequently that the maxillary process mesenchyme was deficient on the affected side. A significant number of the surviving embryos exhibited a cleft of the lip and / or cleft palate.

Part of the mechanism of clefting, Stark believed, was the rapid growth that the facial area of the embryo undergoes. In the absence of sufficient mesodermal ingrowth the unreinforced ectodermal-endodermal membrane between facial prominences ruptures as a result of traction forces exerted during growth, and a cleft results. Current evidence, however, suggests that the facial processes normally grow towards each other, make contact and merge or fuse (Millicovsky & Johnston,1981; Sperber,1989).

Cleft lip with or without cleft palate [CL(P)] is believed to be caused by a combination of genetic and environmental factors. One of the ways that these can be expressed is by altering the facial geometry during the critical period of primary palate development (Trasler, 1968). Millicovsky et al (1982) have reported a very high incidence of spontaneous CL(P) in a colony of inbred mice. Using scanning electron microscopy they demonstrated that the medial nasal prominence in these mice grows almost parallel to the lateral nasal prominence leaving a gap between. In contrast, in a strain of mice with no incidence of clefting the two prominences converge.

It is recognized that clefts of the secondary palate occurring alone are developmentally and genetically different from clefts of the lip with or without cleft palate (Fogh-Anderson,1942; Fraser,1970). Current opinion favours a cleft of the secondary palate to result from a failure of fusion of the secondary shelves. The known pattern of fusion extending in an antero-posterior direction throws light on the variety of clefting that is seen clinically. The appearance can vary from a bifid uvula through a cleft of the whole soft palate to a complete cleft of both soft and hard palate extending as far forward as the incisive foramen. On the other hand, it is extremely rare to find cases where the hard palate is cleft but the posterior portion of the palate is intact. Such a case was described last century by Rose (1891) in a four year old girl who had an oval opening at

the junction of the hard and soft palate. Other cases have been described by Berry & Legg (1912), Lynch et al (1966), and five by Fára (1971). The last author believed them to result from rupture of a submucous cleft.

The pathogenesis of submucous cleft palate (SMCP) can also be explained by a partial failure of the above mechanisms. Poswillo (1974), working with mice (which show the same pattern of palatal closure as man), was able to produce a number of fetuses with SMCP by feeding pregnant dams the anticonvulsant phenytoin. This was in addition to a number that had overt cleft palate. The SMCP specimens were shown histologically to have a deficiency of tissue in the midline of both hard and soft palates. The palatal shelves failed to meet in the midline and there was absence of the normal accumulation of mesenchymal cells along the line of fusion. He argued that this progressive failure of mesenchymal differentiation in the midline could parallel the situation in man, and lead to deficiency in the bony palate, failure of muscle union, and cleft uvula.

In the Pierre-Robin sequence, a cleft of the secondary palate is associated with mandibular retrognathia and glossoptosis. It is felt that altered head posture because of constriction in utero may contribute to development of this syndrome. There is good animal evidence to support this (Trasler et al, 1956; Poswillo, 1966; Schuepbach & Schroeder, 1984). Similarly growth deficiency in Meckel's cartilage at the time of secondary palatal development may also predispose to cleft palate (Diewert,1986)

2.2.ii Heredity and Genetic Factors

Whatever the mechanisms involved in the development of cleft palate it is generally agreed that heredity is probably the most important underlying factor (Fogh-Andersen,1980). Studies by this author of the incidence of cleft lip, or cleft lip with associated cleft palate showed that these two can be grouped together, there being a positive family history in about two-fifths of cases. These cases are also more common

in male infants. In cleft palate alone (isolated cleft palate), more frequent in females, there is a family history in only about one-fifth of cases. This suggests that this condition is genetically distinct, with environmental factors being more important in its aetiology. In rare atypical clefts a positive family history is unusual.

Chromosomal abnormalities can occasionally be associated with rare types of cleft palate including cases of median cleft lip and palate. Three specimens studied in the present work were examples of the Trisomy 13 syndrome. Cleft lip with or without cleft palate occurs in 60-70% of children with this syndrome. Other features include holoprosencephaly, congenital heart defects and hypertelorism. Only about 5% survive beyond three years (Dronamraju, 1986). Cleft palate is a common feature of many congenital malformation syndromes including Treacher Collins, Apert and Strickler syndromes (Shprintzen, 1982).

Exciting recent work has been directed towards mapping the genes coding for extracellular matrix molecules, such as growth factors, minor collagen types and hyaluronic acid, that are known to be important in palatal development (Ferguson, 1988). A gene involved in X-linked cleft palate has now been mapped to specific regions of the X chromosome (Moore et al, 1990). Moore and his colleagues studied a large Icelandic family with X linked cleft palates and were able to localize a gene involved in palate fusion to the Xq13-q21 regions of this chromosome.

2.2.iii Exogenous Factors and Teratogens.

The epidemiology of clefting has been examined with reference to geographical, seasonal, and social factors. No clear relationships have emerged. (Fogh-Andersen,1980). The influence of maternal age remains unclear. (Hay,1967; Burdi et al,1972).

Dietary deficiency, particularly vitamin deficiency, during pregnancy has been linked to the occurrence of common congenital malformations, including cleft lip and palate.

Tolarova (1982) was able to reduce the recurrence rate very significantly in women who had had one child with cleft lip with or without cleft palate by giving dietary supplementation. This took the form of a multivitamin preparation and folic acid taken for at least three months before conception, and continued at least until the end of the first trimester.

Cleft lip and palate have been associated with the ingestion of some drugs during pregnancy such as aminopterin and thalidomide (Fogh-Andersen,1980), diazepam (Safra & Oakley, 1976), and anticonvulsants (South,1972). It has been difficult, however, to establish accurately their role as aetiological agents.

Gregg & Avery (1971) studied the effects of cortisone on palatal vasculature on embryonic A/jax mice using a perfusion technique. Some gravid females treated produced embryos with cleft palate. Cleft palate embryos showed differences in palatal vascular plexuses compared with normal embryos. The authors concluded that the teratogenic effect may work through a vascular mechanism. Diewert (1976) studied the effect of teratogens on palatal vascular development in rats. Sprague-Dawley rat fetuses were treated with vitamin A plus cortisone, 6-aminonicotinamide, and X-rays. All three teratogens affected development of lateral palatine processes and arterial vasculature. Vitamin A plus cortisone produced severe palatal deformities with cleft palate. 6-aminonicotinamide and X-rays delayed development of arterial patterns and palatine processes. The palatine arteries remained widely separated in the cleft palate fetuses. The author could not conclude whether vascular changes noted prior to palatal shelf fusion were an important aetiological factor in the cleft palates seen.

It is clear that the aetiological factors are far from clear at the present time. Fraser (1970) concluded that in a large series of clefts of the lip and / or palate "it will be found that some are caused by single mutant genes, some by chromosomal aberrations, some by specific environmental agents and the great majority by the interaction of many genetic and environmental differences, each with a relatively small effect (the multifactorial group)." Continuing animal experiments will throw more light on these complex issues. For the foreseeable future children with cleft palate will continue to be born and surgeons will continue to be faced with the challenge of dealing with this abnormality.

Chapter 3 PALATAL ANATOMY

3.1.i Normal Palatal Anatomy.

The palate separates the oral cavity from the nasal cavity and nasopharynx. The whole structure is arched anteroposteriorly and also transversely, the transverse curvature being more pronounced in the hard palate. The bony palate is formed by the premaxilla, the paired palatine processes of the maxillae and the horizontal parts of the palatine bones (Fig.14). Laterally it is bordered by the alveolar process with its contained teeth. The incisive fossa communicates with the incisive canals which transmit the terminal portions of the sphenopalatine vessels and nasopalatine nerves. The greater palatine foramina are situated within the palatine bones and transmit the greater palatine neurovascular bundles. Extending anteriorly from these foramina and adjacent to the alveolar margin are situated two grooves for the greater palatine vessels and nerves. There is also normally a spine between the grooves. Jeyaseelan and Gupta (1988) have recently noted the presence of a short fibrous or bony canal just in front of the foramen in a few cases. Posterior to the greater foramina are the lesser palatine foramina for the lesser palatine vessels and nerves.

The incisive foramen with the bilateral suture extending to the space between the lateral incisor and canine teeth is the dividing line between the primary and secondary palate.

Although not part of the palate per se, posteriorly are attached the lateral and medial pterygoid plates of the sphenoid. At the lower end of the medial plate is the pterygoid hamulus. This acts as a pulley for the tendon of the tensor veli palatini muscle which inserts into the palatal or tensor aponeurosis. This structure serves as the foundation for the soft palate or velum into which the palatal muscles gain insertion.

3.1.ii Muscles of Soft Palate.

There are five pairs of muscles in the soft palate: levator veli palatini, tensor veli palatini (although only the tendon enters the velum), musculus uvulae, palatoglossus, and palatopharyngeus. The last two pairs form the anterior and posterior palatopharyngeal arches respectively.

Levator veli palatini

This is a round or cylindrical muscle which arises from the petrous portion of the temporal bone, anterior to the inferior opening of the carotid canal (Fig. 15), and from the lamina of the pharyngobasilar fascia hanging from the vaginal process of the tympanic plate, according to Rohan and Turner (1956). An origin from the medial or inferior surface of the cartilaginous part of the auditory tube is also described (Hamilton, 1976; Sinclair, 1981). It passes downwards and medially inferior to the auditory or Eustachian tube and just before entering the soft palate it crosses the upper border of the superior constrictor muscle and passes lateral to the torus tubarius, at the inferior end of the auditory tube. When it enters the palate it lies superior to palatopharyngeus. As they enter the muscle fibres rotate and fan out, a few of the anterior ones reaching the aponeurosis, but the rest by now intermingled with those of palatopharyngeus, become continuous with those of the opposite side. The main bulk of muscle fibres at the midline occupy an intermediate position in the soft palate (Ruding, 1964; Edgerton and Dellon, 1971; Boorman and Sommerlad, 1985a ; Kuehn and Kahane, 1990).

Tensor veli palatini

This muscle arises from the scaphoid fossa, situated on the posterior aspect of the medial pterygoid plate, the spine of the sphenoid and from the lateral side of the cartilaginous part of the auditory tube (Romanes, 1981 ; Williams et al, 1989) (Fig. 15). Authors have described this muscle as having two (Rood, 1973) or even three components (Deuschle et al, 1960). The muscle fibres converge from their vertical descent anteriorly and oblique descent posteriorly on a tendon which hooks round the hamulus where it is said to be covered by a synovial lined bursa. It then passes through a gap in the origin of

the buccinator to enter the soft palate. The tendon then opens out into a flat fibrous sheet, the aponeurosis, which is inserted into the posterior aspect of the hard palate and merges with its neighbour from the opposite side. A few tensor fibres do not enter the velum but insert into the maxillary tuberosity (Ruding, 1964; Ross, 1971; Latham et al, 1980). According to some authors a few tensor fibres also insert into the hamulus (McMyn, 1940, Graves and Edwards, 1944).

Musculus Uvulae

The musculus uvulae is described by different workers as being either a single (Langdon & Klueber, 1978; Boorman & Sommerlad, 1985b) or paired (Azzam & Kuehn, 1977) muscle. Fibres arise from the palatine aponeurosis very close to the midline and pass backwards, just under the nasal mucosa, to insert into the uvula. The levator muscles merge across the midline on the oral side of the musculus uvulae.

Palatopharyngeus

Descriptions of this muscle vary as to which portion is the origin and which the insertion. As it acts as a depressor of the soft palate, it is convenient to consider it as having an origin from the lateral and posterior pharyngeal walls and an insertion into the palate. According to standard texts (Romanes, 1981; Williams et al, 1989) the muscle is described as having two portions, the upper consisting of fibres arising at the level of the upper fibres of the superior constrictor. These stream horizontally into the posterior portion of the soft palate, inferior to the levator, and blend with those of the opposite side. The lower, thicker portion arises from the inferior part of the lateral pharyngeal wall and the posterior border of the thyroid cartilage, covered by the middle and inferior constrictors. These fibres pass up through the posterior palatopharyngeal arch, covered by mucous membrane, into the palate, some fibres uniting across the midline with those of the opposite side and others reaching the aponeurosis. Towards the midline, palatopharyngeus fibres become intermingled with fibres of the levator.

Palatoglossus

This is a thin, variable sheet of muscle that arises from the dorsum and side of the tongue. It passes up, anterior to the tonsil, covered by mucosa, forming the anterior palatopharyngeal arch and is inserted into the aponeurosis, inferior to the levator and palatopharyngeus. Kriens (1970) considered it undissectable as a separate entity.

Salpingopharyngeus

Although not a component of the soft palate, this muscle should be mentioned briefly. In a series of cadaveric dissections M^CMyn (1940) described it as arising from the apex of the medial cartilaginous lamina (torus tubarius) of the auditory tube by small slips. The fibres descended in the salpingopharyngeal fold to blend with palatopharyngeus and inserted into the lateral and posterior walls of the pharynx. Dickson (1972) found in over twenty human heads dissected that the muscle was often absent. He concluded it had no functional significance.

3.1.iii Nerve supply of the Palatal Muscles

All the muscles of the soft palate, except the tensor veli palatini, receive supply through the pharyngeal plexus from the vagus nerve (Romanes, 1981; Williams et al,1989). It is generally agreed that the tensor is supplied by the trigeminal nerve through its mandibular branch (Rich,1920; Domenech-Ratto,1977; Keller et al,1984). Nerve fibres reach the muscle via a small branch that comes off the nerve to the medial pterygoid muscle.

Keller et al (1984) have recently drawn attention to the fact that there is still disagreement

as to which cranial nerve does convey motor fibres to the levator. They located the motoneurons within the brainstem which innervate the tensor and levator, using retrograde axonal transport of horseradish peroxidase in cats. Levator motoneurons were identified within the nucleus ambiguus. This still implicates either the ninth or tenth cranial nerves as this nucleus is known to send efferent fibres via both of these nerves. Domenech-Ratto (1977) examining human embryos and fetuses histologically found that the only nerve branches reaching the levator proceeded from the glossopharyngeal nerve.

Broomhead (1951) made a study of the nerve supply of the soft palate muscles using gross dissection of one adult and two foetal heads, and also carried out serial sectioning of three embryos and two soft palates. He concluded that the levator received supply from the ninth and tenth cranial nerves.

It has also been claimed that the levator receives efferent fibres from the facial nerve. Ibuki et al (1978) found electromyographic responses within this muscle on stimulating the facial nerve in a series of anaesthetised rhesus monkeys.

3.1.iv Muscles of Posterior Pharyngeal Wall

An account of the superior, middle and inferior constrictors can be found in standard texts (Romanes, 1981; Williams et al, 1989). According to Millard (1980b), Philip Gustav Passavant, a Frankfurt surgeon, in 1869 described a ridge or pad on the posterior pharyngeal wall which approaches the soft palate during speech. After cadaveric dissection he believed this to be part of the superior constrictor muscle. In 1931, Whillis demonstrated a constant band of fibres passing from the upper portion of the superior constrictor into the palatal aponeurosis and noted that these are on a level with Passavant's ridge.

Calnan (1954a), however, showed that this ridge was evident in only 25% of unoperated cleft palate cases, when if it were important for speech it would be expected in a much

higher number of those cases. This author in 1957 questioned whether the palatopharyngeus rather than the superior constrictor may be the muscle responsible and also pointed out that the ridge was at too low a level to play an active role in velopharyngeal closure.

Nerve Supply of Pharyngeal Constrictors.

This comes through the pharyngeal plexus, but the motor nerves come principally from the cranial root of the accessory nerve.

Soft Tissue Covering of Palate

The mucous membrane on the oral surface of the palate is very adherent to the underlying periosteum of the hard palate. The stratified squamous epithelium is non keratinized (Fig.16). The lamina propria contains a layer of elastic fibres which separates it from the submucosa (Stern,1986). The submucosa contains many mucous glands. Typical oral mucosa extends round the free border of the soft palate for a variable distance before being replaced by nasal mucosa showing pseudostratified ciliated columnar epithelium (Fig.17) (Stern, 1986).

3.1.v Function of Palatal Muscles

Although the subject of much investigation, considerable controversy exists regarding the function of the different velar muscles. Current opinions have been summarized recently (Maue-Dickson,1979; Maue-Dickson & Dickson,1980).

It is well established that the levator veli palatini is the principal muscle involved in producing normal velopharyngeal closure during speech. There is good evidence for this from studies using electromyography, cineradiography and nasendoscopy (Fritzell, 1969; Bell-Berti, 1976). The angle of entry of the muscle into the soft palate also

indicates it will draw this structure upwards and backwards towards the posterior wall on contraction. It is also felt that the levator during contraction produces not only velar lift but also synchronous lateral pharyngeal wall movement at the level of the torus tubarius. Finkelstein et al (1990) could not find any evidence that this latter movement contributed to opening of the auditory tube. Different patterns of velar and lateral wall movement may occur in abnormal velopharyngeal closure or attempted closure (Shprintzen et al,1977).

It is felt by most authors from anatomical studies that the tensor veli palatini is the primary muscle responsible for opening the auditory tube. It may be assisted by the tensor tympani muscle. Swarts and Rood (1990), using serial sectioning of human autopsy material, have suggested that the auditory tube is opened by the medial rotation of the tubal cartilage mainly due to the action of the tensor but aided by the levator. Earlier, Seif and Dellon (1978) who carried out serial histology and reconstructions of the auditory tube / tensor / levator complex in human fetal heads believed that the levator was the main muscle responsible for tubal opening. In spite of its name there is little evidence to suggest that the tensor veli palatini has any significant action in tensing the soft palate, but recently Kuehn and Kahane (1990) have suggested that it could relieve stresses at the junction of the hard and soft palate.

The musculus uvulae, for long regarded as of little importance, is currently thought to play a role in velopharyngeal closure. Pigott (1969a,b) observed the nasal surface of the soft palate nasendoscopically in normal and cleft subjects. He consistently noted a ridge in the midline of the velum in normal patients which he attributed to musculus uvulae. He felt this bulge was contributing to velopharyngeal closure during speech. The ridge was absent in many of the cleft patients. Croft et al (1978) investigated a group of patients without overt clefts who had hypernasal speech and normal palatal appearance on oral examination. They were all found to have a V-shaped midline defect on the nasal surface of the velum on nasendoscopic examination, which they felt probably denoted absence of musculus uvulae. These patients were labelled as having occult submucous cleft palate. The normal muscle on contraction is believed to contribute to what has been called the levator eminence. Kuehn et al (1988) has shown from an electromyographical study that musculus uvulae seems to act in concert with the levator during speech.

The palatopharyngeus muscle follows a complex course in the soft palate, interweaving with fibres of levator. The general course of its fibres as they leave the palate is to fan out into the lateral and posterior walls of the pharynx, becoming intermingled with those of the superior constrictor. Anatomically it is positioned as a velar depressor (Dickson,1975). It is not clear whether its function during swallowing is more important than its effect of opposing the action of the levator during speech.

The palatoglossus muscle is at the present time not felt to have much functional significance. Anatomically placed like palatopharyngeus to act as a velar depressor, it has been found to be active for tongue body movements and for pharyngeal narrowing but not for palatal lowering (Maue-Dickson,1979).

The pharyngeal constrictors are more active during swallowing than speech production. By altering pharyngeal volume on contraction, they are thought,however, to play a role in causing variations in vowel quality (Maue-Dickson,1979). Although the upper fibres of the superior constrictor are generally believed to be responsible for Passavant's ridge, it is felt that this ridge is rarely able to compensate for velopharyngeal incompetence in cleft palate patients,because as already noted it is thought to be situated at too low a level in the pharynx (Calnan,1957).

3.2 Cleft Palate Anatomy.

The overt cleft palate deformity can vary from a bifid uvula at its mildest form, and which has a prevalence of about 1% in normal populations (Lindemann et al, 1977), to a cleft extending along the whole length of the palate and through the alveolus. The vomer can be united to one or other palatal shelf or in some cases may be separate from both. In bilateral cases the cleft isolates the premaxilla. In the Pierre-Robin sequence there is often a horseshoe shaped cleft of the secondary palate with poorly developed palatal shelves. The most useful classification relates the different types with reference to the incisive foramen (Kernahan & Stark, 1958).

In submucous cleft palate, according to Millard (1980c) a term first coined by Brown Kelly (1910) of Glasgow, no overt cleft may be present. In its most complete form a triad of signs is present: bifid uvula, zona pellucida, and a deficiency in the bony palate (Calnan, 1954b). Calnan operated on a number of cases and noted a lack of muscle union across the midline. Dorrance (1933) had previously described the insertion of the levator as being displaced anteriorly in this condition. It has also been recognized that a displaced levator insertion can occur in the absence of the above triad. This abnormality is described as an occult submucous cleft palate (Kaplan, 1975a). The levator according to this author can insert wholly or partly into the posterior aspect of the hard palate.

A few authors have investigated the anatomy of the overt cleft deformity. Owing, however, to the extreme scarcity of the material available for study most of these have only reported on single cases. The first description of cleft palate muscle anatomy was that of Fergusson (1845). He described findings of a dissection on a female cadaver with a cleft of the soft and part of the hard palate. Unlike later authors he did not comment on any significant differences from the normal anatomy stating, interestingly, that "the levator palati is much as it is usually met with, its lower end spreading out in all directions on the soft palate." Veau, however, obtained almost 30 fresh specimens of various types of cleft palate, had experience of operating on 500 cleft soft palates and described findings in his book of 1931. He used an illustration from a previous author, von Luschka, to illustrate the differences between the normal and cleft palate musculature

(Fig.18). He noted that the cleft palate muscles were atrophied but believed that this was secondary to the anatomy of the cleft resulting in disuse, and not a congenital condition. According to his description the majority of levator fibres, mixed with those of palatopharyngeus, insert into the mucosa of the free border of the cleft. Posterior fibres pass into the uvula and anterior fibres become, with the anterior part of palatopharyngeus, his so-called cleft muscle.

His account of palatopharyngeus is complicated with the muscle being described as having two portions. The main portion composed of four parts: 1) inserting into the posterior border of the palatal shelf and posterior nasal spine; 2) passing along the border of the cleft as the cleft muscle; 3) fibres passing into the mucosa of the free border of the cleft ; 4) posterior fibres which form the posterior palatopharyngeal pillar and pass in to the uvula merging with fibres of musculus uvulae. A second smaller part is described as being internal to the first and composed of fibres which largely pass below the levator and attach to the nasal mucosa.

The tensor is not discussed in any detail being situated outwith the palate. Veau states at one point that the aponeurosis does not exist in cleft cases and yet at another mentions it! A further illustration also shows it. Short descriptions are given of the palatoglossus and musculus uvulae, the latter being dismissed as not having any surgical interest, presumably a common belief at the time.

Fára and Dvorák (1970) described the findings of dissections carried out over 10 years on 18 full-term stillborn fetuses with various types of cleft palate. Four normal full-term fetuses served as controls. They reported that the differences between the normal and cleft arrangement of the soft palatal muscles were considerable. They occur as the muscles cannot insert into the midline owing to the presence of the cleft. The origins are preserved but abnormal insertions must result. In addition, these authors found the muscles in the cleft cases to be hypoplastic compared with normal cases.

The levator veli palatini muscle belly was found to be reduced in thickness by about half. The posterior fibres ran posterolaterally, reaching the posterior palatopharyngeal arch near the base of the uvula. Medial fibres radiated like a fan into the margin of the cleft. Anterior fibres were attached via a triangular tendinous area from the posterior nasal spine

to the posterior edge of the hard palate or to the compact portion of the tensor tendon. In less severe forms of cleft some anterior bundles were inserted along the cleft margin of the bony palate.

The tensor was also found by the same authors to be somewhat thinner than in a normal fetus. A few of its fibres attached to the pterygoid hamulus. Some anterior fibres either inserted into the rudimentary aponeurosis or into the posterior edge of the bony palate. The main part of the tendon arched back towards the cleft edge where it passed into the anterior bundles of the levator muscle.

The palatopharyngeus was relatively well developed. Its palatine insertion was abnormal. Most of the fibres passed along the cleft margin and inserted onto the posterior edge of the palatine plate and nasal spine.

Some fibres united with bundles of the levator advancing along the cleft edge. In three cases of wide bilateral cleft most of the muscle bundles passed to the cleft margin in a direction similar to normal specimens. The posterior bundles of the palatopharyngeus, turning towards the uvula, passed into the posterior bundles of the levator.

The palatoglossus was found to pass in a posteroanterior direction in the cleft margin to the posterior aspect of the bony palate. In many cases its palatal attachment extended anterior to this with fibres inserting into the oral periosteum of the hard palate.

Finally, these workers reported that musculus uvulae fibres were found along the margin of the cleft intermingled with those of the palatopharyngeus and the levator. They found it very difficult to isolate fibres of this muscle.

Kriens (1970) reported on a single dissection of a fetus with cleft palate. He noted that there were no gliding spaces in the normal palate which would allow a clear functional or anatomical division of the muscles. None could be dissected completely in isolation. He stated that the palatal aponeurosis does not exist in cleft palate, which differed from the findings of Fára and Dvorák.

Using anatomical illustrations and drawings he described an abnormal insertion of the

anterior portion of the levator muscle into the cleft posterior nasal spine and oral mucoperiosteum just anterior to this. These fibres are interwoven with the longitudinal portion of palatopharyngeus (Veau's cleft muscle).

Ruding (1964) reported the findings of a dissection of a cleft palate specimen (probably a fetus though this is not stated in the article). He described the palatal aponeurosis as being situated anterior to a plane through the pterygoid hamuli. By its insertion to the anterior portion of the cleft and its lateral attachment to the hamulus it maintained a fixed anterior position of all the attached muscles. The levator muscle bundles ran parallel to the border of the cleft, perpendicular to their normal direction. The fibres of the levator which the same author had found turning into the uvula in normal dissections were reported in the cleft to be virtually absent.

Interesting results were reported by Mina (1979). Dissection of the muscles of the palate, pharynx, and styloid process were performed on an adult cadaver with an unrepaired complete cleft palate. Regarding the levator, some fibres were found to sweep backward to the free posterior edge of the soft hemi-palate near the hemi-uvula and merge with fibres of the palatopharyngeus. Only the posterolateral fibres continued forward to insert into the bony palate.

There have been a few further reports on human cleft anatomy. Deuschle et al (1960) made a study of the palatal muscles, especially the tensor, in an unspecified number of full term cleft palate human fetuses, using microdissection. They found the muscle could be divided into three parts according to their origins from the skull base and auditory tube. The anterior and posterior fasciculi inserted into the soft palate and the intermediate portion into the hard palate. They concluded the muscle acted both as a tensor of the palate and opened the auditory tube.

Latham et al (1980) carried out a three-dimensional reconstruction of the velopharyngeal musculature in a five month old infant with a cleft of the soft and part of the hard palate. They were able to show the abnormal course of some of the velar muscles. Their reconstruction showed on the other hand that certain muscles were more or less unaffected by the cleft: tensor, lateral portion of palatopharyngeus, palatoglossus, salpingopharyngeus and superior constrictor. In a previous article Latham et al (1977)

described the anatomy of musculus uvulae in two infants with cleft palate, using Plexiglas reconstructions and histology. They found that the muscle was located more anteriorly than normal and felt that this may result in its being damaged during standard cleft palate closure.

It is clear that more studies on cleft palate specimens would be helpful in resolving the sometimes conflicting observations that have been described. An obvious difficulty lies in obtaining suitable cleft specimens. Relevant anatomical findings from the present studies will be included in the appropriate chapter.

4.1.1 Embryological Aspects

Padget (1948,1957) has described the development of the cranial arteries and veins in the human embryo. For the investigation of arterial development he used embryos of from 3mm. to approximately 40mm. crown-rump length, or from 3.5 to 7 weeks gestational age. By this time the definitive adult origin of essentially all the cranial arteries has been established. He built up reconstructions in two or three planes by tracing photographs of serial sections. In the reconstruction of the largest embryo of 43mm. (estimated gestational age 52 days) the origins of various branches of the internal maxillary artery can be seen, including the inferior alveolar, infraorbital, and probably the descending palatine arteries. The greater palatine artery has not yet developed. This is at the time of secondary palatal shelf fusion.

Frederiks (1972) studied blood vessel pathways in human embryos ranging from 8 - 64mm. crown-rump length. Thirteen were normal and six had clefts of the primary or primary and secondary palate. Coronal sections of each head were cut. Drawings were made of every 10th section including all blood vessels.

Slight differences were found in the vascular pattern of the premaxilla between normal and cleft embryos. In the secondary palate the presence of a cleft made little difference to the pattern of blood supply. Both before and during the formation of the primary and secondary palates an extensive and extending blood supply was noted.

4.1.2 Normal Hard Palate Arterial Anatomy

According to Williams et al (1989) the main vessels supplying the hard palate arise from the third part of the maxillary artery. The descending palatine artery runs downwards through the pterygopalatine fossa and greater palatine canal. As it descends it gives off small branches, the lesser palatine arteries, which pass through the lesser palatine foramina to the junction of the hard and soft palate. On emerging from the greater palatine foramen it becomes the greater palatine artery and runs forward close to the alveolar margin and lateral to the accompanying nerve and gives off lateral branches to the alveolus and medial branches to the hard palatal shelf. On reaching the incisive foramen the terminal branch anastomoses with the sphenopalatine artery. This vessel is the terminal continuation of the maxillary artery and passes through the sphenopalatine foramen into the nasal cavity where it divides into posterior lateral nasal branches, which supply the lateral wall of the nasal cavity and related sinuses, and the posterior septal branch. This latter vessel passes across the roof of the nasal cavity then downwards and forwards in a groove on the vomer to the incisive foramen.

The alveolar process gains further supply from two main vessels: the posterior superior alveolar artery (or arteries) and the infraorbital artery. The first arises from the maxillary artery in the pterygomaxillary fissure and descends on the infratemporal surface of the maxilla. It supplies the molar and premolar teeth. The second arises in the pterygopalatine fossa. Passing into the infraorbital canal, it gives off one or more anterior, superior alveolar arteries which supply the canine and incisor teeth.

4.1.3 Previous Research

The blood supply of the maxilla and palate has been investigated in France. Cadenat et al (1974) were concerned about the possibility of arterial haemorrhage occurring during maxillary osteotomy procedures, and also whether the viability of the detached dentoalveolar segment would be maintained following these operations. They used clearing and angiographic techniques to study the blood supply in injected adult and fetal

specimens. They concluded that the principal supplies to the palate and dentoalveolar arch were from the posterior superior alveolar and descending palatine arteries. The interruption of one of these sources necessitated conservation of the other and this required conservation of the palatal mucosa.

Combelles et al (1974) using similar techniques studied the arterial supply of the human maxilla and mandible and concluded that the maxilla and palate has a richer supply largely from a communicating intraosseous network between the descending palatine and sphenopalatine arteries. In an earlier report Combelles (1972) using injected fetal and adult specimens, described the blood supply of the hard and soft palate. He concluded that there is an almost complete separation of the supply to each part of the palate, the hard supplied via the descending palatine and the soft via the ascending palatine artery. Any anastomoses between the two systems that did exist were very small. He also noted that there was an avascular median line along the palatal vault.

The most detailed work to the present time on palatal blood supply is that of Maher from the United States. In a series of papers (Maher & Swindle,1962; Swindle & Maher,1963; Maher & Swindle, 1964 ; Maher, 1976; Maher, 1977; Maher,1981) he and his co-worker used injection techniques to describe in detail the course and distribution of arteries supplying the hard palate in humans and a number of animal species. They found (Maher & Swindle,1962) that the greater palatine arteries in all the animals studied form an arcade system comprised of arterial anastomoses. The primary arcade consisted of the left and right greater palatine arteries. Secondary arcades were made up of symmetrically arched anastomoses. These with tertiary arcades extended well into the gingival area. Animals such as the dog , cat, and bear were found to have much more slender arteries than man or monkey. Descriptions were given of the pattern of arterial supply to the greater palatine nerves and how a common sheath of fibrous connective tissue enveloped the greater palatine arteries and the accompanying nerves.

Observations were also made of the venous pattern within the palatal submucosa. They demonstrated a collecting system of two main veins that led to a venous network in the soft palate posterior to the greater palatine foramina. This network was superficial to the arterial vessels in the posterior palate, but deep to the arterial system anteriorly.

In a related paper the same authors investigated the mucosal vessels of the palate in pre- and post-natal man and other mammals (Swindle & Maher, 1963). This article contained a schematic illustration of the vascular connections between the mucosa and submucosa and depicted vertically orientated lone veins passing into the lamina propria from the submucosa. The arteries accompanied by nerves pursued a similar but independent vertical course into the mucosa.

In later work Maher described the distribution of the major arteries supplying the palate including the greater palatine, posterior superior alveolar, infraorbital and facial arteries. Twelve near-term human fetuses were injected with either Indian ink or calcium carbonate in water (Maher, 1976, 1977). In the group of specimens studied three had a cleft of the secondary palate. He described the greater palatine arteries as having medial and lateral branches which formed a network which consisted of peripheral, deep, and recurrent perforating osseous branches. The peripherally or superficially directed branches passed towards the mucosa and formed a fine network or micronet in the lamina propria. End arteries then passed to the papillary portion of the lamina propria where they terminated as capillaries. Deeply directed branches formed a micronet in the periosteum. Recurrent perforating osseous branches entered minor palatal foramina.

The size and number of branches of the greater palatine arteries varied from specimen to specimen, but the overall distribution was similar in all cases. In the normal palates the arterial network extended across the median raphe. In the cleft cases the palatal mucoperiosteum with contained vessels was reflected around the medial edges of the palatal shelves and became continuous with corresponding structures of the nasal floor. Numerous anastomoses were found between the nasal and palatal (oral) soft tissue mucoperiosteum. Arterial connections were also made by perforating osseous arteries.

In normal and cleft palates, lateral branches of the greater palatine artery supplied the gingiva but also gave contributions to all the maxillary teeth. The posterior superior alveolar artery was found to pass forward in the maxilla and gave supply to the dental sacs and their pulps as far forward as the central incisors.

The infraorbital artery was found to anastomose with branches of the facial artery after passing through the infraorbital foramen and the network so formed supplied the buccal

and labial gingiva as well as the alveolar process, dental sacs and pulps of the maxillary teeth.

Maher then described how raising standard mucoperiosteal flaps in cleft palate closure divides perforating osseous branches as well as lateral branches of the greater palatine arteries. It is postulated whether this nutritional loss could be responsible for subsequent morphological defects in the teeth. He also described how suturing palatal flaps under too much tension could cause ischaemia and necrosis. In a later article Maher (1981) studied the arterial distribution to the prenatal human maxilla (in fetuses from six months to term). He perfused fetuses with Indian ink, calcium carbonate or cinnabar (red mercuric sulphide) and claimed that the posterior superior alveolar artery reaches the midline supplying branches to the incisors and to the posterior teeth. More common descriptions have the anterior superior alveolar artery, a branch of the infraorbital, supplying the anterior maxillary segment and its incisors.

Maher in his articles has not reported on the blood supply of the soft palate or palatal muscles.

In Japan, Sawa (1961) studied the arterial distribution in the palate of ten human fetuses (32-40 weeks' gestation) as well as in several species of animals. He used corrosion techniques following injection of acrylic resin into the common or external carotid artery. As well as describing the course of the greater and lesser palatine arteries he reported on the course of the ascending palatine artery. Dividing behind the pterygoid hamulus the main branch ran posteromedially to the soft palate and uvula. An anterior branch anastomosed with the lesser palatine vessels. Another branch anastomosed with a corresponding branch from the opposite side and one supplied the palatoglossal arch. On one side in two specimens a branch from the middle meningeal artery supplied the anterolateral part of the soft palate.

Okano et al (1962) investigated the blood supply on an eight month old human fetus with a complete unilateral cleft of the lip and palate, following acrylic resin injection. Detailed descriptions are given of arterial supply to both hard and soft palate. This author found the soft palate on the non cleft side to be supplied by the branches of the ascending pharyngeal artery, ascending palatine, maxillary artery (probably accessory meningeal

artery) and lesser palatine. On the cleft side the main vessel supply was a branch of the maxillary artery (accessory meningeal) and remaining supply was through a branch of the lesser palatine artery. No mention was made of velar muscle supply.

Broomhead (1951) carried out a dissection of a single fetal head the arteries of which had been injected with neoprene latex. The lesser palatine vessels were found to supply the anterior half of the oral surface of the soft palate. The largest vessel he found entering the soft palate was the ascending palatine artery which entered the soft palate between the tensor and levator muscles giving branches to each. He found two main terminal branches of this vessel. The anterior passed along the anterior border of the levator. The posterior passed through this muscle and as it approached the midline, turned backwards to reach the uvula. Small twigs from the tonsillar and ascending pharyngeal arteries also entered the soft palate.

The distribution of the accessory meningeal artery in man has been examined by Baumel and Beard (1961). In a series of cadaver dissections they found the vessel had a mainly extracranial distribution. It supplied the pterygoid muscles but also gave branches to the tensor veli palatini muscle.

The blood supply to the uvula was described in detail by Girgis (1966). He injected the external carotid arteries of an unidentified number of cadavers with a dye containing starch and Congo red. He identified a vessel supplying the uvula approaching through the posterior palatopharyngeal arch and called this the uvular artery. It usually arose as a separate branch of the external carotid just above the origin of the ascending pharyngeal artery. Although occurring in most cases it was not constant. It travelled upwards and medially along the palatopharyngeus, in close relation to the tonsil, and curved along the free posterior border of the soft palate to reach the uvula. Branches were given to the sides and terminated at the tip. A vein accompanied the artery, draining into the parapharyngeal and pterygoid venous plexuses. This author claimed that in the operation of tonsillectomy if the artery on both sides was ligated atrophy of the uvula follows, leading to hypernasal speech and regurgitation of food.

The bulk of the work carried out to the present time has concentrated on the blood supply of the hard palate. Only Maher and Broomhead have discussed their findings with

reference to cleft palate surgery. Broomhead (1951) was chiefly concerned about how surgical closure could jeopardize the nerve supply to the tensor veli palatini, but also felt that the blood supply to the soft palate was not at risk. He made this conclusion, however, on the findings of a single dissection.

4.2 Blood Supply of the Posterior Pharyngeal Wall

The blood supply of the pharynx is well established. According to Romanes(1981) the main arteries supplying the pharynx are the ascending pharyngeal, ascending palatine and descending palatine arteries. Only the first of these is concerned with the supply to the posterior wall. The veins form a plexus in the wall of the pharynx which drain either into the pterygoid plexus above or the internal jugular or facial vein below.

The illustrations of a number of modern texts have been consulted in order to establish whether the vessels of the posterior wall are shown in detail. It is clear that a rather schematic representation is often given. Langman & Woerdeman (1982) in their illustration do not show details of the vascular anatomy high on the posterior wall. Gosling et al (1985) gives a similar picture. Langman & Woerdeman (1982) also shows a strictly segmental arterial supply. Clemente (1987) in illustrating the vessels on the dorsal and lateral walls of the pharynx fails to show any branches of the ascending pharyngeal artery passing superior to the superior constrictor. The terminal branches are shown to pass up towards but fail to reach the base of skull. Little detail is shown of vessels on the pharyngobasilar fascia above the superior constrictor.

MATERIALS AND METHODS

Chapter 5.1 Specimens

The studies described in this thesis were carried out entirely on human material.

Fixed adult cadavers

A total of ten fixed cadavers were dissected. (Details of age, sex and cause of death are listed in Appendix 1). These specimens had previously been injected with a variety of media to outline the arterial, or in one case the arterial plus the venous, tree.

Fresh adult soft palates

Ten adult soft palates were obtained following post-mortem examination. No throat or oral pathology was found in any case. Four of these palates were used for injection studies and the remaining six for histochemistry of the palatal muscles. (Details of age, sex and time elapsed between death and post-mortem examination are found in Appendix 1).

Fetuses

Eighteen fresh fetuses were obtained. Gestational ages ranged from 17 - 27 weeks. Seventeen of these were used for dissection and in one the palate only was removed for histology.

Four fetuses had a cleft palate of varying degree, and three of these had a cleft lip in addition. (Figs.19-21).

(Details of gestational ages, measurements and post-mortem findings are found in Appendix 2).

Three fetuses previously fixed in formalin were also available for study. All of these specimens had a neural tube defect. Two had a cleft palate. (For details of these specimens consult Appendix 2). The prior fixation and small size made them unsuitable

for injection and dissection. For these reasons they were examined histologically using serial sections.

Serial sections of a further fetus with a cleft of the secondary palate were made available for study (see Appendix 2).

5.2 Specimens for Scanning Electron Microscopy (S.E.M.)

Embryonic and fetal specimens were used to illustrate various stages of palatal development. These were obtained following pneumatic suction termination of pregnancy. The tissues obtained from 15 normal pregnancies were placed in a modification of Karnovsky's fixative containing gluteraldehyde (Ito & Karnovsky, 1968) and examined as soon as possible after termination (within 2 hours) under loupe magnification. The embryos were always found to have been disrupted but the head or a portion of the head including the palate was found in 12 cases. This was dissected free from blood clot and then placed in fresh Karnovsky's solution overnight. Specimens were prepared for S.E.M. as described later in this chapter.

Gestational ages were determined using a combination of clinical and laboratory data (date of last menstrual period, ultrasound scan), and by comparing the appearance of the palatal shelves with the drawings of stages of palatal development in the publication by Kraus et al (1966). It was not possible to use crown-rump lengths due to specimen fragmentation.

5.3 Injection Media

Various injection media were used:

- i. **Neoprene latex (red, blue)** (Latex ZPK 582G, Pigment set ZPK 584R, Griffin & George, East Preston, West Sussex)

This material if injected intra-arterially normally filled large and small arteries and arterioles. Some medium reached the venous side of the circulation if the volume injected was too large for the arterial tree. The specimens were fixed by formalin injection prior to the latex being injected. Once set to a rubbery consistency the vessels containing it could be dissected with ease. The latex had elastic properties and was resistant to breakage. This meant that if vessels were torn during dissection the latex still tended to hold them together. Red and blue coloured dyes were added to the latex as appropriate and this enhanced the photographic results.

A disadvantage of using coloured latex was discovered when the specimens containing it were cleared. Within a few hours of immersion in methyl salicylate the dye began to be leached out. Eventually the white latex also disappeared.

- ii. **Schlesinger's medium** (Modification of Schlesinger (1957)).

This medium is a gelatin / potassium iodide / barium sulphate mass which solidifies on the addition of formalin just prior to injection. It was the simplest to utilise. Just before use a small volume of formalin was added (c.10% v/v). The injection was then carried out. A white material, it sets in a few hours depending on the pH, concentration of formalin and temperature. It filled arteries, arterioles, but very little reached the venous circulation. The barium renders the medium radiopaque.

A disadvantage was the tendency of the material to fragment during dissection of the vessels containing it due to its particulate nature. This resulted in the vessels tearing, and particles of medium escaping.

A further disadvantage was discovered when decalcification was carried out in specimens containing bone. The medium was dissolved out and so vessel radiopacity was lost. This

occurred in spite of various decalcifying agents being used (RDC, picric acid, and EDTA).

iii. Microfil™ (Canton Bio-Medical Products Inc., Boulder, Colorado).

MV-117 Orange was used. This contains a lead chrome matrix to make it radiopaque. Before use the compound was mixed with an equal quantity (by weight) of diluent. Volume mixing required 5ml. of diluent for every 4ml. of compound. This mixture was then catalyzed with 5% (v/v) of curing agent prior to injection.

Microfil filled the microcirculation as well as arteries and arterioles when injected intra-arterially. In addition to widespread capillary filling veins were commonly outlined. This resulted in difficulties with dissection due to the dense network of filled vessels. At times veins could be confused with arteries. Also, the medium tended to prolapse out of any vascular channels cut and then break up. This obscured the clarity of the dissection and the resulting photographs. It was also the most expensive medium used and was only used for fetal injections.

iv. Indian ink in saline (10% v/v solution). (Black Indian Ink, Windsor & Newton, London, HA3 5RH).

This injection was only used in two adult cases where the soft palate was removed immediately following post-mortem examination. This precluded the use of the other agents.

v. Indian ink / Neoprene latex mixture

vi. Micropaque / Neoprene latex mixture

(Micropaque: Nicholas Laboratories Ltd., Slough).

These two injections were used on fixed adult cadavers. The Indian ink / latex mixture

reached the smallest vessels and passed through to the venous circulation in significant amounts. The ink was used as it was unaffected by clearing in methyl salicylate. The addition of Micropaque (100% w/v barium sulphate) allowed radiography to be carried out. The white barium is also unaffected by clearing.

For further details of preparation of these media see Appendix 3.

5.4 Injection Technique

Fixed adult cadavers

The technique used was that recommended by Tompsett (1970). A femoral artery and vein were cannulated and approximately 10 litres of normal embalming fluid were injected. Forty-eight hours later 1 litre of strong ammonia solution (1 part ammonia to 10 parts water) was injected.

Injections were given as follows :

<u>Injection Mass</u>	<u>No. Cadavers</u>
Red latex	5
Indian ink/Latex	4
Red latex/Micropaque	
+Blue latex/Micropaque	1

Injections were given into a femoral artery cannula using a Lear pump, supplemented on occasions by a further injection of medium into a common carotid artery using a fine catheter and a 50ml. syringe. Tompsett also recommended making a few small incisions at a distant site from the injection and stopping the injection when the mass appeared in these incisions. This was normally done. The total volume of injection varied from 750-1000mls.

In one case a venous injection was also made using blue latex / Micropaque mass. A cephalic vein tributary on the dorsum of the hand was cannulated and about 500 mls of the mass injected.

Fresh adult cadavers

The four specimens which were subsequently used for dissection were injected as follows:

<u>Injection Mass</u>	<u>No. Cadavers</u>
10% Indian ink	2
Schlesinger's medium	2

For these injections a No. 22 Argyle Medicut cannula (Fig.22) was used. Only small amounts were injected (1-7 mls). In the case of the two specimens injected with ink, the injections were done immediately following the post-mortem examination. The stumps of neck vessels were available for cannulation. After the injection the soft palate was removed through the open neck wound by transecting it flush with the posterior aspect of the hard palate. The tensor and levator muscles were removed with the palate by transecting their origins as near the skull base as possible.

The injections of Schlesinger's medium were carried out following removal of the soft palate. Again a No. 22 gauge cannula was used. 0.5-1ml. medium was injected until some was seen leaking from cut surfaces.

Fetuses

The specimens were made available following post mortem examination and with the cranium intact. The heart had been removed leaving behind the aortic arch in cases where this was free of pathology, or the great vessels of the neck if it had to be excised by the pathologist for further study. The superior vena cava had normally been ligated. A No. 22 gauge cannula was then placed in the brachiocephalic trunk or right common carotid artery and tied in position with a fine suture. Following injection of medium the cannula was removed and placed in the left common carotid artery in the same manner and this side was then injected. (In a few specimens only one side was injected).

Injections were given as follows:

<u>Injection Mass</u>	<u>No. Fetuses</u>
Red latex	5
Schlesinger's medium	9
Microfil*	3*

* In two cases venous injections were also made using 50:50 v/v blue latex/ Micropaque mixture.

In two cases of latex injected specimens prior fixation was performed by injection of

30-50 mls of 5% formalin in physiological saline. Formalin was injected until clear fluid exuded from veins and the head of the specimen began to blanch. Latex was normally injected 48 hrs. later.

The total volume of medium injected into each fetus varied according to its size and amount of leakage encountered. (Leakage could be controlled to some extent by gentle pressure over the area or by application of 10% acetic acid). If little leakage occurred 8-16mls was the common range. Injection was given using a 2ml or 5ml syringe with gentle hand pressure. As soon as resistance was felt the injection was stopped.

The venous injections were given in a similar way into the internal jugular vein.

Following injection, specimens were immersed in 5% formalin in physiological saline until required for dissection.

Chapter 6 Dissection Procedure

The total dissection of each specimen normally took 10-16 hours and occasionally longer.

6.1 Adult cadavers

Removal of block for dissection

The head and neck were removed by transection through the level of the lower cervical vertebrae, usually C5 / C6. In two cases the head was bisected in the mid-sagittal plane using a power-driven band saw. In all other cases the cervical vertebrae were then removed. A coronal cut was next made through the skull just posterior to the posterior pharyngeal wall passing through the parietal bone, squamous temporal bone and just anterior to the mastoid process. (Fig. 23) The posterior portion was discarded. The anterior portion of the brain was removed from the cranial cavity.

The mid and lower facial skeleton together with the central piece of the skull base was then removed as follows. Soft tissue incisions were made extending laterally and inferiorly from the nasal bridge along the infraorbital margin to the lateral orbital wall and from there passing laterally to the coronal incision. Bony cuts were then made with a Desoutter saw: anteriorly through the region of the frontonasal suture (and deep to this through the perpendicular plate of the ethmoid), the medial orbital wall, the lateral orbital wall; laterally through the greater wing of the sphenoid, and the squamous temporal (Fig. 23).

From the inner aspect of the skull further osteotomies were made: transversely across the lesser wing of the sphenoid; posteriorly across the middle cranial fossa (completing the previous cuts through the greater sphenoid wing and squamous temporal); and finally posteromedially across the petrous temporal to the margin of the foramen magnum (Fig. 24).

By using an osteotome and sharp dissection the midface, mandible and skull base, together with the pharynx and remaining neck contents, were then completely detached *en*

bloc leaving the orbital contents behind.

Dissection of each bloc

A total of 50 hemifacial dissections was carried out.

Both a posterior and lateral approach were used to the palate (Zuckerman, 1981).

Lateral dissection proceeded as follows:

The skin and subcutaneous tissue posterior to the oral commissure was removed. Parotid and masseter muscle were excised. Following removal of the zygomatic arch the temporalis muscle was removed. The buccal fat pad was dissected free. The head, coronoid process and ascending ramus of the mandible together with a portion of the horizontal ramus were then removed. This entailed freeing of muscle and soft tissue attachments along the posterior, inferior and anterior margins. Care had to be taken at this point to preserve the facial and maxillary vessels particularly the latter as they passed round the neck of the mandible. The temporomandibular joint capsule was incised, a saw cut was made through the anterior part of the horizontal ramus and the bone carefully prised outwards. The insertions of the lateral and medial pterygoid muscles and the origin of mylohyoid were divided close to the bone. The inferior alveolar nerve and vessels were divided and the mandibular segment lifted free.

The two heads of lateral pterygoid and any remaining temporalis fibres were excised carefully preserving the maxillary vessels and their branches. The lateral pterygoid plate was removed using bone nibblers or saw and this allowed removal of the medial pterygoid. (Zuckerman,1981). Just medial to this lies the tensor veli palatini and slightly posterior and medial to this is found the levator veli palatini.

The vessels reaching these muscles were carefully dissected. The maxillary vessels in some dissections were followed into the pterygomaxillary fissure. Any posteriorly directed branches were followed into bony foramina and an attempt made to determine if they reached the tensor and levator veli palatini muscles.

The posterior dissection was simpler. On removal of the vertebral column a portion of the longus capitis muscle was usually left attached to the block. This was first completely removed. The prevertebral fascia was then carefully excised preserving vessels on the posterior pharyngeal wall. Sternomastoid was removed. The ninth, tenth, and eleventh cranial nerves were dissected free as was the cervical sympathetic chain. The internal

jugular vein and common carotid artery were completely exposed. A detailed dissection was then carried out of the vessels supplying the posterior pharyngeal wall. This entailed further removal of bone from the basi-occiput so that the dissection could be carried right up to the pharyngeal tubercle.

Removal of palate

Following completion of the posterior and each lateral dissection the palate was removed. This was usually done after removal of the lips and buccal tissue for separate radiography in the cases where radiopaque medium had been injected. Using scissors, an incision was then made through the superior constrictor muscle and pharyngeal mucosa on either side and this was continued inferiorly down the lateral wall of the pharynx. In this way the palate, remaining skull base and posterior pharyngeal wall were separated from the tongue, remaining mandible, trachea and anterior pharyngeal wall.

Palatal Dissection

The mucosa of the oral surface of the soft palate was carefully removed, noting vessels passing into it from the submucosa. The fat and glandular elements in the submucosa were then dissected away exposing the muscles. The vessels entering the muscles were recorded. The muscles were then removed by detaching them from their insertions on the tensor aponeurosis and reflecting them posteriorly, observing their interrelationships and the intrapalatal course of the blood vessels. The blood supply of the nasal mucosa was examined.

In five cases the soft palate was not dissected but retained for clearing.

6.2 Fetuses

Removal of Block

This was virtually the same as for the adult dissection. The cranium was opened using scissors by cutting through the anterior fontanelle. Incisions were then made along the sagittal suture to the posterior fontanelle, and along the coronal and lambdoid sutures. Care was taken to avoid tearing the dura. The developing skull bones were then reflected outwards, much like opening the petals of a flower. The skull was then tilted and the brain gently removed by supporting it in one hand, cutting away the falx cerebri and tentorium cerebelli and dividing the cranial nerves and spinal cord.

The anterior and lateral "osteotomy" cuts were identical to the adult except that as the fetal skull is largely cartilaginous at the gestational age under study (up to 27 weeks) the cuts could be made with scissors. The interior skull base incisions were made using a scalpel supplemented with scissors. The whole block was then removed as already described for the adult dissections.

Fetal Dissection Technique

Owing to the small nature of the specimens, dissection had to be undertaken using a dissection microscope (Wild M400 Photomakroskop, Fig.25) and microsurgical instruments. The specimen was pinned to a cork board in the required position.

Complete dissection of each fetal head took about 10-16 hours, often the upper end of this time range. Initially difficulties were encountered in trying to identify the very small muscles found. The muscle colour was also much paler than adult cadaver muscle and the consistency much softer and more friable. However, with practice the fetal structures could be dissected and identified with confidence.

Removal of the mandible and lateral pterygoid plate was accomplished using scissors. The dissection in other respects was similar to that described for the adult cadavers. After the lateral and posterior dissections were completed the palate and skull base were removed and a palatal dissection carried out.

Detailed notes and photographs were taken at all stages of the dissections.

6.3 Raising of Pharyngeal Flaps

On a number of the specimens (eight fetal; two adult) pharyngeal flaps were raised. These were of various types: superiorly (4) or inferiorly based (2), Kapetansky (Kapetansky, 1973) (1), or Orticochea (3). Note was made of the vessels remaining intact to nourish the flap pedicle. The size and anatomical relationships differ between fetuses, young children and adults, but the vascular arrangement on the posterior pharyngeal wall once laid down in fetal life is very unlikely to alter significantly. For this reason it was considered valid to observe the effect that the elevation of these flaps would potentially have on their nutrient blood supply.

Chapter 7 Other Methods of Investigation

7.1 Radiology

Radiological examination was carried out on fetal specimens injected with either Schlesinger's medium or Microfil. An X-ray machine fitted with a Machlett OEG-50 tube was used. It was found that best results on soft tissue specimens were obtained with exposure times of 3-5 secs. at 20 Kv. and 5 mA. on Kodak Industrex CX film (a medium speed, fine-grain, high contrast, direct exposure film).

Films were developed in D19 Developer (stock diluted 1: 2 in water and heated to 20⁰C) for 4-6mins., fixed for 3mins. (Super Amfix) and washed in water for 20mins.

The specimens containing bone required decalcification prior to X-ray and it was found that whatever agent was used to do this (EDC, picric acid or EDTA), the barium contained in Schlesinger's medium was leached out and the radiopacity lost.

Radiology, using similar exposures, was also used to determine the completeness of the decalcification procedure prior to histological section of fetal heads, and prior to clearing. For adult palates prior to clearing, exposures of 32mAs and 46-50 Kv. were made. These last films were developed using M & B chemicals in a M100 Kodak processor.

7.2 Clearing Techniques

This was carried out using a modification of the technique of Spalteholtz (Bancroft & Stevens, 1982) and was performed on one fetal and five adult palates. The procedure for adult specimens was as follows:

1. Decalcification (normally in R.D.C.) overnight. Completeness assessed by X-ray.
2. 70% Methyl alcohol Change every 24 hours 2 days
3. 90% Methyl alcohol Change every 24 hours 2 weeks
4. Absolute alcohol (ethyl) Change every 24 hours 2 weeks
5. Methyl salicylate to clear. Change to remove alcohol remaining.

For fetal specimens, steps 3 and 4 were reduced to about 3 days.

As the methyl salicylate bleached out the red dye contained in the red latex mixture, in later specimens either barium or Indian ink was added to the latex to overcome this problem. Both of these materials are unaffected by the clearing agent.

As well as delineating blood vessels within the specimens, clearing had the added advantage of allowing some study of the three-dimensional arrangement of the vascular tree.

7.3 Histology

Examination of fetal specimens with cleft palate that were too small for dissection (three cases) was carried out by serial sectioning of the head. The block was removed from the fetus as already described and processed as described in Appendix 4. It was then placed in Paraplast™ along with four processed segments of human spinal nerve roots. These were orientated vertically on each side of the specimen to act as markers. Serial sections were cut at 10 μ .

Sections were mounted middle and end rows, either 1/10 or 1/12 and stained Masson (see Appendix 5).

In addition to the three cleft specimens, a fetus with a normal palate was used as control. Slides of a fourth cleft palate fetus were available for study. These had been stained H & E.

Some palatal and pharyngeal tissue of both fetal and adult specimens was stained either Masson or H & E (see Appendix 5).

7.4 Histochemistry

Six fresh adult palates were used for histochemical studies (for details of specimens see Appendix 1). Following removal the palates were placed in a thermos flask containing dry-ice for transport to the laboratory. The palatal muscles were then dissected out separately, labelled, and stored at -70°C . In several cases a portion of sternomastoid muscle was also removed to act as a control.

Histochemistry was carried out on the following muscles:

	<u>No. Specimens</u>
Levator veli palatini	6
Palatopharyngeus	4
Musculus uvulae	6
Sternomastoid (as control)	4

Preparation of sections

A block of each muscle was cut in transverse section while frozen and placed on a frozen chuck. Sections were then cut at 10μ . on a cryostat.

In the case of the levator specimens, two or three blocks were cut, where the site of each block was marked on a sketch of the muscle.

Fresh frozen or fixed sections were stained using the following histochemical methods:

- 1) alkaline phosphatase
- 2) aldehyde fuchsin
- 3) NADH_2 reductase
- 4) ATPase (pH 4.2, 4.6, and 9.4).

See Appendix 6 for details of these techniques.

Sections were also stained H & E to show the general orientation of the muscle fibres.

The first two techniques were used in order to obtain details of the intra-muscular arterial pattern within levator veli palatini. Alkaline phosphatase occurs in the vascular endothelium of afferent vessels 30μ or less in diameter (Moynahan et al, 1972). It is not present in veins and venules. Aldehyde fuchsin stains elastic fibres present in the wall of arterial vessels.

NADH₂ reductase and ATPase staining determined the fibre types within the muscles. NADH-dehydrogenase is an oxidative enzyme present in muscle fibre mitochondria. When muscle is incubated with NADH₂ and a colourless soluble tetrazolium salt, such as nitroblue tetrazolium, an insoluble coloured compound is formed at the site of the mitochondria. Type I muscle fibres with high enzyme content stain a darker blue colour compared to type IIb fibres, containing fewer mitochondria and less enzyme (Kremzier, 1984).

Myofibrillar adenosine triphosphatase, or ATPase, is an enzyme associated with myosin. The enzyme catalyses the splitting off of phosphate which in an alkaline environment (pH 9.4) forms insoluble calcium phosphate at the site of enzyme activity within the myofibre. Cobalt is then exchanged for calcium and when the muscle is then placed in a solution of ammonium sulphide black cobaltous sulphide is deposited. By variation of the pH of the reaction, it is possible to reverse the fibre typing (Kremzier, 1984). At pH 9.4, type I fibres stain light and type IIb fibres dark, reflecting their higher content of enzyme and anaerobic glycolytic activity.

The sections were examined under a light microscope and a visual assessment was made of the approximate percentages of dark and pale staining fibres. Detailed counting was not carried out.

7.5 Scanning Electron Microscopy

After fixation in Karnovsky's solution (Ito & Karnovsky, 1968), palatal specimens from suction terminations were processed as follows:

- | | | |
|--|------|-----------|
| 1. Wash in Millonig's phosphate buffer (pH7.4) | | Overnight |
| 2. Impregnate with 1% osmic acid | | 30mins. |
| 3. Wash in phosphate buffer | | 30mins. |
| 4. Dehydrate in acetone series | 50% | 60mins. |
| | 100% | 60mins |
| | 100% | 60mins. |
| | 100% | 60mins. |

7. Critical point dry from liquid CO₂
8. Mount specimen on aluminium stub
9. Dry in dessicator
10. Sputter coat with gold
11. Examine in Scanning Electron Microscope (Jeol JSM T 300)

7.6 Skull Examination

The bases of 31 dried adult Asian skulls, one fetal and seven child skulls were examined. Any foramina present at the bony origins of the tensor and levator veli palatini, *i.e.* in the scaphoid fossa and on the inferior aspect of the apex of the petrous temporal bone, were noted. These if present represented entry or exit points for small blood vessels passing between these muscles and the skull base. The vertical height of the lateral pterygoid plate to its lowest point was measured. (The hamulus would have been taken as a reference point but this had usually been broken off). This series of measurements was compared with those taken using calipers from fetal and a small series of children's skulls (approximate ages 6 months, 3-4 yrs., 7-8 yrs., 8-9yrs., 9-11 yrs., 14-16 yrs.).

The distance gives an indication of the depth of dissection required to reach the skull base during cleft palate closure.

7.7 Photography

The methods used were as follows:

Scanning Electron Microscopy: Camera contained in Jeol JSM T300. Kodak 120 Technical Pan TP120 film.

Adult cadaver dissections : Tripod mounted Olympus OM2 SLR camera with a 50mm macro lens and flash attachment. Kodak Vericolor III film.

Fetal dissections: Camera attachment (Photoautomat MPS 55) on the Wild dissecting microscope. Lighting was by means of two tungsten lamps. The automatic mode was used throughout for exposures. Kodak Vericolor III film.

Fetal palatal specimens, general views: Nikon 35mm camera with 105mm or 55mm macro lens and studio flashlamps. Kodak Vericolor III film.

Cleared specimens: Submerged in methyl salicylate. Nikon 35mm camera, 105mm or 55mm macro lens. Lighting by two tungsten overhead lamps and transillumination. Kodak Panatomic X film.

Slides from histological and histochemical preparations: Leitz Vario-Orthomat Orthoplan light microscope with camera attachment. Wratten No. 80A filter. Kodak Vericolor III film.

7.8 Clinical Material

An operative series of photographs of a one-stage cleft palate closure performed by the author on a 12-month old child is included (Fig.105). The child had a complete unilateral cleft of the secondary palate, and had previously undergone bilateral lip repair.

OBSERVATIONS

General Comments on Injection Results

The results achieved varied from case to case and from one medium to another. Most media to a lesser or greater extent reached the venous circulation if injected arterially. Fig. 26 shows the posterior pharyngeal wall of a fetus injected with red latex. Medium can clearly be seen in the inferior thyroid vein following injection into the common carotid artery. Indian ink and Microfil both showed a particular propensity to pass through the capillary bed following arterial injection. An example of the former is shown in Fig.27. Schlesinger's medium did not reach the venous circulation.

In the adult cadavers the best results were obtained with the Indian ink / latex mixture. The small palatal arteries were regularly filled. With the red latex injected specimens the results were patchy with some specimens giving excellent results and others poor.

Generally it was found that better photographic results were obtained with the fetal specimens and so the majority of illustrations are from this group. Schlesinger's medium in particular gave good results.

In most of the illustrations the arteries only are shown. For clarity the veins were removed during dissection. Considerable information was gained about the pattern of venous drainage of the areas under study. This will be described and illustrated where appropriate.

Chapter 8 Identification of Extrapalatal Blood Supply of Levator and Tensor Veli Palatini Muscles

The arbitrary boundary between extrapalatal and intrapalatal has been made with reference to the pterygoid hamulus, structures lateral to this landmark being described as extrapalatal.

8.1 Normal Fetal Specimens

Three arteries were found to be involved in supplying these muscles:

- 1) ascending palatine artery
- 2) ascending pharyngeal artery
- 3) accessory meningeal artery.

Ascending palatine artery

This vessel arose either from the medial aspect of the trunk of the external carotid artery at the origin of the facial artery, or more commonly from the facial artery itself near the commencement of this vessel. It normally passed between styloglossus and stylopharyngeus, giving supply to both these muscles. Isolated cases were seen where the artery passed either superficial or deep to styloglossus (Fig.28a,b). Continuing upwards it lay on the lateral surface of the superior constrictor muscle, between it and the medial pterygoid, giving small branches to both. It reached the lower border of the tensor veli palatini close to the pterygoid hamulus. Figs.29,30 show typical courses.

Here at the upper border of the superior constrictor it passed medially between the tensor and levator veli palatini giving small branches to the inferior aspect of both muscles. (Figs.31,32). A further vessel was often noted passing up to supply the auditory tube. From the point the vessel passes medial to the hamulus it can be described as being intrapalatal and its continuing course is described in Chapter 9.

Ascending pharyngeal artery

This vessel arose from the external carotid artery in all but one case, where the origin was the internal carotid. In six cases the artery was duplicated and in a single case three vessels corresponding to the ascending pharyngeal were seen. (In Chapter 11 on posterior wall supply further description of these vessels is given). The two most common sites of origin from the external carotid were at the level of origin of the lingual artery and at the origin of the occipital artery.

The main vessel passed up medial and anterior to the internal carotid artery situated between this vessel and the posterior pharyngeal wall. As it reached the skull base (petrous temporal bone) it normally gave off a branch which ran forward on the lateral aspect of the pharyngobasilar fascia. This reached the posterosuperior aspect of the levator and at this point small twigs were given to supply this muscle (Figs.33,34).

Accessory meningeal artery

The accessory meningeal artery arose directly from the maxillary artery, from the middle meningeal artery, or from the bifurcation of these two vessels. It passed upwards anterior to the middle meningeal artery at the posterior edge of the lateral pterygoid plate towards the foramen ovale. It gave branches to the lateral and medial pterygoid muscles. On removing the lateral pterygoid plate a branch was regularly seen to pass between the medial pterygoid muscle and the upper lateral surface of the tensor veli palatini. At this point a number of small twigs were seen to enter the tensor. (Figs. 35,36) In some cases recurrent branches from this vessel were seen passing up into the skull base. The vessel continued towards the hamulus but was normally spent by the time this was reached. In one particularly well injected specimen an anastomosis was demonstrated on the lateral surface of the tensor with a branch of the ascending palatine artery (Fig. 37).

A network of veins was sometimes observed on the lateral aspect of the tensor. These drained either inferiorly into the ascending palatine veins or posteriorly into the pharyngeal venous plexus.

Fig.38 illustrates the relationships between the three arteries described above.

8.2 Adult cadavers

Similar observations on the arterial supply were made with the adult specimens. Initial difficulties were encountered in exposing the branch of the accessory meningeal artery that supplied the tensor veli palatini muscle. Adequate exposure of this vessel deep to the lateral pterygoid plate and medial pterygoid muscle is difficult in the adult and in some poorly injected specimens it was not clearly identified.

A striking finding was the noticeable tortuosity of the ascending palatine artery as it passed up on the superior constrictor muscle towards the tensor. (Fig.39). The appearance was similar to the better known tortuosity of the facial artery as it crosses the cheek.

In seven dissections the branches of the third part of the maxillary artery in the pterygomaxillary fissure were explored and the small branch passing into the pterygoid canal followed. In only a single case was a vessel of significant size found to approach close to the scaphoid fossa, and in no case to reach the origin of the levator from the petrous temporal bone. It was concluded that no significant arterial supply reaches either of these muscles through the pterygoid canal in most cases.

As with the fetal specimens, significant venous plexuses were identified on a number of occasions on the lateral surface of the tensor muscle (Fig.40). These venous channels were lateral to the arterial branch of the accessory meningeal and communicated with veins on the inferior and lateral surface of the levator. From here drainage was either to venae comitantes alongside the ascending palatine artery or posteriorly to pharyngeal veins and finally into the internal jugular vein.

The ascending palatine artery on both sides of one specimen clearly failed to reach the palate. Its distribution was taken over by a branch of the ascending pharyngeal artery which turned down near the skull base and looped round to the inferior aspect of the tensor.

The findings on the extrapalatal arterial supply of the levator and tensor muscles in specimens with normal palates are summarized in Tables 1 and 2.

Table 1 **Arterial Supply Levator Veli Palatini**
Normal palates (Fetal / Adult)

		Number Muscles	Percentage
Dual supply	all cases asc.pal./ asc. pharyngeal	31	70
Single supply	asc.palatine	7 }	30
	asc.pharyngeal	6 }	
	Total	44	100

Table 2 **Arterial Supply Tensor Veli Palatini**
Normal Palates (Fetal / Adult)

		Number Muscles	Percentage
Dual supply	acc. meningeal / asc. palatine	27 }	79
	acc. meningeal / asc. pharyngeal	3 }	
	acc. meningeal / lesser palatine	1 }	
Single supply	acc. meningeal	5 }	21
	asc. palatine	2 }	
	ascending pharyngeal	1 }	
	Total	39*	100

* 5 muscles excluded as either accessory meningeal artery not identified at dissection or no information recorded in notes.

It can be seen from these tables that the levator and tensor in most cases had a dual arterial supply. These figures could be falsely low. In some cases where only a single vessel supply was identified it is possible that failure to identify a dual supply resulted from lack of filling of the second vessel or its branches with the injected medium.

Only two arteries were responsible for the supply to the levator muscle, namely the ascending palatine and the ascending pharyngeal. Observations suggested that branches from these vessels gave supply in a segmental fashion to the extrapalatal portion of the muscle. In a number of dissections it was quite clear that one or other of these vessels failed to reach the palate. A single artery then took over the complete supply. In no case did the accessory meningeal artery give a contribution.

A higher figure (79%) was obtained for dual supply of the tensor. This again could be lower than the true situation due to a few poorly injected specimens. The most important supply to this muscle came via a branch of the accessory meningeal artery which regularly passed along its upper lateral border, sandwiched between it and the medial pterygoid muscle. The ascending palatine artery, giving supply to the inferomedial surface, also participated in most cases.

Apart from the ascending palatine and ascending pharyngeal vessels, the lesser palatine arteries, small branches from the facial and occasionally lingual arteries were found to enter the soft palate. The facial and lingual vessels entered the soft palate through the palatopharyngeal arches.

9.1.i Mucosal Supply (Oral)

The oral mucosa was found to receive its arterial supply from two types of vessels. The first was a series of direct arterial or arteriolar branches from the vessels feeding into the palate that passed through the glandular elements into the submucosal plexus and then into the mucosa itself. The second was a number of myomucosal perforators that were seen passing out through the palatopharyngeus and palatoglossus muscles en route to the mucosa. (Fig.41) Most of the supply came from the latter type. The submucosal plexus can be seen in Fig.42 and consisted of a network of veins and small arteries situated in the superficial glandular layer. Fig.43 shows the oral mucosa removed from a soft palate. Where the mucosa has been elevated superficially, the submucosal vessels have been left behind.

9.1.ii Mucosal Supply (Nasal)

The supply here was similar to the oral side with direct mucosal vessels and myomucosal perforators arising from arteries feeding into the palate. The perforators were usually seen passing through the levator muscle. Fig.44 shows an area where a rich nasal mucosal network has been exposed.

The veins draining the soft palate in the main passed out laterally into the larger vessels situated around the tensor and levator muscles, and from there into the pharyngeal veins posteriorly or inferiorly into the facial system.

9.1.iii Intrapalatal Muscular Supply

Particular attention was paid to the supply of the intrapalatal portion of the levator muscle in view of its clinical importance.

Series of illustrations showing the typical course of intrapalatal vessels are found in Figs.45-49.

The main artery entering the soft palate, usually the ascending palatine but occasionally the ascending pharyngeal, did so between the levator and tensor muscles. At this point it divided into two main terminal branches. The anterior one passed forward very close to the pterygoid hamulus, giving small twigs to this structure, before running deep to the mucosa on the nasal side of the palate along the lateral nasal wall. The posterior branch turned medially and either passed deep to, through, or superficial to the intrapalatal portion of the levator (as viewed from the oral surface). This branch gave off small vessels to supply this portion of the levator and the overlying palatopharyngeus. It then turned posteromedially towards the midline reaching the musculus uvulae which it finally supplied. The artery and branches were accompanied by venae comitantes.

It was also common to find branches of the ascending pharyngeal artery passing through the uppermost fibres of the superior constrictor or through the pharyngobasilar fascia to reach the posterior part of the velum giving supply to palatopharyngeus in this area. Other small branches of the facial (tonsillar) artery entered palatoglossus and palatopharyngeus in the region of the palatopharyngeal arches, and were found to reach the posterior part of musculus uvulae.

Branches of the accessory meningeal artery were not found to enter the soft palate in a single case, the distribution being confined to the tensor muscle belly which is entirely extrapalatal.

The lesser palatine vessels were not found to give significant supply to the palatal muscles, their distribution confined to the junction of the hard and soft palate and maxillary tuberosity area (Freedlander & Jackson, 1989).

9.2 Adult Cadaver Intrapalatal Dissections

The pattern of vessel distribution corresponded to the fetal observations. Cleared specimens showed an intricate network of vessels throughout the soft palate which communicated across the midline (Fig.50). The main intrapalatal branch of the ascending palatine artery was found in a well injected specimen to pass through the medial or intrapalatal portion of the levator before reaching the musculus uvulae (Fig.51). Accompanied by its venae comitantes it gave small branches as it passed through (Fig. 52). This vessel could also be seen on X-rayed specimens (Fig. 53), and details of its termination are shown in Figs.54,55.

Apart from branches of the ascending pharyngeal artery, small facial and lingual artery branches were noted in the posterior part of the soft palate.

Palatopharyngeus and palatoglossus were supplied by branches from the ascending palatine in their anterior portions and posteriorly by branches of the ascending pharyngeal and lingual arteries. These last were seen entering both muscles in the faucal area.

10.1 Extrapalatal Blood Supply of Levator and Tensor Veli Palatini in Cleft Specimens Dissected

Three cleft palate specimens were large enough to dissect. Two had complete clefts of the palate with absence of the primary palate ('median' cleft lip and palate) (Fig.20), and the other had a partial cleft of the secondary palate including the soft palate (Fig. 21).

Branches of the ascending palatine, ascending pharyngeal, and accessory meningeal arteries were found to be the supplying vessels as in the normal cases. Their origins were as previously described, although in a single case the ascending pharyngeal artery arose from the occipital artery. Two minor anomalies of the early part of the course of the ascending palatine artery were found. In one specimen (cleft of secondary palate) both ascending palatine arteries passed lateral to styloglossus. This had been noted occasionally with normal specimens. However, in one of the complete clefts one ascending palatine artery passed through styloglossus. The ascending pharyngeal and accessory meningeal arteries pursued courses as already described for the normal group.

The majority of the levator and tensor muscles had a dual supply. Details are summarized in Tables 3 and 4.

Table 3**Arterial Supply Levator Veli Palatini
Cleft Palate Specimens**

		Number	Percentage
Dual supply	asc.palatine /	3 }	67
	asc. pharyngeal		
	asc. pharyngeal / acc. meningeal	1 }	
Single supply	asc.palatine	1 }	33
	asc. pharyngeal	1 }	
	Total	6	100

Table 4**Arterial Supply Tensor Veli Palatini
Cleft Palate Specimens**

		Number	Percentage
Dual supply	acc.meningeal /	3 }	80
	asc. palatine		
	acc. meningeal / asc. pharyngeal	1 }	
Single supply	acc. meningeal	1 }	20
	Total	5*	100

* 1 muscle excluded as accessory meningeal artery not identified at dissection.

Illustrations from these cases are found in Figs. 56-58.

It can be seen from Table 3 that the commonest pattern of supply to the levator was a double one from the ascending palatine and ascending pharyngeal arteries. An exception was observed in a single muscle where the accessory meningeal artery gave supply in place of the ascending palatine, which failed to reach the palate. In this specimen with a complete cleft, the opposite ascending palatine also failed to reach the palate, but here the ascending pharyngeal became the sole source of supply to the muscle.

A dual arterial supply was noted in four out of five tensor muscles (Table 4) where the relevant feeding vessels could be identified. In three cases the ascending palatine and accessory meningeal arteries both gave supply.

The extrapalatal venous drainage appeared identical to the normal dissections in that veins passed either posteriorly and laterally into the pharyngeal plexus or collecting veins around the lower border of the tensor emptied into veins accompanying the ascending palatine artery.

10.2 Intrapalatal Cleft Palate Dissections

Because of hypoplasia of the cleft soft palates little intrapalatal dissection was possible in the lateral-medial direction. This dissection was only of value in following the detailed blood supply in the two specimens with complete clefts. In the third fetus injected with latex, the medium failed to reach the palate.

In the specimen injected with Microfil, when the mucosa was removed from the hard/soft palate junction a network of filled vessels, both arteries and veins, was noted in the submucosa. A number of vessels were seen passing up into the mucosa from this network (Fig.59) and in elevating the mucosa these were severed. The ascending palatine vessels entered the palate between the tensor and levator in this same specimen.

In the remaining cleft specimen with a complete cleft palate, injected with Schlesinger's medium, the right palatopharyngeus muscle was supplied by the ascending pharyngeal artery, which also gave supply to the levator (Fig.60a). The accessory meningeal gave a branch to the levator entering its anterior surface just posterior to the hamulus (Fig.60b).

On the left side, palatopharyngeus was again supplied by the ascending pharyngeal in the region of the posterior palatopharyngeal arch. This artery was confirmed to be the sole supply of the levator (Fig.61). Palatoglossus was fed by small branches of the facial artery. An anastomosis was noted between the ascending pharyngeal and accessory meningeal posterior to the hamulus. Near this structure a branch of the ascending pharyngeal passed into the intermingled medial portions of the levator and palatopharyngeus, and continued on to reach the uvula. The musculus uvulae was not identified.

The intrapalatal venous pattern was as noted previously in the normal palates with venae comitantes running with the arterial vessels and draining into a plexus in the region of the extrapalatal part of the levator and tensor.

The mucosal blood supply based on the dissection findings of both normal and cleft cases is shown diagrammatically in Fig.62. The majority of feeding vessels reaching the mucosa have to pass through muscles, principally the levator and palatopharyngeus. The possible clinical importance of the pattern of supply will be discussed later.

10.3 Findings on Serially Sectioned Fetal Heads

From careful examination of serial sections, the courses of the three main arteries supplying the soft palate (ascending palatine, ascending pharyngeal and accessory meningeal) were determined.

In the serially sectioned head of the specimen with the normal palate, the ascending palatine arteries were found to pursue an identical course to that found by dissection. Fig.63 shows the ascending vessels at the inferior border of the levator and tensor muscles. Branches of the accessory meningeal artery are identifiable in Fig.64 between the tensor and medial pterygoid as was also found on dissection.

In the specimen with the cleft of the primary palate alone, extrapalatal vessel distribution to the palatal muscles was very similar to the normal fetus serially sectioned. Views of branches of the ascending palatine and accessory meningeal vessels are shown in Fig.65.

Sections from the two remaining specimens examined by serial sections with the cleft of secondary palate alone and complete cleft of primary and secondary palates respectively are shown in Figs.66-70. The pattern of vessel distribution was similar to normal palates.

Comment on Histological Findings

It was not possible to trace the individual branches of the various vessels entering the palatal muscles owing to the complexity of the vascular pattern and also to small areas of haemorrhage sometimes seen within the tissues.

The overall pattern of supply of the normal specimen sectioned, the three cleft specimens sectioned, and dissected specimens appeared very similar.

11.1 Specimens with Normal Palates (Adult and Fetal)

Twenty-three full dissections were completed. In four of these (three adult cadavers and one fetus) a poor injection resulted in failure to fill the appropriate vessels on the posterior pharyngeal wall and so no useful information regarding blood supply was obtained. In one further fetus most of the posterior wall had been previously excised. Eighteen cases are therefore considered below.

Typical appearances of the vessel pattern can be seen in Figs.71-74.

Two arteries were found to be involved in supplying the portion of the posterior pharyngeal wall that is commonly used to provide tissue for pharyngoplasties (that is, down to the lower border of the third cervical vertebra). These were the ascending pharyngeal and superior thyroid arteries with the first of these being the most important. In the 36 sides of the 18 cases it was found that there was duplication of the ascending pharyngeal artery in six cases and three vessels in a single case. The commonest origin for the artery was from the medial wall of the external carotid at the level of the origin of the lingual and facial arteries. The ascending pharyngeal artery(ies) gave two or three branches to the upper part of the posterior pharyngeal wall above the level of the greater cornu of the hyoid bone. These branches formed an anastomotic network, and at times anastomoses were seen with vessels from the opposite side. In some dissections a branch of the superior thyroid artery passed on to the posterior wall at the level of the laryngopharynx. Branches of the facial and lingual arteries were not seen to contribute to the posterior wall supply at this level.

Arterial branches were also observed passing from the posterior wall to the longus capitis muscles on either side of the midline. These passed through the prevertebral fascia.

It was noted that the venous drainage was arranged in a characteristic manner and followed two routes: a central longitudinally arranged series of veins draining first downwards and then laterally, and a laterally situated network at the junction of the posterior and lateral pharyngeal walls. The final common pathway was drainage into the internal jugular veins. It was noticeable that neither the arteries nor the veins coursing

over the posterior wall conformed to a segmental pattern. A segmental pattern, however, was seen over the posterior aspect of the upper oesophagus.

An important feature noted in all well injected specimens was the constant presence of a very high branch given off the ascending pharyngeal just before this vessel entered the skull base. This branch passed on to the posterior wall at the level of the pharyngobasilar fascia (Figs.75,76).

Histological note: cross sections of normal adult posterior pharyngeal wall revealed that arterial branches pierce the muscular coat of the pharynx and ramify in the submucosa (Fig.77).

11.2 Cleft Palate Fetuses

Dissections were possible on four specimens. In three of these cases there was a single ascending pharyngeal vessel on either side feeding the upper part of the posterior pharyngeal wall via several branches. In one case, in addition to the main artery, two very small accessory ascending pharyngeal arteries were noted passing to the posterior wall. Supply from the superior thyroid artery was observed in two cases. The venous drainage pattern was as seen for the normal cases.

The overall pattern of the blood supply to the upper part of the posterior wall in the cleft cases appeared identical to non-cleft cases.

11.3

Pharyngoplasties

As the blood supply to the area of the posterior wall under study appeared to be identical in cleft and non-cleft cases, various pharyngoplasties were raised in both groups. This was to offset the obvious shortage of cleft specimens.

As mentioned previously the following pharyngoplasty flaps were raised: superiorly based pharyngeal flap (4 cases); inferiorly based pharyngeal flap (2 cases); Orticochea flaps (3 cases); Kapetansky flaps (1 case).

It was noted that raising a superiorly based pharyngeal flap cuts off all the feeding arteries from branches of the superior thyroid and ascending pharyngeal artery coming in from below and laterally. However, even if the base of the flap was obviously above the level of the palate, it was seen that the branch from the ascending pharyngeal passing across the pharyngobasilar fascia just below the skull base was always preserved (Figs. 78,79). Similarly one or two of the highest veins were preserved.

The supply of the inferiorly based flaps appeared on gross appearance to be more robust. All the arterial branches from the ascending pharyngeal were divided, but branches from the superior thyroid arteries were outwith the incision area and so were undisturbed. Similarly the midline draining venous system was also left intact. (Fig.80a,b).

As there are constant vessels both arterial and venous situated laterally it is clear that flaps based laterally should have a secure blood supply. Fig.81a,b shows such a laterally based flap as designed by Kapetansky (1973). It was seen that both the arterial inflow and venous drainage should be more than adequate to drain these flaps.

The cleared specimen in Fig.82 indicates that in the region of the palatopharyngeal arches there is a rich network of vessels in the form of interconnecting arcades arranged in a mainly longitudinal direction. This ensures that in raising flaps such as that designed by Orticochea (1968) this longitudinal arrangement will be preserved and so will tend to ensure the flap's viability.

Unrelated to the supply of the posterior wall itself, but of obvious surgical importance in considering raising flaps from the posterior palatopharyngeal arch and posterior wall is

the course of the internal carotid artery. In most cases this vessel ascended from its origin from the common carotid artery to the skull base in a fairly direct manner, situated just lateral to the pharynx. However, in at least one occasion (see Fig.71) the arteries showed a more tortuous course. The clinical significance of this will be discussed later.

Some interesting observations were made on the palatal anatomy of both the normal and cleft cases. Due to the extreme scarcity of anatomical reports of cleft palate specimens in the world literature these have been recorded in detail. Attention will be mainly directed towards describing details of the patterns of insertion of the palatal muscles, as this is of particular relevance to cleft palate surgery.

12.1 Normal palates (Adult and Fetal)

Levator veli palatini

This cylindrical muscle could be followed well into the soft palate as a discrete entity, only becoming intermingled with palatopharyngeus a short distance from the midline. It ran in close contact with the nasal mucosa in the lateral part of the soft palate. Its anterior fibres in some dissections passed forwards to be inserted into the aponeurosis. The majority of the fibres turned medially to unite with corresponding fibres of the other levator, forming a muscular sling in the mid portion of the velum.

It was noted from adult dissections that as the levator passed into the soft palate the upper or nasal fibres "rolled over" the lower ones in such a way that the upper ones became posterior and the lower ones anterior. The appearance was analogous to gentle twisting of a piece of string.

Tensor veli palatini

Apart from arising from the scaphoid fossa, some fibres were seen to take origin from the lateral cartilaginous part of the auditory tube. On approaching the hamulus some fibres were noted to insert via a small tendon into the maxillary tuberosity. Also, in at least one adult dissection a few fibres passed lateral to the hamulus to be inserted into the pterygomandibular raphe. No insertion of the tensor veli palatini into the hamulus itself was noted.

Palatopharyngeus

A lateral portion of this muscle ran forward to the aponeurosis superficial to the levator as seen from the oral surface. (A few fibres could be seen reaching the posterior nasal spine in one fetal specimen [Fig.83]). Most of the muscle fibres from the posterior palatopharyngeal arch passed on the oral side of the levator as they ran forward with some reaching the aponeurosis and the rest turning medially to intermingle with the levator and merge with those of the opposite side. At times fibres of the intermixed levator / palatopharyngeus mass were seen to insert into the oral and nasal mucosa in the central portion of the velum towards the midline, as sharp dissection was required to free it from the mucosa.

Palatoglossus

This muscle was most clearly seen in adult specimens and particularly in fresh palates. It consisted of a thin band of muscle measuring 4-7mm in width. Laterally in the soft palate where it was seen to merge with the superior constrictor, it was situated just deep to the mucosa and superficial to palatopharyngeus. Medially, it passed deep to the glandular, fatty tissue as it travelled towards its neighbour from the opposite side. It could be followed as a separate muscle well into the palate. Towards the aponeurosis into which it inserted, it became fused with fibres of palatopharyngeus.

Musculus uvulae

Discrete longitudinally running muscle bundles were identifiable at the midline in both fetal and adult dissections. Posteriorly the muscle entered the uvula, but anteriorly it petered out as it approached the aponeurosis and did not reach the hard palate. It was surrounded by a considerable amount of glandular tissue in the adult specimens.

12.2 Cleft Palate Specimens

The most striking observation on inspection of the cleft specimens was the obvious hypoplasia of the two palatal halves. Not only was this noticeable in the transverse direction but also in the anteroposterior. In other words the palate was noticeably short. It was observed, for example, that the hamulus was in almost the same coronal plane as the hemi-uvula (Fig.84) In normal cases the hamulus was considerably anterior to the hemi-uvula.

Levator veli palatini

Owing to the importance of the levator muscle in cleft palate surgery the findings in each specimen dissected will be described in full.

1. Complete cleft of primary and secondary palate

The extrapalatal portion of the levators did not appear hypoplastic. Most fibres ran medially towards the free margin of the soft hemi-palate. Anterior fibres of the right levator ran round the hamulus into the tensor aponeurosis. Similarly the bulk of the left levator ran not towards the hard palate but medially towards the cleft edge and hemi-uvula (Fig.85a,b,c).

2. Complete cleft of primary and secondary palate

The right levator ran medially towards the hemi-uvula with only some anterior fibres passing forwards towards the back of the hard palate. The left levator pursued a similar course, most of the muscle running towards the cleft edge. (Fig.86). Medially the levator was crossed by anterior running fibres of palatopharyngeus. At this point the mass formed by these two muscles was dissected off the aponeurosis. Intermingled fibres inserted into the cleft edge, nasal mucosa and also into the back of the hard palate.

3. Cleft of secondary palate

The extrapalatal part of each muscle appeared of normal bulk but the intrapalatal portion hypoplastic. The right levator inserted into the tensor tendon round the hamulus and aponeurosis. Medially a few fibres merged with palatopharyngeus and reached the back of the hard palate (Fig.87a,b). The left muscle inserted into the tensor tendon, aponeurosis and nasal mucosa. Some fibres came to run almost parallel to the aponeurosis and appeared to insert into the nasal side of the hard palate shelf (Fig.87a,c).

Tensor veli palatini

The tensor veli palatini muscle belly did not appear to be hypoplastic in these cases. In one muscle a few fibres inserted into the hamulus and some others into the maxillary tuberosity. In the other cases the fibres converged on the tendon which rounded the hamulus and was then inserted into a rudimentary aponeurosis. This aponeurosis was seen in each case. Although deficient it ran slightly forwards towards the angle between the cleft edge and the bony hard palatal shelf. In two specimens superior constrictor and palatoglossus fibres were seen inserting into the tendon or aponeurosis.

Palatopharyngeus

Hypoplasia of this muscle was noted. As already described some fibres were seen to insert into the hard palate, with others inserting into the oral mucosa of the mid part of the soft palate.

In dissecting the "muscle" off the posterior hard palate shelf it could be seen that the majority of this was composed of palatopharyngeus fibres rather than levator.

The muscle insertions of the levator and palatopharyngeus are represented schematically in Figs.88,89. Note how the quantity of muscle fibres reaching the hard palate edge can vary from one side to the other.

Palatoglossus

Palatoglossus was clearly identified in two specimens. As in normal cases fibres inserted into the aponeurosis.

Musculus uvulae

This muscle was identified in two of the three dissected cleft specimens. In one it was composed of a thin band of muscle running along the cleft margin of the soft palate. It was juxtaposed to and could easily be rolled off the nasal mucosa. It appeared to reach the posterior edge of the hard palate. In the second specimen the muscle was represented only by a few longitudinally running fibres along each cleft margin.

12.3 Observations on Nerve Supply to Palatal Muscles

It is of interest to record some observations made during the course of fetal dissection on the innervation of the levator and tensor muscles. Relevant observations were only possible in a few cases, as in dissection of the vascular tree it was not usually possible to preserve fine nerve branches.

In three fetal dissections (two normal and one with cleft palate) very fine nerve fibres were identified passing from the glossopharyngeal nerve to the levator muscle. These fibres looped up across the pharyngobasilar fascia reaching the posterolateral aspect of the muscle (Fig.90). The nerve supply to the tensor was identified in a single dissection. Fascicles from the mandibular branch of the trigeminal nerve (via nerve to medial pterygoid) approached the superolateral part of the tensor in close proximity to the arterial branches from the accessory meningeal artery, entering the same portion of the muscle (Fig 91).

12.4 Anatomical Findings of Cleft Palate Specimens Examined Histologically

Observations similar to those made on the dissected cleft specimens were recorded on the specimens with clefts involving the secondary palate. Fig.92a shows the "cleft " muscle fibres inserting into the edge of the bony palatal shelf and overlying nasal mucosa. Slightly posterior to this, levator and palatopharyngeus fibres were seen inserting into the aponeurosis (Fig.92b). Within the soft hemi-palate, Fig.92c and Fig.92d show some levator fibres passing medially towards the cleft edge.

In the fetus with the unilateral complete cleft of primary and secondary palate, Fig. 93a again shows an aponeurosis. Levator fibres are clearly seen streaming medially into the base of the hemi-uvula in Fig.93b,c.

The specimen with the cleft of the primary palate alone had a normal soft palate with musculature of normal appearance.

Chapter 13 Histochemical Findings

13.1 Intramuscular Vascular Patterns

Alkaline phosphatase staining demonstrated a rich arteriolar network within all levator specimens examined. The endothelium of both small and large vessels were stained. Staining within the endothelium of an artery entering the muscle can be seen in Fig.94b in addition to the staining of many smaller vessels. In the case of aldehyde fuchsin stained sections, only larger vessels were picked out. In sections of levator muscles taken through the upper, middle and lower (medial) portions respectively neither method of staining demonstrated a specimen where there was a significant arterial vessel running through the upper part near the muscle origin. Fig.94 a-c show an example of this for alkaline phosphatase and Fig.95 a-c a different specimen stained for aldehyde fuchsin. The significance of this will be discussed later.

13.2 Identification of Muscle Fibre Type

The results of NADH₂ reductase and ATPase staining are shown in Table 5.

Table 5 Percentage Fibre Types in Palatal Muscles

Muscle	NADH ₂		ATPase	
	% type I	% IIb	% type I	% IIb
Levator	30	70	20	80
M. uvulae	40	60	50	50
P'pharyngeus	40	60	50	50
(S'mastoid)	40	60	50	50

Results showed that each palatal muscle examined, along with sternomastoid, contained two types of muscle fibre with the levator appearing to have a greater proportion of type IIb fibres than the others. Type IIa fibres could not be confidently identified in the sections examined.

Some problems were encountered with freezing artifacts. This caused spaces between groups of muscle fibres, but the fibres themselves appeared healthy. Fig.96 shows a frozen section of levator muscle stained for ATPase. Dark type I fibres are seen in small numbers among paler staining type IIb fibres. In a section of musculus uvulae (Fig.97), interspersed among fat spaces are roughly equal numbers of type I and type IIb fibres.

A further section of the same specimen as Fig.97 can be seen in Fig.98 stained for NADH₂ reductase. Palatopharyngeus stained for NADH₂ reductase is illustrated in Fig.99. In this particular section mainly darkly staining type I fibres are shown. Finally, a higher power view of a section of levator is seen in Fig.100 showing the two fibre types.

14.1 Measurements

The heights of the lateral pterygoid plates of 31 dried adult skulls and the child skulls are listed in Appendix 7. The mean adult value was 21mm. In the child skulls the corresponding measurement was 9mm at six months, 15mm at 3-4 years and 19-21mm by 14-16 years.

The vertical height of the lateral pterygoid plate gives an indication of the distance between the skull base and the palate. The distance between the scaphoid fossa and the hard palatal shelves was found to be a few millimeters less than this distance. Fig.101 a-c shows how the upper alveolus and thus the hard palate descends relative to the skull base with growth.

Foramina were identified in the region of the bony origin of the levator veli palatini in 16 adult sides out of a total of 62. As opposed to this, foramina were identified at the origins of 43 tensor veli palatini muscles. It is assumed that at least some of these foramina transmitted tiny blood vessels during life. The number of foramina varied from one to four. In the child skulls, foramina were seen in the scaphoid fossa in six cases, but in only one case at the bony origin of the levator.

The striking difference in the number of small foramina seen around the bony origin of the levator compared with that of the tensor, in 26% compared with 69% of cases respectively, indicates that, in the majority, little circulation enters or leaves the former muscle through or around its bony origin.

GENERAL DISCUSSION

15.1 Some General Comments

A prerequisite for successful cleft palate surgery is thorough knowledge of the anatomy, including vascular anatomy, of the deformity. It has been recognised for some years that more research was required into palatal blood supply (Kriens,1969; Maue-Dickson,1979; Maue-Dickson & Dickson,1980). This thesis has addressed the problem by investigating the blood supply of the human soft palate and posterior pharyngeal wall in normal and cleft cases. Detailed information on the blood supply of individual palatal muscles has not been previously reported.

The main object in studying the blood supply of these areas was to explore ways in which operative techniques could be improved and surgery carried out in such a way as to minimise disturbance to the vascular anatomy. It is recognized, however, that cadaveric dissection and examination of histological material can only allow provisional conclusions to be drawn about the blood flow in living muscles. These methods of investigation are qualitative not quantitative.

15.2 Discussion on Dissection Findings Related to Blood Supply

15.2.i Quality of Injection Results

In general, the fetal specimens gave superior results. Several factors probably contributed to this. Because of their size, only a very small volume of medium was required to outline the arterial tree, and as they were injected fresh it was unlikely thrombi had formed within the vessels. Also, the injection was always given into the common carotid artery, close to the target site, whereas although some of the adult cadavers had carotid injections, others were only given into the femoral artery. (The cadavers had been used initially for general dissection studies.) Finally, the use of the dissection microscope with microsurgical instruments allowed very detailed dissection in a way not possible with the much larger adult heads.

The best injection mass for fetal specimens was found to be Schlesinger's medium. The method was simple and predictably good results were achieved, with very little medium reaching the venous circulation. During dissection the vessels containing medium were easily torn, however, and the material lacked the elasticity of latex.

Neoprene latex containing Indian ink was another mass used in adult cadavers to good effect. Its toughness due to its rubber content aided dissection and the black colour stood out surprisingly clearly against the tissues. The Indian ink also gave excellent contrast in cleared specimens. On the negative side, a considerable amount reached the venous side of the circulation and this potentially confused interpretation of results. Latex containing coloured dyes was satisfactory for general dissection purposes, but was unsuitable for clearing due to loss of colour following immersion in methyl salicylate.

Microfil gave rather disappointing results and is not recommended by the author. As it filled all vessels, arterial, capillary and venous, the dissections tended to be obscured by too much medium. Cost also precludes it from large volume use. An advantage of this material was its ability to outline capillary beds in a way not seen with the other media.

15.2.ii Palatal Blood Supply

The 44 dissections on facial halves with normal palates has allowed the detailed blood supply to the soft palate and individual palatal muscles to be described in detail for the first time. A fairly consistent pattern emerged with only three arteries playing a significant role: the ascending palatine, ascending pharyngeal, and accessory meningeal arteries. The observations and variations were similar in both fetal and adult specimens. An interesting detailed difference in the ascending palatine artery between adult and fetal specimens was noted. In the adult specimens the artery was very noticeably tortuous. The reason why this develops is not clear. It may simply be related to mandibular movement. Jaw opening will result in increasing the distance between the origin of the ascending palatine from the facial artery and the palate. Tortuosity could be the way in which allowance is made for this. The other two arteries did not show this phenomenon, perhaps because the distance between origin and destination does not alter in their cases.

It was clear that the levator and tensor veli palatini muscles had a dual arterial supply in most instances. Equally, however, in a small minority of cases these muscles gained supply from only one artery. The ascending palatine occasionally failed to reach the palate, even in well-injected specimens. In these cases the ascending pharyngeal, for the levator, and the accessory meningeal for the tensor, take over its distribution. Last century Cunningham (1896) described the palatine branch of the ascending pharyngeal artery as of variable size, varying inversely with the ascending palatine vessel.

It was not usually possible to decide the relative importance of each artery in cases where a dual supply was observed for the tensor and levator. Size and number of vessels entering the muscle can give some indication, but as the feeding branches were very small this was only considered a rough guide. The most prevalent pattern was of two vascular pedicles entering from different regional arteries, corresponding to a Type III vascular anatomy according to the classification of Mathes and Nahai (1981). Similarly, the few cases where a single nutrient artery gave multiple pedicles of similar size segmentally correspond to the Type II pattern.

The palatopharyngeus and palatoglossus were found to have a segmental supply from whatever artery entered the velum close to the hamulus (normally ascending palatine) in their anterior portions, and from branches of the lingual, facial and ascending pharyngeal vessels in their posterior or inferior portions in the region of the palatopharyngeal arches. These muscles have a very rich supply as a result. The musculus uvulae appeared to receive its main supply from a vessel, usually ascending palatine, reaching the midline after passing through or around the levator. Other tiny vessels reached this muscle through the palatopharyngeal arches, as also noted by Girgis (1966).

15.2.iii Blood Supply in Cleft Palate Cases

The three cases dissected in this group showed a similar pattern to normal cases. Again the levator and tensor most commonly received extrapalatal supply from two sources.

The only different finding of any note in this group was the contribution to the supply of one levator by an accessory meningeal artery. It is not possible to comment on the significance of this in a single case, and probably only represents the finding that where an artery is weak or absent its distribution is taken over by an adjacent vessel.

Two levator muscles were found to have only a single arterial supply. This is believed to be a valid finding in well injected fetuses. Its importance will be elaborated on later.

15.2.iv Comment on Posterior Pharyngeal Wall Dissections

The ascending pharyngeal artery was observed to be the most important vessel feeding the posterior wall. Occasional cases revealed that accessory ascending pharyngeal arteries are sometimes present.

It was noticeable that the arrangement of the arteries and veins on the superior portion of the posterior wall differed from that lower down where the pharynx narrowed into the oesophagus. The vessels running on to the posterior surface of the oesophagus were seen to have a segmental distribution with arteries accompanied by veins. Higher up on the nasopharyngeal and oropharyngeal wall the network of vessels formed a much more irregular pattern. Arterial anastomoses crossing the midline also were not necessarily symmetrical, with for example a branch of the ascending pharyngeal on one side anastomosing with a superior thyroid branch on the other.

The pattern of vessels therefore on the area of the posterior wall utilised for pharyngeal flaps was that of a network of communicating arterial branches, and a system of veins where there were both midline and lateral concentrations of drainage channels.

15.3 Discussion on Anatomical Findings

15.3.i Muscle Anatomy

Several authors have reported insertion of the tensor veli palatini into the maxillary tuberosity (Ruding, 1964; Ross,1971; Latham et al,1980) as noted in a number of the present dissections of normal palates. Ross (1971) and Fára and Dvorák (1970) also demonstrated that this muscle can insert into the hamulus. Ross (1971) and Rood (1973) described its division into two components, a medial component accounting for about 75% of the muscle arising from the cartilaginous and / or membranous lateral wall of the auditory tube, and a lateral one arising from the scaphoid fossa and spine of the sphenoid. A portion of this second component frequently inserted into the maxillary tuberosity and the lateral surface of the medial pterygoid plate. A hamular insertion was not described by Rood(1973) or Deuschle et al (1960) and this is consistent with the present observations, with the exception of a single muscle in a fetus with a cleft palate.

In the cleft cases the presence of an aponeurosis has been confirmed in each specimen studied. This concurs with the histological findings of Maue-Dickson (1980). The aponeurosis was less extensive than in normal cases, an observation previously made by Ruding (1964) and Fára and Dvorák (1970).

There were three significant observations regarding the levator insertion in the cleft cases:

1. Anterior fibres inserted into the tensor tendon just medial to the hamulus.
2. The bulk of the fibres inserted into the soft palate along the medial edge and posteriorly towards the hemi-uvula.
3. Only a small portion of the muscle inserted into the posterior edge of the hard palate.

The amount of muscle inserting into each of these areas varied between specimens and from side to side in each individual specimen.

There have been few descriptions of the detailed anatomy of the muscle insertions within the velum in cleft cases. Kriens (1969;1970), in his article describing his dissection of a single cleft, shows drawings of the insertion of the levator into the posterior edge of the hard palate. There is no mention in the text of any insertion into the cleft margin within

the soft palate, although another line drawing appears to show this. Latham et al (1980) reconstructed the cleft of the secondary palate in a five month infant using serial Plexiglas tracings. They concluded that fibres of levator, palatopharyngeus and musculus uvulae came together to insert into the posterior nasal hemispine and bony cleft margin. Fára and Dvorák (1970) reporting on 18 cases of mature stillborn children with a range of cleft types made different observations on the levator insertion. In most of their dissections the posterior bundles of the levator entered the posterior palatopharyngeal arch near the base of the uvula, and joined up with palatopharyngeus fibres. Medial levator fibres passed into the margin of the cleft. Anterior fibres either inserted along the cleft margin of the palatine plate, inserted into a tendinous area lateral to the posterior nasal hemi-spine, or linked up directly with the tensor tendon. The findings of the present dissections agree very closely with those of Fára and Dvorák, as opposed to those of Kriens (1969;1970) and Latham et al.(1980).

It is interesting also to note that Fára and Dvorák stated that in the less serious forms of cleft some anterior bundles of levator advanced for some millimeters along the cleft bony margin. Ruding (1964) makes a similar observation in his article, stating that the insertion of the levator into the aponeurosis extends together with the aponeurosis very close to the most anterior portion of the cleft. In the dissection of the cleft of the secondary palate carried out in the present studies some levator fibres were found to run almost parallel to the aponeurosis reaching as far forward as the nasal side of the hard palate shelf at the cleft margin.

The palatopharyngeus insertions in the cleft cases are again in agreement with the observations made by Fára and Dvorák (1970). Fibres were seen to insert into both the posterior edge of the palatal shelf and into the cleft velar margin and oral mucosa. The fact that the bulk of the fibres dissected off the posterior edge of the hard palate were from palatopharyngeus will be referred to again.

The observations on musculus uvulae are scanty. However, it is clear that this muscle does differentiate in at least some cases of cleft palate. Fára and Dvorák (1970) reported on the great difficulty in isolating the fibres of this muscle. Latham et al (1977) reported on its presence in two infants with cleft palate. Hypoplasia noted in both palatopharyngeus and levator muscles in the present studies is clearly very likely in the

case of musculus uvulae, as is its absence in some cases.

15.3.ii Nerve Supply

The tensor veli palatini apart, there is still controversy regarding the precise nerve supply to the palatal muscles. The pharyngeal plexus which gives supply is made up of contributions from glossopharyngeal, vagus and accessory nerves. There is evidence that it is the bulbar portion of the accessory nerve that supplies motor innervation through the pharyngeal branch of the vagus and the glossopharyngeal which supplies sensory innervation (Dickson,1975). The findings described demonstrated innervation of the levator via the glossopharyngeal nerve. The course of the fibres is similar to that shown in a drawing by Broomhead (1951) who, however, concluded that they arose from the pharyngeal branch of the vagus. Domenech-Ratto (1977) found in a study of the innervation of the palatal muscles of ten human embryos and fetuses that nerve fibres to levator and palatopharyngeus come from both the glossopharyngeal and vagus nerves.

Ibuki et al. (1978) studying levator innervation in rhesus monkeys concluded on the other hand that fibres from the facial nerve reach this muscle through the greater petrosal nerve. More recently, Keller et al. (1984) located levator motoneurons in the nucleus ambiguus of the brainstem. Both the glossopharyngeal and vagus nerves contain efferent fibres arising from this nucleus. The same workers found that tensor innervation was clear, enzyme being present within the nucleus of the trigeminal nerve. This is consistent with the present observation.

Nerve fibres in three dissections in the present studies were found to reach the lateral aspect of the lateral portion of the levator. If these are motor fibres (the precise origin is of little consequence to the surgeon) then their location would mean they are relatively immune to surgical damage. As a result, denervation of the muscle should be extremely unlikely during cleft palate repair. This finding, however, should be interpreted with caution in view of the very small number of cases where nerve fibres were seen.

15.4 Discussion on Histochemical Findings

Histochemical examination of the velar muscles, including identification of fibre types, has not previously been reported to the author's knowledge. The intramuscular vascular pattern of the levator muscle as shown by histochemical staining was consistent with that seen on microdissection of the fetal specimens. Dissection had revealed that a branch of the ascending palatine artery could pass into and along the medial portion of the muscle as it turned towards the midline. The branches of the ascending pharyngeal artery entering the upper, lateral part of the muscle were small seen on dissection and this was in keeping with the lack of any "large" vessel demonstrated histochemically in the lateral portion.

Type I muscle fibres are slow-twitch oxidative fibres resistant to fatigue whereas type IIb fibres have short twitch durations and are glycolytic (Vander et al, 1980). In a histochemical study of the human cricopharyngeus muscle the large majority were found to be type I fibres (Bonington et al, 1988). It was felt by the authors this reflected its function in providing tone over long periods as part of the oesophageal sphincter. The much larger proportion of type IIb fibres found in the three palatal muscles examined in this study appears to reflect the more rapid movements the soft palate has to perform during speech. The type I fibres, it is interesting to speculate, are more concerned with the slower more sustained contraction seen on swallowing.

It is noteworthy that the levator contained the highest proportion of fast twitch fibres, perhaps emphasizing its cardinal role in velopharyngeal movement related to speech.

15.5 Surgical Implications of Soft Palate Dissections

15.5.i Oral mucosa

The soft palate has been shown in this thesis to have a very rich blood supply. Broomhead (1951) remarked that he felt that the blood supply to the velum is not endangered in cleft palate closure. He noted that even if the lesser palatine vessels are divided or damaged in raising mucoperiosteal flaps based on the greater palatine vessels, supply from the ascending palatine, ascending pharyngeal and tonsillar branches are left intact. It must be rare to see sloughing of a significant portion of the soft palate following palate repair and the author of this thesis has not seen such a case.

What is occasionally seen following cleft palate closure is a little sloughing of the oral mucosa at the midline suture line, typically at the junction of the hard and soft palate. This may be due to excessive tension in drawing the cleft edges together, but may also result from elevating mucosal flaps on the oral side with insufficient submucosa attached. As a consequence of this the submucosal plexus of vessels that has been demonstrated in the present studies is left behind and the mucosal edge becomes ischaemic. This mechanism could account for some small midline fistulas that arise after cleft palate repair.

A similar mechanism may be responsible for the loss of mucosa occasionally seen at or near the cleft edge after "cleft muscle" fibres that insert into the oral mucosa have been dissected off during intravelar veloplasty. In cutting these fibres free the overlying mucosa can become devascularised.

15.5.ii Palatal muscles

The dissections carried out for this thesis have most relevance to the palatal musculature and the effect that various surgical manoeuvres used during cleft palate closure may have on their blood supply.

A consistent finding was that the main arterial supply to the intrapalatal portion of the levator veli palatini (and the anterior portion of palatopharyngeus) enters the soft palate very close to the pterygoid hamulus. Situated just posterior to this bony landmark the artery, whether a branch of the ascending palatine, ascending pharyngeal or, in one case, of the accessory meningeal artery, is at risk of damage if a deep lateral dissection is undertaken during palate closure. Venae comitantes running with the artery similarly could be damaged.

Lateral dissection is described in the literature to facilitate cleft palate repair (Braithwaite, 1964; Braithwaite & Maurice, 1968; Trier, 1985b). However, these authors do not discuss the possibility of damaging the blood supply to the muscles as a result of this dissection. Sudden haemorrhage is sometimes encountered at this point, but the surgeon has previously not known what vessel(s) he has damaged. Veau in his book of 1931 refers to this when he remarks, on discussing the ascending palatine artery, "on ne la voit pas quand on opère. Je ne la connais pas." It is the author's opinion that where a deep lateral dissection is combined with an extensive intravelar veloplasty there is a possibility that ischaemic damage to the intrapalatal portion of the levator muscles could result. This hypothesis will be discussed further in this chapter.

It is apparent from the pterygoid plate measurements obtained that the course of the levator and tensor muscles must alter with skull growth. Dickson (1975) reports that in the fetus the levator is approximately horizontal, whereas in the adult it assumes an angle of 45°. Although in the adult the vertical distance between the palate and skull base was found to be in the order of 20mm, in an infant or young child this distance was only about 10mm. (Appendix 7). Seif and Dellon (1978) showed by measurements of four adult and three fetal skulls that the levator's origin moves laterally and its insertion moves downwards with growth. Downward movement occurs because during infancy and childhood bone deposition occurs on the inferior surface of the palate, and is accompanied by resorption from its superior surface (Sperber, 1989). This remodelling results in the descent of the palate.

It has been demonstrated that the levator muscle had a dual arterial supply in most cases. The entry points of one source of supply to the levator via a branch of the ascending pharyngeal are situated close to the skull base near the muscle origin and, in the adult,

well lateral to the normal area of dissection. This would ensure relative safety for this source of supply from surgical damage. However, as in the infant's and young child's skull the distance between the oral surface of the palate and the skull base is significantly shorter, put differently this means that in a child undergoing cleft palate closure the origin of the levator is closer to the area where a lateral dissection is made in cleft palate closure both in depth and in the coronal plane. For these reasons the blood supply entering the levator at the skull base is also potentially at some risk from damage if a deep lateral dissection is undertaken as, for example, described by other authors such as Wardill (1937), Broomhead (1951), Randall (1979), and Borchgrevink (1986).

The arterial supply to the tensor is normally from two arteries, the ascending palatine and the accessory meningeal. The former supply may be at risk of damage during lateral dissection as with that to the levator. The supply from the latter would appear to be at much less risk, as it enters the tensor near the skull base and is sandwiched between this muscle and the medial pterygoid. However, Broomhead (1951) in his description of cleft palate closure described blunt dissection through a lateral incision into the plane between these muscles, separating one from the other. He felt that the nerve supply to the tensor was at risk in this area, and by the same token if this were the case the vascular supply from the accessory meningeal would be also. It is not common practice, however, among surgeons at the present time to pursue dissection in this area.

As fresh tensor muscles were not obtained, no histochemistry observations were made regarding the intramuscular vascular pattern. Dissection findings suggest that the supply is segmental but that the accessory meningeal supply is more important in the majority of cases.

15.5.iii Implications of Vessel Distribution for Intravelar Veloplasty

In an extensive intravelar veloplasty where the levator muscles are dissected free from the hard palate, nasal, and oral mucosa almost as far laterally as the auditory tube (Boorman & Sommerlad, 1985a), the only way blood can reach the free end of the muscle bundles is through a vessel network within the bundles of fibres themselves. All other small

vessels around the intrapalatal part of the muscle capable of giving supply will have been divided during the dissection. If the intramuscular anastomoses are not adequate to nourish the terminal portion then this will become ischaemic. Survival of functioning muscle fibres as a graft is a possibility but, in view of palatal mobility and surrounding extravasation of blood, is unlikely. The high metabolic requirements of muscle fibres would also militate against their survival in this way, particularly the highly oxidative type I fibres (Kremzier, 1984).

The fetal and adult cadaver dissections have demonstrated that in some cases a branch of the main artery entering the soft palate, usually the ascending palatine artery, passes through the intrapalatal portion of the levator as it turns medially and posteriorly towards the uvula. This branch as has been illustrated supplies the muscle fibres via smaller branches as it passes through. This supply would appear to be sufficient to nourish the medial part of the muscle following an intravelar veloplasty where this vessel had been preserved. In the event of this vessel passing on the nasal side of the levator then when the muscle is dissected off the hard palate, nasal and oral mucosa, and dissected laterally, this will result in the branch of the ascending palatine artery being left behind on the nasal side. In these instances the only remaining supply to the whole muscle would come from the small branches entering at the skull base.

The histochemical findings illustrate that there was no significant arterial vessel running axially through the levator from the skull base. The intramuscular vascular pattern of the lateral portion of the muscle was uniform with only small vessels being noted.

Palatal dissections revealed the levator as having a segmental supply with a number of small pedicles entering usually from two feeding arteries. In the specimens where the muscle had only a single nutrient vessel there were still a number of pedicles entering it from this artery along its length. To recall, Fig.102 illustrates diagrammatically the various findings.

In muscles with a segmental supply (sartorius is an example of such a limb muscle) the amount of muscle which each pedicle can sustain if adjacent ones are damaged will depend on the extent of the intramuscular anastomoses. These are usually poorly developed in this type of muscle (Cormack & Lamberty, 1986). Again taking sartorius

as an example, if, during transposition of this muscle to cover the femoral vessels following a groin dissection, the upper two or three pedicles are divided, the upper end of the muscle will become noticeably dusky from ischaemia. The intramuscular anastomotic network is not sufficient for the lower pedicles to perfuse the adjacent vascular territories adequately. A further example can sometimes be seen during a functional neck dissection. The sternomastoid muscle can become ischaemic in places when one or more of the segmentally arranged vascular pedicles are divided.

Early work on intramuscular vascular anastomoses by Le Gros Clark and Blomfield (1945) and Blomfield (1945) had indicated the relative vulnerability of different limb muscles to necrosis following trauma. They recognised variability between muscles in site of entry and number of nutrient vessels and of the intramuscular vascular pattern, together with what was described as the efficiency of intramuscular anastomoses. Blomfield also realised that the relationship of muscle volume to the size of feeding vessels and anastomoses was also important in determining susceptibility to necrosis following injury. Edwards (1953) on describing muscle blood supply commented "an intramuscular network of anastomoses between branches of arteries does exist but it is often of a pattern which makes ischaemia probable after occlusion." Allowing for the fact that the levator veli palatini muscle is very much smaller than limb muscles, the vessels which supply it are correspondingly smaller. For this reason the hypothesis that damage to the blood supply of a portion of the levator may lead to ischaemic changes or necrosis does require to be explored.

Thus, if the dissected medial portion of levator does not contain a terminal branch of the ascending palatine artery or its equivalent, or if a lateral dissection has resulted in its being damaged, then the intrapalatal part of this muscle could undergo ischaemic fibrosis. Reduced mobility of the soft palate may follow. Ruding (1964) on the basis of anatomical dissections and without investigating blood vessel pathways similarly concluded that an extensive dissection in the region of the posterior rim of the medial pterygoid plate could result in scarring and fibrosis within the levator muscles. Boorman & Sommerlad (1985b) have also suggested small midline gaps in the soft palate seen nasendoscopically could be the result of palatal muscle atrophy from ischaemia due to surgery.

In summary, the findings from the present studies indicate that ischaemic changes within the medial part of the muscle would depend on the extent of dissection and on the precise distribution and course of the vessels to this area.

15.5.iv Implications of Anatomical Findings on Levator Insertions in Cleft Palate Cases for Intravelar Veloplasty

Following on the early reports proposing levator displacement on anatomical grounds (Veau, 1931; Ruding, 1964; Braithwaite & Maurice, 1968; Kriens, 1970) the procedure was taken up enthusiastically by others (Edgerton & Dellon, 1971; Kaplan, 1975b). The regularly quoted report by Kriens (1970) was based on a single dissection of a fetus with cleft palate. Kriens in turn discussed the previous work of Veau (1931). Victor Veau popularised the term cleft muscle referring to the intermingled anterior portions of the levator and palatopharyngeus which he found attached to the back of the cleft hard palate.

As a result of this, illustrations which appear in the literature (Kriens; 1970; Millard, 1980a; see Figs. 103a,b; 104a,b) often portray the levator muscle inserting solely into the back of the hard palate and bony cleft edge. This is an oversimplification as has been shown in the present work. It is misleading when deciding how extensive muscle dissection should be to restore normal muscle anatomy during cleft palate closure.

It is quite clear from the findings of Fára and Dvorák (1970) that the levator has a much more widespread insertion than is commonly thought. They reported that muscle fibres insert into the uvula and the free margin of the cleft, as well as the palatal shelves. Mina (1979) similarly identified levator fibres in an adult cadaver with an unrepaired cleft palate passing as far back as the free posterior edge of the soft hemi-palate near the hemi-uvula and merging with fibres of palatopharyngeus.

The present findings also revealed a complicated insertion for the levator. A significant portion inserted into the cleft soft palate edge with palatopharyngeus fibres. Perhaps most strikingly some anterior bundles were identified inserting into the tensor tendon by rounding the hamulus. This portion of the muscle could not easily be reached during an intravelar veloplasty carried out through a normal medial to lateral approach. Any attempt

to release these fibres through a lateral incision could damage the blood supply to the medial portion of the levator as already discussed, or could result in division of medially running fibres.

The observations made indicate a pattern of insertion of the levator as illustrated in Fig.88. However, as shown by these few cleft dissections, cleft palate cases can show a spectrum of appearances. Controversy about intravelar veloplasty wrongly presupposes that the anatomical abnormality has been fully documented for each type of cleft. As pointed out by Dingman and Argenta (1985) there is great variation seen at operation in the size and distortion of the palatal muscles. The first question to be answered is not how much of an intravelar veloplasty is required, but the extent of the abnormality. The procedure undertaken should perhaps differ according to the type of cleft present. Allowing for this, on anatomical grounds the present findings indicate that extensive intravelar veloplasty as advocated by some is not necessary simply because much of the levator muscle is running in a normal direction.

There are two recent reports in the literature suggesting that the addition of intravelar veloplasty to cleft palate closure gives improved velopharyngeal competence (Brown et al,1983; Dreyer & Trier, 1984). However, both these studies were retrospective. In the former paper 85 children who had primary palatoplasty aged between 6 to 18 months were evaluated at least two years after operation. Forty patients had palatal repair without levator reconstruction and the remaining 45 had an intravelar veloplasty. A higher percentage of patients who had an intravelar veloplasty had "normal speech" but the difference was not statistically significant. This study has been criticised for not explaining how the children who had intravelar veloplasty were selected, and for subdividing the two groups further by having some undergo a pushback (lengthening of the palate) if deemed clinically appropriate, based on palatal length and degree of clefting. Curtin and Dorf (1983) also criticised the speech evaluation carried out.

Dryer and Trier (1984) examined 80 children who underwent palatal repair. In those that had an intravelar veloplasty, only 9% subsequently required a pharyngeal flap, against 38% of those that had no levator retrodisplacement. Pressure flow studies were also reported indicating that intravelar veloplasty improved velopharyngeal closure. In this paper the difference between the two groups achieved statistical significance. The

authors, however, used historical controls.

In the only prospective study reported, Marsh et al (1989) examined 75 patients operated on by two surgeons. There was an equal distribution of cleft types between those undergoing a standardised intravelar veloplasty at the time of palate closure and those not. The mean age of palate repair in each group was approximately the same (14-15 months). Following speech and language evaluation at age 3, the distribution of velopharyngeal symptoms across the two groups was not significantly different. These authors concluded that their findings suggested either that intravelar veloplasty had no beneficial effect regarding velopharyngeal competence or that the effect, if present, was small.

It is clear reading the literature that some surgeons carry out a more radical intravelar veloplasty than others. For example, the procedures described by Edgerton and Dellon (1971) and by Boorman and Sommerlad (1985a) are more extensive than that of Marsh et al (1989). In the technique described by the last author, the significant insertion of the levator into the tensor tendon in the region of the pterygoid hamulus cannot have been divided, possibly limiting the retrodisplacement of the muscle achieved. This lack of uniformity in the procedure that is carried out is a further factor that makes comparisons between intravelar veloplasty versus no intravelar veloplasty difficult to interpret.

No paper has shown that a radical intravelar veloplasty gives poorer results, because of levator muscle necrosis resulting from the dissection, compared with no intravelar veloplasty. The author of this thesis accepts that some arguments put forward have not been and perhaps cannot easily be confirmed clinically. A suitable study would be difficult to mount. It is obviously not possible to submit children to palatal muscle biopsies following cleft palate closure unless re-exploration is indicated on clinical grounds. Having stated this, it is clear that in spite of its almost universal popularity over the last twenty years, the value of intravelar veloplasty remains to be proved.

15.6

Surgical Implications of Posterior Pharyngeal Wall Dissections for Pharyngoplasty

The results of the pharyngeal wall dissections have indicated the relative safety of various pharyngoplasty procedures from the vascular standpoint. Pharyngoplasties described by Hynes (1950), Moore (1960), and Orticochea (1968), in using tissue from the lateral pharyngeal wall and posterior palatopharyngeal arch superiorly based, appear to have a very adequate vascular supply. Vessels from both the facial and ascending pharyngeal systems give branches to this area. The problem most often seen with these flaps is not necrosis but dehiscence. From these studies it can be said that this is unlikely to be related to ischaemia. Tension on the flaps, muscular contraction and inadequate inseting are likely to be the important considerations.

Laterally based flaps will also have a rich blood supply. These flaps were first introduced in an attempt to preserve innervation and thus contractility in the superior constrictor fibres raised in a flap. McCoy and Zahorsky (1972) carried out dissections in five cadavers and showed that the branch of the vagus nerve supplying the superior and middle constrictor entered these muscles at about one to two centimetres above the level of the greater cornu of the hyoid bone. It seemed apparent to these authors that incisions for the conventional superiorly or inferiorly based flaps would sever this nerve supply. They then described a laterally based bipediced flap to circumvent this problem. Laterally based flaps, whether bipediced or bilateral, as described by Kapetansky (1973), carry the added advantage of preservation of more of their blood supply due to the general arrangement of arteries and veins on the posterior pharyngeal wall. Trier (1985a) has pointed out, however, that the size of flaps that can be raised in such a way is significantly smaller than those based superiorly or inferiorly.

Superiorly and inferiorly based pharyngeal flaps both have their advocates. It is normal to incorporate muscle in them, although Champion (1957) advised raising an inferiorly based one using only mucous membrane. Fára and Véle (1972) carried out electromyography on 154 patients who had had pharyngeal flaps performed from 10 days to 42 years previously. One hundred and eight patients had flaps based superiorly and 46

inferiorly. Histological studies were obtained from 8 flaps. Their findings showed that the inferiorly based flap preserved its muscle content to a greater extent, the superiorly based flap showing a greater degree of muscle atrophy and fibrosis. This could indicate better innervation and also less disturbance to the blood supply of the muscle fibres. On the other hand, they found that the superiorly based flap gave better clinical results. Whitaker et al (1972) showed no significant difference between the results achieved by the superiorly based and inferiorly based flap.

Inferiorly based flaps have been criticised for tethering the soft palate, preventing it lifting during speech, for being narrower than those superiorly based, due to the anatomical configuration of the pharynx, and for having to be taken down in the unusual event of significant postoperative bleeding (Trier, 1985a). Graham et al.(1973) also reported an increased incidence of partial and complete flap dehiscence with the inferiorly based flap.

The normal superiorly based flap is raised to about the lower border of the third cervical vertebra, but longer ones have been reported to survive. Holmström et al (1986) described a series of 11 patients where superiorly based flaps were raised down to the level of the cricoid cartilage or sixth cervical vertebra, using a pharyngotomy to reach the lower border. They claimed all survived as seen at nasendoscopy. They stated that the pharyngeal flap is an "arterial" flap because of the longitudinal arrangement of the vessels on the posterior pharyngeal wall. In Owsley's description (Owsley et al, 1966) of raising a superiorly based flap the dissection is carried as high toward the cranial base as possible. It is likely in these cases that the pedicle is at a level of the uppermost fibres of superior constrictor or even within the pharyngobasilar fascia.

The present findings have shown that the high superiorly based flap is normally not an arterial or axial pattern flap. It is consistently nourished by the uppermost pharyngeal branches of the ascending pharyngeal artery at the level of the pharyngobasilar fascia, but these branches only rarely run into or along the flap. Venous drainage is more precarious but appears to rely on high laterally draining veins that empty into the laterally based pharyngeal veins.

This work has also shown that whatever disadvantages the inferiorly based flap is

believed by some to have, its arterial input is potentially richer thanks to ascending pharyngeal and superior thyroid branches coming in from below. Venous outflow will also include the well developed midline vessels passing inferiorly. It is not evident from the literature, however, that this apparent anatomical advantage of the inferior flap makes any difference as regards viability in the clinical situation.

From the vascular standpoint there is no doubt from the dissections described that laterally based flaps enjoy the richest supply. Preserved innervation is an added advantage (McCoy and Zahorsky, 1972). For this reason they deserve more popularity than they have enjoyed up to the present time. By narrowing the pharynx they could be useful for obturating small lateral gaps recognised nasendoscopically or radiologically that do not require a large flap to achieve velopharyngeal closure.

Some comment should be made on the tortuous course of the internal carotid artery that was seen in one specimen dissected. This has potential clinical significance. MacKenzie-Stepner et al (1987) reported carotid artery abnormalities in three young children in whom pharyngeal flap surgery was planned for velopharyngeal incompetence. In two of these cases pulsatile vessels were identified in the posterior pharyngeal wall prior to surgery. Carotid arteriography showed tortuous internal carotid arteries displaced from their normal lateral position towards the midline. It is clearly important for surgeons to be alert to this possibility when they plan pharyngoplasties, not only when designing posterior wall flaps, but also those that include tissue from the palatopharyngeal arch area.

15.7 Proposals for Cleft Palate Closure

On the basis of the anatomical findings both on the vascular anatomy and of the cleft palate musculature a series of sequential steps is proposed for cleft palate closure. The surgical difficulty varies. Narrow clefts of the palate are technically easier to close than wide ones, and a cleft only involving the soft palate is a different problem from a

complete cleft of the primary and secondary palate. Dingman and Argenta (1985) have alluded to this by commenting that the extent of the cleft should play a part in the procedure chosen and on its timing.

Rather than having a number of steps that are always followed, it seems logical that cleft closure should only consist of those steps necessary to complete the operation adequately. It is the author's current practice to raise mucoperiosteal flaps from the hard palatal shelves. No consideration, for example, is given in the following description to the technique described by Perko (1974; 1979) where in closing the soft palate, two supraperiosteal flaps are raised in the posterior third of the hard palate. With regard to the present studies, the less the dissection required laterally in the soft palate the less chance there will be of interfering with the blood supply of the palatal muscles, particularly the levator.

The following sequence is therefore proposed for closure of clefts of the primary and / or secondary palate :

1. Incision of the cleft edges, with the emphasis placed on preserving most of the mucosa for nasal layer closure.
2. Raising mucoperiosteum from the hard palatal shelves by dissecting from medial to lateral; wide freeing up of the mucosa from the nasal surface of the shelves.
3. Careful blunt dissection of the tissue around the greater palatine vessels in order to tease these vessels out of the greater palatine foramina.
4. Sharp dissection of the abnormally inserted anterior fibres of the palatopharyngeus / levator complex from the posterior aspect of the hard palate, nasal and oral mucosa. Minimal retrodisplacement of these fibres.
5. Closure of the nasal mucosa of the hard and soft palate (a vomer flap may be used in addition), proceeding round to oral mucosa via the uvula. Proceed to approximate oral mucosa with exposed but undissected muscle layer as far anteriorly as possible without undue tension. Approximation of the two bundles of retrodisplaced fibres by separate

muscle suture or by incorporation of this into oral layer closure.

In narrow clefts involving the posterior part of the secondary palate only, completion of the closure may be achieved without further dissection.

6. If tension becomes evident, at the junction of the hard and soft palate, lateral relaxation incisions should be made beginning at the maxillary tuberosity and running anteriorly just medial to the alveolar ridges to a point a little in front of the apex of the cleft, or to the junction of the lateral and anterior curves of the alveolar arch in complete clefts. This converts the flaps into bipediced von Langenbeck flaps.

7. A further attempt should then be made to close the remainder of the oral mucosa.

8. If this is still difficult then, and only then, should a lateral dissection be made behind the maxillary tuberosity. Blunt dissection with an elevator may be required to elevate the mucoperiosteum off the medial pterygoid plate in very wide clefts, but this should be reserved as the last step in the sequence.

It should also be remembered that this last step in the dissection may damage the auditory tube, apart from the risk of damage to the levator and its blood supply. Ruding (1964) pointed out the close relationship between the superior arc of the medial pterygoid plate and the opening of the auditory tube.

Obviously, in many cleft palate closures most or all of the steps described above may have to be used. However, in the cases where some of the last steps are not required and lateral dissection is not necessary, the surgeon can be sure that the blood supply to the palatal muscles is not disturbed. The total absence of scarring in these lateral areas can only be beneficial as regards palatal movement and maxillary growth.

15.8 Description of Cleft Palate Closure

An example of cleft palate closure proceeding along the lines outlined above is shown in

Fig.105a-f. This 12 month old female infant had a moderately wide unilateral cleft of the secondary palate, and had previously undergone bilateral lip repair (right side microform, left side complete). Following marking, the edges of the cleft were incised (Fig. 105c). Stay sutures were placed to retract the oral mucosa, and mucoperiosteum was then raised from the oral surface of the hard palate by blunt dissection using a small elevator. Blunt dissection was also used to free the nasal mucosa from the nasal aspect of the palatal shelves. Sharp dissection of muscle fibres from the back of the hard palate is not illustrated (as the author has found it very difficult to show this clearly in clinical photographs).

The nasal mucosa was then closed using 4/0 simple interrupted Vicryl™ sutures, incorporating a vomerine mucosal flap anteriorly (Fig. 105d). Oral layer closure was carried out commencing at the uvula and it was possible to close most of the soft palate without tension (Fig. 105e). When this became evident, lateral releasing incisions were made over the hard palate and closure was completed using 3/0 interrupted Vicryl™ after minimal blunt dissection behind the left tuberosity (Fig. 105f). The space of Ernst (Ernst, 1925) was not disturbed. Retrodisplaced muscle was incorporated into the oral layer closure.

By doing the operation in steps as described, operating time is extended by about 15 minutes if the complete sequence is required, compared with an operation where standard Veau or von Langenbeck flaps are raised at the beginning of the procedure.

In considering the results of surgery, Grabb et al (1971) listed the following goals of cleft palate repair: preservation of hearing, normal dental occlusion and swallowing, the separation of oral and nasal cavities, and, most importantly, the provision of a mechanism for normal speech. The number of patients with unsatisfactory speech is not likely to be reduced dramatically due to extraneous factors, already listed at the beginning of this thesis, outwith the surgeon's control. The only way in which he can positively influence results is by improving surgical technique.

The history of cleft palate surgery reveals a continuing evolution of surgical technique which looks towards the restoration of normal anatomy and function. These goals have yet to be reached in that consistently good results are not always attained. Any new

methods and procedures introduced should originate from a sound understanding of the anatomy of both the normal palate and cleft palate defect. If this is not the case then in time it may be shown from clinical experience that adverse and harmful effects can result in the patients in whom they have been used. The present study detailing the surgical anatomy and blood supply of the velum and pharynx is aimed at improving our knowledge of this area. In this way progress in the treatment of cleft palate patients can continue to be based on accurate anatomical findings.

APPENDICES

Appendix 1

Fixed adult cadavers

<u>No.</u>	<u>Age at death</u>	<u>Sex</u>	<u>Cause of Death</u>
1	88yrs.	M	Cerebrovascular accident
2	82	F	Myocardial infarction
3	76	M	Bronchopneumonia
4	92	F	Cerebrovascular accident
5	93	F	Myocardial infarction
6	71	M	Myocardial infarction
7	77	M	Ischaemic heart disease.
8	60	M	Chronic obstructive airways disease
9	79	M	Congestive cardiac failure
10	92	F	Bronchopneumonia

Fresh adult palates

<u>No.</u>	<u>Age at death</u>	<u>Sex</u>	<u>Time elapsed before PM</u>	<u>Histochemistry / Injection Studies</u>
1	72 yrs.	M	11 hrs.	Histochemistry
2	77 yrs.	F	38 hrs.	Histochemistry
3	75 yrs.	F	45 hrs.	Histochemistry
4	72 yrs.	F	17 hrs.	Histochemistry
5	63 yrs.	F	18 hrs.	Histochemistry
6	80 yrs.	M	16 hrs.	Histochemistry
7	42 yrs.	F	22 hrs.	Injection Studies
8	53yrs.	M	53 hrs.	Injection Studies
9	68 yrs.	F	117 hrs.	Injection Studies
10	72 yrs.	M	36 hrs.	Injection Studies

Appendix 2

Fresh fetuses

<u>No./Sex</u>	<u>Sp/Th</u>	<u>Gestation</u>	<u>Wt</u>	<u>CR</u>	<u>Foot length</u>	<u>Remarks / Summary</u>
1F	Sp	24/25wks	572g	20cm	4.3cm	Normal fetus
2M	Sp	23/24	490g	19cm	3.9cm	Normal
3F	Th	21+ s.s	294g	17cm	3.2cm	Cleft palate Trisomy 13
4F	Th	20 s.s.	277g	15cm	3.1cm	Spina bifida Hydrocephalus
5M	Th	20 s.s.	318g	15cm	2.3cm	Spina bifida
6-	Sp	26	-	-	-	Normal
7M	Th	27 s.s.	760g	22cm	5.0cm	Spinabifida Hydrocephalus
8M	Sp	22/23 s.s.	478g	19cm	3.9cm	Normal
9F	Sp	24	645g	21cm	4.5cm	Normal
10F	Sp	23	748g	23cm	4.5cm	Normal
11M	Sp	26	717g	23cm	4.5cm	Normal
12M	Sp	26	650g	22cm	4.9cm	Normal
13F	Sp	27 s.s	811g	24cm	5.0cm	Normal
14F	Th	17+s.s	87g	10cm	2.4cm	Anencephaly R Cleft L & P. Spina bifida

15M	Th	25 s.s	592g	22cm	4.7cm	Median Cleft L & P Trisomy 13 Aplasia cutis Polydactyly VSD
16M	Sp	21	399g	18cm	3.2cm	Normal
17M	Sp	23	478g	20cm	3.8cm	Normal
18F	Th	20+	307g	17cm	3.1cm	Median Cleft L & P Trisomy 13 Alobar holoprosencephaly

Sp : spontaeous abortion
Th: therapeutic abortion
s.s.: skeletal survey estimate
CR: crown - rump length

Fixed Fetuses

<u>No./Sex</u>	<u>Sp/Th</u>	<u>Gestⁿ</u>	<u>Wt</u>	<u>C.R.</u>	<u>Foot</u>	<u>Remarks/Summary</u>
i M	Th	18wks	100g	9.5cm	2.2cm	Anencephaly
ii F	Th	16+	60g	8.5cm	1.9cm	Unilat.Cleft Lip & Cleft 1Y Palate, Anencephaly, Gastrochisis
iii F	Th	19	180g	9.0cm	3.0cm	Cleft 2Y Palate, Iniencephaly, Spina bifida, Exomphalos
iv F*	Th	20	245g	14cm	3.6cm	Cleft 2Y palate, Anencephaly

* serial sections available

Appendix 3

Preparation of injection media

Red /blue neoprene latex mixtures

When making a mixture, one part colour to 5 parts latex was used.

Indian ink / Neoprene latex mixture

A 10% solution of ink in latex was used.

Micropaque / Neoprene latex mixture

Equal parts of Micropaque and latex were mixed well to prevent precipitation of Micropaque.

Appendix 4

Tissue processing

- | | | |
|-----|---|--------------|
| 1. | Decalcify in RDO | 8 hrs. |
| 2. | Buffer overnight | |
| 3. | X-ray block to check decalcification | |
| 4. | Further decalcification in RDO if necessary | 4 hrs. |
| 5. | Histokinette. 70% alcohol | 2 hrs. |
| | 90% alcohol | 2 hrs. |
| | Absolute alcohol / celloidin | 3 changes |
| | | 1 hr. each |
| 6. | 4% celloidin in absolute alcohol | 24 - 48 hrs. |
| 7. | 8% celloidin in absolute alcohol | 24 - 48 hrs. |
| 8. | Histokinette. Amyl acetate | 3 changes |
| | | 3 hrs. each |
| | Wax | 2 changes |
| | | 4 hrs. each |
| 9. | Vacuum embed | 20 mins. |
| 10. | Change wax. Embed. | |

Appendix 5

Masson stain

1. Dewax xylene and hydrate
2. Wash in water
3. Stain in Weigert's Haematoxylin 30 mins.
4. Differentiate in 1% acid alcohol 30 secs. - 1min.
5. Blue in Scott's solution
6. Stain in 2% Ponceau Fuchsin 1.5 mins.
7. Wash quickly in water
8. Mordant in 1% phosphomolydic acid 2.5 - 3 mins.
9. Stain Light Green 3 mins.
10. Wash in water 2 changes
11. Dehydrate
12. Clear in xylene 5 mins.
13. Mount in Histomount

Haematoxylin & Eosin

1. Dewax xylene and hydrate
2. Absolute alcohol 2 changes 30 secs.
3. 90% alcohol 30 secs.
4. 70% alcohol 1-2 mins.
5. Wash in water 2 changes 1 min.
6. Mayer's Haematoxylin 5 mins.
7. Blue in Scott's solution
8. Wash in water
9. Eosin 30 secs.-1 min.
10. Wash in water 2 changes
11. Dehydrate
12. Clear in xylene 2 changes 3 mins.
13. Mount in Histomount

Appendix 6

Alkaline phosphatase (McGadey, 1970)

1. Fixed and frozen sections cut at 10 μ .
2. Sections incubated in 2.5mg 5-bromo-4-chloroindoxyl phosphate dissolved in 0.5ml dimethyl formamide /10ml 0.2 M veronal acetate buffer pH 9.5 / 5mg nitro B.T. for 10-20mins.
3. Wash in water.
4. Fix in 10% formal saline for 30mins.
5. Dehydrate and clear.
6. Mount in D.P.X.

Gomori's aldehyde fuchsin

1. Dewax sections and hydrate in water.
2. Oxidise in equal volumes of 0.3% KMnO₄ / 0.3% H₂SO₄ for 2mins.
3. Decolourise in 2% oxalic acid.
4. Stain in Gomori's aldehyde fuchsin for 15mins.
6. Wash in water.
7. Stain in Ponceau de Xylidine / acid fuchsin 3:1 for 5mins.
8. 2% phosphotungstic acid for 1min.
9. Wash, dehydrate and mount.

NADH₂ reductase

1. Frozen sections cut 10 μ .
2. Sections incubated in NADH₂ / nitroblue tetrazolium solution / phosphate buffer (pH 7.4) at 37⁰C for 30mins.
3. Transfer to 15% formal saline for 15mins.
4. Wash in distilled water.
5. Dehydrate through alcohols to xylene.
6. Mount in D.P.X.

Adenosine triphosphatase (pH 9.4)

1. Frozen sections cut 10 μ .
2. Sections incubated in veronal acetate buffer (pH 9.4) for 15mins. at room temp.
3. Sections incubated in ATP (disodium salt) for 45mins. at room temp.
4. Wash in three changes 1% calcium chloride for 10mins.
5. Wash in six changes 0.01M sodium barbitone.
6. Wash in water 30secs.
7. Place in 1% yellow ammonium sulphide for 30secs.
8. Wash in water.
9. Dehydrate through alcohols to xylene.
10. Mount.

(For pH 4.6 and 4.2, pre-incubate in veronal acetate buffer of appropriate pH for 5mins. at room temp.)

Appendix 7

Adult skulls

Pterygoid plate height (vertical height from scaphoid fossa-lowest point plate)

19,21mm	25,25	20,22	-,22	20,22
20,21	23,24	21,23	19,20	23,24
24,26	18,19	20,21	18,19	24,23
21,22	20,20	20,21	23,23	-,23
20,24	18,20	22,20	22,21	18,20
20,24	21, -	21,21	21,25	20,20
25,25				

n=31

Mean value: 21mm

Child skulls

Pterygoid plate height

<u>Age</u>	<u>Height</u>
Fetal (term)	4-5mm
6 months	9,9
3-4yrs.	16,15
7-8yrs	-,17
8-9yrs*	17,18
9-11yrs*	15,15
14-16yrs	21,19

*Probable sex difference to account for anomalous measurements.

BIBLIOGRAPHY

Anderson, H. & Mathiessen, M.E. (1967) Histochemistry of the early development of the human central face and nasal cavity with special reference to the movements and fusion of the palatine processes. Acta Anatomica, **68**, 473-508.

Azzam, N.A. & Kuehn, D.P. (1977) The morphology of musculus uvulae. Cleft Palate Journal, **14**, 79-87.

Bancroft, J.D. & Stevens, A. eds. (1982) Theory and Practice of Histological Techniques. 2nd Edition. Edinburgh: Churchill Livingstone.

Baumel, J.J. & Beard, D.Y. (1961) The accessory meningeal artery of man. Journal of Anatomy, **95**, 386-402.

Bell-Berti, F. (1976) An electromyographic study of velopharyngeal function in speech. Journal of Speech and Hearing Research, **19**, 225-240.

Berry, J. & Legg, T.P. (1912) Harelip and Cleft Palate. Ch.1, pp 1-17. Development of lips and palate. London: Churchill.

Bill, A.H., Moore, A.W., Coe, H.E. (1956) The time of choice for repair of cleft palate in relation to the type of surgical repair and its effect on bony growth of the face. Plastic and Reconstructive Surgery, **18**, 469-473.

Blomfield, L.B. (1945) Intramuscular vascular patterns in man. Proceedings of the Royal Society of Medicine, **38**, 617-618.

Bluestone, C. (1971) Eustachian tube obstruction in the infant with cleft palate. Annals of Otolaryngology, Rhinology and Laryngology, **80**, 1-28.

Bonington, A., Mahon, M. & Whitmore, I. (1988) A histological and histochemical study of the cricopharyngeus in man. Journal of Anatomy, **156**, 27-37.

Boorman, J.G. & Sommerlad, B.C. (1985a) Levator palati and palatal dimples: their anatomy, relationship and clinical significance. British Journal of Plastic Surgery, **38**, 326-332.

Boorman, J.G. & Sommerlad, B.C. (1985b) Musculus uvulae and levator palati: their anatomical and functional relationship in velopharyngeal closure. British Journal of Plastic Surgery, **38**, 333-338.

Borchgrevink, H.H.C. (1986) In Plastic and Reconstructive Surgery, ed. Muir, I.F.K. Ch.4 , Cleft palate repair, pp. 64-91. London: Baillière Tindall.

Braithwaite, F. (1964) In "Modern Trends in Plastic Surgery" ed. Gibson, T. Chap. 2, Section 2, pp 30-49. London: Butterworths.

Braithwaite, F.& Maurice,D.G. (1968) The importance of the levator palati muscle in cleft palate closure. British Journal of Plastic Surgery, **21**,60-62.

Broomhead, I.W. (1951) The nerve supply of the muscles of the soft palate. British Journal of Plastic Surgery, **4**,1-15.

Brophy, T.W. (1927) Cleft lip and cleft palate. Journal of the American Dental Association, **14**, 1108- 1115.

Brown, A.S., Cohen, M.A. & Randall, P. (1983). Levator muscle reconstruction: does it make a difference? Plastic and Reconstructive Surgery, **72**,1-6.

Burdi, A. & Faist, K. (1967) Morphogenesis of the palate in normal human embryos with special emphasis on the mechanisms involved. American Journal of Anatomy, **120**, 149-159.

Burdi, A., Feingold,M., Larsson,K.S., Leck,I., Zimmerman, E.F. & Frasar, F.C. (1972). Etiology and pathogenesis of congenital cleft lip and cleft palate, an NIDR state of the art report. Teratology, **6**, 255-268.

Burke,G.W., Feagans W.M., Elzay,R.P. & Schwartz,L.D. (1966) Some aspects of the origin and fate of midpalatal cysts in human fetuses. Journal of Dental Research, **45**,159-164.

Cadenat,H. (1974) La vascularisation du maxillaire supérieur. Revue de Stomatologie et de Chirurgie Maxillo-Faciale (Paris),**75**,139-141.

Calnan, J.S. (1954a) The error of Gustav Passavant. Plastic and Reconstructive Surgery, 13, 275-289.

Calnan, J.S. (1954b) Submucous cleft palate. British Journal of Plastic Surgery, 6,264-282.

Calnan,J.S. (1957) Modern views on Passavant's ridge. British Journal of Plastic Surgery,10,89-113.

Champion, R. (1957) Some observations on the primary and secondary repair of the cleft palate. British Journal of Plastic Surgery, 9,260-264.

Clemente,C.D. (1987) Anatomy. A Regional Atlas of the Human Body. 3rd edition. Baltimore-Munich: Urban & Schwarzenberg.

Clodius, L. (1972) Translation of article by Billroth,T. (1889) On uranoplasty. Wiener Klinische Wochenschrift, 2, 241. Plastic and Reconstructive Surgery,50, 71-74.

Combelles, R. (1972) Vascularisation de la cavité buccale. Archives d'Anatomie, d'Histologie et d'Embryologie, 55,179-208.

Combelles, R., Becue, G., Bastide, G. & Juskiewenski, S. (1974) Vascularisation arterielle des maxillaires. Bulletin de l' Association des Anatomistes (Nancy),58,85-94.

Cormack,G.C. & Lamberty,B.G.H. (1986) The Arterial Anatomy of Skin Flaps. Edinburgh: Churchill Livingstone.

Cosman, B. & Falk, A.S. (1980) Delayed hard palate repair and speech deficiencies: A cautionary report. Cleft Palate Journal,17, 27-33.

Croft, C.B., Shprintzen, R.J., Daniller, A. & Lewin, M.L. (1978) The occult submucous cleft palate. Cleft Palate Journal, 15,150-154.

Curtin, J.W. & Dorf, D.S. (1983) Discussion of paper by Brown et al. Plastic and Reconstructive Surgery, 72,7-8.

Cunningham,D.J. (1896) Manual of Practical Anatomy, 2nd Edition,Vol.ii. Edinburgh: Young J. Pentland.

Desai, S.N. (1983) Early cleft palate repair completed before the age of 16 weeks: observations on a personal series of 100 children. British Journal of Plastic Surgery, **36**,300-304.

Deuschle, F, de Stephano,G ,Longacre J & Holinstrand K.(1960) Soft palate musculature: an anatomic study of full-term fetuses using a stereoscopic dissection microscope. Cleft Palate Bulletin,**10**,60-61.

Dickson, D.R. (1972) Normal and Cleft Palate Anatomy. Cleft Palate Journal, **9**,280-293.

Dickson, D.R. (1975) Anatomy of the Normal Velopharyngeal Mechanism. Clinics in Plastic Surgery, **2**, 235-248.

Diewert,V.M. (1976) Effects of three teratogens on development of arteries in the secondary palate in rats. Teratology,**13**,113-130.

Diewert,V.M. (1980) Differential changes in cartilage cell proliferation and cell density in the rat craniofacial complex during secondary palate development. Anatomical Record, **198**, 219-228.

Diewert, V.M. (1986). Craniofacial growth during human secondary palate formation and potential relevance of experimental cleft palate observations. Journal of Craniofacial Genetics and Developmental Biology Supplement, **2**, 267-276.

Dingman, R.O. & Argenta, L.C. (1985) In Clinics in Plastic Surgery. Cleft Lip and Palate. ed. Trier,W.C. Ch. The correction of cleft palate with primary veloplasty and delayed repair of the hard palate, Vol. **12**, pp 677-684.

Dingman, R.O. & Grabb,W.C. (1971) A rational program for surgical management of bilateral cleft lip and cleft palate. Plastic and Reconstructive Surgery,**47**,239-242.

Doménech-Ratto,G. (1977) Development and peripheral innervation of the palatal

muscles. Acta Anatomica,97,4-14.

Dorrance, G. M. (1925) Lengthening the soft palate in cleft palate operations. Reprinted in Plastic and Reconstructive Surgery (1972), 50,275-279. Original article in Annals of Surgery, 82,208.

Dorrance,G.M. (1933) The Operative Story of Cleft Palate. Philadelphia: Saunders.

Dreyer,T.M. & Trier,W.C. (1984) A comparison of palatoplasty techniques. Cleft Palate Journal,21,251-253.

Dronamraju, K.R. (1986) Cleft Lip and Palate. Aspects of Reproductive Biology. Springfield: Thomas.

Edgerton, M.T. & Dellon, A.L. (1971) Surgical retrodisplacement of the levator veli palatini muscle. Plastic and Reconstructive Surgery,47,154-167.

Edwards, E.A. (1953) The anatomic basis for ischaemia localised to certain muscles of the lower limb. Surgery,Gynaecology and Obstetrics, 97, 87-94.

Edwards, M. (1980) In Advances in the Management of Cleft Palate, ed. Watson, A.C.H. & Edwards M., ch.8, pp. 83-96. Edinburgh: Churchill Livingstone.

Ernst, F. (1925) Zur Frage der Gaumenplastik. Zentralblatt für Chirurgie, 52, 464-470.

Evans, D. & Renfrew,C. (1974) The timing of primary cleft palate repair. Scandinavian Journal of Plastic and Reconstructive Surgery, 8,153-155.

Fára, M. & Brousilova, M. (1969) Experiences with early closure of velum and later closure of hard palate. Plastic and Reconstructive Surgery, 44,134-141.

Fára, M.& Dvorák, J. (1970) Abnormal Anatomy of the Muscles of Palatopharyngeal Closure in Cleft Palates. Plastic and Reconstructive Surgery,46,488-497.

Fára, M. (1971) Congenital defects in the hard palate. Plastic and Reconstructive

Surgery,**48**,44-47.

Fára, M. & Véle, F. (1972) The histology and electromyography of primary pharyngeal flaps. Cleft Palate Journal,**9**,64-72.

Fergusson, W. (1845) Observations on cleft palate and on staphyloraphy. Medico-Chirurgical Transactions, **28**,273-301.

Ferguson, M.W.J. (1981) The structure and development of the palate in alligator *Mississippiensis*. Archives of Oral Biology, **26**,427-443.

Ferguson, M.W.J. (1988) Palate Development. Development, **103** Supplement, 41-60.

Finkelstein, Y., Talmi, Y.P, Nachmani, M.A., Hauben, D.J. & Zohar, Y. (1990) Levator veli palatini muscle and Eustachian tube function. Plastic and Reconstructive Surgery, **85**,684-692.

Fitzgerald, M.J.T. (1978) Human Embryology. New York: Harper & Row.

Fogh-Anderson, P. (1942) Inheritance of harelip and cleft palate. Copenhagen: Busck.

Fogh-Andersen, P. (1980). In Advances in the Management of Cleft Palate, ed. Edwards, M. & Watson, A. C. H. Ch. 5, 43-48. Edinburgh: Churchill Livingstone.

Francis, W.W. (1971) Latin translation of article by Stephenson, J. (1820) De Velosynthesi. Plastic and Reconstructive Surgery, **47**, 277-282.

Fraser, F.C.(1970). The genetics of cleft lip and cleft palate. American Journal of Human Genetics, **22**, 336-352.

Frederiks, E. (1972) Vascular patterns in normal and cleft primary and secondary palate in human embryos. British Journal of Plastic Surgery, **25**, 207-223.

Freedlander, E. & Jackson, I.T. (1989) The fate of buccal mucosal flaps in primary palatal repair. Cleft Palate Journal, **26**, 110-112.

Friede, H., Moller, M., Lilja, J., Lauritzen, C. & Johanson, B. (1987) Facial morphology and occlusion at the stage of early mixed dentition in cleft lip and palate patients treated with delayed closure of the hard palate. Scandinavian Journal of Plastic and Reconstructive Surgery, **21**, 65-71.

Fritzell, B. (1969) The velopharyngeal muscles in speech: An electromyographic and cineradiographic study. Acta Otolaryngology, **250** (Suppl.): 1-81.

Furlow, L.T. (1986) Cleft palate repair by double opposing Z-plasty. Plastic and Reconstructive Surgery, **78**, 724-736.

Ganzer, H. (1920) Wolfsrachenplastik mit Ausnutzung des gesamten Schliemhautmaterials zur Vermeidung des Verkürzung des Gaumensegels. Berl. Klin. Wochenschr, **57**, 619.

Girgis, I.H. (1966) Blood supply of the uvula and its surgical importance. Journal of Laryngology and Otology, **80**, 397-402.

Gosling, J.A., Harris, P.F., Humpherson, J.R., Whitmore, I & Whillan, P.L.T. (1985) Atlas of Human Anatomy With Integrated Text. Edinburgh: Churchill Livingstone.

Grabb, W.C., Rosenstein, S.W. & Bzoch, K.K. (1971) Cleft Lip and Palate. Boston: Little Brown.

Graber, T.M. (1949) Craniofacial deformities in cleft palate and cleft lip deformities. Surgery, Gynaecology and Obstetrics, **88**, 359-369.

Graham, W.P., Hamilton, R., Randall, P, Winchester, R. & Stool, S. (1973). Complications following pharyngeal flap surgery. Cleft Palate Journal, **10**, 176-180.

Graves, F.O. & Edwards, L.E. (1944) The Eustachian Tube. Archives of Laryngology, **39**, 359.

Greene, R.M. & Pratt, R.M. (1976). Developmental Aspects of Secondary Palate Formation. Journal of Embryology and Experimental Morphology, **36**, 225-245.

Gregg, J.M., & Avery, J.K. (1971) Experimental studies of vascular development in normal and cleft palate mouse embryos. Cleft Palate Journal, **8**,101-118.

Hamilton, W.J., Boyd & Mossman (1972) Human Embryology, 4th Edition, London: MacMillan Press.

Hamilton, W. J. (1976). Textbook of Human Anatomy, 2nd Edition, London: MacMillan Press.

Hay,S. (1967). Incidence of clefts and maternal age. Cleft Palate Journal, **4**,205-213.

Holdsworth,W.G. (1954) Early treatment of cleft lip and cleft palate. British Medical Journal, **1**,304-308.

Holmström, H., Stenborg, R. & Blomqvist, G. (1986). Elongated pharyngeal flap in extensive clefts of the hard and soft palate. Cleft Palate Journal, **23**, 41-47.

Hotz, M. & Gnoinski,W.M. (1976) Comprehensive care of cleft lip and palate children at Zurich University: A preliminary report. American Journal of Orthodontics,**70**,481-504.

Hotz, M., Gnoinski,W.M., Nussbaumer, H. & Kistler, E. (1978) Early maxillary orthopaedics in cleft lip and palate cases: Guidelines for surgery. Cleft Palate Journal, **15**, 405.

Humphrey, T. (1969) The relation between human fetal mouth opening reflexes and closure of the palate. American Journal of Anatomy, **125**, 317-344.

Hynes,W. (1950). Pharyngoplasty by muscle transposition. British Journal of Plastic Surgery, **3**,128-135.

Ibuki, K., Matsuya, T., Nishio, J., Hamamura, Y. & Miyazaki, T. (1978) The course of facial nerve innervation for the levator veli palatini muscle. Cleft Palate Journal, **15**,209-214.

Ito, S. & Karnovsky, M.J. (1968) Formaldehyde-gluteraldehyde fixatives containing

trinitro compounds. Journal of Cell Biology, **39**,168a-169a.

Jackson.I.T., McLennan,G. & Scheker, L.R. (1983). Primary veloplasty or primary palatoplasty: Some preliminary findings. Plastic and Reconstructive Surgery, **72**,153-157.

Jeyaseelan, N. & Gupta, M. (1988) Canals for the greater palatine nerve and vessels in the hard palate. Journal of Anatomy, **156**, 231-233.

Johnston, M.C. & Millicovsky, G. (1985) Normal and Abnormal Development of the Lip and Palate. In Clinics in Plastic Surgery. ed. Trier, W.C., **12**, pp 521-532.

Jolleys,A. (1954) A review of the results of operations on cleft palates with reference to maxillary growth and speech function. British Journal of Plastic Surgery, **7** ,229-241.

Kapetansky, D.I. (1973). Bilateral transverse pharyngeal flaps for repair of cleft palate. Plastic and Reconstructive Surgery, **52**, 52-54.

Kaplan, E.N. (1975a) The occult submucous cleft palate. Cleft Palate Journal, **12**, 356-368.

Kaplan, E.N. (1975b) Soft palate repair by levator muscle reconstruction and a buccal mucosal flap. Plastic and Reconstructive Surgery, **56**, 129-136.

Kaplan, E.N. (1981) Cleft palate repair at three months. Annals of Plastic Surgery, **7**,179-190.

Keller, J.T.,Saunders, MC, van Loveren, H & Shipley, M.T. (1984) Neuroanatomical considerations of palatal muscles; tensor and levator veli palatini. Cleft Palate Journal, **21**,70-75.

Kelly, A.B. (1910) Congenital insufficiency of the palate. Journal of Laryngology, Rhinology and Otology, **25**,281-300.

Kernahan, D.A. & Stark, R.B. (1958) A new classification for cleft lip and cleft palate. Plastic and Reconstructive Surgery, **22**, 435-441.

Kilner, T.P. (1937) Cleft lip and palate repair technique. St. Thomas's Hospital Report, 2, 127-140.

Kitamura, H. & Kraus, B.S. (1964) Visceral variations and defects associated with cleft lip and palate in human fetuses. A macroscopic description. Cleft Palate Journal, 1, 99-115.

Koberg, W. & Koblin, I. (1973). Speech development and maxillary growth in relation to technique and timing of maxillary growth. Journal of Maxillofacial Surgery, 1, 44-50.

Kraus, B. S., Kitamura, M. & Latham, R.A. (1966) Atlas of Developmental Anatomy of the Face. New York: Harper and Row.

Kraus, B.S. (1970). Basic research in cleft palate- an appraisal and some suggestions. Cleft Palate Journal, 7, 1-26.

Kremzier, J.E. (1984) In Muscle Pathology, ed. Heffner, R.R., Chapter 4, Histochemistry of Muscle, p.31. New York: Churchill Livingstone.

Kriens, O (1967). Anatomische Untersuchungen am gespaltenen weichen Gaumen. Chirurgia Plastica Recons., 4, 14-32.

Kriens, O. (1969) An anatomical approach to veloplasty. Plastic and Reconstructive Surgery, 43, 29-41.

Kriens, O. (1970) Fundamental anatomic findings for an intravelar veloplasty. Cleft Palate Journal, 7, 27-36.

Kuehn, D.P., Folkins, J.W. & Linville, R.N. (1988) An electromyographic study of the musculus uvulae. Cleft Palate Journal, 25, 348-355.

Kuehn, D.P. & Kahane, J.C. (1990) Histologic study of the normal human adult soft palate. Cleft Palate Journal, 27, 26-34.

Langdon, H.L. & Klueber, M.S. (1978) The longitudinal fibromuscular component of the soft palate in the fifteen-week human fetus: musculus uvulae and palatine raphe.

Cleft Palate Journal, **15**,337-348.

Langenbeck, von B. (1861a) Operation der Angeborenen totalen Spaltung des harten Gaumens nach einer neuen Methode. Deutsche Klinik, **8**,231. (English translation reprinted in Plastic and Reconstructive Surgery, **49**,323-326).

Langenbeck, von B. (1861b) Die Uranoplastik mittelst Ablösung des Mucös-periostalen Gaumenüberzuges. Arch. f. Clin. Chir., **2**,205-287. (English translation in Plastic and Reconstructive Surgery,**49**,326-330).

Langman,J.,Woerdeman,M. (1982) Atlas of Medical Anatomy. Philadelphia: Saunders.

Larsson, KS, Bostrom H & Carsroo, S. (1959). Studies on the closure of the secondary palate I. Autoradiographic study in the normal mouse embryo. Experimental Cell Research,**16**, 379-383.

Latham, E.A.& Latham, R.A. (1977) Anatomy of the musculus uvulae in two infants with cleft palate. Cleft Palate Journal,**14**,354.

Latham, R.A., Long, R.E.& Latham,E.A. (1980) Cleft palate velopharyngeal musculature in a five-month old infant. Cleft Palate Journal,**17**,1-16.

Le Gros Clark,W.E. & Blomfield, L.B. (1945) The efficiency of intramuscular anastomoses, with observations on the regeneration of devascularised muscle. Journal of Anatomy, **79**,15-32.

Lessard, J.L., Wee E.L. & Zimmerman E.F. (1974). Presence of Contractile Fetal Proteins in Mouse Fetal Palate Prior to Shelf Elevation. Teratology, **9**, 113-126.

Limborgh, van,J., Lieuw Kie Song, S.H. & Been,W. (1983) Cleft lip and palate due to deficiency of mesencephalic neural crest cells. Cleft Palate Journal, **20**, 251-259.

Lindemann, G., Riis,B. & Sewerin, I. (1977) Prevalence of cleft uvula among 2,732 Danes. Cleft Palate Journal, **14**, 226-229.

Luke, D.A. (1976). Development of the secondary palate in man. Acta Anatomica,

94,596-608.

Lynch, J.B., Lewis, S.R. & Blocker, T.G. (1966) Cleft palate not explained by embryology. Plastic and Reconstructive Surgery, **38**,552-554.

McCoy, F.J. & Zahorsky, C.L. (1972) A new approach to the elusive pharyngeal flap. Plastic and Reconstructive Surgery, **49**,160-164.

McGadey, J. (1970) A tetrazolium method for non-specific alkaline phosphatase. Histochemie, **23**,180-184.

McClyn, J.K. (1940) The Anatomy of the Salpingopharyngeus Muscle. Journal of Laryngology, **55**,1-22.

McDowell, M. (1971) Translation of article by Robert, M. (1764) Treatise on the principal aims of medicine, with a summary of most of the theses presented at the schools of Paris from 1762 to 1764. First volume, p. 8-9. Paris:Lacombe. Plastic and Reconstructive Surgery, **47**,181.

MacKenzie-Stepner, K., Witzel, M.A., Stringer, D.A., Lindsay, W.K., Munro, I.R. & Hughes, H. (1987) Abnormal carotid arteries in the velocardiofacial syndrome: a report of three cases. Plastic and Reconstructive Surgery, **80**, 347-351.

Maher, W.P. & Swindle, P.F. (1962) Submucosal blood vessels of the palate. Dental Progress, **2**,167-180.

Maher, W.P. & Swindle, P.F. (1964) Variations in the network of submucosal arteries in the human fetal palate. Journal of the American Dental Association, **69**,106-111.

Maher, W.P. (1976) Distribution of the greater palatine arteries and other oral facial arteries in instances of human cleft palate. Anatomical Record, **184**,467-468.

Maher, W.P. (1977) Distribution of palatal and other arteries in cleft and non-cleft human palates. Cleft Palate Journal, **14**,1-12.

Maher, W.P. (1981) Artery distribution in the prenatal human maxilla. Cleft Palate

Journal, 18,51-58.

Malek, R. & Psaume, J. (1983) A new operative sequence and technique in the treatment of cleft lip and palate. Two hundred and twenty cases. Ann. Chir. Plast. Esthét., 28, 237-247.

Marsh, J.L., Grames, L.M. & Holtman, B. (1989). Intravelar veloplasty: a prospective study. Cleft Plate Journal, 26, 46-50.

Mathes, S.J. & Nahai, F. (1981) Classification of the vascular anatomy of muscles: Experimental and clinical correlation. Plastic and Reconstructive Surgery, 67, 177-187.

Mato, M., Aikawa, E. & Smiley, G.R. (1972a) Invagination of human palatal epithelium prior to contact. Cleft Palate Journal, 9,335-340.

Mato, M., Smiley, G.R. & Dixon, A.D. (1972b) Epithelial changes in the presumptive regions of fusion during secondary palate formation. Journal of Dental Research, 51,1451-1456.

Maue-Dickson,W. (1979) The craniofacial complex in cleft lip and palate: An updated review of anatomy and function. Cleft palate Journal,16,291-317.

Maue-Dickson,W. & Dickson, D.R. (1980) Anatomy and Physiology Related to Cleft Palate: Current Research and Clinical Implications. Plastic and Reconstructive Surgery, 65,83-90.

Maue-Dickson,W. (1980) In Cleft Craft. Millard,D.R. Vol.3 Alveolar and Palatal Deformities,Ch. 2,pp.19-50. Boston: Little,Brown.

May,M. (1971) Translation of article by Graefe, von C.F. (1820) A newly discovered method to correct congenital speech defects. Journal der Chirurgie und Augenheilkunde, 1,1. Plastic and Reconstructive Surgery, 47, 488-492.

Mazaheri, M.,Krogman, W.M.,Harding, R.L., Millard, R.T. & Mehta, S. (1977) Longitudinal analysis of growth of the soft palate and nasopharynx from six months to six years. Cleft Palate Journal, 14,52-62.

- Millard, D.R. (1976) Cleft Craft Vol. 1 The Unilateral Deformity. Boston: Little, Brown.
- Millard, D.R. (1980a) Cleft Craft. Vol.3 Alveolar and Palatal Deformities, Illustration opp. p.37. Boston: Little,Brown.
- Millard, D. R. (1980b) Cleft Craft Vol. 3 Alveolar and Palatal Deformities, Ch. 22, pp. 383-389. Boston: Little, Brown.
- Millard, D.R. (1980c) Cleft Craft. Vol.3 Alveolar and Palatal Deformities, Ch. 43,pp 707-731. Boston: Little,Brown.
- Millicovsky, G. & Johnston, M.C. (1981) Active role of embryonic facial epithelium: new evidence of cellular events in morphogenesis. Journal of Embryology and Experimental Morphology, **63**,53-66.
- Millicovsky, G., Ambrose, J.H. & Johnston, M.C. (1982) Developmental alterations associated with spontaneous cleft lip and palate in CL/Fr mice. American Journal of Anatomy, **164**,29-44.
- Mina, M.M.F. (1979). Styloid, Velar, and Pharyngeal Muscles in Cleft Palate. The Journal of Otolaryngology, **8**,179-190.
- Moore, F.T. (1960) A new operation to cure nasopharyngeal incompetence. British Journal of Plastic Surgery, **47**,424-428.
- Moore, G.E., Ivens, A., Newton, R., Balacs, M.A., Henderson, D.J., Jenson,O. (1990) X Chromosome genes involved in regulation of facial clefting and spina bifida. Cleft Palate Journal, **27**, 131-135.
- Morel-Fatio, D. (1971) Translation of article by Roux, P. (1819) Observation on a congenital division of the soft palate and the uvula cured by means of an operation similar to that for a hare-lip. Journal Universel des Sciences Médicales,**16**,356. Plastic and Reconstructive Surgery,**47**,180.
- Moynahan, E.J.,Sethi, N.C.& Brookes, M.(1972) Histochemical observations on

developing rat skin. Journal of Anatomy, **111**,427-435.

Okano, H., Ohta, Y., Ozaki, A. & Kimoto, M. (1962) Blood supply of the cleft lip, alveolus and palate in a human fetus. Okajimas Folia Anatomica Japonica,**38**,191-203.

Ortiz-Monasterio, F., Olmedo, A., Trigros,I . (1974) Final results from delayed treatment of patients with clefts of the lip and palate. Scandinavian Journal of Plastic and Reconstructive Surgery, **8**,109-115.

Orticochea, M. (1968). Construction of a dynamic muscle sphincter in cleft palates. Plastic and Reconstructive Surgery,**41**,323-327.

Orticochea, M. (1970). Results of the dynamic muscle sphincter operation in cleft palates. British Journal of Plastic Surgery,**23**,108-114.

Owsley, J.Q., Lawson, L.I., Miller, E.R. & Blackfield, H.M. (1966). Experience with the high attached pharyngeal flap. Plastic and Reconstructive Surgery, **38**, 232-242.

Padget,D. H. (1948). The development of the cranial arteries in the human embryo. Contributions to Embryology, No. **212**, 205-261.

Padget,D. H. (1957). The development of the cranial venous system in man. Contributions to Embryology, No. **247**, 80-140.

Perko, M.A. (1974) Primary closure of the cleft palate using a palatal mucosal flap: an attempt to prevent growth impairment. Journal of Maxillofacial Surgery, **2**,40.

Perko, M. A. (1979) Two stage closure of cleft palate. Journal of Maxillofacial Surgery, **7**, 76-80.

Pigott, R.W. (1969a) The nasendoscopic appearance of the normal palatopharyngeal valve. Plastic and Reconstructive Surgery, **43**,19-24.

Pigott, R.W., Benson, J.F. & White, F.D. (1969b) Nasendoscopy in the diagnosis of velopharyngeal incompetence. Plastic and Reconstructive Surgery,**43**,141-147.

- Pigott, R.W. (1980) In Advances in Management of Cleft Palate, ed. Watson,A.C.H. & Edwards,M., Ch.15, 206-231. Edinburgh:Livingstone.
- Pourtois, M. (1969) Study on the fusion of palatal processes *in vitro* and *in vivo*. Journal of Dental Research, **48**,1135.
- Poswillo,D. (1974). The pathogenesis of submucous cleft palate. Scandinavian Journal of Plastic and Reconstructive Surgery, **8**, 34-41.
- Poswillo,D. (1966) Observations of fetal posture and causal mechanisms of congenital deformity of palate, mandible, and limbs. Journal of Dental Research, **45**, 384-396.
- Pratt,R.M.,Goggins,J.R.,Wilk,A.L. & King, C.T.G.(1973). Acid mucopolysaccharide synthesis in the secondary palate of the developing rat at the time of rotation and fusion. Developmental Biology, **32**, 230-237.
- Pratt, R.M. & Hassell, J.R. (1975). Appearance and distribution of carbohydrate-rich macromolecules on the epithelial surface of the developing rat palatal shelf. Developmental Biology, **45**,192-198.
- Randall, P. (1979) In Plastic Surgery, 3rd Edition, ed. Grabb,W.C., Smith.J.W. Ch. 8,Cleft Palate., pp. 205-226.
- Randall,P. (1980). In Advances in the Management of Cleft Palate, ed. Watson,A.C.H. & Edwards,M., Ch.17, 247-263. Edinburgh: Churchill Livingstone.
- Rich, A.R. (1920). The innervation of the tensor veli palatini and levator veli palatini muscles. John Hopkins Hospital Bulletin, **355**,305-310.
- Robertson, N.R.E. & Jolleys,A. (1974) The timing of cleft palate repair. Scandinavian Journal of Plastic and Reconstructive Surgery,**8**,49-51.
- Rogers, B.O. (1967) Palate surgery prior to von Graefe's pioneering staphylorrhaphy (1816): An historical review of the early causes of surgical indifference in repairing the cleft palate. Plastic and Reconstructive Surgery, **39**,1-19.

Rohan, R.F. & Turner, L. (1956) The levator palati muscle. Journal of Anatomy, **90**, 153-154.

Romanes, G.J. (ed.) (1981) Cunningham's Textbook of Anatomy. 12th Edition London: Oxford University Press.

Rood, S.R. (1973). The morphology of m. tensor veli palatini in the human fetus. American Journal of Anatomy, **138**,191-195.

Rose,W. (1891) Harelip and Cleft Palate. Chapter 1, p.1-25. London: Lewis.

Ross, M.E. (1971) Functional anatomy of tensor palati-- its relevance in cleft palate surgery. Archives of Otolaryngology,**93**,1-8.

Ross, R.B. (1987) Treatment variables affecting facial growth in complete unilateral cleft lip and palate. Cleft Palate Journal, **24**,5-77.

Ruding, R.(1964) Cleft palate. Anatomic and surgical considerations. Plastic and Reconstructive Surgery, **33**,132-147.

Safra, M.J. & Oakley, G.P. (1976). Valium: an oral cleft teratogen? Cleft Palate Journal, **13**, 198.

Sanvenero-Roselli, G. (1953) Developmental pathology of the face and the dysraphic syndrome - an essay of interpretation based on experimentally produced congenital defects. Plastic and Reconstructive Surgery, **11**,36-38.

Sawa, H. (1961) Arterial distribution of the palate in some mammals. Okajimas Folia Anatomica Japonica, **37**,49-92.

Schlesinger, M.J. (1957) New radiopaque mass for vascular injection. Laboratory Investigation, **6**,1-11.

Schmid, E. (1971) Translation of article by Dieffenbach, J. F. (1826) Beitrage zur Gaumennath. Litt. Ann. d. ges. Heilk.,**4**,145. Plastic and Reconstructive Surgery, **47**, 588-591.

- Schuchardt, K. (1971) Translation of article by Graefe, von C.F. (1817). *Journal der praktischen Heilkunde*, p.118. *Plastic and Reconstructive Surgery*,**47**, 375-376.
- Schuepbach, P.M. & Schroeder, H.E. (1984) Prenatal repair of experimentally induced clefts in the secondary palate of the rat. *Teratology*, **30**,131-142.
- Schweckendiek, W. (1978) Primary veloplasty: long-term results without maxillary deformity. A twenty-five year report. *Cleft Palate Journal*, **15**,268-274.
- Seif,S. & Dellon,A.L. (1978) Anatomic relationships between the human levator and tensor veli palatini and the Eustachian tube. *Cleft Palate Journal*,**15**,329-336.
- Semb, G. & Shaw,W.C. (1990) Pharyngeal flap and facial growth. *Cleft Palate Journal*, **27**, 217-224.
- Shprintzen,R.J., Rakof,S.J., Skolnick,N.L., & Lavorato,A.S. (1977) Incongruous movements of the velum and lateral pharyngeal walls. *Cleft Palate Journal*,**14**,148-157.
- Shprintzen,R.J. (1982) Palatal and pharyngeal abnormalities in craniofacial syndromes. *Birth Defects*, **18**, 53-78.
- Sinclair,D.C. (1981). In *Cunningham's Textbook of Anatomy*, Ed. Romanes,G.J. 12th Edition, Ch. 5, 265-409.
- Skolnick, M.L. (1969) Video velopharyngography in patients with hypernasal speech, with emphasis on lateral pharyngeal motion in velopharyngeal closure. *Radiology*, **93**, 747-755.
- South, J. (1972). Teratogenic effects of anticonvulsants. *Lancet*, **2**, 1154.
- Sperber, G.H. (1989) *Craniofacial Embryology*. 4th Edition. Bristol: Wright.
- Stark, R.B. & DeHaan, C. (1960) The addition of a pharyngeal flap to primary palatoplasty. *Plastic and Reconstructive Surgery*, **26**,378-387.

Stark, R.B. (1973) Development of the face. Surgery, Gynecology & Obstetrics, **137**,403-408.

Stellmach, R.K. (1972) Translation of article by Schoenborn, K. (1876) On a new method of staphylorrhaphy. Arch. für klinische Chirurgie, **19**, 527-531. Plastic and Reconstructive Surgery, **49**, 558-561.

Stern, I.B. (1986) In Orban's Oral Histology and Embryology.10th. Edition. ed.Bhaskar,S.N. St.Louis: CV Mosby.

Subtelny, J.D. & Nieto, R.P. (1978) A longitudinal study of maxillary growth following pharyngeal flap surgery. Cleft Palate Journal, **15**,118-131.

Swarts, J.D.& Rood, S.R. (1990) The morphometry and three dimensional structure of the adult Eustachian tube: implications for function. Cleft Palate Journal, **27**, 374-381.

Swindle, P.F. & Maher,W.P. (1963) Mucosal blood vessels of the palate. Dental Progress, **3**, 106-111.

Thurston, J.B., Larson, D.L., Shanks, J.C., Bennett, J.E. & Parsons, R.W. (1980) Nasal obstruction as a complication of pharyngeal flap surgery. Cleft Palate Journal, **17**,148-154.

Tolarova, M. (1982). Periconceptual supplementation with vitamins and folic acid to prevent recurrence of cleft lip. Lancet, **2**, 217.

Tompsett, D.H. (1970) Anatomical Techniques (2nd Edition) Edinburgh: E & S Livingstone.

Trasler, D.G., Walker,B.E. & Fraser,F.C. (1956) Congenital malformations produced by amniotic sac puncture. Science, **124**,439.

Trasler, D.G. (1968) Pathogenesis of cleft lip and its relation to embryonic face shape in A /J and C57BL mice. Teratology, **1**,33-50.

Trier,W.C. (1985a). In Clinics in Plastic Surgery, Cleft Lip and Cleft Palate ed. Trier,W.C. Ch. The Pharyngeal Flap Operation,Vol.12, pp 697-710.

Trier,W.C. (1985b). In Clinics in Plastic Surgery, Cleft Lip and Cleft Palate ed. Trier,W.C. Ch. Primary Palatoplasty,Vol. 12, pp 659-675.

Trier, W.C. (1985c) In Clinics in Plastic Surgery, Cleft Lip and Cleft Palate ed. Trier,W.C. Ch. Evaluation and Treatment Planning for Patients with Cleft Lip and Cleft Palate, Vol. 12, pp. 553-572.

Trusler, H.M., Bauer, T.B., & Tondra, J.M. (1955) The cleft lip-cleft palate problem. Plastic and Reconstructive Surgery, 16,174-188.

Tyler,M.S. & Koch,W.S. (1974). Epithelial-mesenchymal interactions in the secondary palate of the mouse. Journal of Dental Research, 53,64.

Vander, A.J., Sherman, J.H. & Luciano, D.S. (1980) Human Physiology: The Mechanics of Body Function. 3rd Edition. New York: M^cGraw-Hill.

Veau,V. (1931) Division Palatine, Paris:Masson et Cie.

Wardill,W. E. M. (1937) The technique of operation for cleft palate. British Journal of Surgery, 25 ,117-130.

Waterman, R.E. & Mellor, S.M. (1974) Alterations in the epithelial surface of human palatal shelves prior to and during fusion: a scanning electron microscopic study. Anatomical Record, 180, 111-136.

Watson, A.C.H. (1980) Advances in the Management of Cleft Palate, ed. Watson, A.C.H. & Edwards,M. Edinburgh:Churchill Livingstone.

Weston, J.A. (1970) The migration and differentiation of neural crest cells. Adv. Morphog., 8,41-114.

Whillis, J. (1931) A note on the muscles of the palate and the superior constrictor. Journal of Anatomy and Physiology, 65,92-95.

Whitaker, L.A., Randall, P., Graham, W.P., Hamilton, R.W. & Winchester, R. (1972). A prospective and randomised series comparing superiorly and inferiorly based posterior pharyngeal flaps. Cleft Palate Journal, 9, 304-311.

Williams, P.L., Warwick, R., Dyson, M. & Bannister, L.H. (eds.) (1989) Gray's Anatomy. 37th Edition Edinburgh: Churchill Livingstone.

Wood, P.J. & Kraus, B.S. (1962) Prenatal development of the human palate. Archives of Oral Biology, 7, 137-150.

Zimmerman, E.F. & Wee, E.L. (1984) Role of neurotransmitters in palate development. In Current Topics in Developmental Biology, ed. Zimmerman, E.F. Chap. 3, pp. 37-63. Orlando : Academic Press.

Zuckerman, S. (1981) A New System of Anatomy. (2nd Edition). Oxford: Oxford University Press.



The Blood Supply of the Human Velum and Pharynx.

Some Implications for Cleft Palate Surgery.

(Two Volumes)

Volume 2

Eric Freedlander

April, 1991

© E. Freedlander, 1991 Vol.2

Contents

Volume 2

	Page
Abbreviations	7
Illustrations	
Fig. 1 von Graefe's instruments	10
2 Veau flaps	11
3 von Langenbeck flaps	11
4 Furlow's double opposing Z-plasty	12
5 Drawing of face of 6-week embryo	13
6 Scanning electron micrograph (SEM) of stomatodeal chamber of 7-week embryo	14
7 SEM of palatal shelves	14
8 SEM of palatal shelves	15
9 SEM of palatal shelves	15
10a SEM of medial edge epithelium	16
10b Higher magnification of medial edge epithelium	16
11 Palate of 9-week fetus	17
12 Palate of 22-week fetus showing midline cysts	18
13 Palate of 20-week fetus showing bone formation	18
14 Normal adult bony palate	19
15 Drawing of origins of levator and tensor veli palatini	20
16 SEM of soft palate of embryo	21
17 SEM of soft palate of embryo	21
18 Drawing from Veau's book	22
19 18-week fetus with right cleft lip and palate	23
20 22-week fetus with "median" cleft lip and bilateral cleft palate	23

Fig. 21	20-week fetus with cleft secondary palate	24
22	Argyle Medicut trochar and cannula	24
23	Lateral view of adult skull showing osteotomy cuts	25
24	Inner aspect adult skull	25
25	Dissection microscope	26
26	Posterior pharyngeal wall in 26-week fetus	27
27	Posterior pharyngeal wall in adult cadaver	27
28a	Right lateral view of fetal head	28
28b	Sketch of fetal head	28
28c	Right lateral view of fetal head	28
29	Right lateral view of fetal head	29
30	Left lateral view of fetal head	29
31	Left lateral view of fetal head	30
32	Right lateral view of fetal head	30
33	Right lateral view of fetal head	31
34a	Drawing of oral surface of fetal palate	31
34b	Extrapalatal muscles of fetal palate	31
35	Left lateral view of fetal head	32
36	Right lateral view of tensor veli palatini muscle	32
37	Right lateral view of fetal head	33
38a	Inferior view of fetal palatal muscles	33
38b	Drawing of oral surface of palate	33
39	Left lateral view of head of adult cadaver	34
40	Venous plexus on lateral surface of adult tensor muscle	34
41	Oral surface of fetal soft palate	35
42	Oral surface of fetal soft palate	35
43	Oral mucosa of fetal soft palate	36
44	Oral view of fetal soft palate	37
45	Oral view of fetal soft palate	37
46a	Oral view of fetal soft palate	38
46b	Oral view of fetal soft palate	38
47a	Ascending palatine artery entering fetal soft palate	39
47b	Drawing of fetal palate	39
47c	Ascending palatine artery and levator veli palatini muscle	39
47d	Ascending palatine artery in relation to hamulus	40

Fig. 48a	Oral surface of fetal palate	41
48b	Drawing of fetal palate	41
48c	Palatopharyngeus muscle dissected off aponeurosis	41
48d	Ascending palatine artery passing through levator	42
49a	Oral surface of palate of 25-week fetus	43
49b	Drawing of fetal palate	43
49c	Further dissection of palate	43
49d	Ascending palatine artery passing deep to levator	44
49e	Ascending palatine artery reaching musculus uvulae	44
50	Cleared palate of adult cadaver	45
51	Oral view of adult palate	45
52	Ascending palatine artery of adult palate	46
53	Xray of adult palate	46
54	Xray of adult palate	47
55	Cleared adult soft palate	47
56a	Left lateral view of fetal head (cleft secondary palate)	48
56b	Drawing of lateral view of fetal head	48
57a	Right lateral view of fetal head (cleft primary and secondary palate)	48
57b	Further dissection	49
58a	Left lateral view of fetal head (cleft primary and secondary palate)	49
58b	Drawing of dissected fetal head	49
59	Oral surface of fetal cleft palate	50
60a	Montage of right side of fetal cleft palate	50
60b	Montage of further dissection	51
61	Inferior view of fetal cleft palate	51
62	Drawing of mucosal blood supply of soft palate	52
63	Coronal section of 18-week fetal head (normal palate)	53
64	Coronal section of 18-week fetal head	53
65a,b	Coronal sections of 16-week fetus with cleft primary palate	54
66	Coronal section of 19-week fetus with cleft secondary palate	55
67a,b	Coronal sections of 19-week fetus with cleft	

	secondary palate	56
Fig. 68	Coronal section of 19-week fetus with cleft secondary palate	57
69	Coronal section of 17-week fetus with cleft primary, secondary palate	57
70	Coronal section of 17-week fetus with cleft primary, secondary palate	58
71a	Posterior pharyngeal wall of adult cadaver	59
71b	Posterior pharyngeal wall of adult cadaver	59
72a	Posterior pharyngeal wall of adult cadaver	60
72b	Close-up view of posterior pharyngeal wall	60
73 &	Frontispiece Posterior pharyngeal wall of cleared specimen adult cadaver	61
74	Xray of posterior pharyngeal wall of adult cadaver	61
75	Posterior pharyngeal wall of adult cadaver	62
76	Posterior pharyngeal wall of cleared specimen	62
77	Transverse section posterior pharyngeal wall of adult surgical specimen	63
78	Posterior pharyngeal wall of 20-week fetus	64
79	Superiorly based pharyngeal flap	64
80a	Montage of posterior pharyngeal wall of 24-week fetus	65
80b	Inferiorly based pharyngeal flap	65
81a	Posterior pharyngeal wall of 20-week fetus showing Kapetansky flap	66
81b	Kapetansky flap elevated	66
82	Left palatopharyngeal arch of cleared specimen	67
83	Oral surface of palate of 27-week fetus	68
84	Oral surface of right hemipalate in 25-week fetus	68
85a	Left soft hemipalate of fetus with cleft palate	69
85b	Left levator veli palatini muscle	69
85c	Levator muscle inserting into aponeurosis	70
86	Left soft hemipalate of 20-week fetus with cleft palate	70
87a	Montage of dissected soft palate of fetus with cleft secondary palate	71
87b	Dissected right soft hemipalate	72

Fig. 87c	Left soft hemipalate	72
88	Drawing of insertions levator veli palatini muscle	73
89	Drawing of insertions palatopharyngeus, superior constrictor and levator muscles	73
90	Left lateral view of 22-week fetus with cleft palate	74
91	Left extrapalatal muscles of fetus with cleft palate	74
92a	Coronal section through hemipalate of 19-week fetus with cleft secondary palate	75
92b	Coronal section through hemipalate showing aponeurosis	75
92c	Coronal section through soft hemipalate	76
92d	Levator veli palatini muscle fibres	76
93a	Coronal section of soft hemipalate of cleft specimen	77
93b	Coronal section through hemiuvula	78
93c	Coronal section through hemiuvula	78
94a	Transverse section through upper portion levator muscle	79
94b	Transverse section through mid portion levator	79
94c	Transverse section through medial portion levator	80
95a	Transverse section through levator muscle	80
95b	Transverse section through mid portion levator	81
95c	Transverse section through medial portion levator	81
96	Frozen section of levator	82
97	Frozen section of musculus uvulae	82
98	Frozen section of musculus uvulae	83
99	Frozen section of palatopharyngeus	83
100	High power view of frozen section of levator	84
101a-c	Lateral views of infant, child and adult skulls	85
102A-D	Patterns of arterial supply to levator veli palatini	86
103a,b	Drawings of levator and palatopharyngeus insertions	87
104a,b	Drawings of levator and palatopharyngeus insertions	88
105a	Intraoperative photograph of cleft palate	89
105b	Cleft edges marked	89
105c	Cleft edges incised	89
105d	Nasal mucosal closure completed	90
105e	Oral closure completed on soft palate	90
105f	Oral closure completed over hard palate	90

Abbreviations

A	aponeurosis
Alv	alveolus
a m	accessory meningeal artery
a p	ascending palatine artery
a ph	ascending pharyngeal artery
aud t	auditory tube
c c	common carotid artery
D	digastric muscle (posterior belly)
e c	external carotid artery
EP	epithelial pearl
f	facial artery
gl	glandular elements
GPF	greater palatine foramen
H	pterygoid hamulus
HP	hard palate
Hy	greater cornu hyoid bone
Hyp N	hypoglossal nerve
i c	internal carotid artery
IF	incisive fossa
L	lip
LN	lingual nerve
LPF	lesser palatine foramen
L Pt	lateral pterygoid muscle
L Pt P	lateral pterygoid plate
LVP	levator veli palatini muscle
m	maxillary artery
M	mandible
m m	middle meningeal artery

MN	mandibular nerve
MPS	midpalatal suture
M Pt	medial pterygoid muscle
M Pt P	medial pterygoid plate
MU	musculus uvulae muscle
N	nerve
NP	nasopharynx
NS	nasal septum
OP	oropharynx
PB	horizontal plate of palatine bone
PBF	pharyngobasilar fascia
Pet T	petrous temporal bone
PMS	premaxillary "suture"
Pph	palatopharyngeus muscle
PPM	palatine process maxilla
PPW	posterior pharyngeal wall
PS	secondary palatal shelf
S	styloid process
SC	superior constrictor muscle
SG	styloglossus muscle
SH	stylohyoid muscle
SMG	submandibular gland
SP	soft palate
SPh	stylopharyngeus muscle
Sp Sph	spine of sphenoid bone
s thy	superior thyroid artery
T	tongue
TG	tooth germ
Thy	thyroid gland
TVP	tensor veli palatini muscle
U	uvula

LEGENDS FOR ILLUSTRATIONS

Fig.1 Von Graefe's instruments.
(illustration from "The Operative Story of Cleft Palate," by
Dorrance, G.M. 1933)

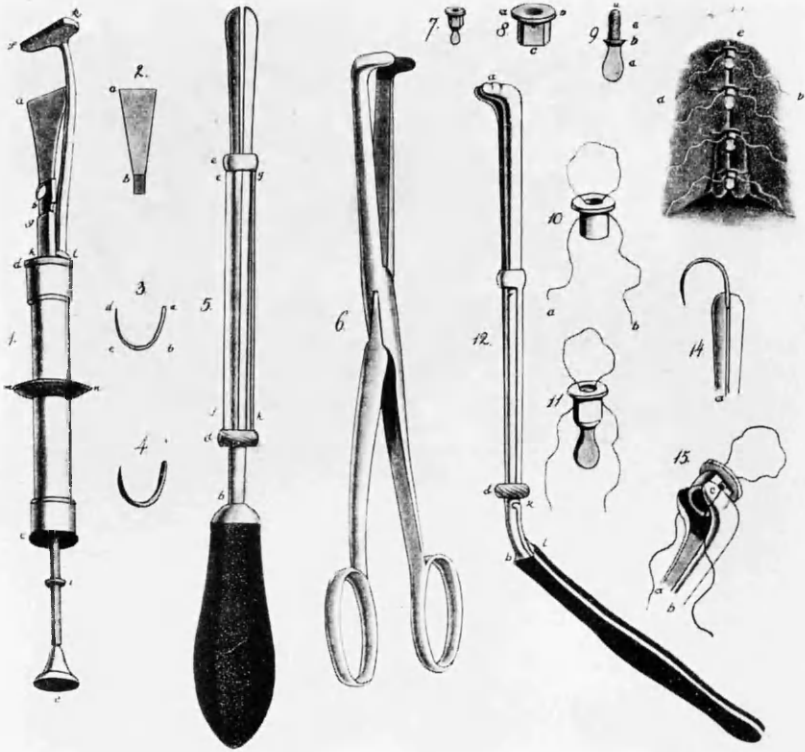


Fig.2 **Diagram of palate showing Veau flaps marked and sutured in position.**

Fig.3 **Diagram of hard palate showing von Langenbeck flaps marked and sutured.**

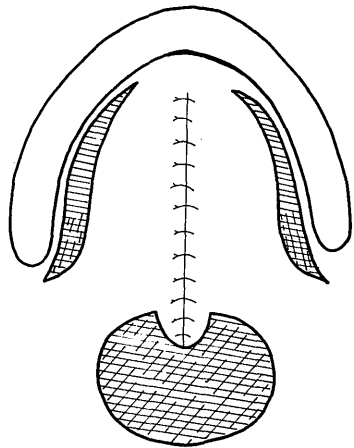
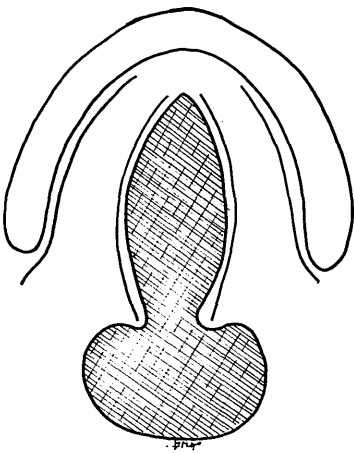
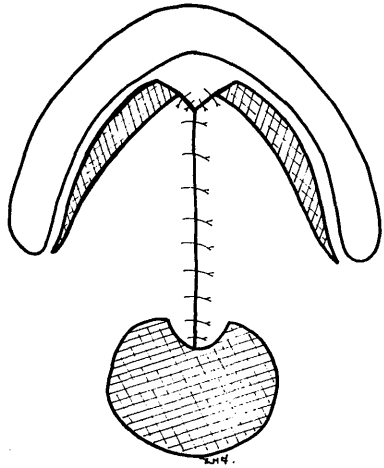
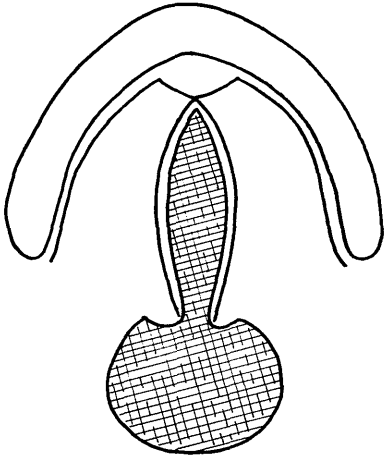
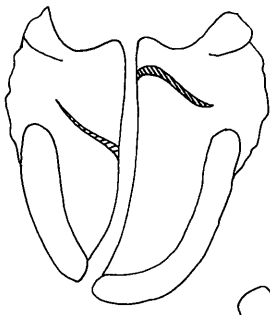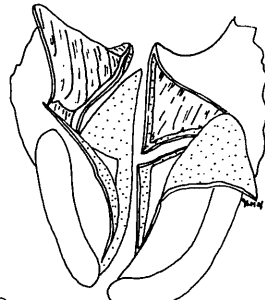


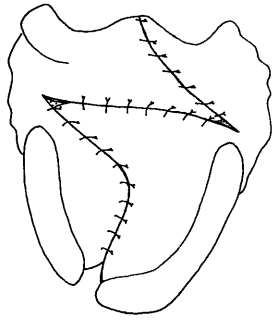
Fig.4 **Diagram of palate showing Furlow's double opposing Z-plasty procedure. a. oral incisions. b. oral flaps raised and nasal flaps incised. c. flaps sutured in position.**



a



b



c



Fig.5 Drawing of face of 6-week human embryo showing facial prominences.

(Abbreviations: FNP= frontonasal process; LNP= lateral nasal process ; MXP= maxillary process; MDP= mandibular process)

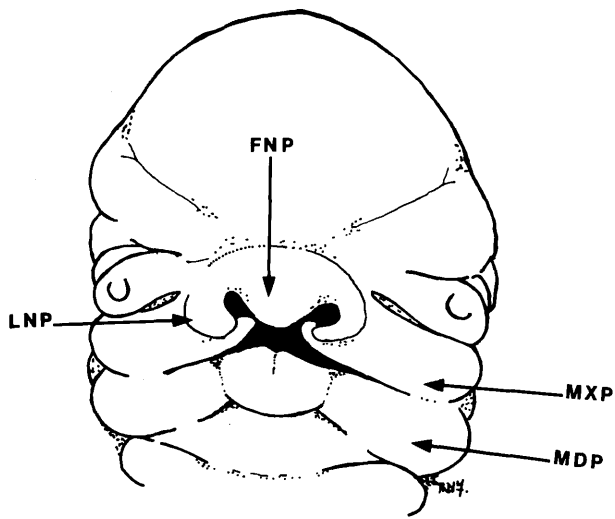


Fig.6 Scanning electron micrograph of stomatodeal chamber of 7-week human embryo showing tongue between secondary palatal shelves (x 35).

Fig.7 Scanning electron micrograph of specimen slightly older than that in Fig. 6. Note horizontal anterior portion of palatal shelf and vertically orientated posterior portion (x 75).

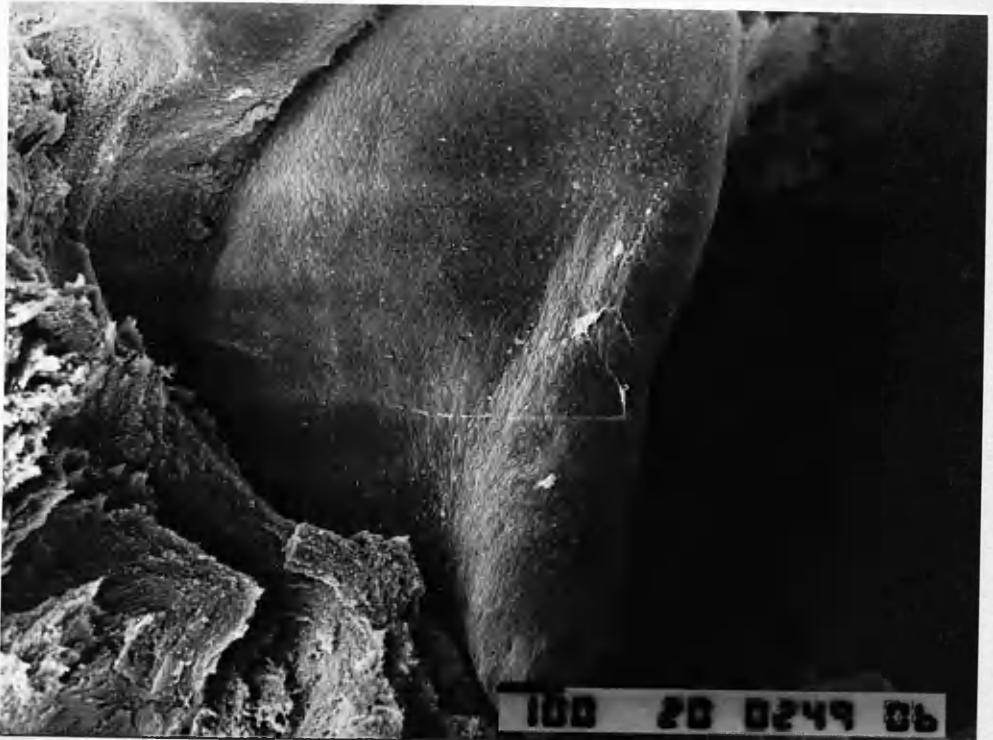
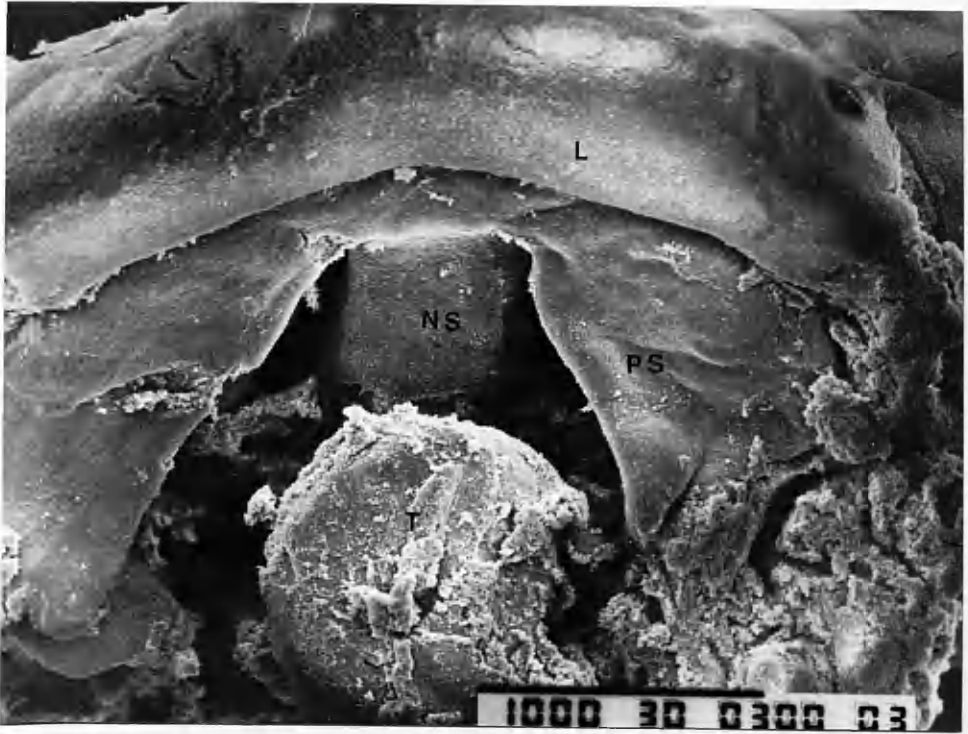

Fig.8 Scanning electron micrograph of 8-week human embryo showing horizontal secondary palatal shelves almost in contact (x 35).

Fig.9 Rotated view of same specimen as Fig.8 showing medial edge epithelium (x 75).

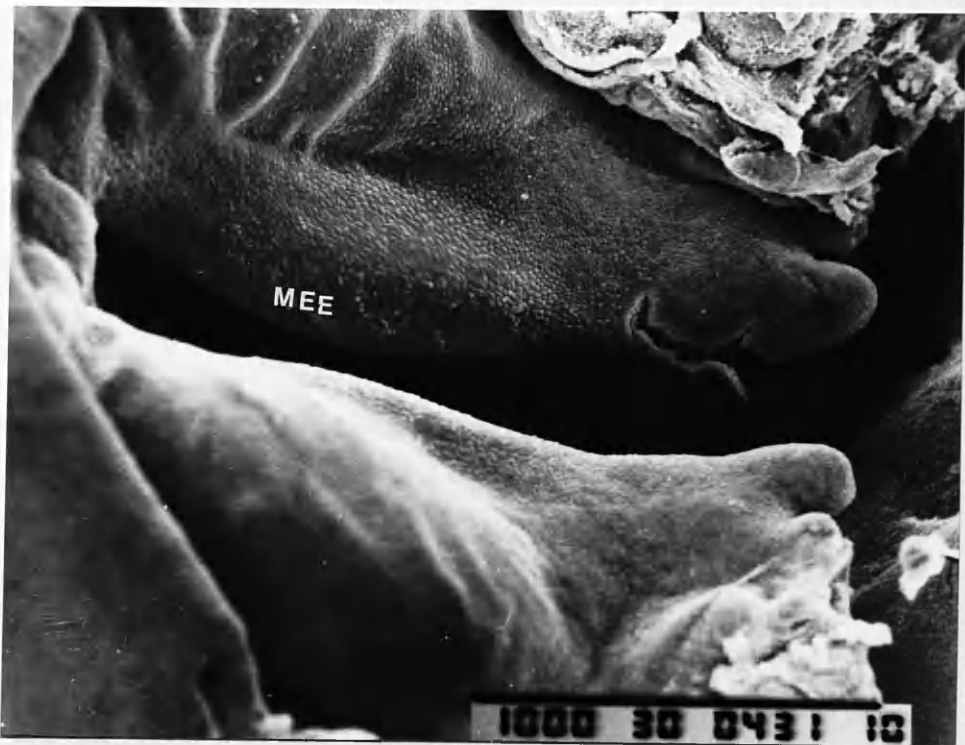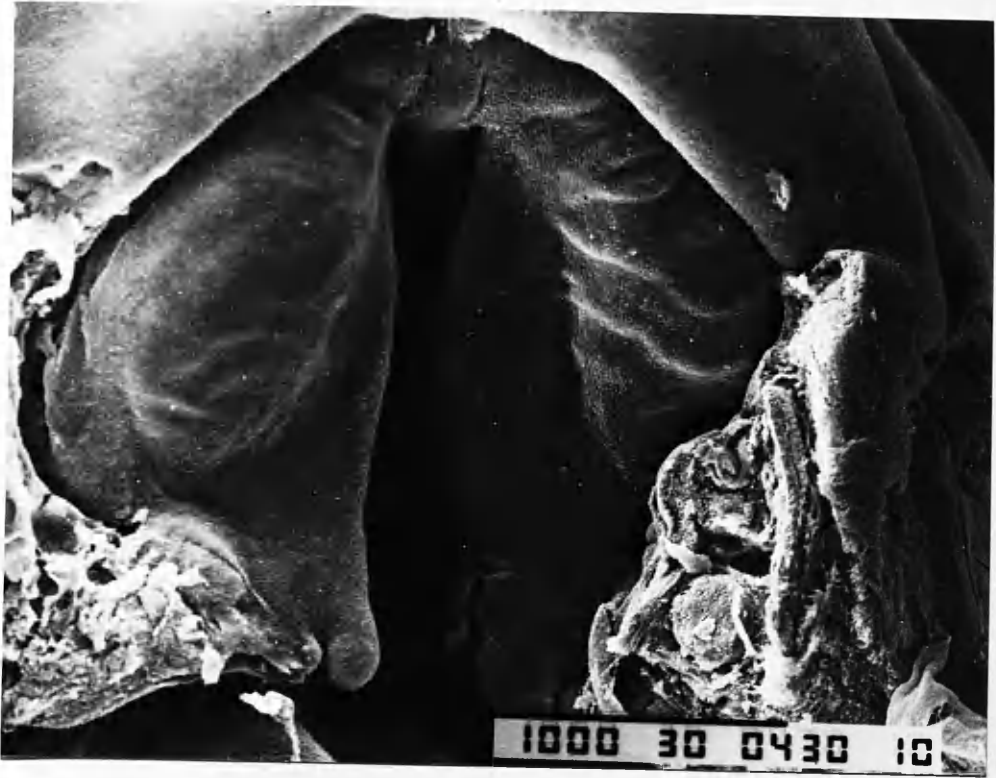


Fig 10a. Medium edge epithelium at higher magnification. Note healthy epithelial cells to right of field and area of apparent desquamation left and centre field (x 500).

Fig.10b. Higher magnification of area degeneration of medial edge epithelium. Note elongated cells (arrowed) (x1000).

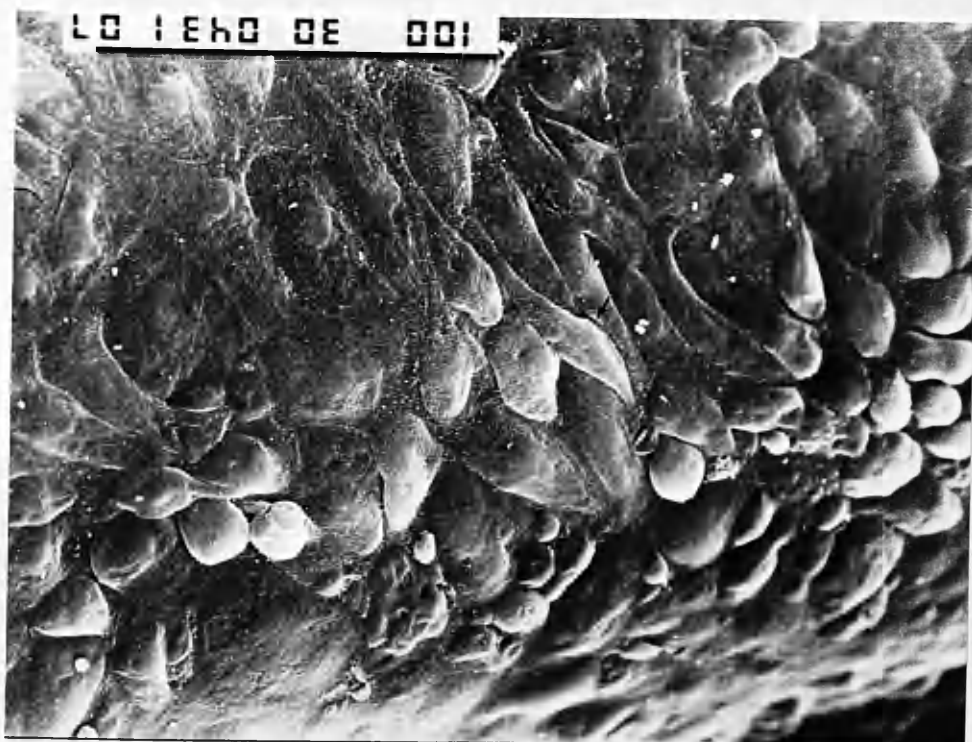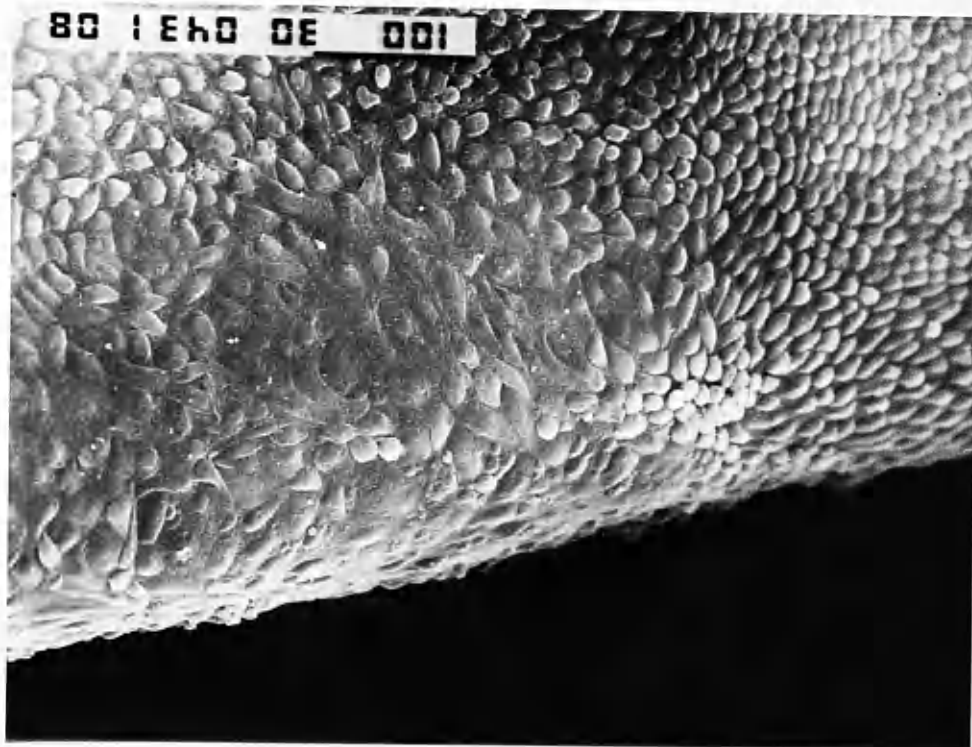


Fig.11 Dissection microscope photograph of 9-week human fetus showing fused hard palate and open soft palate. Posterior edge of developing hard palatal shelf can be identified (arrows) (x13).

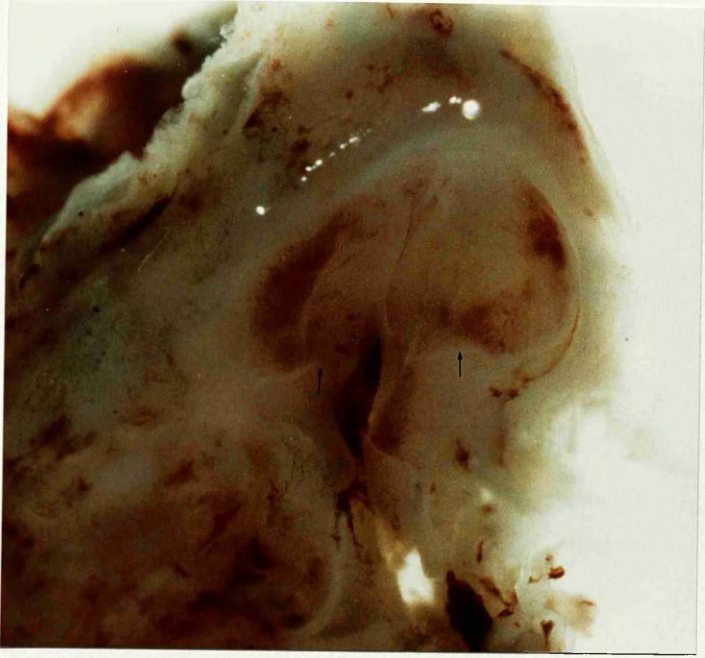


Fig. 12 Oral view of palate of 22-week fetus. Note row of midline cysts on hard palate and cluster at hard / soft palate junction (x8).

Fig. 13 Anterior portion of oral surface of palate of fetus of 20 weeks' gestation. The soft tissues have been removed revealing bone forming in premaxilla and in palatal shelves. The midpalatal suture and premaxillary 'suture' can be clearly seen (x8).

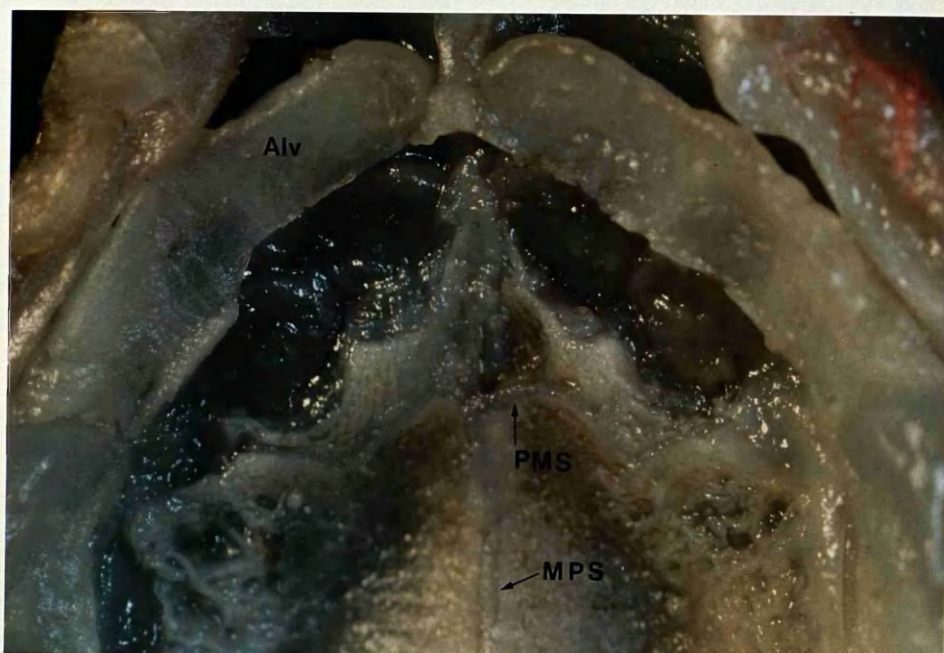
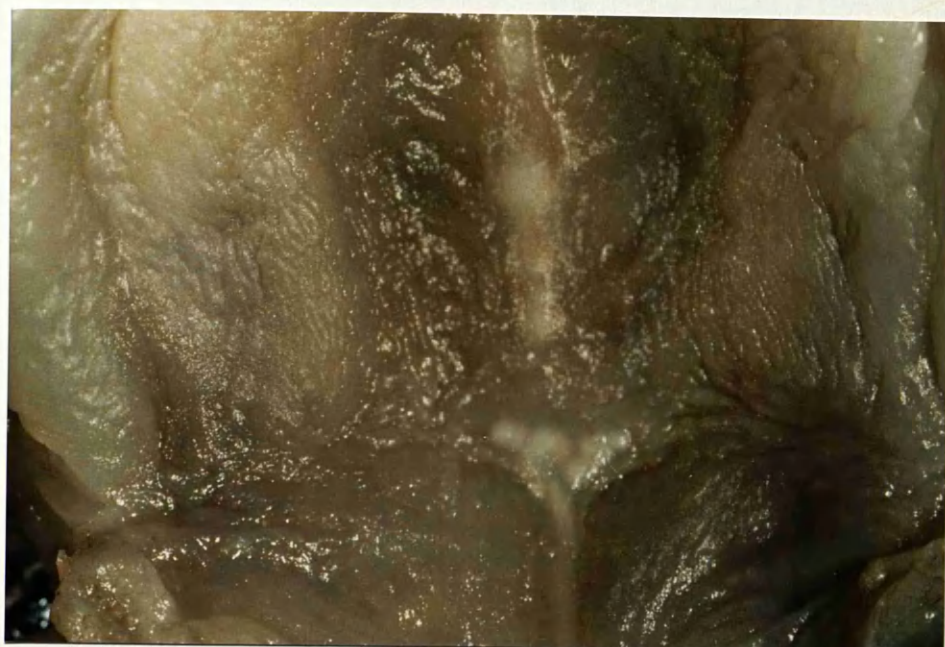

Fig. 14 **Normal adult bony palate.**

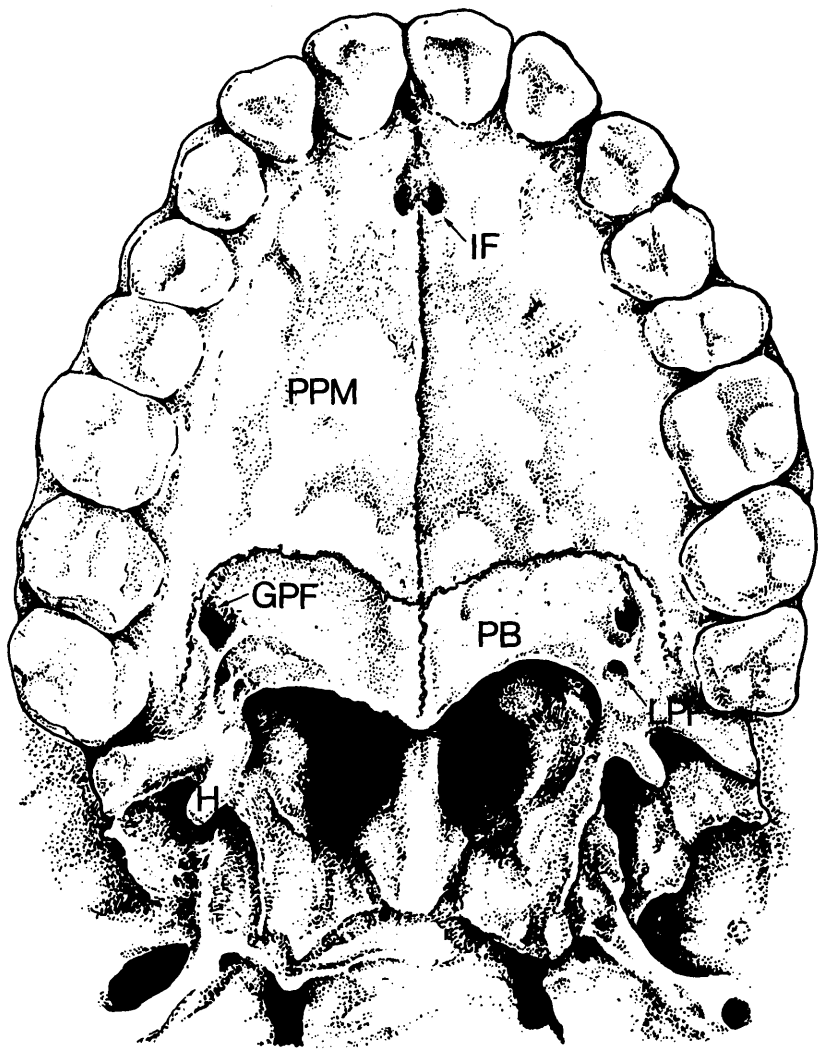


Fig. 15. Drawing of skull base showing bony origins of levator veli palatini and tensor veli palatini muscles.

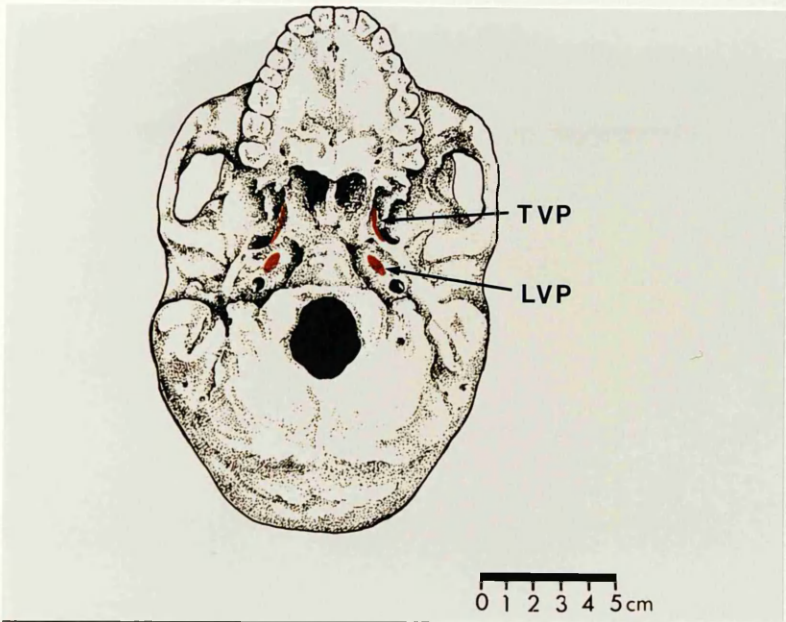


Fig.16 Scanning electron micrograph of oral surface of soft palate of human embryo showing squamous epithelium (x1500).

Fig.17 View of nasal side of developing soft palate of same specimen showing ciliated columnar epithelium (x2000).


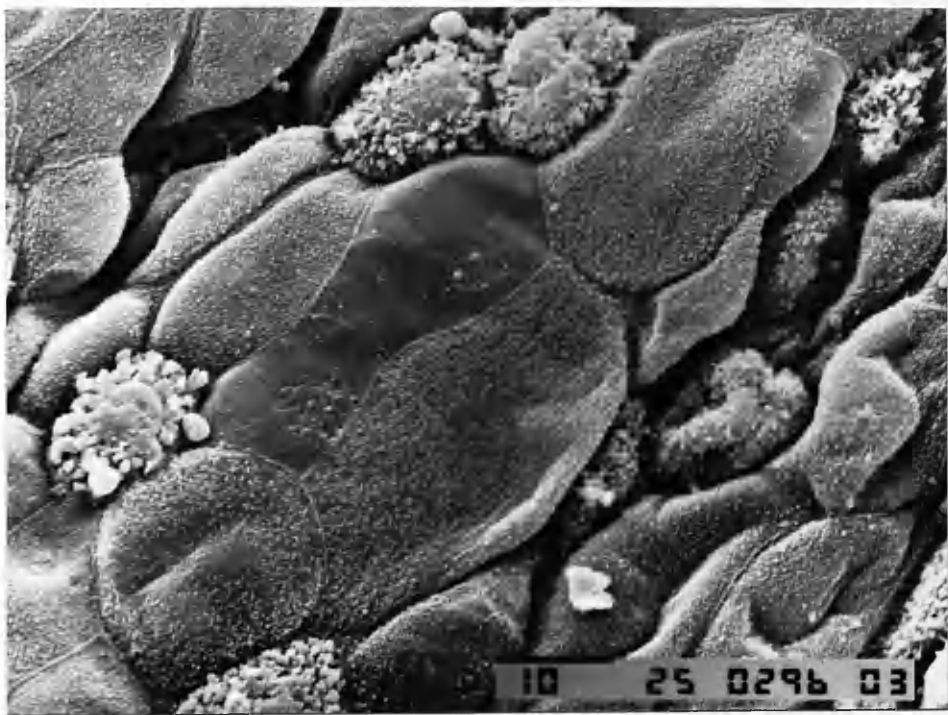


Fig.18 Drawing in Veau's book of differences between normal and cleft palate anatomy (after Veau, 1931). The normal muscular anatomy is shown on the right side of the drawing and the cleft muscle insertions on the left.

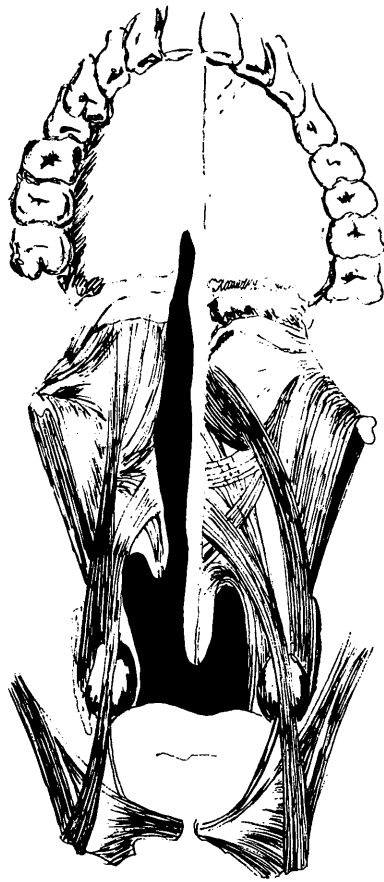

Fig.19 Anterior view of 18-week anencephalic fetus with complete right cleft lip and palate.

Fig.20 View of palate of 22-week fetus with 'median' cleft lip and bilateral cleft palate.

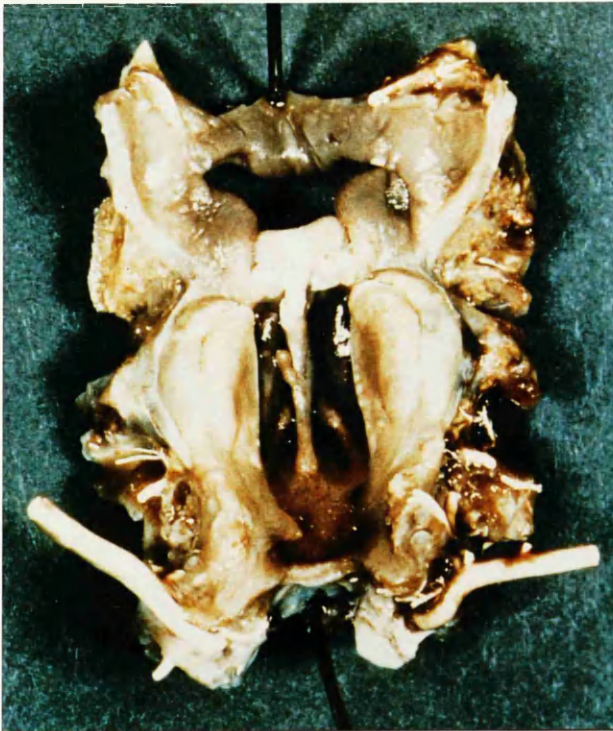
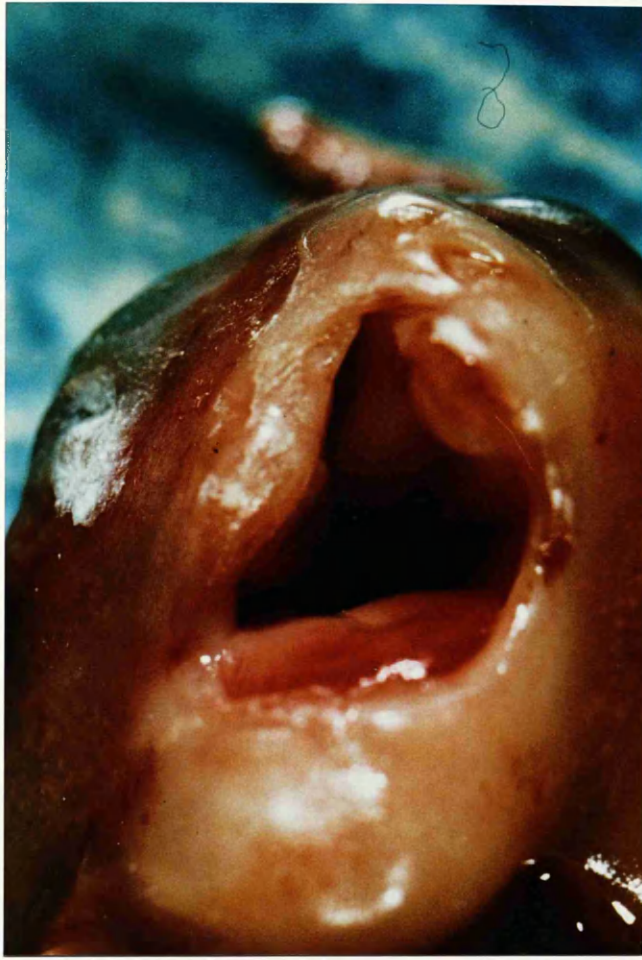

Fig. 21 Fetus of 20-weeks gestation with cleft of secondary palate.

Fig.22 No. 22 gauge Argyle Medicut trochar and cannula.

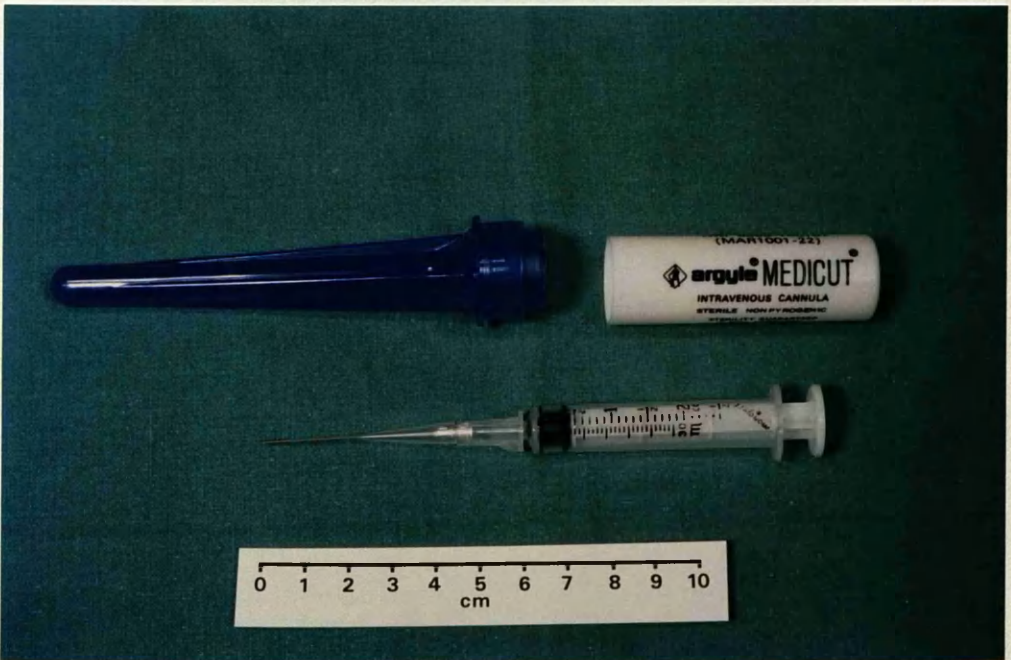
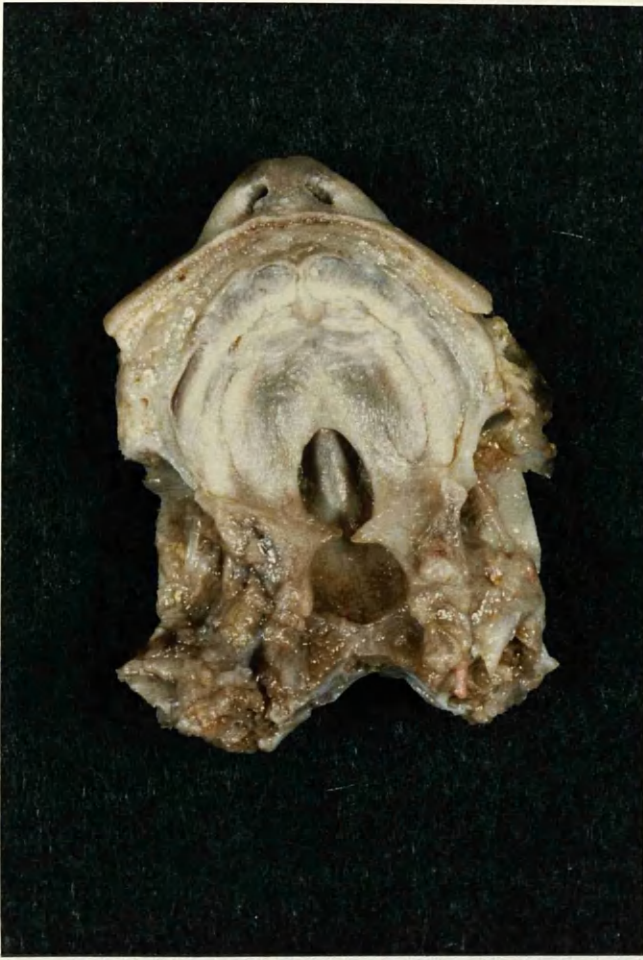

Fig.23 Lateral view of adult skull showing coronal, anterior and lateral osteotomy cuts.

Fig.24 Inner aspect of adult skull showing position of osteotomies.

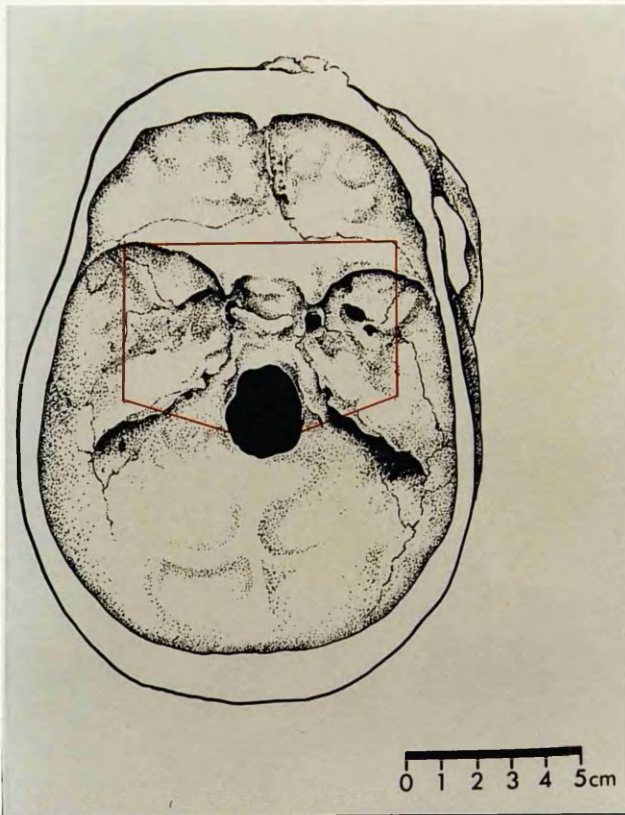
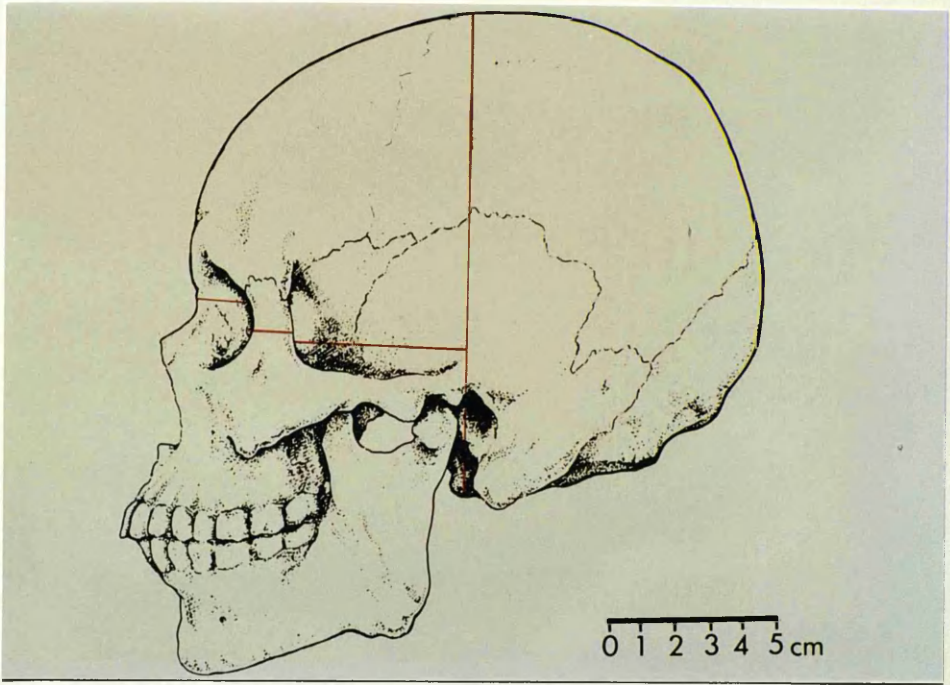


Fig.25 Wild M400 Photomakroskop dissection microscope showing camera and exposure controls.

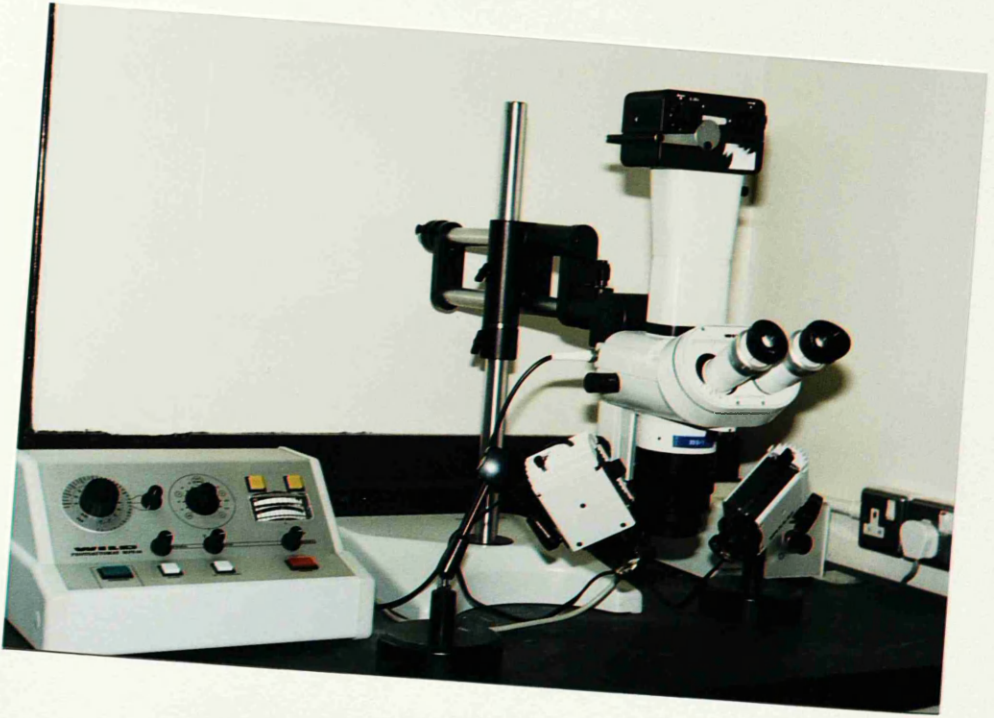

Fig.26 Posterior aspect of posterior pharyngeal wall in 26-week fetus, showing inferior thyroid vessels. Note red latex in inferior thyroid vein (arrowed) (x13).

Fig.27 Adult cadaver. Posterior pharyngeal wall with Indian ink / latex in veins in significant amounts.

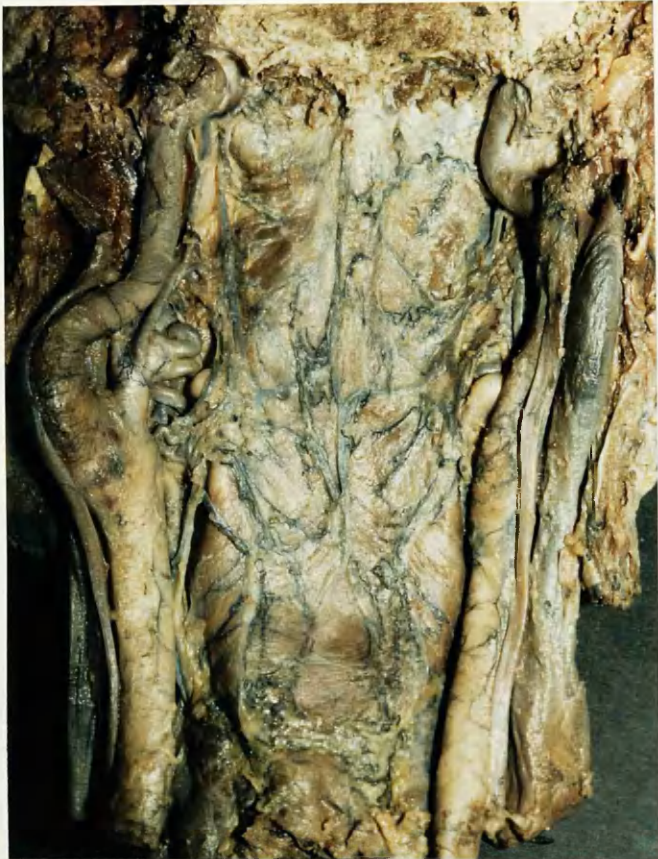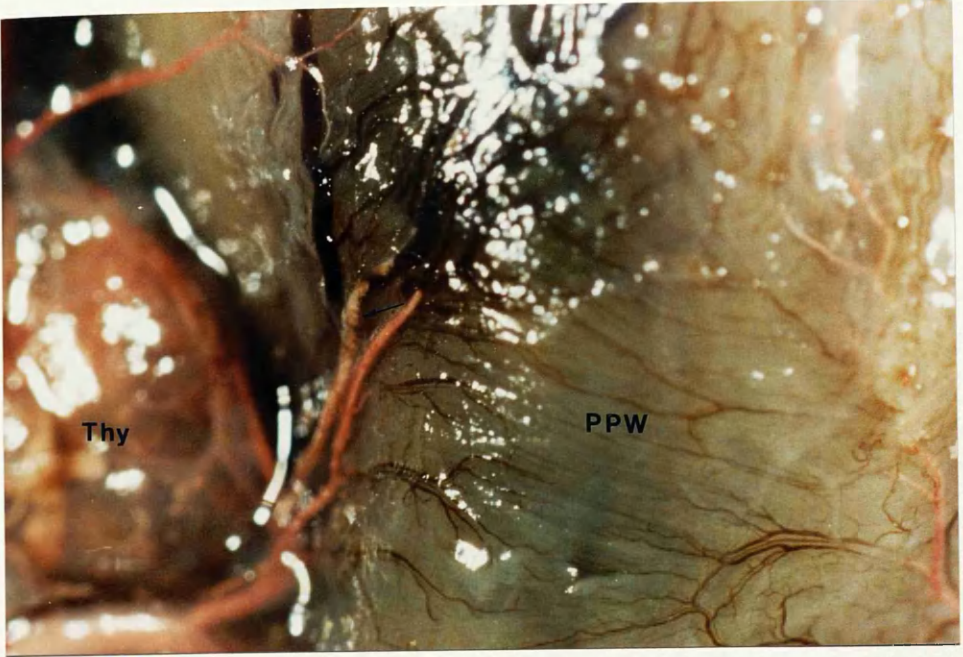


Fig.28 a Right lateral view of fetus following removal of most of horizontal ramus of mandible and pterygoid muscles. Ascending palatine artery passing lateral to styloglossus muscle. Red latex injection (x 10).

Fig. 28b Sketch of side of dissected fetal head following removal of the cranium and orbital contents (nose and lips to right) with rectangle showing area of photograph above.

Fig.28c View slightly inferior to Fig. 28a following reflection of digastric and stylohyoid muscles (x 10).

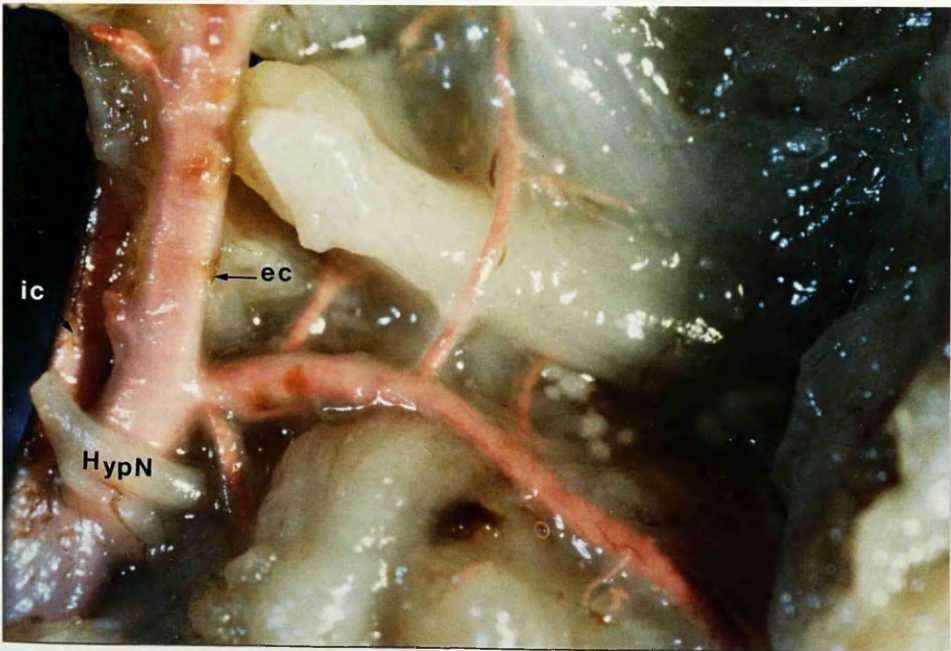
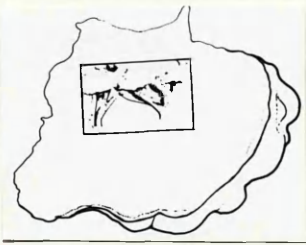
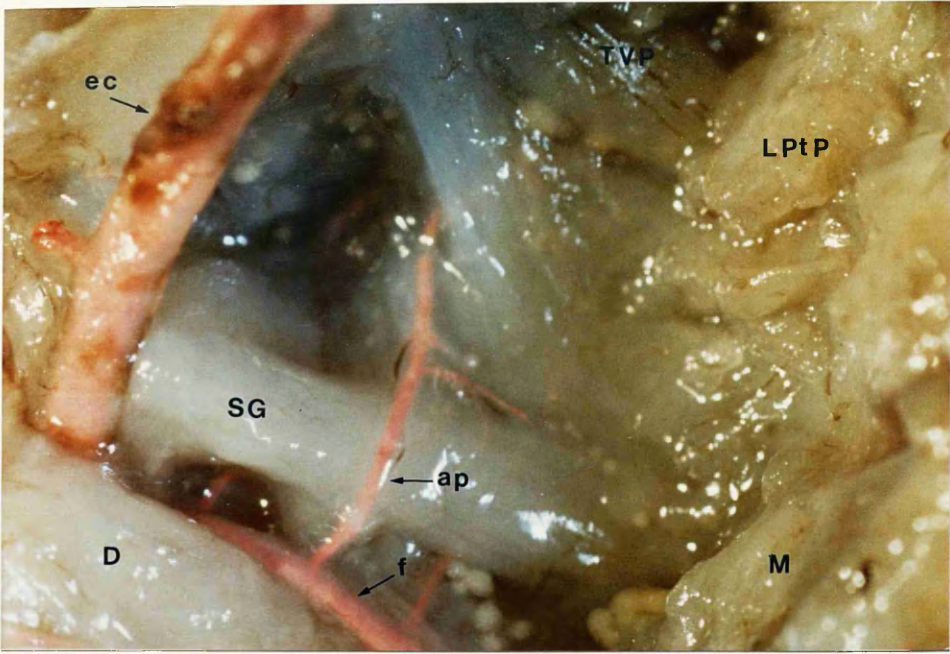


Fig.29 Right lateral view of infratemporal fossa of fetus with ascending palatine artery supplying tensor and levator veli palatini muscles. Schlesinger's medium (x 8).

Fig.30 Left lateral view of fetus with ascending palatine and ascending pharyngeal arteries. The former is giving branch to tensor veli palatini. Red latex injection (x 10).

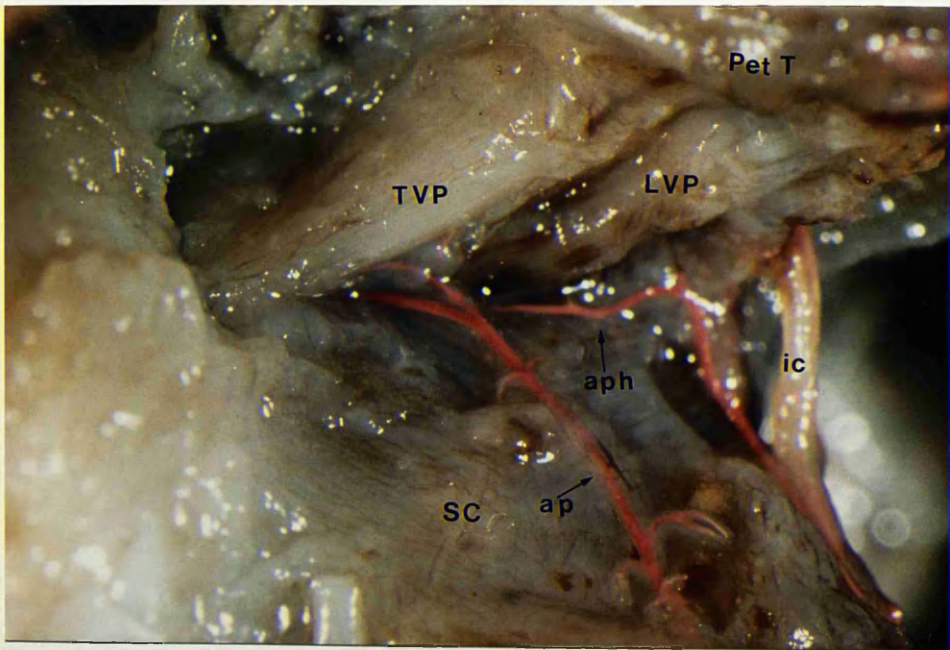
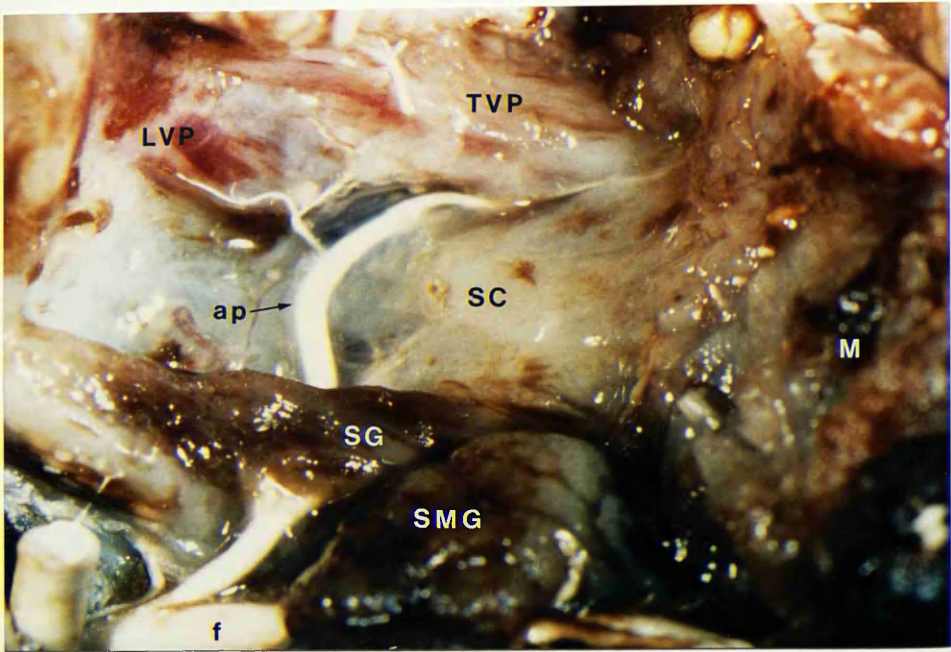


Fig.31 Left lateral view of fetus showing course of ascending palatine artery. Schlesinger's medium. (x 8).

Fig.32 Right lateral view of fetus with ascending palatine artery passing up to inferior border of tensor veli palatini muscle. Schlesinger's medium. (x8).

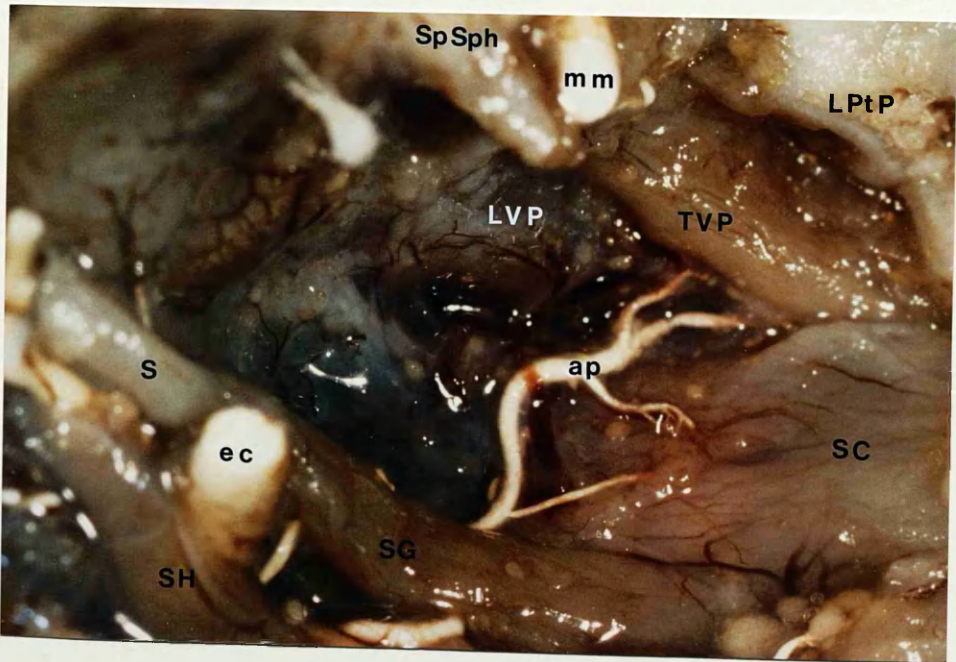
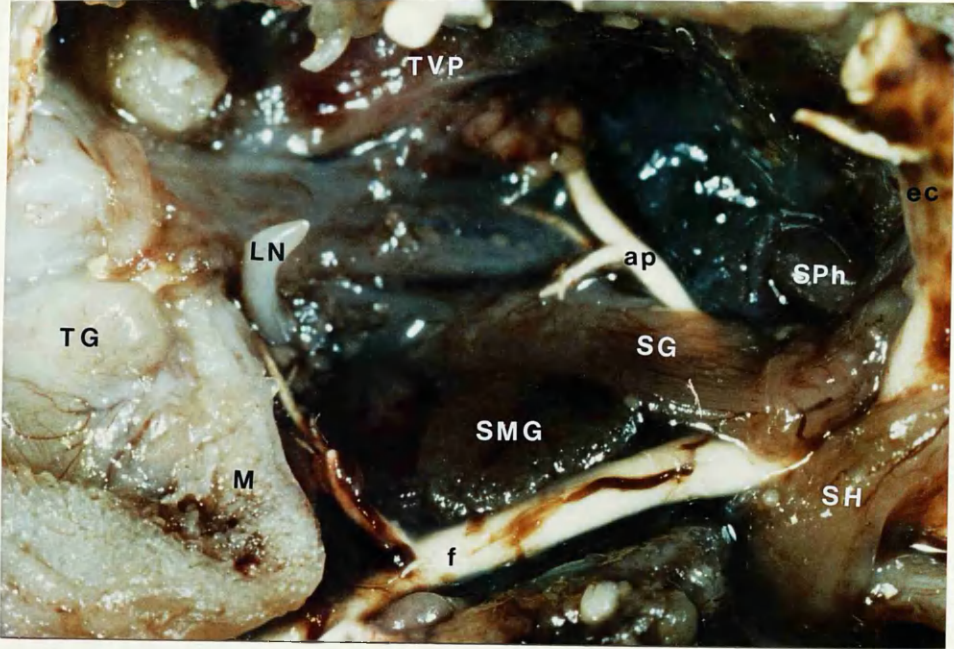


Fig.33 Right lateral view of branch ascending pharyngeal artery approaching levator veli palatini muscle and giving supply (arrow). Schlesinger's medium. (x 8).

Fig.34a Drawing of oral surface of fetal palate with rectangle outlining approximate area of photograph in Fig. 34b.

Fig.34b Inferior view of left extrapalatal muscles same fetus as Fig.33 showing branches ascending pharyngeal supplying levator (x 13).

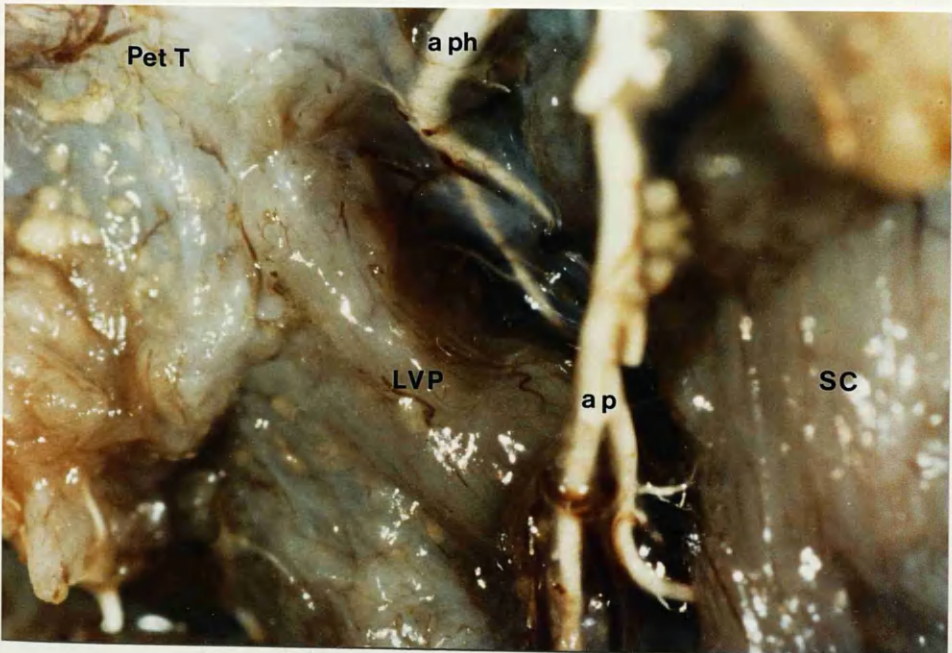
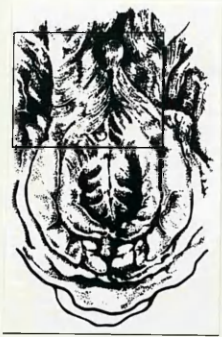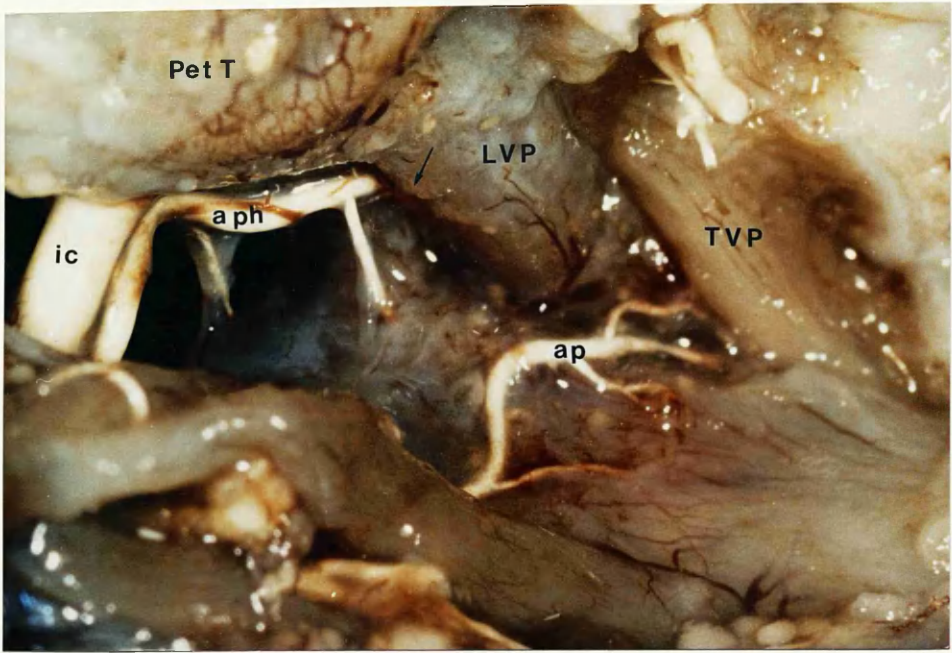


Fig.35 Left lateral view of fetus following removal lateral pterygoid plate showing branch of accessory meningeal artery sending twigs into tensor veli palatini (short arrows). Red latex injection (x 8).

Fig.36 Right lateral view of same specimen as Fig.35 showing twigs from branch accessory meningeal artery on lateral surface of tensor (x 13).

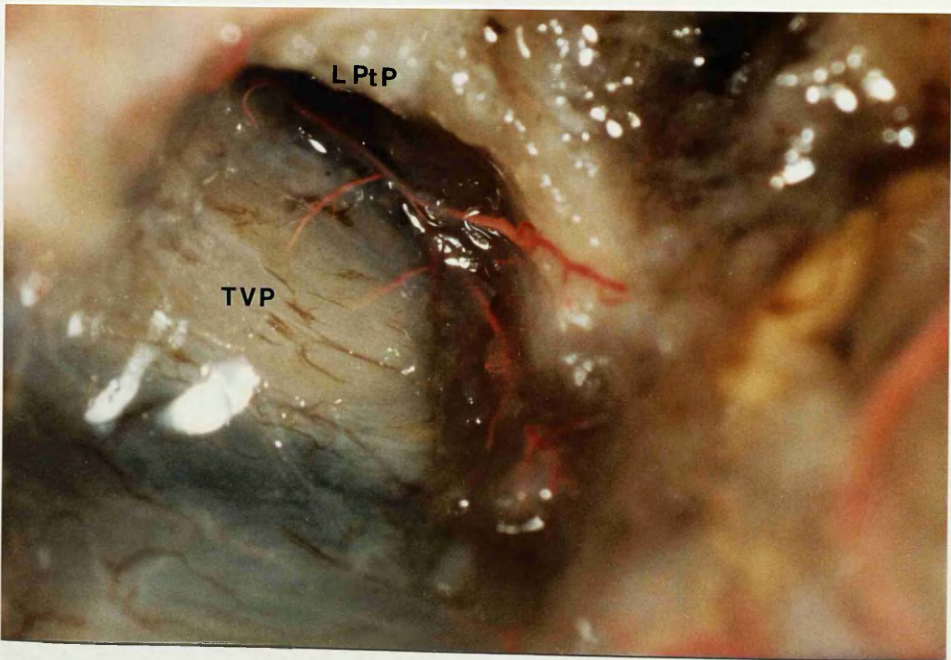
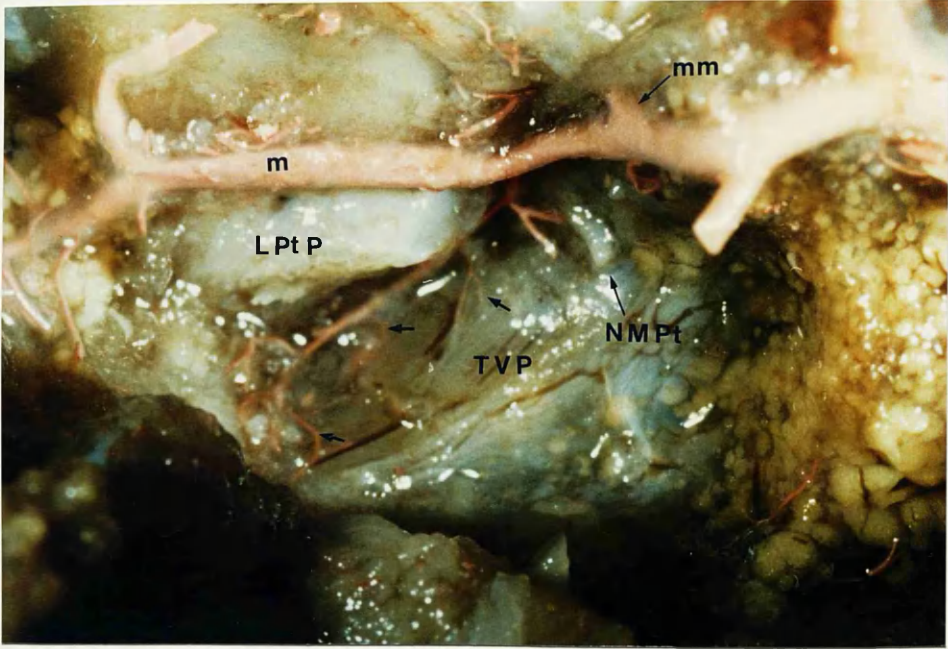


Fig.37 Right lateral view showing anastomosis (small arrow) between ascending pharyngeal and accessory meningeal arteries. Red latex injection. (x8).

Fig.38a An inferior view showing branches of ascending palatine (unfilled), ascending pharyngeal, and accessory meningeal arteries in relationship to tensor and levator muscles. Schlesinger's medium (x 8).

Fig. 38b Drawing of oral surface of fetal palate with area of adjacent photograph outlined.

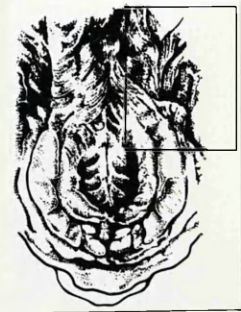
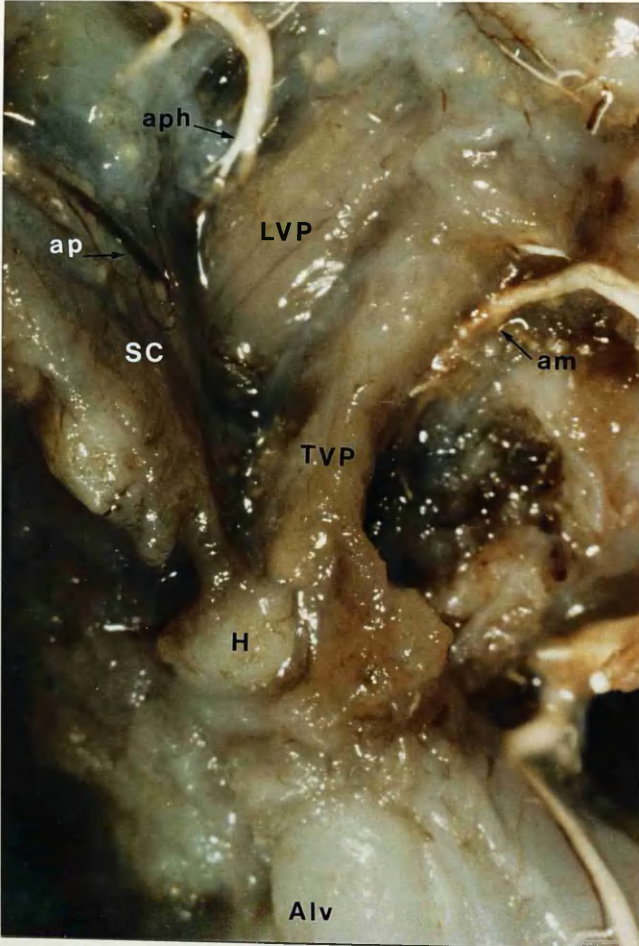
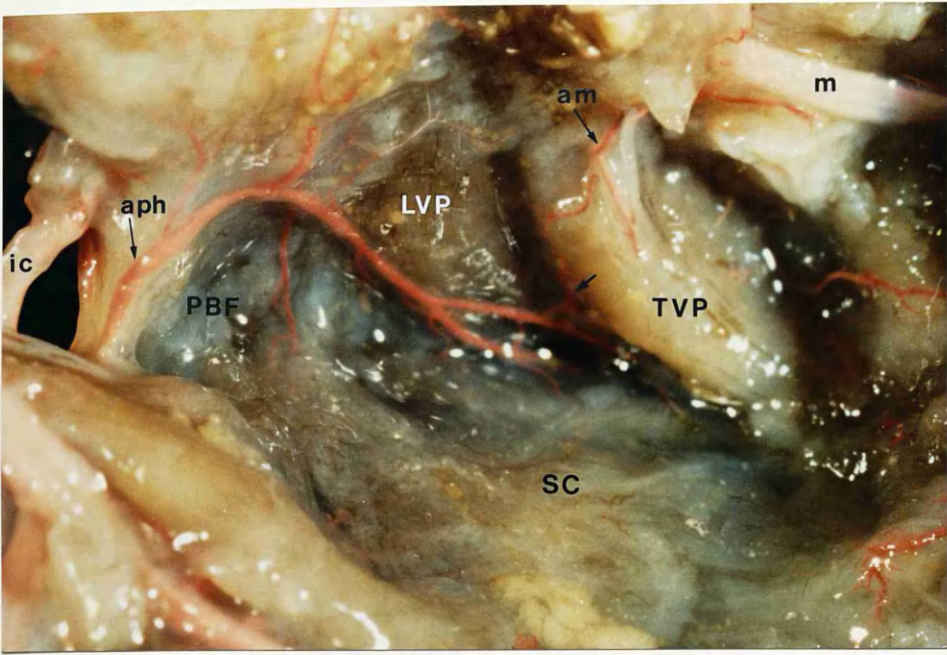


Fig.39 Left lateral view of infratemporal fossa of adult cadaver. Indian ink/ latex injection. Note tortuosity of ascending palatine artery (arrowed)

Fig.40 Left lateral view of adult cadaver. Red latex / blue latex injection. Note significant venous plexus on lateral surface tensor and at inferior aspect of levator.

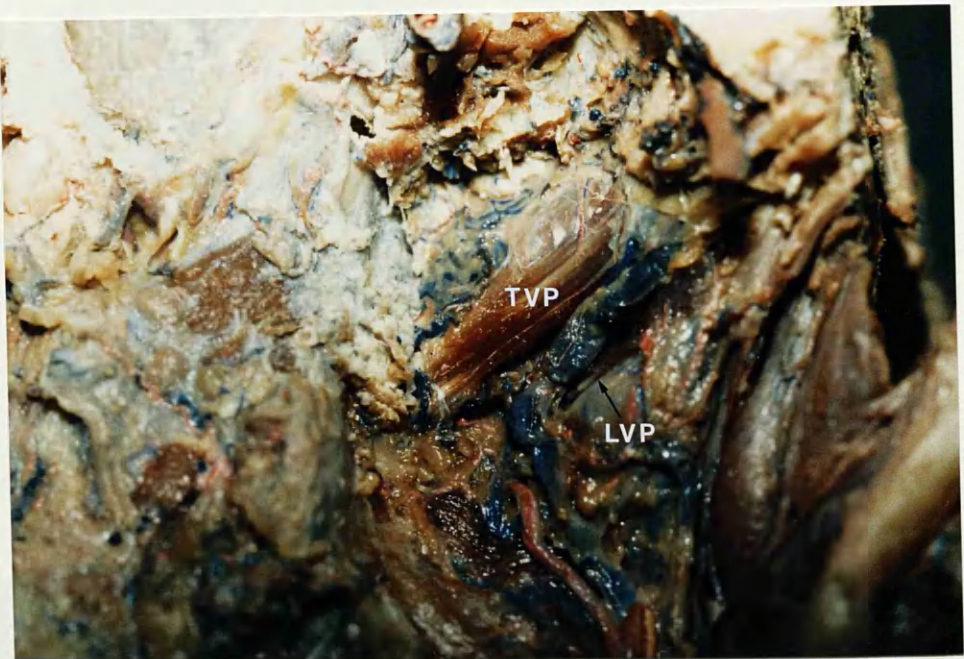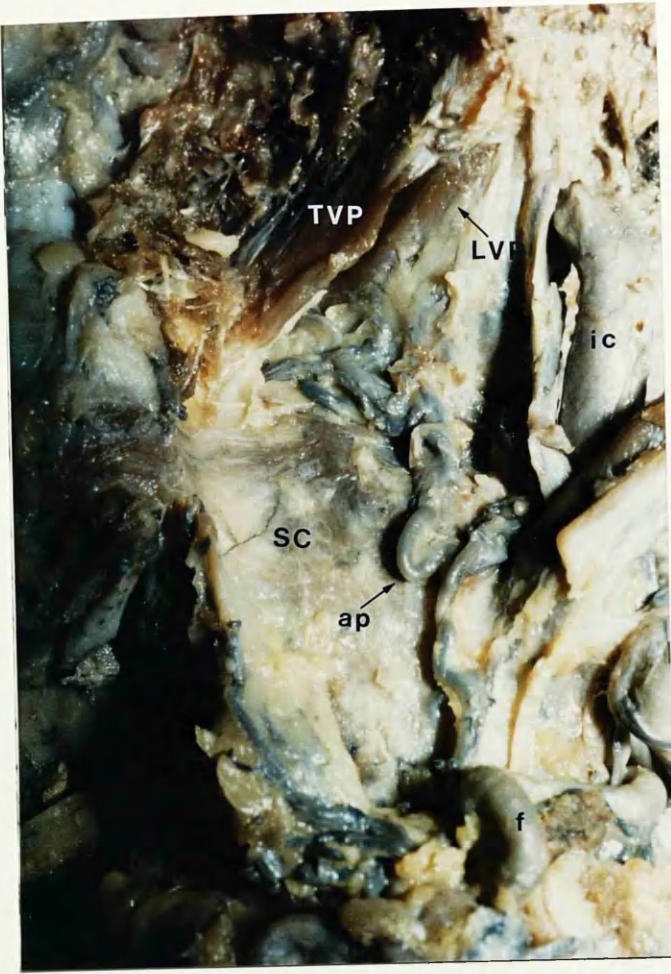


Fig.41 View of oral surface of fetal soft palate. Note arterial branch (arrowed) from ascending palatine artery passing through palatopharyngeus muscle into mucosa (x 8).

Fig.42 Oral view of fetal soft palate showing network of unfilled vessels on deep aspect of mucosa and in submucosa (x 8).

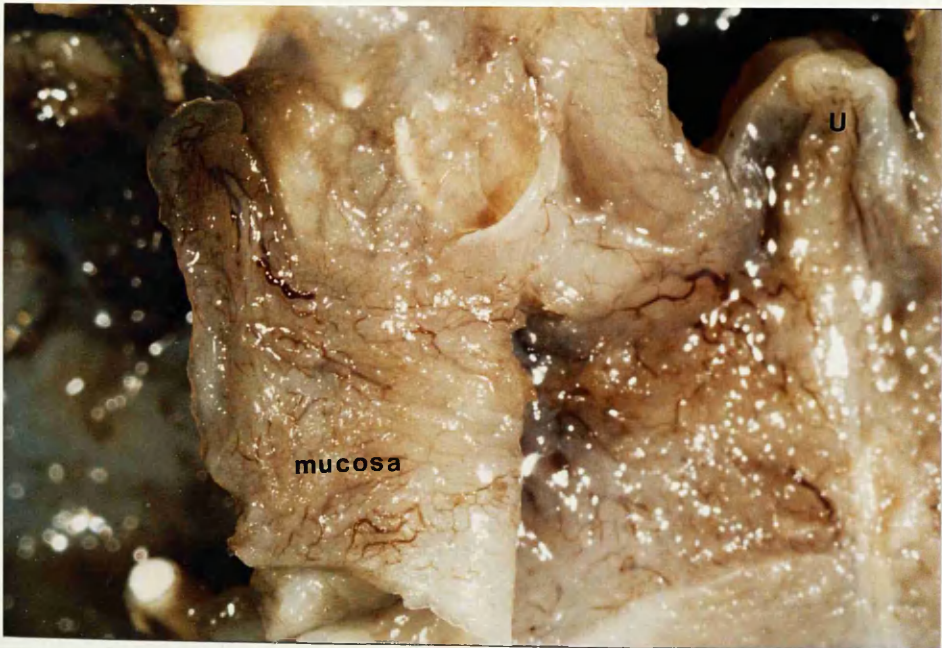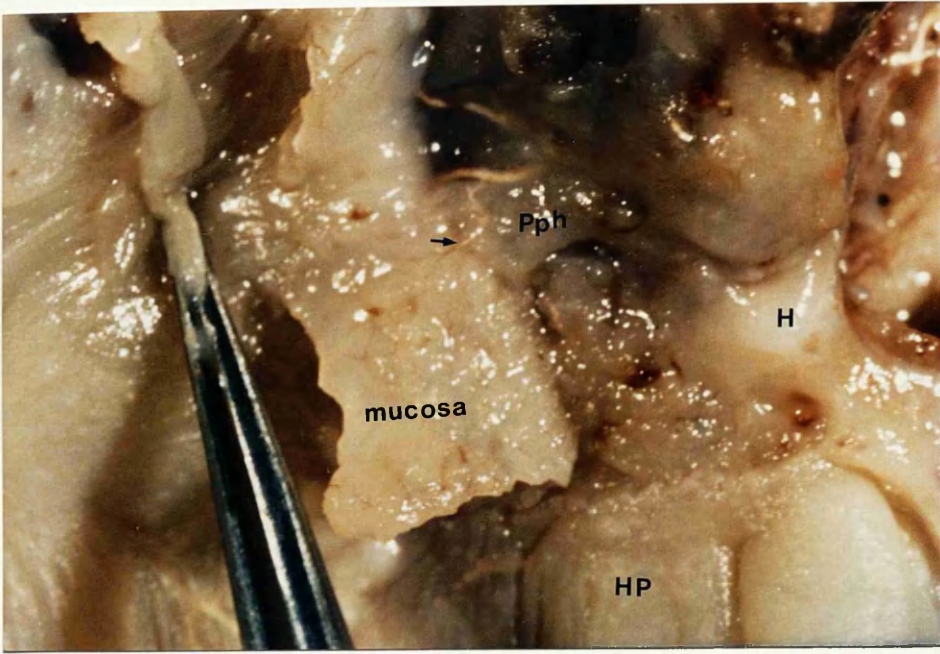


Fig.43 Oral mucosa of fetal soft palate photographed via transmitted light.
Note network of vessels absent in lower right of frame where mucosa
has been removed superficially (x 8).

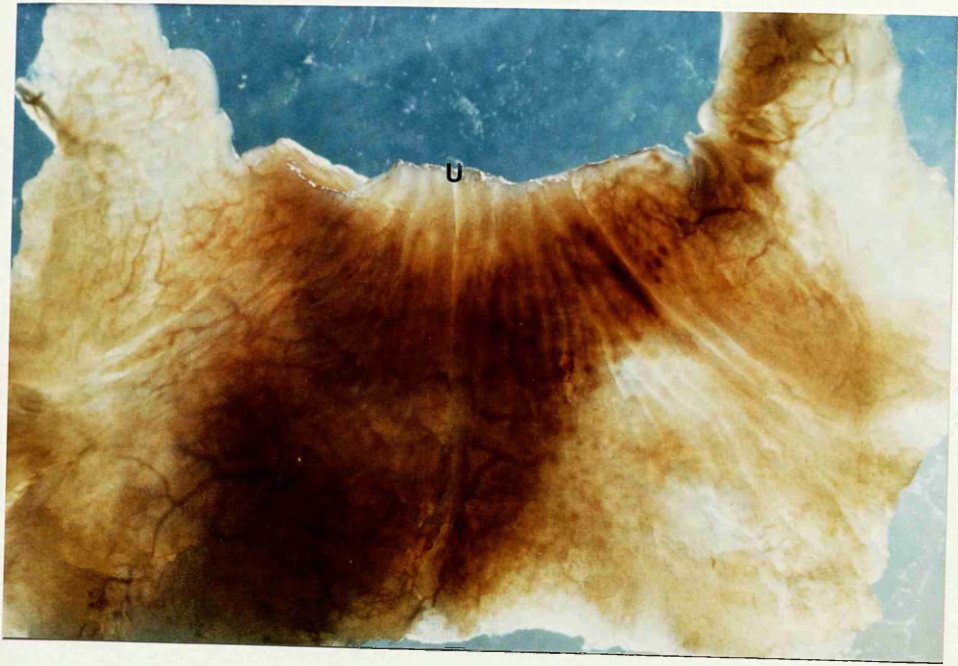


Fig.44 Oral view of fetal soft palate showing network of Microfil filled vessels on nasal mucosa (small arrow). Portion levator and aponeurosis reflected (x 8).

Fig.45 Oral view of fetal soft palate showing general course of ascending palatine artery and relationship to hamulus. Red latex (x 13).

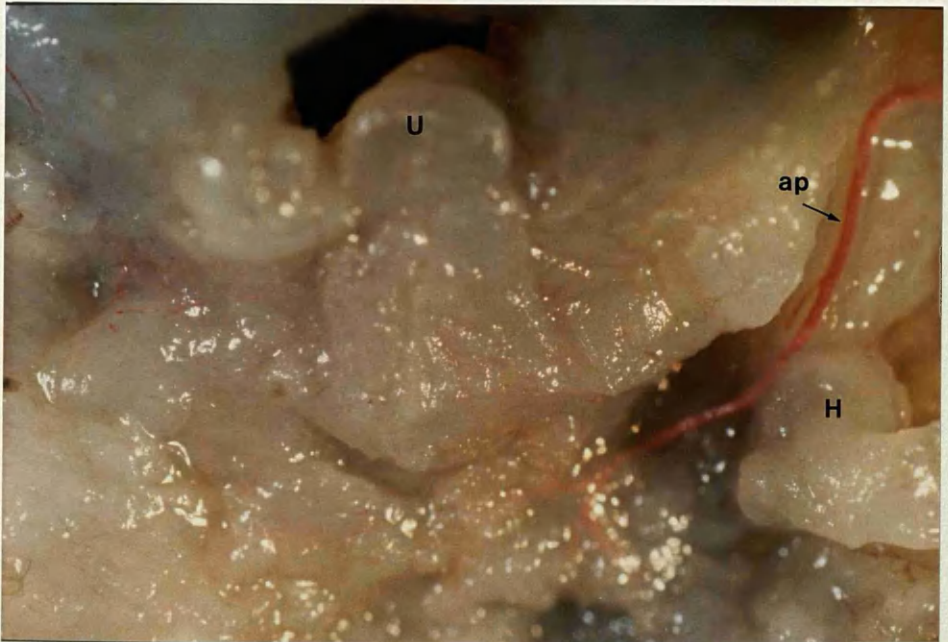
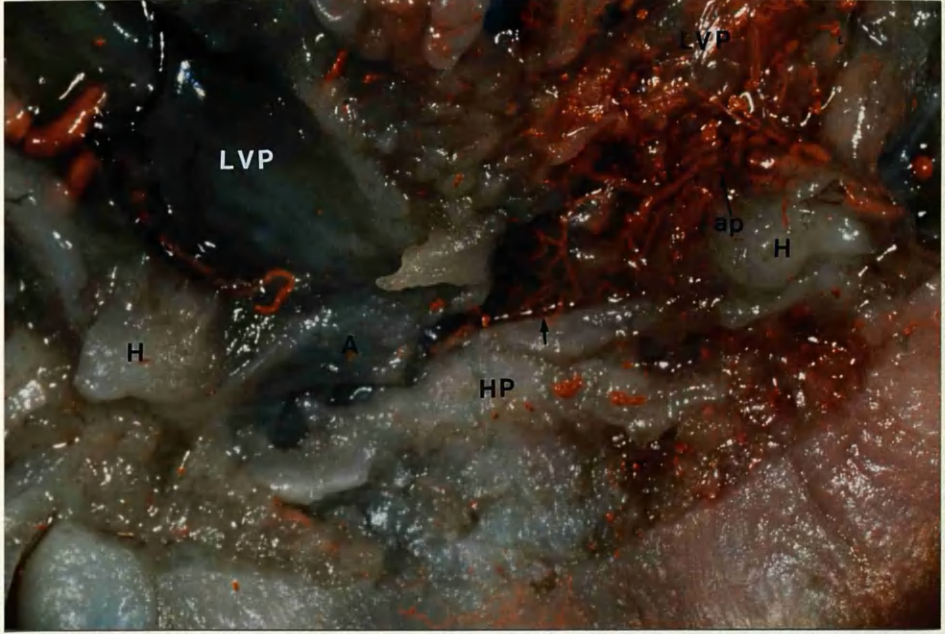


Fig.46a Oral view of fetal soft palate. Ascending palatine arteries approaching hamuli. Schlesinger's medium. (x 8).

Fig.46b Further dissection showing main terminal branches of ascending palatine artery. Palatopharyngeus muscles dissected off aponeurosis (x8).

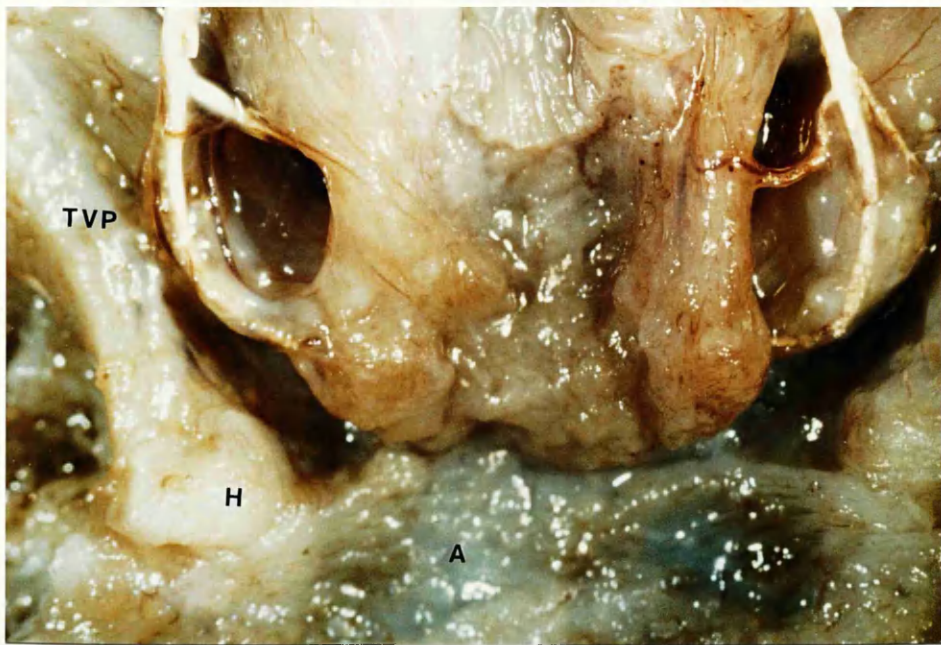
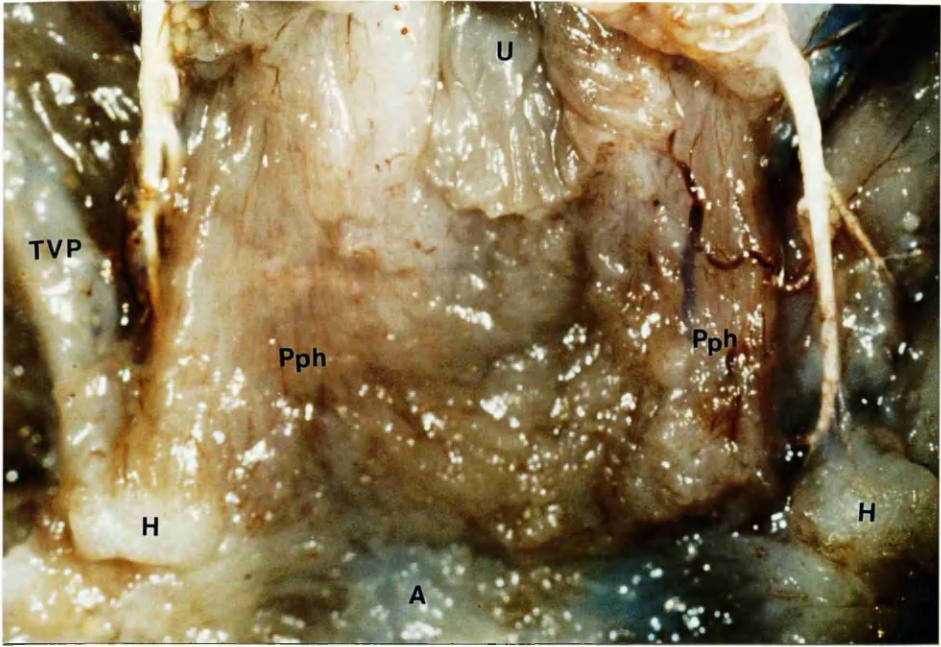


Fig.47a Ascending palatine artery entering fetal palate and dividing into terminal branches. Schlesinger's medium (x 8).

Fig.47b Drawing showing area of photographs.

Fig.47c Further dissection showing how ascending palatine branch passes superficial to levator (x 8).

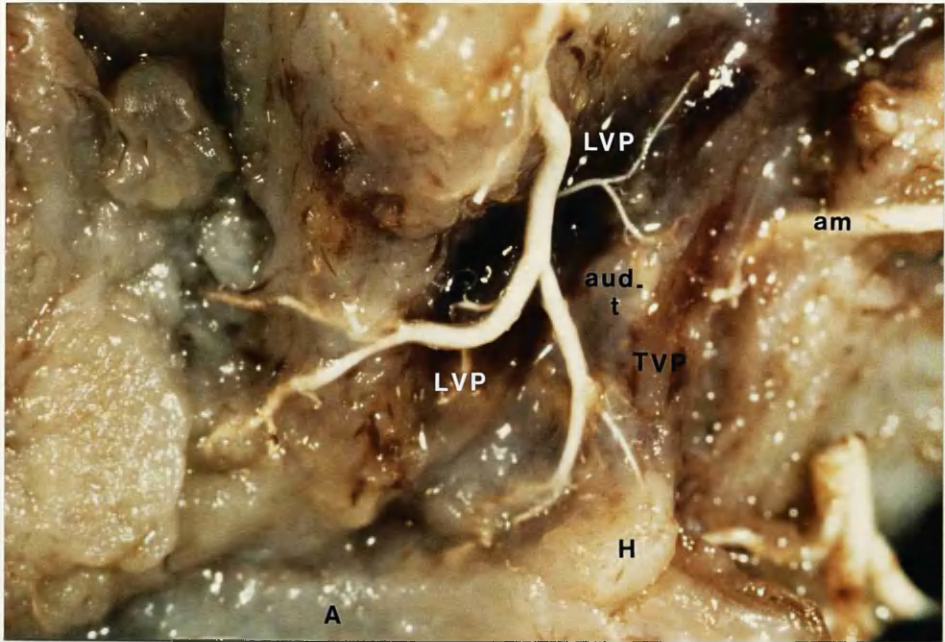
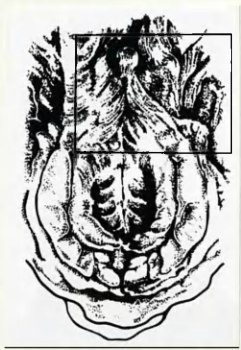
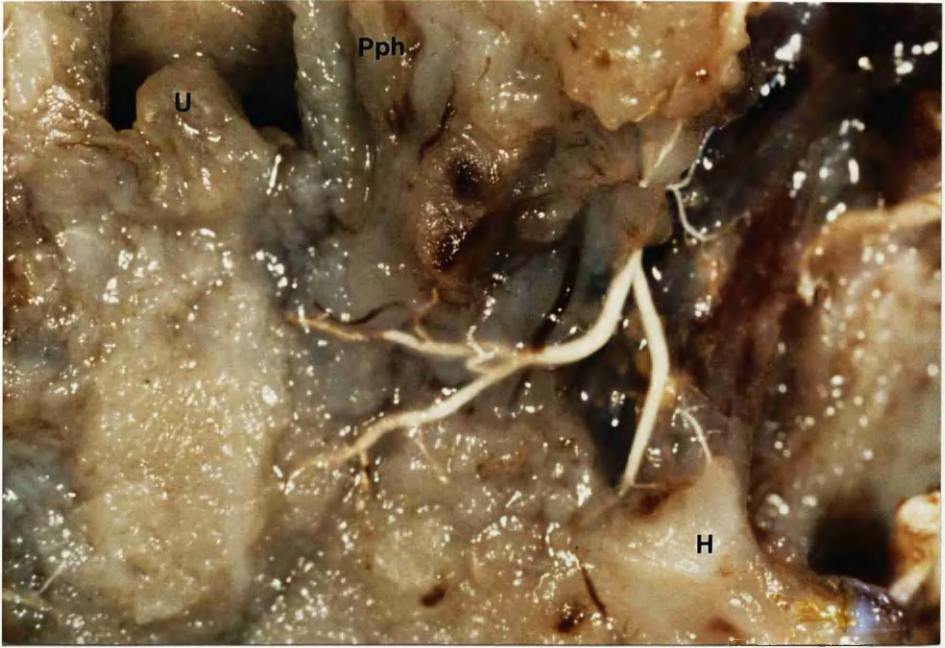

Fig.47d Scale (Biemer microvascular clamp) showing anterior branch of ascending palatine artery passing within 1mm of hamulus (x 8).

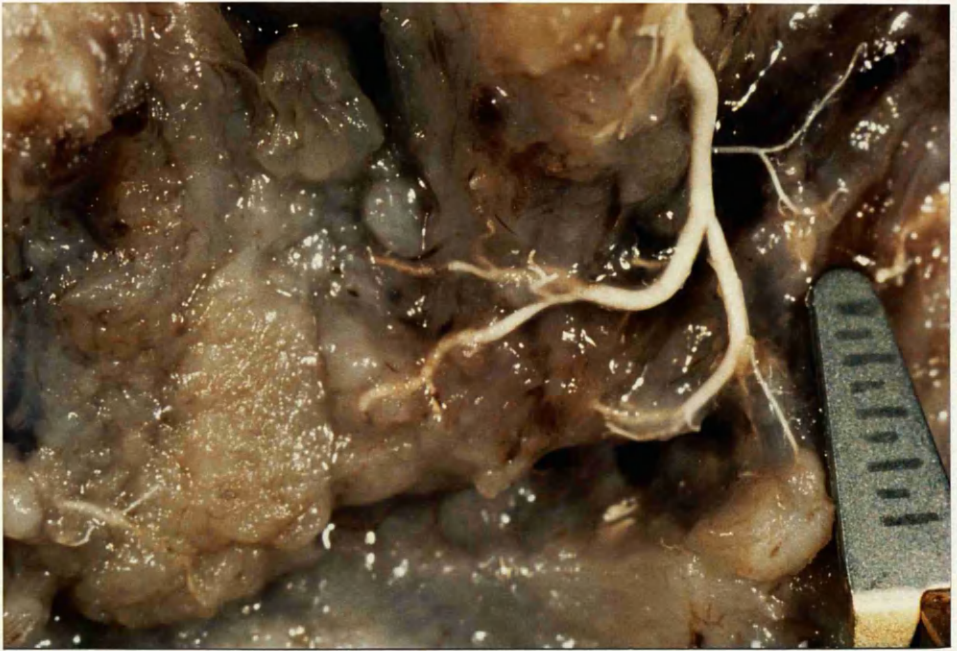

Fig.48 a Oral surface of fetal palate. Lateral pharyngeal wall retracted medially revealing ascending palatine artery approaching hamulus. Note venae comitantes. Schlesinger's medium (x 8).

Fig.48b Drawing showing area of photograph outlined.

Fig.48c Palatopharyngeus muscle dissected off aponeurosis (x 8).

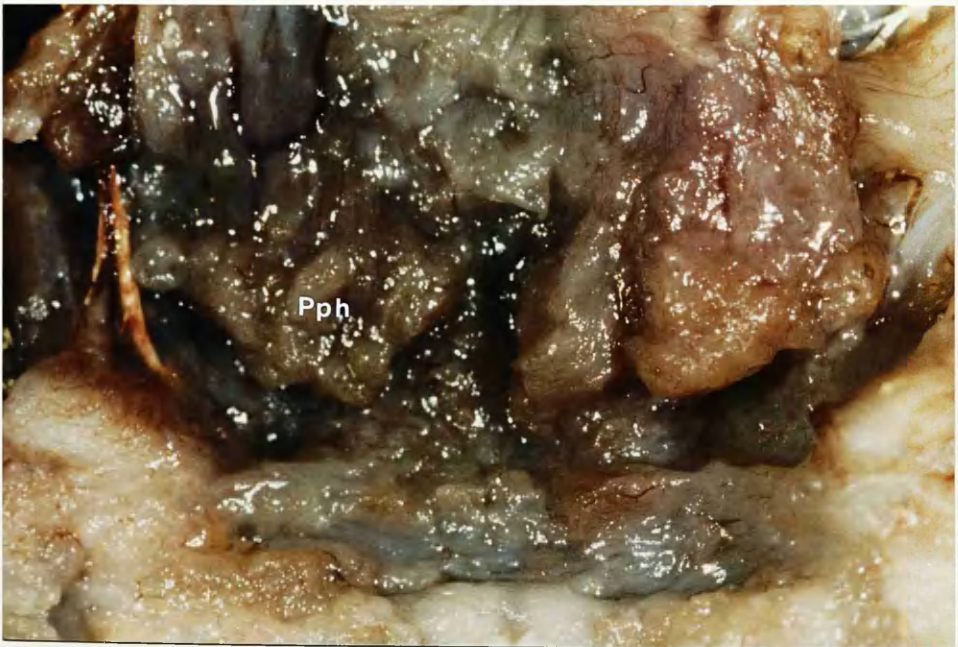
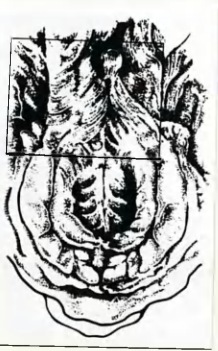
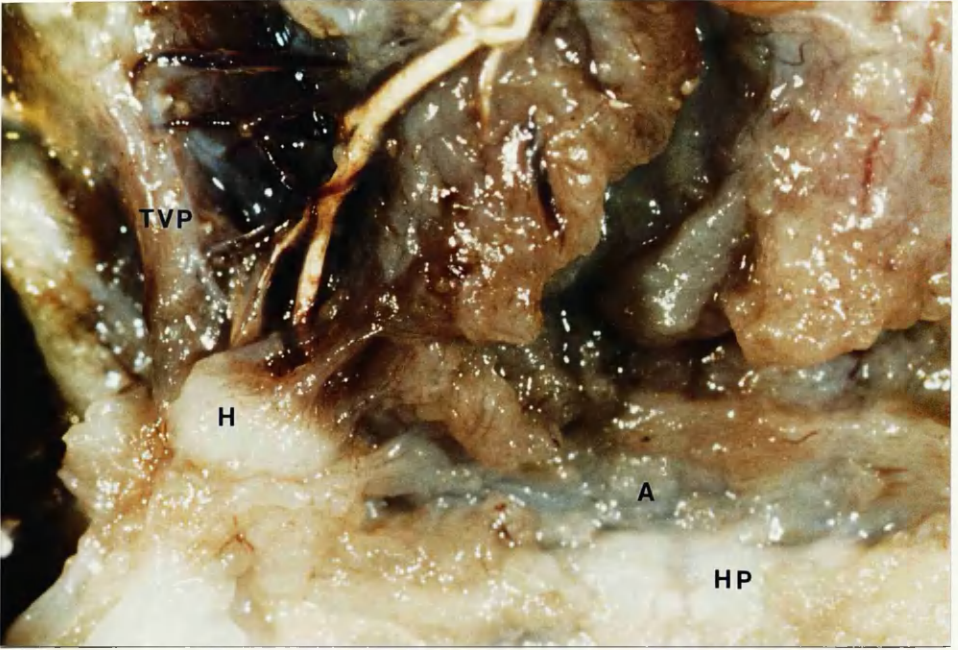


Fig.48 d Further dissection with palatopharyngeus and levator muscles reflected posteriorly. Note posterior terminal branch of ascending palatine artery passing through levator muscle (arrow) (x 8).

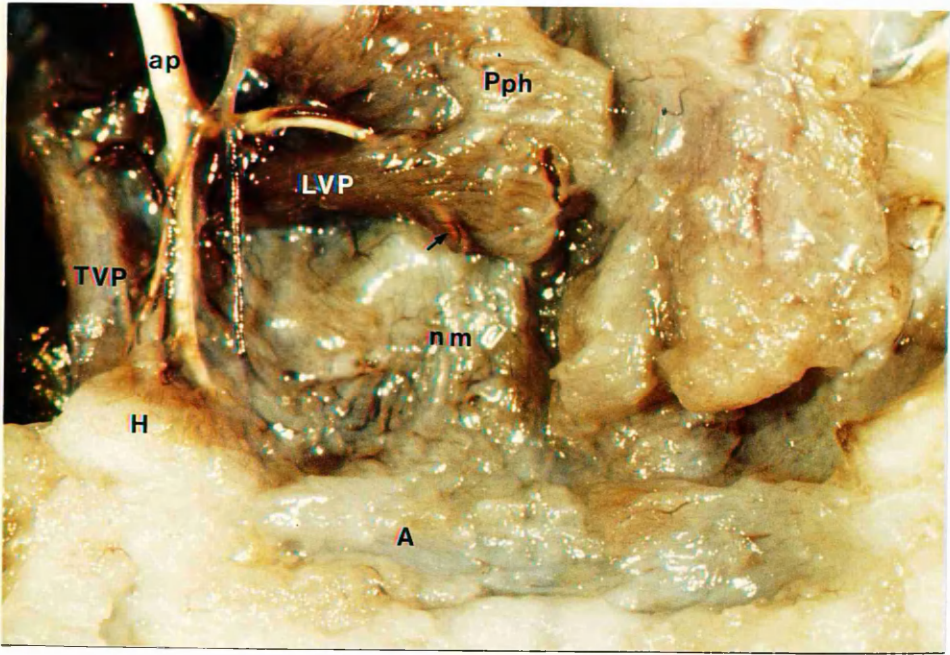


Fig.49 a Oral surface of palate of 25-week fetus. Schlesinger's medium (x 8).

Fig. 49b Drawing showing area of photographs outlined.

Fig.49c Superior constrictor muscle removed and palatopharyngeus reflected posteriorly (x 8).

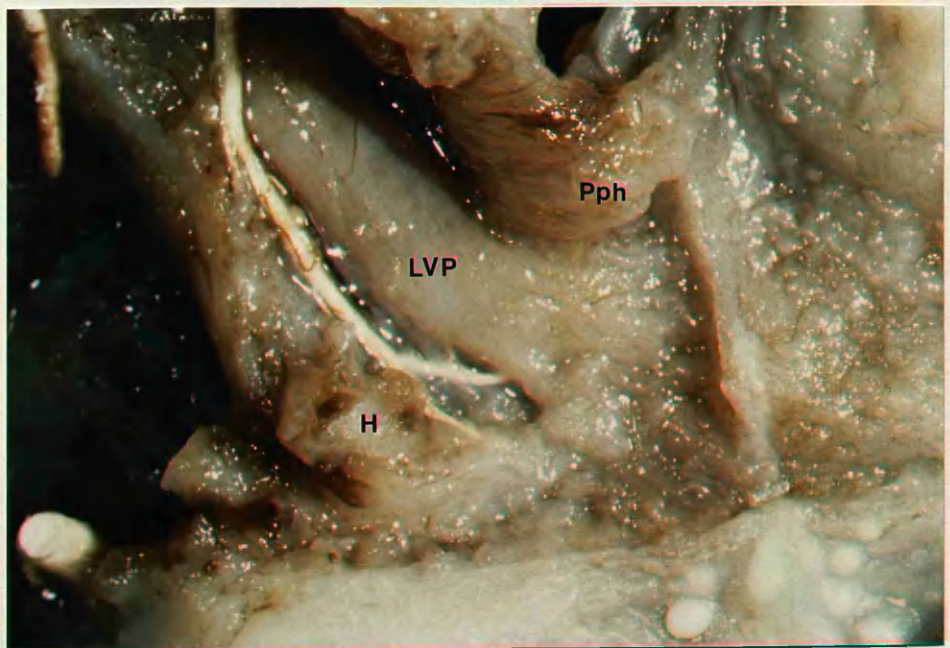
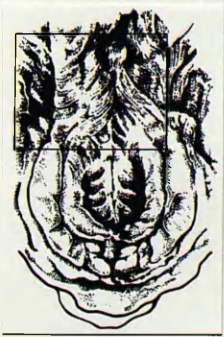
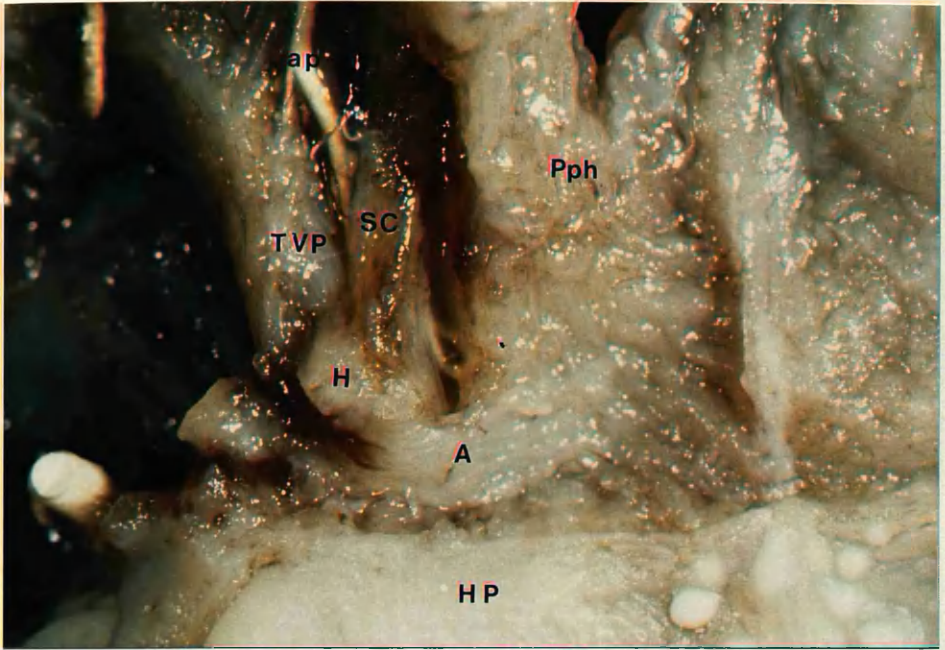


Fig.49d Levator detached from insertion on aponeurosis. Ascending palatine artery passing deep to levator (x 8).

Fig.49e Further dissection. Unfilled ascending palatine artery reaches musculus uvulae (x 8).

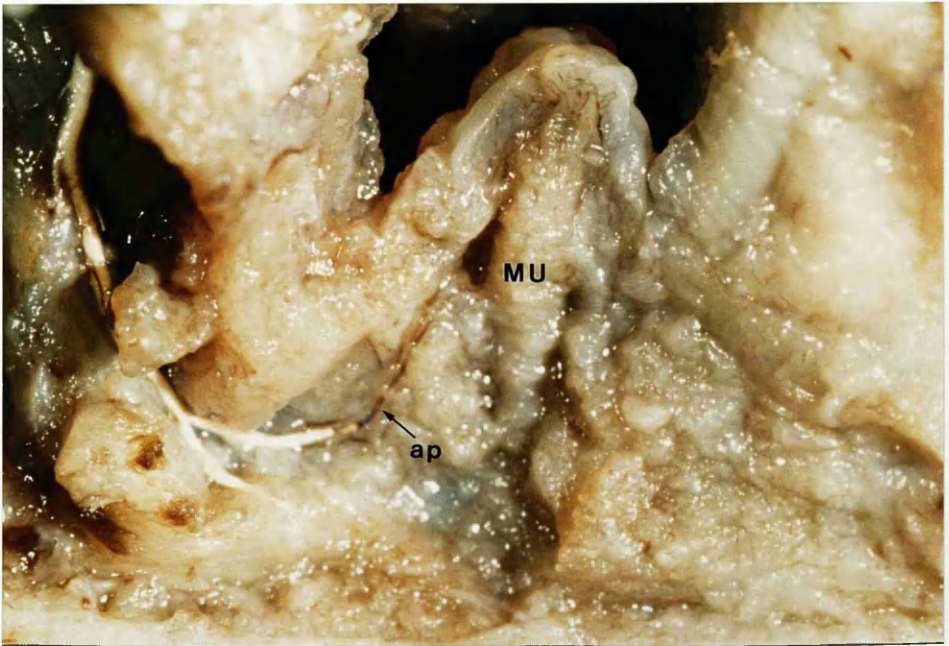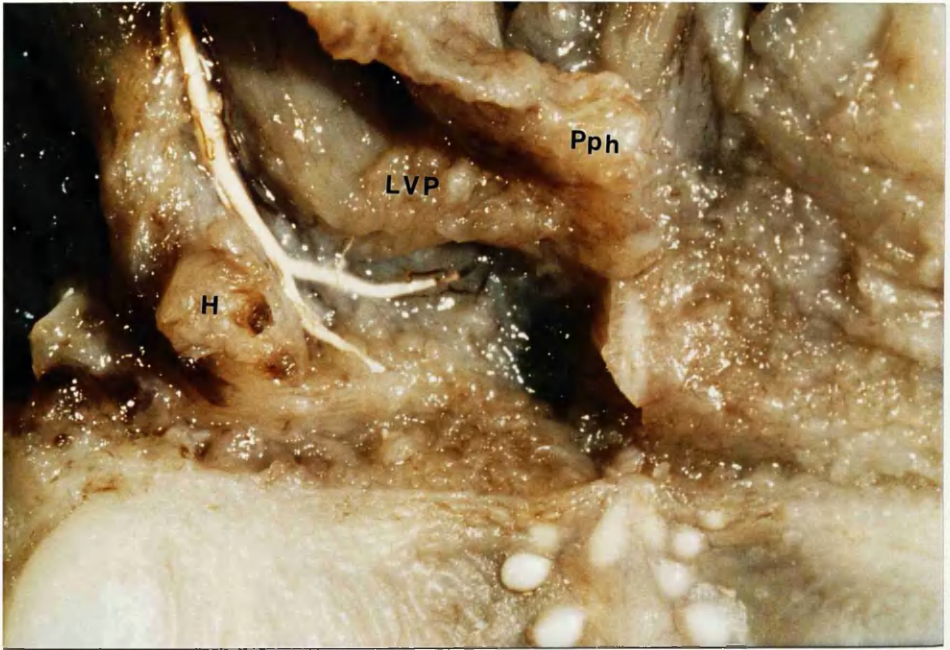


Fig.50 Cleared specimen of fixed adult cadaver. Indian ink / latex injection. Oral surface of soft palate showing rich vascular network. Note numerous vessels crossing midline.

Fig.51 Oral view of adult palate. Indian ink / latex injection. Portion left levator muscle reflected posteriorly to show ascending palatine artery and venae comitantes passing through levator towards musculus uvulae (x 8).

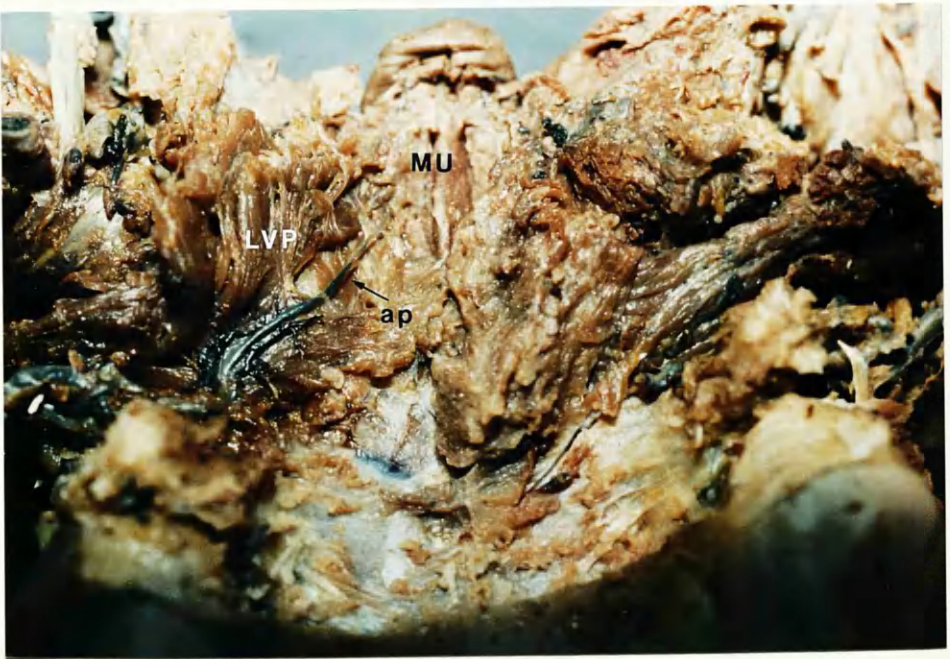
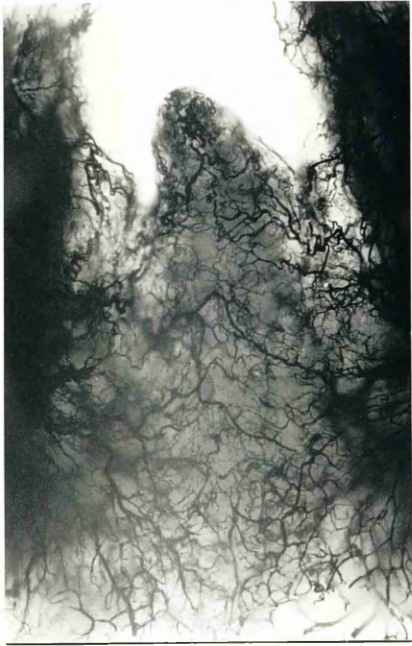
Fig.52 **Adult cadaver. Indian ink / latex injection. Ascending palatine artery supplying levator as passes through it (x 8).**

Fig.53 **X-ray fresh adult soft palate. Ascending palatine arteries injected with Schlesinger's medium. On right, vessel passes through levator as it approaches midline. (Extravasation of medium from contralateral vessel).**

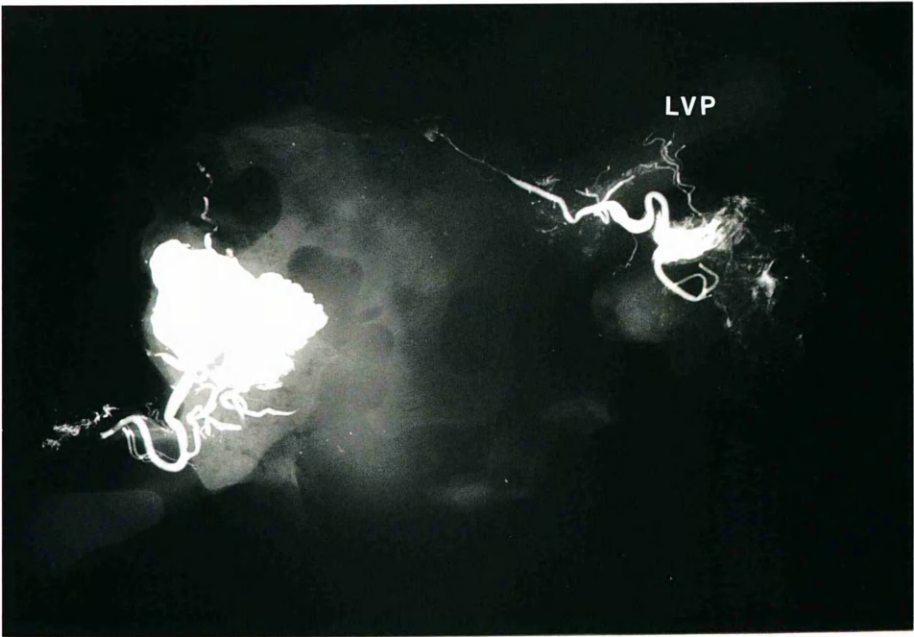
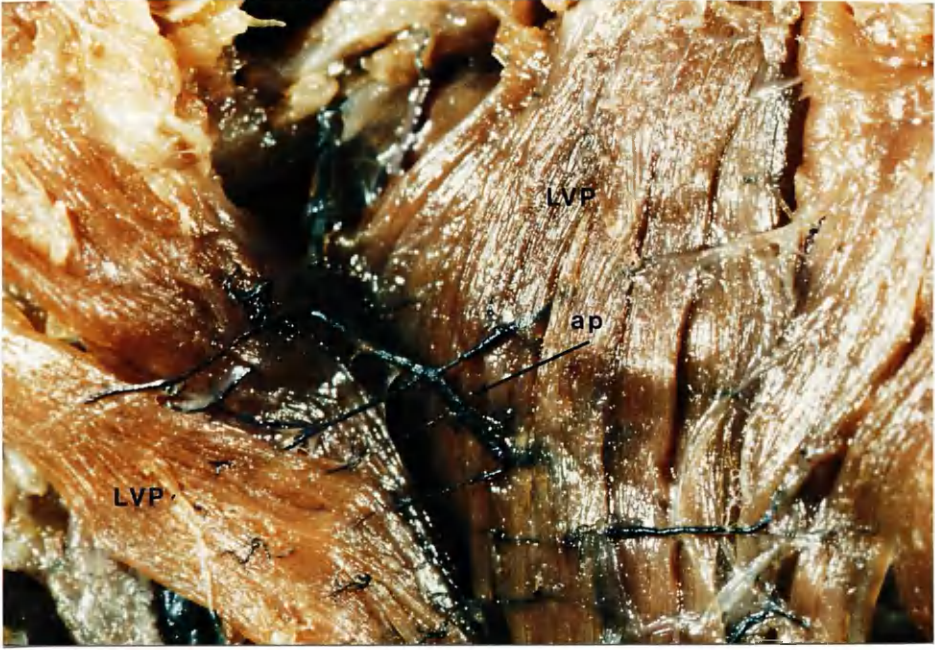

Fig.54 Palate, palatopharyngeal arches of fixed adult cadaver injected with latex / Micropaque. X-ray showing right ascending palatine artery (arrowed) passing medially and posteriorly to reach uvula.

Fig.55 Cleared adult soft palate. Indian ink / latex injection. Ascending palatine artery can be seen running into uvula and communicating across midline by several interconnecting loops in region of musculus uvulae muscle.

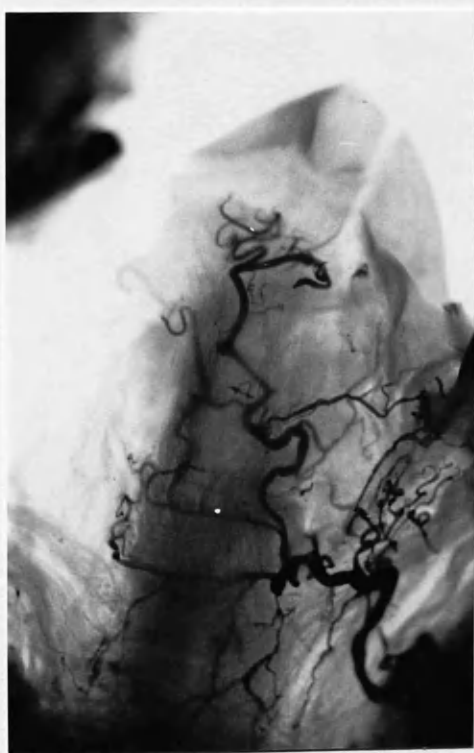
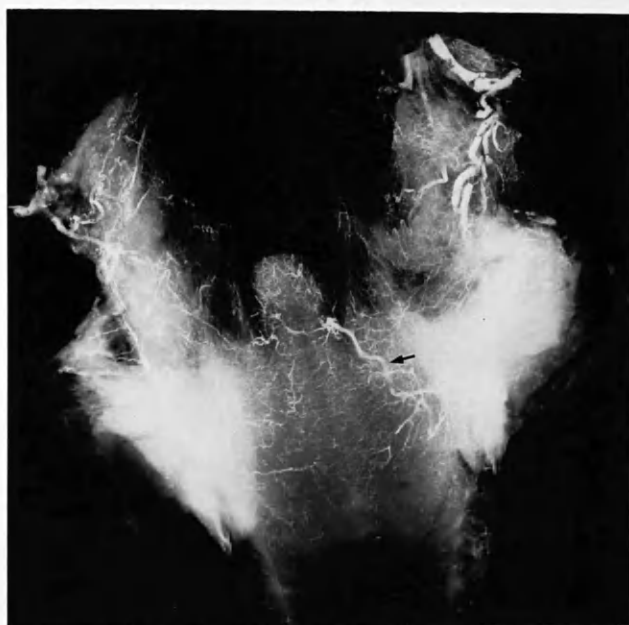

Fig.56a Left lateral view of infratemporal fossa of fetus with cleft secondary palate. Note ascending palatine vessels running between the two muscles. Red latex (x 13).

Fig. 56b Sketch of left lateral view of block of dissected fetal head. Area of photograph outlined.

Fig.57a Right lateral view of fetus with complete cleft primary and secondary palate. A branch of the accessory meningeal artery is visible passing medial to tensor. The ascending palatine artery passes into the superior constrictor muscle. Schlesinger's medium (x8).

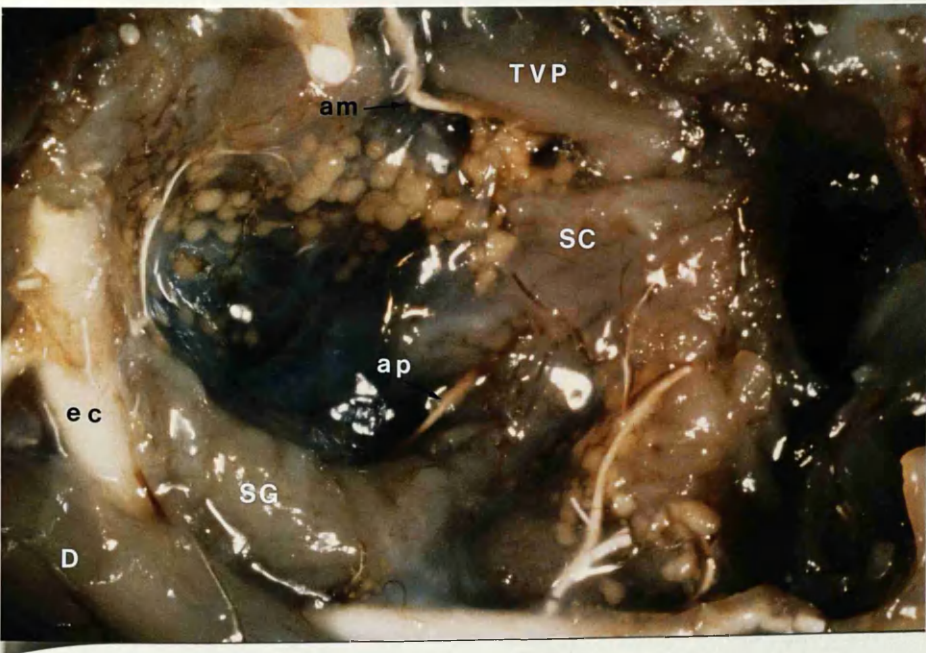
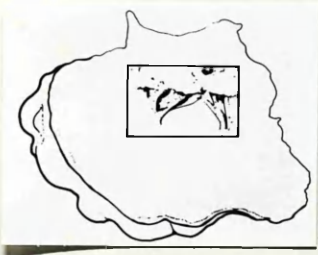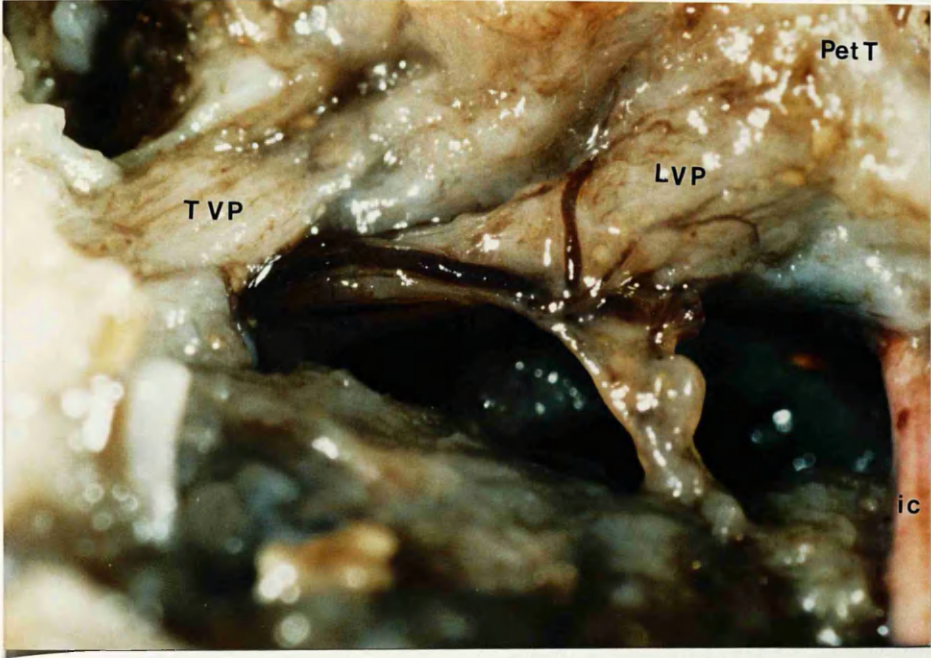
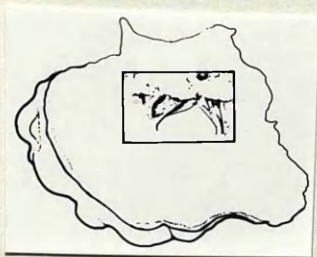
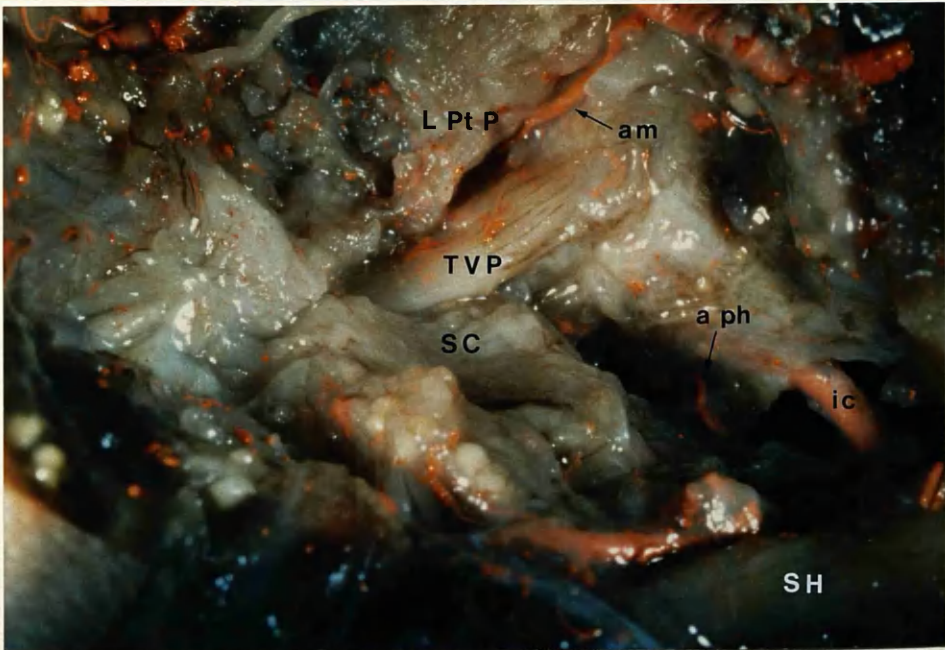
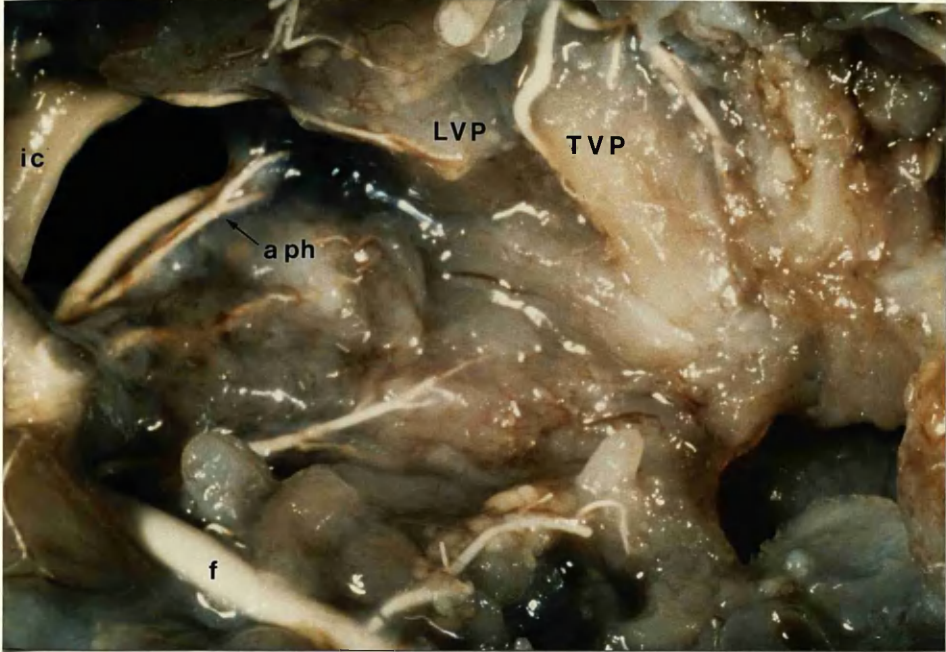


Fig.57b Further dissection showing ascending pharyngeal artery approaching levator (x 8).

Fig.58a Left lateral view of fetus with complete cleft primary and secondary palate. Microfil / blue latex injection. A branch of the accessory meningeal artery is seen on the lateral surface of the tensor (x 8).

Fig. 58b Sketch of dissected fetal head . Area of photograph outlined.



www.zoology.com

Fig.59 Oral mucosa of fetal cleft palate reflected medially revealing Microfil filled vessel (arrowed) passing up into mucosa (x 8).

Fig. 60a Montage of right side of fetal cleft palate showing relationship of palatal branches of ascending pharyngeal and accessory meningeal arteries to levator and tensor (x 8).

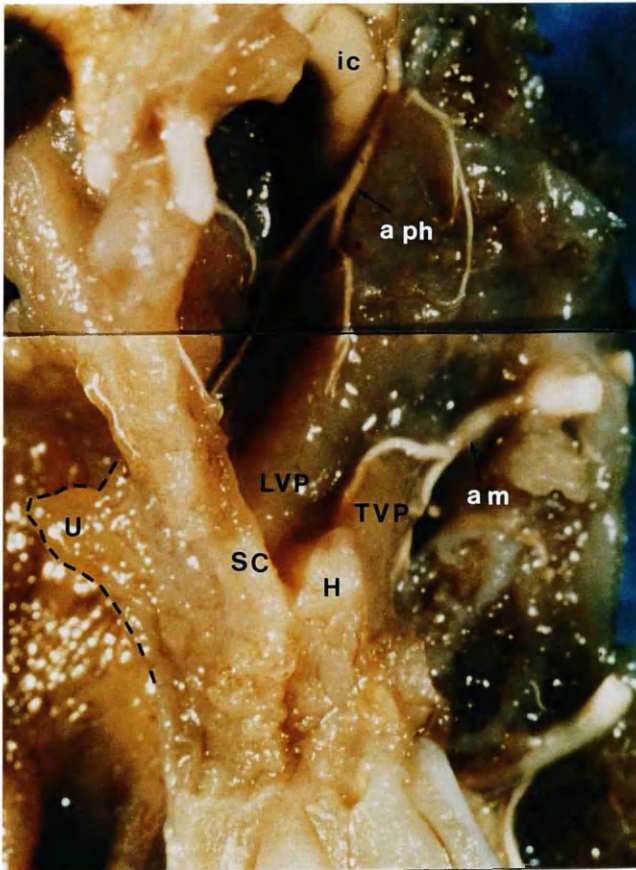
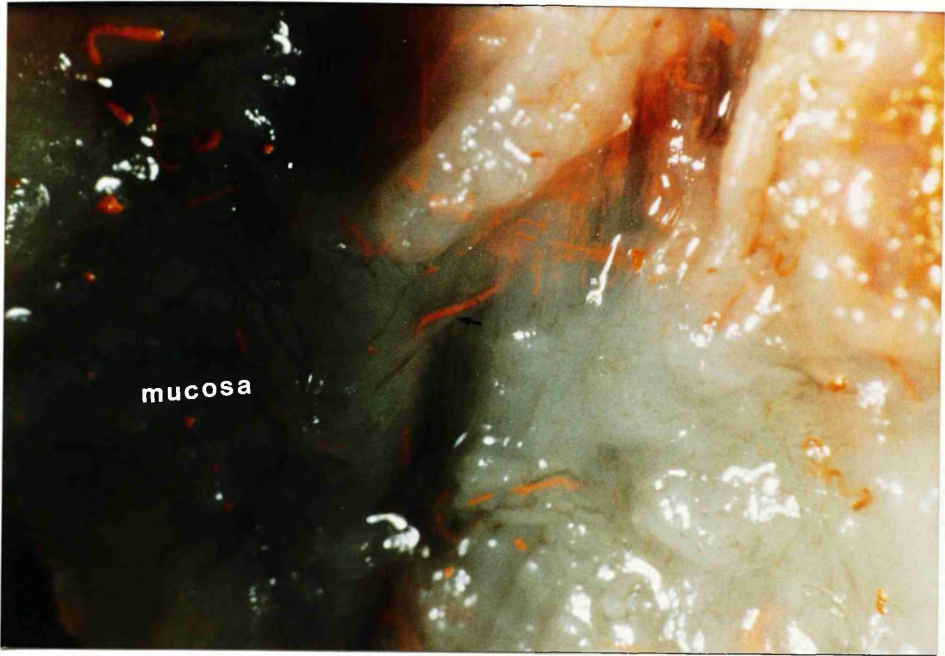


Fig. 60b Montage with intrapalatal portion levator / palatopharyngeus muscles reflected posteriorly. A branch of the accessory meningeal artery is entering levator (arrow) (x 8).

Fig. 61 Inferior view of fetal cleft palate specimen (left side) showing branches of ascending pharyngeal supplying levator. Schlesinger's medium (x8).

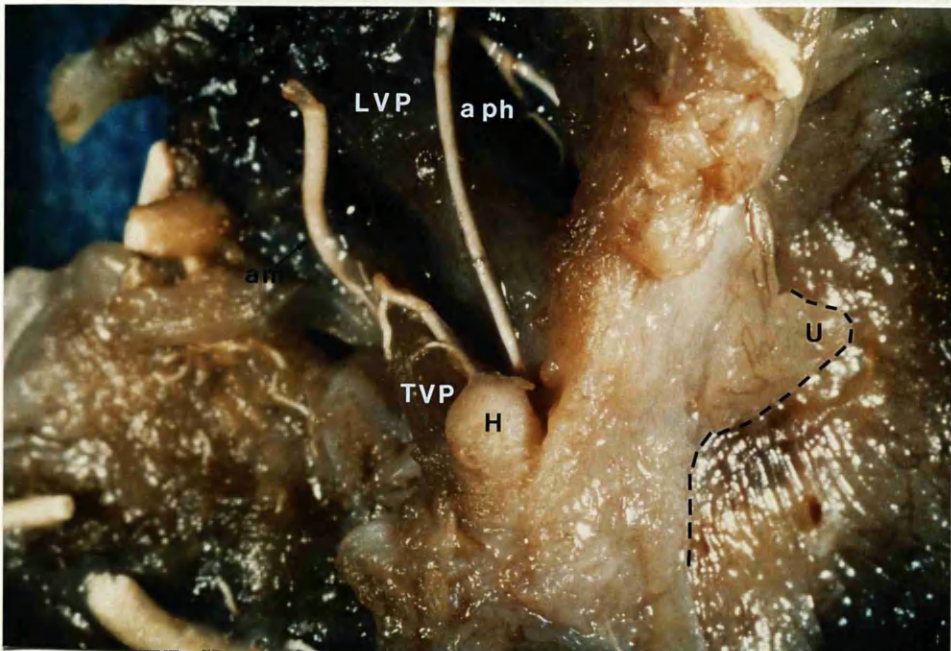
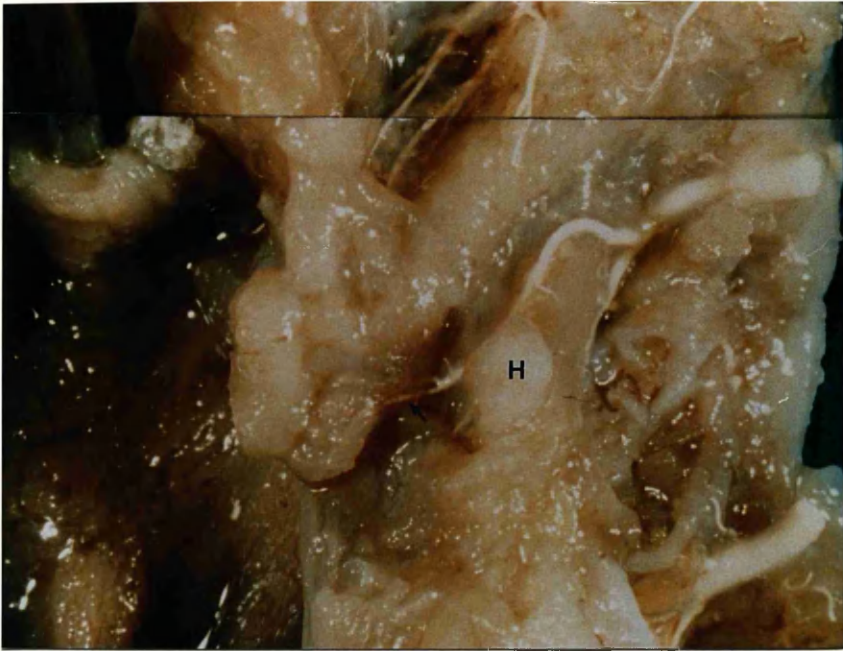

Fig. 62 Schematic drawing from dissection findings of mucosal blood supply of the soft palate. Note direct mucosal vessels and myomucosal perforating vessels.

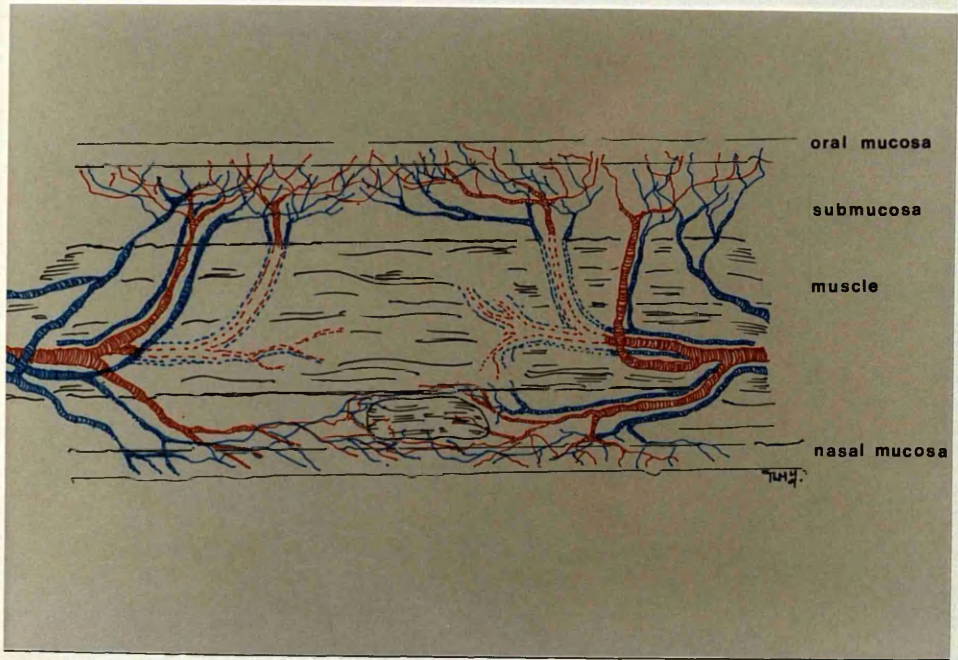


Fig.63 Coronal section of 18-week fetal head (normal palate). Ascending palatine vessels are situated between tensor and levator (Masson, x 8).

Fig.64 Coronal section of same fetus as Fig.63. Branches of accessory meningeal vessels are seen between tensor and medial pterygoid muscles. (Masson, x 8).

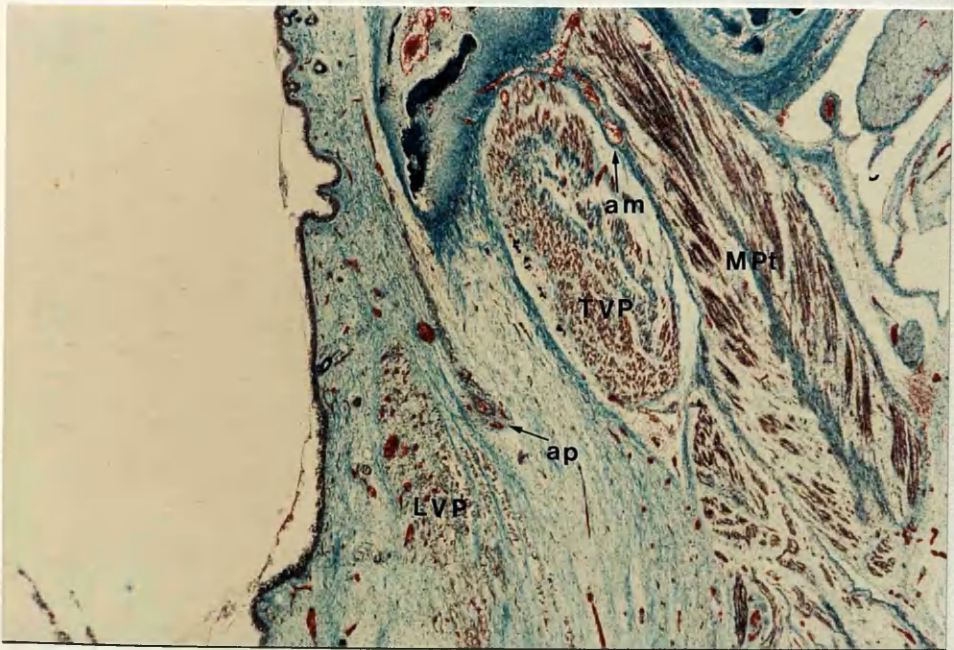
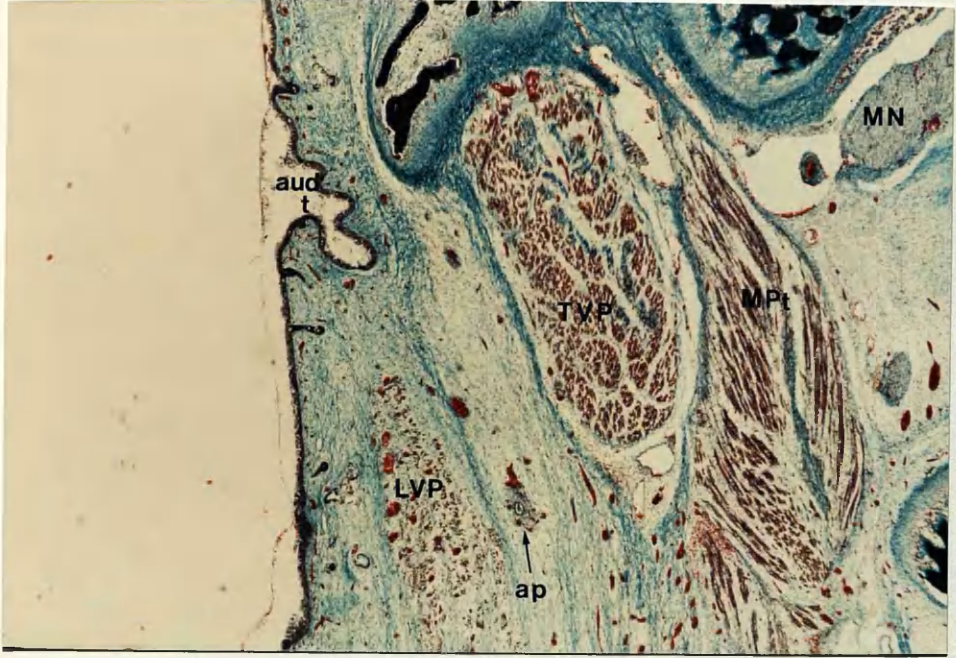


Fig. 65a

Fig.65b

Fig.65a & b. Coronal sections of 16-week fetus with cleft primary, intact secondary palate. Positions of ascending palatine and accessory meningeal vessels are the same as in normal specimen (Masson, x 8).

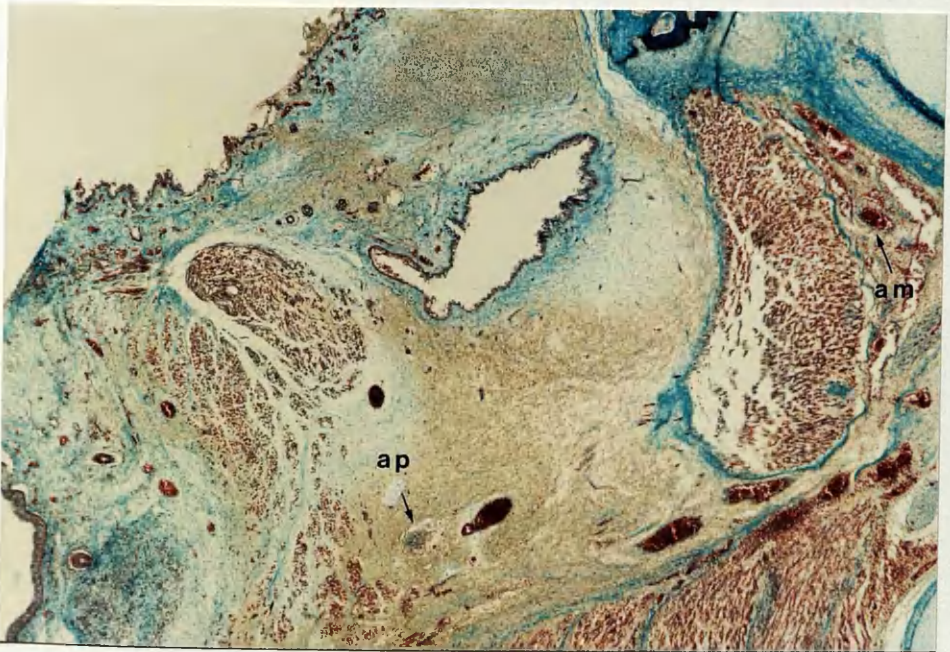
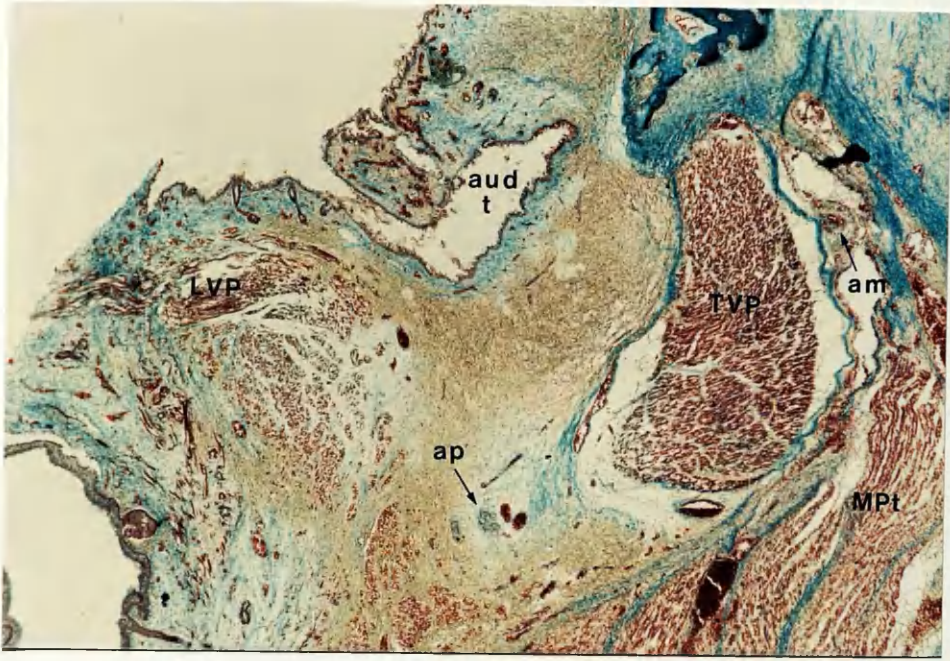


Fig.66 Coronal section of 19-week fetus with complete cleft secondary palate
Montage with ascending palatine vessels seen passing between
styloglossus and stylopharyngeus muscles (Masson, x 8).

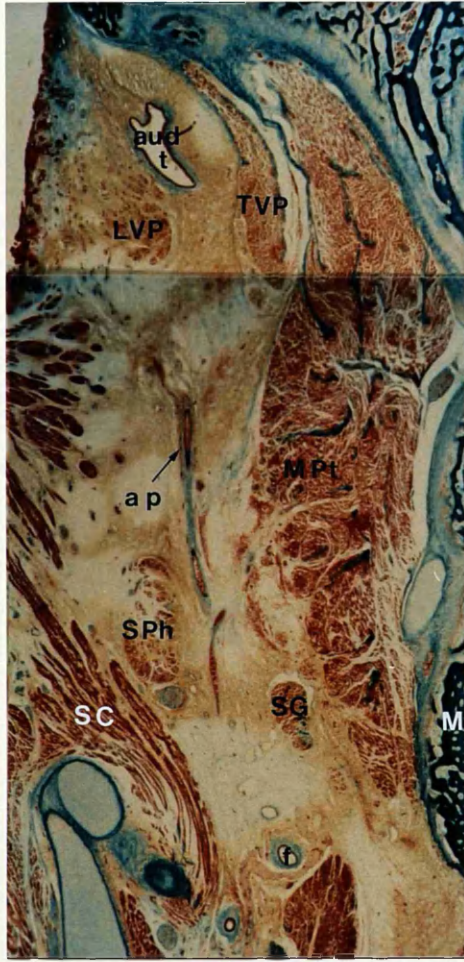


Fig.67a

Fig.67b

Fig. 67a &b Coronal sections of same 19-week fetus with complete cleft secondary palate. Views of ascending palatine and accessory meningeal vessels (Masson, x 8).

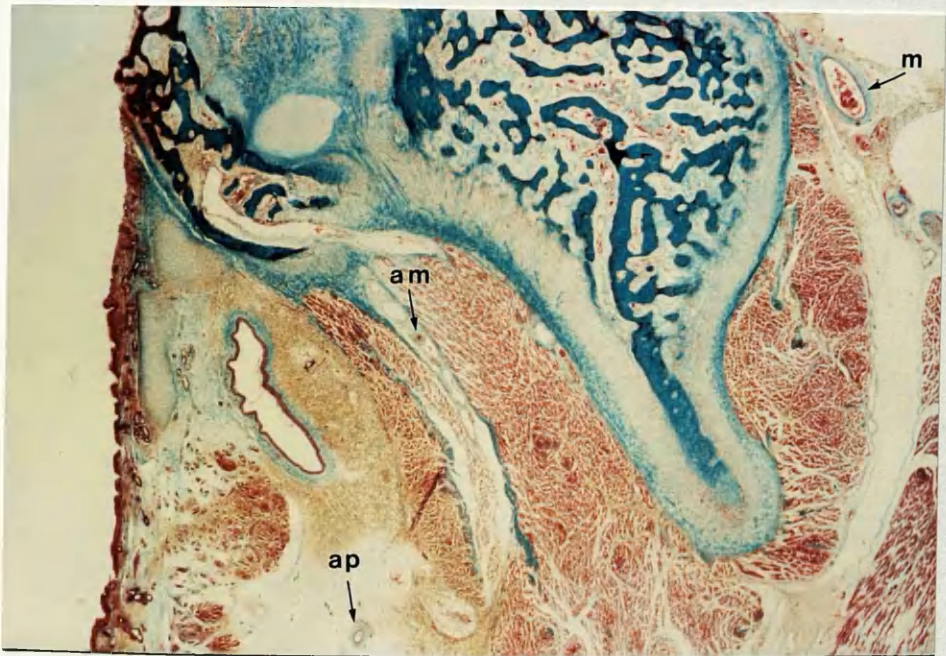
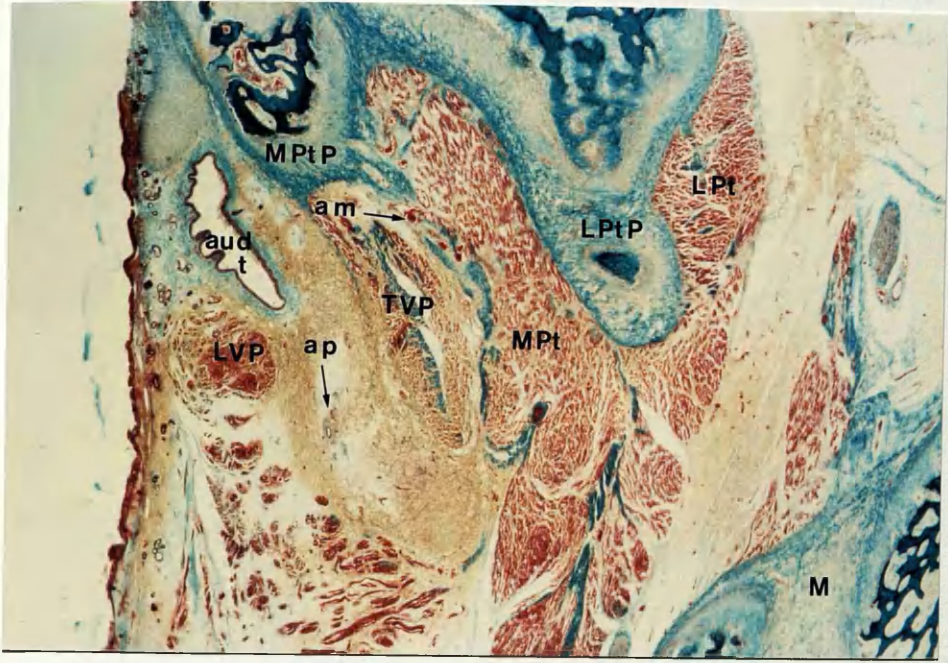


Fig.68 Further coronal section of same fetus as in previous figure showing branch of ascending pharyngeal artery in relation to levator (Masson, x 8).

Fig.69 Coronal section of 17-week fetus with complete cleft of primary and secondary palate. Note ascending palatine vessels on the lateral surface of the superior constrictor muscle (Masson, x 4).

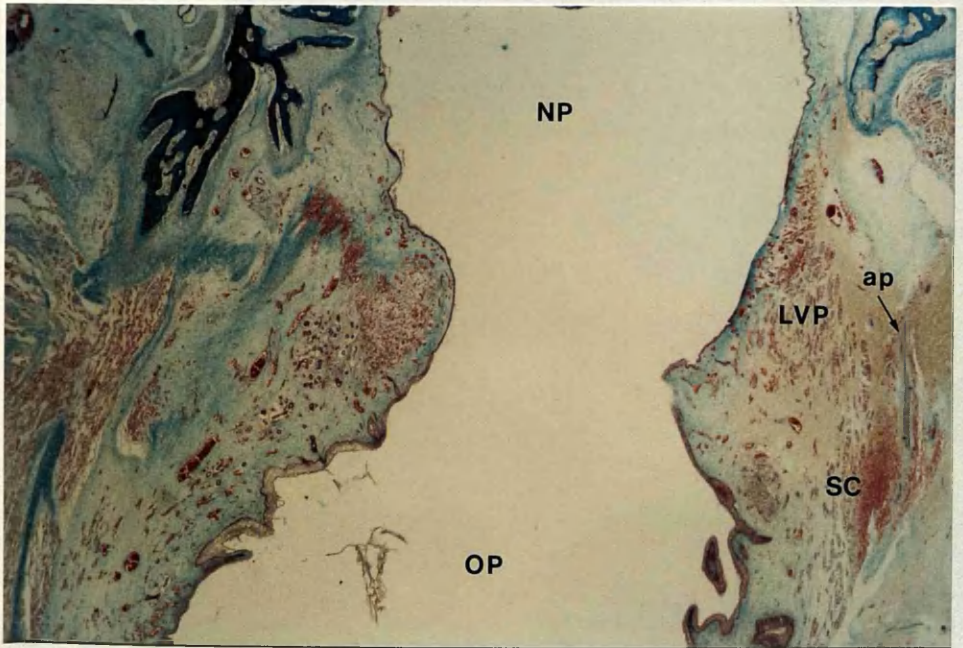
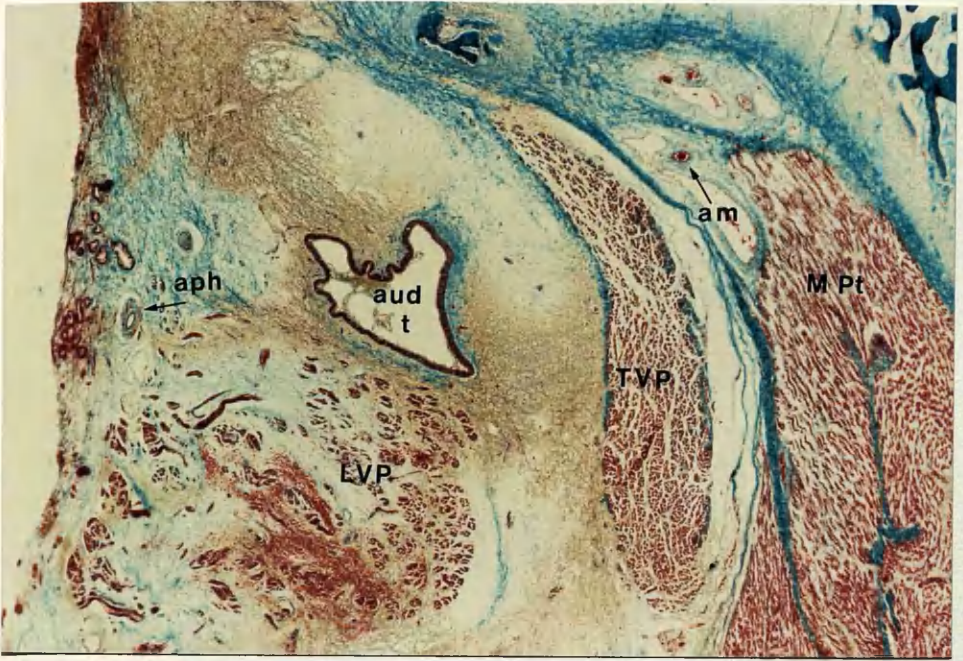


Fig.70 Same specimen as in previous figure. Ascending palatine vessels are situated between levator and tensor veli palatini (Masson, x 12).

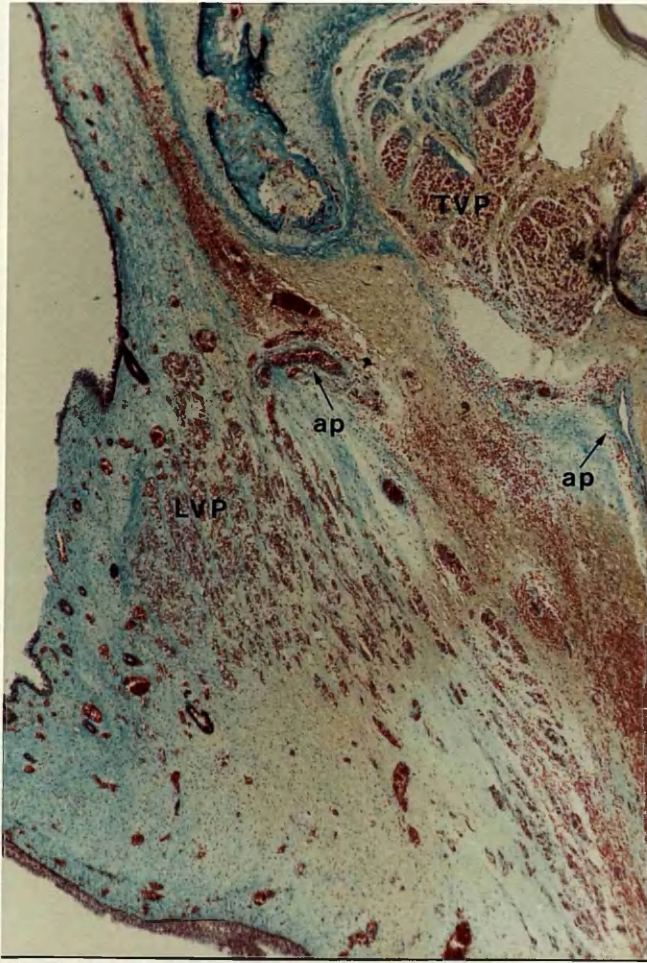


Fig.71a **Posterior pharyngeal wall of adult cadaver. Indian ink / latex injection showing filled arteries and veins.**

Fig.71b **Close-up view of upper portion posterior wall of above specimen. The tortuous arterial branches in places can be distinguished from the straighter veins.**

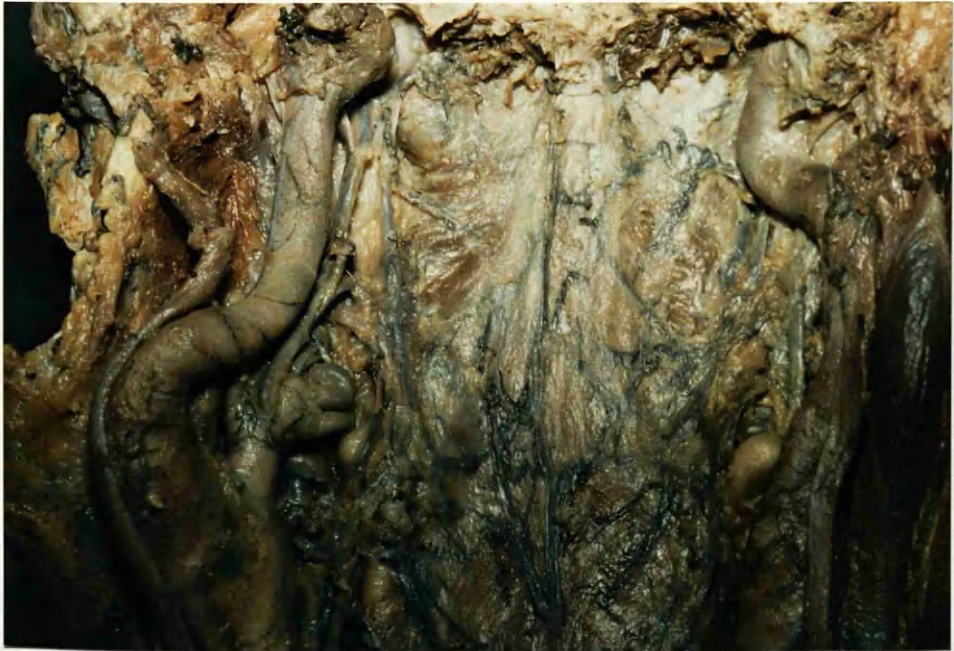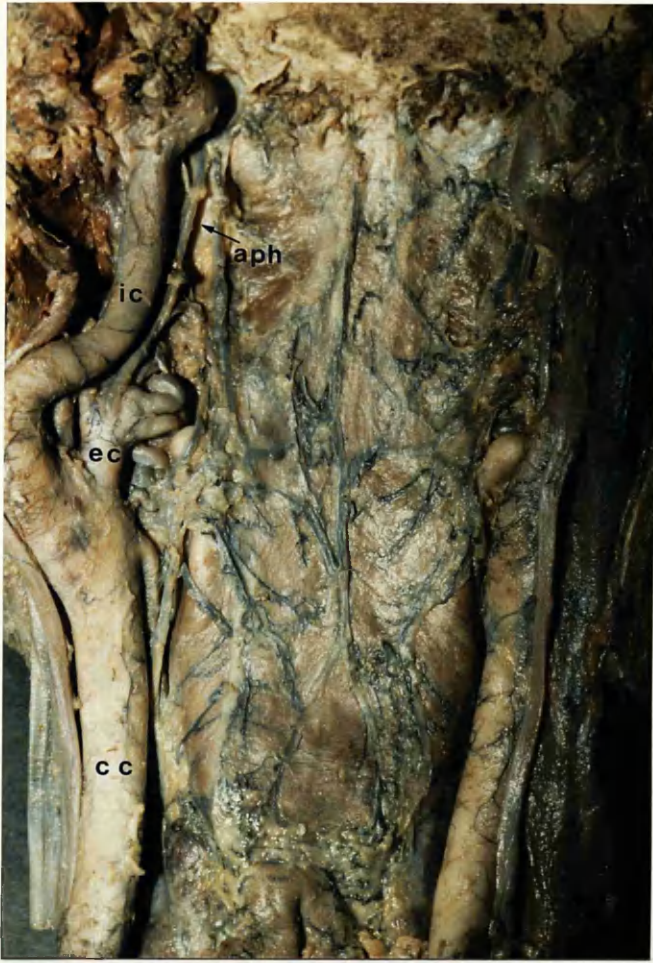


Fig.72a **Posterior pharyngeal wall of adult cadaver. Red, blue latex /
Micropaque injection. Arterial vessels (pink) and veins (blue) can be
identified.**

Fig.72b **Close-up view of above specimen.**

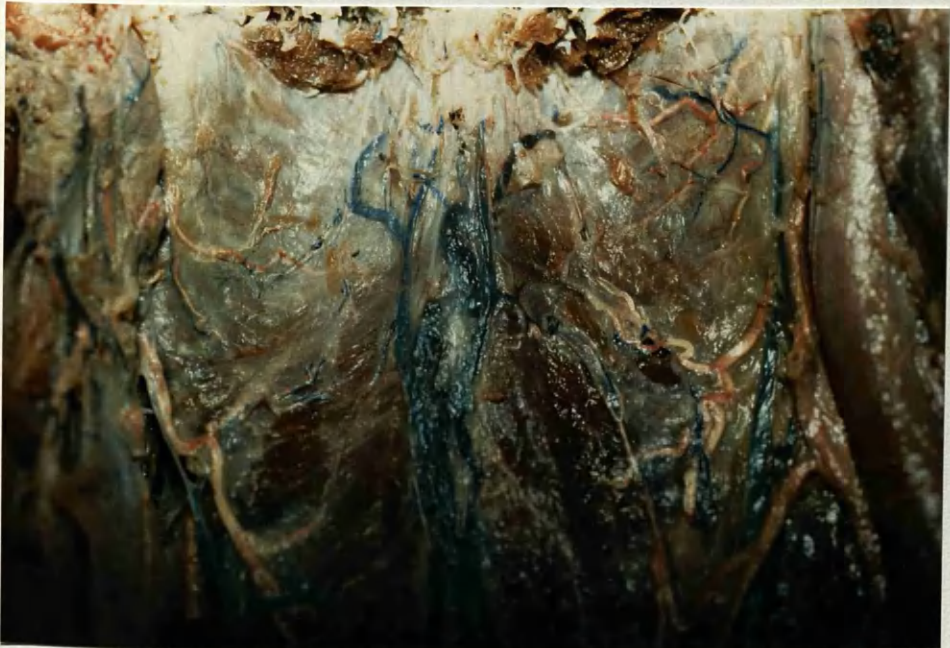
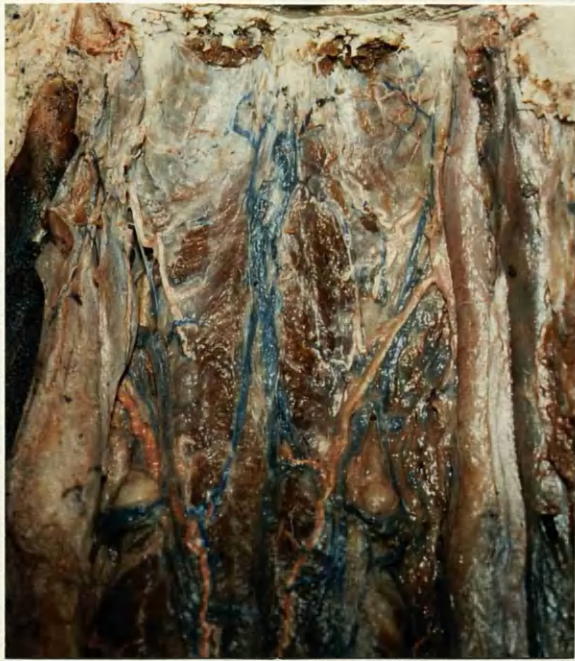
Fig.73 & Frontispiece Upper portion of posterior pharyngeal wall of cleared specimen adult cadaver. Indian ink / latex injection. Centrally draining veins can be differentiated from narrower tortuous arteries.

Fig.74 X-ray of posterior pharyngeal wall of adult cadaver. Latex / Micropaque injection. Note essentially random pattern of vessels and dense concentration in area of palatopharyngeal arches (arrows).

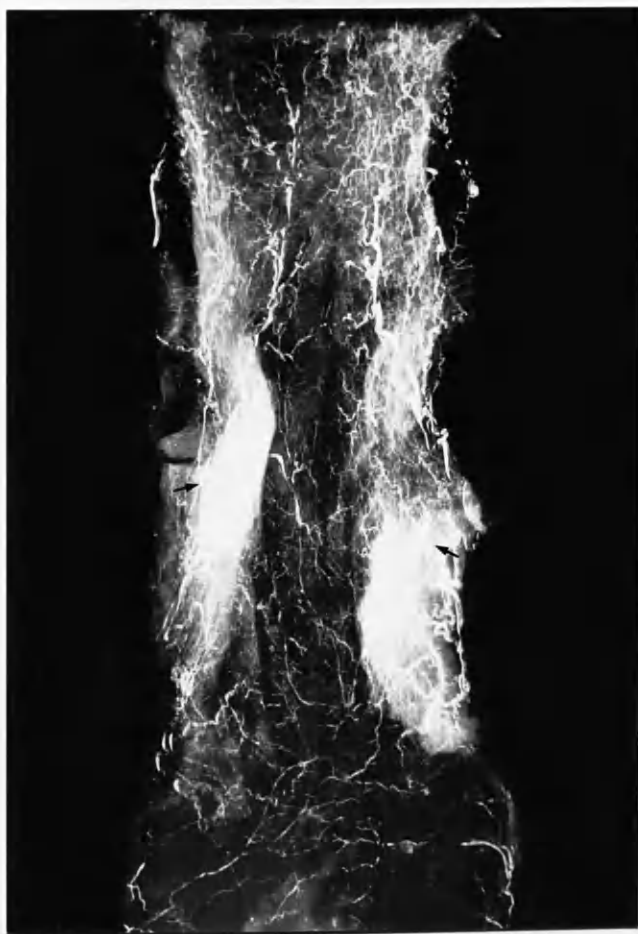
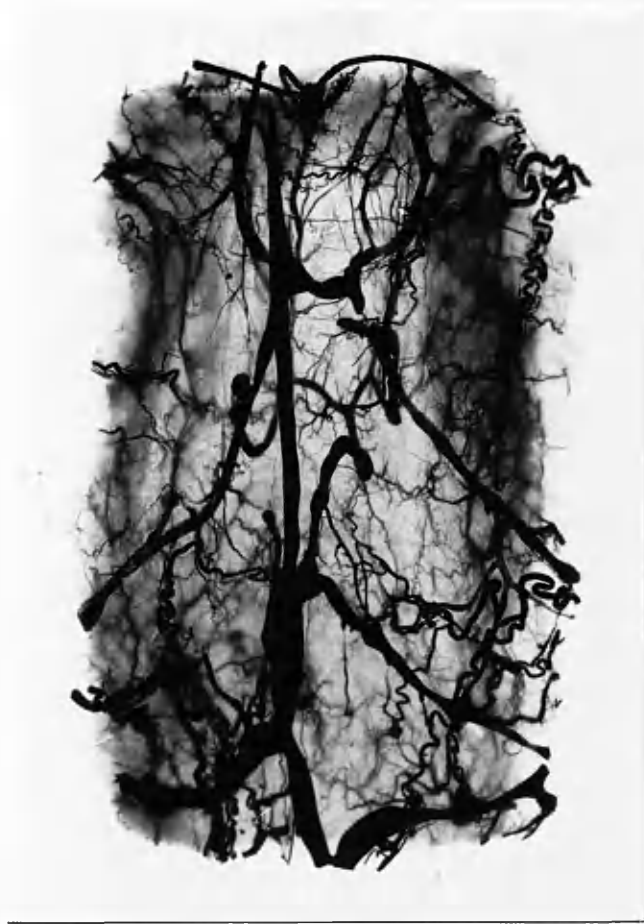

Fig.75 Uppermost portion of posterior pharyngeal wall of adult cavaver. Indian ink / latex injection. Note branches of ascending pharyngeal arteries on pharyngobasilar fascia.

Fig.76 Posterior pharyngeal wall of cleared specimen adult cadaver. Red, blue latex / Micropaque injection. High branch of ascending pharyngeal artery can be seen on right side. Note also centrally and laterally draining veins.

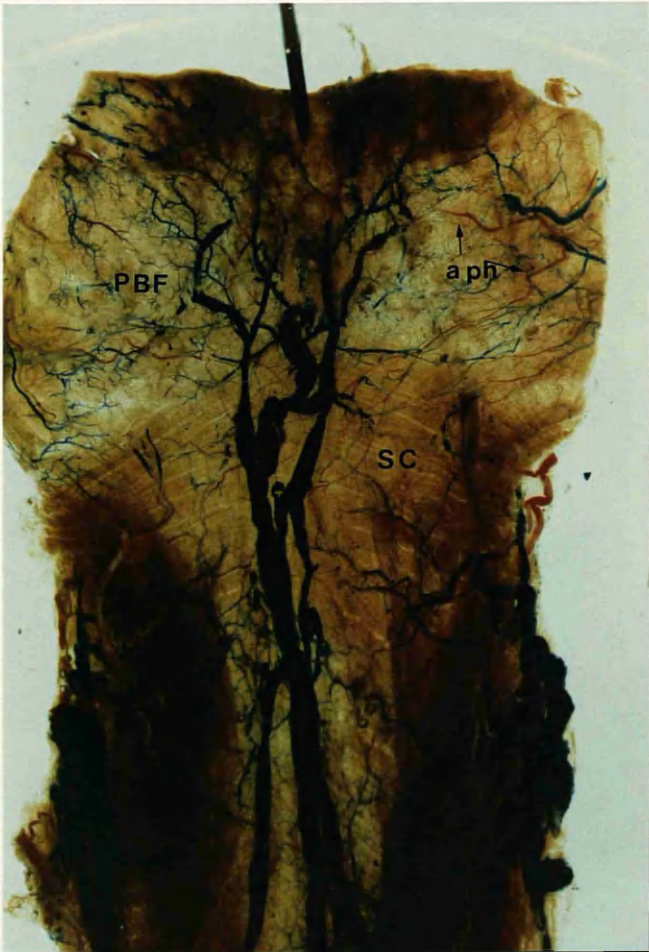
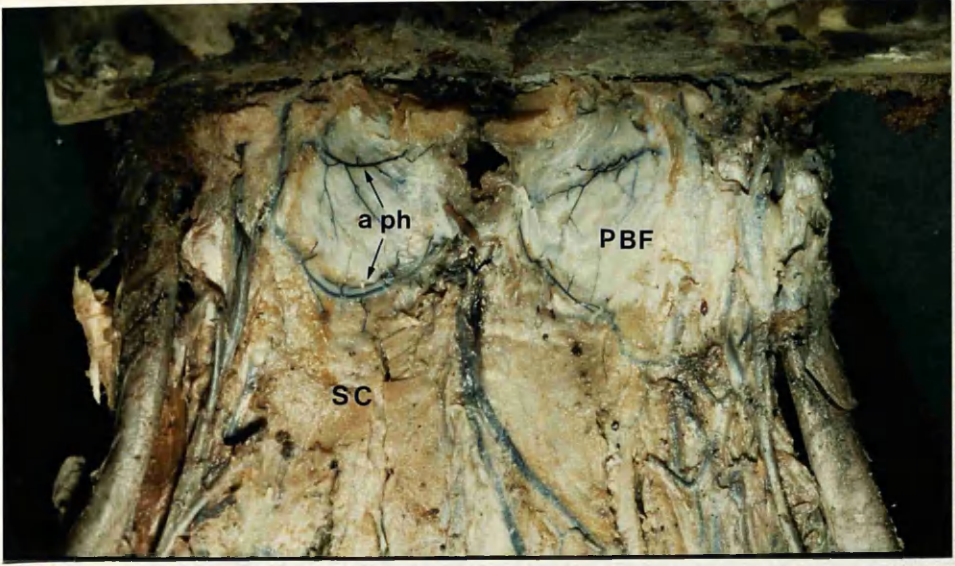


Fig.77 Transverse section through surgical specimen of adult posterior pharyngeal wall at level of soft palate. Numerous vessels are seen in the submucosa among mucous glands (Masson, x 7).

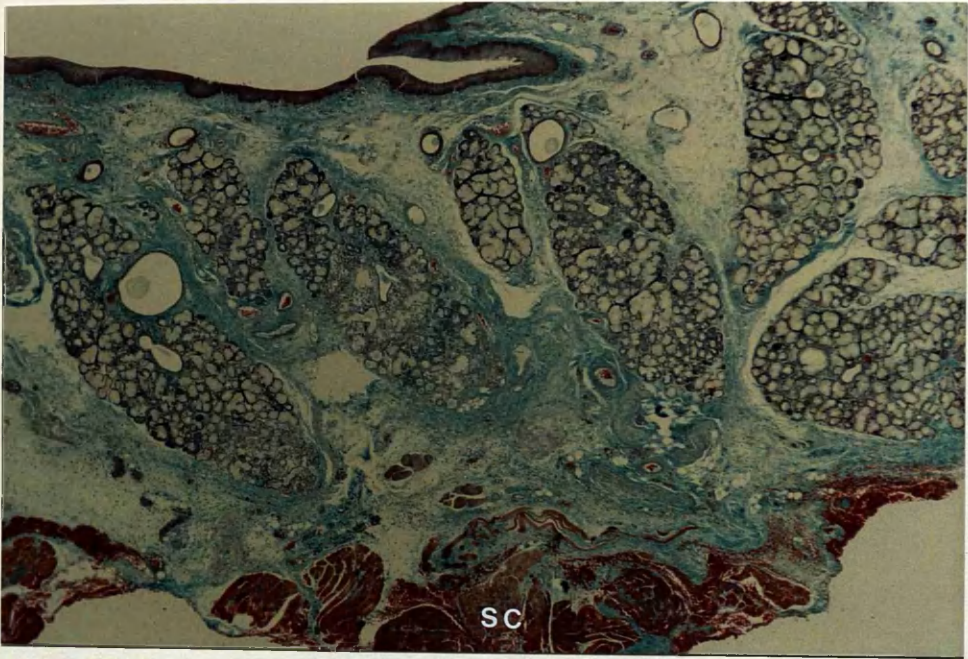


Fig.78 Posterior surface of posterior wall of upper pharynx of 20-week fetus. Superiorly based pharyngeal flap elevated (suture demonstrating base). Note branches (arrowed) of ascending pharyngeal artery preserved (x 8).

Fig.79 Superiorly based flap of posterior pharyngeal wall of adult cadaver. Cleared specimen. Indian ink / latex injection. Branches ascending pharyngeal arteries (arrowed) visible on pharyngobasilar fascia.

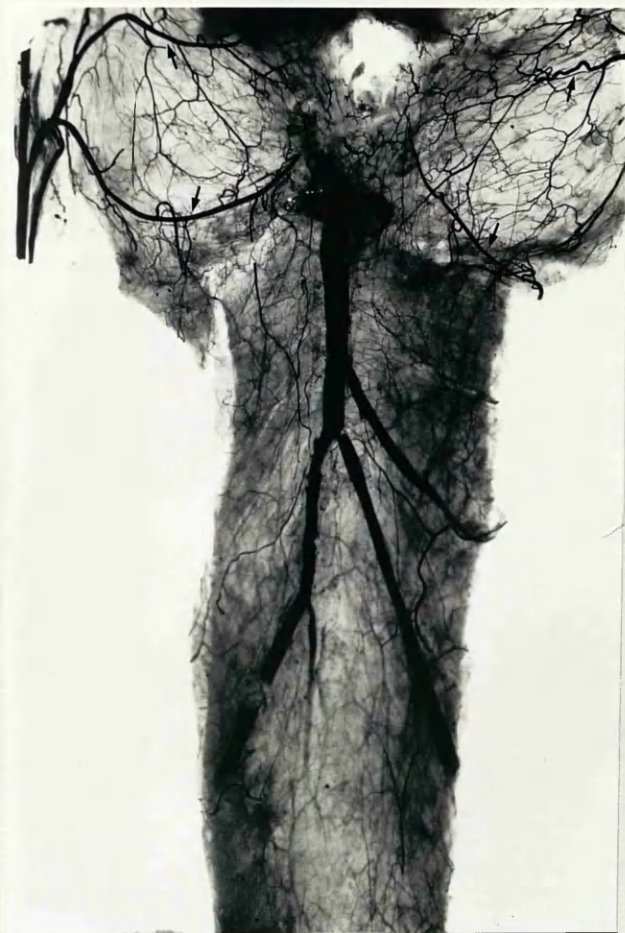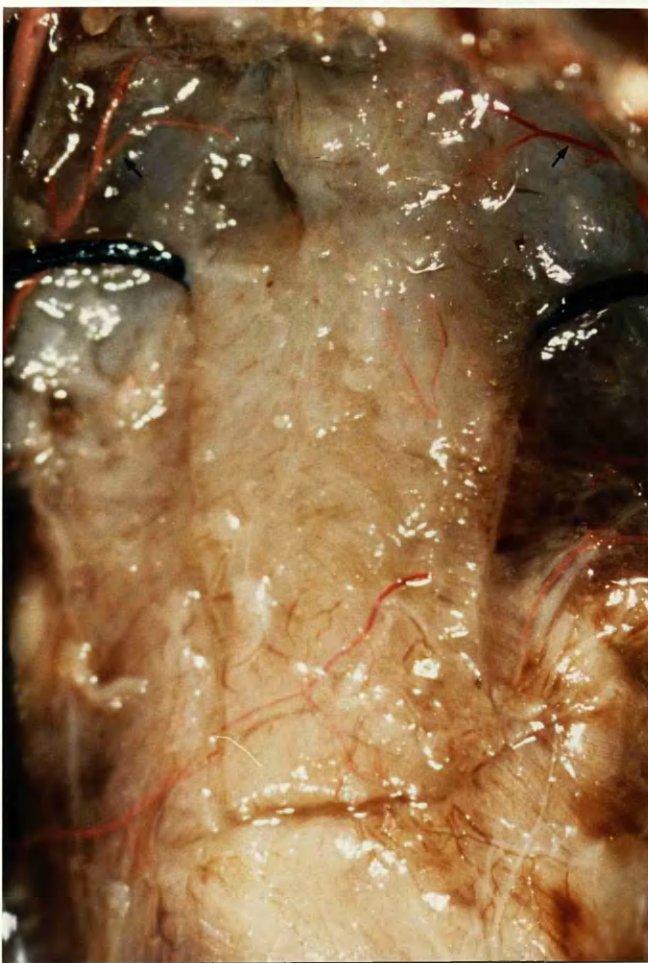


Fig.80a Montage of posterior aspect of pharyngeal wall of 24-week fetus.
Schlesinger's medium (x 8).

Fig.80b Inferiorly based flap raised on above specimen. Pharyngeal branches
of superior thyroid arteries preserved together with inferiorly draining
veins (x 8).

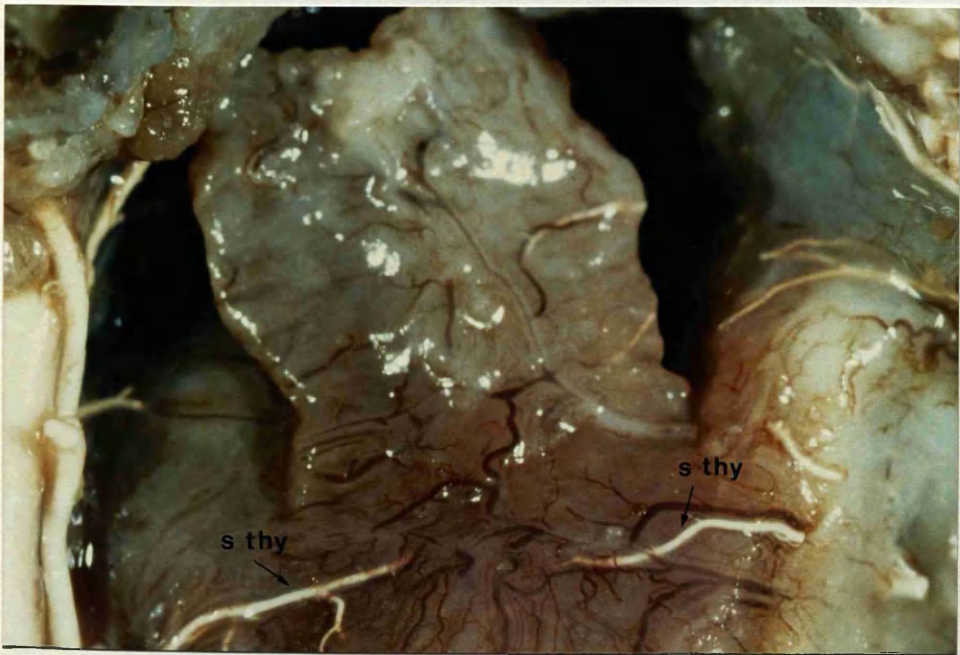
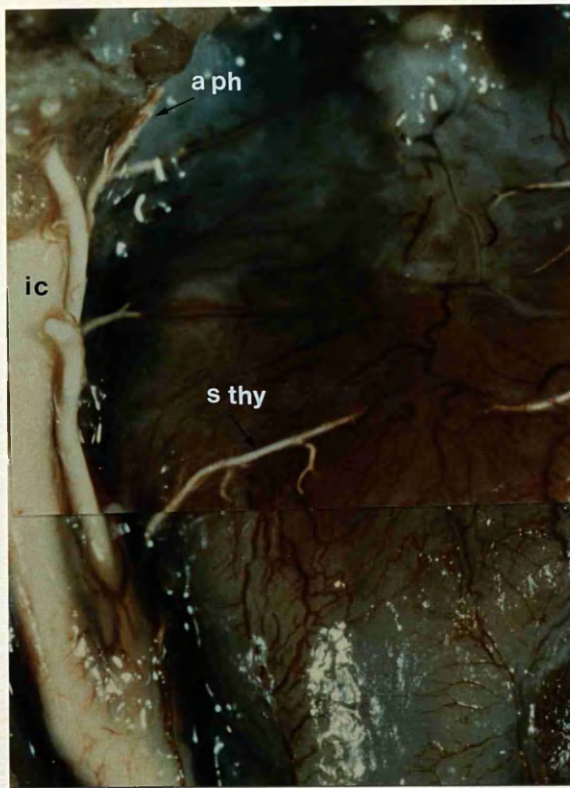


Fig.81a **Posterior aspect of posterior pharyngeal wall of 20-week fetus.**
Microfil / blue latex injection. Right Kapetansky flap incised. Note
arterial and venous supply preserved (x 8).

Fig.81b **Flap elevated (x 8).**

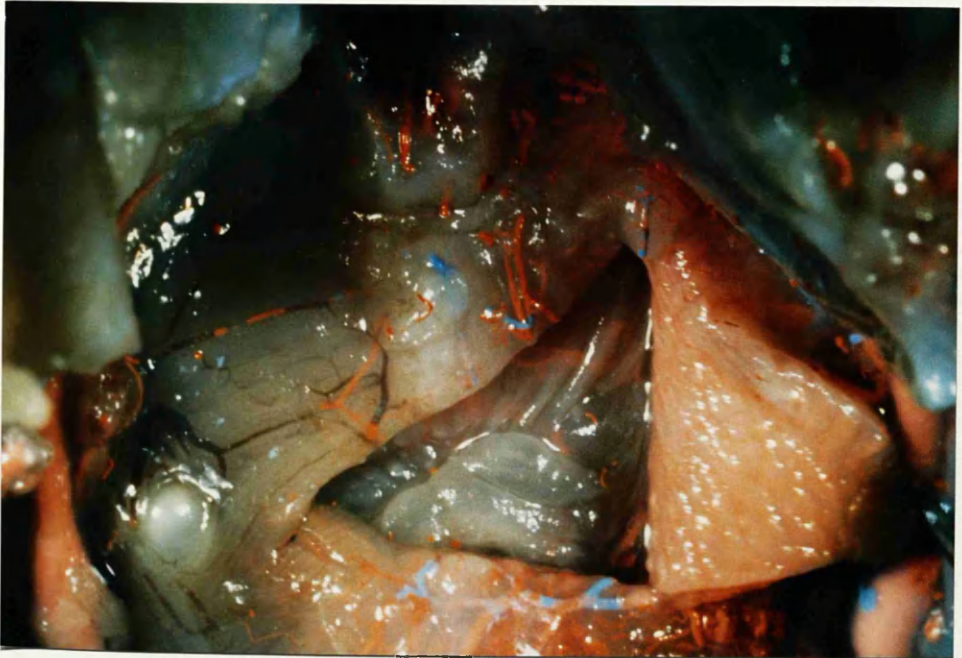
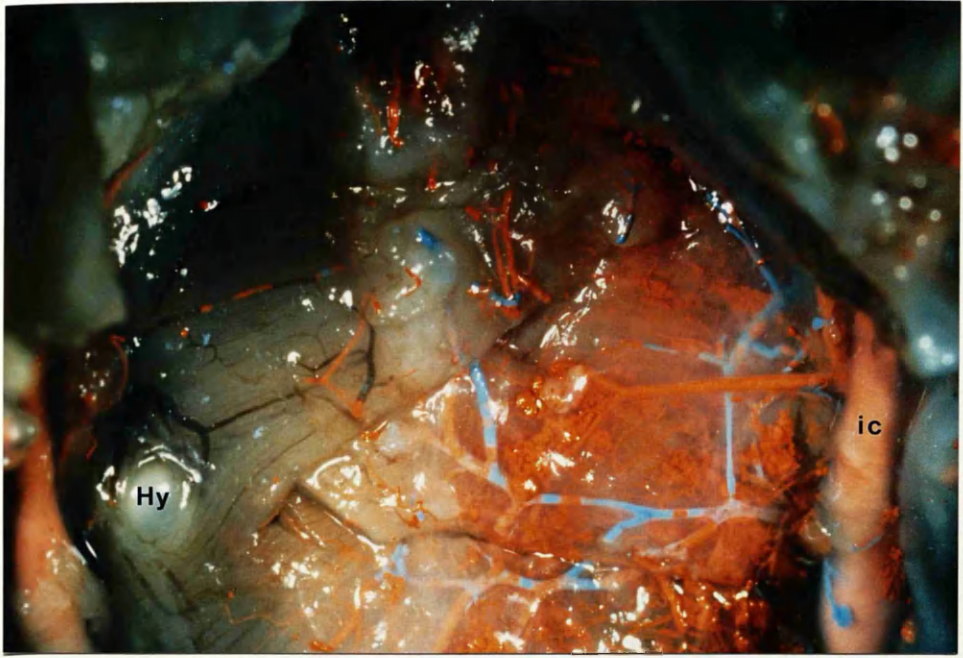


Fig.82 Cleared specimen adult cadaver. Indian ink / latex injection showing uvula and left palatopharyngeal arch. Longitudinally orientated interconnecting network of vessels can be seen running along arch.



Fig.83 Oral surface of hard / soft palate junction in 27-week fetus. A few fibres of palatopharyngeus muscle (arrowed) are passing superficial to the aponeurosis towards the posterior nasal spine. Note epithelial pearls (x 13).

Fig.84 View of oral surface of right soft hemipalate in 25-week fetus with complete cleft palate. Note how hamulus and uvula lie almost on the same coronal axis (x 8).

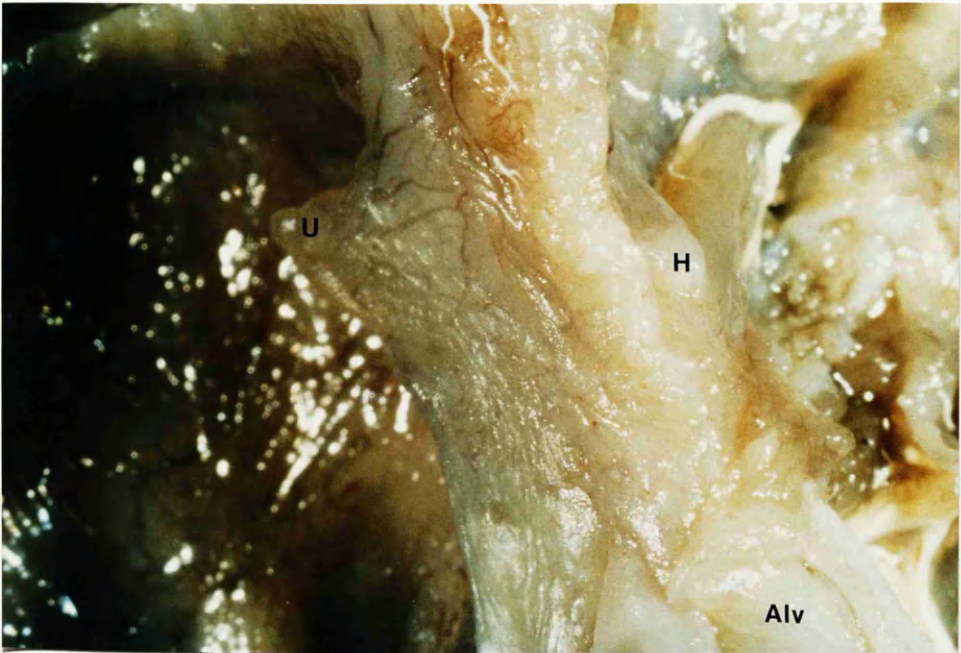
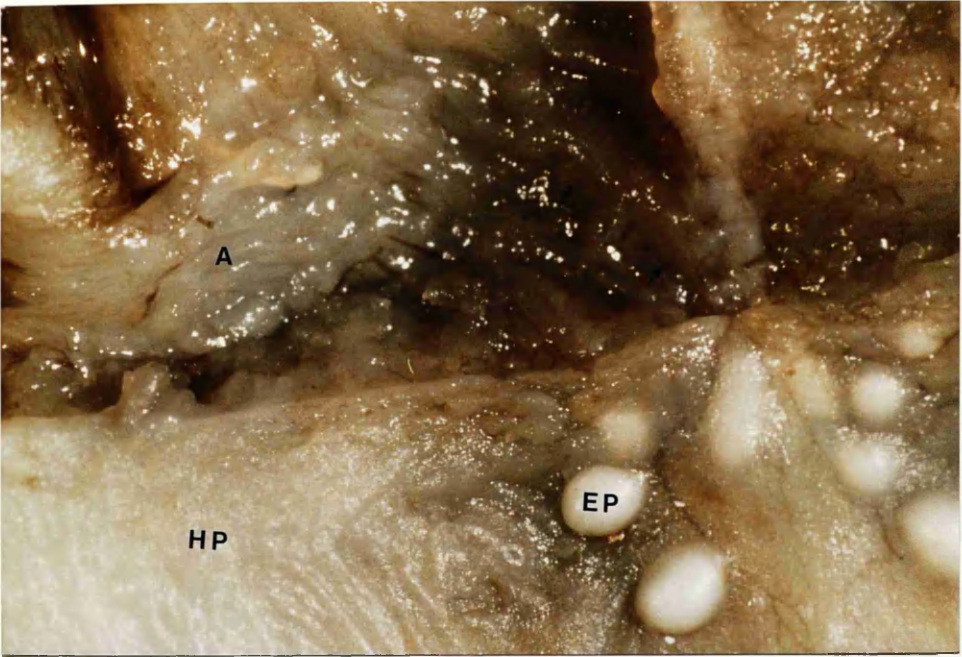


Fig.85a Left soft hemipalate of fetus shown in Fig.20. Levator muscle is running towards cleft edge (x 8).

Fig.85b Arrows indicating direction of muscle fibres of left levator (x 16).

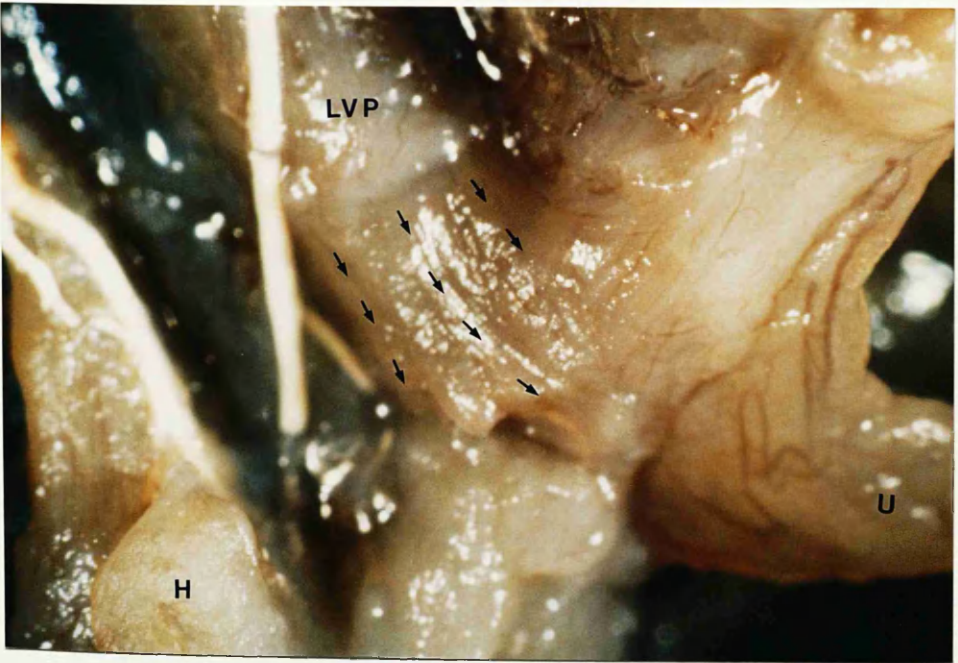
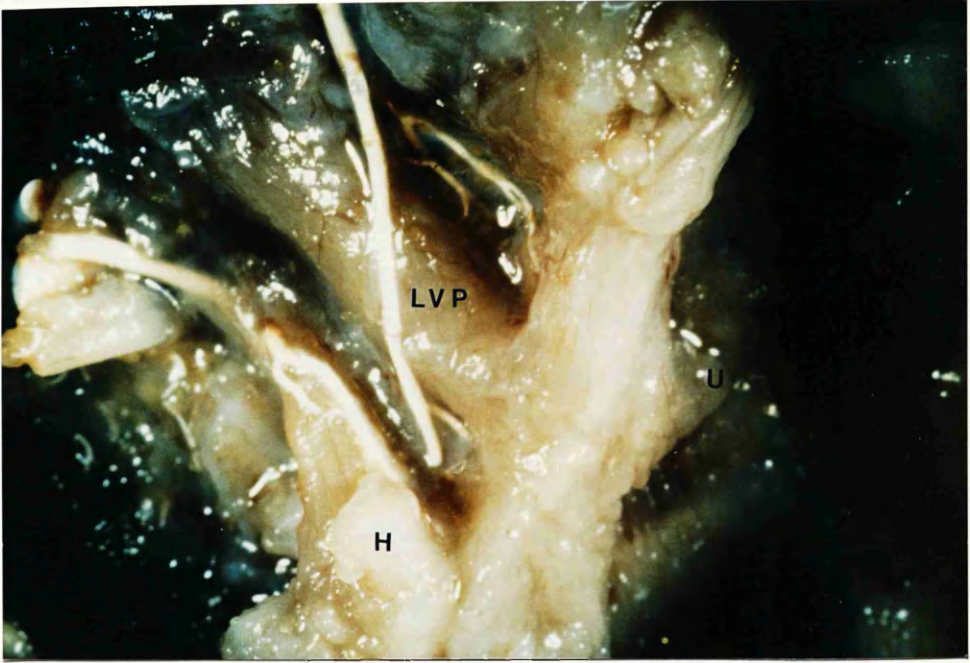


Fig.85c Anterior fibres of levator inserting into rudimentary aponeurosis round hamulus (x 13).

Fig.86 Left soft hemipalate (oral view) of 20-week fetus with complete bilateral cleft palate. Levator fibres running anteriorly into aponeurosis and medially towards cleft edge. Palatopharyngeus fibres can be seen running forwards (x 13).

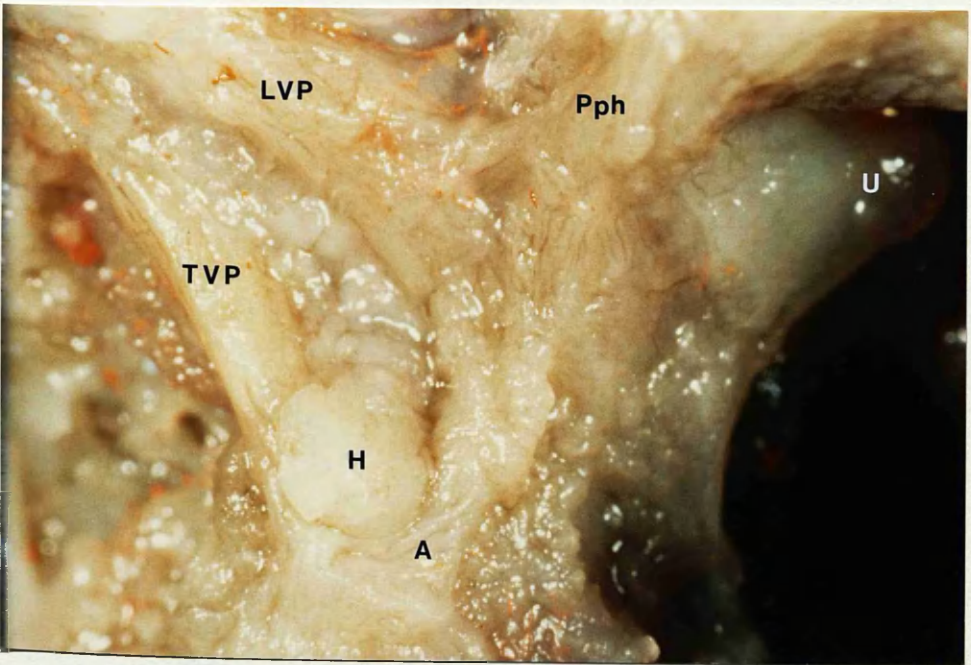
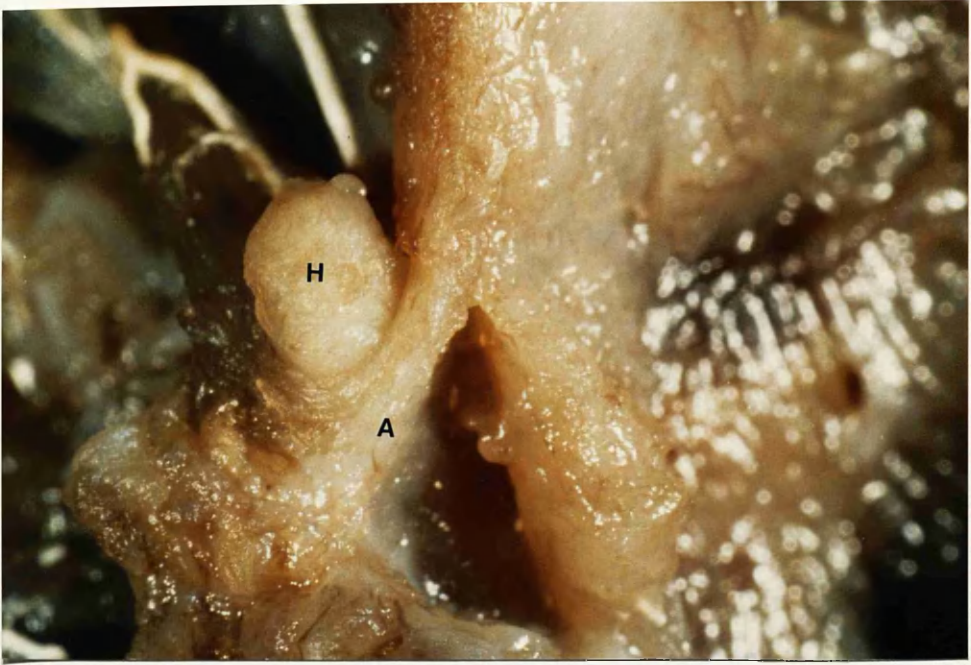


Fig.87a Montage of dissected soft palate of specimen with cleft secondary palate (Fig. 21). Note how most of right levator muscle inserts into tensor tendon. Only a few fibres pass forwards to the posterior edge of the hard palate.

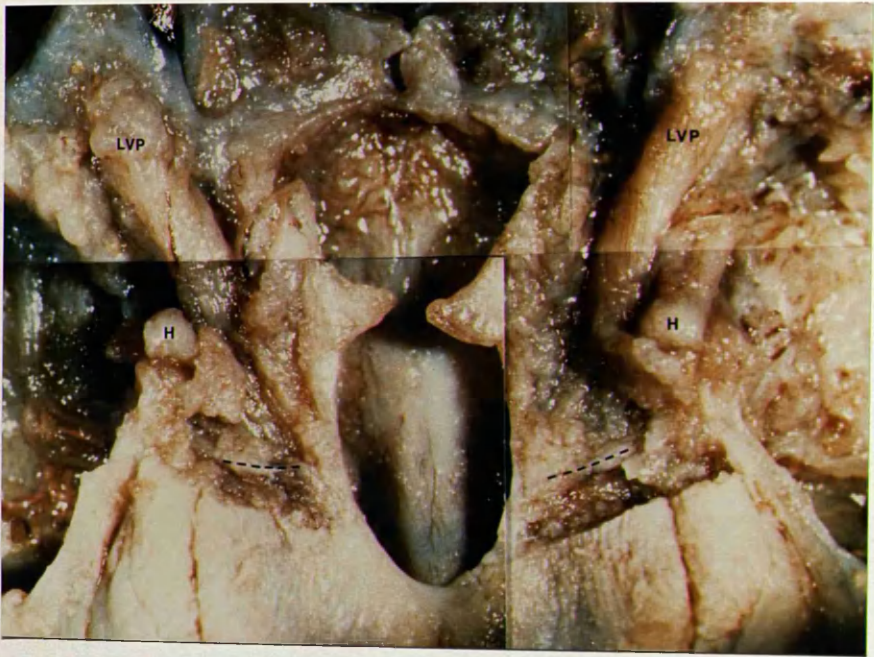

Fig.87b Oral view of dissected right soft hemipalate showing levator inserting into tensor tendon. Posterior edge of hard palatal shelf marked by broken line (x 8).

Fig.87c Left soft hemipalate showing levator insertions (x 13).

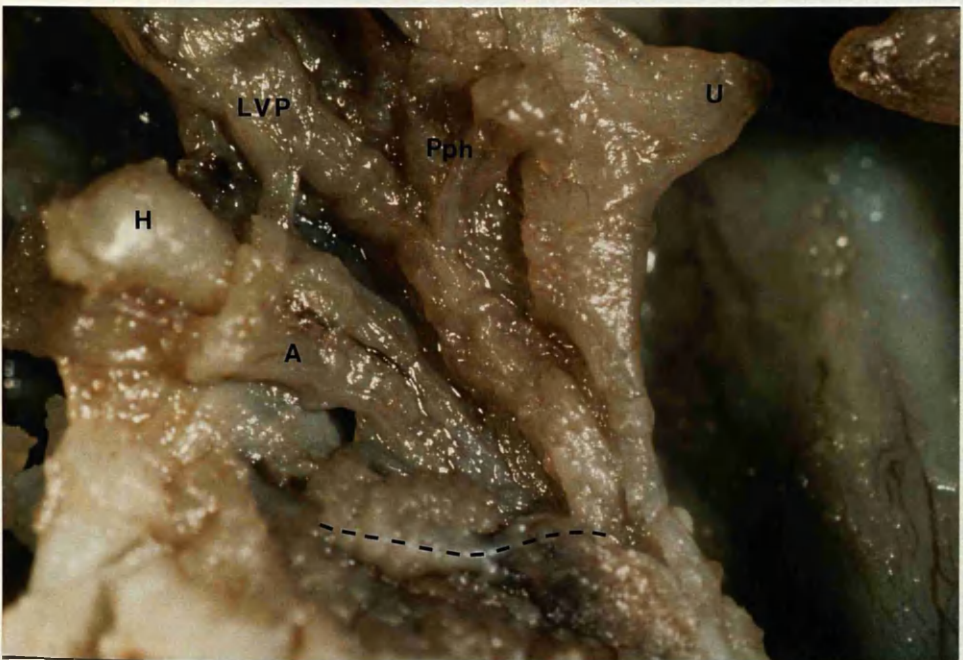
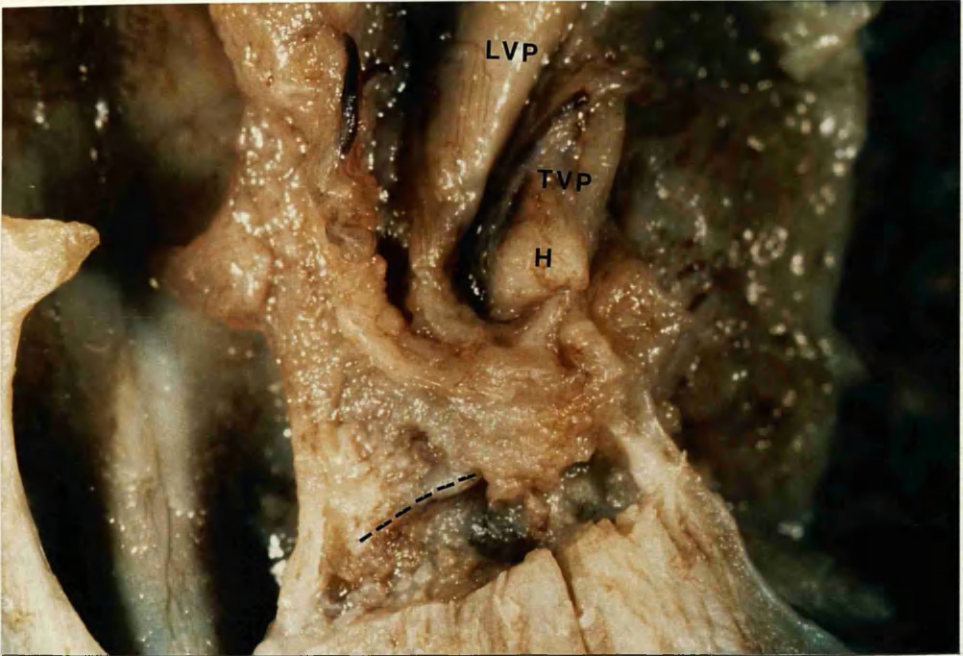

Fig.88 Cleft secondary palate. Schematic illustration of tripartite insertion of levator veli palatini muscle into tensor aponeurosis, cleft soft palate edge and posterior edge of hard palate.

Fig.89 Schematic illustration of insertions palatopharyngeus, superior constrictor and levator muscles.

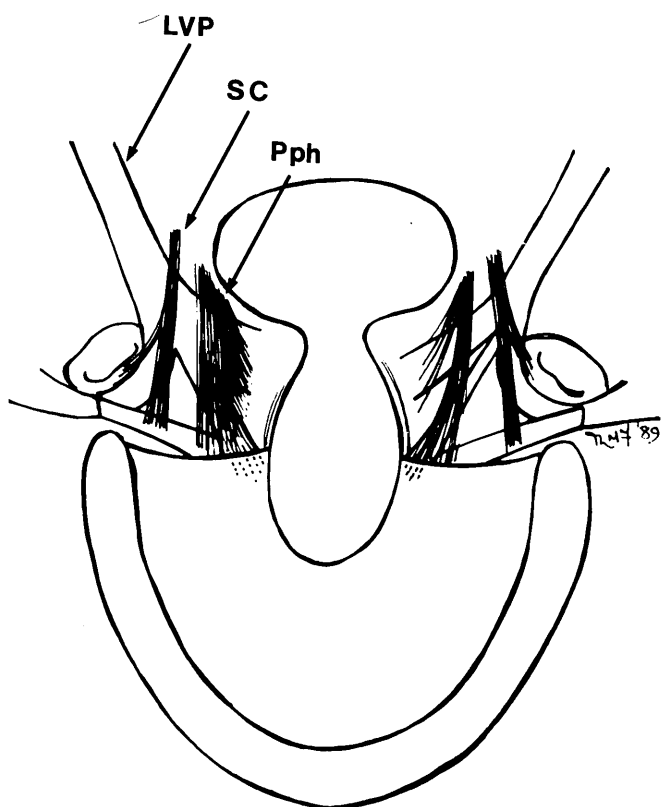
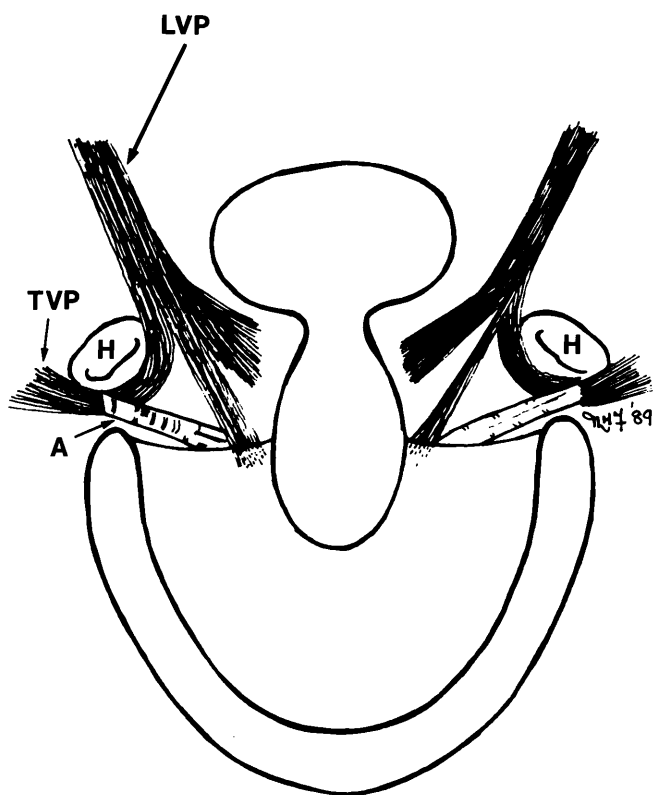


Fig.90 **Left lateral view of dissection of 22-week fetus with cleft palate.**
Lateral pterygoid plate and pterygoid muscles removed. Fascicles from
glossopharyngeal nerve can be seen approaching levator (x 8).

Fig.91 **Left extrapalatal muscles of fetus in Fig.90. A branch from the nerve**
to the medial pterygoid muscle can be seen lateral to tensor veli palatini
(small arrow). This branch entered the superior aspect of the muscle
(x 8).

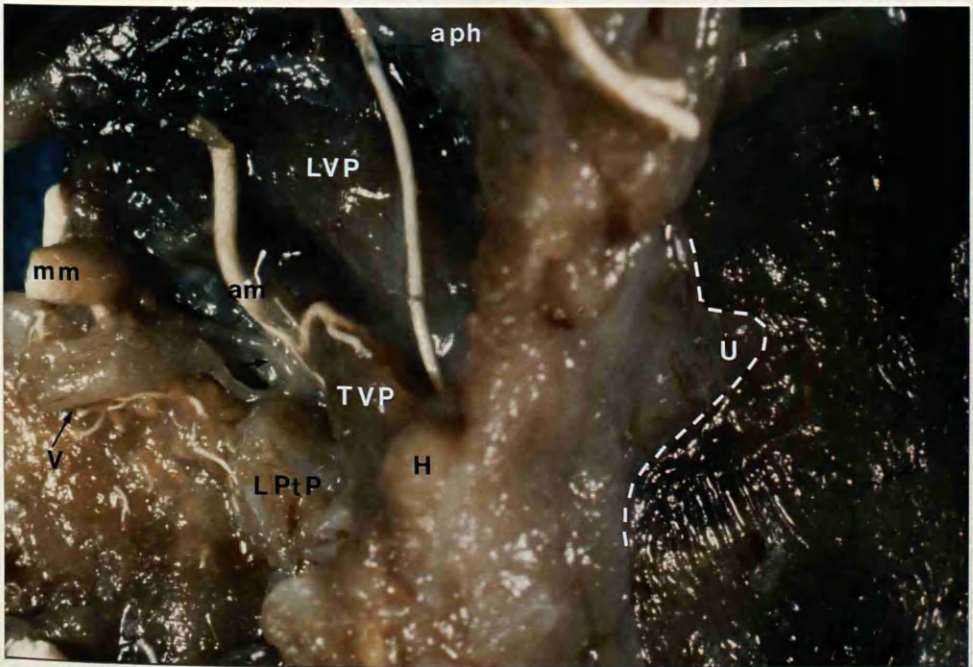
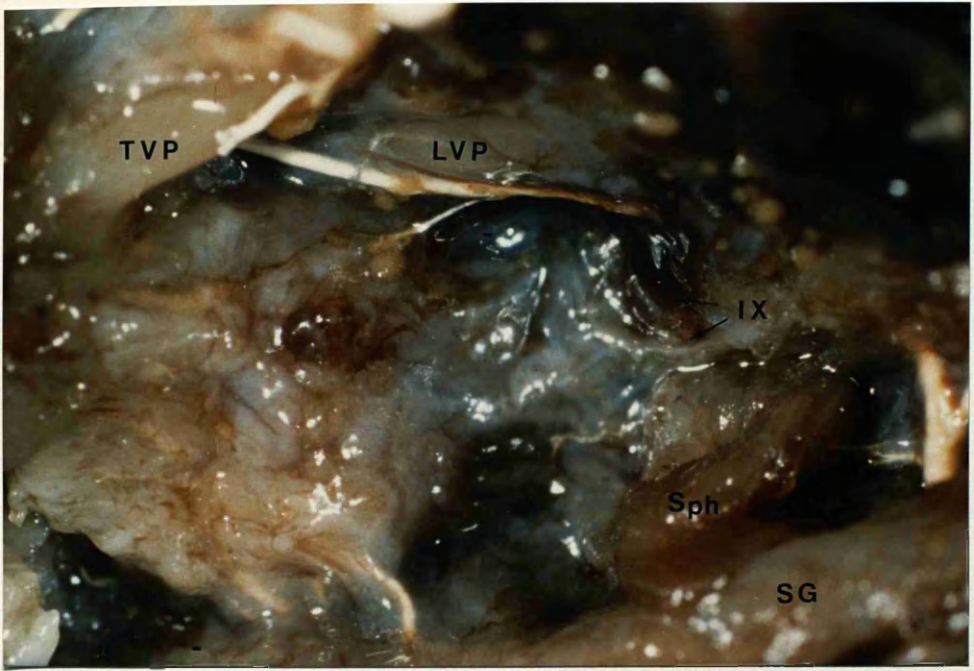


Fig.92a Coronal section through the posterior hard hemipalate. 19-week fetus with cleft secondary palate. Muscle fibres are seen inserting into bony palatal shelf (arrow). (Masson, x8).

Fig.92b Coronal section through the anterior soft hemipalate. Aponeurosis is clearly seen acting as insertion for muscles (Masson, x 8).

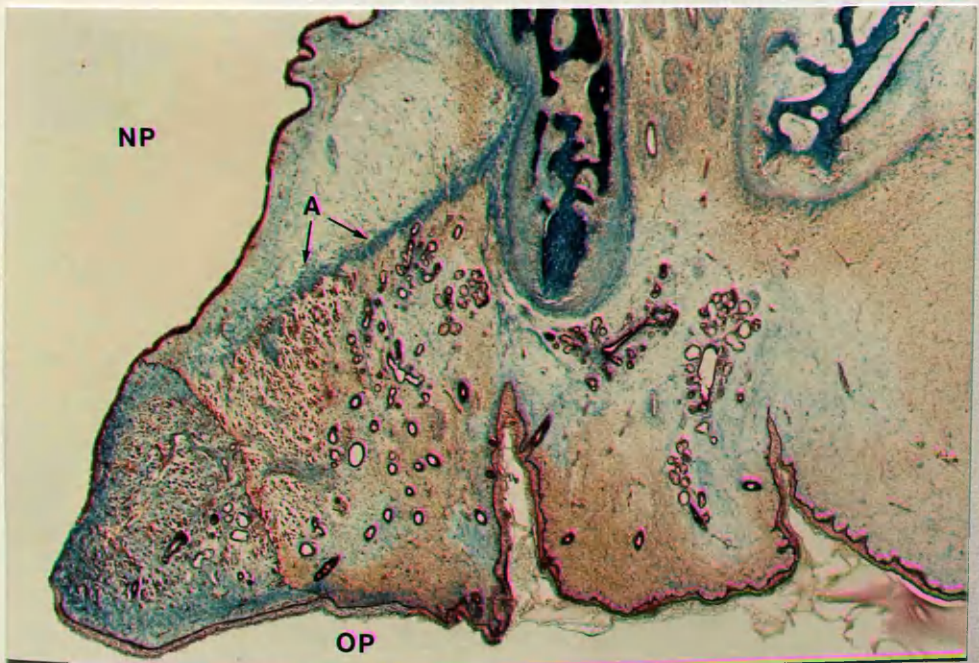
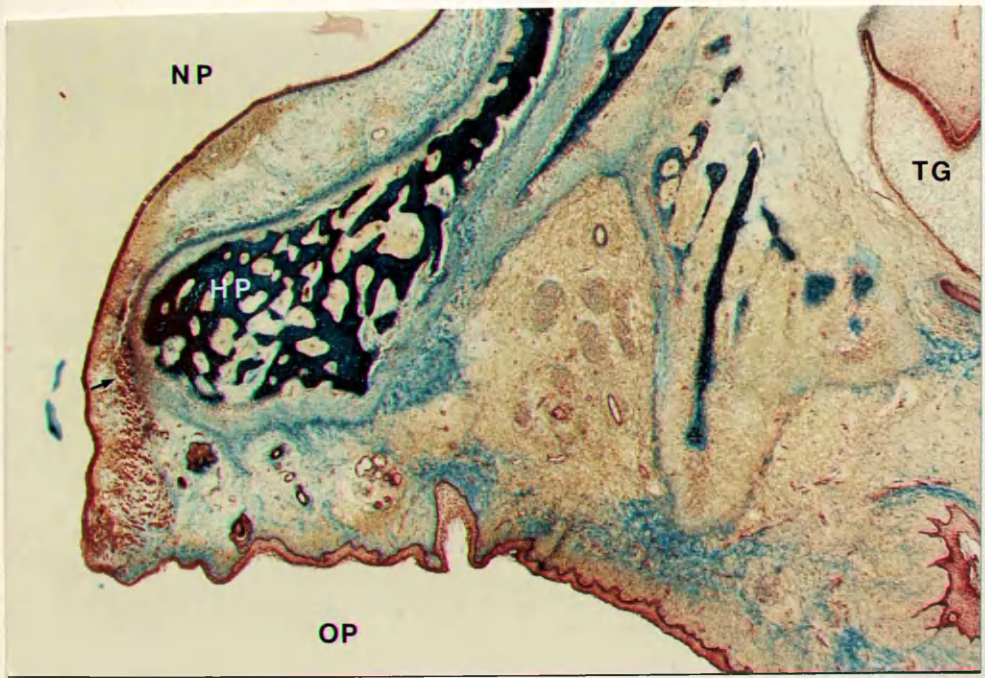


Fig.92c Coronal section through soft hemipalate (Masson, x8).

Fig.92d Higher power of portion Fig.92c. Note some bundles of levator fibres running transversely (arrows) towards cleft edge (Masson , x 20).

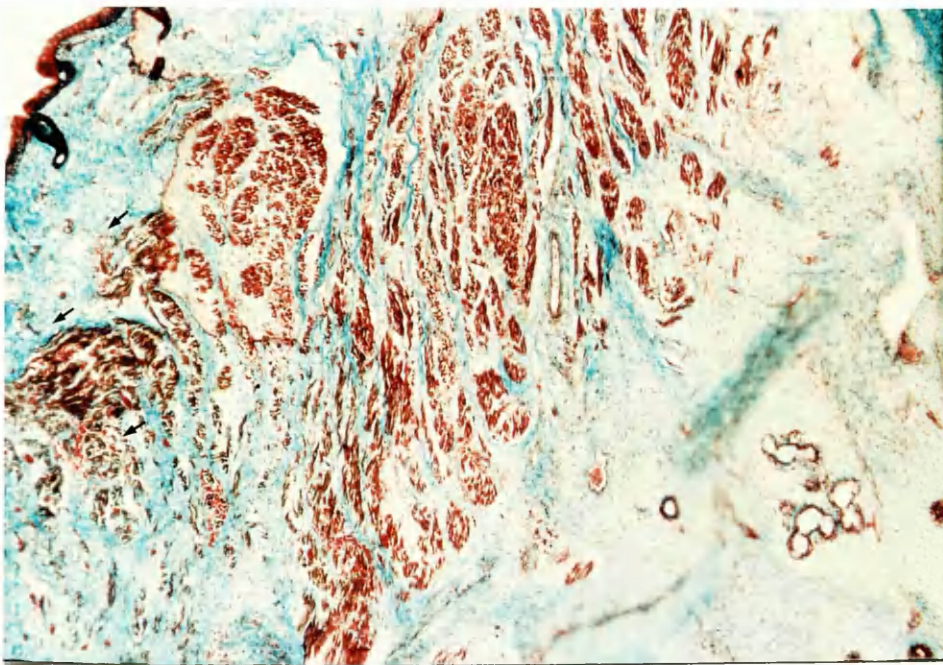
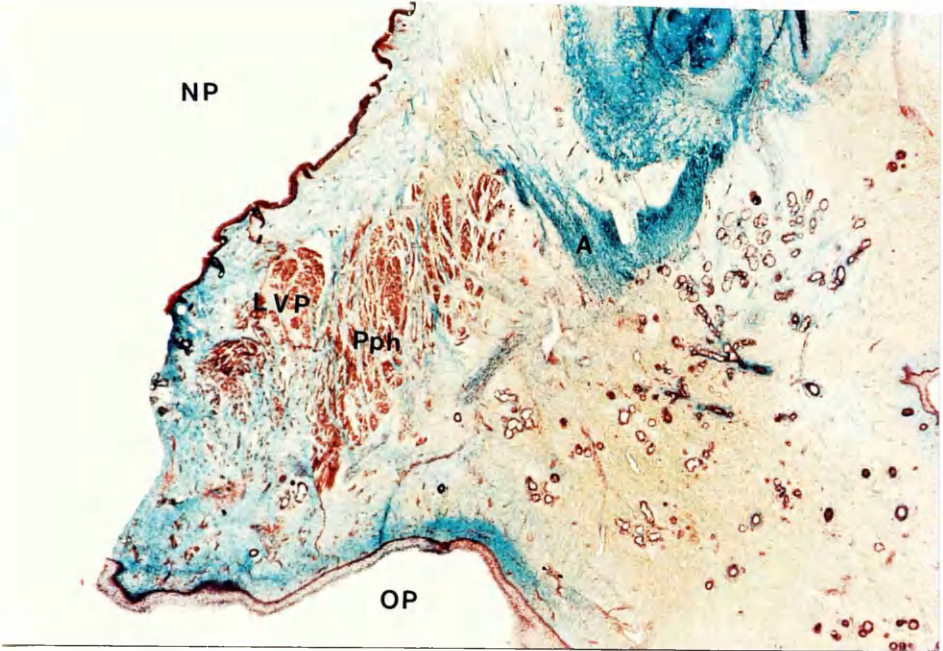


Fig.93a Coronal section through the soft hemipalate and nasal septum of specimen with complete unilateral cleft lip and palate (Fig.19). Note some transversely running levator fibres (arrow) (Masson, x 20).

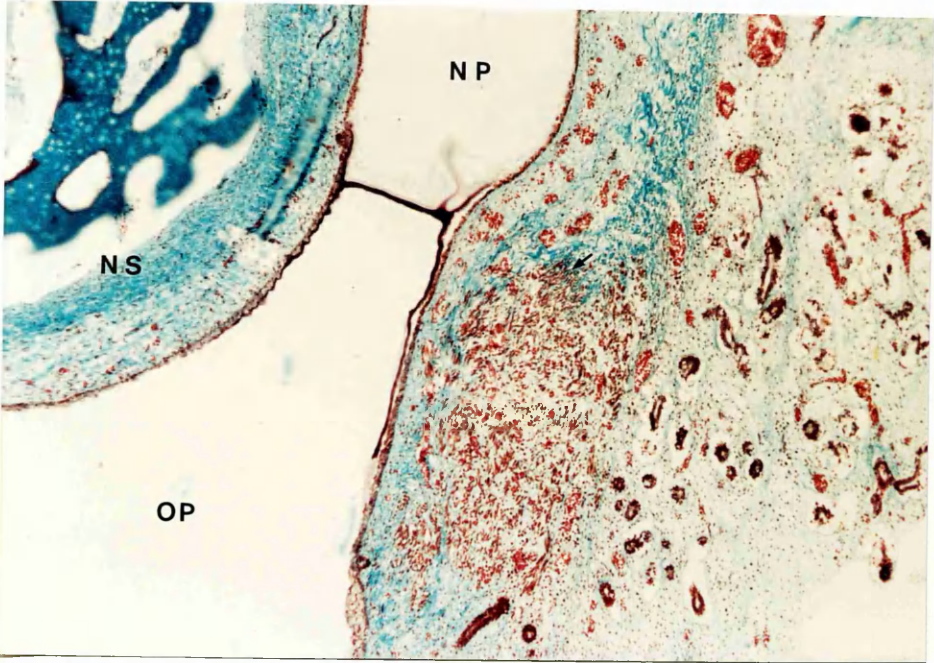


Fig.93b Coronal section through hemiuvula (Masson, x 8).

Fig.93c Higher power of above figure. Levator fibres are seen streaming into base of hemiuvula (arrows) (Masson, x 20).

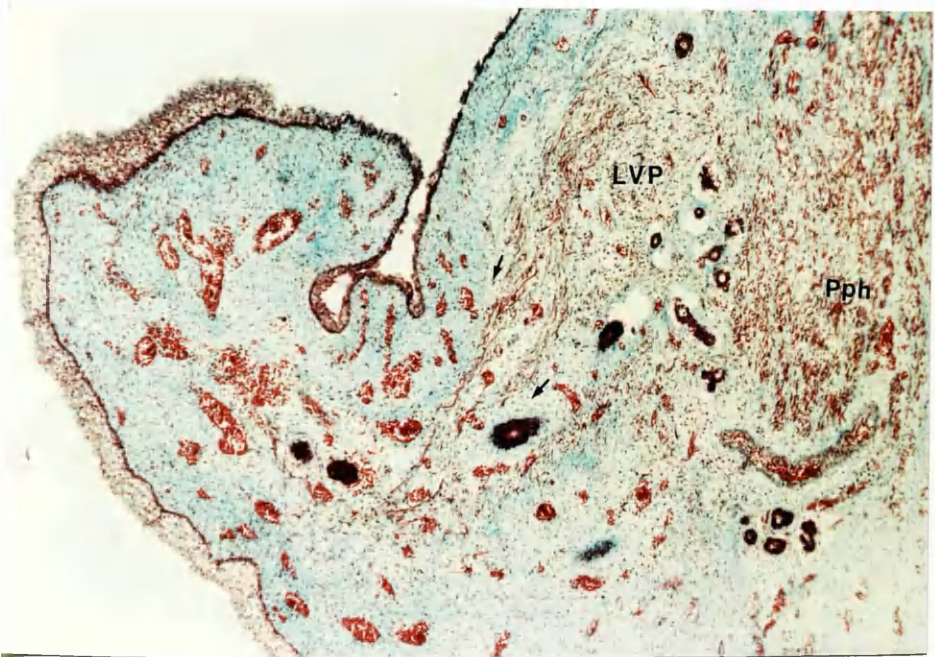
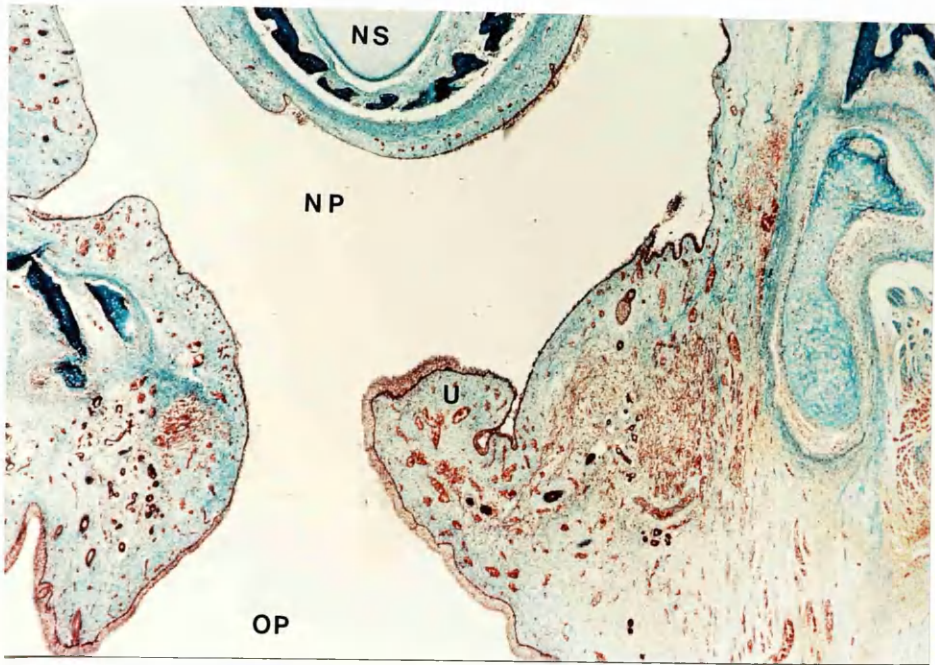


Fig.94a Transverse paraffin section through upper portion of levator veli palatini muscle. Stain for alkaline phosphatase (x 9).

Fig.94b Transverse section of mid portion of same muscle. Stain for alkaline phosphatase (x 9).

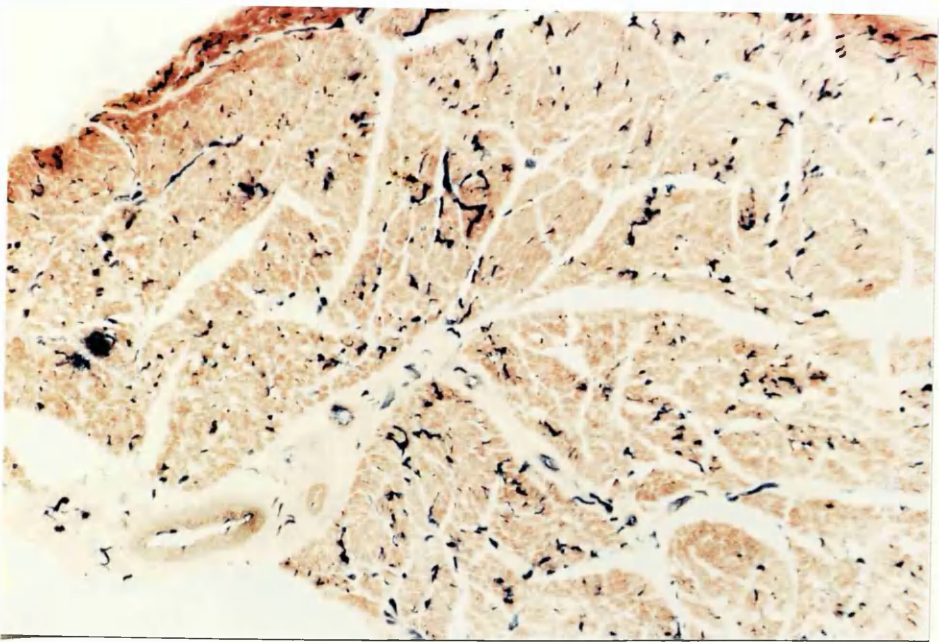
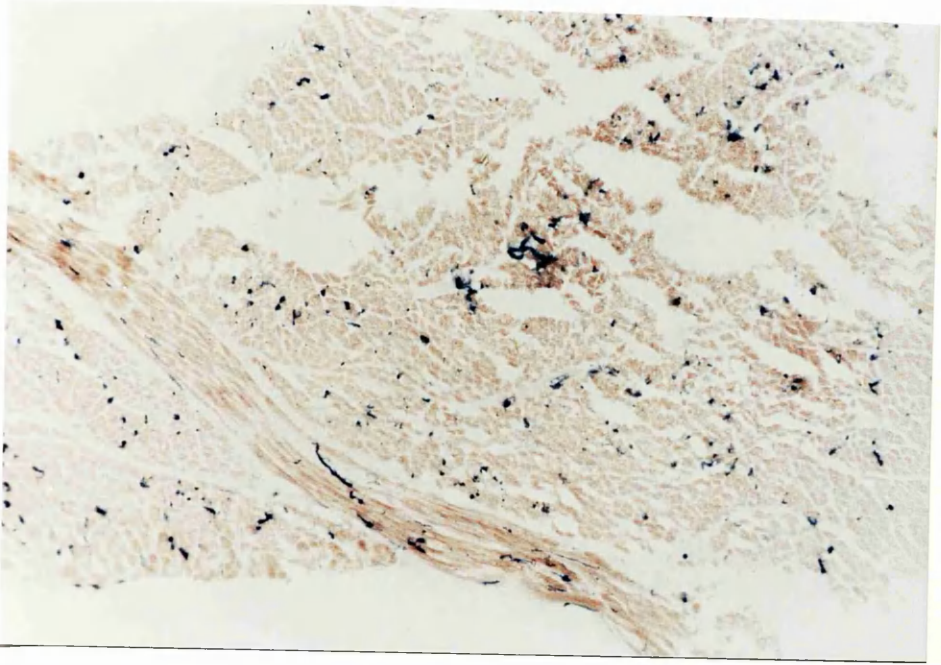


Fig.94c Transverse section through the medial portion of same muscle. Stain for alkaline phosphatase. Note how in Fig.94a no large vessel can be seen within muscle (x 9).

Fig. 95a Transverse paraffin section through lateral part of a levator specimen (aldehyde fuchsin, x 8).

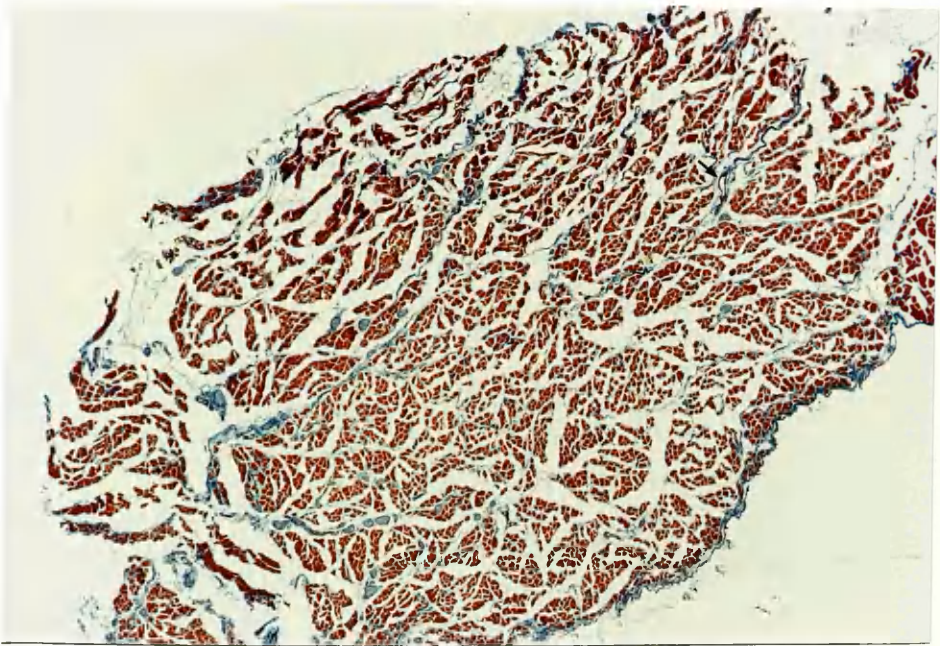
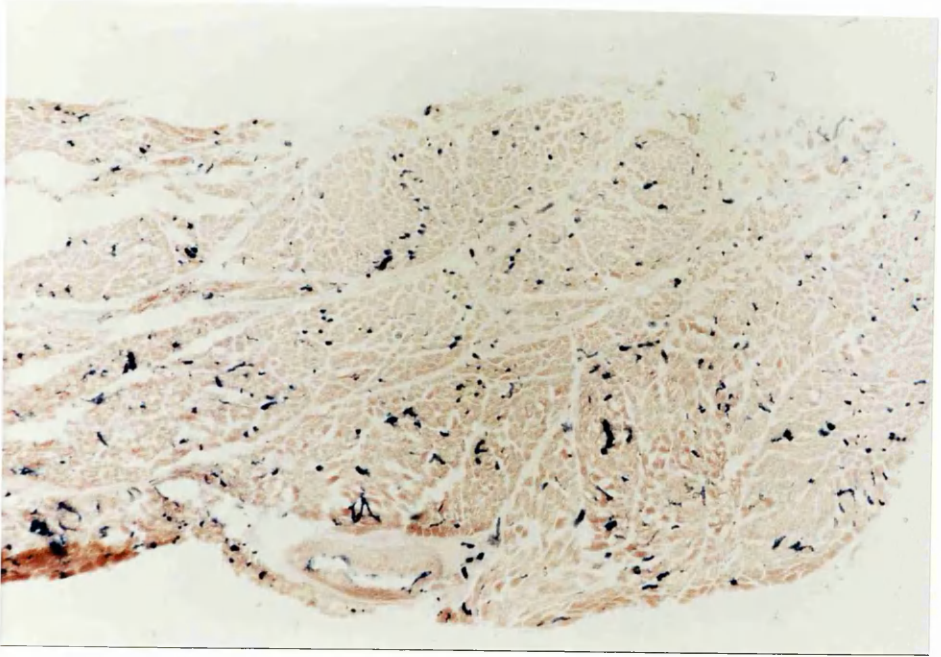


Fig.95b Transverse section through mid portion of levator (aldehyde fuchsin, x 8).

Fig. 95c Transverse section through the medial portion of levator (aldehyde fuchsin, x 11). In Fig. 95a small artery (arrowed) is present but nothing approaching size of vessel indicated by arrow in this figure.

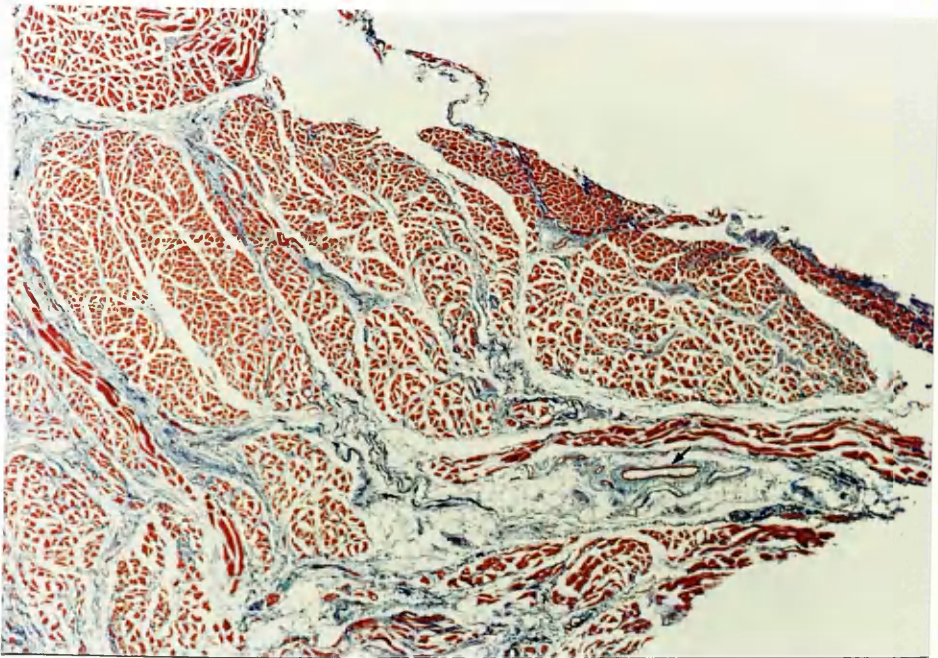
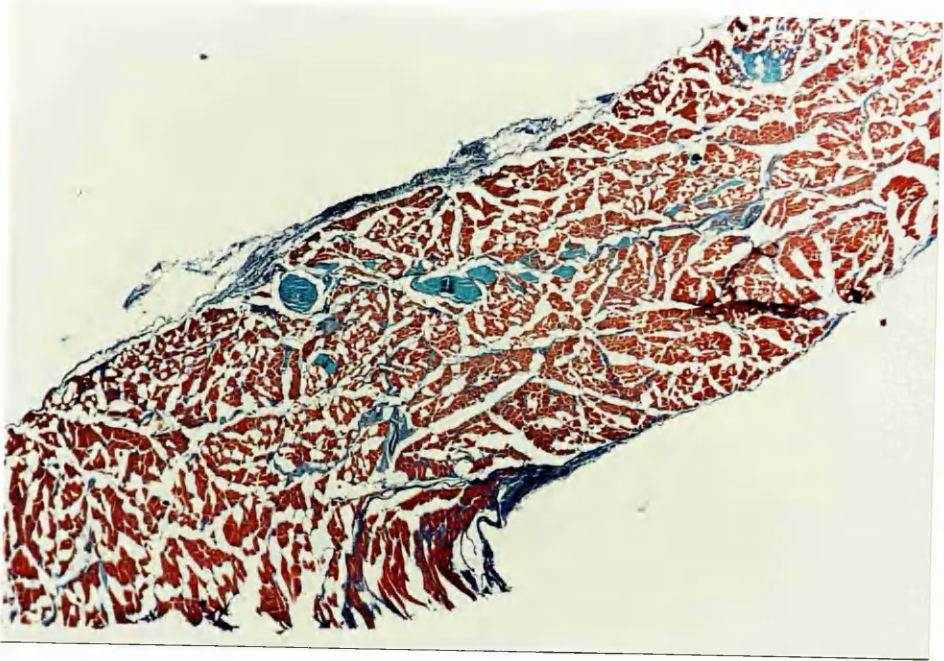

Fig.96 Frozen section of levator veli palatini muscle. Stained for ATPase. Dark type I and pale type IIb fibres are visible (x 20).

Fig.97 Frozen section of musculus uvulae. Stained for ATPase. Interspersed among fatty tissue are both pale and darkly staining fibres. (x 20).

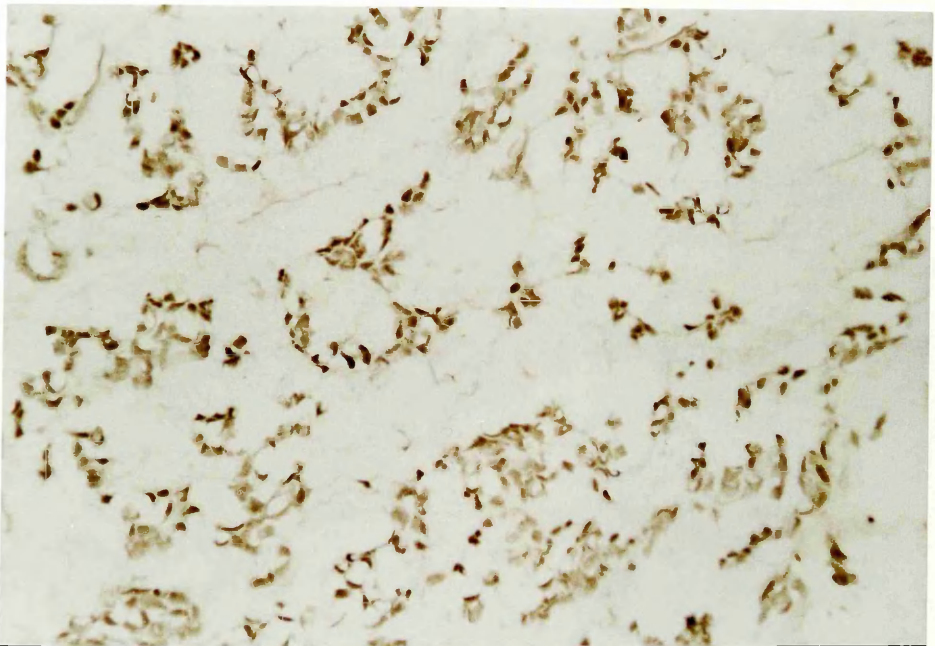
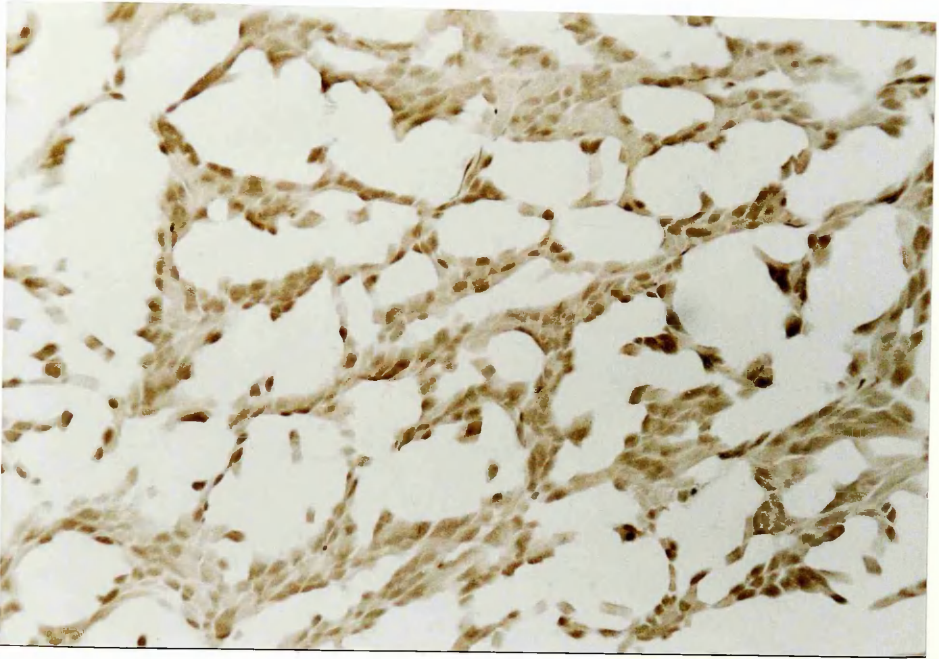


Fig.98 Frozen section of musculus uvulae. Same specimen as Fig.97.
Stained for NADH₂ reductase (x 17).

Fig.99 Frozen section of palatopharyngeus muscle. Stained for NADH₂.
Mainly darkly staining fibres are present in this field (x 20).

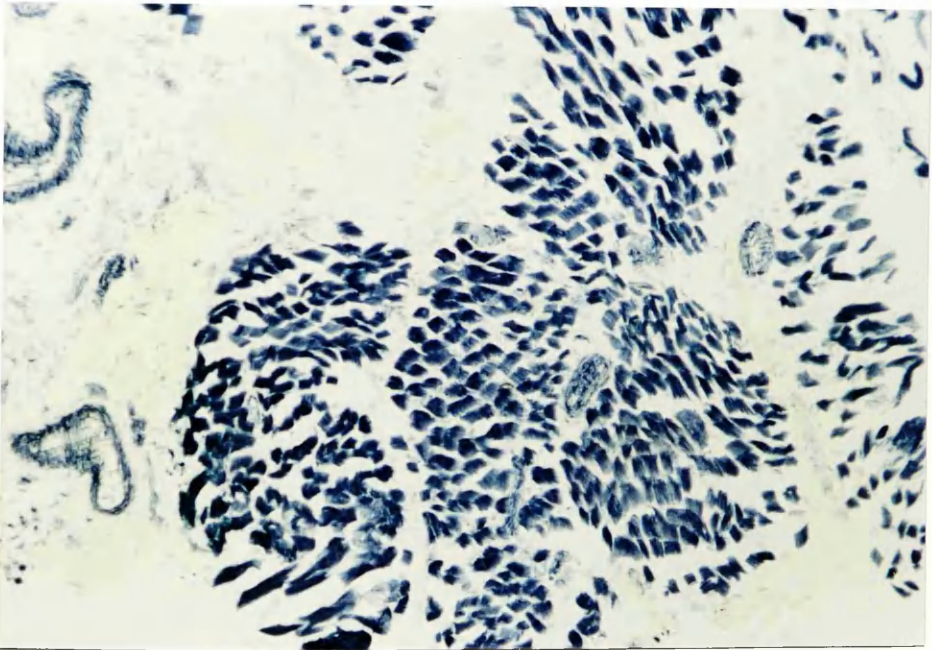
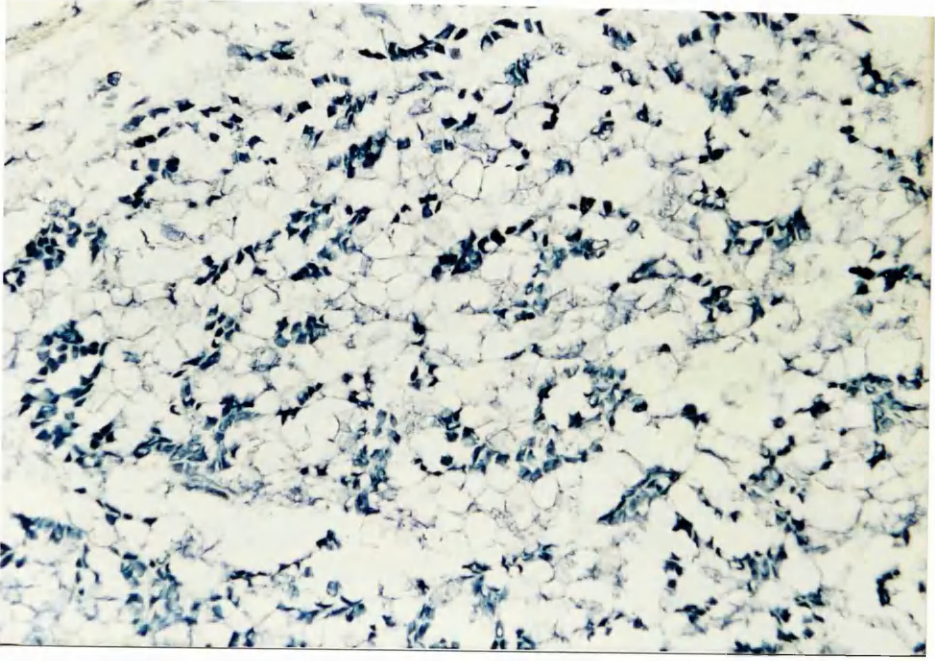


Fig.100 High power view of frozen section levator muscle stained for NADH₂, showing two fibre types - mainly darkly staining fibres to lower left and more pale fibres to upper right of field (x 40).

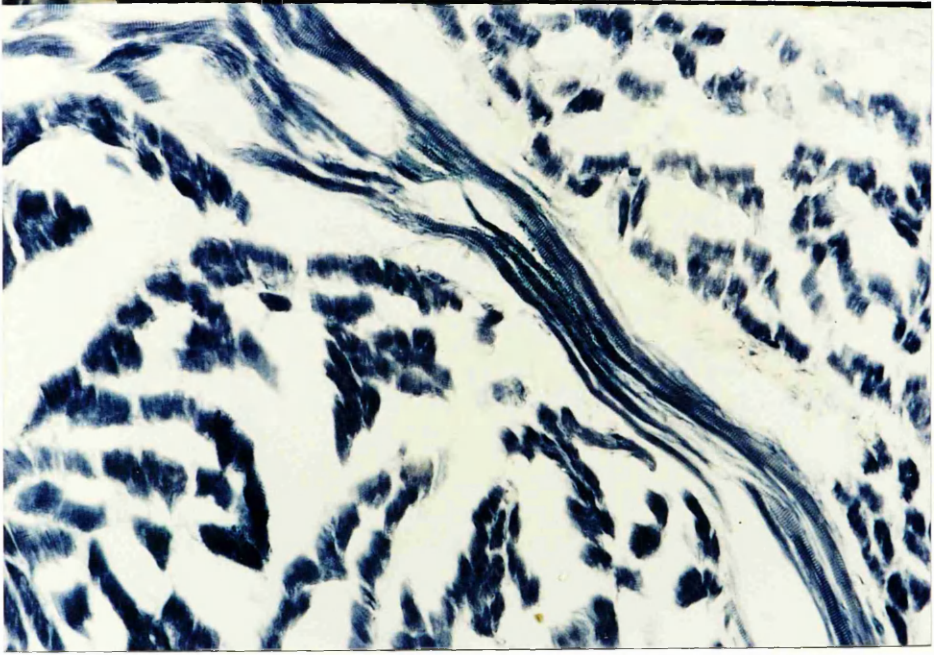


Fig.101a

Fig.101b

Fig.101c

Fig. 101a-c Lateral views of infant, child (3-4 years), and adult skulls. Note the increasing distance from skull base to the lower end of the lateral pterygoid plate with age.

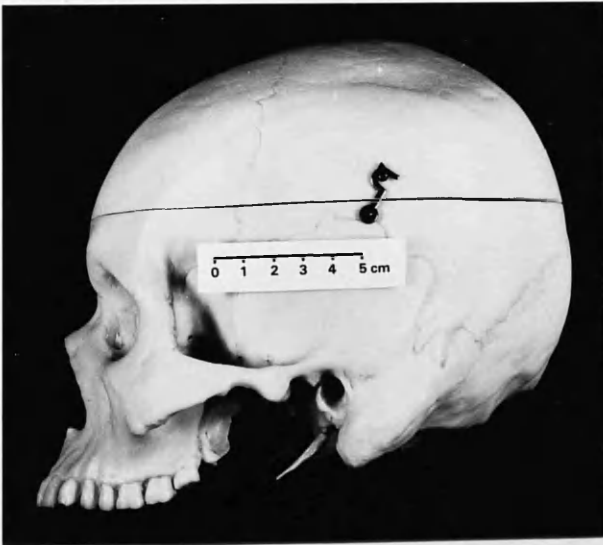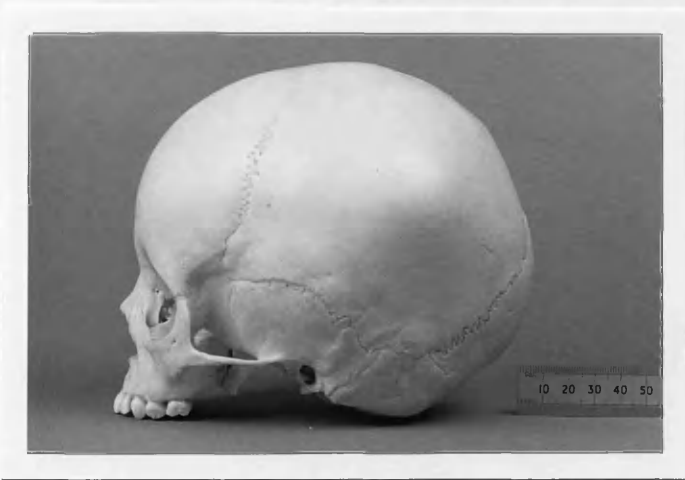


Fig. 102 Patterns of arterial supply to levator veli palatini muscle.

Fig. 102A Supply from ascending palatine and ascending pharyngeal arteries.

Fig. 102B Supply from ascending palatine alone.

Fig. 102C Supply from ascending pharyngeal artery alone.

Fig. 102D Supply from ascending pharyngeal and accessory meningeal.

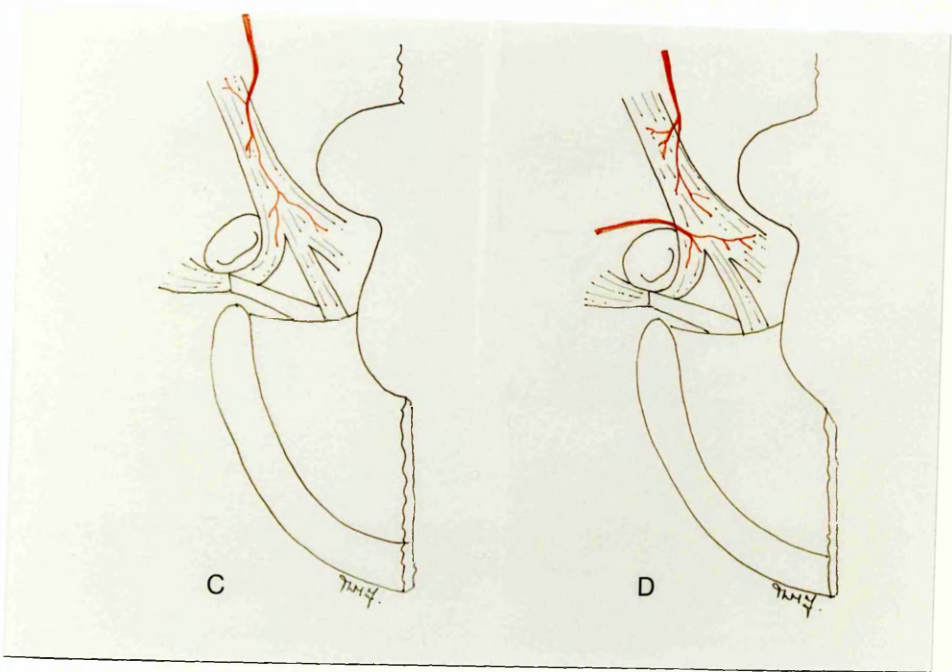
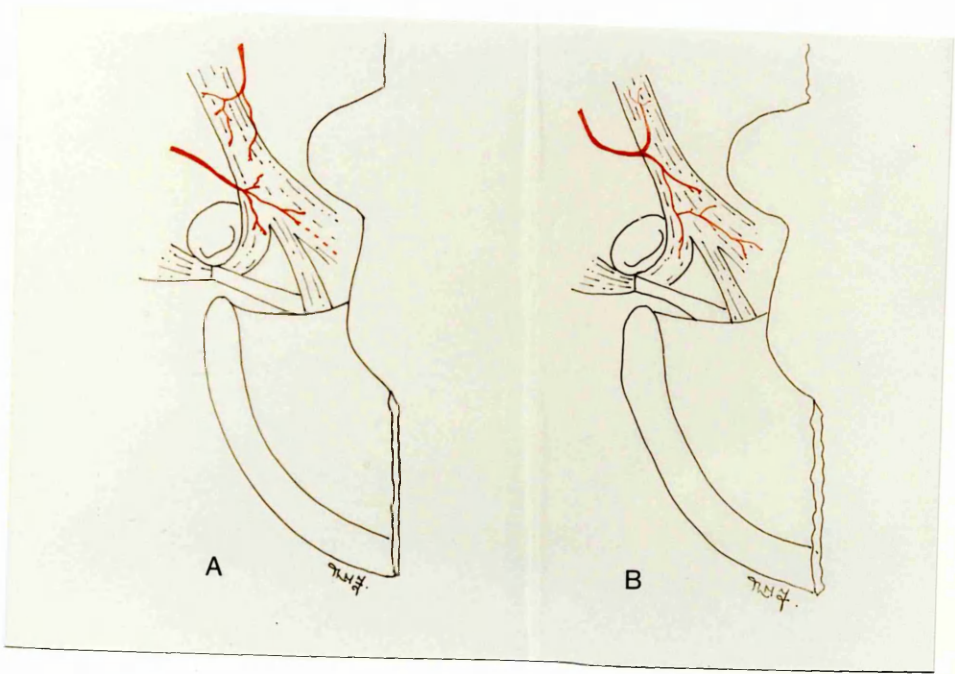


Fig. 103a

Fig.103b

Fig.103a,b Drawing of levator and palatopharyngeus muscle insertions in normal and cleft palate (after Kriens,1970).

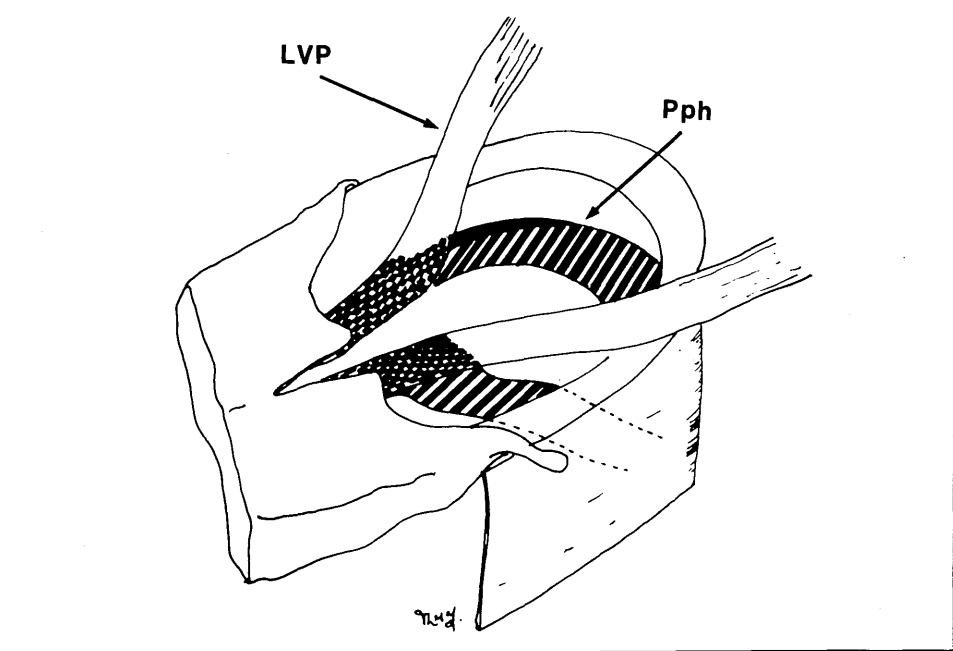
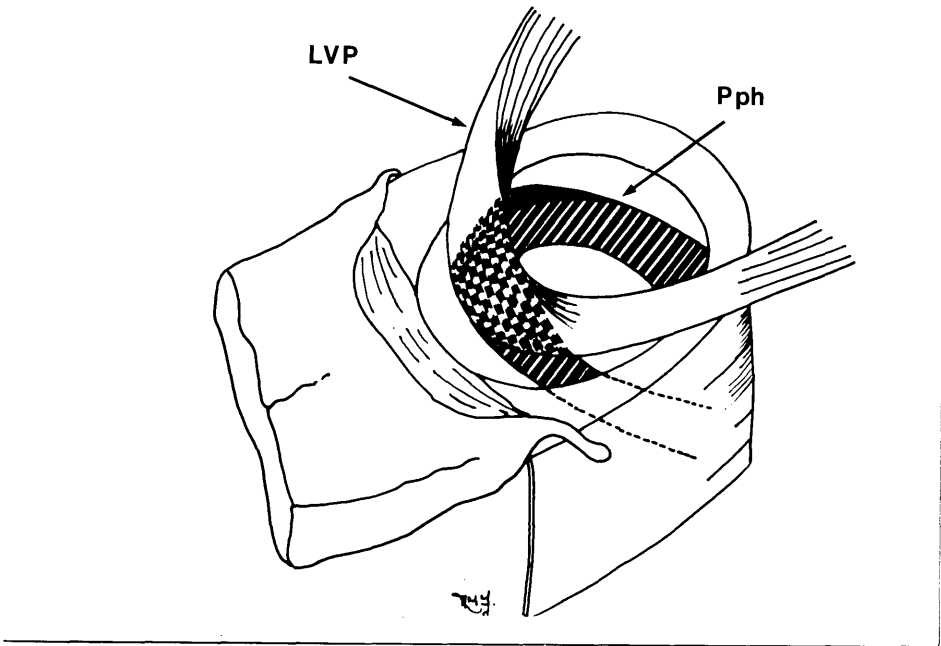


Fig.104a

Fig.104b

Fig.104a,b

Drawing of levator muscle insertion in normal and cleft palate (after Millard, 1980a).

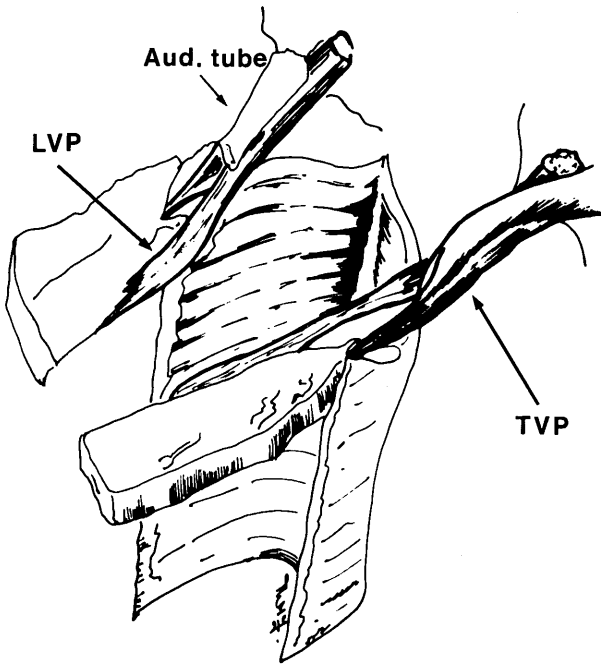
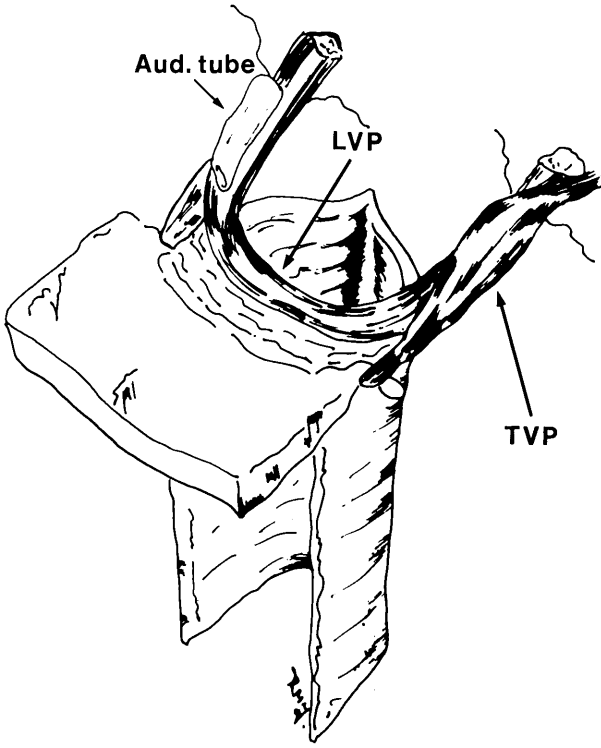


Fig.105a Intraoperative photograph showing infant with complete cleft of secondary palate (upper incisors at lower border of frame).

Fig.105b Edges of palatal cleft marked with Bonney's blue. Vomer also marked for raising a vomerine flap.

Fig.105c Cleft edges have been incised.

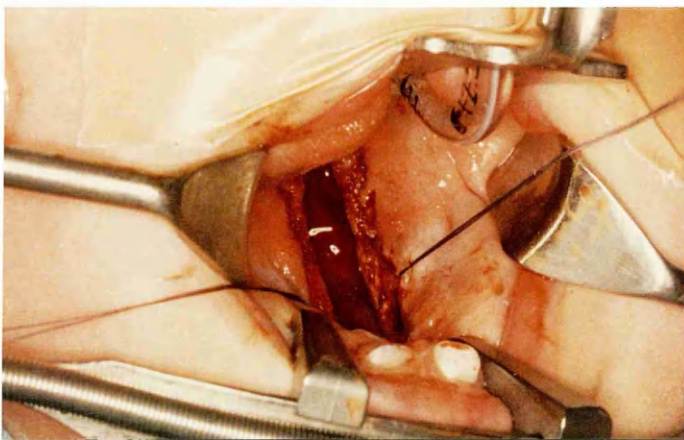
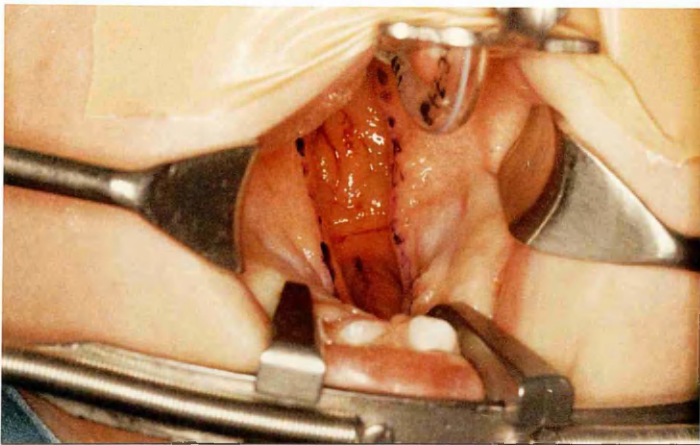
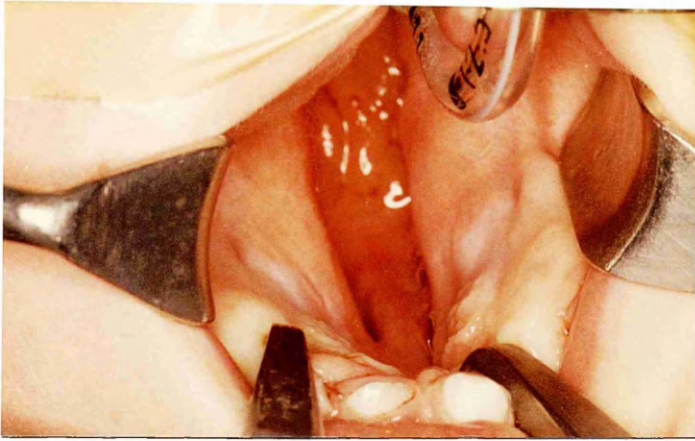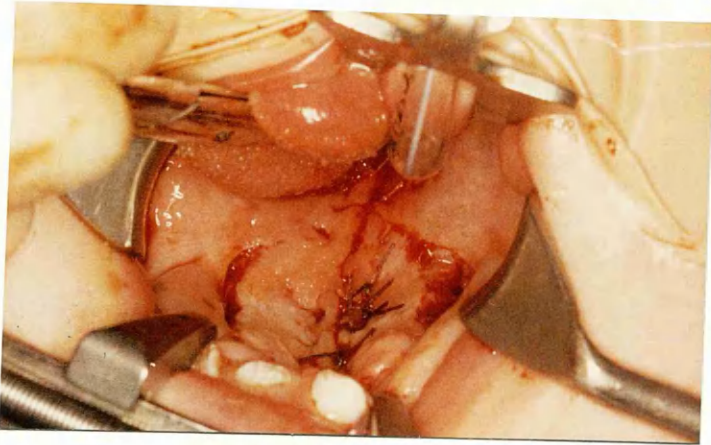
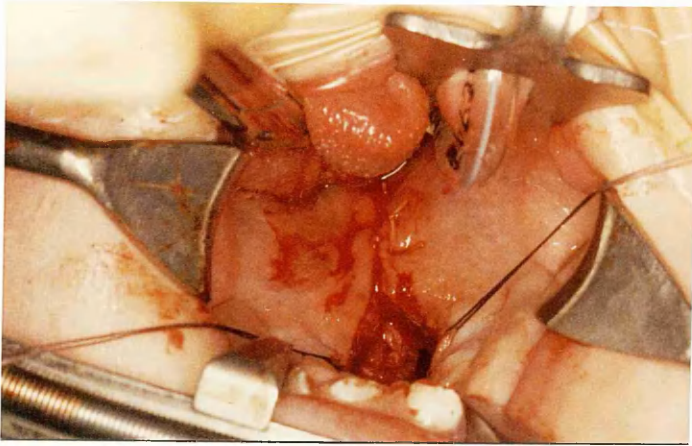
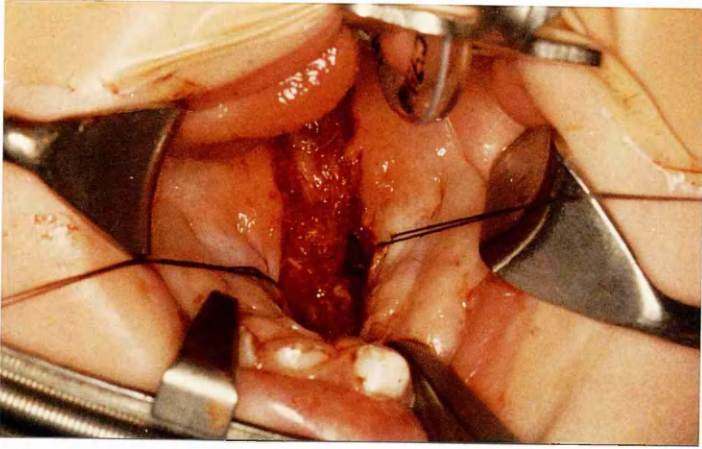


Fig.105d Nasal mucosal closure completed. Small tear in mucosa visible on right side.

Fig.105e Oral closure completed on soft palate without any lateral dissection.

Fig.105f Oral closure completed over hard palate. Lateral incisions have been required, but only minimal blunt dissection was performed posterior to left maxillary tuberosity.





GLANSON
UNIVERSITY
LIBRARY:

Abbreviations

A	aponeurosis
Alv	alveolus
a m	accessory meningeal artery
a p	ascending palatine artery
a ph	ascending pharyngeal artery
aud t	auditory tube
c c	common carotid artery
D	digastric muscle (posterior belly)
e c	external carotid artery
EP	epithelial pearl
f	facial artery
gl	glandular elements
GPF	greater palatine foramen
H	pterygoid hamulus
HP	hard palate
Hy	greater cornu hyoid bone
Hyp N	hypoglossal nerve
i c	internal carotid artery
IF	incisive fossa
L	lip
LN	lingual nerve
LPF	lesser palatine foramen
L Pt	lateral pterygoid muscle
L Pt P	lateral pterygoid plate
LVP	levator veli palatini muscle
m	maxillary artery
M	mandible
m m	middle meningeal artery
MN	mandibular nerve
MPS	midpalatal suture
M Pt	medial pterygoid muscle
M Pt P	medial pterygoid plate

MU	musculus uvulae
N	nerve
NP	nasopharynx
NS	nasal septum
OP	oropharynx
PB	horizontal plate of palatine bone
PBF	pharyngobasilar fascia
Pet T	petrous temporal bone
PMS	premaxillary "suture"
Pph	palatopharyngeus muscle
PPM	palatine process maxilla
PPW	posterior pharyngeal wall
PS	secondary palatal shelf
S	styloid process
SC	superior constrictor muscle
SG	styloglossus muscle
SH	stylohyoid muscle
SMG	submandibular gland
SP	soft palate
SPh	stylopharyngeus muscle
Sp Sph	spine of sphenoid bone
s thy	superior thyroid artery
T	tongue
TG	tooth germ
Thy	thyroid gland
TVP	tensor veli palatini muscle
U	uvula