

Intravascular absorption syndrome : case report of a life-threatening complication during hysteroscopy

R. NIEUWENHUIZEN (*), A.F. KALMAR (*), N. VAN DER VEKENS (*), J. HEERMAN (*), M. CASTEELS (**), H. VANOVERSCHELDE (*)

Abstract : A 40-year old, healthy woman underwent hysteroscopic endometrial ablation with a bipolar electrocautery using 0.9% saline as distension fluid. After 45 minutes of surgery, arterial oxygen saturation decreased and liquid was obstructing the laryngeal mask. With an estimated total fluid deficit of 5000 mL, fluid overload was suspected and the patient's trachea was intubated. Furosemide was given intravenously and a urinary catheter was inserted. The intra-abdominal pressure, measured through the urinary catheter, was 28 mmHg. As ventilation became unfeasible, the patient became cyanotic and no clear pulse could be detected, cardiopulmonary resuscitation was started. In order to decrease the abdominal pressure, a laparotomy was performed and extracorporeal membrane oxygenation was started to increase the arterial oxygenation. After one week in the Intensive Care Unit, the patient was extubated and gradually recovered without further complications nor residual morbidity.

The pathophysiological aspects of the evolution to severe pulmonary edema due to massive fluid translocation during operative hysteroscopy, and the rationale behind the successful interventions are being discussed.

Close continuous monitoring of the amount of fluid deficit should be performed to avoid severe fluid overload during operative hysteroscopy. Extracorporeal membrane oxygenation can be life-saving to bridge the period of desaturation until standard treatment suffices to provide adequate oxygenation.

Key words : Intravascular absorption syndrome, volume overload, hysteroscopy, pulmonary edema, ECMO.

INTRODUCTION

Operative hysteroscopy has successfully replaced hysterectomy for multiple indications, including treatment of congenital anomalies, endometrial polyps, cervical and uterine neoplasia and submucous myomas (1). Although complications are rare (incidence <1%)(2), anesthesiologists and surgeons should be aware that, even during such a minimally invasive procedure, life-threatening complications can suddenly arise. We report a case

of massive pulmonary edema caused by severe fluid overload during operative hysteroscopy.

CASE REPORT

The patient gave written consent to publish this case report, read the article and confirmed its content. A 40-year old, healthy female underwent an operative hysteroscopy for endometrial ablation under general anesthesia. She had no significant medical history and preoperative laboratory test results were normal. After induction of anesthesia with propofol and sufentanil, a laryngeal mask airway was placed, and anesthesia was maintained with sevoflurane. Monitoring consisted of electrocardiography (ECG), end-tidal carbon dioxide (EtCO₂), non-invasive blood pressure (NIBP) and pulse oximetry (SpO₂). The patient was continuously in supine position with the legs elevated and placed in the leg holders. Saline 0.9 % was used as distention and irrigation medium with an irrigation pressure of 350 mmHg. A total of 12000 mL of rinsing fluid was instilled, and at the end of the 30-minute procedure, the recollected volume was 7000 mL. The endometrial resection with bipolar electrocautery necessitated coagulation of a wide area of the endometrial surface due to significant blood loss in the cavum uteri. During the total procedure, 2-3 instrument insertions were performed for specimen removal.

Rik NIEUWENHUIZEN, MD, Alain Frederic KALMAR, MD. MsC., PhD., Nicky VAN DER VEKENS, DVM, PhD, Jan HEERMAN, MD, Martine CASTEELS, MD, Henk VANOVERSCHELDE, MD.

(*) Department of Anesthesia and Critical Care Medicine, Maria Middelaers Hospital, Ghent, Belgium

(**) Department of Gynecology, Maria Middelaers Hospital, Ghent, Belgium

Corresponding author : Alain Frederic Kalmar, Department of Anesthesia and Critical Care Medicine, Maria Middelaers Ziekenhuis, Ghent, Belgium.
E-mail : alainkalmar@gmail.com

Paper submitted on Sep 06, 2018 and accepted on May 12, 2019.

Conflict of interest : None

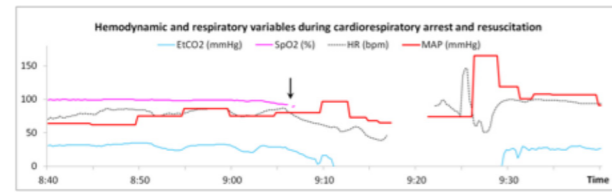


Fig. 1. — Evolution of hemodynamic and respiratory variables during cardiorespiratory arrest and resuscitation. Arrow : moment of drape removal and observation of facial edema. Several data points are missing owing to the resuscitation efforts and alternate ventilation devices.

After an uneventful 30 minutes of surgery, the tidal volume (TV) and EtCO₂ decreased from 230 to 150 mL and from 34 mmHg to 24 mmHg, respectively over a period of 10 minutes, and the SpO₂ and NIBP also gradually decreased. The drapes were removed (Figure 1, arrow) from the face for visual inspection and chest auscultation, immediately showing signs of facial oedema with severely thickened and cyanotic lips. Further evaluation showed a general oedema of the neck, conjunctiva and face, and protrusion of the tongue. Chest auscultation revealed significantly dampened symmetrical rhonchi and crepitations. The abdomen was tense but compressible. The auscultation and the absence of subcutaneous emphysema suggested a pneumothorax unlikely. Closer examination revealed clear liquid coming out of the laryngeal mask. Pulmonary edema due to severe fluid overload was suspected and an endotracheal tube was placed. Cardiac and abdominal echography revealed a normal ventricular function, no signs of venous air embolism, bilateral pleural effusion and considerable free fluid around the spleen and liver. No clear ECG changes were observed. Invasive ventilation with peak pressure of 43 cm H₂O resulted

in a TV of merely 204 ml. Bradycardia set in for which atropine 0.5 mg was administered. Cyanosis worsened and no clear carotid pulse could be felt, for which cardiopulmonary resuscitation was initiated in accordance with the ALS guidelines. Adrenaline boli of 1 mg were given. Return of spontaneous circulation occurred after 10 minutes of CPR. A urinary catheter was inserted, showing an abdominal pressure of 28 mmHg, and furosemide 40 mg IV was given resulting in a 1400 ml urine production within 60 minutes. Because of the dramatic blood gas values and the worsening cyanosis despite maximal invasive ventilation, we considered an instantaneous decrease of the abdominal pressure imperative. Even though to the best of our knowledge, there is no scientific proof of the value of a laparotomy in this particular clinical indication, a prompt intervention to improve oxygenation was required, and we deemed no alternative options sufficient. Therefore, a laparotomy was performed, after which the omentum majus expulsed and an estimated 700ml of clear fluid could be evacuated. This immediately enabled a TV increase to 389 ml. The ventilatory pressure was subsequently decreased in accordance to Acute Respiratory Distress Syndrome (ARDS) prevention guidelines (3). At this moment, a SpO₂ of 64% with an EtCO₂ of 22 mmHg and an NIBP of 135/80 mmHg was measured. To increase the oxygenation level, veno-arterial extracorporeal membrane oxygenation (ECMO) was started and the SpO₂ gradually increased to 96%. Blood gas analysis before and after laparotomy and ECMO are shown in Table 1. The patient was admitted to the ICU where reduction of edema permitted removal of the ECMO after 6 hours. The chest x-ray showed bilateral consolidations (Figure 2A), consistent with ARDS. After one week, these consolidations were

Table 1

Blood gas analysis before and after laparotomy and ECMO

Laboratory parameter	Normal values	10 min before laparotomy	10 min after laparotomy	10 min before start ECMO	25 min after start ECMO
pH	7.35 - 7.45	6.90	6.93	7.04	7.32
PCO ₂ (mmHg)	35 - 48	74	61	65	34
PO ₂ (mmHg)	83 - 108	31	46	66	278
Base excess (mmol/L)	-2.0 - 3.0	-18.5	-19.5	-13.2	-7.8
Sodium (mmol/L)	136 - 145	141	141	143	143
Potassium (mmol/L)	3.5 - 5.1	1.9	2.2	1.9	2.2
Chloride (mmol/L)	98 - 107	117	115		
Calcium (mmol/L)	1.15 - 1.33	0.82	0.85	0.77	0.94
Glucose (mg/dL)	74 - 106	197	205		
Lactate (mg/dL)	2.24 - 6.76	29	26	24	25
Haemoglobine (g/dl)	12.0 - 15.0	10.6	11.0		

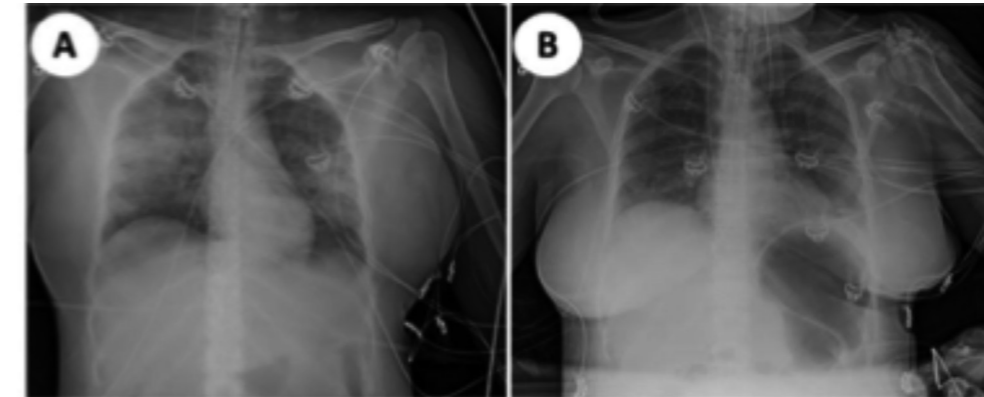


Fig. 2. — Radiographic chest image after the procedure (A) shows increased consolidations in both lung fields. After one week (B) the densities were cleared.

sufficiently diminished (Figure 2B), the patient could be extubated and subsequently completely recovered gradually over several weeks. The pathology report of the uterine tissue described adenomyosis as underlying pathology.

DISCUSSION

Absorption of an excessive amount of distension fluid during hysteroscopy can lead to hyponatremia, intravascular fluid overload and pulmonary edema. Sodium chloride as distension fluid does not cause hyponatremia, but can cause hyperchloremia. Two ways of fluid translocation most probably occurred in this case: direct flow of rinsing fluid to the abdominal cavity through the fallopian tubes, and intravascular resorption in the uterus. The risk of this life-threatening complication depends on the type of anesthesia, type and duration of surgery and the amount and nature of the distension fluid (4). In this case, normal saline was used during a 30-minute bipolar electrosurgery under general anesthesia. Normal saline, compared to none-electrolyte containing solutions, has the notable disadvantage of dissipating the current and hindering electrocautery with monopolar RF-systems. The use of bipolar instruments however permits the benefit of saline for such procedures (5). A primary advantage of the use of this isotonic fluid is that it incurs only limited electrolyte disturbances (5). Still, fluid overload may occur, especially at higher intrauterine pressure and when a lot of blood vessels are transected. Intravasation can occur when the intrauterine pressure is greater than the patient's mean arterial pressure (6,7). Intravascular absorption might also be higher during gas anesthesia than spinal anesthesia owing to the vasodilating effect of inhaled anesthetics on the uterine vessels (8).

The pathophysiology of pulmonary edema can be understood as the net result of the Starling forces across the pulmonary microvasculature, where the net driving force (NDF) is governed by tissue permeabilities, the transmural hydrostatic pressure difference and the oncotic pressure difference.

$$NDF = KhA(Pc - Pi) - \sigma(\pi_c - \pi_i)$$

The transmural hydrostatic pressure force is determined by the fluid permeability of the capillary wall (Kh), the capillary surface area (A), and the difference between the capillary (Pc) and interstitial (Pi) hydrostatic pressure, while the oncotic pressure force is determined by the reflection coefficient for plasma proteins (σ) and the difference between the capillary (π_c) and interstitial (π_i) oncotic pressure (9).

The NDF of fluid across the pulmonary capillary membrane is therefore governed by the net balance between the transcapillary hydrostatic pressure (Pc-Pi), causing fluid to flow out of the capillary, and the transcapillary protein osmotic pressure ($\pi_c - \pi_i$), which acts to retain fluid within the capillary (10).

As such, different pathophysiological entities of pulmonary edema exist: permeability edema, caused by a disruption of the normal alveolar-capillary barrier, and hemodynamic pressure edema, caused by an increase in the capillary hydrostatic pressure difference or a decrease in the capillary oncotic pressure. In this case of volume overload, the pulmonary edema was primarily induced by a combined increase in capillary hydrostatic pressure and a decrease in capillary oncotic pressure due to dilution of the plasma proteins with saline 0.9%. In addition, the increased hydrostatic capillary pressure and increased hydraulic flow through the capillary glycocalyx is described to deform the endothelial

glycosaminoglycan fibers, which activates the endothelial nitric oxide synthase, leading to barrier dysfunction with eventually additional permeability edema (11).

A fluid deficit of no more than 2500 mL fluid has been recommended, and guidelines prescribe that the surgery should be stopped if this is exceeded (4,12,13). In the presented case, because of focussed attention on challenging hemorrhaging control, the surgeon only became aware of the fluid deficit at the end of this relatively short procedure. Intrauterine bleeding is conventionally controlled by coagulation, while also the pressure of the distension media themselves may yield enough pressure to cause hemostasis during a procedure. In the literature, procedures with a particular risk for intravasation of irrigation fluid are reported to be resection of fibroids or myometrial trauma that results in open uterine venous channels or unidentified perforations (14). Still, in this procedure for endometrium ablation – albeit over a large surface – very fast translocation of irrigation fluid occurred. A noteworthy consideration is that the presence of adenomyosis may have contributed to the exceptional fluid intravasation. Limiting the pressure of the irrigation fluid will correspondingly decrease the amplitude of the fluid shift. In this case, the irrigation fluid pressure was set at a level greatly exceeding recommended pressure (13). Secondly, close monitoring of the fluid balance during and after each hysteroscopic surgery is, therefore, necessary to timely detect and avert dangerous complications. Whereas isotonic irrigation fluid bears a minimal risk of severe electrolyte disturbance, the risk of fluid overload still rationalizes the use of precise irrigation instruments with accurate pressure and inflow/outflow measurement. Moderating the irrigation pressure to the strictly necessary level for adequate visualisation and working conditions will arguably significantly decrease intravasation of fluid and therefore the risk of complications.

The emergency laparotomy had a particularly beneficial effect on the ventilation performance by virtue of an immediate decrease of the intra abdominal pressure, permitting improved downward expansion of the diaphragm, resulting in improved tidal volumes with lower ventilatory pressure. Secondly, the reduction in intra abdominal pressure immediately improved the compliance of the splanchnic capacitance vessels and a prompt reduction in venous return, CVP and pulmonary artery pressure. Thirdly, a substantial amount of abdominal clear water could be removed directly by suction.

When observing the clinical deterioration as described, the anaesthesiologist should be aware of alternative causes of hemodynamic collapse. While in this case fluid overload was quickly considered most plausible, given facial swelling and echography information, anaesthesiologists and surgeons must be vigilant towards the venous air embolism (15) (VAE) or pneumothorax diagnosis, and consider the primary symptoms as observed in this case as caused by VAE until proven otherwise, in which case a completely different therapeutic approach would be mandatory. Particularly during procedures such as hysteroscopic endometrial resection with pressurised irrigation fluid, a large resection surface, electrocautery and repeated instrumentations, VAE is probably more common than anticipated by many. VAE will cause a sudden drop in EtCO₂ followed by a gradual decline in SpO₂ (16). In hypervolemic pulmonary oedema, the decrease in EtCO₂ and SpO₂ will both be gradual. Also bronchospasm, pulmonary oedema and cardiac arrest can occur after VAE. In our case, echocardiography rapidly confirmed fluid overload. We advise that echocardiography is performed swiftly in such circumstances to help establish the diagnosis: a dilated right ventricle would suggest pulmonary embolism, biventricular dilatation would suggest hypervolemia and air-bubbles in the right ventricle and pulmonary artery would suggest air embolism (15).

When life-threatening hypoxemia due to fluid overload pulmonary edema occurs, ECMO can temporarily be used until edema reduction measures are effective and conventional intensive support suffices.

CONCLUSION

While hysteroscopy is mostly a low-risk routine procedure, this case emphasizes the importance of moderation of the fluid pressure, continuous monitoring and vigilance for fluid overload, and of the close availability for immediate cardiopulmonary support and intensive care therapy.

References

1. Preuthipan S. 2005. Role of hysteroscopy in modern gynaecology. *J. Med. Assoc. Thai.* 88: S85-92.
2. McGurgan PM and McIlwaine P. 2015. Complications of hysteroscopy and how to avoid them. *Best Pract. Res. Clin. Obstet. Gynaecol.* 29: 982-93.
3. Fan E., Del Sorbo L., Goligher EC., Hodgson CL., Munshi L., Walkey A.J. and Adhikari NKJ. et al. 2017. An Official American Thoracic Society/European Society of Intensive Care Medicine/Society of Critical Care Medicine Clinical

- Practice Guideline: Mechanical ventilation in adult patients with Acute Respiratory Distress Syndrome. *Am. J. Respir. Crit. Care Med.* 195: 1253-63.
4. Jackson S. and Lampe G. 1995. Operative hysteroscopy intravascular absorption syndrome. *West. J. Med.* 162: 53-54.
 5. AAGL Advancing Minimally Invasive Gynecology Worldwide, Munro MG., Storz K., Abbott JA., Falcone T., Jacobs VR. and Muzii L. et al. 2013. AAGL Practice Report: Practice guidelines for the management of hysteroscopic distending media. *J. Minim. Invasive Gynecol.* 20: 137-418.
 6. Cholkeri-Singh A. and Sasaki K. 2016. Hysteroscopy safety. *Curr. Opin. Obstet. Gynecol.* 28: 250-254.
 7. Aas-Eng M.E., Langebrenke A. and Hudelist G. 2017. Complications in operative hysteroscopy-is prevention possible? *Acta Obstet. Gynecol. Scand.* 96: 1399-1403.
 8. Moharram EE., El Attar AM. and Kamel MA. 2017. The impact of anesthesia on hemodynamic and volume changes in operative hysteroscopy; a bioimpedance randomized study. *J. Clin. Anesth.* 38: 59-67.
 9. Miller R., Eriksson L., Fleisher L., Wiener-Kronish J. and Young W. 2005. *Anesthesia Management* In: Miller RD, editor. *Miller's Anesthesia*. 7th ed. pp. 1726, Philadelphia: Elsevier Churchill Livingstone.
 10. Murray JF. 2011. Pulmonary edema: pathophysiology and diagnosis. *Int. J. Tuberc. Lung. Dis.* 15: 155-160.
 11. Collins SR., Blank RS., Deatherage LS. and Dull RO. 2013. The endothelial glycocalyx: emerging concepts in pulmonary edema and acute lung injury. *Anesth. Analg.* 117: 664-674.
 12. Berg A., Sandvik L., Langebrenke A. and Istre O. 2009. A randomized trial comparing monopolar electrodes using glycine 1.5% with two different types of bipolar electrodes (TCRis, Versapoint) using saline, in hysteroscopic surgery. *Fertil. Steril.* 91: 1273-1278.
 13. Umranikar S., Clark TJ., Saridogan E., Miligkos D., Arambage K. and Torbe E. et al. 2016. BSGE/ESGE guideline on management of fluid distension media in operative hysteroscopy. *Gynecol. Surg.* 13: 289-303.
 14. Jansen FW., Vredevoogd C., van Ulzen K. Hermans J., Trimbos JB. and Trimbos-Kemper TC. 2000. Complications of hysteroscopy: a prospective, multicenter study. *Obstet Gynecol.* 96: 266-70.
 15. Storm BS., Andreasen S., Hovland A. and Nielsen EW. 2017. Gas Embolism During Hysteroscopic Surgery?: Three Cases and a Literature Review. *AA Case Rep.* 9: 140-143.
 16. Munro MG and Christianson LA. 2015. Complications of Hysteroscopic and Uterine Resectoscopic Surgery. *Clin. Obstet. Gynecol.* 58: 765-797.