

## CLINICAL RESEARCH STUDIES

From the Society for Vascular Surgery

# The size of juxtaluminal hypoechoic area in ultrasound images of asymptomatic carotid plaques predicts the occurrence of stroke

Stavros K. Kakkos, MD, PhD, RVT,<sup>a</sup> Maura B. Griffin, PhD,<sup>a</sup> Andrew N. Nicolaides, FRCS, PhD,<sup>a</sup> Efthymoulos Kyriacou, PhD,<sup>b</sup> Michael M. Sabetai, MD, PhD,<sup>a</sup> Thomas Tegos, MD, PhD,<sup>a</sup> Gregory C. Makris, MD,<sup>a,c</sup> Dafydd J. Thomas, MD, FRCP,<sup>d</sup> and George Geroulakos, MD, PhD,<sup>a,c</sup> for the Asymptomatic Carotid Stenosis and Risk of Stroke (ACSRS) Study Group,\* London, United Kingdom; and Limassol, Cyprus

**Objective:** To test the hypothesis that the size of a juxtaluminal black (hypoechoic) area (JBA) in ultrasound images of asymptomatic carotid artery plaques predicts future ipsilateral ischemic stroke.

**Methods:** A JBA was defined as an area of pixels with a grayscale value <25 adjacent to the lumen without a visible echogenic cap after image normalization. The size of a JBA was measured in the carotid plaque images of 1121 patients with asymptomatic carotid stenosis 50% to 99% in relation to the bulb (Asymptomatic Carotid Stenosis and Risk of Stroke study); the patients were followed for up to 8 years.

**Results:** The JBA had a linear association with future stroke rate. The area under the receiver-operating characteristic curve was 0.816. Using Kaplan-Meier curves, the mean annual stroke rate was 0.4% in 706 patients with a JBA <4 mm<sup>2</sup>, 1.4% in 171 patients with a JBA 4 to 8 mm<sup>2</sup>, 3.2% in 46 patients with a JBA 8 to 10 mm<sup>2</sup>, and 5% in 198 patients with a JBA >10 mm<sup>2</sup> ( $P < .001$ ). In a Cox model with ipsilateral ischemic events (amaurosis fugax, transient ischemic attack [TIA], or stroke) as the dependent variable, the JBA (<4 mm<sup>2</sup>, 4-8 mm<sup>2</sup>, >8 mm<sup>2</sup>) was still significant after adjusting for other plaque features known to be associated with increased risk, including stenosis, grayscale median, presence of discrete white areas without acoustic shadowing indicating neovascularization, plaque area, and history of contralateral TIA or stroke. Plaque area and grayscale median were not significant. Using the significant variables (stenosis, discrete white areas without acoustic shadowing, JBA, and history of contralateral TIA or stroke), this model predicted the annual risk of stroke for each patient (range, 0.1%-10.0%). The average annual stroke risk was <1% in 734 patients, 1% to 1.9% in 94 patients, 2% to 3.9% in 134 patients, 4% to 5.9% in 125 patients, and 6% to 10% in 34 patients.

**Conclusions:** The size of a JBA is linearly related to the risk of stroke and can be used in risk stratification models. These findings need to be confirmed in future prospective studies or in the medical arm of randomized controlled studies in the presence of optimal medical therapy. In the meantime, the JBA may be used to select asymptomatic patients at high stroke risk for carotid endarterectomy and spare patients at low risk from an unnecessary operation. (*J Vasc Surg* 2013;57:609-18.)

Risk stratification for stroke in patients with asymptomatic carotid artery stenosis is a matter of active research, and despite decades of research, no uniform agreement on prognostic factors has been achieved. Several factors that have been proposed to predict stroke in patients with asymptomatic carotid stenosis and contribute to risk stratification

include the severity of stenosis,<sup>1</sup> echolucent (hypoechoic) plaque type,<sup>2-5</sup> low grayscale median (GSM),<sup>6,7</sup> increased percentage of echolucent plaque components,<sup>7</sup> clinical risk factors,<sup>6</sup> brain infarction on computed tomography,<sup>8</sup> and the presence of discrete white areas (DWAs) without acoustic shadowing.<sup>6</sup>

From the Department of Vascular Surgery, Imperial College, London<sup>a</sup>; Frederick University, Limassol<sup>b</sup>; the Department of Vascular Surgery, Ealing Hospital, London<sup>c</sup>; and the Department of Neurology, St. Mary's Hospital, London.<sup>d</sup>

\*The full list of the study investigators is shown in the Appendix (online only).

Supported by a grant from the European Commission (Biomed II) Program (PL 650629) for the first 3 years and subsequently by a grant from the CDER Trust (United Kingdom), 30 Weymouth Street, London W1G 7BS, United Kingdom.

Author conflict of interest: Drs Nicolaides and Kyriacou are consultants to Iconsoft International Limited and own shares with the company. The other authors have no conflicts to declare.

Presented at the 2012 Vascular Annual Meeting of the Society for Vascular Surgery, National Harbor, Md, June 7-9, 2012.

Additional material for this article may be found online at [www.jvascsurg.org](http://www.jvascsurg.org). Reprint requests: Andrew N. Nicolaides, MS, FRCS, PhD, Vascular Screening and Diagnostic Centre, 28 Weymouth Street, London W1G 7BZ, UK (e-mail: [anicolaides1@gmail.com](mailto:anicolaides1@gmail.com)).

The editors and reviewers of this article have no relevant financial relationships to disclose per the JVS policy that requires reviewers to decline review of any manuscript for which they may have a conflict of interest.

0741-5214/\$36.00

Copyright © 2013 by the Society for Vascular Surgery.

<http://dx.doi.org/10.1016/j.jvs.2012.09.045>

Histologic studies showed that the necrotic core is twice as close to the lumen in unstable, symptomatic plaques compared with asymptomatic plaques.<sup>9</sup> These findings correspond to subsequent observations made in cross-sectional studies using ultrasound scanning, showing an association between the juxtalumenal black (hypoechoic) area (JBA) and the presence of neurologic symptoms in the patient.<sup>10-12</sup> A JBA in ultrasound images of asymptomatic carotid artery plaques is associated with a lipid core close to the lumen on histologic examination of carotid endarterectomy specimens.<sup>13</sup> A cross-sectional study of patients with symptomatic and asymptomatic plaques by our group has demonstrated that a JBA  $>8 \text{ mm}^2$  in the absence of a visible echogenic cap was associated with a high prevalence of symptomatic plaques in all grades of stenosis.<sup>10</sup>

Despite the previously mentioned evidence from cross-sectional studies, the prognostic role of the JBA in longitudinal studies of asymptomatic carotid artery stenosis and its contribution to risk stratification remain unknown. We previously suggested that cutoff points from cross-sectional studies need to be validated in prospective studies of asymptomatic patients.<sup>10</sup>

The Asymptomatic Carotid Stenosis and Risk of Stroke (ACSRS) study was a multicenter longitudinal study of patients with asymptomatic carotid stenosis managed conservatively. The aim of our study was to test the hypothesis that the presence and size of a JBA in the absence of a visible echogenic cap predicts future ipsilateral ischemic stroke in this cohort of patients.

## METHODS

**Patient recruitment.** Inclusion and exclusion criteria and recruitment sources have been previously reported in detail.<sup>6</sup> Briefly, newly referred patients with 50% to 99% internal carotid artery stenosis in relation to the carotid bulb diameter (European Carotid Surgery Trial [ECST] method) without previous ipsilateral cerebral or retinal ischemic (CORI) symptoms and without neurologic abnormality were eligible for inclusion; these patients were recruited to the study after they provided written informed consent. Patients who had contralateral cerebral hemispheric or retinal or vertebrobasilar symptoms or signs of stroke or transient ischemic attack (TIA) were included if they were asymptomatic for at least 6 months before recruitment. For patients with bilateral asymptomatic carotid atherosclerosis, the side with the more severe stenosis was considered ipsilateral (the study artery). Patients who could not attend for 6 monthly neurologic assessments and patients with a limited life expectancy because of conditions such as severe cardiac failure or disseminated malignancy were excluded. Approval was obtained from the Multicenter Research Ethics Committee (North Thames, London, United Kingdom) and local ethics committees.

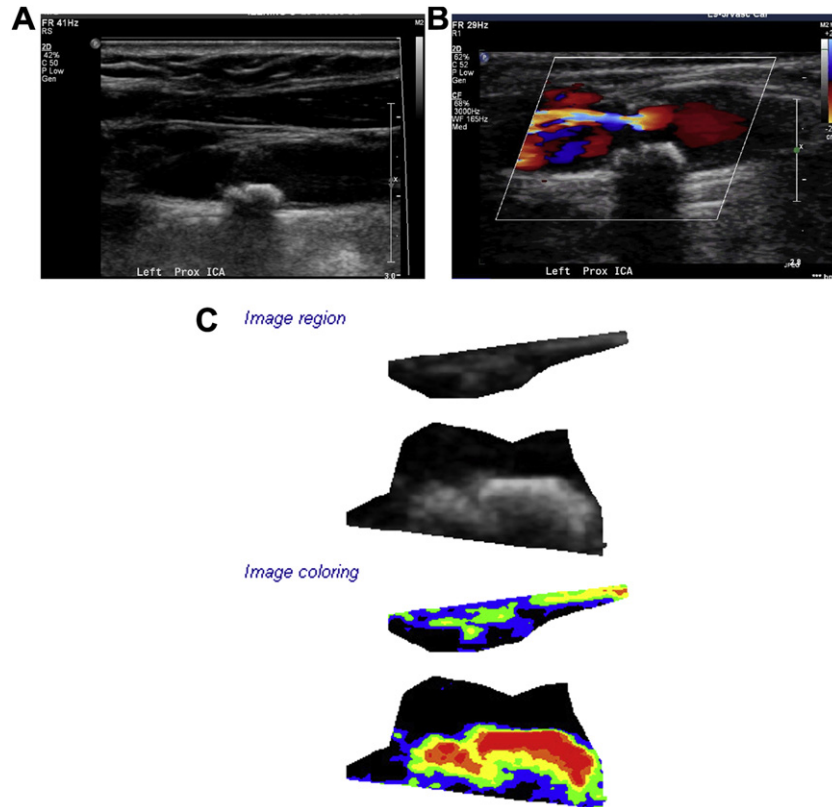
**Clinical and biochemical characteristics.** Clinical and biochemical characteristics have been published previously.<sup>6</sup>

**Duplex examination.** Carotid duplex scanning was performed on admission to the study. Ultrasonographers from all centers attended a 1-day training course on equipment settings, image capture, and use of velocity criteria at the coordinating center. The duplex examination, recorded on S-VHS videotape, was sent to the coordinating center for quality control. As previously described, a combination of velocity criteria was used to express the degree of stenosis in terms of the ECST method and the North American Symptomatic Carotid Endarterectomy Trial (NASCET) method.<sup>1,6,14</sup> Although velocities and both ECST and NASCET stenoses were available for every patient, ECST stenosis was used in the analysis because of its linear relationship to the risk of ipsilateral CORI events, in contrast to NASCET stenosis, which has an S-shaped relationship.<sup>1</sup> Contralateral internal carotid artery occlusion was noted. Bilateral vertebral artery flow was reported as cephalad, reversed, or not visualized.

**Image acquisition of carotid plaques.** As reported previously,<sup>6,15</sup> several prerequisites essential for successful image normalization were applied during duplex image acquisition, as follows:

1. Maximum dynamic range was used that ensured the greatest possible display of grayscale values and texture detail.
2. Persistence was set on low and frame rate was set on high, the latter ensuring good temporal resolution.
3. The time gain compensation curve was sloping through the tissues but was positioned vertically through the lumen of the vessel because the ultrasound beam was not attenuated as it passed through blood; this ensured that the adventitia of the anterior and posterior walls had similar brightness.
4. The overall gain was adjusted to give optimal image quality; this was achieved by adjustment of the gain control to minimize, but not abolish, noise. In practice, the gain was turned down so that noise was abolished and then gradually increased until some noise appeared in the lumen; this ensured that low-intensity features in the plaque were not lost and that there was a black area without noise in the lumen to be used for normalization.
5. A linear postprocessing curve was used. In the absence of a linear curve, a curve closest to linear was used.
6. The ultrasound beam was at 90 degrees to the arterial wall.
7. The minimum depth was used so that the plaque occupied a large part of the image.
8. The position of the probe was adjusted so that adventitia adjacent to the plaque was clearly visible as a hyper-echoic band and could be used for normalization.

**Image normalization and analysis.** Baseline images from video recordings were digitized offline on a PC using a video grabber card (Videologic, TV Snap version 1.0.3; Play Inc, Rancho Cordova, Calif) at a resolution of



**Fig 1.** **A**, Normalized grayscale image of the origin of the internal carotid artery (ICA) showing an apparently hyperechoic plaque. **B**, Color flow image of the same plaque showing the jet of blood at the tightest part of the stenosis (90%-95% North American Symptomatic Carotid Endarterectomy Trial method) and a juxtaluminal black (hypoechoic) area (JBA) as a filling defect on the far wall component of the plaque. **C**, Segmented grayscale image of the same plaque before and after color contouring according to the gray level of pixels (*grayscale*: 0-25 = *black*; 26-50 = *blue*; 51-75 = *green*; 76-100 = *yellow*; 101-125 = *orange*;  $\geq 125$  = *red*). The larger JBA of the far wall component of the plaque measures 13.6 mm<sup>2</sup>. The larger JBA of the near wall component of the plaque measures 2.7 mm<sup>2</sup>.

640 × 480 pixels at the coordinating center by two members of the team who were experienced in carotid scanning. Image normalization for grayscale using linear scaling with “blood” (grayscale = 0) and adventitia (grayscale = 190)<sup>16</sup> and pixel density standardization to 20 pixels/mm were performed followed by image analysis of the plaque outline. The exact plaque outline was determined with the aid of the color Doppler video clip from which a representative single image was selected. The Plaque Texture Analysis software version 4 (Iconsoft International Ltd, Greenford, London, United Kingdom) was used.<sup>15</sup> Plaque texture features that were automatically calculated using the Feature Extraction module of the software included GSM and plaque area using the on-screen millimeter scale from each ultrasonic image.<sup>6,15</sup> The presence of DWAs without acoustic shadowing was identified visually after image normalization.<sup>6</sup> The JBA without a visible echogenic cap was assessed as previously described.<sup>10</sup> Briefly, the largest JBA of the contoured image (ie, area with pixels having a grayscale value <25) without a visible echogenic cap (ie, pixels with grayscale value >25) was

outlined using the cursor. The JBA area was automatically calculated by the software and expressed as square millimeters (Fig 1).<sup>10</sup> The larger value was used in cases where there were two plaque components with black areas. Reproducibility of the JBA measurement has been previously reported.<sup>10</sup>

**Follow-up.** Patient follow-up was conducted every 6 months to perform a repeat Duplex examination, as described earlier, and to record clinical events (see later).

**Outcome measures.** The primary outcome measure (end point) of the current report was ipsilateral cerebral ischemic stroke (fatal or nonfatal). Stroke was defined as a cerebral deficit most likely of vascular origin lasting >24 hours. For each stroke, details recorded by the local neurologist, a 6-month modified Rankin score, and computed tomography or magnetic resonance imaging (MRI) brain scan results were requested. Two coordinating center members including a neurologist made the final classification of the primary outcome measure. CORI events were considered as secondary outcomes.

**Study exit points.** Follow-up ceased with the first occurrence of any of the following: the first CORI event,

including ipsilateral stroke; carotid endarterectomy or angioplasty and stenting for the still-asymptomatic study artery; death from causes other than ipsilateral stroke; or loss to follow-up. Carotid endarterectomy or angioplasty and stenting were not included in the CORI events. Also, stroke associated with carotid intervention for the still-asymptomatic study artery was not included in event rate calculations.

**Statistical analysis.** Receiver-operating characteristic (ROC) curves for the JBA were constructed with stroke as the state variable, and the area under the curve was estimated. The JBA was categorized and used for stratified Kaplan-Meier plots, which were compared with the log-rank test. For this purpose, several cutoff points were tested, including a previously suggested cutoff point (8 mm<sup>2</sup>) based on a cross-sectional study. Subsequently, the JBA was entered into a multivariate proportional hazards model with CORI events or stroke as the dependent variable, together with other plaque features known to be associated with increased risk (stenosis, GSM, presence of DWA indicating neovascularization, plaque area, and history of contralateral TIA or stroke).<sup>6</sup> The association between the JBA and stenosis grade was tested with Pearson correlation. Statistical analysis was performed with PASW/SPSS Statistics 18 or later (SPSS Inc, Chicago, Ill), and survival plots were created with Prism 6 for Windows (GraphPad Software, Inc, La Jolla, Calif).

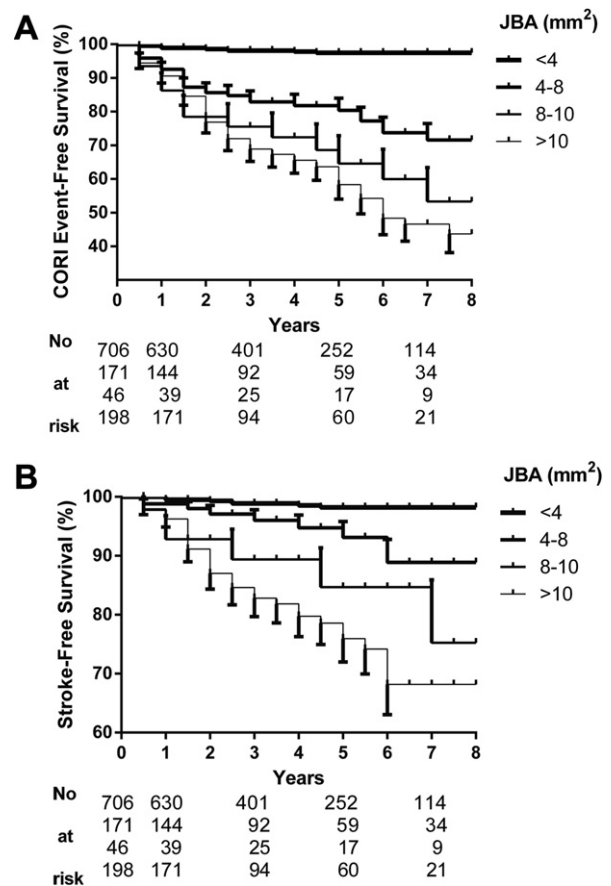
## RESULTS

The study included 1121 patients 39 to 89 years old (mean age, 70.0 years; standard deviation, 7.7; 61% men), recruited from 1998 to 2002 with a follow-up of 6 to 96 months (mean, 48 months), as previously reported.<sup>6</sup> During patient follow-up, 130 first ipsilateral CORI events occurred (59 strokes, of which 12 were fatal; 49 TIAs; and 22 amaurosis fugax episodes). The association between baseline clinical, biochemical, and ultrasound baseline features associated with the development of CORI events and stroke has been previously reported.<sup>6</sup>

**Ipsilateral cerebrovascular events.** Using Kaplan-Meier curves, the 5-year CORI event rate was 3% in 706 patients with a JBA <4 mm<sup>2</sup>, 21% in 171 patients with a JBA 4 to 8 mm<sup>2</sup>, 36% in 46 patients with a JBA 8 to 10 mm<sup>2</sup>, and 43% in 198 patients with JBA >10 mm<sup>2</sup> ( $P < .001$ ) (Fig 2, A). The corresponding average annual rates (mean at 5 years) were 0.6%, 4.2%, 7.2%, and 8.6%.

In a multivariate analysis using Cox proportional-hazards regression with ipsilateral CORI events (amaurosis fugax, TIA, or stroke) as the dependent variable, the JBA (<4 mm<sup>2</sup>, 4-8 mm<sup>2</sup>, >8 mm<sup>2</sup>) was still significant after adjusting for other plaque features known to be associated with increased risk, including stenosis, GSM, presence of DWA, plaque area, and history of contralateral TIA or stroke (Table, Model A).<sup>6</sup> Plaque area and GSM were not significant. JBA and percent stenosis were poorly correlated (Pearson correlation coefficient  $r = 0.083$ ).

**Ipsilateral stroke.** The JBA had a linear association with future stroke rate. Using Kaplan-Meier curves, the 5-year



**Fig 2.** Kaplan-Meier plots showing ipsilateral cerebrovascular or retinal ischemic (CORI) event-free survival (A) and stroke-free survival (B), stratified by juxtaluminar black (hypochoic) area (JBA). Standard error bars are shown for each curve; the number of patients at risk at each interval is shown at the bottom of each graph.

stroke rate was 2% in 706 patients with a JBA <4 mm<sup>2</sup>, 7% in 171 patients with a JBA 4 to 8 mm<sup>2</sup>, 16% in 46 patients with a JBA 8 to 10 mm<sup>2</sup>, and 25% in 198 patients with JBA >10 mm<sup>2</sup> ( $P < .001$ ) (Fig 2, B). The corresponding average annual rates (mean at 5 years) were 0.4%, 1.4%, 3.2%, and 5%.

The area under the ROC curve for stroke using the JBA as a continuous variable was 0.816 (95% confidence interval [CI], 0.77-0.86;  $P < .001$ ). Of the 59 ipsilateral ischemic strokes, 42 (71%) occurred in the 244 patients (22% of the cohort) who had a JBA of  $\geq 8$  mm<sup>2</sup> ( $P < .001$ ) (Fig 3, A). A JBA >8 mm<sup>2</sup> was also able to identify the patients who were likely to develop a fatal stroke. Fatal stroke occurred in 0.2% (2/877) of patients with a JBA <8 mm<sup>2</sup> and in 4.1% (10/244) with a JBA  $\geq 8$  mm<sup>2</sup> ( $P < .001$ , using Fisher's exact test; odds ratio, 18.7; 95% CI, 4.1-85.9). At 8 years, fatal stroke-free survival was 90.1% in patients with a JBA  $\geq 8$  mm<sup>2</sup> and 99.5% in patients with a JBA <8 mm<sup>2</sup> ( $P < .001$ ; hazard ratio, 19.6; 95% CI, 4.3-89.6) (Fig 3, B).

Multivariate analysis was subsequently performed using Cox proportional-hazards regression, with ipsilateral stroke

**Table.** Cox proportional hazards models including JBA and other plaque features known to be associated with increased risk<sup>a</sup>

Variable	$\beta$	HR	95% CI	P
<b>Model A</b>				
JBA (<4, 4-8, 8-10, >10 mm <sup>2</sup> )	0.816	2.26	1.84-2.78	<.001
Stenosis (50-69, 70-89, 90-99%)	0.241	1.27	0.98-1.66	.073
DWA (present, absent)	0.883	2.42	1.52-3.85	<.001
History of contralateral TIA or stroke (present, absent)	0.518	1.68	1.14-2.47	.008
GSM (<15, 15-30, >30)	-0.041	0.96	0.72-1.27	.776
Plaque area (<40, 40-80, >80 mm <sup>2</sup> )	0.099	1.04	0.83-1.47	.502
<b>Model B</b>				
JBA (4, 4-8, 8-10, >10 mm <sup>2</sup> )	0.773	2.16	1.58-2.97	<.001
Stenosis (50-69, 70-89, 90-99%)	0.465	1.59	1.06-2.38	.025
DWA (present, absent)	0.619	1.86	0.98-3.51	.057
History of contralateral TIA or stroke (present, absent)	0.793	2.21	1.28-3.61	.004
GSM (<15, 15-30, >30)	0.163	1.18	0.75 to 1.83	.471
Plaque area (<40, 40-80, >80 mm <sup>2</sup> )	0.051	1.05	0.68-1.62	.818
<b>Model C</b>				
JBA (4, 4-8, 8-10, >10 mm <sup>2</sup> )	0.853	2.34	1.89-2.91	<.001
Stenosis (50-69, 70-89, 90-99%)	0.462	1.59	1.06-2.37	.023
DWA (present, absent)	0.582	1.90	0.98-3.27	.059
History of contralateral TIA or stroke (present, absent)	0.788	2.20	1.27-3.79	.005

CI, Confidence interval; DWA, discrete white areas; GSM, grayscale median; HR, hazard ratio; JBA, juxtaluminal black (hypochoic) area; TIA, transient ischemic attack.

<sup>a</sup>Stenosis, GSM, presence of DWAs without acoustic shadowing indicating neovascularization, plaque area, and history of contralateral TIA or stroke, with ipsilateral cerebral or retinal ischemic events as the dependent variable in model A and ipsilateral ischemic stroke as the dependent variable in models B and C.

as the dependent variable. JBA (<4 mm<sup>2</sup>, 4-8 mm<sup>2</sup>, >8 mm<sup>2</sup>) was still significant after adjusting for other plaque features known to be associated with increased risk, including stenosis, GSM, presence of DWA, plaque area, and history of contralateral TIA or stroke (Table, Model B).<sup>6</sup>

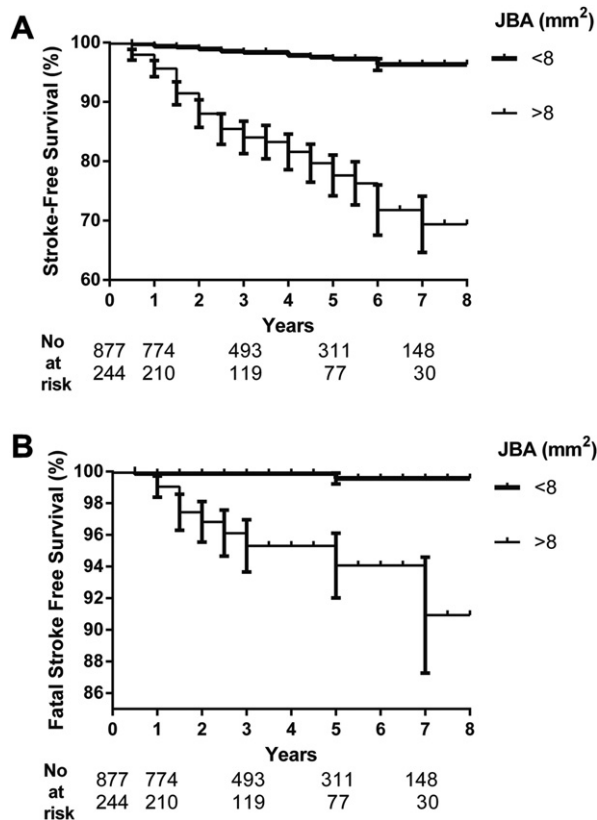
Using the significant variables (stenosis, DWA, JBA, and history of contralateral TIA or stroke) in the Cox model C (Table, Model C), the 5-year stroke-free survival (not shown) and average annual risk of stroke were calculated for each patient. Subsequently, patients were grouped in five subgroups of annual stroke risk (<1.0, 1.0-1.9, 2.0-3.9, 4.0-5.9, and  $\geq 6$ ) (Fig 4, A-C). The annual stroke risk was <1% in 722 patients, 1% to 1.9% in 110 patients, 2% to 3.9% in 162 patients, 4% to 5.9% in 70 patients, and 6% to 10% in 57 patients.

## DISCUSSION

This is the first study to demonstrate that the size of the JBA on ultrasound scan can be used in risk stratification models to calculate the risk for individual patients with asymptomatic carotid artery stenosis. The initial observation, which probably led to the development of JBA determination on ultrasound, was reported in a histologic study that showed carotid plaques causing symptoms were associated with a more frequent juxtaluminal location of the lipid core compared with asymptomatic carotid plaques.<sup>9</sup> Subsequently, the JBA was studied in carotid plaque images obtained with ultrasound scanning and was found to occur more frequently in symptomatic than asymptomatic plaques.<sup>11</sup> Additionally, an absent, thin, or ruptured echogenic cap has been observed more frequently in carotid plaques causing cerebrovascular symptoms or cerebral

infarction on ultrasound scan or MRI.<sup>17,18</sup> However, the JBA and echogenic cap determination was subjective in this early research because computer or scanner monitor brightness can alter the results of visual assessment, including the extension of plaque.<sup>19</sup> It became obvious at that time that standardization of this new ultrasound feature using objective methodology was necessary. Subsequently, image normalization and color mapping were employed in JBA determination<sup>13</sup> so that echolucent areas near the plaque lumen could become well defined with reproducible measurements of their area, without the aforementioned disadvantages of visual assessment.<sup>19</sup> Finally, the use of the corresponding color Doppler image and the video clip of the duplex examination in cases of hypochoic plaques is of paramount importance for the accurate determination of the extension of the JBA and the precise estimation of its size, without inclusion of luminal areas that can falsely increase its size.

Stratified GSM is another relative technique aiming to identify juxtaluminal echolucent plaque components<sup>13</sup>; however, this technique considers all pixels at a certain distance from the luminal surface and is unsuitable to estimate regional plaque characteristics. A refinement of this method was published more recently that calculates the proportion of echolucent pixels within the most superficial 0.5 mm of the plaque surface and a derivative score (risk index) that additionally takes into account severity of stenosis.<sup>20</sup> Our group advanced JBA determination further not only by estimating its size and determining the best cutoff point in a cross-sectional study but also excluding plaques with a clearly visible echogenic cap, a surrogate end point of plaque stability.<sup>10</sup> In symptomatic unstable



**Fig 3.** Kaplan-Meier plots showing ipsilateral ischemic stroke-free survival (**A**) and fatal stroke-free survival (**B**), stratified by a juxtaluminal black (hypoechoic) area (JBA) size of 8 mm<sup>2</sup>. Standard error bars are shown for each curve; the number of patients at risk at each interval is shown at the bottom of each graph.

plaques, mean fibrous cap thickness on plaque histology was 0.2 mm compared with 0.4 mm for asymptomatic plaques.<sup>9</sup> We hypothesized that because resolution of ultrasound in carotid images is 0.2 mm, fibrous caps thinner than 0.2 mm are unlikely to be visualized. Alternative explanations could be that the plaque has already ruptured or the hypoechoic area is a thrombus overlying the plaque. Whatever the explanation, all of the above-mentioned possibilities are dangerous. Further support to our hypothesis is provided not only from our results but also from previous studies, which have shown good agreement between carotid ultrasound scanning and plaque histology.<sup>21,22</sup> In addition, it has been shown that the presence of a thin or ruptured fibrous cap on carotid MRI in patients with moderate asymptomatic stenosis is a strong predictor of future neurologic events.<sup>23</sup> Also, in patients with TIAs and carotid plaques causing mild to moderate stenosis, the presence of juxtaluminal hemorrhage or thrombus on MRI is a strong predictor of TIA recurrence.<sup>24</sup>

Whether stratified GSM and risk index are better than JBA size determination in predicting future neurologic events including stroke in patients with asymptomatic carotid stenosis remains to be clarified. In cross-sectional

studies, however, odds ratios for risk index and JBA size in discriminating symptomatic from asymptomatic plaques were 4.89 and 6.7.<sup>10,20</sup>

In the present study, we demonstrated for the first time that the presence of a JBA without a visible echogenic cap was associated with the occurrence of future ipsilateral neurologic events in patients with asymptomatic carotid artery stenosis; this association was still significant after adjustment for known predictors in multivariate analysis. Although JBA was associated with the presence of ipsilateral carotid symptoms in two previous studies,<sup>11,25</sup> the cross-sectional nature of these studies precluded the findings from risk assessment modeling, and longitudinal studies such as ACSRS were necessary.

Our study also showed that the size of a JBA was a very strong predictor of stroke, with the area under the ROC curve being 0.816; a linear association with stroke rate reinforces the value of this feature. Additionally, the finding that not only neurologic events as a whole, but also ipsilateral ischemic stroke, a hard end point, is associated with JBA size increases the validity of our results. Plaques with a small or nonmeasurable JBA ( $\leq 1$  mm<sup>2</sup>) were associated with a minimal stroke risk (1/330; 0.3%).

An association between fatal stroke and JBA was demonstrated by the current investigation. A possible explanation is that a large JBA capable of producing a large ulcer of the carotid surface that can produce a large embolus can lead to a large brain infarct and more often to a fatal stroke.

We have previously shown that the severity of stenosis, a history of contralateral TIA or stroke (indicative of a systemic cause of plaque instability), and the presence of markers of plaque vulnerability (GSM, plaque area, and DWA without acoustic shadowing that indicate neovascularization)<sup>26</sup> can be used in risk modeling for stroke in asymptomatic carotid stenosis.<sup>6</sup> Our updated findings support the concept of plaque heterogeneity, previously shown to be predictive of neurologic events.<sup>27</sup> A carotid plaque with a large JBA and DWA is certainly heterogeneous. The difference with visual assessment is that computerized assessment of components of heterogeneity is objective and reproducible. Additionally, the number of independent predictive factors has been reduced from five in our prior report to four with our current approach, without compromising its predictive value, as reflected by the area under the ROC curve. Apart from stenosis that everybody measures, there are only two new ultrasound features—the JBA size and presence or absence of DWA. After image normalization, both of these features are easy to detect and measure regardless of the ultrasound equipment used. As expected for an independent predictor on multivariate analysis, JBA did not correlate with degree of stenosis. We showed that 24% of plaques producing mild stenosis (50%-69% ECST or <50% NASCET; Fig 4, C) were also at some risk, being associated with an annual stroke risk >1%. In support of this finding, the odds ratio of JBA size in discriminating symptomatic from asymptomatic plaques is greater in less severe stenoses.<sup>10</sup> In agreement with our findings, one MRI study showed that the

**A**

		History of Contralateral TIAs or Stroke Absent				History of Contralateral TIAs or Stroke Present				Annual Stroke Rate %
DWA	Present	0.8%	2.0%	4.1%	6.2%	1.0%	3.6%	7.6%	10.0%	
	n =	101	39	8	30	19	9	4	8	
		< 4	4-8	8-10	≥ 10	< 4	4-8	8-10	≥ 10	
			JBA mm <sup>2</sup>				JBA mm <sup>2</sup>			
		0.6%	1.2%	3.0%	3.8%	0.7%	2.6%	5.2%	7.4%	
		44	16	2	24	14	2	4	0	

≥ 6
4.0-5.9
2.0-3.9
1.0-1.9
< 1.0

**B**

		History of Contralateral TIAs or Stroke Absent				History of Contralateral TIAs or Stroke Present				Annual Stroke Rate %
DWA	Present	0.6%	1.4%	2.8%	4.4%	0.8%	2.6%	5.8%	8.4%	
	n =	220	50	20	44	25	7	2	15	
		< 4	4-8	8-10	≥ 10	< 4	4-8	8-10	≥ 10	
			JBA mm <sup>2</sup>				JBA mm <sup>2</sup>			
		0.4%	0.9%	1.4%	2.6%	0.5%	1.6%	3.4%	5.4%	
		129	19	3	40	12	1	2	8	

≥ 6
4.0-5.9
2.0-3.9
1.0-1.9
< 1.0

**C**

		History of Contralateral TIAs or Stroke Absent				History of Contralateral TIAs or Stroke Present				Annual Stroke Rate %
DWA	Present	0.2%	0.8%	1.6%	2.6%	0.4%	1.6%	3.4%	5.0%	
	n =	67	11	4	10	11	9	0	4	
		< 4	4-8	8-10	≥ 10	< 4	4-8	8-10	≥ 10	
			JBA mm <sup>2</sup>				JBA mm <sup>2</sup>			
		0.1%	0.4%	0.9%	1.5%	0.3%	1.0%	2.0%	3.3%	
		49	8	1	8	13	0	0	3	

≥ 6
4.0-5.9
2.0-3.9
1.0-1.9
< 1.0

**Fig 4.** **A**, Stenosis 90%-99% European Carotid Surgery Trial (83%-99% North American Symptomatic Carotid Endarterectomy Trial) (n = 325) and predicted annual stroke risk. **B**, Stenosis 70%-89% European Carotid Surgery Trial (50%-82% North American Symptomatic Carotid Endarterectomy Trial) (n = 598) and predicted annual stroke risk. **C**, Stenosis 50%-69% European Carotid Surgery Trial (<50% North American Symptomatic Carotid Endarterectomy Trial) (n = 198) and predicted annual stroke risk. *DWA*, Discrete white areas; *JBA*, juxtaluminal black (hypochoic) area; *TIA*, transient ischemic attack.

prevalence of atherosclerotic American Heart Association type VI lesions (lesions with luminal surface defect, hemorrhage or thrombus, or calcified nodule) in carotid arteries with stenosis of similar severity (16%-49% using the Strandness criteria) was 22%.<sup>28</sup> In another MRI study performed in a cohort of symptomatic and asymptomatic patients, most unstable plaques were observed in the group with stenosis <70% NASCET,<sup>29</sup> whereas in a cohort of patients with cryptogenic stroke and nonstenosing (<50%) eccentric carotid plaques, American Heart Association type VI plaques were found in 12 of 32 arteries (37.5%) ipsilateral to the stroke.<sup>30</sup> Although there is no trial evidence to support intervention in this subgroup of patients with vulnerable plaques producing mild stenosis, medical management should probably be aggressive.

A limitation of our study, as previously discussed, was the suboptimal medical management according to current practice.<sup>6</sup> Improved management is expected to reduce event rates, and our findings need to be verified in patients having optimal medical therapy. Another limitation was that no assessment of optimal GSM cutoff points for JBA determination was performed. As indicated in the Methods section, a black area was defined as an area with gray pixel values of  $\leq 25$ . The basis of this is that the human eye is unlikely to distinguish shades of gray within the range of 0 to 25 and a previously published cross-sectional study.<sup>10</sup> However, as far as the JBA is concerned, the 8-mm<sup>2</sup> cutoff value was found to be optimum. Sometimes, the identification and measurement of the JBA is not such a straightforward process and can be severely affected by common ultrasound limitations, such as calcifications, vessel tortuosity, and poor anatomic positioning of the vessels.

Only baseline ultrasound images obtained at entry to the study were used for analysis in the present report. Plaque progression, a feature unavailable at baseline, has been considered to be outside the scope of this study. It will be reported subsequently.

Finally, to include the JBA in the daily clinical practice, software such as the software used for the purpose of our study has to be widely available, ideally as a built-in feature of the ultrasound scanners, so that the analysis could be carried out in <10 minutes. The software used by the authors is widely available for use on a laptop computer and relatively inexpensive. Surgeons from several vascular teams referring patients to the authors' vascular laboratory request not only the degree of stenosis but also the risk stratification. Asymptomatic embolic signals by use of transcranial Doppler have already been shown to predict future stroke.<sup>31</sup> Both transcranial Doppler embolic signals and plaque echolucency have been shown to be independent predictors of stroke, and the presence of both can identify a subgroup with an 8% annual stroke risk.<sup>32</sup> The relationship between transcranial Doppler embolic signals and the size of a JBA, whether they are independent predictors of stroke, could be assessed in a cross-sectional study before a possible independent association is evaluated in longitudinal studies.

## CONCLUSIONS

The size of JBA is linearly related to the risk of stroke and can be used for risk stratification. These findings need to be confirmed in future prospective studies or in the medical arm of randomized controlled studies in the presence of optimal medical therapy. We believe that confirmation of our findings will change current practice in patients with asymptomatic carotid stenosis based on the severity of stenosis alone. In the meantime, it may be used to select high-risk asymptomatic patients for carotid endarterectomy and spare many from an unnecessary operation.

We are grateful to Suzan Francis, Elena Ioannidou, and Anne Taft for their contributions as administrative managers at different periods of the study.

## AUTHOR CONTRIBUTIONS

Conception and design: SK, AN, EK

Analysis and interpretation: SK, AN, GM

Data collection: SK, MG, MS, TT, DT, GG

Writing the article: SK, MG, AN, EK, MS, TT, GM, DT, GG

Critical revision of the article: Not applicable

Final approval of the article: SK, MG, AN, EK, MS, TT, GM, DT, GG

Statistical analysis: SK, AN

Obtained funding: AN

Overall responsibility: AN

## REFERENCES

- Nicolaides AN, Kakkos SK, Griffin M, Sabetai M, Dhanjil S, Tegos T, et al. Severity of asymptomatic carotid stenosis and risk of ipsilateral hemispheric ischaemic events: results from the ACSRS study. *Eur J Vasc Endovasc Surg* 2005;30:275-84.
- Gray-Weale AC, Graham JC, Burnett JR, Byrne K, Lusby RJ. Carotid artery atheroma: comparison of preoperative B-mode ultrasound appearance with carotid endarterectomy specimen pathology. *J Cardiovasc Surg (Torino)* 1988;29:676-81.
- Langsfeld M, Gray-Weale AC, Lusby RJ. The role of plaque morphology and diameter reduction in the development of new symptoms in asymptomatic carotid arteries. *J Vasc Surg* 1989;9:548-57.
- Polak JF, Shemanski L, O'Leary DH, Lefkowitz D, Price TR, Savage PJ, et al. Hypochoic plaque at US of the carotid artery: an independent risk factor for incident stroke in adults aged 65 years or older. *Radiology* 1998;208:649-54.
- Mathiesen EB, Bonna KH, Joakimsen O. Echolucent plaques are associated with high risk of ischemic cerebrovascular events in carotid stenosis: the tromsø study. *Circulation* 2001;103:2171-5.
- Nicolaides AN, Kakkos SK, Kyriacou E, Griffin M, Sabetai M, Thomas DJ, et al. Asymptomatic internal carotid artery stenosis and cerebrovascular risk stratification. *J Vasc Surg* 2010;52:1486-96.e1-5.
- Hashimoto H, Tagaya M, Niki H, Etani H. Computer-assisted analysis of heterogeneity on B-mode imaging predicts instability of asymptomatic carotid plaque. *Cerebrovasc Dis* 2009;28:357-64.
- Kakkos SK, Sabetai M, Tegos T, Stevens J, Thomas D, Griffin M, et al. Silent embolic infarcts on computed tomography brain scans and risk of ipsilateral hemispheric events in patients with asymptomatic internal carotid artery stenosis. *J Vasc Surg* 2009;49:902-9.
- Bassiouny HS, Sakaguchi Y, Mikucki SA, McKinsey JF, Piano G, Gewertz BL, et al. Juxtalumenal location of plaque necrosis and neof ormation in symptomatic carotid stenosis. *J Vasc Surg* 1997;26:585-94.



10. Griffin MB, Kyriacou E, Pattichis C, Bond D, Kakkos SK, Sabetai M, et al. Juxtaluminar hypoechoic area in ultrasonic images of carotid plaques and hemispheric symptoms. *J Vasc Surg* 2010;52:69-76.
11. Pedro LM, Fernandes e Fernandes J, Pedro MM, Goncalves I, Dias NV, Fernandes e Fernandes R, et al. Ultrasonographic risk score of carotid plaques. *Eur J Vasc Endovasc Surg* 2002;24:492-8.
12. Sztajzel R, Momjian-Mayor I, Comelli M, Momjian S. Correlation of cerebrovascular symptoms and microembolic signals with the stratified gray-scale median analysis and color mapping of the carotid plaque. *Stroke* 2006;37:824-9.
13. Sztajzel R, Momjian S, Momjian-Mayor I, Murith N, Djebaili K, Boissard G, et al. Stratified gray-scale median analysis and color mapping of the carotid plaque: correlation with endarterectomy specimen histology of 28 patients. *Stroke* 2005;36:741-5.
14. Nicolaidis AN, Shifrin EG, Bradbury A, Dhanjil S, Griffin M, Belcaro G, et al. Angiographic and duplex grading of internal carotid stenosis: can we overcome the confusion? *J Endovasc Surg* 1996;3:158-65.
15. Griffin M, Nicolaidis A, Kyriacou E. Normalisation of ultrasonic images of atherosclerotic plaques and reproducibility of grey scale median using dedicated software. *Int Angiol* 2007;26:372-7.
16. Elatrozy T, Nicolaidis A, Tegos T, Zarka AZ, Griffin M, Sabetai M. The effect of B-mode ultrasonic image standardisation on the echodensity of symptomatic and asymptomatic carotid bifurcation plaques. *Int Angiol* 1998;17:179-86.
17. Pedro LM, Pedro MM, Goncalves I, Carneiro TF, Balsinha C, Fernandes E, et al. Computer-assisted carotid plaque analysis: characteristics of plaques associated with cerebrovascular symptoms and cerebral infarction. *Eur J Vasc Endovasc Surg* 2000;19:118-23.
18. Demarco JK, Ota H, Underhill HR, Zhu DC, Reeves MJ, Potchen MJ, et al. MR carotid plaque imaging and contrast-enhanced MR angiography identifies lesions associated with recent ipsilateral thromboembolic symptoms: an in vivo study at 3T. *AJNR Am J Neuroradiol* 2010;31:1395-402.
19. Kakkos SK, Nicolaidis AN, Geroulakos G, Griffin MB, Tegos TJ. Effect of computer monitor brightness on visual (subjective) carotid plaque characterization. *J Clin Ultrasound* 2011;39:497-501.
20. Momjian-Mayor I, Kuzmanovic I, Momjian S, Bonvin C, Albanese S, Bichsel D, et al. Accuracy of a novel risk index combining degree of stenosis of the carotid artery and plaque surface echogenicity. *Stroke* 2012;43:1260-5.
21. Snow M, Ben-Sassi A, Winter RK, Vergheze A, Hibberd R, Saad RA, et al. Can carotid ultrasound predict plaque histopathology? *J Cardiovasc Surg (Torino)* 2007;48:299-303.
22. Hatsukami TS, Thackray BD, Primozich JF, Ferguson MS, Burns DH, Beach KW, et al. Echolucent regions in carotid plaque: preliminary analysis comparing three-dimensional histologic reconstructions to sonographic findings. *Ultrasound Med Biol* 1994;20:743-9.
23. Takaya N, Yuan C, Chu B, Saam T, Underhill H, Cai J, et al. Association between carotid plaque characteristics and subsequent ischemic cerebrovascular events: a prospective assessment with MRI—initial results. *Stroke* 2006;37:818-23.
24. Teng Z, Sadat U, Huang Y, Young VE, Graves MJ, Lu J, et al. In vivo MRI-based 3D mechanical stress-strain profiles of carotid plaques with juxtaluminar plaque haemorrhage: an exploratory study for the mechanism of subsequent cerebrovascular events. *Eur J Vasc Endovasc Surg* 2011;42:427-33.
25. Kakkos SK, Nicolaidis AN, Kyriacou E, Daskalopoulou SS, Sabetai MM, Pattichis CS, et al. Computerized texture analysis of carotid plaque ultrasonic images can identify unstable plaques associated with ipsilateral neurological symptoms. *Angiology* 2011;62:317-28.
26. Staub D, Partovi S, Schinkel AF, Coll B, Uthoff H, Aschwanden M, et al. Correlation of carotid artery atherosclerotic lesion echogenicity and severity at standard US with intraplaque neovascularization detected at contrast-enhanced US. *Radiology* 2011;258:618-26.
27. Bock RW, Gray-Weale AC, Mock PA, Robinson DA, Irwig L, Lusby RJ. The natural history of asymptomatic carotid artery disease. *J Vasc Surg* 1993;17:160-9; discussion: 170-1.
28. Saam T, Underhill HR, Chu B, Takaya N, Cai J, Polissar NL, et al. Prevalence of American Heart Association type VI carotid atherosclerotic lesions identified by magnetic resonance imaging for different levels of stenosis as measured by duplex ultrasound. *J Am Coll Cardiol* 2008;51:1014-9.
29. Lindsay AC, Biasioli L, Lee JM, Kylintireas I, Macintosh BJ, Watt H, et al. Plaque features associated with increased cerebral infarction after minor stroke and TIA: a prospective, case-control, 3-T carotid artery MR imaging study. *JACC Cardiovasc Imaging* 2012;5:388-96.
30. Freilinger TM, Schindler A, Schmidt C, Grimm J, Cyran C, Schwarz F, et al. Prevalence of nonstenosing, complicated atherosclerotic plaques in cryptogenic stroke. *JACC Cardiovasc Imaging* 2012;5:397-405.
31. Markus HS, King A, Shipley M, Topakian R, Cullinane M, Reihill S, et al. Asymptomatic embolisation for prediction of stroke in the Asymptomatic Carotid Emboli Study (ACES): a prospective observational study. *Lancet Neurol* 2010;9:663-71.
32. Topakian R, King A, Kwon SU, Schaafsma A, Shipley M, Markus HS, et al. Ultrasonic plaque echolucency and emboli signals predict stroke in asymptomatic carotid stenosis. *Neurology* 2011;77:751-8.

Submitted Jun 30, 2012; accepted Sep 12, 2012.

*Additional material for this article may be found online at [www.jvascsurg.org](http://www.jvascsurg.org).*

## DISCUSSION

**Dr R. Clement Darling** (*Albany, NY*). Did most of your patients start with large areas of JBA, or did you watch them progress?

**Dr Stavros K. Kakkos**. These are baseline observations. We haven't yet analyzed the changes over time.

**Dr Joy Roy** (*Stockholm, Sweden*). I have two questions. And the first is, as you know, we are more restrictive in operating on women. Did you see a difference between men and women?

**Dr Kakkos**. No.

**Dr Roy**. And the second question is, how many patients developed a JBA during the follow-up?

**Dr Kakkos**. As I already explained to the moderator, we do have the data, but it has not been analyzed yet.

**Dr Mahmoud Malas** (*Baltimore, Md*). Dr. Cambria stressed yesterday, in his presidential speech, the importance of focusing research on asymptomatic carotid artery stenosis. Identifying these patients who need surgery is one of the research priorities for our society. I am interested in the way you measured the

JBA. Using ultrasound, you are looking at the JBA only in a few angles. How did you translate that to square centimeters? Because the only way you can really measure it accurately is by doing either a computed tomography angiogram or a rotational angiogram and three-dimensional reconstruction. If you could, please elaborate a little bit more on the software that you have used.

**Dr Kakkos**. To measure the size of a JBA, you need to have a scale, and because all ultrasound images have a scale, it's very easy from the technical point of view to measure area. This is a study of two-dimensional images obtained by standard ultrasound probes. At that time, obviously, there was no three-dimensional ultrasound. Perhaps three-dimensional ultrasound may perform better.

**Dr Mark Fillinger** (*Lebanon, NH*). It appeared in your table that there may be some colinearity between the JBA and carotid stenosis. Did you look at the predictive power of your model with and without the JBA to see if the area under the curve was

affected greatly by including JBA in the model? Does it significantly change the discriminatory power?

**Dr Kakkos.** Yes, it does.

**Dr Robert Zwolak** (*Lebanon, NH*). It's always been a bit of a mystery why most vascular laboratories in the United States haven't taken up a more sophisticated approach toward carotid plaque analysis. I'm sure part of it has to do with the lack of additional reimbursement, and the likelihood of added reimbursement for plaque analysis is very low. So if we're going to do this in the United States and be a bit more sophisticated about it, the technique has to be easy, quick, reproducible, inexpensive, and scaleable. I wonder if you would comment on each of these. How easy is this? How scaleable is it? Is it something that could be adopted commonly across the U.S. in many labs without much trouble?

**Dr Kakkos.** Ideally, this software should be part of the ultrasound equipment. Now, it takes 10 minutes off-line on a laptop. If that's going to be the case, yes, I agree it doesn't take time, it's

scaleable, and also it would be cost-effective. Visual classification has certain problems, and it's not objective. This is why there is no reimbursement for visual classification of echolucency or heterogeneity. Our technique is objective because it's based on image analysis, which is based on the computer, not on the human eye.

**Dr Walter Dorigo** (*Florence, Italy*). Do you think that the use of enhanced contrast ultrasound can improve the visualization of JBA and your experience with this tool?

**Dr Kakkos.** I do not have personal experience with contrast-enhanced ultrasound. It could improve the results. I don't think that it would certainly improve visualization or identification of JBA, but it would find areas within the plaque of high vascularization that are thought to be dangerous and contribute to the identification of a high-risk lesion. Now we think that the echogenic areas, shown as red on the example, might represent these highly vascularized areas, but this is a hypothesis and obviously we need more studies.

**APPENDIX (online only).**

**The ACSRS Study Group**

- R. Adovasio and B. Ziani (Trieste, Italy)  
F. P. Alò and C. G. Cicilioni (Ancona, Italy)  
G. Ambrosio (Venezia, Italy)  
A. Andreev (Stara Zagora, Bulgaria)  
G. M. Andreozzi, F. Verlato, and G. Camporese (Padova, Italy)  
E. Arosio (Verona, Italy)  
E. Barkauskas (Vilnius, Lithuania)  
A. A. B. Barros D'Sa and P. Brannigan (Belfast, United Kingdom)  
V. Batchvarova and A. Dramov (Sofia, Bulgaria)  
P. Belardi, G. P. Novelli, and G. Simoni (Genoa, Italy)  
P. Bell (Leicester, United Kingdom)  
G. M. Biasi & P. Mingazzini (Milan, Italy)  
N. M. Bornstein (Tel-Aviv, Israel)  
D. Bouchier-Hayes and P. Fitzgerald (Dublin, Ireland)  
M. A. Cairols (Barcelona, Spain)  
P. G. Cao and P. DeRango (Perugia, Italy)  
G. P. Carboni and C. Geoffredo (Rome, Italy)  
M. Catalano (Milan, Italy)  
B. Chambers, M. Goetzmann, and A. Dickinson (Victoria, Australia)  
D. Clement & M. Bobelyn (Ghent, Belgium)  
S. Coccheri & E. Conti (Bologna, Italy)  
E. Diamantopoulos and E. A. Andreadis (Athens, Greece)  
P. B. Dimakakos and T. Kotsis (Athens, Greece)  
B. Eikelboom (Utrecht, The Netherlands)  
L. Entz (Budapest, Hungary)  
A. Ferrari-Bardile, T. Aloï, and M. Salerno (Montescano, Italy)  
J. Fernandes e Fernandes and L. Pedro (Lisbon, Portugal)  
D. E. Fitzgerald and A. M. O'Shaughnessy (Dublin, Ireland)  
J. Fletcher (Westmead, Australia)  
S. Forconi, R. Cappeli, M. Bicchi, and S. Arrigucci (Siena, Italy)  
V. Gallai and G. Cardaiolli (Perugia, Italy)  
G. Geroulakos and S. Kakkos (London, United Kingdom)  
L. F. Gomez-Isaza (Medellin, Colombia)  
G. Gorgoyannis and N. Liasis (Athens, Greece)  
M. Graf (Vienna, Austria)  
P. Guarini (Napoli, Italy)  
S. Hardy (Blackburn, United Kingdom)  
P. Harris and S. Aston (Liverpool, United Kingdom)  
G. Iosa (Cesena, Italy)  
A. Katsamouris and A. Giannoukas (Crete, Greece)  
M. Krzanowski (Krakow, Poland)  
G. Ladurner (Salzburg, Austria)  
J. Leal-Monedero (Madrid, Spain)  
B. B. Lee (Seoul, Korea)  
C. Liapis and P. Galanis (Athens, Greece)  
W. Liboni and E. Pavanelli (Torino, Italy)  
E. Mannarino and G. Vaudo (Perugia, Italy)  
P. McCollum and R. Levison (Dundee, United Kingdom)  
G. Micieli and D. Bosone (Pavia, Italy)  
L. Middleton, M. Pantziaris, and T. Tyllis (Nicosia, Cyprus)  
E. Minar and A. Willfort (Vienna, Austria)  
L. Moggi and P. DeRango (Perugia, Italy)  
G. Nenci and S. Radicchia (Perugia, Italy)  
A. Nicolaides, S. Kakkos, and D. Thomas (London, United Kingdom)  
L. Norgren and E. Ribbe (Lund, Sweden)  
S. Novo and R. Tantillo (Palermo, Italy)  
D. Olinic (Cluj-Napoca, Romania)  
W. Paaske (Aarhus, Denmark)  
A. Pagnan (Castelfranco, Italy)  
P. Pauletto and V. Pagliara (Padova, Italy)  
G. Pettina (Pistoia, Italy)  
C. Pratesi and S. Matticari (Firenze, Italy)  
J. Polivka and P. Sevcik (Plzen, Czech Republic)  
P. Poredos, A. Blinc, and V. Videcnik (Ljubjana, Slovenia)  
A. Pujia (Cantanzaro, Italy)  
A. Raso, P. Rispoli, and M. Conforti (Torino, Italy)  
T. Robinson and M. S. J. Dennis (Leicester, United Kingdom)  
S. Rosfors (Stockholm, Sweden)  
G. Rudofsky (Essen, Germany)  
T. Schroeder and M. L. Gronholdt (Copenhagen, Denmark)  
G. Simoni, C. Finocchi, and G. Rodriguez (Genoa, Italy)  
C. Spartera, M. Ventura, and P. Scarpelli (L'Aquila, Italy)  
M. Sprynger, B. Sadzot, C. Hottermans, and M. Moonen (Chenee, Belgium)  
P. R. Taylor (London, United Kingdom)  
A. Tovar-Pardo and J. Negreira (Madrid, Spain)  
M. Vayssairat and J. M. Faintuch (Paris, France)  
J. Valaikiene (Vilnius, Lithuania)  
M. G. Walker (Manchester, United Kingdom)  
A. R. Wilkinson (Hull, United Kingdom)