



タイトル Title	Anesthetic Management of Transcatheter Aortic Valve Replacement under Extracorporeal Membrane Oxygenation in a Patient with Acute Decompensated Heart Failure: A Case Report
著者 Author(s)	Okada, Takuya / Yoshida, Takuya / Makino, Shohei / Obata, Norihiko / Mizobuchi, Satoshi
掲載誌・巻号・ページ Citation	The Kobe journal of the medical sciences,65(3):90-94
刊行日 Issue date	2019
資源タイプ Resource Type	Departmental Bulletin Paper / 紀要論文
版区分 Resource Version	publisher
権利 Rights	
DOI	
JaLDOI	10.24546/81011913
URL	http://www.lib.kobe-u.ac.jp/handle_kernel/81011912

Anesthetic Management of Transcatheter Aortic Valve Replacement under Extracorporeal Membrane Oxygenation in a Patient with Acute Decompensated Heart Failure: A Case Report

TAKUYA OKADA*, TAKUYA YOSHIDA, SHOHEI MAKINO,
NORHIKO OBATA and SATOSHI MIZOBUCHI

*Division of Anesthesiology, Department of Surgery Related, Kobe University Graduate School of Medicine,
Kobe, Japan*

Received 10 April 2019/ Accepted 16 July 2019

Keywords: Transcatheter Aortic Valve Replacement, Aortic Valve Stenosis, Extracorporeal Membrane Oxygenation, Acute decompensated heart failure.

We managed general anesthesia for transcatheter aortic valve replacement (TAVR) under elective extracorporeal membrane oxygenation (ECMO) in a patient with aortic valve stenosis (AS) complicated with acute decompensated heart failure. The patient was an 87-year-old woman with acute heart failure due to severe AS who had been hospitalized. However, her low cardiac output did not improve, and weaning her off catecholamines was difficult, so semi-urgent TAVR was performed. Due to her acute decompensated heart failure complicated by low-left ventricular function, we decided electively to use ECMO for transfemoral TAVR to prevent hemodynamic collapse during induction of anesthesia and surgery, enabling the safe perioperative management of this patient under general anesthesia.

INTRODUCTION

The surgical outcomes of transcatheter aortic valve replacement (TAVR) for aortic valve stenosis (AS) are not inferior to those of surgical aortic valve replacement (SAVR) in high-risk patients, making it a standard treatment for elderly high-risk patients [1,2].

The number of cases of TAVR has increased in recent years and there have been some reports of TAVR in which extracorporeal membrane oxygenation (ECMO) was used electively in severe cases. However, there is no definite opinion regarding the choice of general anesthesia or local anesthesia and the use of ECMO [3].

We managed general anesthesia during a TAVR with elective ECMO in a patient with AS complicated by acute decompensated heart failure. Written informed consent was obtained from the patient for publication of this case report.

CLINICAL CASE

An 87-year-old woman, weighing 45 kg and 150 cm in height, had been treated for AS for the previous 6 years, although with gradually progressive symptoms. Dyspnea and leg edema were seen upon physical examination, with New York Heart Association Functional Classification (NYHA) Class IV, and she was admitted to our hospital with the diagnosis of acute heart failure due to severe AS. Her vital signs upon admission were: blood pressure (BP) of 119/59 mmHg, pulse rate (PR) of 85 beats•min⁻¹ regular, respiratory rate (RR) of 25 times•min⁻¹, SpO₂ of 95 % (under 2 L•min⁻¹ oxygen inhalation via nasal cannula), body temperature of 37.3 degrees. Chest x-rays revealed cardiomegaly, bilateral pleural effusion and intensified pulmonary vascular markings, and blood brain natriuretic peptide (BNP) was elevated to 4319 pg•mL⁻¹. Transthoracic echocardiography (TTE) under intravenous infusion of 5 µg•kg⁻¹•min⁻¹ of dobutamine indicated an aortic valve area of 0.52 cm², peak velocity of 4.93 m•s⁻¹, and mean pressure gradient of 64.8 mmHg (Figure.1)—all signs of severe AS complicated by severe aortic valve regurgitation (pressure half time of 179 ms). Decreased contractility was also noted, with an ejection fraction (EF) of 36.6%, and a tricuspid regurgitation peak gradient of 40 mmHg, suggesting mild pulmonary hypertension. After admission, her respiratory state stabilized when her weight decreased from 47.3 kg to 45.3 kg following treatment with diuretics and non-invasive positive pressure ventilation (NPPV). Although weaning her off NPPV was easy, low cardiac output persisted and weaning her off dobutamine was difficult. The patient's surgical risk scores indicated a Society of Thoracic Surgeons score of 30.2% and Logistic-Euro score of 25.5%, making her a high-risk patient for surgical aortic valve replacement, so TAVR was scheduled. A preoperative contrast CT examination showed her respiratory status had worsened and she needed to be treated with NPPV again. Acute worsening of her heart failure was diagnosed to be due to the volume load of the contrast agent, and

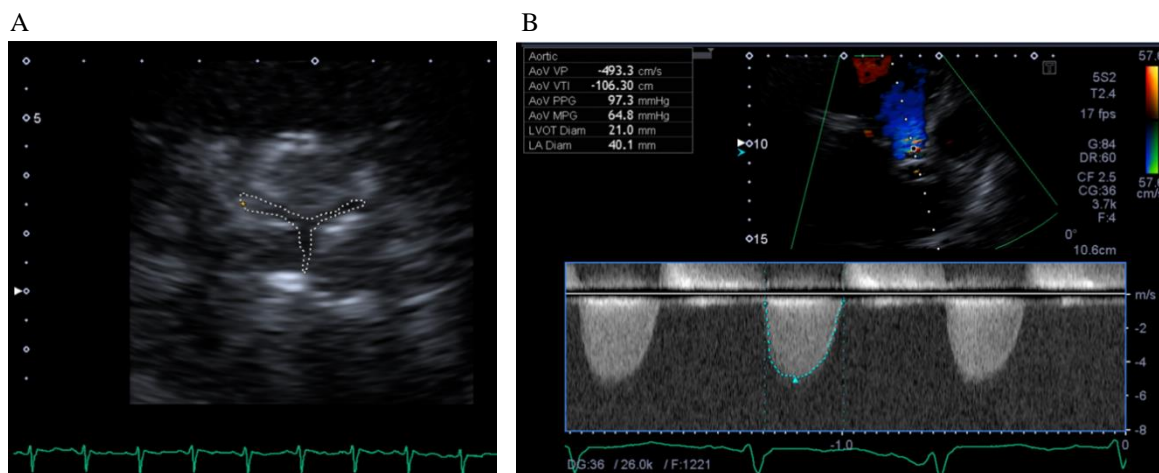


Figure 1.

Images of transthoracic echocardiography on admission. (A,B) Transthoracic echocardiography (TTE) indicated an aortic valve area of 0.52 cm^2 , peak velocity of $4.93 \text{ m}\cdot\text{s}^{-1}$, and mean pressure gradient of 63.8 mmHg .

she was treated by increasing the dose of dobutamine to $7 \mu\text{g}\cdot\text{kg}^{-1}\cdot\text{min}^{-1}$ and additional administration of diuretics. We decided that further medical treatment would be difficult and semi-urgent TAVR via the transfemoral approach was scheduled. Since she was in a state of acute decompensated heart failure with low cardiac output, we decided to perform TAVR with elective use of ECMO.

We planned to conduct this case using general anesthesia. The monitoring including pulse oximetry, non-invasive blood pressure, electrocardiography, capnometry, urine volume and temperature were used. Before induction, the left radial artery was cannulated for intra-arterial pressure monitoring. At anesthesia induction, her vital signs were: BP of $113/55 \text{ mmHg}$, PR of $108 \text{ beats}\cdot\text{min}^{-1}$, RR of $16 \text{ times}\cdot\text{min}^{-1}$, SpO₂ of 95% (under $2 \text{ L}\cdot\text{min}^{-1}$ oxygen inhalation via nasal cannula) under intravenous infusion of $7 \mu\text{g}\cdot\text{kg}^{-1}\cdot\text{min}^{-1}$ of dobutamine. We planned to use ECMO in case of emergency, 6 Fr sheaths were inserted into the femoral vein and artery under local anesthesia before anesthesia induction to prevent hemodynamic collapse during anesthetic induction. General anesthesia was induced with fentanyl $5 \mu\text{g}\cdot\text{kg}^{-1}$, midazolam $0.02 \text{ mg}\cdot\text{kg}^{-1}$, and rocuronium $0.8 \text{ mg}\cdot\text{kg}^{-1}$. After endotracheal intubation, a transesophageal echocardiography (TEE) probe was inserted and a pulmonary artery catheter was inserted via the right internal jugular vein. After induction, her vital signs were: BP of $91/49 \text{ mmHg}$, PR of $119 \text{ beats}\cdot\text{min}^{-1}$, RR of $12 \text{ times}\cdot\text{min}^{-1}$, SpO₂ of 99% (under mechanical ventilation with 60% oxygen with air). The pulmonary catheter indicated a cardiac output of $5.1 \text{ L}\cdot\text{min}^{-1}$, cardiac index of $3.6 \text{ L}\cdot\text{min}^{-1}\cdot\text{m}^{-2}$, and pulmonary arterial pressure (PAP) of $62/34 \text{ mmHg}$.

After anesthesia induction, a 15 Fr inflow catheter (Capiiox, percutaneous catheter, Terumo Co, Tokyo, Japan) was inserted into the left femoral artery, a 21 Fr outflow catheter (Capiiox, percutaneous catheter, Terumo Co, Tokyo, Japan) was inserted into the right femoral vein under fluoroscopy and ECMO (Capiiox emergency bypass system, Terumo Co, Tokyo, Japan) was started before the balloon aortic valvuloplasty (BAV) procedure. ECMO flow was gradually increased to $1.4 \text{ L}\cdot\text{min}^{-1}$ with stabilization of hemodynamics (her atrial pressure and pulse rate were $105/55 \text{ mmHg}$ and $100 \text{ beats}\cdot\text{min}^{-1}$). Since the patient had severe AR, TEE was used to monitor her left ventricular volume as a guide to adjusting the ECMO flow at 1.0 - $2.0 \text{ L}\cdot\text{min}^{-1}$, as needed. An artificial valve (SAPIEN XT® 23mm, Edwards Lifesciences Inc., Irvine, CA, USA) was placed after BAV under rapid pacing. After valve replacement, her vital signs were: arterial BP of $93/57 \text{ mmHg}$, PR of $75 \text{ beats}\cdot\text{min}^{-1}$ (under pacing) under continuous administration of dobutamine $7 \mu\text{g}\cdot\text{kg}^{-1}\cdot\text{min}^{-1}$ and noradrenaline $0.1 \mu\text{g}\cdot\text{kg}^{-1}\cdot\text{min}^{-1}$. Since catecholamine support was required by low left ventricular function before surgery, we decided that an assisted circulation device was necessary even after valve replacement. Therefore, we inserted an intra-aortic balloon pump (IABP; XEMEX IABP Balloon Plus, ZEON MEDICAL INC, Tokyo, Japan) before weaning her off ECMO, which was easy as a result. ECMO was used for 75 minutes. After TAVR, paravalvular leakage was almost nothing with TEE monitoring and PAP was markedly decreased to $32/16$ with IABP use by the time the patient left the operating room. The patient was moved to the Intensive Care Unit (ICU) still intubated. At admission to ICU, her vital signs were: BP of $115/34 \text{ mmHg}$, PR of $75 \text{ beats}\cdot\text{min}^{-1}$ (under pacing), RR of $12 \text{ times}\cdot\text{min}^{-1}$, SpO₂ of 99% (under mechanical ventilation with 50% oxygen with air) under intravenous infusion of $7 \mu\text{g}\cdot\text{kg}^{-1}\cdot\text{min}^{-1}$ of dobutamine and $0.1 \mu\text{g}\cdot\text{kg}^{-1}\cdot\text{min}^{-1}$ of noradrenaline.

The patient's subsequent recovery was good, allowing her to be weaned off IABP by the day after TAVR, extubated by day 2 post-surgery, weaned off catecholamines by day 14 post-surgery and discharged on day 40

post-surgery (Figure 2). At discharge, her NYHA classification had improved from class IV to class II, and she was able to walk slowly. Chest X-rays showed marked improvement in her pulmonary congestion. TTE scores at discharge were an aortic valve area of 0.97 cm², peak velocity of 2.08 m·s⁻¹, and mean pressure gradient of 11 mmHg. In addition to improved AS, cardiac function also improved, with an EF of 53%. At 6 months after discharge, the patient remained free of any cardiovascular events.

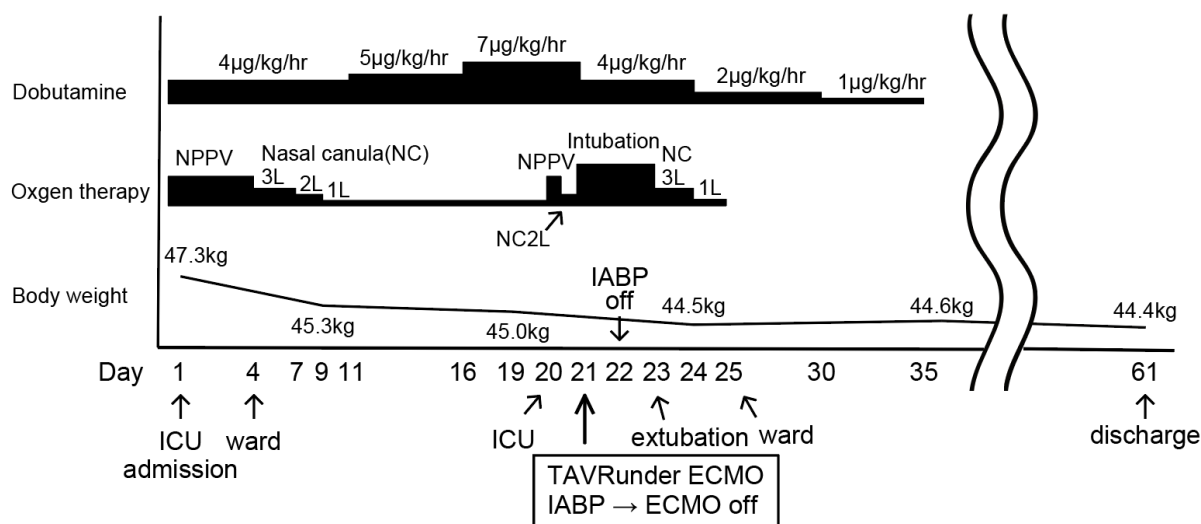


Figure 2. Clinical course of this case.

DISCUSSION

Few reports have discussed the anesthetic management of TAVR in severe cases with complicated acute decompensated heart failure. We experienced a case of anesthetic management of TAVR with elective ECMO under general anesthesia in a patient with AS complicated by acute decompensated heart failure.

TAVR is one of the treatments for severe AS and is an appropriate therapeutic option, especially for elderly high-risk patients [1,2]. Recently, it has been reported that TAVR was performed even in severe cases with complicated cardiogenic shock or low-left ventricular function with EF less than 30%. However, the 30-day mortality rate after TAVR performed on patients with complicated cardiogenic shock was still as high as 13-33% [4,5].

Regarding the method of anesthesia for TAVR, Bufton et al. reported that general anesthesia was common in North America, whereas local anesthesia or sedation was common in Europe [6]. Since our patient had a high risk of intraoperative hemodynamic collapse and real-time monitoring by TEE was considered to be essential, especially for adjustment of the appropriate ECMO flow, we managed our patient under general anesthesia. Local anesthesia has some advantages, such as shortening of the procedure time and duration of hospitalization, and reduction in the amount of vasopressor administered during surgery. On the other hand, general anesthesia has some advantages, such as ease of use of TEE, which enables performance of TEE in real-time and detailed evaluation of paravalvular leakage [7]. There had been no reports showing significant differences in the success rates of the procedures, the occurrence of intraoperative events and prognosis between general and local anesthesia [3,7,8]. However, since the probability of transition from local to general anesthesia during TAVR was reportedly 6.3-17.0% [3,8], it is essential to be prepared for a transition to general anesthesia even in cases managed under local anesthesia.

The use of elective or urgent ECMO for TAVR is controversial. A 30-day mortality rate of 30-45% had been reported in patients who suffered hemodynamic collapse during surgery and needed the urgent use of ECMO during TAVR [9,10,11]. On the other hand, favorable results have been achieved when elective ECMO was used during TAVR. Drews et al. reported a 30-day mortality rate of 14% (6 out of 43 cases) and Husser et al. reported a mortality rate of 0% (0 out of 9 cases) with elective ECMO for TAVR. Husser et al. also reported a 30-day mortality of 44% (4 out of 9 cases) in patients who require urgent use of ECMO during TAVR. These results indicate that elective use of ECMO reduces mortality in serious cases. Therefore, those reports have recommended the elective use of ECMO during TAVR in such cases: (1) severely impaired left ventricle function; (2) severe pulmonary hypertension; (3) insufficient distance between the coronary artery ostium and the aortic valve annulus [12,13]. In our case, it was necessary to administer catecholamine before surgery, and complicated with mild pulmonary hypertension, heart failure was possible solely from the contrast medium load, suggesting the potential

for intraoperative hemodynamic collapse. Hence, we decided to perform transfemoral TAVR with elective use of ECMO. The use of TEE during ECMO is reportedly useful for the detection of complications and readiness for weaning off ECMO [14]. Since flow volume was adjusted with careful TEE monitoring of left ventricular dimensions, preventing further left ventricular myocardial damage, subsequent weaning off of ECMO was easy in our patient.

In conclusion, we successfully managed general anesthesia for TAVR under ECMO in a patient with AS complicated with acute decompensated heart failure. In high-risk patients undergoing TAVR, the anesthesiologist should remain aware of elective ECMO as a possible procedure to improve outcomes and be familiar with its anesthetic management.

ACKNOWLEDGEMENTS

None of the authors has any conflicts of interest or any financial ties to disclose.

REFERENCES

1. Mack, M.J., Leon, M.B., Smith, C.R., Miller, D.C., Moses, J.W., Tuzcu, E.M., Webb, J.G., Douglas, P.S., Anderson, W.N., Blackstone, E.H., Kodali, S.K., Makkar, R.R., Fontana, G.P., Kapadia, S., Bavaria, J., Hahn, R.T., Thourani, V.H., Babaliaros, V., Pichard, A., Herrmann, H.C., Brown, D.L., Williams, M., Akin, J., Davidson, M.J., and Svensson, L.G. 2015. 5-year outcomes of transcatheter aortic valve replacement or surgical aortic valve replacement for high surgical risk patients with aortic stenosis (PARTNER 1): a randomised controlled trial. *Lancet* **385**:2477-84.
2. Kapadia, S.R., Leon, M.B., Makkar, R.R., Tuzcu, E.M., Svensson, L.G., Kodali, S., Webb, J.G., Mack, M.J., Douglas, P.S., Thourani, V.H., Babaliaros, V.C., Herrmann, H.C., Szeto, W.Y., Pichard, A.D., Williams, M.R., Fontana, G.P., Miller, D.C., Anderson, W.N., Akin, J.J., Davidson, M.J., and Smith, C.R. 2015. 5-year outcomes of transcatheter aortic valve replacement compared with standard treatment for patients with inoperable aortic stenosis (PARTNER 1): a randomised controlled trial. *Lancet* **385**:2485-91.
3. Frohlich, G.M., Lansky, A.J., Webb, J., Roffi, M., Toggweiler, S., Reinthaler, M., Wang, D., Hutchinson, N., Wendler, O., Hildick-Smith, D., and Meier, P. 2014. Local versus general anesthesia for transcatheter aortic valve implantation (TAVR)--systematic review and meta-analysis. *BMC Med* **12**:41.
4. Unbehaun, A., Pasic, M., Buz, S., Dreysse, S., Kukucka, M., Hetzer, R., and Drews, T. 2014. Transapical aortic valve implantation in patients with poor left ventricular function and cardiogenic shock. *J Thorac Cardiovasc Surg* **148**:2877-82.e1.
5. Frerker, C., Schewel, J., Schluter, M., Schewel, D., Ramadan, H., Schmidt, T., Thielsen, T., Kreidel, F., Schlingloff, F., Bader, R., Wohlmuth, P., Schafer, U., and Kuck, K.H. 2016. Emergency transcatheter aortic valve replacement in patients with cardiogenic shock due to acutely decompensated aortic stenosis. *EuroIntervention* **11**:1530-6.
6. Bufton, K.A., Augoustides, J.G., and Cobey, F.C. 2013. Anesthesia for transfemoral aortic valve replacement in North America and Europe. *J Cardiothorac Vasc Anesth* **27**:46-9.
7. Oguri, A., Yamamoto, M., Mouillet, G., Gilard, M., Laskar, M., Eltchaninoff, H., Fajadet, J., Iung, B., Donzeau-Gouge, P., Leprince, P., Leguerrier, A., Prat, A., Lievre, M., Chevreul, K., Dubois-Rande, J.L., Chopard, R., Van Belle, E., Otsuka, T., and Teiger, E. 2014. Clinical outcomes and safety of transfemoral aortic valve implantation under general versus local anesthesia: subanalysis of the French Aortic National CoreValve and Edwards 2 registry. *Circ Cardiovasc Interv* **7**:602-10.
8. Bergmann, L., Kahlert, P., Eggebrecht, H., Frey, U., Peters, J., and Kottenberg, E. 2011. Transfemoral aortic valve implantation under sedation and monitored anaesthetic care--a feasibility study. *Anaesthesia* **66**:977-82.
9. Trenkwalder, T., Pellegrini, C., Holzamer, A., Philipp, A., Rheude, T., Michel, J., Reinhard, W., Joner, M., Kasel, A.M., Kastrati, A., Schunkert, H., Endemann, D., Debl, K., Mayr, N.P., Hilker, M., Hengstenberg, C., and Husser, O. 2018. Emergency extracorporeal membrane oxygenation in transcatheter aortic valve implantation: A two-center experience of incidence, outcome and temporal trends from 2010 to 2015. *Catheter Cardiovasc Interv* **92**:149-156.
10. Dolmatova, E., Moazzami, K., Cocke, T.P., Elmann, E., Vaidya, P., Ng, A.F., Satya, K., and Narayan, R.L. 2017. Extracorporeal membrane oxygenation in transcatheter aortic valve replacement. *Asian Cardiovasc Thorac Ann* **25**:31-4.
11. Banjac, I., Petrovic, M., Akay, M.H., Janowiak, L.M., Radovancevic, R., Nathan, S., Patel, M., Loyalka, P., Kar, B., and Gregoric, I.D. 2016. Extracorporeal Membrane Oxygenation as a Procedural Rescue Strategy for Transcatheter Aortic Valve Replacement Cardiac Complications. *ASAIO J* **62**:e1-4.
12. Drews, T., Pasic, M., Buz, S., Dreysse, S., Klein, C., Kukucka, M., Mladenow, A., Hetzer, R., and

- Unbehaun, A.** 2015. Elective use of femoro-femoral cardiopulmonary bypass during transcatheter aortic valve implantation. *Eur J Cardiothorac Surg* **47**:24-30
13. **Husser, O., Holzamer, A., Philipp, A., Nunez, J., Bodi, V., Muller, T., Lubnow, M., Luchner, A., Lunz, D., Riegger, G.A., Schmid, C., Hengstenberg, C., and Hilker, M.** 2013. Emergency and prophylactic use of miniaturized veno-arterial extracorporeal membrane oxygenation in transcatheter aortic valve implantation. *Catheter Cardiovasc Interv* **82**:E542-51.
14. **Platts, D.G., Sedgwick, J.F., Burstow, D.J., Mullany, D.V., and Fraser, J.F.** 2012. The role of echocardiography in the management of patients supported by extracorporeal membrane oxygenation. *J Am Soc Echocardiogr* **25**:131-41.