

**Surgical Management of Recurrent Temporomandibular Joint Dislocation -
Systematic Literature Review and Development of a Treatment Protocol**

Dr Shreya Tocaciu

ORCID: 0000-0002-9537-9302

University of Melbourne

MPHIL-MDHS

Student ID: 883225

Final Submission Date: December 2019

Supervisors

Prof Michael McCullough (BSc MSc (Oral Med, Oral Path) PhD FRACDS (Oral Med) FOMAA FPFA FICD)

Dr George Dimitroulis (MSc(Melb), PhD(Melb), FDSRCS(Eng), FFDRCS(Irel), FRACDS(OMS))

Executive Summary

Introduction

Dislocation of the temporomandibular joint (TMJ) is defined as a condition whereby the condyle of the temporomandibular joint moves outside the glenoid fossa, and may require external manipulation to return into its normal position. The condyle is usually dislocated into a position anterior and superior to the articular eminence. This is distinct from subluxation, where the condyle is only partially dislocated from its normal relation to the glenoid fossa, and can always be relocated without external forces. Dislocation of the TMJ can be classified as acute, chronic or recurrent.

Most cases of TMJ dislocation are acute, and occur as a result of trauma, protracted medical procedures, or as a result of dystonias. Chronic dislocation occurs as a result of the condyle sitting outside the glenoid fossa for a long period of time. It usually occurs in elderly or medically compromised patients, and can be difficult to treat as a result of formation of pseudoarthroses anterior to the glenoid fossa.

Recurrent TMJ dislocation is a rare entity and is poorly understood. Understanding regarding its pathogenesis and treatment is limited, and Oral and Maxillofacial surgeons often base treatment decisions on published case reports and limited case series. This thesis aims to consolidate the current understanding on the management of recurrent TMJ dislocation. It also aims to present a retrospective analysis of a new surgical treatment regime to treat this elusive condition, and proposed a rational approach to management.

Chapter Outline

Chapter One – Introduction

The aetiology of recurrent TMJ dislocation is poorly understood, and is likely to be multifactorial. Broadly, contributing factors can be grouped into three categories: altered bony anatomy, altered soft tissue laxity, and abnormal muscle movements.

The works of Sensoz et al in 1992 [1] and Hall in 1984 [2] found that patients suffering from recurrent TMJ dislocation had a more prominent articular eminence. Altered soft tissue laxity due to connective tissue disorders such as Marfan syndrome and Ehlers Danlos syndrome may also predispose to recurrent TMJ dislocation [3,4].

Abnormal muscle movements causing TMJ dislocation can be further classified as behavioural, iatrogenic, or dystonic. Behaviours such as excess yawning and biting large objects while protruding the mandible can result in dislocation. Iatrogenic causes of dislocation include prolonged dental or otolaryngology procedure, or overzealous mandibular manipulation during intubation or upper gastrointestinal endoscopy [5]. Lack of adequate occlusion can also result in a loss of vertical lower facial height and resulting overclosure of the mandible. This can also contribute to recurrent dislocation.

Dystonia caused by medications such as haloperidol [6], phenothiazine [5] and metoclopramide [7] can result in TMJ dislocation. Similarly, medical conditions causing extra-pyramidal symptoms such as Parkinson's disease and Huntington's disease can also cause recurrent TMJ dislocation [8].

An understanding of the anatomy of the TMJs is essential in appreciating the challenges in managing recurrent TMJ dislocation. Temporomandibular joints are a relatively late evolutionary feature of mammals, and arise from the third branchial arch [9]. They are unique in that in utero they are lined with hyaline cartilage, but this is quickly replaced with fibrocartilage after birth [10].

Movement within the joint compromises of rotation within the lower joint space, and translation in the upper joint space. The TMJ's are connected to each other across the midline via the mandible, meaning that pathology or abnormal movements in one joint will inadvertently affect the other. The function of each TMJ is also intimately affected by the occlusion and muscles of mastication.

Movements of the TMJ are supported and limited by the TMJ capsule and the three associated ligaments; the sphenomandibular, stylomandibular, and lateral TMJ ligaments. Dislocation of the TMJ causes these ligaments and the capsule to stretch and deform, which can further increase the risk of subsequent dislocations.

Dislocation of the condyle outside the glenoid fossa is usually as a result of hypermobility of the joint capsule, or due to external forces overcoming the integrity of the joint capsule and its supporting ligaments. Dislocation can also occur as a result of joint effusion, haemarthrosis or fracture dislocation. These types of dislocation must be approached differently and are outside the scope of this thesis.

The direction of condylar displacement can be in any direction, but is usually anteromedial.

Throughout history, many surgeons have described methods to treat recurrent TMJ dislocation. These include minimally invasive methods such as injection of sclerosing agents into the pericapsular tissues, eminectomy to remove obstruction to condylar movements, or various eminoplasty techniques to block the path of the condyle. These methods have been modified and adjusted by subsequent surgeons and academics, but to date no true gold standard treatment exists for recurrent TMJ dislocation.

Chapter Two – Systematic Review

Most current studies relating to management of recurrent TMJ dislocation are limited to case reports or small case series of single modalities. No true prospective randomised clinical trials exist. Most treatment modalities are based on anecdotal evidence and observation. In this thesis a systematic review was undertaken of the recent literature, extending from 2006 to 2016. The aim of the systematic review was to collate the current understanding on the management of recurrent TMJ dislocation, to allow surgeons treating this rare clinical entity to remain evidence based.

Using PRISMA guideline, a search was conducted over three databased; PubMed, Cochrane Library and Science Direct. The Medical Subject Heading (MeSH) terms “recurrent” “temporomandibular joint” and “dislocation” were used. This revealed a total of 64 papers, of which 33 met the required inclusion and exclusion criteria.

Thirty-three papers met criteria for inclusion in the systematic review. Of these papers, the majority were of low level evidence pertaining to level III (retrospective cohort series), level IV (case series) and level IV (case report or expert opinion). None of the papers could define the true incidence of recurrent TMJ dislocation in the adult population.

Goals of treatment of recurrent joint dislocation could be classified into three categories. The first category was where management strategies could aim to either counteract joint hypermobility by inducing fibrosis in the superior joint space or pericapsular tissues. The second group of treatment modalities aims to remove barriers to condyle movement (such as with eminectomy) and the third group limit excess anterior condylar translation (such as with disc plication or eminoplasty).

Some authors suggested that conservative or minimally invasive methods should be trialled before resorting to surgical management [2], while others suggested that the management of recurrent TMJ dislocation is primarily surgical, and that conservative methods provide temporary relief at best [11].

A review of the current literature (2006 to 2016) on recurrent TMJ dislocation was undertaken to update the surgeon on which is the ideal treatment for their patient.

Minimally invasive modalities described for treatment of recurrent TMJ dislocation between 2006 and 2016 were botulinum toxin into the lateral pterygoid muscle, autologous blood injection, injection of other sclerosing agents such as modified dextrose and OK-432, and arthroscopic electrothermal capsulorrhaphy with either Hol:YAG laser or electrocautery.

Injection of 25 to 50 units of botulinum toxin type A was described to have a success rate of 80%, and was usually utilised patients who were unsuitable for surgery. The lateral pterygoid was accessed either trans-cutaneously [25] or trans-orally [26], and the use of either pre-operative computerised tomography or intra-operative continuous electromyography was used to aid localisation of the muscle [26]. Injection of botulinum toxin into the lateral pterygoid muscle was not without risks, with reported adverse events including haematoma, intravascular injection, and inadvertent injection of adjacent muscles, including those involved in speech and swallowing [27,28].

Injection of autologous blood to induce fibrosis was also associated with a success rate of approximately 80% at 12 months [29,30,31,32]. Some cases required multiple injections (maximum three) [15]. Increased success was found in injection of both the superior joint space and the posterior pericapsular tissues [14]. Success was further increased when autologous blood injection was followed with a four-week period of intermaxillary fixation. However, this was also associated with corresponding decrease in mouth opening [15].

A preparation of 50% dextrose and lignocaine was also found to alleviate recurrent TMJ dislocation in 80% of cases when injected into the pericapsular tissues. Although the effect of the modified dextrose is not well understood, this retrospective study of 45 patients [16] shows promising initial results.

Another sclerosing agent used successfully for recurrent TMJ dislocation is OK-432, which is a group A streptococcal pyogenes derivative that have been inactivated with penicillin and lyophilized. This was shown in a series of only two patients [17], and therefore needs further study.

Arthroscopic delivery of electrocautery or Hol:YAG laser was shown in 82% (9 of 11 patients) to treat recurrent TMJ dislocation, with no recurrence at 27 months [18]. This method has the advantage that capsulorrhaphy is delivered under direct vision, limiting inadvertent effect to adjacent structures, as can occur with the previously described methods. Previous authors have also described concomitant injection of sclerosing agents such as sodium tetradecyl sulphate under direct vision to amplify the capsulorrhaphy effect [33]. This combined approach requires more investigation to demonstrate a true benefit.

Surgical methods for treatment of recurrent TMJ dislocation included in the systematic review include disc plication, eminectomy, eminoplasty and orthognathic surgery.

Disc plication using non-resorbable sutures and Mitek anchors was shown to have a 100% success rate at 12 months [19]. The advantage of this technique was that the joint space does not have to be entered if the disc is in its normal position [33]. Risks of disc plication are fracture of the Mitek anchors, or loosening or breakage of the sutures [33].

Eminectomy was described by several authors, with a success of 100% at up to five years [34,35,36]. The advantage of this technique is that theoretically there should be no recurrence as the barrier to relocation of the condyle has been removed. Risks include inadvertent entry into the infratemporal or middle cranial fossae [2]. This can be prevented by pre-operative CT scanning to determine the dimensions of the articular eminence or cranialisation/pneumatisation of the eminence [2].

Many forms of eminoplasty were described for management of recurrent TMJ dislocation. Some authors used Dautrey's original procedure [20], while others modified this with metalware or interpositional block grafts harvested from the calvarium, chin or anterior iliac crest [37,38,39]. All

studies found alleviation of recurrent TMJ dislocation. However, adverse effects of these procedures included limitation of mouth opening, fracture or failure of metalware requiring removal, or failure of the block graft [37,38,39].

Orthognathic surgery was also found to successfully treat recurrent TMJ dislocation when it was caused by a hyperdivergent dolichofacial type in a series of seven patients [23].

Recurrent TMJ dislocation remains a management challenge for practitioners, with no ideal treatment modality identified. In general, minimally invasive methods were associated with a success rate of 80%, although some patients required multiple treatments. The risk profile of minimally invasive methods was usually self-limiting and easy to manage, such as localised haematoma, or effect of botulinum toxin spreading to adjacent muscle groups. The risks of inadvertent injection of sclerosing into the joint, and the hypothetical risk of cartilage destruction was not explicitly explored. In this systematic review, there were no randomised clinical trials comparing minimally invasive treatment modalities.

Surgical methods for recurrent TMJ dislocation were associated with better success rate, with none of the included studies showing any failed cases. However, surgical management via disc plication and eminoplasty were associated with risks such as failure of metalware or failure of any interpositional block graft. Eminectomy was associated with a theoretical risk of inadvertent entry into the infratemporal or middle cranial fossae, but this could be prevented by pre-operative computerised tomography imaging and careful surgical technique.

A comparative study between eminoplasty and eminectomy showed that eminectomy was associated with better post-operative mouth opening [20]. However, randomised clinical trials comparing surgical modalities are lacking, as is a rationale for when one surgical modality should be chosen over the other.

Chapter Three – Surgical management of recurrent dislocation of the temporomandibular joint: a new treatment protocol

Recurrent dislocation of the TMJ is a rare clinical entity, which can pose a management dilemma for the health practitioner. The cause of recurrent dislocation is likely to be multifactorial, and can be grouped into altered bony anatomy, altered soft tissue laxity (hypermobility) or altered lateral pterygoid muscle tone (dystonia or spasm). The cause of an individual patient's recurrent TMJ dislocation may be elicited from medical history, imaging, or by the description of the dislocation. For example, a patient with a connective tissue disorder such as Ehlers Danlos syndrome is likely to suffer from joint hypermobility, whereas a patient with an extra-pyramidal movement disorder such as Huntington's disease may get dislocation secondary to lateral pterygoid spasm. These causative factors should be addressed in management of recurrent TMJ dislocation.

The current understanding of recurrent TMJ dislocation and its management is limited to case series and case reports of single modality treatment. In general, surgical management is associated with a better success rate than minimally invasive techniques. In the recent years (2006-2016), three categories of surgical management have been described, all with good effect. These include disc plication, eminectomy and various subtypes of eminoplasty. Of the three surgical modalities, eminectomy was associated with the best side-effect profile.

Of all the clinical papers critiqued in the systematic review, none assessed the effect of various treatment modalities on patient TMJ-related quality of life. Furthermore, none of the assessed papers looked at the efficacy of combined therapy, such as with disc plication and eminectomy together, or with de-functioning the lateral pterygoid via myotomy while accessing the joint for eminectomy.

This retrospective review aimed to describe the efficacy of combined surgical therapy on recurrent TMJ dislocation. Patients were treated with eminectomy and disc plication together, as

both of these modalities have been reported to show favourable success rates for alleviating recurrent dislocation.

Furthermore, patients who reported spontaneous TMJ dislocation, which represents lateral pterygoid muscle or spasm, underwent a lateral pterygoid myotomy at the same time as the eminectomy and disc plication. This aimed to tailor the surgery to the patient, rather than providing all patients with the same surgery regardless of their causation.

Methodology

A retrospective analysis was conducted on patients undergoing surgical management of recurrent TMJ dislocation over a period of six years, from 2010 to 2016. These cases were identified via hospital databases, consultant records and registrar logbooks, all relating to one consultant Oral and Maxillofacial surgeon who has a special interest in temporomandibular joint surgery.

Inclusion criteria were surgical management between March 2010 and March 2016 under the care of an Oral and Maxillofacial surgeon, age of patient above 18 years, and a diagnosis of recurrent TMJ dislocation.

Patients were reviewed with regards to demographic, presenting history, previous medical comorbidities, regular medications, and surgical management. Patients were also reviewed post-operatively with a TMJ-related quality of life survey. This survey was adapted from a previously validated questionnaire [40]. Ethical approval for this study was granted by the Human Research and Ethics Committee (HREC).

Results

During the study period of six years, a total of 14 patients suffering from recurrent TMJ dislocation underwent surgical management. Of these patients, most were female (10 of 14 patients), and aged between 21 and 30 years of age (11 of 14 patients).

Patients reported TMJ dislocation both spontaneously (10 of 14 patients) and on wide opening (12 of 14 patients). Most patients suffered from a dislocation event every 60 days, and all patients had suffered from recurrent dislocation for a minimum of three years before surgical intervention was undertaken. Of the fourteen patients, one patient had a history of myotonic dystrophy, resulting in lateral pterygoid dystonia and spontaneous TMJ dislocation.

Bilateral TMJ dislocation was seen commonly, in 10 of the 14 patients. Of the remaining 4 of 14 patients with unilateral dislocation, there was equal distribution between the right and left sides. Less than half of the patients (6 of 14 patients) reported that on occasion they could manipulate the condyle back into the glenoid fossa themselves, whereas the remaining (8 of 14 patients) required medical attention for every single dislocation event.

All patients underwent a pre-auricular approach to the temporomandibular joint. An eminectomy and disc plication was performed in all cases. A lateral pterygoid myotomy was also performed on the one patient who had reported a history primarily of spontaneous TMJ dislocation.

Patients were followed up for a minimum of 12 months, and a maximum of 5.6 years. During this period, there was no recurrence in TMJ dislocation in any patient. Most patients (12 of 14 patients) reported that they were completely pain-free.

Patients were asked to complete a TMJ-related quality of life survey which has previously been validated in another study [40]. The response rate to this questionnaire was 11 of 14 patients.

Regarding their TMJ-related quality of life, all patients were satisfied that their TMJ caused no limitations to speech, normal activities of daily living, or recreational activities.

Most patients reported no pain (8 of 11 patients), and no limitations to diet (9 of 11 patients). Only 3 of 11 of patients reported any residual anxiety related to the fear of a recurrent dislocation during wide opening or spontaneously.

The majority of patients felt that surgery had resulted in an improvement in their health related quality of life (9 of 11 patients) and 10 of 11 would recommend the surgery to a friend suffering from recurrent TMJ dislocation

Discussion

This is the first retrospective review which combines eminectomy and disc plication for patients suffering from recurrent dislocation of the TMJ. It is also the first study to tailor management via the addition of a lateral pterygoid myotomy for cases where predominantly a spontaneous type of joint dislocation is described.

A proposed treatment approach is outlined. Once the diagnosis of recurrent TMJ dislocation is established, the patient must be assessed for surgery. If surgery is contraindicated due to medical co-morbidities or patient preference, then minimally invasive methods may be trialled. If a surgical approach is supported, then the options considered include:

- Eminectomy and disc plication
- Eminectomy, disc plication and lateral pterygoid myotomy.

Patients describing spontaneous dislocation of their joint may benefit from the additional lateral pterygoid myotomy procedure as the anteromedial pull of the lateral pterygoid muscle is significantly reduced, if not eliminated.

This paper proposes a combined surgical arthroplasty approach including eminectomy and disc plication. For patients suffering from spontaneous TMJ dislocation, a lateral pterygoid myotomy is also performed.

Despite the small sample size, this paper shows promising long term results in the surgical management of recurrent TMJ dislocation when combining the procedures of eminectomy and disc plication. However, a larger prospective study directly comparing the different surgical modalities

separately and in combination is required before we can be certain of the most appropriate technique for the management of recurrent TMJ dislocation.

Chapter Four - Conclusion and Clinical Recommendations

The treatment modalities with highest success rate of alleviating recurrent TMJ dislocation are eminectomy [20] and disc plication [19]. Both of these treatment modalities, when described in case series or small case reports, describe a success rate of 100%. Eminoplasty also showed promising success, but there was no consensus on technique, and risks included limitation of mouth opening, need for the fixation to be removed, and temporary facial nerve paralysis [22].

The lack of consensus on management options for recurrent TMJ dislocation, as well as the lack of a personalised treatment approach led to a retrospective analysis of fourteen patients with recurrent TMJ dislocation treated via a tailored surgical approach. Here, patients were treated with eminectomy and disc plication, both of which have been associated with 100% success rate in small case series [19,20]. This was augmented with a lateral pterygoid myotomy in patients who described spontaneous dislocation, which is thought to represent lateral pterygoid muscle dystonia or spasm.

All patients included in the study were managed via a combined surgical approach. Patients underwent a pre-auricular approach to the joint, and were treated with an eminectomy and disc plication. Those patients who described spontaneous TMJ dislocation were also treated with a lateral pterygoid myotomy. Patients were followed up for a minimum of 12 months. There were no cases of recurrence in TMJ dislocation. Patients were followed up with a TMJ-related quality of life survey that has been previously validated [40]. Most patients reported no pain with daily activities (78.6%, 11 of 14 patients). All patients could note no issues with speech, and most (81.2%, 9 of 14 patients) could tolerate a full diet. The majority of patients (90.9%) would recommend surgery to a friend with recurrent TMJ dislocation.

Prior to the current study, the role of a tailored combined surgical approach for recurrent TMJ dislocation has not been described. Eminectomy removes any barriers for the condyle to return to the glenoid fossa. Furthermore, disc plication allows coordinated movement between the articular disc and the condyle. It also may alter proprioceptive feedback relating to condyle position, limiting anterior translation. Lateral pterygoid myotomy addresses any muscle dystonia or spasm causing spontaneous TMJ dislocation.

Recurrent TMJ dislocation is a rare clinical entity that is poorly understood, and has no gold standard treatment modality. An understanding of normal TMJ anatomy and function is necessary to understand the role of different treatment modalities for recurrent TMJ dislocation.

Assessment of the patient with recurrent TMJ dislocation is essential in identifying what factors are precipitating dislocation. These factors can then be targeted via either a minimally invasive or surgical approach.

Based on the current limited evidence base, surgical approaches are associated with better success rates when compared to minimally invasive techniques. Prior to this thesis, the role of combined surgical approaches has not been described. This paper suggests that a tailored approach comprising of eminectomy, disc plication and/or lateral pterygoid myotomy is associated with a 100% success rate at 12 months. It is also associated with improvement in TMJ-related quality of life, and has great patient acceptability, with most patients reporting that they would recommend this surgery to a friend suffering from recurrent TMJ dislocation.

Word Count: 3,660 (limit 2500-5000 words)

Abstract

Recurrent TMJ dislocation is a rare entity, clinically distinct from acute or chronic dislocation. It is associated with significant morbidity and deterioration to quality of life for affected patients. Recurrent temporomandibular joint (TMJ) dislocation can be challenging to treat and current understanding regarding aetiology and management of this condition is limited.

The aim of this thesis was twofold. The first was to conduct a systematic review regarding the current understanding of managing recurrent TMJ dislocation. The second aim was to review the surgical management and long-term outcomes of patients with recurrent TMJ dislocation who presented to a single Hospital Department over a period of six years so as to formulate a practical treatment algorithm. A retrospective review of cases surgically managed for recurrent TMJ dislocation was undertaken with respect to patient demographics, clinical features, surgery provided, and long term follow up.

A literature review was conducted using PRISMA guidelines to identify papers published between 2006 and 2016. The resultant papers were analysed.

A total of 33 papers were found relevant to the study. Minimally invasive techniques described included autologous blood injection, which was associated with an overall success of 80% at 12 months. Other modalities investigated included OK-432 sclerotherapy, laser capsulorrhaphy, botulinum toxin of the lateral pterygoid muscle or modified dextrose. These publications show promising success rates.

Surgical techniques described included disc plication, eminoplasty and eminectomy. These modalities had a similar success rate, although numbers were limited.

For the second part of this thesis, a total of 14 patients were identified who were managed for recurrent TMJ dislocation over a 6-year period from 2010 to 2016. The cases were followed up for a minimum of 12 months and a maximum of seven years. Results showed effective long-term

resolution of symptoms using a combination of eminectomy, disc plication (meniscopexy) and where clinically indicated, lateral pterygoid myotomy.

This thesis found that the true incidence of recurrent TMJ dislocation is unknown and aetiology is limited to expert opinion. The current understanding of management for recurrent TMJ dislocation is limited to case series and case reports. This thesis compiles the current understanding of management of recurrent TMJ dislocation. A decision making algorithm, with a personalised, step-wise approach to treatment is presented. The retrospective review portion of the thesis has shown that a combination of eminectomy and disc plication (meniscopexy) is effective in providing long term positive outcomes in the surgical management of recurrent TMJ dislocation. Those cases of recurrent TMJ dislocation resulting from dystonia of the lateral pterygoid muscle also benefitted from additional lateral pterygoid myotomy.

Word Count Abstract: 422 (limit 500 words)

Declaration

This thesis comprises original works towards the author's Masters of Philosophy (MDHS) except where indicated in the preface.

Due acknowledgement has been made in the text to all other materials used.

This thesis is fewer than the maximum word limit of 30,000, exclusive of tables, maps, bibliographies and appendices.

Dr Shreya Tocaciu

BDS, MBBS

Acknowledgements

This thesis would have been impossible without the following people:

Firstly, my supervisors, Mr George Dimitroulis and Prof Michael McCullough, who encouraged me during conception of the project, were supportive during my numerous drafts and re-drafts, remained patient during my dozens of emails, and kept inspiring me to push on. Your enthusiasm and drive is an inspiration, and I am grateful for your constant support.

Second, my family, who provide me with an endless source of love, wisdom, and encouragement. Mum, Papa and Surabhi - you keep my feet firmly grounded but still inspire me to aim for the stars. You are my role models for achieving the balance between work and life, between academic and philosopher, and between teacher and student.

Lastly, my husband Luke, who allows me to pursue my dreams with patience. You pick me up when I fall and back me when I waiver. Your strength, compassion and energy is inspiring.

Table of Contents

Title page	1
Executive Summary	3
Abstract	17
Declarations	19
Acknowledgements	21
Table of Contents	23
List of Tables	27
List of Figures	29
Ethics Approval	31
List of all third party copyright material	33
Chapter 1: Introduction	35
1.1 Aetiology of TMJ dislocation	35
1.2 Anatomy of the Temporomandibular Joint	37
1.2.1 Embryology of the TMJs	37
1.2.2 Unique features of TMJs	39
1.2.3 Components of the TMJs and its supporting structures	39
1.2.3.1 The condyle	39
1.2.3.2 The glenoid fossa and articular eminence	39
1.2.3.3 The articular eminence	42
1.2.3.4 The articular cartilage	45
1.2.3.5 The TMJ capsule and ligaments	45
1.2.3.6 Synovial fluid and the synovial membrane	46
1.2.3.7 Sensory innervation to the TMJ	46
1.2.3.8 Vascular supply of the TMJ	46
1.2.4 The muscles of mastication	46
1.2.4.1 Masseter	47
1.2.4.2 Temporalis	48
1.2.4.3 Medial pterygoid	49
1.2.4.4 Lateral pterygoid	50
1.2.4.5 Anterior belly of the digastric	52
1.2.5 Comparative Anatomy	52
1.2.6 Surgical Relevance to Dislocation	53

1.2.7 Surgical Relevance of TMJ Anatomy	55
1.3 Temporomandibular Joint Dislocation	57
1.3.1 Acute Dislocation	57
1.3.1.1 The Hippocratic manoeuvre	57
1.3.1.2 The gag reflex procedure	58
1.3.1.3 The wrist pivot technique	58
1.3.1.4 The extra-oral technique	58
1.3.2 Chronic/Protracted Dislocation	59
1.4 History of Temporomandibular Joint Surgery	61
1.4.1 Procedures that remove obstruction to the condylar path	61
1.4.2 Procedures that limit anterior translation of the condyle	62
1.5 Justification for Systematic Review and Retrospective Analysis	64
Chapter 2: Systematic Review	67
2.1 Protocol	67
2.1.1 Objectives and Hypothesis	67
2.1.2 Inclusion Criteria	69
2.1.3 Exclusion Criteria and Review Methods	69
2.2 Results of Systematic Review	71
2.2.1 Description of Studies	71
2.2.2 Papers relating to overviews of opinions	71
2.2.2.1 Incidence	71
2.2.2.2 Aetiology	71
2.2.2.3 Investigations	72
2.2.2.4 Treatment options	72
2.2.2.5 Efficacy of treatment	73
2.2.3 Minimally Invasive Methods	73
2.2.3.1 Botulinum Toxin A Injection	73
2.2.3.2 Autologous blood into joint space	74
2.2.3.3 Modified Dextrose Injection into Joint Space	76
2.2.3.4 Intra-articular injection of OK-432	77
2.2.3.5 Electrothermal Capsulorrhaphy	77
2.2.4 Surgical Methods	79
2.2.4.1 Disc Plication	79
2.2.4.2 Eminectomy	79

2.2.4.3 Eminoplasty	80
2.2.4.4 Orthognathic Surgery	83
2.3 Discussion of Systematic Review	85
2.3.1 Botulinum Toxin A into Lateral Pterygoid Muscle	86
2.3.2 Autologous blood into joint space	87
2.3.3 Modified Dextrose Injection into Joint Space	88
2.3.4 Intra-articular injection of OK-432	89
2.3.5 Electrothermal Capsulorrhaphy	89
2.3.6 Disc Plication	89
2.3.7 Eminectomy	90
2.3.8 Eminoplasty	90
2.3.9 Orthognathic Surgery	91
2.4 Conclusion of Systematic Review	92
Chapter 3: Surgical management of recurrent dislocation of the temporomandibular joint: a new treatment protocol	97
3.1 Introduction	97
3.2 Methodology	99
3.3 Results	104
3.4 Discussion	111
Chapter 4: Conclusion and Clinical Recommendations	117
References	121
Appendices	131
Appendix I - Search Strategies	131
Appendix II – Appraisal Instrument Utilised	133
Appendix III – Studies Retrieved from Databases	135
Appendix IV – Included Studies and Appraisal	145
Appendix V – Summary of Appraisals	151
Appendix VI – Excluded Studies with Justification	155
Appendix VII – Data from Included Studies	161
Appendix VIII – Questionnaire	163
Appendix IX – List of Abbreviations	167
Appendix X – Publication: Surgical management of recurrent dislocation of the temporomandibular joint: a new treatment protocol	169
Appendix XI – Publication: Recurrent dislocation of the TMJ – a systematic review	175

List of Tables

Table	Description	Page
Table I	Minimally invasive management of recurrent TMJ dislocation	78
Table II	Surgical management of recurrent TMJ dislocation	84
Table III	Inclusion criteria for patient selection	103
Table IV	Patient demographics and pre-operative data	106
Table V	Operative management of patients	107
Table VI	Post-operative findings	108
Table VII	Results from TMJ-related quality of life questionnaire completed at final patient visit	109
Table VIII	Causes of recurrent TMJ dislocation	111
Table IX	Recommended patient history when determining nature of recurrent TMJ dislocation	111

List of Figures

Figure	Description	Page
Figure 1	Histopathological slide of a coronal slice through a developing temporomandibular joint on low power with haematoxylin and eosin stain [90].	38
Figure 2	Osteology of the TMJ and its adjacent structures [90].	41
Figure 3	Cadaveric specimen showing the upper joint compartment between the temporal bone and articular disc, and the lower joint compartment, between the articular disc and condyle [91].	43
Figure 4	Histological cross-section of the temporomandibular joint with Masson's trichrome stain, depicting the anatomy of the articular disc [90].	44
Figure 5	Relationship between the masseter and temporalis, and their bony attachments [90].	48
Figure 6	Medial and lateral pterygoid muscles depicted with the mandibular ramus removed [90]	50
Figure 7	Dried mandibular specimen showing attachments of some of the muscles of mastication [90].	51
Figure 8	Orthopantomogram (OPG) (1a) and lateral cephalogram (1b) of a patient suffering from bilateral temporomandibular joint dislocation	54
Figure 9	Papers included and excluded in study	70
Figure 10	Comparison of post-operative maximum inter-incisive opening	94
Figure 11	Operative field before (A) and after (B) eminectomy	101
Figure 12	Decision making algorithm for treatment of recurrent TMJ dislocation	115

Ethical Approval

This research was granted ethical approval from the Research Governance Unit of the St Vincent's Hospital Melbourne. LNR HREC reference number LNR/17/SVHM/19.

List of all third party copyright material

Consent for publication

All authors and subjects involved in this research have consented for its publication

Availability of data and material

Raw data and further material is available on request from the corresponding author

Conflict of interest

The author has no conflict of interest to declare.

Funding

The authors did not receive any funding for this research or any associated publication

Chapter 1: Introduction

1.1 Aetiology of TMJ dislocation

Dislocation of the temporomandibular joint occurs when the condyle moves outside of the glenoid fossa, and cannot relocate into the fossa without external force.

The causes of dislocation can be classified as those due to altered bony anatomy, altered soft tissue laxity, and abnormal movements.

Anatomical differences in the form of the articular eminence have been shown in patients prone to TMJ dislocation. Sensoz et al, in 1992 found that patients prone to TMJ subluxation or dislocation were more likely to have a higher articular eminence [1].

Altered soft tissue laxity, such as that caused by connective tissue disorders, can result in joint hypermobility. In particular, Marfan's syndrome and Ehlers Danlos syndrome have been implicated in recurrent TMJ dislocation [3,4].

Factors resulting in abnormal movement of the TMJ's, causing dislocation include excessive yawning and trauma. Iatrogenic causes include prolonged dental procedure, vigorous mandibular manipulation during anaesthetic procedures, and upper gastrointestinal endoscopy [5]. Abnormal movements can also be caused by any agent that induces extra-pyramidal side effects. Drugs implicated in causing TMJ dislocation include haloperidol [6], phenothiazine [5] and metoclopramide [7]. Medical conditions causing extra-pyramidal symptoms such as Parkinson's disease can also cause recurrent TMJ dislocation [8].

Acute dislocation may occur as a result of trauma or parafunction. Chronic or prolonged dislocation may occur due to a lax joint capsule, either due to age related joint degeneration, or anatomical, or even due to the extrapyramidal side effects of anti-psychotic drugs such as haloperidol. It occurs when there is an acute episode of TMJ dislocation which is not treated for a prolonged period of time. Recurrent TMJ dislocation is repeated acute dislocation of the joint

which occurs sporadically over an extended time line of many months or years, resulting in functional deterioration of the joint. It can be due to joint laxity or anatomical variation of the articular components [41].

Discussion on types of TMJ dislocation cannot be complete without mention of subluxation. Subluxation of the TMJ is described as movement of the condyle outside glenoid fossa or its normal path of opening, but where reduction can be achieved by the patient without the help of any external manoeuvres. True dislocation of the TMJ may require external forces to be applied to the mandible for reduction to occur [5]. This can either be by self-manipulation by the patient, or guidance into the glenoid fossa by a medical or dental practitioner.

The term *elapsio prearticularis*, or physiological subluxation, has also been described for situations where the condyle moves anterior to the articular eminence of wide opening, as seen on open mouth radiographs, but can move back into the glenoid fossa on closing [24]. Physiological subluxation of the condyle anterior to the articular eminence when opening wide can be seen in 65 to 85.3% of patients with normal temporomandibular joints [5].

1.2 Anatomy of the Temporomandibular Joint

Understanding the anatomy of the temporomandibular joint is critical in appreciating pathology in the joints, as well as the role of different surgical procedures. The embryology of the TMJs is discussed, as well as the unique features of the TMJs when compared to other joints. The components of the joint and its supporting structures are described, and the relevance to dislocation and its management presented.

1.2.1 Embryology of the TMJs

The evolution of temporomandibular joints occurred relatively late in mammalian development [9]. They are unique to mammals and develop from Meckel's cartilage, which is a derivative of the third branchial arch [9]. The bones involving the joint, the mandible and temporal bone, are both intramembranous in origin. Another unique feature is that their articular surfaces are covered in fibrocartilage rather than hyaline cartilage that line other joints [9]. The exception to this is in neonates, where the joint is lined with hyaline cartilage. With time, this is quickly replaced with a thin layer of fibrocartilage [10].

The Meckel's cartilage derives from the first branchial arch at around the 6th week of embryonic development. It acts as the scaffold for development of the mandible, middle ear, glenoid fossa, and trigeminal nerve [42]. Other derivatives of Meckel's cartilage include sphenomandibular ligament (figure 1).

The TMJ has an important role in growth activation and modification [9]. The Meckel's cartilage of the TMJ may modify growth of the adjacent bones, which develop via intramembranous ossification. Other cartilaginous structures in the head and neck and exhibit this growth modifying behaviour are the cranial base and nasal cartilages [9].

Figure 1 – Histopathological slide of a coronal slice through a developing temporomandibular joint on low power with haematoxylin and eosin stain [42].

(MC) – Meckel’s Cartilage

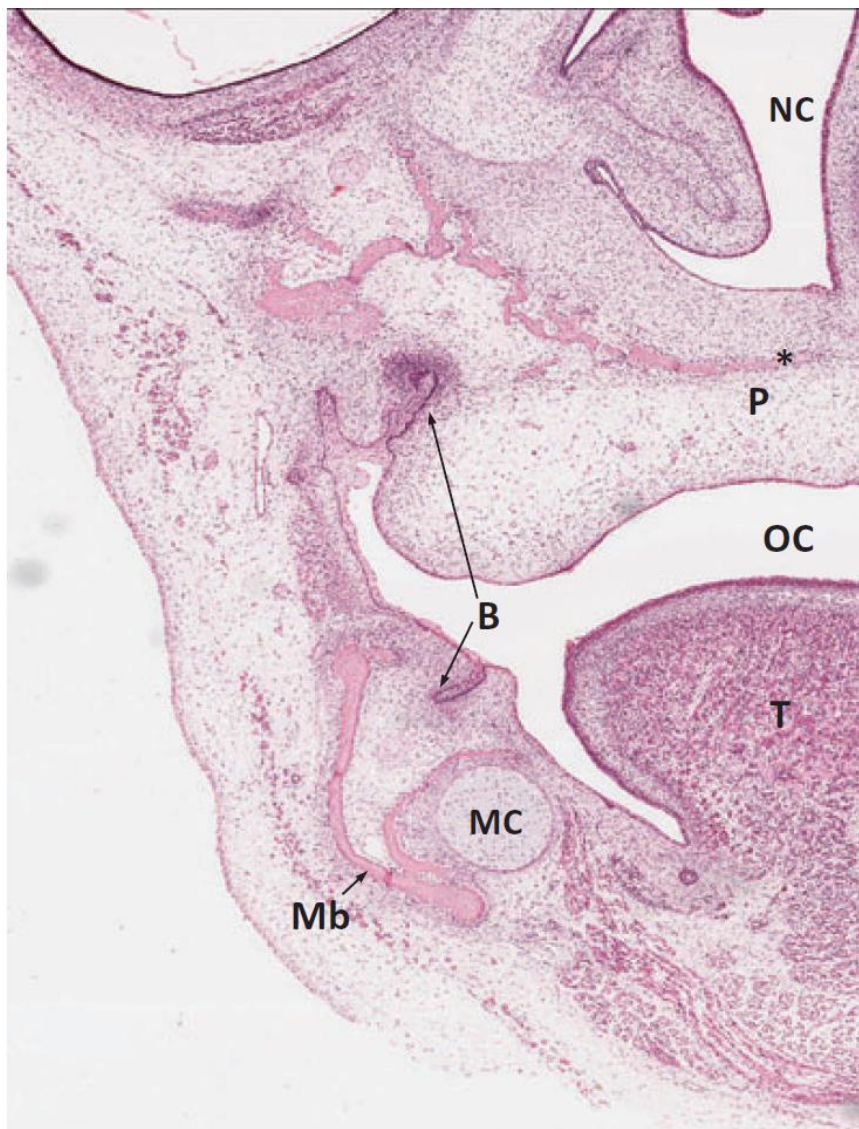
(Mb) – Mandible

(NC) – Nasal cavity

(P) – Palate

(OC) – Oral cavity

(T) – Tongue



1.2.2 Unique features of the TMJs

The TMJs are interesting joints as they have some unique features;

The first of these is that the TMJ is a ginglymoarthrodial joint as the range of motion includes both rotation (ginglymus) and translation (arthrodial movement). The rotational movements are predominantly between the articular disc and the condyle (the inferior joint space) and translational movements occur in the upper joint space, which is formed between the articular disk and the glenoid fossa/articular eminence

Secondly, the articular surfaces are lined with fibrocartilage rather than hyaline cartilage. The sternoclavicular joints are also lined with fibro-cartilage, hence their proposed use in TMJ reconstruction.

Next, the TMJs are bilateral and are connected through the midline via the mandible. This means that they are controlled and affected not only by the muscles of mastication, but by the function (and parafunction) of the contralateral joint.

Lastly, movements of the TMJs during the final few millimetres of closure are guided intimately by the occlusion. These unique characteristics must be addressed when considering the pathogenesis and treatment of TMJ disorders.

1.2.3 Components of the TMJs and its supporting structures

1.2.3.1 The Condyle

The mandibular condyle measures on average 15-20mm in the lateral dimension, and 8-10mm in the anteroposterior direction [43]. The long axis of the condyle is perpendicular to the ramus [44]. The anterior surface of the condyle is convex.

1.2.3.2 The Glenoid Fossa and Articular Eminence

The temporalis bone forms the cranial component of the TMJ. There are two parts to the temporal bone articulation, the glenoid fossa and the articular eminence. The glenoid fossa is

formed by thin concave bone that separates the upper joint space from the middle cranial fossa [44].

The articular eminence is a thick convex strut of bone anterior to the glenoid fossa and posterior to the root of the zygomatic process. Its lateral extent forms a tubercle, to where the TMJ capsule and lateral TMJ ligament insert [44] (Figure 2).

Figure 2 – osteology of the TMJ and its adjacent structures [42].

(Cn) – Coronoid process

(R) – Ramus

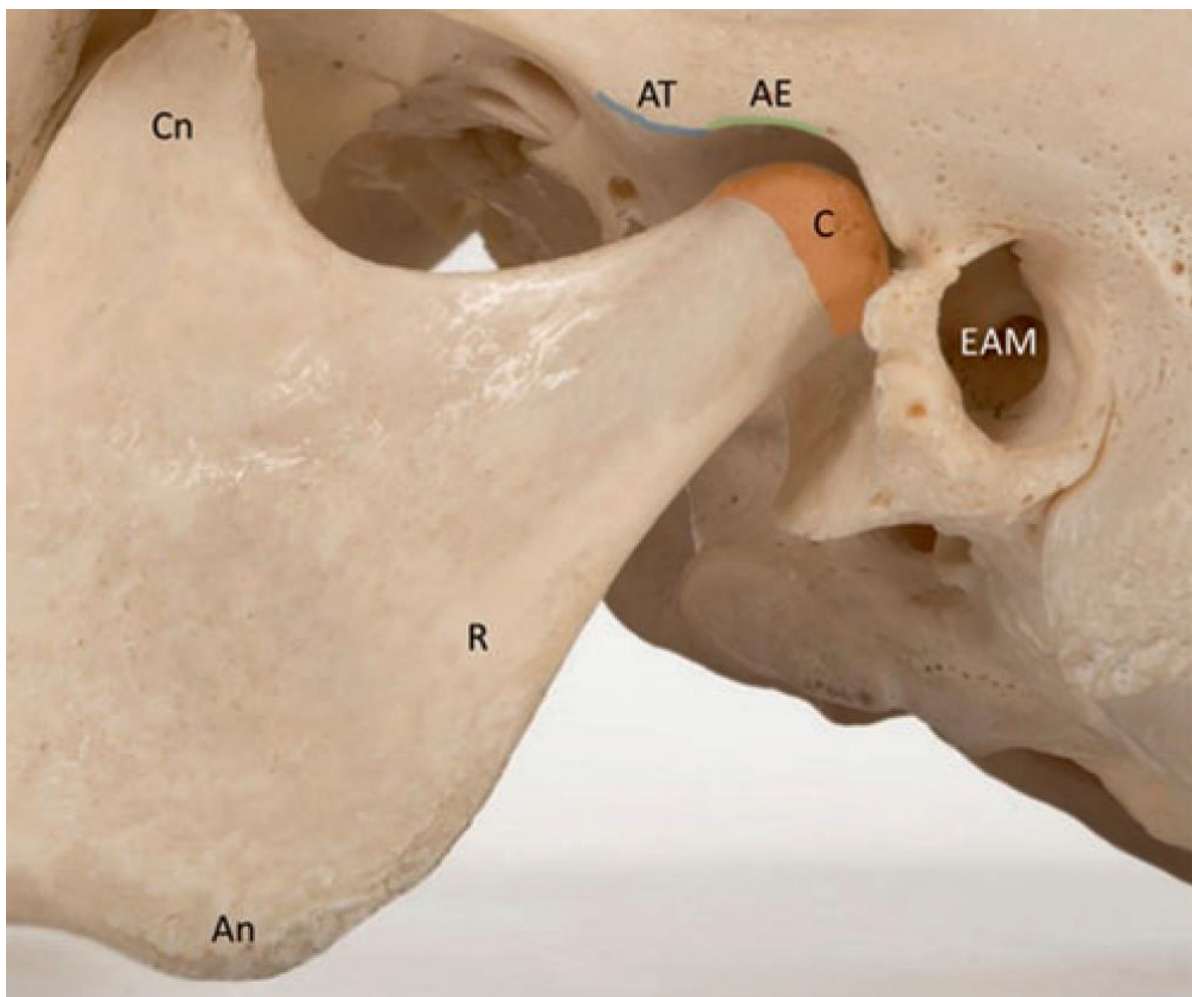
(C) – Condyle

(EAM) – External acoustic meatus

(AE) – Articular eminence

(AT) – Articular tubercle

(An) – Angle of the mandible



1.2.3.3 The Articular Meniscus

The articular meniscus is an avascular and aneural structure, composed largely of fibrocartilage lined with synovial membrane. It comprises of three zones; the anterior thick zone, the intermediate thin zone, and the thick posterior zone [43]. This causes the articular meniscus to be biconcave in shape [44].

The anterior thick zone attaches to fibres of the upper head of the lateral pterygoid muscle, which allows anterior translation of the disc with mouth opening. The anterior thick zone also attaches to the articular eminence and condyle via the joint capsule [43].

The posterior thick zone is continuous with the vascular retrodiscal tissue. The articular disc and its attachments divide the temporomandibular joint into upper and lower compartments (figure 3)

The intermediate thin zone is where the majority of forces are imparted. With ongoing functional or dysfunctional forces, the middle of the intermediate thin zone may form a perforation [44]. These zones form into a biconcave articular disc, which is closely adapted to the articular surfaces of the condyle, glenoid fossa, and articular eminence (Figure 4).

Fibres within the disc are interwoven, allowing a small degree of stretch [10].

Figure 3 – Cadaveric specimen showing the upper joint compartment between the temporal bone and articular disc, and the lower joint compartment, between the articular disc and condyle [45].

(E) – Articular eminence

(U) – Upper joint space

(D) – Articular disc

(L) – Lower joint space

(C) – Condyle of mandible

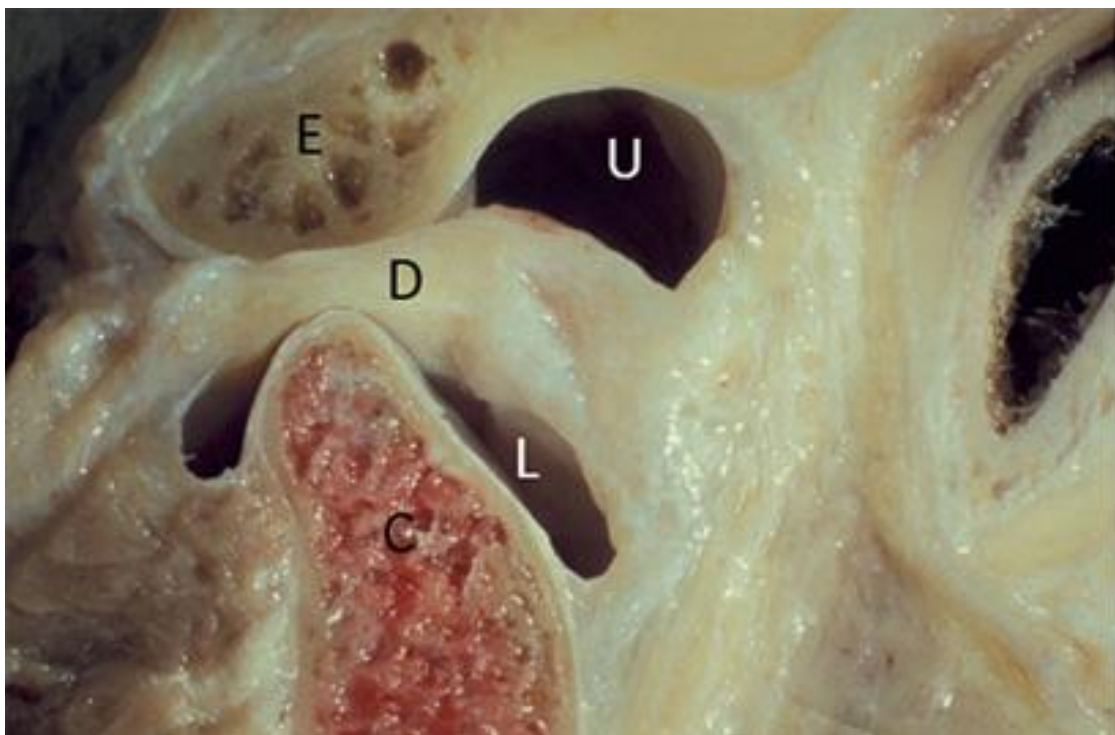


Figure 4 - Histological cross-section of the temporomandibular joint with Masson's trichrome stain, depicting the anatomy of the articular disc [42].

(T) – Temporal bone

(C) – Condyle

(LPt) – Lateral pterygoid muscle

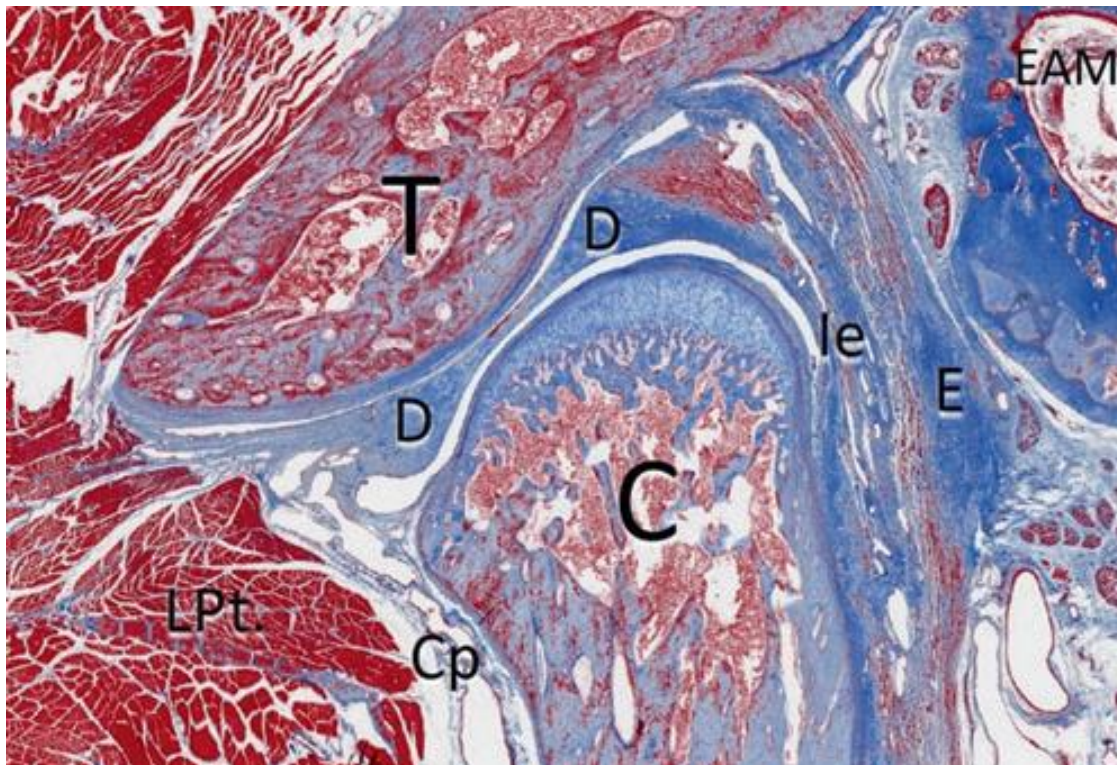
(Cp) – Joint capsule

(D) – Articular disc

(le) – Inelastic component of retrodiscal tissue

(E) – Elastic component of retrodiscal tissue

(EAM) – External acoustic meatus



1.2.3.4 The Articular Cartilage

In contrast to other joints, the TMJ originates from intramembranous bone, and is therefore lined with fibrocartilage, rather than hyaline cartilage. This is the same cartilage of which the articular meniscus is formed [10].

The articular cartilage of the TMJ consists of 4 distinct layers [46].

1. The superficial or articular zone
2. The proliferative or polymorphic zone. This zone has the capacity to regenerate or remodel under functional stress [47] and can form either cartilage or bone.
3. The chondroblastic zone
4. The hypertrophic zone

The fibrocartilage of the TMJ has minimal vascular supply, and relies on the synovium for gas exchange and nutrients [47].

1.2.3.5 The TMJ Capsule and Ligaments

The TMJ capsule is attached to the articular eminence, glenoid fossa, condyle, squamo-tympanic fissure [10] and the medial and lateral aspects of the articular meniscus [43]. The role of the TMJ capsule is to provide structural support to the joint, and to prevent disarticulation.

There are three supporting ligaments of the temporomandibular joint. The lateral TMJ ligament, the sphenomandibular ligament, and the stylomandibular ligament.

The lateral TMJ ligament is composed of a superficial and a deep band, whose collagen fibres pass in different directions [44]. The larger superficial band runs postero-inferiorly from the lateral tubercle of the articular eminence to the posterior aspect of the condylar neck. The smaller medial band originates on the lateral tubercle of the eminence and attaches to the lateral surface of the condylar disc. Some collagen fibres also attach to the articular meniscus.

The sphenomandibular ligament arises from the spine of the sphenoid bone and inserts into the lingula of the mandibular foramen, on the medial surface of the mandibular ramus. This ligament maintains its length and tension with all movements of the joint [10].

The stylomandibular ligament arises from the styloid process of the sphenoid bone, to the posterior aspect of the mandibular angle. It is formed by a thickening of fascial tissue, and does not contribute significantly to the structural integrity of the temporomandibular apparatus.

1.2.3.6 Synovial Fluid and the Synovial Membrane

The TMJ articular surfaces are lined with synovium, a thin layer of synovial cells with a rich vascular and neural supply [47]. Synovial cells produce synovial fluid, which is an ultra-filtrate of blood plasma [47]. Synovial fluid is a viscous lubricating fluid rich in hyaluronic acid and nutrients. In a healthy TMJ, there is usually less than 2ml of synovial fluid [47]. Synovial cells also have a phagocytic function, cleaning up any particulate cartilage lost into the synovial fluid with shear stress. Synovial cells may also have the capacity to differentiate into chondrocytes, especially under stressful conditions [47].

1.2.3.7 Sensory Innervation to the TMJ

The TMJ receives sensory innervation mainly from the auriculotemporal nerve. It also receives some innervation from the masseteric branch of the mandibular nerve (Hilton's law) which supplies the masseter muscle [10,44]. Hilton's law states that the nerve supplying a muscle which acts on a particular joint also innervates the corresponding joint and overlying skin. In relation to the TMJ, this means that the joint and its overlying skin are supplied by branches of the trigeminal nerve, which also supplies the muscles of mastication [10,44].

1.2.3.8 Vascular Supply of the TMJ

Arterial supply to the TMJ is from multiple sources. The posterior aspect of the joint is supplied by the superficial temporal artery, one of the terminal two branches of the maxillary artery [43]. The anterior aspect of the joint is supplied by masseteric, deep temporal, and lateral pterygoid branches of the maxillary artery [43].

1.2.4 The Muscles of Mastication

The role of the muscles of mastication is to allow the mandible to move in infero-superior, anteroposterior and medio-lateral directions. The muscles of mastication attach to the mandible

and either the cranial base or the hyoid bone, and thereby indirectly apply force vectors on the TMJ. There are five pairs of muscles of mastication: the masseters, temporalis, medial pterygoids, lateral pterygoids, and anterior bellies of digastric. Other muscles that also influence mandibular position, and therefore TMJ function, include the geniohyoid and mylohyoid muscles. All of the muscles of mastication are innervated by branches of the anterior trunk of the mandibular nerve, which is the third division of the trigeminal cranial nerve [44].

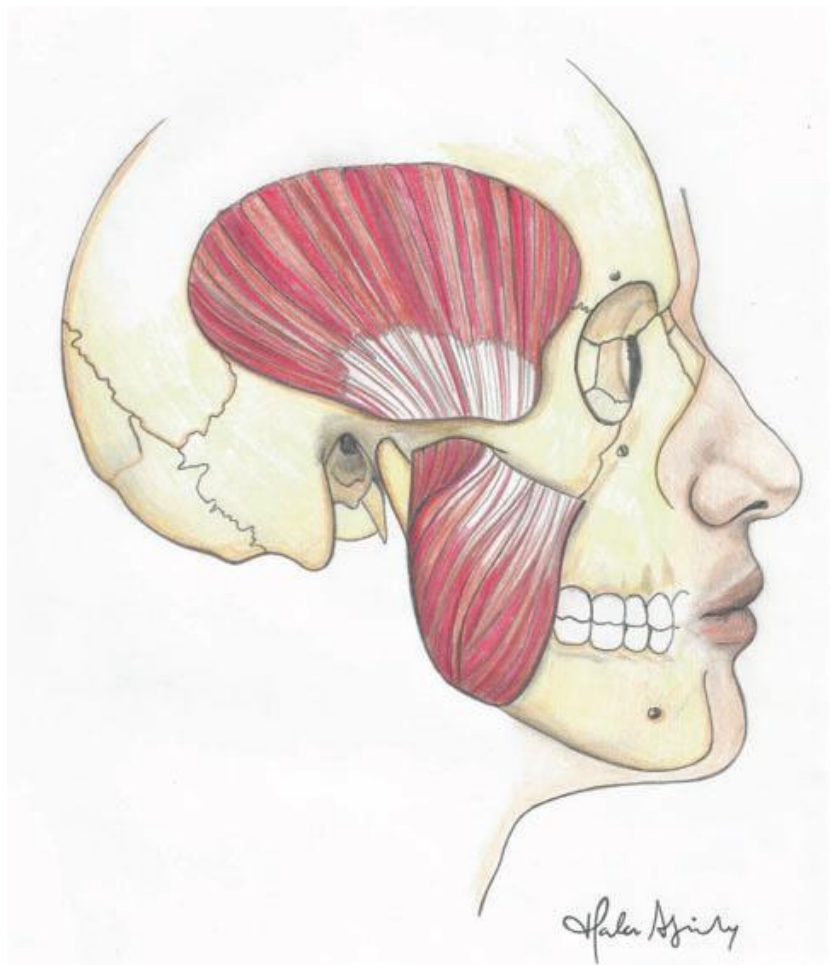
1.2.4.1 Masseter

The masseter muscles are thick quadrilateral muscles that are situated on the lateral aspect of the ramus. They can be divided into three distinct layers by the direction in which the muscle fibres run [44]. The superficial layer originates from the anterior half of the inferior surface of the zygomatic arch and the zygomatic process of the maxilla. It inserts into the mandibular angle and the inferior half of the ramus, such that muscle fibres run in an inferior and posterior direction. The middle layer originates from the anterior half of the medial surface of the zygomatic arch, as well as the inferior surface of the posterior face of the zygomatic arch. It inserts to the lateral surface of the ramus, with fibres running inferiorly. The deep layer of the masseter muscle originates from the medial surface of the zygomatic arch, and attaches to the superior half of the lateral ramus. Some muscle fibres also attach to the coronoid process. Fibres in the deep layer of the masseter lie in a infero-medio-anterior direction [44] (Figure 5).

The masseter muscle has innervation from the anterior division of the mandibular branch of the trigeminal nerve. Its arterial supply is from the masseteric branches of the maxillary artery, and venous drainage is to the retromandibular vein and the pterygoid venous plexus via the masseteric vein [44].

Contraction of the masseter muscle elevates the mandible and moves it to the contralateral side (deep layer) [44].

Figure 5 – relationship between the masseter and temporalis, and their bony attachments [42].



1.2.4.2 Temporalis

The temporalis muscle originates from the temporal fossa of the parietal bone, and the infratemporal crest of the greater wing of sphenoid. It is covered by a tenuous temporalis fascia. As muscle fibres extend anteriorly and inferiorly they converge under the zygomatic arch to form a thick tendon. This attaches to the medial, superior and anterior surfaces of the coronoid process of the mandible. Some muscle fibres extend from the anterior surface of the coronoid process along the anterior surface of the ramus and attach to the retromolar trigone [44].

The temporalis is innervated by the anterior division of the mandibular nerve, via anterior and posterior deep temporalis nerves [44]. Venous drainage is via the deep temporal veins to the

pterygoid venous plexus [44]. Arterial supply is via the deep temporal arteries, which are branches of the maxillary artery as it courses through the infratemporal fossa.

Contraction of the temporalis elevates the mandible (middle fibres) and moves it either posteriorly (posterior fibres) or anteriorly (anterior fibres) [44].

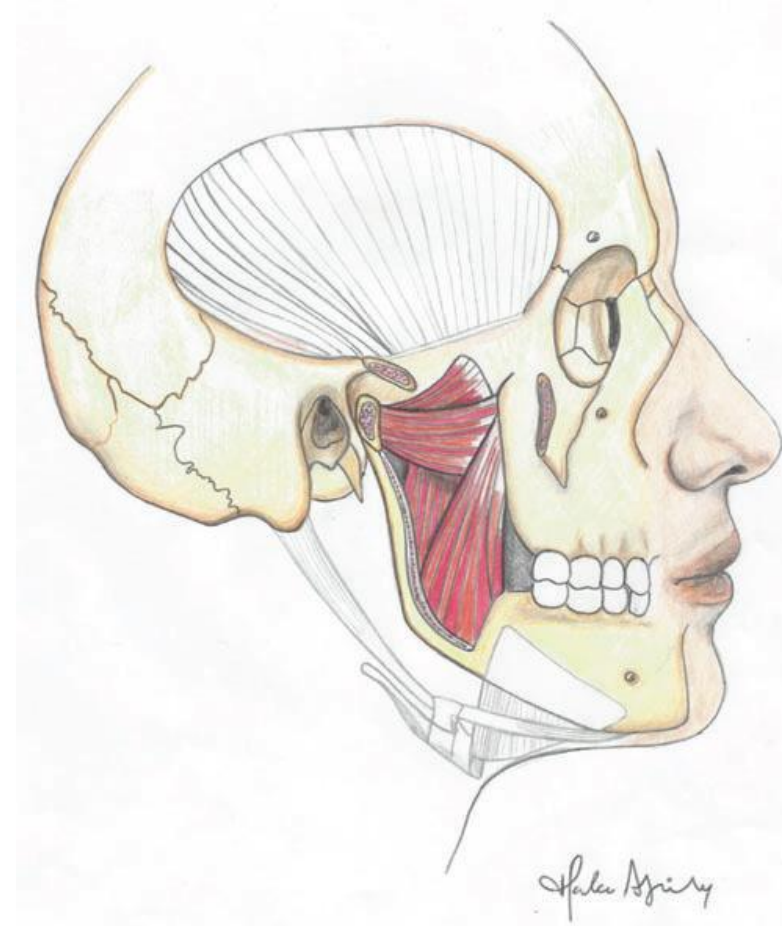
1.2.4.3 Medial Pterygoid

The medial pterygoid muscle originates from the medial surface of the lateral pterygoid plate, the pyramidal process of the palatine bone, and the maxillary tuberosity. It inserts into the inferior half of the medial surface of the ramus. Muscle attachment extends to just below the mandibular foramen and lingula superiorly, and to the mylohyoid line anteriorly. Together with the masseter muscles, the medial pterygoids form the pterygomasseteric sling.

The pterygomasseteric sling encases the lower two thirds of the ramus, up to the antegonial notch. This fibro-muscular sling is responsible for elevation (mouth closure) and lateral excursions of the mandible (figure 6). Its release facilitates access to the sigmoid notch and condylar neck. Releasing the pterygomasseteric sling is also important in any procedure which requires lengthening of the ramus.

The action of the medial pterygoid is to elevate the mandible, protrude it (together with the lateral pterygoid muscles) and to move it medially [44].

Figure 6 – Medial and lateral pterygoid muscles depicted with the mandibular ramus removed [42].



1.2.4.4 Lateral Pterygoid

The lateral pterygoid is the muscle of mastication most intimately related to the TMJ. It is composed of an upper and lower head. The upper head originates from the infratemporal surface of the sphenoid bone. Some fibres also extend to the infratemporal crest of the sphenoid. The upper head attaches to the anterior surface of the condylar neck, with some fibres attaching to the anterior surface of the TMJ capsule and the articular disc.

The lower head of the lateral pterygoid muscle originates from the lateral surface of the lateral pterygoid plate and attaches to the anterior surface of the condylar neck (figure 7).

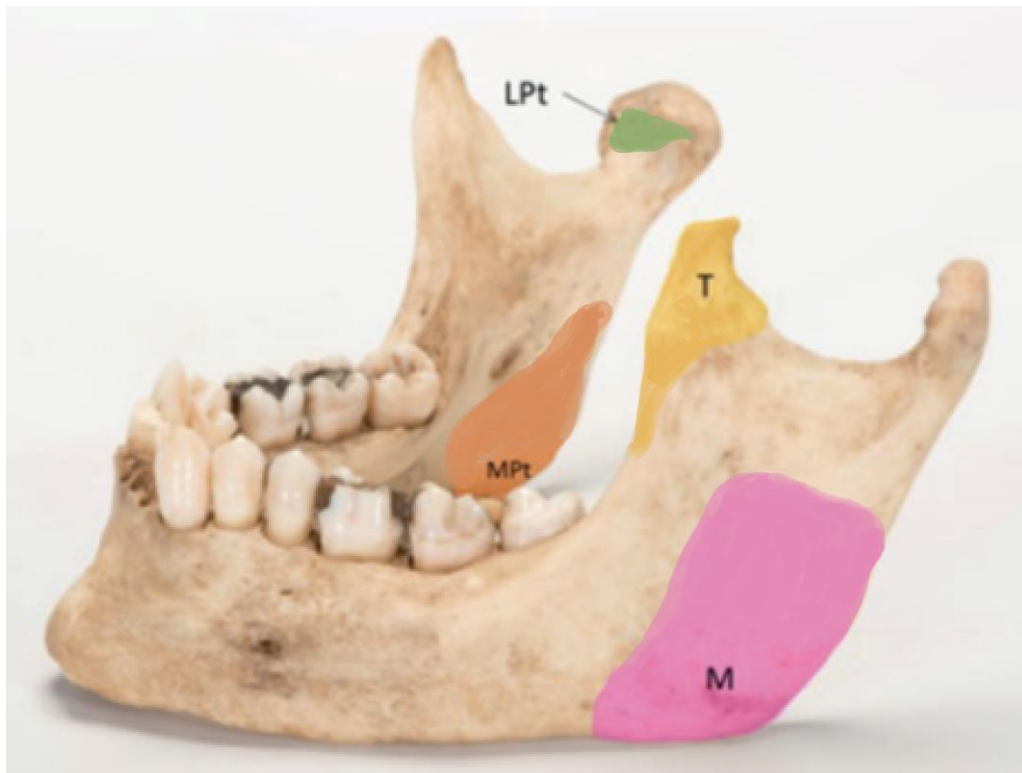
Figure 7 – Dried mandibular specimen showing attachments of some of the muscles of mastication [42].

(M) – Masseter

(T) – Temporalis

(MPt) – Medial pterygoid

(LPt) – Lateral pterygoid



Contraction of the lateral pterygoid muscles moves the condyle and articular disc in an anterior direction, thereby protruding and depressing the mandible as the condyle rotates and translates anteriorly within the joint. Spasmodic dysfunction or parafunction of the lateral pterygoid muscle can result in the condyle translating anterior to the articular eminence, thereby causing dislocation of the TMJ.

1.2.4.5 Anterior Belly of the Digastric

The anterior belly of digastric originates from the digastric fossa and inferior surface of the anterior mandible. It travels in a posteromedial direction to form an intermediate tendon at the hyoid bone where fibres then continue posterolaterally to form the posterior belly of digastric. With the mandible held in one position, the anterior belly of digastric contracts to elevate the hyoid bone. Conversely, when the hyoid bone is held in one position by the suprahyoid and infrahyoid muscle, the anterior belly of the digastric contracts to depress the mandible. The innervation of this muscle is via the trigeminal nerve, in contrast to the posterior belly of digastric, which is supplied by the facial nerve. This relates to their differing embryology, as the anterior belly of digastric forms from the first brachial arch, whereas the posterior belly of digastric forms from the second brachial arch.

1.2.5 Comparative Anatomy

The temporomandibular joint is unique to mammals, and its presence is used as a mammalian identifier [9]. It shows significant variation between species, reflecting differences in diet and habits [9]. For example, the orientation of the condylar long axis is coronal in most carnivores such as cats, whereas it is sagittal in rats [9]. Sagittal orientation of the joint cavity allows more translation in the medio-lateral direction, which is favourable in some feeding behaviours. On the other hand, coronal orientation of the condyle allows antero-posterior movement, which may be required when feline animals are hunting and killing their prey.

In herbivorous animals, TMJ anatomy is different. Herbivores tend to have condyles that are extremely flat with a reversed concave/convex relationship when compared to the human TMJ [9]. This allows translation in all directions, which is necessary when ruminating and processing fibrous leafy fodder. An extreme of this example is in artiodactyl ungulates (even-toed hoofed animals) such as cows and sheep, where the relationship between the glenoid fossa and condyle is reversed. In these mammals, the condyle is the concave component of the joint, and the temporal bone (possibly the articular eminence) forms the convex or male component of the joint.

In general, mammals that require high forces when biting (e.g. carnivores, including humans) tend to have a prominent articular eminence which can be loaded. This forms a clear ball and socket relationship to the joint, which subsequently is at risk of dislocation. Mammals that require minimal forces on the TMJ, such as rats feature a much shallower joint in comparison [9].

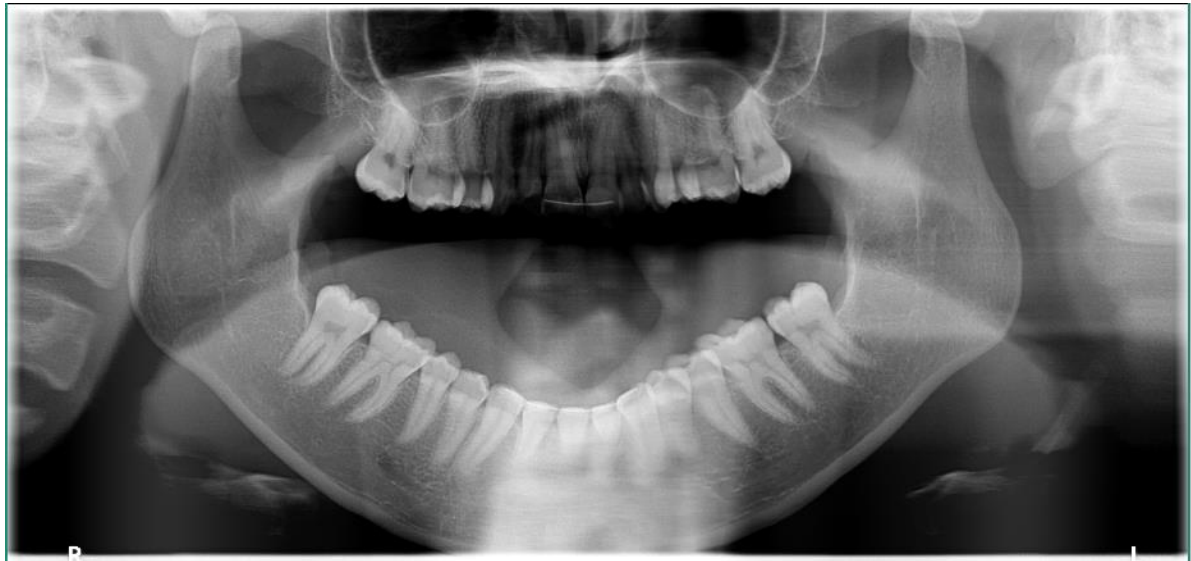Anthropological assessment of historical human skulls by Reisert [2] showed that ancient human skulls had a flat articular eminence. His anthropological studies on modern skulls showed that humans now have a much steeper articular eminence, and that those who suffer from recurrent TMJ dislocation may have a more prominent articular eminence [2].

1.2.6 Surgical Relevance of Dislocation

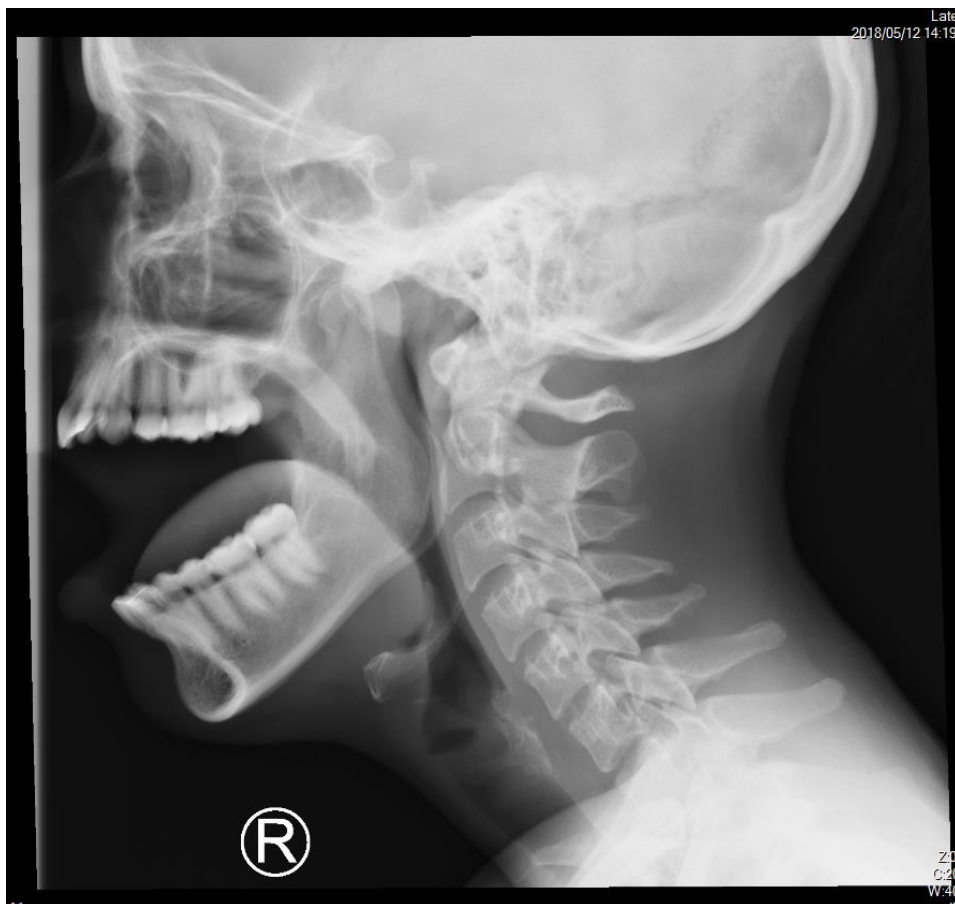Dislocation of the TMJ can occur in any direction, but is most commonly in an antero-medial direction [48]. Dislocation of the TMJ occurs when the condyle translates anterior to the articular eminence (figure 8). This occurs with unopposed forces from the lateral pterygoid muscle, without stabilising forces from the temporalis and masseter [48]. Other muscles that impart a forward vector on the TMJ include the anterior belly of digastric, medial pterygoid muscle and to a small degree the masseter muscle.

Once dislocated, relocation of the condyle requires the condyle to move inferiorly until it bypasses the articular eminence, and then posteriorly back into the glenoid fossa. This initial inferior movement is often prevented by spasm of the masseters and temporalis muscles, which is worsened with pain [10]. Downward movement of the condyle is also prevented by the TMJ capsule and its ligaments [10].

Figure 8 – Orthopantomogram (OPG) (1a) and lateral cephalogram (1b) of a patient suffering from bilateral temporomandibular joint dislocation



A



B

Dislocation of the condyle out of the glenoid fossa can be detected by posterior open bite on the ipsilateral side, and a palpable depression where the lateral pole of the condyle is usually felt [48]. Diagnosis can be confirmed with radiological imaging, most routinely via orthopantomogram. Here, the condyle is visible anterior to the glenoid fossa when the patient is attempting to close their mouth [48]. Akinbami [49] classified dislocation of the TMJ based on radiological assessment, with type I dislocation occurring when the condyle is located at the inferior tip of the articular eminence, type II dislocation when the condyle rests against the anterior slope of the articular eminence, and type III dislocation when the condyle is well in front of the articular eminence, against the root of the zygomatic arch [49].

1.2.7 Surgical Relevance of TMJ Anatomy

The TMJ can be approached via either a pre-auricular, post-auricular, retromandibular, coronal, submandibular and rhytidectomy approaches. The pre-auricular approach is the most commonly used approach to access the intra-articular spaces of the TMJ [10]. The main structure at risk during exposure of the TMJ is the facial nerve [43]. Other important structures around the TMJ include the maxillary artery, superficial temporal vessels, parotid gland, and auriculotemporal nerve [50]. The location of the pre-auricular incision aims to avoid the facial nerve, and to remain inconspicuous within the pre-auricular skin crease. On dissection to the joint, the layers encountered are skin, subcutaneous fat, the parotideomasseteric fascia, the parotid gland (often bypassed posteriorly), and joint capsule. The pre-auricular muscles are also often encountered during the approach, and lie deep to the temporalis fascia.

Arising from the superior aspect of the parotid gland are the superficial temporal artery and vein, and the auriculotemporal nerve. Within the parotid gland, the facial trunk divides into the temporofacial and cervicofacial trunks at a distance of 15 to 28mm inferior to the lowest aspect of the bony external meatus [50]. These branches then divide further to form the five terminal branches of the facial nerve; temporal, zygomatic, buccal, marginal mandibular and cervical. These

terminal branches travel just deep to the temporo-parietal fascia, with the temporal branches most at risk during pre-auricular access to the TMJ. The temporal branches of the facial nerve cross the zygomatic arch approximately 20mm (range 8 to 35mm) anterior to the external auditory meatus. To avoid damage to the temporal branches of the facial nerve, the temporoparietal fascia must be incised less than 8mm anterior to the external auditory meatus [50].

Understanding the anatomy of the TMJ, and the articular eminence in particular, is crucial when performing eminectomy. Overzealous osteotomy can result in the surgeon inadvertently entering the middle cranial fossa or the infratemporal fossa [2].

Hall and colleagues assessed the anatomy of the articular eminence in 38 cadaveric half-heads and found the dimensions of the articular eminence in their population are 11mm in an anteroposterior direction (range 9-18mm), 21mm in a medio-lateral direction (range 16-25mm) and 9mm in height (range 5-14mm) [2].

Pre-operative computerised tomography is crucial in preparation for eminectomy as it confirms dimensions of the articular eminence, and excludes pneumatisation or cranialisation of the eminence [2].

1.3 Temporomandibular Joint Dislocation

Temporomandibular joint dislocation refers to displacement of the condyle out of the glenoid fossa [44]. This may be due to hypermobility of the joint (either acute or chronic), displacement out of the fossa due to a joint effusion or haemarthrosis, or it may be due to a fracture dislocation. Only hypermobility related TMJ dislocation will be further discussed in this section, as displacement secondary to trauma or fluid accumulation is out of the scope of this thesis.

Temporomandibular joint dislocation may be acute, chronic, or recurrent. Some texts also classify dislocation as acute, chronic protracted or chronic recurrent [10]. The direction of dislocation of the condyle is most commonly in an anteromedial direction, following the pull of the lateral pterygoid muscle [43]. However, in cases of acute trauma, dislocation can occur in any direction, included upwards into the middle cranial fossa [43]. Further discussion will relate to anteromedial dislocation of the condyle.

Although this thesis pertains to the topic of recurrent dislocation of the TMJ, a brief description of acute and chronic TMJ dislocation is made here for comparison.

1.3.1 Acute Dislocation

Acute Dislocation occurs most commonly as a result of trauma to the joint capsule and associated ligaments [49]. This may be due to fall, motor vehicle accident, interpersonal violence or sports. It may also occur as a result of forceful or prolonged mouth opening, such as that from ENT or dental procedures, or during anaesthetic intubation or manipulation of the airway [49].

1.3.1.1 The Hippocratic manoeuvre

In most instances, reduction of the acutely dislocated TMJ can be achieved by downward and backward pressure on the posterior body of the mandible. This is called the Hippocratic manoeuvre, and can be achieved with a calm relaxed patient, although in many instances muscle

spasm requires some degree of anaesthesia (local or general) or sedation to overcome [49]. In 1633, Ambroise Pare suggested an alternative method to reduction of TMJ dislocation, where the patient was asked to bite on a hard object with their molars, as the chin was elevated. This action dis-impacted the condyles from the articular eminence, and allowed reduction back into the glenoid fossa [5].

Alternate methods to reduce acutely dislocated temporomandibular joints include the gag reflex procedure, the wrist-pivot technique, and the extra-oral technique [49].

1.3.1.2 The gag reflex procedure

The gag reflex procedure was described by Awang in 1987 [51], with rubbing the soft palate or posterior pharyngeal wall to stimulate the gag reflex which in turn was thought to relax the lateral pterygoid muscles and allow the condyle to reduce into the glenoid fossa [51].

1.3.1.3 The wrist pivot technique

The wrist pivot technique was described by Lowery et al in 2004 [52] as an alternative technique that was less likely to involve sedation. Here, Lowery described a case where a 53-year-old man underwent two failed attempts at conventional reduction under intravenous sedation. An alternate approach was tried once sedation had worn off, where the physician stood in front of the patient, and held the patient's mandible with the index and middle finger on the occlusal plane and the thumbs under the chin. Pressure was then applied via a pivoting action of the physician's wrists, alternatively one side then the other, which moved the anterior mandible superiorly and the posterior mandible inferiorly, thereby rocking the condyles inferiorly, dis-impacting them, and allowing reduction into the glenoid fossa [52].

1.3.1.4 The extra-oral technique

In 2007, Chen and his group based in Taiwan described a group of seven patients treated via an extra oral manoeuvre for reduction of acute TMJ dislocation. Chen noted that with

dislocation of the condyle in an anteromedial direction, the coronoid process and anterior ramus become palpable through the cheek. This group described that with steady pressure backward on the anterior ramus through the cheek [53], the condyle could be successfully reduced. In all seven cases, no sedation was required [53]. A proposed benefit of this technique was that by avoiding intra-oral manoeuvres, the treating practitioner avoided being accidentally bitten.

Of all of the above techniques, the Hippocratic manoeuvre was associated with the best success rate [49].

1.3.2 Chronic/Protracted Dislocation

Chronic dislocation is defined as situations where the condyle remains outside of the glenoid fossa for an extended period of time. The minimum time required to classify a dislocation as chronic has not been explicitly defined in the literature.

Manual reduction of chronic dislocation of the TMJ has a much lower success rate than acute dislocation. Traditional methods of reduction for patients with chronic TMJ dislocation as described in section 1.3.1 have shown to have a success rate of 12.5 to 16.7% [5].

The use of intra-articular local anaesthetic injection with prilocaine has also been successfully described to alleviate chronic TMJ dislocation [54]. In this case report, the local anaesthetic was thought to break sensory feedback loops, allowing relaxation of the lateral pterygoid muscles.

Closed reduction in patients with chronic dislocation may have to followed with a period of immobilisation with intermaxillary fixation (IMF) to prevent relapse [5]. The duration of IMF may vary from seven to 21 days, and should be limited by the risk of pseudoankylosis formation or trismus [5].

Where traditional manual manoeuvres fail, an alternate closed approach with the use of arch bars has been described [55]. Posterior occlusal bite splints are inserted, and arch bars are

applied with strong anterior wiring and class III vectors on the posterior wires. This allows prolonged downward traction on the condyles, with the aim of slowly disengaging them from anterior of the articular eminence, thereby allowing reduction into the glenoid fossa [55].

Chronic dislocation can result in formation of a fibrous pseudo-articulation between the displaced condyle and the temporal bone anterior to the articular eminence [5]. In these patients, closed reduction is likely to fail, and an open approach and release of the pseudo-articulation may be warranted [5].

Protracted joint dislocation may also result in shortening of the temporalis muscle tendons, and formation of scar tissue, limiting the success of closed reduction. Although closed reduction via manoeuvres described above should be attempted initially, patients who fail conservative therapy should be considered for surgical management [5].

Various novel methods for surgical reduction for chronic dislocation have been described. These include use of a Bristow elevator via a trans-temporal approach to apply posterior and inferior force on the anterior condyle [56]. A bone hook on the sigmoid notch or into burred holes into the angle of the mandible has also been described to pull the condyle-ramus unit inferiorly [57].

In failing the above surgical measures, condylectomy and gap arthroplasty, as well as eminectomy have been described for treatment of chronic dislocation that has failed a more conservative approach to management [5,56].

1.4 History of Temporomandibular Joint Surgery

Temporomandibular joint surgery was first described by Thomas Anandale in 1887 [58]. This published paper in The Lancet described access to the joint via a three quarter inch curved incision directly over the joint. This access was modified by Stimson in 1895, where he suggested a T-shaped incision, with a horizontal arm along the inferior aspect of the zygomatic arch and a perpendicular incision extending inferiorly [59]. This T-shaped incision was modified to an L-shaped incision in 1914 by Murphy, who moved the vertical arm of the incision to the pre-auricular skin [60].

Over the next century, this incision for open TMJ surgery was modified by several authors including Alkayat and Bramley to a hockey stick shaped incision, composed of the pre-auricular incision with a curvilinear extension at the superior aspect [61]. Alternate approaches to the TMJ include a posterior auricular approach, a rhytidectomy approach, and submandibular approach [62].

Surgical methods to treat dislocation of the temporomandibular joint can be broadly classified into procedures that remove obstruction to the condylar path, and procedures that limit anterior translation of the condyle [5].

1.4.1 Procedures that remove obstruction to the condylar path

The first surgeon to describe surgical management of TMJ dislocation was Riedel in 1887. He prescribed unilateral condylectomy for patients with chronic or recurrent TMJ dislocation [5]. This was a morbid procedure resulting in facial asymmetry of unilateral cases, or anterior open bite in bilateral cases [2]. A closed method of condylectomy was subsequently described by Kostecka, via use of a specialised Gigli saw, but this method too was associated with significant morbidity to the occlusion and facial symmetry, and quickly fell out of favour [2].

Surgical methods for treating recurrent TMJ dislocation began to appear more commonly in the literature in the 1950's. Eminectomy was first described by Myrhaug in 1951 [63] as a

method of treating recurrent TMJ dislocation. The eminectomy was then adapted by Irby [64] in 1957 for treatment of other internal derangement of the TMJ causing pain.

Discectomy was first described by Riedel in 1883 [62], but other authors were **not** able to replicate his success [5]. Wolford first described the use of artificial anchors or ligaments to plicate the disc, aiming to reduce recurrent TMJ dislocation [65].

Laskin first described temporalis tendon myotomy at the 4th international conference on Oral Surgery in Copenhagen in 1973 [66]. This method was thought to be able to relieve any temporalis tendon shortening that occurred with recurrent dislocations. Others tried lateral pterygoid myotomy to limit anteromedial pull on the condyle. However, when lateral pterygoid myotomy was performed in isolation, the recurrence of TMJ dislocation was found to occur due to reattachment of the lateral pterygoid fibres [67]. Interpositional silastic sheets as barriers to reattachment were tried, but failed to show any benefit [67].

1.4.2 Procedure that limit anterior translation of the condyle

Eminoplasty was first described by Mayer in 1933, where a zygomatic osteotomy was performed to obstruct anterior hypermobility of the condyle [5]. This procedure was developed by LeClerc as a glenotemporal osteotomy [68], and was later modified by Gosserez and Dautrey via interposition of a bone graft into a subperiosteal pocket. This procedure involves down fracture of the zygomatic arch and has been associated with a relocation of the articular eminence inferiorly by approximately 3.5mm and anteriorly by approximately 4.5mm [69]. Adaptations of this procedure have been described since then, including the incorporation of miniplates and temporal fascial flaps [21]. More recently, blocking techniques have been described using calvarial [37], chin [38] or iliac bone grafts [39] fixated with or without miniplates to produce an articular eminence over which the condyle cannot glide, thereby preventing dislocation. This procedure has been associated with post-operative pain, infection and fracture of miniplate [39].

Conservative methods for limiting the anterior translation of the condyle include the use of sclerosing agents. Injection of sclerosants into the TMJ or periarticular tissues was first described in 1947 by Schultze, who used sodium psylliate to induce fibrosis [70]. Since then, multiple other agents have been described including modified dextrose [16] and autologous blood [29].

To date, no surgical modality has been shown to superior to others in treating recurrent TMJ dislocation.

1.5 Justification for Systematic Review and Retrospective Analysis

Recurrent temporomandibular (TMJ) dislocation can be debilitating for patients, and challenging with regards to diagnosis and management for practitioners.

Dislocation of the temporomandibular joint causes significant pain and anxiety for patients, and results in trauma to the joint capsule and ligaments. This dislocation may occur in one of four forms. The first form, subluxation, occurs when there are transient partial dislocations of the TMJ that are usually self-resolving. Second, acute dislocation usually occurs as a result of trauma or excessive mouth opening (e.g. during yawning or after prolonged dental procedures [71]). Acute TMJ dislocation is managed via manual reduction, which may require sedation. This may be augmented with supportive bandages and soft diet. The third form, chronic dislocation occurs when there is prolonged disarticulation of the TMJ, usually as a result of underlying laxity of the joint capsule. This may be secondary to age related degeneration, an inherent connective tissue disorder (such as Ehlers Danlos Syndrome [71]), or as an adverse effect of antipsychotic medication such as clonazepam [72]. Chronic dislocation may be managed conservatively via positional devices, or surgically. The last form of TMJ dislocation is recurrent dislocation. This occurs when there are recurrent acute episodes of TMJ disarticulation due to either joint capsule/ligament laxity, anatomical variation in the joint, or dystonia of the lateral pterygoid muscle causing spasmodic antero-medial pull on the condyle. Although the four forms of TMJ dislocation are discrete in their mechanisms, they can be difficult to differentiate clinically, and patients may have features or risk factors of more than one type of dislocation. Ideally, the type and risk factors for dislocation should be identified so that treatment can address the mechanism of dislocation.

Recurrent TMJ dislocation and its treatment are not well understood [48]. Treatment modalities described for the management of recurrent TMJ dislocation in the literature can be classified as conservative or surgical. In general, conservative methods are trialled before surgical management. Currently, there is no ideal treatment guide with which to approach recurrent TMJ

dislocation [11]. The current study assessed our present understanding of recurrent TMJ dislocation, specifically in regards to its surgical management and long term follow up.

Chapter 2: Systematic Review

2.1 Protocol for Systematic Review

Using PRISMA guidelines [73], a search was carried out with the Medical Subject Heading (MeSH) terms "recurrent" "temporomandibular joint" and "dislocation", over the last 10 years (2006-2016) using the databases PubMed (MEDLINE), Cochrane Library and Science Direct.

“Recurrent” was included as a search term to limit publications to those pertaining to recurrent dislocation, and not acute or chronic dislocation, which are more common. Acute dislocation often occurs due to trauma or an acute event, and is usually successfully managed via manual reduction. They are usually isolated events that do not pose a management dilemma [33]. Chronic dislocation, on the other hand, tends to occur when the condyle is placed outside of the glenoid fossa for a protracted amount of time. It is also unlike recurrent TMJ dislocation, where the condyle is reduced back into the glenoid fossa between dislocation events [33].

“Dislocation” was used as a MeSH term to limit studies to those relating to true dislocations, rather than subluxations, or fracture related dislocation.

The search was limited to the last ten years (2006 and 2016). This was to determine what the current understanding is regarding management of recurrent TMJ dislocation.

2.1.1 Objectives and Hypothesis

Recurrent dislocation of the temporomandibular joint occurs when there are recurrent acute episodes of TMJ disarticulation due to either joint capsule/ligament laxity, anatomical variation in the joint, or dystonia of the lateral pterygoid muscle causing spasmodic antero-medial pull on the condyle. It differs to the other forms of TMJ dislocation, which are subluxation, acute dislocation, and chronic dislocation. The four forms of TMJ dislocation are discrete in their mechanisms, and it is important to differentiate them clinically, as their approach to treatment differs. Patients may have features or risk factors of more than one type of dislocation. Ideally, the

type and risk factors for dislocation should be identified so that treatment can address the mechanism of dislocation.

Recurrent TMJ dislocation and its treatment are not well understood³. Treatment modalities described for the management of recurrent TMJ dislocation in the literature can be classified as minimally invasive or surgical. In general, conservative methods are trialled before surgical management. Currently, there is no ideal treatment guide with which to approach recurrent TMJ dislocation [5]. The aim of this study was to undertake a systematic review of current concepts regarding clinical management of recurrent TMJ dislocation. This is especially important as recently, newer treatment modalities for recurrent TMJ dislocation are emerging.

The aim of this study was to undertake a systematic review of current concepts regarding clinical management of recurrent TMJ dislocation.

Clinical and review papers published between 2006 and 2016 are critically reviewed to determine the current understanding about recurrent TMJ dislocation, which is a rare and poorly understood clinical entity. Currently, many different treatment options have been described in the literature, with no clear superior modality.

Clinical papers are classified as conservative therapies or surgical management. Conservative treatment modalities for recurrent TMJ dislocation include autologous blood injection and botulinum toxin. Surgical management modalities are further divided into treatment that allows free movement of the condyle, and into treatment that limits anterior translation of the condyle. Surgery that allows free movement of the condyle includes eminectomy, whereas modalities that limit anterior translation include eminoplasty and disc plication.

Most clinical papers relating to recurrent TMJ dislocation are limited to case reports and small case series, which are of low level of evidence. Investigation of all of the recent clinical papers together will help to ascertain efficacy of different treatment modalities for management of recurrent TMJ dislocation.

This can then aid tailoring further studies that are larger scale prospective trials, looking at which modalities are superior in treating recurrent TMJ dislocation. This allows the surgeon to remain evidence based when managing recurrent TMJ dislocation.

2.1.2 Inclusion Criteria

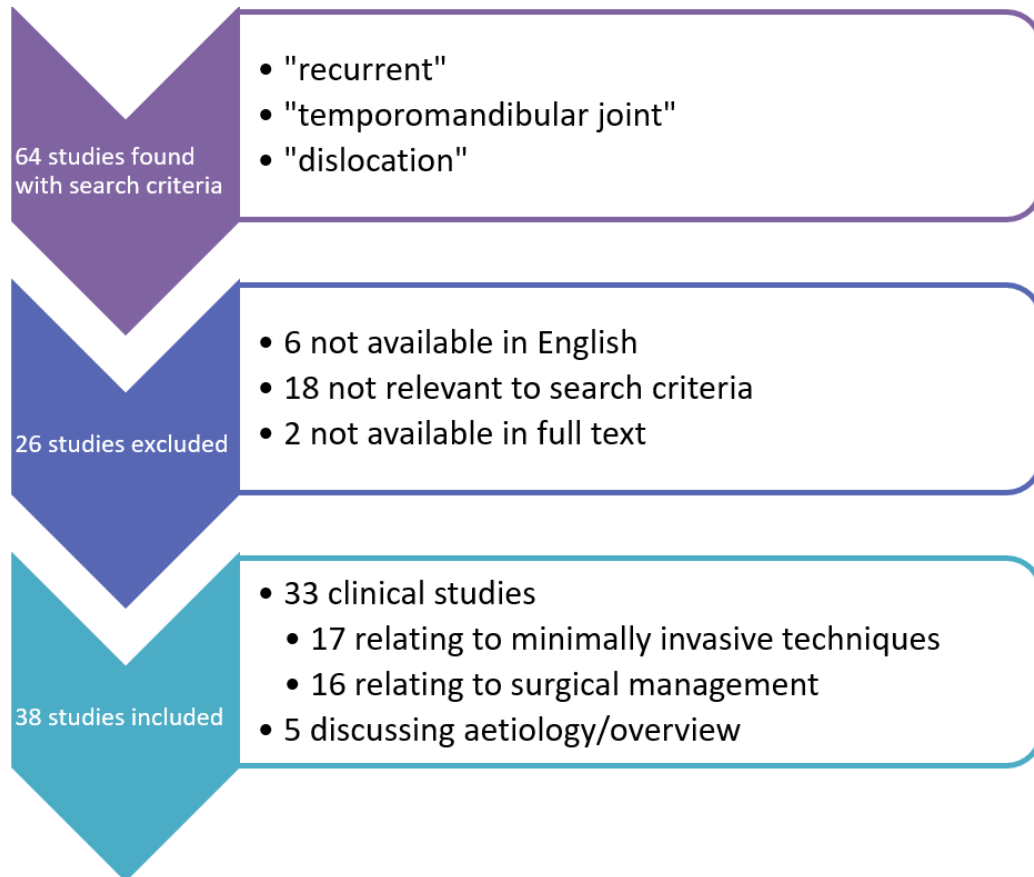
Inclusion criteria were studies involving patients with recurrent TMJ dislocation, undergoing either conservative or surgical management, where conservative management included minimally invasive treatment, such as intra-articular injection. Surgical management was any open joint procedure, including eminectomy, disc plication and eminoplasty. Eminectomy was defined as any procedure where the lateral two thirds or more of the articular eminence was removed [2]. An eminoplasty was defined as any procedure where the eminence was altered in shape or position, and included glenotemporal osteotomy, downfractures and interpositional grafts.

A total of 64 papers were found using the above terms. These papers were screened for exclusion criteria, as listed in section 2.1.3.

2.1.3 Exclusion Criteria and Review Methods

Papers not relating directly to recurrent TMJ dislocation or those papers not available in English were excluded (Figure 8). This resulted in a total of 38 papers for analyses, 33 clinical papers relating to either minimally invasive techniques or surgery and five regarding the aetiology or overview of TMJ dislocation. The papers were reviewed in relation to patient demographics, aetiology of TMJ dislocation, management, and outcomes (recurrence of dislocation).

Figure 9 – papers included and excluded in study



2.2 Results of Systematic Review

2.2.1 Description of Studies

A total of 33 clinical papers were found to be suitable for the basis for this review of recurrent TMJ dislocation in the last 10 years. Of these, only one paper was of level I evidence (systematic review or meta-analysis), 4 were level II evidence (randomised clinical trials), 6 level III evidence (retrospective cohort studies), 14 level IV evidence (case series), and 8 level V evidence (case report or expert opinion). The longest period of follow up was up to 12 years. However, when assessing surgical management of recurrent TMJ dislocation specifically, the evidence was not as strong, with no level I evidence, and only 1 prospective cohort studies. The majority of literature on surgical management of recurrent TMJ dislocation was limited to case series or case reports.

2.2.2 Papers relating to overviews or opinions

2.2.2.1 Incidence

The true incidence of recurrent TMJ dislocation in the general population has not been described, although it is thought to be more often associated with females, pre-existing joint disease, and perhaps neuromuscular disorders.

In patients with known TMJ pathology, there is an incidence of 1.8% of recurrent TMJ dislocation [74].

2.2.2.2 Aetiology

The true aetiology of recurrent TMJ dislocation is poorly understood. The aetiology of recurrent TMJ dislocation can be based on either anatomical factors or functional factors. Murakami [75] described synovial plicae in 62.5% (18 of 28) TMJs undergoing surgery for recurrent dislocation. The role of the plicae in recurrent TMJ dislocation is not understood, but could potentially be a contributor. The effect that surgical modalities such as autologous blood injection or eminectomy would have on synovial plicae remain unexplored.

Liddell considered functional factors that may contribute to recurrent TMJ dislocation. The authors suggested that connective tissue disease such as Ehlers Danlos Syndrome [33] can be

attributed to recurrent TMJ dislocation as a result of increased joint laxity. Furthermore, insufficient joint support from the masticatory apparatus can also result in recurrent dislocation. This lack of support may be due to muscular dystonias [33]. Neurodegenerative disease such as Parkinson's and Huntington's can cause muscular dystonia, thereby resulting in recurrent TMJ dislocation [33]. These factors predisposing to recurrent dislocation are speculation only, as the incidence of recurrent TMJ dislocation in patients with each condition is not known to be higher than the overall population.

2.2.2.3 Investigations

No papers were found assessing the sensitivity or specificity of investigations for recurrent TMJ dislocation specifically. In general, OPG x-ray is used as a general screening tool. Sahoo [69] used OPG to assess post-operative changes in the articular eminence form after Dautrey's procedure. This study found that the average height of the pre-operative articular eminence was 7.49mm on the right and 7.32mm on the left.

CT and MRI are used in investigation of TMJ disease in general, but their use in investigating the cause of recurrent TMJ dislocation is unknown.

2.2.2.4 Treatment options

The management of recurrent TMJ dislocation should be personalised to the patient [48], with some reference to the hypothesised aetiology for that particular patient. Treatment should have a sequential approach, with minimally invasive modalities trialled before surgery is undertaken.

In general, management of recurrent TMJ dislocation is based on one of three aims. The first of these is to induce fibrosis within the peri-articular tissues. This may be via autologous blood injection, capsulorrhaphy, or OK-432 sclerosing agent.

The second aim of treatment is to remove the obstruction to joint relocation. This is largely achieved via eminectomy. The third goal of treatment of recurrent TMJ dislocation is to limit

anterior joint translation. This can be achieved by methods such as mini-anchor, eminoplasty or inactivating the lateral pterygoid muscle.

Treatment modalities aimed at limiting jaw joint movement need to be combined with a period of post-operative limitation of mouth opening. This should be followed by some physiotherapy to prevent joint ankylosis [2]. Undt [2] suggested in his review paper of eminectomy that surgical options for recurrent TMJ dislocation should only be considered once minimally invasive techniques have been trialled and failed.

Contraindications to eminectomy or eminoplasty include high surgical risk due to patient co-morbidities or pneumatisation of the articular eminence as seen on CT or MRI imaging [48].

2.2.2.5 Efficacy of treatment

De Almeida [11] conducted a systematic review on the management of recurrent temporomandibular joint dislocation, and showed that there is no good quality evidence on efficacy of different treatment modalities. The study also suggested that some surgeons opted for eminectomy in cases where other treatment modalities had failed, suggesting that although evidence is not robust, eminectomy may be perceived as the gold standard for recurrent TMJ dislocation [11].

2.2.3 Minimally Invasive Methods

Of the 33 papers describing treatment modalities for recurrent TMJ dislocation, 17 referred to minimally invasive techniques (Table 1), and 16 referred to surgical management (Table 2)

Conservative methods include intermaxillary fixation, injection of botulinum toxin A into the lateral pterygoid muscle, as well injections into the joint space. Materials injected into the joint space included autologous blood, modified dextrose [44], and OK-432 [17].

2.2.3.1 Botulinum Toxin A Injection

Botulinum toxin A injection into bilateral lateral pterygoid muscles has been shown in 2 case reports [12,13] to alleviate recurrent TMJ dislocation without recurrence at up to 6 months. Oztel and colleagues [12] described a case of a 99-year-old woman who presented to a regional

centre with bilateral recurrent TMJ dislocation. She was initially treated with manual reduction and IMF, which she did not tolerate. She was then treated with 25 units of botulinum toxin diluted in 2ml 0.9% normal saline. The lateral pterygoids were injected trans-cutaneously via the sigmoid notch. There was no recurrence at 6 months. Vazquez et al [13] described 4 cases of recurrent TMJ dislocation, all of which were thought to be neurogenic in origin with the predisposing conditions being traumatic brain injury, Alzheimer's disease, Parkinson's disease and myotonic dystrophy. The mean follow-up period was 7 months, with one patient suffering recurrence, and another patient requiring 2 doses of botulinum toxin. Thus, undertaking the present systemic review revealed 5 cases where botulinum toxin was used in the lateral pterygoid muscle to alleviate recurrent TMJ dislocation, with a success of 80% (4 of 5) at 6 months.

2.2.3.2 Autologous blood into joint space

Injection of autologous blood into the superior joint space and into the joint capsule has been discussed in multiple case series, and has been associated with up to 80% success rate in alleviating recurrent TMJ dislocation at 12 months [29,30,31,32].

Bayoumi and colleagues described a case series of 15 patients, all who underwent bilateral injections of autologous blood, 2ml into the superior joint space and 1ml into the pericapsular tissues [29]. The patients were followed up for 12 months, and 80% (12 of 15) had no recurrence. Those who suffered recurrence of their dislocation did so early, at a mean of 3 weeks post procedure. Similarly, Coser et al assessed the efficacy of ABI [30] in a cohort of eleven patients who received bilateral ABI for recurrent TMJ dislocation. Over a mean follow-up period of 30 months, 73% (8 of 11) had no recurrence.

A further study reported 25 patients with bilateral TMJ dislocation who underwent ABI and were followed up for a mean of 12 months [32]. Within four weeks, the success rate was 60% (15 of 25) [32]. The remaining 10 patients underwent a second treatment at this stage and at 12 months, 80% of patients (20 of 25) had no recurrence of their dislocation after either one or two treatments. Single case reports of this technique have also been published, with one of an 82-year

old man who underwent bilateral ABI for recurrent TMJ dislocation, with no recurrence at 8 months [31], another of an 84-year old patient was treated successfully for recurrent TMJ dislocation with ABI, showing no clinical recurrence at 5 months [76], and a third describing a case where ABI was combined with a supportive head bandage for four weeks with no recurrence at 12 months [77].

The above papers described a total of 54 patients treated with ABI, with a success rate of 80% (43 of 54) at a mean follow up of 16 months.

The technique of ABI described by most studies involves injection of 2-3ml of autologous blood into the superior joint space (SJS), with or without injection of a further 1ml into the pericapsular tissues (PT). Daif [14] showed that injection into both the SJS and PT was associated with a success of 80% (12 of 15) at 12 months compared to a success of 60% (9 of 15) if only the SJS was injected.

This success rate may be further increased with the concurrent use of intermaxillary fixation for 4 weeks [15]. Hegab described a study in which 48 patients with recurrent TMJ dislocation were divided equally into three groups. The first group received ABI into the SJS and PT. The second group received ABI in the same way, but were also treated with IMF for four weeks. The third group received IMF alone for four weeks. Of the 16 patients that received ABI alone, half (n=8) had recurrence of TMJ dislocation. Three of the 16 patients treated with IMF alone had recurrence of dislocation. The combined ABI and IMF treatment group was associated with the best success, none of 16 patients suffering recurrent dislocation. However, all three treatment modalities were associated with decreased mouth opening. The mean decrease in mouth opening for ABI alone, IMF alone, and combined ABI and IMF were 8.5mm, 9.13mm, and 11mm respectively. The difference between the ABI group and the IMF group was not statistically significant, but combined treatment with both ABI and IMF was associated with a statistically significant decrease in mouth opening when compared to the other two groups. Recurrence in the ABI only group was overcome by multiple injections. No patients had recurrence after a maximum

of three injections. Recurrence in the IMF alone group was overcome with a further two weeks of IMF.

The mechanism of action of autologous blood injection for the treatment of recurrent TMJ dislocation was explored by Candirli et al [78] in a laboratory study using eight New Zealand white rabbits who underwent bilateral autologous blood injection, followed by IMF for four weeks. This was achieved via fixation of orthodontic brackets and elastics. After four weeks, the animals were sacrificed and the TMJs underwent histological analysis. This showed accumulation of fibrin within the joints, without an inflammatory infiltrate or vessel proliferation. Gulses et al [79] explored this further, when they compared histological changes in 16 pigs who underwent bilateral ABI versus those who received injection of normal saline only. Joints injected with autologous blood were associated with fibrosis in the retrodiscal and pericapsular tissues, whereas histology of saline-injected joints appeared unchanged.

Candirli et al in 2012 assessed MRI changes in human subjects one month after autologous blood injection [80]. This study of 14 subjects showed improvement in the condyle-glenoid fossa relationship four weeks after ABI. Specifically, open-mouth views showed the condyle either at or posterior to the articular eminence. This was in contrast to pre-operative MRI, where the condyle was found to be anterior to the eminence in open mouth views. There were no MRI findings suggesting of haematoma or structural joint change.

2.2.3.3 Modified Dextrose Injection into Joint Space

Zhou et al [16] described injection of 4ml of lignocaine and 50% dextrose into the posterior periarticular tissues, as a method of inducing fibrosis in treatment of recurrent TMJ dislocation in 45 patients with recurrent TMJ dislocation, aged 17 to 59 years-of-age. Post operatively patients were instructed to have a soft diet and avoid wide opening for two weeks. Patients were followed up for a mean of 18 months, with a success of 91% (40 of 45 patients). However, 27% (12 of 45) patients required a second injection, and 4% (2 of 45) patients required a total of three injections.

No animal studies have been found investigating the histological changes induced by this technique.

2.2.3.4 Intra-articular injection of OK-432

OK-432 is a group A streptococcal pyogenes derivative that has been treated with penicillin G and lyophilized [81]. It is therefore contraindicated in patients with a penicillin allergy. This agent can then be stored in 15ml tubes containing 0.16ml of EDTA (ethylenediaminetetraacetic acid) solution. OK-432 has been found to induce a local inflammatory response, resulting in fibrosis. OK-432 was used as a sclerosing agent into the temporomandibular joints of two patients unsuitable for surgical management [17]. The first of these patients was a 68-year-old man with supra-nuclear palsy who had been treated with bilateral injection of autologous blood that resulted in recurrence of dislocation at one month. He was subsequently treated with bilateral OK-432 sclerosing agent that successfully treated his dislocation at a follow up of six months [17]. The second patient was a 91-year-old woman, also with bilateral recurrent TMJ dislocation, who was treated primarily with OK-432 bilaterally, and had no recurrence at six months [17]. No animal studies were found to explore the histological changes induced by OK-432.

2.2.3.5 Electrothermal Capsulorrhaphy

Stimulation of fibrosis within the TMJ with electrothermal capsulorrhaphy treatment for recurrent TMJ dislocation can also be achieved via an arthroscopy and either Hol:YAG laser or electrocautery [18]. Only one study looks at this treatment modality, a success rate of 82% (9 of 11 patients) was found with a long follow-up period of 27 months [18].

Table 1 – Minimally invasive management of recurrent TMJ dislocation

Reference Number	Authors	Year	Journal	Type	Case Number	Modality	Follow up (months)
30	Coser	2015	IJOMS	Case series	11	Blood	35
29	Bayoumi	2014	IJOMS	Case Series	15	Blood	12
15	Hegab	2013	BJOMS	RCT	48	Blood	12
32	Machon	2009	JOMS	Case Series	25	Blood	12
76	Kato et al	2007	J Oral Sci	Case Report	1	Blood	5
31	Gupta	2013	J Oral Biol Craniofac Res	Case report	1	Blood	8
79	Gulses et al	2013	J Craniomaxillofac Surg	Clinical Trial (animal)	16	Blood	1
80	Candirli et al	2012	Imaging Sci Dent	Prospective	14	Blood	1
78	Candirli et al	2011	J Craniofac Surg	Clinical Trial (animal)	8	Blood	1
77	Pinto	2009	JOMS	Case Series	1	Blood	12
14	Daif	2010	OOOOE	RCT	30	Blood	12
12	Oztel et al	2016	BJOMS	Case report	1	Botox	6
13	Vazquez et al	2010	OOOOE	Case Series	4	Botox	7
18	Torres	2012	IJOMS	Case Series	11	Electrothermal Capsulorrhaphy	27
16	Zhou et al	2014	BJOMS	Retrospective review	45	50% dextrose	12
17	Matsushita at al	2007	BJOMS	Case Series	2	OK-432	6

Legend of Journals	
BJOMS	British Journal of Oral and Maxillofacial Surgery
IJOMS	International Journal of Oral and Maxillofacial Surgery
OMS	Oral and Maxillofacial Surgery
Pediatr Dent	Pediatric Dentistry
J Oral Biol Craniofac Res	Journal of oral biology and craniofacial research
J Craniomaxillofac Surg	Journal of cranio-maxillo-facial surgery
Imaging Sci Dent	Imaging science in dentistry
J Craniofac Surg	The journal of craniofacial surgery
OOOOE	Oral surgery, oral medicine, oral pathology, oral radiology, endodontology
J Laryngol Otol Suppl	The journal of laryngology and otology. Supplement
JOMS	The Journal of Oral and Maxillofacial Surgery
J Oral Sci	Journal of oral science

2.2.4 Surgical Methods

Surgical management of recurrent TMJ dislocations could be grouped into methods of disc plication, eminectomy or eminoplasty, orthognathic surgery, or alloplastic joint replacement. Alloplastic joint replacement will not be further mentioned in the below section as no clinical papers studied this treatment modality in the present systematic review.

Known complications of open arthroplasty of the TMJ include facial nerve damage, auriculotemporal nerve paraesthesia, scar, Frey's syndrome, salivary fistula and sialocele. General complications such as pain, infection, bleeding and haematoma formation can also occur. Surgical methods are adopted when conservative methods have either failed, or are not suitable due to patient factors.

2.2.4.1 Disc Plication

Disc plication using artificial anchors/ligaments was first described by Cottrell and Wolford [65]. Zachariah and his group [19] conducted a case series of 17 patients (27 joints) where the disc was plicated to the condyle by using an orthodontic mini-screw placed into the condyle and a non-resorbable Prolene suture anchoring the posterior disc to the mini-screw [19]. There were no cases of recurrence of TMJ dislocation at 12 months using this technique [19].

2.2.4.2 Eminectomy

Eminectomy is the removal of the articular eminence of the temporal bone, and thus reducing obstruction to the relocation of the condyle after dislocation, and was first described by Myrhaug in 1951 [63]. It has been reported as having 100% efficacy at up to 5 years, however there have only been a small number of reports with small sample sizes of 3 or less [34,35,36]. Guven in 2009 assessed patients undergoing both eminectomy and eminoplasty, and found that eminectomy was associated with greater inter-incisal opening [20]. They reported on 19 patients with recurrent TMJ dislocation (a total of 37 joints), aged between 22 to 80 years (mean = 44) that were treated with eminectomy (n=9) if they had either previously failed surgical treatment, had a systemic condition pre-disposing to dislocation (e.g. neurodegenerative disease), or if post-

operative IMF was contraindicated [20]. All other patients in this study (n-12) were treated with eminoplasty via an oblique osteotomy with inter-positional chin graft without fixation [20]. This study reported 100% success, with none of the 19 patients suffering recurrence of their dislocation over a follow-up period that was between 12 months and 12 years [20]. The only variation between the two techniques reported was that patients treated with eminectomy had a decrease in their pre-operative mouth opening of a mean of 7mm, and those treated with eminoplasty had a decrease of 11.67mm [20].

2.2.4.3 Eminoplasty

Eminoplasty was first described by LeClerc and Girard as a glenotemporal osteotomy [68], and was later modified by Gosserez and Dautrey via interposition of a bone graft into a sub-periosteal pocket. This procedure involves down fracture of the zygomatic arch and has been associated with a relocation of the articular eminence inferiorly by approximately 3.5mm and anteriorly by approximately 4.5mm [69]. Adaptations of this procedure have been described since then, including the incorporation of mini-plates and temporal fascial flaps [21]. More recently, blocking techniques have been described using calvarial [37], chin [38] or iliac bone grafts [39] fixated with or without mini-plates to produce an articular eminence over which the condyle cannot glide, thereby preventing dislocation. This procedure has been associated with post-operative pain, infection and fracture of miniplate [39].

In this systematic review, nine studies described eminoplasty for recurrent TMJ dislocation. Guven in 2009 [20] described 19 patients suffering from recurrent TMJ dislocation. These patients were managed either by eminectomy or eminoplasty, depending on their number of dislocations and previous treatment provided. Aetiology was grouped into 5 categories. Type one patients were those who had few episodes of dislocation, and could have their joints reduced without anaesthesia. Group two patients had many episodes of recurrence and required local or general anaesthesia for reduction. Group three patients had an underlying systemic disorder and therefore proceeded straight to arthroplasty. Group four patients had previously failed other treatment

modalities and group five patients were not able to have IMF due to local or systemic factors. Patients falling into groups one and two underwent a modified eminoplasty, and all other patients underwent an eminoplasty. Of the 12 patients that underwent eminoplasty, none had recurrence at a follow up of between 2 and 6 years. These patients had a decrease of mean 11.67mm in their maximal mouth opening [20].

Gadre and colleagues looked at 20 patients who underwent Dautrey's procedure for recurrent TMJ dislocation, and followed them for 18 months. There was no recurrence, and a mean decrease in MMO of 7mm [82].

Kahveci et al described 73 patients that were treated for recurrent TMJ dislocation with autologous bone graft fixated to the antero-inferior surface of the articular eminence with miniplate and screws [39]. These patients were followed up for between three and 30 months. Post-operative maximum mouth opening (MMO) was reduced to a mean of 38mm, although pre-operative MMO was not defined. Three cases were complicated by post-operative infection or fracture of metalware. The exact recurrence rate of TMJ dislocation was not defined in the paper [39].

Da Costa Ribeiro explored surgical treatment options for patients where eminectomy was not possible due to pneumatisation of the articular eminence [83]. Two patients were treated with a modified Dautrey's procedure, where the zygomatic arch was down-fractured, and a miniplate was applied from the lateral of the articular eminence to the displaced zygomatic arch. Both patients who underwent this procedure had no recurrence at 12 and 24 months, and had a MMO of 48 and 45mm respectively [83].

Ying et al also introduced a modified eminoplasty technique for recurrent TMJ dislocation [21]. Seven patients underwent a modified LeClerc blocking procedure, where two osteotomies were made along the zygomatic arch – one anterior to the articular eminence, and one at the zygomaticotemporal suture. The zygomatic arch was down-fractured such that the posterior end of the segment was antero-inferior to the articular eminence. Fixation in this position was achieved

via mini-plates and screws. An inferior-based temporal fascia flap was then used to plicate the antero-lateral aspect of the TMJ capsule. There was no recurrence in the sample group over a follow-up period ranging from 6 to 24 months. There was a mean decrease in mouth opening of 9.8mm. Four of the seven patients also had improvement in TMJ pain and sounds [21].

Sahoo and colleagues looked at the changes in the articular eminence dimensions after Dautrey's procedure in ten patients [69]. Dimensions were measured on OPG x-ray at 12 months, and there was found to be an increase in the vertical height of the eminence of 3.65mm (average, right) and 3.52mm (average, left), which reflects an increase of 48.73% and 48.08% respectively [69]. There was also an anterior shift of the articular eminence of 4.56mm (average, right) and 4.51mm (average, left). There was also a mean decrease in MMO of 4.09mm [69].

Guven in 2008 described another modification of eminoplasty. Twelve patients underwent an oblique osteotomy of the articular eminence, and interpositional autologous bone graft, which was obtained from the chin. No conventional fixation methods were used. The patients were followed up for a mean of 4.2 years, with no recurrence [38]. Guarda-Nardini also described an interpositional graft of the articular eminence, this time harvested from calvarium. In this case report of one patient, there was no recurrence at 8 months [37]. Medra looked at a larger sample size, this time of 60 patients with recurrent TMJ dislocation [22]. All patients underwent a horizontal osteotomy of the articular eminence, and interpositional autologous bone graft, wither from iliac crest or split calvarial. Fixation was either with wires, or miniplates and screws. Patients were followed up for a mean of 36 months, with a mean MMO of 42mm at 12 months. Five patients had temporary facial nerve paralysis, with resolution by 3 months. Three patients required removal of wire which was causing pain from impingement on surrounding tissues [22].

The above papers describing eminoplasty for recurrent TMJ dislocation cannot be directly compared, as they describe varied techniques. Guven showed that eminoplasty was successful in 12 patients suffering from recurrent TMJ dislocation that was not attributed to an underlying systemic condition [20]. Their treatment was associated with a decrease in MMO of 11.67mm [20].

Gadre et al followed 20 patients undergoing Dautrey's procedure, showing a success rate of 100% at 18 months, and a mean decrease in MMO of 7mm [82]. Kahveci and colleagues described a novel method of eminoplasty, but exact success rates were not described [39]. Da Costa also described a new method of eminoplasty, with no recurrence, but only in two patients [83]. Ying et al also described success in a novel procedure, this time a modified LeClerc procedure with a temporal fascia flap in seven patients [21]. Guven and Guarda-Nardini also described modified techniques, using interpositional chin or calvarial grafts, and no fixation [36,37]. The largest study was by Medra, who described a group of 60 patients undergoing interpositional grafting of the articular eminence [22].

2.2.4.4 Orthognathic Surgery

Bimaxillary orthognathic surgery has been described [23] to correct dolichofacial pattern to mesofacial as a treatment modality for recurrent TMJ dislocation. In a study of seven patients, all of whom had a class II skeletal pattern with steep mandibular plane angle and dolichofacial type, all suffering from recurrent TMJ dislocation, were treated with a combination of orthodontic and orthognathic surgery, and a bimaxillary osteotomy [23]. There was no recurrence of TMJ dislocation reported at 12-month review [23]. It was hypothesised that the correction of their hyperdivergent dentofacial deformity also corrected the recurrent TMJ dislocation by optimising the relationship between the condyle and articular eminence.

Table 2 – Surgical management of recurrent TMJ dislocation

Reference Number	Authors	Year	Journal	Type	Case number	Modality	Follow up (months)
71	De Freitas Silva et al	2016	J Craniofac Surg	Letter to Editor	1	Disc plication	12
19	Zachariah et al	2015	JOMS	Case series	17	Disc plication	12
34	Pentyala et al	2014	J Craniofac Surg	Case Report	1	Eminectomy	Not specified
35	Martins	2014	Cranio	Case Report	2	Eminectomy	12
36	Mayrink	2012	J Craniofac Surg	Case Series	3	Eminectomy	60 (5 years)
20	Guyen	2009	J Craniomaxillofac Surg	Retrospective	19	Eminectomy and Eminoplasty	12-144 (1-12 years)
39	Kahveci et al	2013	JOMS	Retrospective analysis	73	Eminoplasty	30
83	Da Costa Ribeiro	2014	IJOMS	Case Series	2	Eminoplasty	12-24
21	Ying et al	2013	J Craniofac Surg	Case Series	7	Eminoplasty	24
69	Sahoo	2013	JOMS	Case Series	10	Eminoplasty	12
82	Gadre	2010	JOMS	Retrospective	20	Eminoplasty	36
38	Guyen	2008	J Craniofac Surg	Case Series	12	Eminoplasty	48 (mean 4 years)
37	Guarda-Nardini et al	2008	Oral Maxillofac Surg	Case Report	1	Eminoplasty	8
22	Medra et al	2008	BJOMS	Prospective Study	60	Eminoplasty	12 – 96 (8 years)
23	Taglialatela	2012	J Craniofac Surg	Case Series	7	Orthognathic Surgery	12

Legend of Journals	
J Craniofac Surg	The journal of craniofacial surgery
JOMS	The Journal of Oral and Maxillofacial Surgery
Cranio	Journal of craniomandibular practice CRANIO
IJOMS	International Journal of Oral and Maxillofacial Surgery
J Craniomaxillofac Surg	Journal of cranio-maxillo-facial surgery
OMS	Oral and Maxillofacial Surgery
BJOMS	British Journal of Oral and Maxillofacial Surgery

2.3 Discussion of Systematic Review

TMJ dislocation can be characterised as unilateral or bilateral, complete (luxation) or partial (subluxation), and by its direction of dislocation, which is most commonly anterior [35]. It can be further defined acute, chronic or recurrent. Subluxations are transient partial TMJ dislocations which are self-resolving.

Acute TMJ dislocation has been attributed to trauma and excessive mouth opening (e.g. during yawning or dental procedures) [35]. Acute TMJ dislocation is managed via reduction (with or without sedation) and may involve adjunctive therapy such as supportive bandages, soft diet and medications.

Chronic TMJ dislocation can result in prolonged disarticulation of one or both joints. Conditions associated with chronic TMJ dislocation include connective tissue disorders such as Ehlers Danlos syndrome [35] and antipsychotic medications such as clonazepam [84]. Ehlers Danlos syndrome can also cause recurrent TMJ dislocation, due to its association with increased soft tissue laxity. Age related or anatomical changes in the condyle, articular eminence and glenoid fossa can also contribute to chronic TMJ dislocation [35,85]. Chronic dislocation may be managed conservatively (e.g. in the palliative setting) or via positional devices, or via surgical management. Acute and chronic protracted TMJ dislocation is outside the scope of this review and will no longer be discussed here.

Recurrent TMJ dislocation is not as well understood as acute or chronic dislocation [86]. Factors contributing to recurrent TMJ dislocation include spasm of the lateral pterygoid muscle and laxity in the meniscus and lateral TMJ ligament [35]. Although usually described in middle aged or elderly populations, recurrent TMJ dislocation can occur at all ages, including infants [8]. Recurrent dislocations can further injure the disc, capsule and TMJ ligaments, contributing to tendency for progressive internal derangement and recurrence of dislocation [87].

Search terms used in this systematic review were MESH terms "recurrent" "temporomandibular joint" and "dislocation". This aimed to capture studies on the recurrent

dislocation, rather than acute dislocation, or protracted chronic subluxation. For this same reason, hypermobility was not included as a search term as this would include a broader range of TMJ disorders not specifically causing recurrent dislocation of the condyle outside of the glenoid fossa. A study period of ten years (2006 to 2016) was chosen to limit the literature review to newer treatment options of recurrent TMJ dislocation. This meant that there was an emphasis on minimally invasive measures such as modified dextrose and autologous blood injection. If the literature review period was extended to older studies, there would have likely been a larger representation of established treatment methods such as eminectomy and eminoplasty.

2.3.1 Botulinum Toxin A into Lateral Pterygoid Muscle

In the study period from 2006 to 2016, there were only two publications describing injection of botulinum toxin A into the lateral pterygoid muscle for management of recurrent TMJ dislocation [12,13]. Approximately 25 to 50 units of botulinum toxin were injected into each lateral pterygoid muscle, using surface landmarks. This can either be transcutaneous, via the sigmoid notch [25] or trans-oral [26]. Pre-operative CT can assist in planning surgical technique. Alternatively, continuous electromyography (EMG) can be used intra-operatively to guide injection [26].

The five cases described in the two papers all involved patients who were not suitable for surgical management. The pooled success rate at six months was 80%. One of the patients who was deemed to be successfully treated with botulinum toxin required a second injection after the first failed. The follow-up for these studies was only six months, after which the botulinum toxin would be wearing off. A longer follow-up period may have revealed a larger sub-group of the patients required repeat injections, but this was not discussed in the studies.

Botulinum toxin injection into the lateral pterygoid muscles significant paralyse their function for approximately three months [13]. This is via irreversible inhibition of acetylcholine release at the neuromuscular junction. During this time, there is decreased anterolateral pull on

the condyles, thereby preventing TMJ dislocation. While there is no dislocation, the supporting structures of the TMJ may have time to regain their integrity, reducing the likelihood of recurrent dislocation even when the lateral pterygoid muscle has regained its function. This hypothesis has to date not been proven in animal models or human studies.

Adverse effects of botulinum toxin A injection into the lateral pterygoid muscles include haematoma, intravascular injection, and inadvertent injection of adjacent muscles, which can cause velopharyngeal insufficiency, dysarthria and dysphagia. Luckily, most of these adverse effects tend to be transient, lasting less than four weeks [27,28].

2.3.2 Autologous blood into joint space

Injection of autologous blood into the superior joint space and lateral TMJ capsule has been extensively described in the literature, but with variable success. In this systematic review, autologous blood injection was found to be associated with a success rate of 80% at 12 months in alleviating recurrent TMJ dislocation [29,30,31,32]. Those that did recur, tended to do so early, with a mean time to recurrence of three weeks [29]. Those that did suffer from recurrence were found to benefit from repeated injections (a maximum of three treatments) [15].

The mechanism by which autologous blood injection prevents TMJ dislocation is thought to be due to stimulation of fibrotic changes within the retro discal tissue and joint capsule. This has been shown histologically in pig [79] and rabbit models [78].

In human specimens, autologous blood injection has been found to be associated with a more favourable relationship between the condyle and glenoid fossa [55]. However, no structural changes within the TMJ have been identified on MRI [80].

Several variations to surgical technique have been described. Most studies describe the use of autologous whole blood injected into the superior joint space (approximately 1-2ml). Some authors also describe injection of a further 1ml of autologous whole blood into the pericapsular tissues, namely the retrodiscal tissues. Efficacy is found to be higher with injection into both the

superior joint space and the peri capsular tissues when compared to the superior joint space alone [14]. Following the ABI with four weeks of intermaxillary fixation was also found to further increase the success rate of this procedure [15]. However, this was associated with a corresponding decrease in mouth opening post-operatively. In Hegab's cohort of 48 patients, those who were treated with ABI alone had a decrease in post-operative mouth opening of 8.5mm, whereas those treated with ABI followed with IMF had a decrease in mouth opening of 11mm [15].

2.3.3 Modified Dextrose Injection into Joint Space

Modified dextrose solution, prepared as 50% dextrose and lignocaine, has been used as a sclerosing agent for recurrent TMJ dislocation. Although only one paper describes this modality [16] this study follows 45 patients treated with intracapsular injection of modified dextrose for recurrent TMJ dislocation. In this patient group, a success rate of 80% (40 or 45 patients) was seen over a period of 18 months, although 14 patients required multiple injections (maximum of three procedures).

The histological changes that are induced by modified dextrose have not been studied in animal models. The proposed mechanism is that the dextrose induces an inflammatory response, which is followed by fibrosis within the joint capsule, which limits mobility of the joint.

Adverse effects of intra-capsular injection of modified dextrose have not been documented. However, Machon hypothesises that inadvertent intraarticular injection of any sclerosing agent, including modified dextrose, may result in damage to intra-articular chondrocytes, and subsequent joint degeneration [32]. This could be avoided by performing intracapsular injection of modified dextrose under arthroscopic guidance [33].

2.3.4 Intra-articular injection of OK-432

OK-432 is a known sclerosing agent, consisting of group A streptococcal pyogenes derivatives that have been inactivated with penicillin and lyophilized. OK-432 can be stored in 15ml vials with 0.16ml of EDTA (ethylenediaminetetraacetic acid).

Intra-capsular injection of OK-432 as a treatment of recurrent TMJ dislocation has been successfully described in a series of two patients who were unsuitable for surgical management. [17].

The effect of OK-432 on human tissues and the resulting fibrosis is well documented [66]. However, the histological changes seen with OK-432 in pericapsular tissues of TMJs in particular have not been documented.

As with the use of other sclerosants such as modified dextrose, there is a theoretical risk to the joint synovium and fibrocartilage with inadvertent intra-articular injection [33].

The long term sequelae of forming intra-articular fibrosis and adhesions, and its relationship to eventual internal joint dysfunction is not known [2].

2.3.5 Electrothermal Capsulorrhaphy

Use of Hol:YAG laser or electrocautery has been described via arthroscopy to stimulate scarring of the TMJ capsule and retrodiscal tissues [18]. In this series of 11 patients, 9 were successfully treated with arthroscopic electrothermal capsulorrhaphy, with a follow up of 27 months. The resulting scarring effect may be further encouraged by injection of a sclerosing agent such as sodium tetradecyl sulphate into the retrodiscal tissues at the same time as the electrothermal capsulorrhaphy [33].

2.3.6 Disc Plication

Cottrell and Wolford first described disc plication as treatment for recurrent TMJ dislocation in 1993 [65]. More recently, in 2015, Zachariah [19] treated 17 patients suffering from

recurrent TMJ dislocation with disc plication using a Prolene suture to anchor the posterior disc to an orthodontic mini-screw fixated into the lateral pole of the condyle. A second Mitek anchor was secured into the root of the zygomatic arch. The Prolene sutures were adjusted to allow some movement of the condyle, but limiting anterior movement such that the condyle was not able to translate over the articular eminence fully.

In this series of 17 patients, there was no recurrence of dislocation at 12 months [19]. The advantages of this procedure include the fact that if the disc is not displaced, then access to it does not require either the superior nor inferior joint space to be breached [33].

Risks of disc plication include fracture of the Mitek anchors, or loosening or breakage of the sutures [33].

2.3.7 Eminectomy

Eminectomy is regarded as the “rescue” procedure for recurrent TMJ dislocation [11] as it removes any obstruction for the condyle to relocate into the glenoid fossa. In this systematic review, eminectomy was associated with a success rate of 100% at a follow up of up to five years [34,35,36].

Guven in 2009 compared eminectomy with eminoplasty in 19 patients [20]. In this study, both modalities were successful in alleviating recurrent TMJ dislocation. However, eminectomy was associated with better post-operative mouth opening. Limitations of this study are that patients were not randomised into treatment groups, meaning that direct comparison between treatment modalities is not possible.

Risks of eminectomy relate to inadvertent entry into the middle cranial fossa or the infratemporal fossa [2].

2.3.8 Eminoplasty

Adverse effects described as a result of eminoplasty include damage to facial nerve, auriculotemporal nerve, complete or unfavourable fracture of the zygomatic arch, or infection,

fracture or exposure of metalware, which would warrant its subsequent removal [33].

Modifications to the zygomatic osteotomy that require blocking techniques as described by Guarda-Nardini, Guven and Kahveci also may be at risk of morbidity from the donor site [37,38,39].

Another limitation of eminoplasty techniques is that they result in reduced mouth opening post-operatively. In Guven's work [20] patients with recurrent TMJ dislocation who were treated with eminoplasty were associated with a reduction in mouth opening of 11.7mm, and those treated with eminectomy had a post-operative reduction in mouth opening of 7mm. The reduction in mouth opening with eminectomy was likely to be due to post-operative swelling or scarring, as the eminectomy itself should not limit mouth opening.

2.3.9 Orthognathic Surgery

The role of orthognathic surgery in treating recurrent TMJ dislocation is limited to cases where there is an obvious dentofacial subtype that is predisposing to dislocation.

Taglialatela in 2012 [23] described a series of seven patients with dolichofacial patterns with a steep mandibular plane angle. All of the seven patients also suffered from recurrent TMJ dislocation. Following bimaxillary osteotomy to correct their dentofacial deformity, none of the seven patients had recurrent TMJ dislocation at 12 months.

2.4 Conclusion of Systematic Review

The aim of this literature review was to review the current treatment modalities available for management of recurrent TMJ dislocation. These treatment modalities can be either minimally invasive, or surgical. Surgical treatment is aimed at either removing any obstruction to the movement of the condylar path (eminectomy) or by increasing it, thereby preventing condylar dislocation (disc plication or Dautrey's procedure and its modifications). Minimally invasive treatment includes injection of sclerosing agents in and around the TMJ, or botulinum toxin of the lateral pterygoid muscle. Since previous review articles, new sclerosing agents have been researched, with promising results.

Injection of autologous blood into the superior joint space and lateral TMJ capsule has been extensively described in the literature, with a success rate of 80% at 16 months. This is likely due to stimulation of fibrotic changes within the retro discal tissue and joint capsule based on histological studies in pig [79] and rabbit models [78] but no structural changes have been identified on MRI [80]. Efficacy is found to be higher with injection into both the superior joint space and the peri capsular tissues when compared to the superior joint space alone [14].

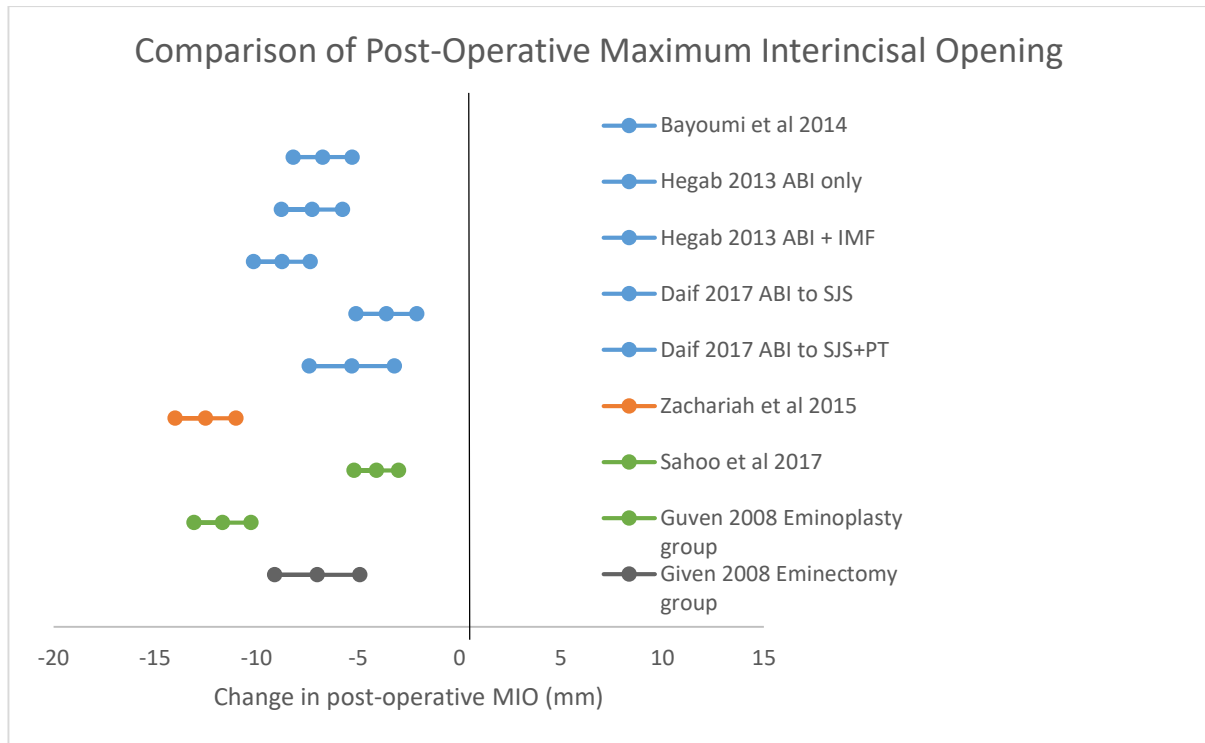
Botulinum toxin injection of the lateral pterygoid muscle has also been reported to have a success of 80% at 6 months. However, the transient nature of botulinum toxin implies that patients may require multiple treatment, and currently longer term larger cohort studies are lacking.

Modified dextrose has been shown to be a promising new modality for the minimally invasive management of recurrent TMJ dislocation. A study of 45 patients reported a success of 91% at 18 months, which is higher than that reported by any other modality. If this can be replicated by other researchers, then perhaps modified dextrose may surpass other treatment modalities for management of recurrent TMJ dislocation.

Current papers on minimally invasive or surgical management of recurrent TMJ dislocation do not clearly advocate for one treatment modality over the other, except that as a principal, conservative or minimally invasive treatment should be trialled first. As with any systematic review

of disease management, there may be a publication bias supporting positive results. One outcome that can be directly compared between the studies is the decrease in post-operative maximum inter-incisal mouth opening (MMO). Of the studies which included sufficient statistical analysis, it was found that a decrease in post-operative MMO occurs with all treatment modalities (Figure 9), with no one treatment modality found worse than the others.

Figure 10 – Comparison of Post-Operative Maximum Inter-Incisal Opening



Key:

Blue	BI	Autologous Blood Injection
Orange	O	Disc Plication
Green	G	Eminoplasty
Grey	G	Eminectomy

Legend:

- ABI – autologous blood injection
- IMF – intermaxillary fixation
- SJS – superior joint space
- PT – pericapsular tissues
- MIO - maximum inter-incisal opening

Large sample size studies on surgical management of recurrent TMJ dislocation with long term follow up are lacking, as are studies exploring the use of multiple surgical modalities in the same patient (e.g. disc plication and eminectomy together). Currently, the mainstay of minimally invasive management is autologous blood injection, although the potential for modified dextrose to surpass this is possible. Botulinum toxin injection of the lateral pterygoid muscle and OK-432 have also shown good results, but not in a large enough cohort.

The mainstay of surgical management of recurrent TMJ dislocation is eminectomy. However, disc plication has also shown excellent promise, with 100% success at 12 months in a group of 27 patients. Eminoplasty can also be effective, with several modifications described. Techniques involving miniplates or block grafting carry with it the risk of fixation failure and donor site morbidity respectively.

Several treatment modalities have been described for the management of recurrent TMJ dislocation. The surgeon must consider the patient's suitability for surgery and possible aetiology when deciding the best approach to management. Current evidence supports the trial of ABI or modified dextrose as minimally invasive management. The success of surgical approaches (disc plication, eminectomy or eminoplasty) are equivocal, and should be tailored to the patient's situation.

Recurrent TMJ dislocation remains a management challenge for practitioners, with no ideal treatment modality. For treatment to be successful, the treatment modality needs to be tailored to the aetiology of the recurrent dislocation. This is a challenge, as the exact aetiology of recurrent TMJ dislocation is poorly understood. For example, if a lax disc is implicated, disc plication with non-resorbable sutures or a mini orthodontic screw [19] can improve the relationship between the condyle, disc and fossa subunits of the TMJ, thereby promoting synchronised movements. Alternatively, if the eminence form is implicated in the cause of recurrent dislocation, then eminectomy or eminoplasty procedures may be of benefit. Thirdly, if lateral pterygoid dysfunction is causing recurrent dislocation, then lateral pterygoid myotomy or injection of botulinum toxin A

into the muscle can help alleviate this problem. Identification of the aetiology of the patient's recurrent dislocation, either on history, clinical examination, or imaging, has not previously been outlined. In one of the practitioner's surgical practice, patients are currently being successfully managed by eminectomy and disc plication. A lateral pterygoid myotomy is also performed if lateral pterygoid spasm or dysfunction is suspected to be contributing to recurrent dislocation. Eminectomy allows free movement of the condyle, and avoids entrapment of the condylar anterior to the eminence, thereby avoiding the need for hospital presentation for reduction. Disc plication aims to promote synchronous movement of the condyle and TMJ meniscus, thereby reducing ligamentous injury with hypermobility.

A new treatment algorithm is proposed in figure ten, that requires clinical validation.

The wide variety of treatment strategies for recurrent TMJ dislocation highlights the fact that this condition is difficult to manage. Treatment should aim to address the factors contributing to recurrent TMJ dislocation, such as muscular dysfunction of the lateral pterygoid, anatomy of the articular eminence, or parafunctional habits. Initially minimally invasive treatment such as injection of autologous blood can be trialled, although a proportion of cases the patient may need to progress to surgical management.

Large sample size studies on surgical management of recurrent TMJ dislocation with long term follow up are lacking, as are studies exploring the use of multiple surgical modalities in the same patient (e.g. disc plication and eminectomy together).

Chapter 3: Surgical management of recurrent dislocation of the temporomandibular joint: a new treatment protocol

3.1 Introduction

Temporomandibular joint dysfunction can be a debilitating condition for patients, resulting in pain, loss of function, and a negative impact on quality of life [40]. Dislocation of the temporomandibular joint (TMJ) carries with it additional morbidity as patients may need to seek medical help for reduction of their dislocated jaw, and each dislocation can further damage the joint as the ligaments and capsule are stretched [84].

Temporomandibular joint dislocation [41] may be acute as a result of trauma or parafunction. It may be chronic as a result of prolonged dislocation due to a lax joint capsule, either due to age related joint degeneration, or anatomical, or even due to the extrapyramidal side effects of anti-psychotic drugs such as haloperidol. Recurrent TMJ dislocation is repeated acute dislocation of the joint which occurs sporadically over an extended time line of many months or years, resulting in functional deterioration of the joint. It can be due to joint laxity or anatomical variation of the articular components.

Dislocation of the condyle is usually in an antero-medial direction due to pull from the lateral pterygoid muscle [84]. This luxation of the condyle anterior to the articular eminence can result in significant trauma to the joint capsule and ligaments [86]. Stretching of these ligaments outside their normal physiological range of motion results in activation of Golgi tendon organs and muscle spindle cells [86], which in turn causes a reflex muscle contraction and pain [87]. The pain and muscle contraction may further prevent the downward and backward movement of the condyle which is required to reduce the joint back into its normal relationship [85].

Dislocation of the TMJ may be on wide opening, where the condyle translates anteriorly to the eminence, or it may be spontaneous, due to abhorrent pull from the lateral pterygoid muscle.

Patients are often able to describe the nature of their dislocation, wide opening, spontaneous, or both, and often avoid behaviours which lead to dislocation. This in turn can lead to anxiety and thereby affect their quality of life.

Current treatment modalities for recurrent TMJ dislocation include minimally invasive techniques such as autologous blood injection [88] or botulinum toxin [12]. Surgical techniques such as eminectomy or eminoplasty have also been well described [35]. In general, surgical modalities are considered superior to minimally invasive techniques, which rely largely on inducing joint fibrosis [89]. None of the methods currently described are without their limitations, and according to Pogrel [85], there is no superior treatment modality identified.

The aim of this study is to look at the long-term outcomes of surgical management of recurrent TMJ dislocation using a combined approach of eminectomy and disc plication (meniscopexy). Furthermore, myotomy of the lateral pterygoid muscle attachment is also presented as an additional treatment modality for cases of muscle dystonia.

3.2 Methodology

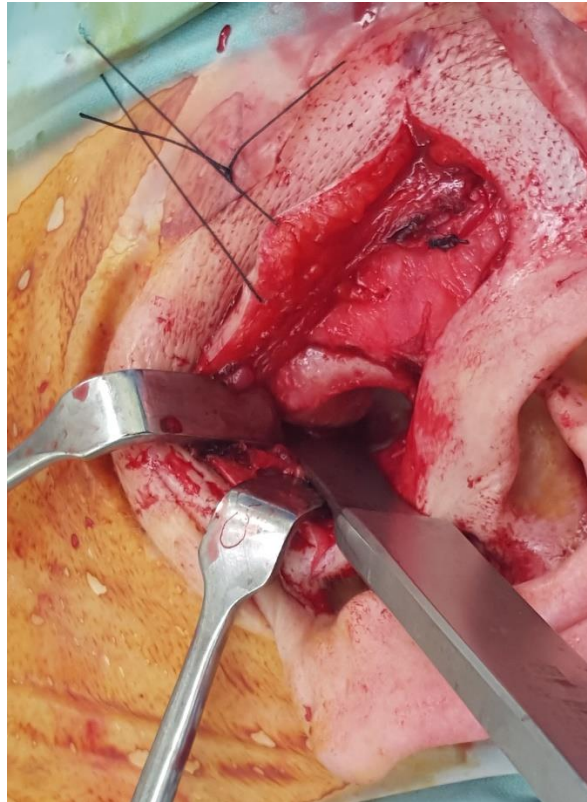Patient records were retrieved using the hospital database, consultant records, and registrar logbooks, to identify cases of recurrent temporomandibular joint (TMJ) dislocation. These records were then analysed to find those who went on to surgical management. Patients were treated by one Oral and Maxillofacial Surgery Consultant surgeon (GD), either in a private facility (Epworth Freemasons, Melbourne, Victoria), or in a public hospital (St Vincent's Hospital Melbourne). Cases seen in the public health care system were treated in conjunction with an OMFS surgical registrar under the direct supervision of the consultant (GD).

Patients treated from March 2010 to March 2016 (6 years) with a follow-up period of at least 12 months were included in this study. Further inclusion criteria were minimum age at diagnosis of 18 years, diagnosis of recurrent TMJ dislocation as defined by a minimum of 6 episodes of temporomandibular dislocation requiring medical attention over a 12-month period (Table 3).

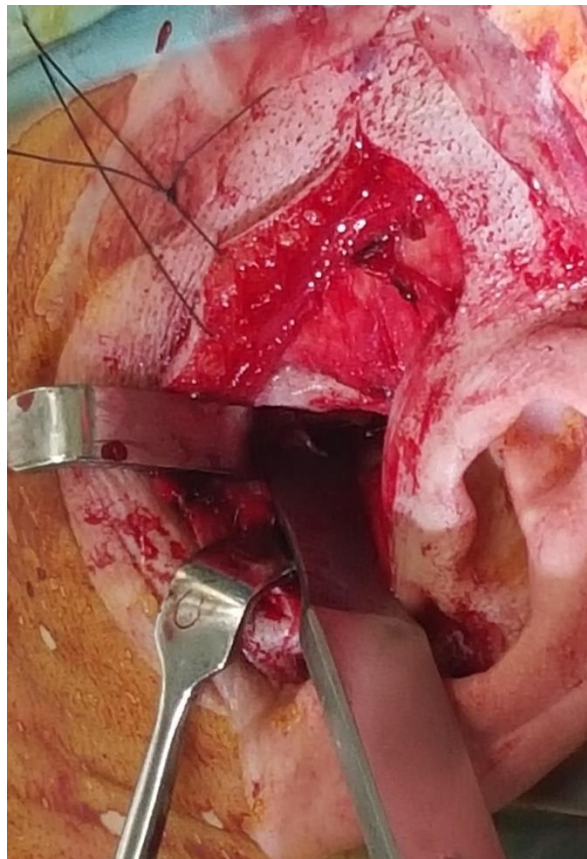The procedure undertaken for all patients was an eminectomy and disc plication via a pre-auricular approach. Under naso-endotracheal general anaesthetic, the patient was placed in a supine position with the head rotated slightly to the contralateral side. Any pre-auricular hair was shaved, and surrounding hair was retracted using Leukoplast Sleek® tape. The skin was prepared with betadine, and Jelonet® gauze was inserted into the external acoustic meatus to protect it from filling up with blood or irrigant fluid during the procedure. A pre-auricular incision was marked utilising an existing skin crease. A small temporal extension was added to allow adequate visualisation of the joint. The dissection was completed in layers, with identification of subcutaneous tissues, SMAS (superficial musculoaponeurotic system, continuous with the temporoparietal fascia), deep temporal fascia, and lateral TMJ capsule. Often encountered were the superficial temporal vessels, which were either retracted or ligated and divided, and the pre-auricular muscles, which were superficial to the temporoparietal fascia. Once the root of the zygomatic arch and lateral TMJ capsule were exposed, sub-periosteal dissection along the root of

the zygoma in an anterior direction allowed exposure of the eminence. An incision was made at the superior edge of the TMJ capsule, to expose the superior joint space. A periosteal elevator was inserted into the superior joint space to retract the disc inferiorly. Eminectomy was completed with a 3mm osteotome, such that at least the lateral two thirds of the eminence was removed (figure 11).

Figure 11 Operative field before (A) and after (B) eminectomy



A



B

A pre-operative CT was completed to ensure the articular eminence was not pneumatized. A hand bone file was used to ensure the osteotomy edges were smooth. Free movement of the condyle was confirmed via manual manipulation of the mandible.

A disc plication was performed using two or three 4-0 non-resorbable sutures, plicating the posterolateral aspect of the disc to the retrodiscal tissues. This restricted excessive anterior movement of the disc via encouraging scar formation within the lax retrodiscal tissues.

In cases where spontaneous TMJ dislocation was described, a lateral pterygoid myotomy was also performed. This was completed by entering the inferior joint space and exposing the anterior aspect of the condylar neck (condylar fovea). The attachment of the lateral pterygoid muscle was sharply dissected from the condylar fovea.

The surgical site was inspected and any bleeding was controlled. The tissues were re-approximated in layers, with resorbable sutures for deep tissues, and non-resorbable sutures for skin. The Jelonet® was removed from the external acoustic meatus, and the meatus was inspected and irrigated if required. A skin dressing (Xeroform®, gauze and crepe bandage) was applied, with light compression for the first 24 hours. The patient was discharged the following day, and reviewed 7 days later for suture removal. Patients were advised a soft diet for 4-6 weeks, and were given instructions regarding restricting mouth opening for the initial post-operative period.

Data was analysed to determine patient demographics, the presentation and nature of the TMJ dislocations, surgical management provided, and the post-operative outcome, including functional and psychological impact on the patient. All patients underwent a standardised TMJ quality of life (QoL) survey which has previously been validated (Appendix VIII) [40].

Ethics approval was granted by the Human Research and Ethics Committee (HREC), St Vincent's Hospital Melbourne. All data was collected in a retrospective fashion, and was stored in a de-identified manner.

Table 3: Inclusion criteria for patient selection

Inclusion Criteria
<ul style="list-style-type: none">- Age over 18 years- Diagnosis of recurrent TMJ dislocation- Surgery between March 2010 and March 2016- Surgery performed or supervised by OMFS Consultant (GD)- Patient followed up for at least 12 months

3.3 Results

During the study period in question, a total of 14 patients were identified. Of these, ten were female, and most patients (11 of 14) were aged 21 to 30 years old (Table 4).

Patients reported TMJ dislocation either on wide opening (12 of 14), or spontaneously (10 of 14). Dislocations occurred more than 6 times a year for the majority of patients, over a duration of 3 or more years.

Most patients suffered from bilateral TMJ dislocation (10 of 14), and those where one joint was affected were equally distributed between right and left. Patients were either able to sometimes reduce the dislocation themselves (6 of 14) or always required medical attention (8 of 14), either with or without sedation.

The majority of cases were not painful (n=12 of 14), and were not associated with an alteration in diet (11 of 14). On pre-operative clinical evaluation, there was no decrease in maximal mouth opening in 10 of 14 patients, although some patients reported guarding to avoid dislocation (4 of 14).

One patient had a history of myotonic dystrophy, which may have directly contributed to her dislocations. Two patients had previously undergone minimally invasive treatment of their recurrent TMJ dislocation (autologous blood injections) which had not resolved their condition.

Patients underwent an eminectomy and disc plication through a pre-auricular approach. Patients received lateral pterygoid myotomy if they complained of spontaneous TMJ dislocation if their surgery was performed in 2013 or later, as this is when the surgeon began undertaking this procedure (table 5).

Post operatively, patients were followed up for a minimum of 12 months, and a maximum of 67 months (5.6 years). No patients reported post-operative recurrence of their TMJ dislocation, and 12 of 14 were pain free. Most patients (12 of 14) had a post-operative mouth opening of more

than 30mm, and all were able to tolerate a full diet. Patients were overall satisfied with their treatment during the post-operative period (table 6).

Patients were requested to complete a post-operative quality of life survey specific to their TMJ function. This was based on a previously validated TMJ-related quality of life survey [40] (Table 7). The response for this survey was 11 of 14.

More than half of patients (8 of 14) reported no pain at the time of final consultation. All patients could speak normally, and 9 of 14 reported that they could tolerate a full diet. Those with restrictions reported only avoidance of very hard foods like apple and steak.

There was no effect on normal activities of daily living or recreational activities, and only one patient reported a mild impact on their overall mood. Only two patients reported a mild level of anxiety related to fear of TMJ dislocation whilst others did not fear recurrence of their dislocation at all.

The main issues noted by patients were pain, effect on diet and anxiety related to dislocation. Eight of 11 patients did not have any issues that were uppermost in their mind. Nine patients reported that their overall health related quality of life had much improved. This is significant as two patients reported that their baseline health related QoL in general was poor.

Most importantly, ten of the eleven patients would recommend surgery to a friend or relative that presented with a similar problem.

Table 4: Patient Demographics and Pre-Operative Data

Patient Number	Age at Surgery (years)		Gender		Dislocation on				Laterality		Pain	
					Wide Opening	Spontaneous						
1	21		M		Y	N			B		N	
2	62		F		Y	Y			B		N	
3	30		M		Y	N			B		N	
4	30		F		Y	N			B		N	
5	28		F		Y	N			L		N	
6	68		M		Y	N			B		N	
7	22		F		Y	Y			R		Y	
8	41		F		Y	Y			L		N	
9	24		F		Y	N			B		N	
10	23		F		N	Y			R		Y	
11	23		F		Y	Y			B		N	
12	30		F		Y	Y			B		N	
13	30		M		Y	N			B		N	
14	27		F		N	Y			B		N	
	Mean	32.8	F:M	2.5:1	%Y	85.7%	%Y	50%	%B	71.4%	%Y	14.3%
									%R	85.7%		
									%L	85.7%		

Legend

M	Male
F	Female
Y	Yes
N	No
R	Right
L	Left
B	Bilateral

Table 5: Operative Management of Patients

Patient Number	Dislocation on		Surgery Performed		
	Wide Opening	Spontaneous	Eminectomy	Disc Plication	Lateral Pterygoid Myotomy
1	Y	N	Y	Y	N
2	Y	Y	Y	Y	Y
3	Y	N	Y	Y	N
4	Y	N	Y	Y	N
5	Y	N	Y	Y	N
6	Y	N	Y	Y	N
7	Y	Y	Y	Y	N
8	Y	Y	Y	Y	N
9	Y	N	Y	Y	N
10	N	Y	Y	Y	Y
11	Y	Y	Y	Y	Y
12	Y	Y	Y	Y	N
13	Y	N	Y	Y	N
14	N	Y	Y	Y	Y

Legend	
Y	Yes
N	No

Table 6: Post-operative Findings

Patient Number	Post-operative Findings						Follow up (months)
	Ongoing Dislocation	Pain	Mouth Opening (mm)	Deviation on Opening	Diet	Patient Satisfaction (self-reported)	
1	N	N	>40	N	F	Y	12
2	N	Y	>25	N	F	Y	12
3	N	N	>40	N	F	Y	59
4	N	N	>35	N	F	Y	30
5	N	N	>35	N	F	Y	32
6	N	N	>35	N	F	Y	20
7	N	N	>45	N	F	Y	12
8	N	N	>40	N	F	Y	12
9	N	Y	>40	N	F	Y	45
10	N	N	>30	N	F	Y	21
11	N	N	>45	N	F	Y	18
12	N	N	>30	N	F	Y	70
13	N	N	>45	N	F	Y	12
14	N	N	<20	N	F	Y	67
%Success	100%	85.7%	85.7%	100%	100%	100%	Average – 27.1

Legend

Y	Yes
N	No
F	Full diet

Table 7: Results from TMJ-related Quality of Life Questionnaire completed at final patient visit

Patient Number	Pain	Diet and Chewing	Speech	Activity	Recreation	Mood	Anxiety	Other Issues	Overall QoL since Surgery	Health-related QoL in general	Recommend similar surgery to a friend?
1	X	X	X	X	X	X	X	X	X	X	X
2	0	1	0	0	0	0	0	Nil	0	4	0
3	0	0	0	0	0	0	0	Nil	0	0	0
4	1	0	0	0	0	0	0	Nil	0	1	0
5	0	0	0	0	0	0	0	Nil	1	0	0
6	0	0	0	0	0	0	0	Nil	0	0	0
7	X	X	X	X	X	X	X	X	X	X	X
8	X	X	X	X	X	X	X	X	X	X	X
9	2	0	0	0	0	1	1	Pain	0	0	0
10	1	1	0	0	0	0	0	Diet	0	1	2
11	0	0	0	0	0	0	0	Nil	0	1	0
12	0	0	0	0	0	0	1	Anxiety	1	4	0
13	0	0	0	0	0	0	0	Nil	0	0	0
14	0	0	0	0	0	0	0	Nil	0	0	0
	72.7% No Pain	81.2% Full Diet	100% Normal	100% Normal	100% unrestricted	90.9% excellent	81.2% no anxiety	72.7% no issues	81.2% much better		90.9% recommend surgery as first line

Legend		
X		Did not respond
Pain	0	I have no pain
	1	I have mild pain not requiring medication
	2	I have moderate pain requiring medication
	3	I have severe pain controlled with medication
	4	I have severe pain not controlled by medication
Diet and Chewing	0	I can chew and chew whatever I like
	1	I can chew most things except tough foods like steak and apple
	2	I only stick to soft foods such as pasta and soft bread
	3	I need to cut up all food into small pieces
	4	I can only eat food that has been put through the blender
Speech	0	My speech is normal
	1	I have difficulty in saying some words
	2	I have difficulty in saying some words
	3	Only my friends and family can understand me
	4	I cannot be understood at all
Activity	0	I am as active as I have ever been
	1	There are times where I can't keep up my old pace, but not often
	2	I am often tired and have slowed down my activities though I still get out
	3	I don't go out very often because I don't have the strength
	4	I am usually in bed or a chair and don't leave home
Recreation	0	There are no limitations to recreation at home or away from home
	1	There are a few things I can't do but I still get out and enjoy life
	2	There are many times where I wish I could get out more, but I am not up to it
	3	There are severe limitations to what I can do, mostly I stay at home and watch TV
	4	I can't do anything enjoyable
Mood	0	My mood is excellent and unaffected by my TMJ disorder
	1	My mood is generally good and only occasionally affected by my TMJ disorder
	2	I am neither in a good mood nor depressed about my TMJ disorder
	3	I am somewhat depressed about my TMJ disorder
	4	I am extremely depressed about my TMJ disorder
Anxiety	0	I am not anxious about my TMJ disorder
	1	I am a little anxious about my TMJ disorder but I am coping
	2	I am very anxious about my TMJ disorder and am finding it difficult coping
	3	I am severely anxious about my TMJ disorder and am not coping at all
Overall QoL	0	Much better
	1	Somewhat better
	2	About the same
	3	Somewhat worse
	4	Much worse
Health QoL in general	0	Excellent
	1	Very good
	2	Good
	3	Fair
	4	Poor
Recommend Surgery to Friend for similar problem?	0	Recommend TMJ surgery as the primary treatment
	1	Recommend TMJ surgery only if other measures such as physiotherapy and splint therapy and medications fail
	2	Recommend TMJ surgery only as a very last resort
	3	Do not recommend TMJ surgery at all

3.4 Discussion

Recurrent TMJ dislocation is rare, but carries with it significant morbidity for affected patients. The causes of recurrent TMJ dislocation are shown in table 8 [48].

Patients may have a combination of aetiological factors contributing to their recurrent joint dislocation, and every dislocation will result in further trauma to the joint. The need for surgical management to address both the eminence and the joint capsule laxity has previously been discussed [90]. In addition, a personalised approach to surgical management should be considered. This involves a detailed patient history to ascertain the nature of their recurrent dislocation, which is shown in table 9.

Table 8: Causes of Recurrent TMJ Dislocation

Causes of Recurrent TMJ Dislocation
Age related joint laxity
Acquired joint injury ² <ul style="list-style-type: none"> - Wide opening – e.g. yawning, vomiting, psychogenic - Parafunction – e.g. seizure disorder
Systemic joint laxity <ul style="list-style-type: none"> - Connective tissue disorders such as Ehlers Danlos syndrome, Marfan’s syndrome - Medications such as benzodiazepines, muscle relaxants
Anatomical -Shallow glenoid fossa/eminence or steep eminence <ul style="list-style-type: none"> - Inherent anatomical variation - Acquired – e.g. Loss of vertical dimension, occlusal discrepancies²

Table 9: Recommended Patient History when determining nature of recurrent TMJ Dislocation

Recommended Patient History when Determining nature of recurrent TMJ Dislocation
Increased joint laxity <ul style="list-style-type: none"> - Dislocation on wide opening - History of connective tissue disorder such as Marfan’s syndrome.
Paroxysmal lateral pterygoid contraction (Dystonia) <ul style="list-style-type: none"> - Spontaneous dislocation (e.g. during talking, while asleep)

The nature of the dislocation should be directly addressed when formulating a surgical plan.

The benefits of eminectomy have been widely described in the literature and is a mainstay of treatment [36]. However, eminectomy has limitations in efficacy [38]. Furthermore, it is reported only in small case series of three or fewer cases [35]. Eminectomy aims to remove barriers to reduction of the condyle to the glenoid fossa, and is associated with an increased post-operative mouth opening when compared to eminoplasty [20].

Disc plication has also been described in the management of recurrent TMJ dislocation [19]. In a case series of 17 patients, there was no recurrence at 12 months.

The benefit of-disc plication and eminectomy together has been established, as eminectomy improves access to the joint for disc plication procedure, and allows smoother disc movements post-operatively [62]. This also supports the argument of a combined approach to surgical management of recurrent TMJ dislocation as shown in this study.

Lateral pterygoid myotomy alone has not been described for the surgical management of recurrent TMJ dislocation. However, botulinum toxin in the lateral pterygoid muscle results in a similar reduction of function, and is associated with no recurrence in the short term (case series of 2 patients with no recurrence at 6 months [12,91]). The surgical technique of lateral pterygoid myotomy is not well described in the literature. In this patient cohort, the lateral pterygoid muscle was sharply dissected from the condylar fovea. The surrogate outcome marker used in this study was the success of the operation in preventing further dislocation events, but it is unknown if there was any partial reattachment of muscle fibres. The fate of this myotomy could be followed up with an MRI, to check if there is reattachment of the lateral pterygoid to the anterior surface of the condylar neck.

In patients who describe spontaneous TMJ dislocation, a lateral pterygoid myotomy or muscle detachment may be of benefit in addition to eminectomy and disc plication.

A proposed treatment approach is depicted in figure ten. Once the diagnosis of recurrent TMJ dislocation is established, the patient must be assessed for surgery. If surgery is contraindicated due to medical co-morbidities or patient preference, then minimally invasive methods may be trialled. If a surgical approach is supported, then the options considered include:

- Eminectomy and disc plication
- Eminectomy, disc plication and lateral pterygoid myotomy.

Patients describing spontaneous dislocation of their joint may benefit from the additional lateral pterygoid myotomy procedure as the anteromedial pull of the lateral pterygoid muscle is significantly reduced, if not eliminated.

Recurrent dislocation of the TMJ is a unique entity, which is different to acute or chronic dislocation. Although rare, recurrent TMJ dislocation poses some challenges for the Oral and Maxillofacial Surgeon. Furthermore, it is a condition associated with significant morbidity and deterioration of quality of life.

There are two distinct types of recurrent TMJ dislocation – that on wide opening, where the condyle is allowed to translate anterior to the eminence due to a lax connective tissue support, and spontaneous dislocation, where the condyle is pulled anteromedially due to paroxysmal lateral pterygoid spasm. In the described patient cohort, patient could suffer from one or both of these mechanisms of dislocation.

Previously described treatment options for recurrent TMJ dislocation include minimally invasive methods such as autologous blood injection, or open TMJ arthroplasty techniques such as eminectomy and eminoplasty. Both groups of treatment are associated with ongoing questions regarding side-effect profile, and efficacy of one modality over the other. Disc plication alone for

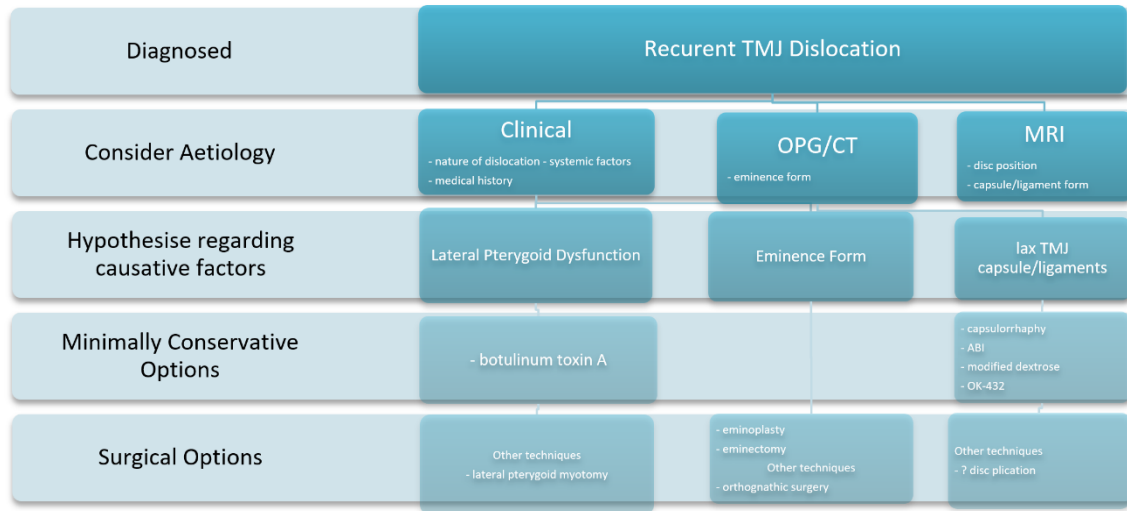
treatment of recurrent TMJ dislocation has limited evidence, but it thought to improve the coordinated movement of the disc and condylar head during mouth opening, and limits anterior translation of the TMJ disc. The role of eminectomy in recurrent TMJ dislocation was thought to be elimination of the cause of obstruction. Some suggest that it may also induce intra-articular scarring, thereby preventing excessive anterior translation of the condyle [2]. This would explain why eminectomy is beneficial even in cases where the medial third of the eminence is left in situ.

This paper proposes a combined surgical arthroplasty approach including eminectomy and disc plication. For patients suffering from spontaneous TMJ dislocation, a lateral pterygoid myotomy is also performed.

Despite the small sample size, this paper shows promising long term results in the surgical management of recurrent TMJ dislocation when combining the procedures of eminectomy and disc plication. However, a larger prospective study directly comparing the different surgical modalities separately and in combination is required before we can be certain of the most appropriate technique for the management of recurrent TMJ dislocation.

The TMJ related quality of life survey used in this study was previously validated in the setting of discectomy. Its extrapolation to use in the assessment of recurrent TMJ dislocation was deemed appropriate as the outcome measures (mouth opening, pain, diet tolerated etc.) are similar in both population groups. Not all patients completed the TMJ related quality of life questionnaire, with the study drop-out rate of 3 of 14 patients. This may introduce a bias to the results. No pre-operative quality of life questionnaire was performed, as the study was retrospective. However, patients were asked to comment on changes to their quality of life measures since the operation, to identify improvement or lack thereof. A follow-up prospective trial should include a baseline questionnaire prior to surgical treatment to better validate any outcome measures.

Figure 12 – Decision making algorithm for treatment of recurrent TMJ dislocation



Chapter 4: Conclusion and Clinical Recommendations

Dislocation of the temporomandibular joint is defined as movement of the condyle outside of the glenoid fossa, which cannot be reduced without external force. Dislocation of the condyle can cause pain, resulting in spasm of the adjacent muscles of mastication. This can prevent reduction of the condyle without some degree of analgesia or sedation.

Most cases of TMJ dislocation are acute and are a result of trauma, prolonged dental procedures or anaesthetic manipulation of the airway. In these cases, reduction can be achieved via the use of manual manoeuvres, which may require sedation to overcome muscle spasm. Isolated acute TMJ dislocation does not usually have long term sequelae.

Chronic TMJ dislocation is where the condyle sits outside the glenoid fossa for a protracted amount of time. Here, manual reduction can be challenging due to formation of scar tissue, which can lead to shortening of the temporalis tendons or formation of a pseudoarthrosis outside the joint proper. Manual reduction may have to be supplemented with a short duration in intermaxillary fixation. If this fails, the patient may require surgical procedures such as open reduction via a trans temporal approach, or even condylectomy.

Recurrent TMJ dislocation is less common than acute dislocation. Here, the patient suffers from repeated episodes of acute dislocation, which require manual reduction. Each episode can be associated with significant pain, and damage to the supporting structures of the TMJ. This damage to the joint capsule and supporting ligaments can further predispose the patient to ongoing dislocation.

Recurrent TMJ dislocation may be precipitated by wide opening, such as during yawning or eating an apple. Alternatively, recurrent TMJ dislocation has also been described as spontaneous, which may be as a result of lateral pterygoid spasm or dystonia. Spontaneous dislocation of the temporomandibular joint can occur during speech, or even at rest.

Patients with recurrent TMJ dislocation require manual reduction with each episode. Definitive management of recurrent TMJ dislocation is not well understood in the current literature, with publications limited to case reports and case series. In general, management of recurrent dislocation can be divided into conservative (or minimally invasive) methods, or surgical methods.

A literature review was carried out to determine the current understanding about the management of recurrent TMJ dislocation. Using PRISMA guideline, three databases (PubMed, Cochrane library and Science Direct) were searched from 2006 to 2016 using the MeSH terms “recurrent”, “temporomandibular joint” and “dislocation”. This yielded a total of 64 papers. After applying the appropriate inclusion and exclusion criteria, a total of 33 papers were reviewed. Of the included studies, 17 related to minimally invasive techniques, including injection of botulinum toxin A into the lateral pterygoid muscle, autologous blood injection, injection of other sclerosing agents such as modified dextrose or OK-432, and electrothermal capsulorrhaphy. The remaining 16 papers related to surgical management of recurrent TMJ dislocation. Surgical methods included disc plication, eminectomy, eminoplasty and orthognathic surgery.

The lack of consensus on management options for recurrent TMJ dislocation, as well as the lack of a personalised treatment approach led to a retrospective analysis of fourteen patients with recurrent TMJ dislocation treated via a tailored surgical approach. Here, patients were treated with eminectomy and disc plication, both of which have been associated with 100% success rate in small case series [20,22]. This was augmented with a lateral pterygoid myotomy in patients who described spontaneous dislocation, which is thought to represent lateral pterygoid muscle dystonia or spasm.

Over a period of six years (from 2010 to 2016), a total of 14 patients with recurrent TMJ dislocation were treated by an Oral and Maxillofacial Surgeon with a special interest in temporomandibular joint surgery.

All patients included in the study were managed via a combined surgical approach. Patients underwent a pre-auricular approach to the joint, and were treated with an eminectomy and disc plication. Those patients who described spontaneous TMJ dislocation were also treated with a lateral pterygoid myotomy. Patients were followed up for a minimum of 12 months. There were no cases of recurrence in TMJ dislocation. Patients were followed up with a TMJ-related quality of life survey that has been previously validated [85]. Most patients reported no pain with daily activities (11 of 14 patients). All patients could note no issues with speech, and most (9 of 14 patients) could tolerate a full diet. The majority of patients (10 of 11) would recommend surgery to a friend with recurrent TMJ dislocation.

Prior to the current study, the role of a tailored combined surgical approach for recurrent TMJ dislocation has not been described. Eminectomy removes any barriers for the condyle to return to the glenoid fossa. Furthermore, disc plication allows coordinated movement between the articular disc and the condyle. It also may alter proprioceptive feedback relating to condyle position, limiting anterior translation. Lateral pterygoid myotomy addresses any muscle dystonia or spasm causing spontaneous TMJ dislocation.

Recurrent TMJ dislocation is a rare clinical entity that is poorly understood, and has no gold standard treatment modality. An understanding of normal TMJ anatomy and function is necessary to understand the role of different treatment modalities for recurrent TMJ dislocation.

Assessment of the patient with recurrent TMJ dislocation is essential in identifying what factors are precipitating dislocation. These factors can then be targeted via either a minimally invasive or surgical approach.

Based on the current limited evidence base, surgical approaches are associated with better success rates when compared to minimally invasive techniques. Prior to this thesis, the role of combined surgical approaches has not been described. This paper suggests that a tailored approach comprising of eminectomy, disc plication and/or lateral pterygoid myotomy is

associated with a 100% success rate at 12 months. It is also associated with improvement in TMJ-related quality of life, and has great patient acceptability, with most patients reporting that they would recommend this surgery to a friend suffering from recurrent TMJ dislocation.

Word Count: 19,296

References

- 1 Sensoz O, Ustuner ET, Celebioglu S et al. Eminectomy for the treatment of chronic subluxation and recurrent dislocation of the temporomandibular joint and a new method of patient evaluation. *Ann Plast Surg.* 1992; 29:299-302
- 2 Undt G. Temporomandibular joint eminectomy for recurrent dislocation. *Atlas Oral Maxillofac Surg Clin N Am.* 2011; 19:189-206
- 3 De Coster PJ, Van den Berghe LI, Martens LC. Generalized joint hypermobility and temporomandibular disorders: inherited connective tissue disease as a model with maximum expression. *Journal of orofacial pain.* 2005 Jan 1;19(1).
- 4 Thexton A. A case of Ehlers Danlos Syndrome presenting with recurrent dislocation of the TMJ. *Br J Oral Surg.* 1965; 2:190-193
- 5 Caminiti MF, Weinberg S. Chronic mandibular dislocation: the role of non-surgical and surgical treatment. *J Can Dent Assoc.* 1998; 64(7):484-91
- 6 O'Connor M, Rooney M, Nienaber CP. Neuroleptic-induced dislocation of the jaw. *Dr J Psych.* 1992; 161:281
- 7 Wood GD. AN adverse reaction to metoclopramide therapy. *Br J Oral Surg.* 1978; 15:278-280
- 8 Loh HS. Idiopathic oromandibular dystonia causing failure of mouth closure. *Br Dent J.* 1983; 154:291-292
- 9 Herring SW. TMJ Anatomy and animal models. *J Musculoskeletal Neuronal Interact.* 2003; 3(4):391
- 10 McMinn RMH. *Last's Anatomy – regional and applied.* 9th ed. Churchill Livingstone. London 2009.
- 11 de Almeida VL, Vitorino Nde S, Nascimento AL, da Silva Júnior DC, de Freitas PH. Stability of treatments for recurrent temporomandibular joint luxation: a systematic review. *Int J Oral Maxillofac Surg.* 2016 Mar;45(3):304-7.
- 12 Oztel M, Bilski WM, Bilski A. Botulinum toxin used to treat recurrent dislocation of the temporomandibular joint in a patient with osteoporosis. *Br J Oral Maxillofac Surg.* 2016 May 30.

- 13 Vázquez Bouso O, Forteza González G, Mommsen J, Grau VG, Rodríguez Fernández J, Mateos Micas M. Neurogenic temporomandibular joint dislocation treated with botulinum toxin: report of 4 cases. *Oral Surg Oral Med Oral Pathol Oral Radiol Endod.* 2010 Mar;109(3): e33-7.
- 14 Daif ET. Autologous blood injection as a new treatment modality for chronic recurrent temporomandibular joint dislocation. *Oral Surg Oral Med Oral Pathol Oral Radiol Endod.* 2010 Jan;109(1):31-6.
- 15 Hegab AF. Treatment of chronic recurrent dislocation of the temporomandibular joint with injection of autologous blood alone, intermaxillary fixation alone, or both together: a prospective, randomised, controlled clinical trial. *Br J Oral Maxillofac Surg.* 2013 Dec;51(8):813-7.
- 16 Zhou H, Hu K, Ding Y. Modified dextrose prolotherapy for recurrent temporomandibular joint dislocation. *Br J Oral Maxillofac Surg.* 2014 Jan;52(1):63-6.
- 17 Matsushita K, Abe T, Fujiwara T. OK-432 (Picibanil) sclerotherapy for recurrent dislocation of the temporomandibular joint in elderly edentulous patients: Case reports. *Br J Oral Maxillofac Surg.* 2007 Sep;45(6):511-3.
- 18 Torres DE, McCain JP. Arthroscopic electrothermal capsulorrhaphy for the treatment of recurrent temporomandibular joint dislocation. *Int J Oral Maxillofac Surg.* 2012 Jun;41(6):681-9.
- 19 Zachariah T, Neelakandan RS, Ahamed MI. Disc Anchoring with an Orthodontic Mini-Screw for Chronic Meniscocondylar Dislocation of TMJ. *J Maxillofac Oral Surg.* 2015 Sep;14(3):735-44.
- 20 Güven O. Management of chronic recurrent temporomandibular joint dislocations: a retrospective study. *J Craniomaxillofac Surg.* 2009 Jan;37(1):24-9.
- 21 Ying B, Hu J, Zhu S. Modified Leclerc blocking procedure with miniplates and temporal fascial flap for recurrent temporomandibular joint dislocation. *J Craniofac Surg.* 2013 May;24(3):740-2.
- 22 Medra AM, Mahrous AM. Glenotemporal osteotomy and bone grafting in the management of chronic recurrent dislocation and hypermobility of the temporomandibular joint. *BJOMS* 2008. 46:119-122

- 23 Taglialatela Scafati C, Taglialatela Scafati S. Role of orthognathic surgery in the treatment of recurrent mandibular dislocation: importance of mandibular ramus inclination. *J Craniofac Surg*. 2012 Sep;23(5): e420-3.
- 24 Nevakari K. Elapsio pre-articularis of the temporomandibular joint – a pantomographic study of the so-called physiological subluxation. *Acta Odontol Scan*. 1960; 18(2): 123-170
- 25 Fu K, Chen HM, Sun ZP et al. Long term efficacy of botulinum toxin type A for the treatment of habitual dislocation of the temporomandibular joint. *Br J Oral Maxillofac Surg*. 2010; 48:281-284
- 26 Martinez-Perez D, Ruiz-Espiga PG. Recurrent temporomandibular joint dislocation treated with botulinum toxin: report of 3 cases. *J Oral Maxillofac Surg*. 2004; 62:244-246
- 27 Moore AP, Wood GD. Medical treatment of recurrent temporomandibular joint dislocation using botulinum toxin A. *Br Dent J* 1997;183:415-7.
- 28 Zigeler CM, Haag C, Muhling J. Treatment of recurrent temporomandibular joint dislocation with intramuscular botulinum toxin injection. *Clin Oral Invetig*. 2003; 7:52-55
- 29 Bayoumi AM, Al-Sebaei MO, Mohamed KM, Al-Yamani AO, Makrami AM. Arthrocentesis followed by intra-articular autologous blood injection for the treatment of recurrent temporomandibular joint dislocation. *Int J Oral Maxillofac Surg*. 2014 Oct;43(10):1224-8.
- 30 Coser R, da Silveira H, Medeiros P, Ritto FG. Autologous blood injection for the treatment of recurrent mandibular dislocation. *Int J Oral Maxillofac Surg*. 2015 Aug;44(8):1034-7.
- 31 Gupta D, Rana AS, Verma VK. Treatment of recurrent TMJ dislocation in geriatric patient by autologous blood - A technique revisited. *J Oral Biol Craniofac Res*. 2013 Jan-Apr;3(1):39-41.
- 32 Machon V, Abramowicz S, Paska J, Dolwick MF. Autologous blood injection for the treatment of chronic recurrent temporomandibular joint dislocation. *J Oral Maxillofac Surg*. 2009 Jan;67(1):114-9.
- 33 Liddell A, Perez DE. Temporomandibular joint dislocation. *Oral Maxillofac Surg Clin North Am*. 2015 Feb;27(1):125-36. doi: 10.1016/j.coms.2014.09.009. Review.

- 34 Pentyala S, Mysore P, Moller D, Pentyala S, Kardovich R, Martino A, Proothi M. Temporomandibular joint disorder and inner ear pruritus: resolution by eminectomy. *J Craniofac Surg.* 2014 Sep;25(5):1840-2.
- 35 Martins WD, Ribas Mde O, Bisinelli J, França BH, Martins G. Recurrent dislocation of the temporomandibular joint: a literature reviews and two case reports treated with eminectomy. *Cranio.* 2014 Apr;32(2):110-7. Review.
- 36 Mayrink G, Olate S, Assis A, Sverzut A, de Moraes M. Recurrent mandibular dislocation treated by eminectomy. *J Craniofac Surg.* 2012 Sep;23(5): e516-20.
- 37 Guarda-Nardini L, Palumbo B, Manfredini D, Ferronato G. Surgical treatment of chronic temporomandibular joint dislocation: a case report. *Oral Maxillofac Surg.* 2008 May;12(1):43-6.
- 38 Guven O. A clinical study on treatment of temporomandibular joint chronic recurrent dislocations by a modified eminoplasty technique. *J Craniofac Surg.* 2008 Sep;19(5):1275-80.
- 39 Kahveci R, Simsek ME, Akin S, Ozbek S, Ozgenel GY, Gökmen ZG. Treatment of recurrent temporomandibular joint dislocation. *J Maxillofac Oral Surg.* 2013 Dec;12(4):379-81.
- 40 Dimitroulis G, McCullough M, Morrison W. Quality-of-life survey comparing patients before and after discectomy of the temporomandibular joint. *J Oral and Maxillofac Surg* 68:101-106, 2010
- 41 Dolwick FM, Abramowicz S, Bagheri SC. Diagnosis and management of temporomandibular joint pain and masticatory dysfunction. Chapter 98 in *Current Therapy in Oral and Maxillofacial Surgery.* Elsevier Saunders. 2012:859-868.
- 42 Hardiman R, Kujan O, Kochaji N. Normal variation in the anatomy, biology, and histology of the maxillofacial region. In *Contemporary Oral Medicine*, CS Farah et al (eds). Springer International Publishing AG 2018
- 43 Kademani D, Tiwana P (Eds.). *The Anatomy of the face, mouth and jaws.* Chapter 5 in: *Atlas of Oral and Maxillofacial Surgery.* Elsevier Health Sciences. 2015
- 44 Janfaza P, Nadol JB Jr, Galla RJ, Fabian RL, Montogemery WW. Surgical anatomy of the head

and neck. Lippincott Williams and Wilkins 2001

45 Huddleston Slater JJR, de Leeuw R. Internal derangements of the temporomandibular joint. In Contemporary Oral Medicine, CS Farah et al (eds). Springer International Publishing AG 2018

46 Wadhwa S, Kapila S. TMJ Disorders: Future innovations in diagnostics and therapeutics. J Dent Educ. 2008 72(8):930-947

47 Miloro M (Ed). Peterson's principles of oral and maxillofacial surgery. 2nd Ed. 2004 BC Decker Inc London.

48 Sharma NK, Singh Ak, Pandev A, Verma V, Singh S. Temporomandibular joint dislocation. Natl J Maxillofac Surg. 2015; 6(1): 16-20

49 Akinbami BO. Evaluation of the mechanism and principles of management of temporomandibular joint dislocation. Systematic review of the literature and a proposed new classification of temporomandibular joint dislocation. Head Face Med. 2011; 7:10

50 Ellis E III, Zide MF. Surgical approaches to the facial skeleton. 2nd ed. Lippincott Williams and Wilkins. 2006 New York.

51 Awang MN. A new approach to the reduction of acute dislocation of the temporomandibular joint: a report of three cases. Br J Oral Maxillofac Surg. 1987; 25:244

52 Lowery LE, Beeson MS, Lum KK. The wrist-pivot method, a novel technique for temporomandibular joint reduction. J Emerg Med. 2004; 27(2):167-170

53 Chen YC, Chen CT, Lin CH, Chen YR. A safe and effective way for reduction of temporomandibular joint dislocation. Ann Plast Surg. 2007; 58(1):105-108

54 Littler BO. The role of local anaesthesia in the reduction of longstanding dislocation of the temporomandibular joint. British J Oral Surg. 1980; 18:81-85

55 Rao P. Conservative treatment of bilateral persistent anterior dislocation of the mandible. J Oral Surg. 1980; 38:51-52

56 Lewis JE. A simple technique for reduction of long-standing dislocation of the mandible. British

Journal of Oral Surgery. 1981; 19(1):52-6

57 El-Attar A, Ord RA. Longstanding mandibular dislocations: report of a case, review of the literature.

Br Dent J. 1986; 160(3):91

58 Annandale T: Displacement of the interarticular cartilages of the lower jaws and its treatment by operation, Lancet (8):411, 1887.

59 Stimson LA: Manual of operative surgery, ed 3, Philadelphia, 1895, Lea Bros & Co.

60 Murphy JB: Arthroplasty for intra-articular bony and fibrous ankylosis of temporomandibular disarticulation. JAMA (62):1783-1914

61 Al-Kayat A, Bramley P: A modified preauricular approach to the temporomandibular joint and malar arch, Br J Oral Surg 17:91, 1979

62 Kademani D, Tiwana P (Eds.). Arthroplasty and Eminectomy. Chapter 129 in: Atlas of Oral and Maxillofacial Surgery. Elsevier Health Sciences. 2015

63 Myrhaug H. A new method of operation for habitual dislocation of the mandible—review of former methods of treatment. Acta Odont Scand 1951; 9: 247–261.

64 Irby WB. Surgical correction of chronic dislocation of the TMJ not responsive to conservative therapy. J Oral Surg 1957; 15: 307–312.

65 Cottrell DA, Wolford LM. The Mitek mini anchor in maxillofacial surgery. J Oral Maxillofac Surg Educational Summaries and Outlines. 1993;57(3):150.

66 Laskin DM. Myotomy for the management of recurrent and protracted mandibular dislocations. Trans Congr Int Assoc Oral Surg 1973; 4: 264–268.

67 Bradley P. Injuries to the condylar head and coronoid process. In: Rowe NL, Williams JL (eds). Maxillofacial Injures. New York. Churchill Livingston. 1995: 420-473

68 LeClerc G, Girard G. Un nouveau procede de butee dans le traitement chirurgical de la luxation reidivante de la machoire inferieure. Mem Acad Chir 1943; 69:457–459

69 Sahoo NK, Bhardwaj PK. Radiographic assessment of changes in particular tubercle after Dautrey's

procedure. *J Oral Maxillofac Surg.* 2013 Feb;71(2):249-54.

70 Schultze LW. Report on ten years' experience in treating hypermobility of the temporomandibular joint. *J Oral Surg.* 1947; 5:202-20

71 de Freitas Silva L, Ribeiro NR, Faverani LP, Gondim RF, Maia RN. Treatment of Chronic Recurrent Temporomandibular Joint Dislocation. *J Craniofac Surg.* 2016 May;27(3):815.

72 Le Goff F, Lefaucheur R, Fetter D, Rouille A, Maltête D. Recurrent Bilateral Dislocation of the Temporomandibular Joint Induced by Clonazepam in a Parkinsonian Patient. *Clin Neuropharmacol.* 2016 Jan-Feb;39(1):66.

73 Moher D, Liberati A, Tetzlaff J, Altman DG, The PRISMA Group (2009). Preferred Reporting Items for Systematic Reviews and Meta-Analyses: The PRISMA Statement. *PLoS Med* 6(7): e1000097. doi:10.1371/journal.pmed1000097

74 Boering G. Temporomandibular joint osteoarthritis. A clinical and radiographic examination. An analysis of 400 cases. Reprint in English of: arthrosis deformans van het kaakgewricht: een klinische en roentgenologisch onderzoek (thesis). Gronin-gen: Drukkerij van Danderen. 1966/1994:259-264

75 Murakami K, Hori S, Yamaguchi Y, Mercuri LG, Harayama N, Maruo S, Takahashi T. Synovial plicae and temporomandibular joint disorders: surgical findings. *J Oral Maxillofac Surg.* 2015 May;73(5):827-33.

76 Kato T, Shimoyama T, Nasu D, Kaneko T, Horie N, Kudo I. Autologous blood injection into the articular cavity for the treatment of recurrent temporomandibular joint dislocation: a case report. *J Oral Sci.* 2007 Sep;49(3):237-9.

77 Pinto AS, McVeigh KP, Bainton R. The use of autologous blood and adjunctive 'face lift' bandage in the management of recurrent TMJ dislocation. *Br J Oral Maxillofac Surg.* 2009 Jun;47(4):323-4.

- 78 Candirli C, Yüce S, Yldrm S, Sert H. Histopathologic evaluation of autologous blood injection to the temporomandibular joint. *J Craniofac Surg.* 2011 Nov;22(6):2202-4.
- 79 Gulses A, Bayar GR, Aydintug YS, Sencimen M, Erdogan E, Agaoglu R. Histological evaluation of the changes in temporomandibular joint capsule and retrodiscal ligaments following autologous blood injection. *J Craniomaxillofac Surg.* 2013 Jun;41(4):316-20.
- 80 Candirli C, Yüce S, Cavus UY, Akin K, Cakir B. Autologous blood injection to the temporomandibular joint: magnetic resonance imaging findings. *Imaging Sci Dent.* 2012 Mar;42(1):13-8.
- 81 Ogita S, Tsuto T, Nakamura K, Deguchi E. OK-432 therapy for lymphangioma in children: why and how does it work? *J Pediatric Surg.* 1996: 31(4); 477-480
- 82 Gadre KS, Kaul D, Ramanojam S, Shah S. Dautrey's procedure in treatment of recurrent dislocation of the mandible. *J Oral Maxillofac Surg.* 2010. 68:2021-2024
- 83 Da Costa Ribeiro R, dos Santos Jr BJ, Provenzano N, de Freitas PHL. Dautrey's procedure: an alternative for the treatment of recurrent mandibular dislocation in patients with pneumatisation of the articular eminence. *Int J Oral Maxillofac Surg.* 2014; 43:465-469
- 84 August M, Troulis MJ, Kaban LB. Hypomobility and Hypermobility disorders of the temporomandibular joint. Chapter 52 in Peterson's principles of Oral and Maxillofacial Surgery 2nd ED. Miloro M (Ed) 2004. BC Decker Inc p1033-1050
- 85 Pogrel MA (Ed). Temporomandibular Joint Disorders. Part 8 in Oral and Maxillofacial Surgery. 2010 Wiley Blackwell
- 86 Kumar V, Abbas KA, Fausto N. Robbins and Cortan Pathologic Basis of Disease 7th ED. 2005 Elsevier Saunders.
- 87 Nale JC, Tucker MR. Management of Temporomandibular Disorders. Chapter 38 in Part 8:

Temporomandibular and other facial pain disorders in Contemporary Oral and Maxillofacial Surgery 6th Ed. 2014 Elsevier Mosby.

88 Varedi P, Bohluli B. Autologous blood injection for treatment of chronic recurrent TMJ dislocation: is it successful? Is it safe enough? A systematic review. Oral Maxillofac Surg. 2015 Sep;19(3):243-52.

89 Shorey CW, Campbell JH. Dislocation of the temporomandibular joint. Oral Surg Oral Med Oral Pathol Oral Radiol Endo. 2000;89(6):662-668

90 Cascone P, Ungari C, Paparo F, Marianetti TM, Ramieri V, Fatone MG. A new surgical approach for the treatment of chronic recurrent temporomandibular joint dislocation. Journal of Craniofacial Surgery 2008;19(2);510-512.

91 Stark TR, Perez CV, Okeson JP. Recurrent TMJ Dislocation Managed with Botulinum Toxin Type A Injections in a Pediatric Patient. Pediatr Dent. 2015 Jan-Feb;37(1):65-9.

Appendices

Appendix I – Search Strategies for Databases used in Systematic Review

PubMed (Medline)

Recurrent

AND

Dislocation – “joint dislocations” [MeSH Terms] OR ("joint"[All Fields] AND "dislocations"[All Fields]) OR "joint dislocations"[All Fields] OR "dislocation"[All Fields]

AND

Temporomandibular Joint - "temporomandibular joint"[MeSH Terms] OR ("temporomandibular"[All Fields] AND "joint"[All Fields]) OR "temporomandibular joint"[All Fields]

AND

("2006/06/01" [PDat]:"2016/06/01" [PDat])

Cochrane Library

Recurrent

AND

Dislocation – “joint dislocations” [MeSH Terms] OR ("joint"[All Fields] AND "dislocations"[All Fields]) OR "joint dislocations"[All Fields] OR "dislocation"[All Fields]

AND

Temporomandibular Joint - "temporomandibular joint"[MeSH Terms] OR
("temporomandibular"[All Fields] AND "joint"[All Fields]) OR "temporomandibular joint"[All
Fields]

AND

("2006/06/01" [PDat]:"2016/06/01" [PDat])

ScienceDirect

"recurrent" AND "joint dislocations" OR ("joint" AND "dislocations") OR "joint dislocations"
OR "dislocation" AND "temporomandibular joint" OR ("temporomandibular" AND "joint") OR
"temporomandibular joint"

Pub Date 2006-2016

Appendix II – Critical Appraisal Tool Used

Adapted from Crombie, The Pocket Guide to Critical Appraisal; the critical appraisal approach used by the Oxford Centre for Evidence Medicine, checklists of the Dutch Cochrane Centre, BMJ editor's checklists and the checklists of the EPPI Centre.

Critical Appraisal of a Case Study/Case Series

Article Citation: _____



Appraisal Questions	Yes	Can't Tell	No
1. Did the study address a clearly focused question / issue?			
2. Is the research method (study design) appropriate for answering the research question?			
3. Are both the setting and the subject's representative with regard to the population to which the findings will be referred?			
4. Is the researcher's perspective clearly described and taken into account?			
5. Are the methods for collecting data clearly described?			
6. Are the methods for analysing the data likely to be valid and reliable? Are quality control measures used?			
7. Was the analysis repeated by more than one researcher to ensure reliability?			
8. Are the results credible, and if so, are they relevant for practice?			
9. Are the conclusions drawn justified by the results?			
10. Are the findings of the study transferable to other settings?			

Appendix III – Studies Retrieved from Databases

Bold – included in thesis

1. **Oztel M, Bilski WM, Bilski A. Botulinum toxin used to treat recurrent dislocation of the temporomandibular joint in a patient with osteoporosis. Br J Oral Maxillofac Surg. 2016 May 30. pii: S0266-4356(16)30094-8. doi: 10.1016/j.bjoms.2016.05.012. [Epub ahead of print] PMID: 27256802**
2. **de Freitas Silva L, Ribeiro NR, Faverani LP, Gondim RF, Maia RN. Treatment of Chronic Recurrent Temporomandibular Joint Dislocation. J Craniofac Surg. 2016 May;27(3):815. doi: 10.1097/SCS.0000000000002424. PMID: 27159865**
3. Le Goff F, Lefaucheur R, Fetter D, Rouille A, Maltête D. Recurrent Bilateral Dislocation of the Temporomandibular Joint Induced by Clonazepam in a Parkinsonian Patient. Clin Neuropharmacol. 2016 Jan-Feb;39(1):66. doi: 10.1097/WNF.0000000000000124. PMID: 26757315
4. Sharma NK, Singh AK, Pandey A, Verma V, Singh S. Temporomandibular joint dislocation. Natl J Maxillofac Surg. 2015 Jan-Jun;6(1):16-20. doi: 10.4103/0975-5950.168212. Review. PMID: 26668447
5. Gilon Y, Johnen J, Nizet JL. How I Treat. An Anterior Temporomandibular Joint Dislocation. Rev Med Liege. 2015 Sep;70(9):411-4. French. PMID:26638440
6. de Almeida VL, Vitorino Nde S, Nascimento AL, da Silva Júnior DC, de Freitas PH. Stability of treatments for recurrent temporomandibular joint luxation: a systematic review. Int J Oral Maxillofac Surg. 2016 Mar;45(3):304-7. doi: 10.1016/j.ijom.2015.10.022. Epub 2015 Nov 23. Review. PMID: 26616027
7. Bindra A, Bithal P, Sokhal N, Arora A. Pain relief can be painful. Indian J Palliat Care. 2015 Sep-Dec;21(3):355-7. doi: 10.4103/0973-1075.164913.PMID: 26600706 Free PMC Article

8. Zachariah T, Neelakandan RS, Ahamed MI. Disc Anchoring with an Orthodontic Mini-Screw for Chronic Meniscocondylar Dislocation of TMJ. *J Maxillofac Oral Surg.* 2015 Sep;14(3):735-44. doi: 10.1007/s12663-014-0729-2. Epub 2014 Dec 6. PMID: 26225070
9. Coser R, da Silveira H, Medeiros P, Ritto FG. Autologous blood injection for the treatment of recurrent mandibular dislocation. *Int J Oral Maxillofac Surg.* 2015 Aug;44(8):1034-7. doi: 10.1016/j.ijom.2015.05.004. Epub 2015 May 26. PMID: 26022511
10. Varedi P, Bohluli B. Erratum to: Autologous blood injection for treatment of chronic recurrent TMJ dislocation: is it successful? Is it safe enough? A systematic review. *Oral Maxillofac Surg.* 2015 Sep;19(3):329-31. doi: 10.1007/s10006-015-0508-3. No abstract available. PMID: 26004293
11. Varedi P, Bohluli B. Autologous blood injection for treatment of chronic recurrent TMJ dislocation: is it successful? Is it safe enough? A systematic review. *Oral Maxillofac Surg.* 2015 Sep;19(3):243-52. doi: 10.1007/s10006-015-0500-y. Epub 2015 May 3. Erratum in: *Oral Maxillofac Surg.* 2015 Sep;19(3):329-31. PMID: 25934244
12. Ogawa M, Kanbe T, Kano A, Kubota F, Makiguchi T, Miyazaki H, Yokoo S. Conservative reduction by lever action of chronic bilateral mandibular condyle dislocation. *Cranio.* 2015 Apr;33(2):142-7. doi: 10.1179/0886963414Z.00000000041. Epub 2014 Apr 14. PMID:25919752
13. Wu D, Hu K, Zhou H. *Zhonghua Kou Qiang Yi Xue Za Zhi.* [Modified dextrose prolotherapy for the treatment of recurrent temporomandibular joint dislocation]. 2015 Feb;50(2):113-4. Chinese. No abstract available. PMID:25908197
14. Pradhan L, Jaisani MR, Sagtani A, Win A. Conservative Management of Chronic TMJ Dislocation: An Old Technique Revived. *J Maxillofac Oral Surg.* 2015 Mar;14(Suppl 1):267-70. doi: 10.1007/s12663-013-0476-9. Epub 2013 Feb 1. PMID:25838707
15. Murakami K, Hori S, Yamaguchi Y, Mercuri LG, Harayama N, Maruo S, Takahashi T. Synovial plicae and temporomandibular joint disorders: surgical findings. *J Oral Maxillofac Surg.*

- 2015 May;73(5):827-33. doi: 10.1016/j.joms.2014.12.018. Epub 2014 Dec 24. PMID: 25795190
16. Stark TR, Perez CV, Okeson JP. Recurrent TMJ Dislocation Managed with Botulinum Toxin Type A Injections in a Pediatric Patient. *Pediatr Dent*. 2015 Jan-Feb;37(1):65-9. PMID: 25685976
17. Liddell A, Perez DE. Temporomandibular joint dislocation. *Oral Maxillofac Surg Clin North Am*. 2015 Feb;27(1):125-36. doi: 10.1016/j.coms.2014.09.009. Review. PMID: 25483448
18. Bouguila J, Khochtali H. [Treatment of recurrent temporomandibular dislocation by displacement of the zygomatic arch: a modification of Gosserez and Dautrey's technique]. *Rev Stomatol Chir Maxillofac Chir Orale*. 2014 Dec;115(6):374-6. doi: 10.1016/j.revsto.2014.10.011. Epub 2014 Nov 14. French. PMID:25458551
19. Gorchynski J, Karabidian E, Sanchez M. The "syringe" technique: a hands-free approach for the reduction of acute nontraumatic temporomandibular dislocations in the emergency department. *J Emerg Med*. 2014 Dec;47(6):676-81. doi: 10.1016/j.jemermed.2014.06.050. Epub 2014 Sep 30. PMID:25278137
- 20. Pentyala S, Mysore P, Moller D, Pentyala S, Kardovich R, Martino A, Proothi M. Temporomandibular joint disorder and inner ear pruritus: resolution by eminectomy. *J Craniofac Surg*. 2014 Sep;25(5):1840-2. doi: 10.1097/SCS.0000000000000512. PMID: 25072971**
- 21. Bayoumi AM, Al-Sebaei MO, Mohamed KM, Al-Yamani AO, Makrami AM. Arthrocentesis followed by intra-articular autologous blood injection for the treatment of recurrent temporomandibular joint dislocation. *Int J Oral Maxillofac Surg*. 2014 Oct;43(10):1224-8. doi: 10.1016/j.ijom.2014.05.004. Epub 2014 Jun 17. PMID: 24951179**
22. Nishigawa K, Nakano M, Ishikawa T, Bando E, Matsuka Y. Case report of recurrent temporomandibular joint open lock associated with abrupt reduction of displaced articular

- disk. *J Prosthodont Res.* 2014 Jul;58(3):184-90. doi: 10.1016/j.jpor.2014.04.001. Epub 2014 Jun 17. PMID: 24951163
23. **Martins WD, Ribas Mde O, Bisinelli J, França BH, Martins G. Recurrent dislocation of the temporomandibular joint: a literature review and two case reports treated with eminectomy. *Cranio.* 2014 Apr;32(2):110-7. Review. PMID: 24839722**
24. **Kahveci R, Simsek ME, Akin S, Ozbek S, Ozgenel GY, Gökmen ZG. Treatment of recurrent temporomandibular joint dislocation. *J Maxillofac Oral Surg.* 2013 Dec;12(4):379-81. doi: 10.1007/s12663-012-0403-5. Epub 2012 Sep 9. PMID: 24431874**
25. **da Costa Ribeiro R, dos santos BJ Jr, Provenzano N, de Freitas PH. Dautrey's procedure: an alternative for the treatment of recurrent mandibular dislocation in patients with pneumatization of the articular eminence. *Int J Oral Maxillofac Surg.* 2014 Apr;43(4):465-9. doi: 10.1016/j.ijom.2013.10.007. Epub 2013 Nov 12. PMID: 24239140**
26. **Mitsukawa N, Morishita T, Saiga A, Kubota Y, Omori N, Akita S, Satoh K. Dislocation of temporomandibular joint: complication of sagittal split ramus osteotomy. *J Craniofac Surg.* 2013 Sep;24(5):1674-5. PMID: 24163864**
27. **Zhou H, Hu K, Ding Y. Modified dextrose prolotherapy for recurrent temporomandibular joint dislocation. *Br J Oral Maxillofac Surg.* 2014 Jan;52(1):63-6. doi: 10.1016/j.bjoms.2013.08.018. Epub 2013 Sep 21. PMID: 24064304**
28. **Ying B, Hu J, Zhu S. Modified Leclerc blocking procedure with miniplates and temporal fascial flap for recurrent temporomandibular joint dislocation. *J Craniofac Surg.* 2013 May;24(3):740-2. doi: 10.1097/SCS.0b013e3182802441. PMID: 23714870**
29. **Hegab AF. Treatment of chronic recurrent dislocation of the temporomandibular joint with injection of autologous blood alone, intermaxillary fixation alone, or both together: a prospective, randomised, controlled clinical trial. *Br J Oral Maxillofac Surg.* 2013 Dec;51(8):813-7. doi: 10.1016/j.bjoms.2013.04.010. Epub 2013 May 16. PMID: 23684013**

30. Çil AS, Bozkurt M, Bozkurt DK. Intrauterine temporomandibular joint dislocation: prenatal sonographic evaluation. *Clin Med Res.* 2014 Sep;12(1-2):58-60. doi: 10.3121/cmr.2013.1148. Epub 2013 May 13. PMID:23669613
31. Sahoo NK, Bhardwaj PK. Radiographic assessment of changes in articular tubercle after Dautrey's procedure. *J Oral Maxillofac Surg.* 2013 Feb;71(2):249-54. doi: 10.1016/j.joms.2012.10.005. PMID: 23351758
32. Gupta D, Rana AS, Verma VK. Treatment of recurrent TMJ dislocation in geriatric patient by autologous blood - A technique revisited. *J Oral Biol Craniofac Res.* 2013 Jan-Apr;3(1):39-41. doi: 10.1016/j.jobcr.2012.11.004. Epub 2012 Nov 20. PMID: 25737879
33. Bekreev VV, Rabinovich SA, Gruzdeva TA, Gorbunova EV. [Hydraulic pressing in complex treatment of recurrent TMJ disc dislocation]. *Stomatologiya (Mosk).* 2012;91(5):34-9. Russian. PMID:23268183
34. Gulses A, Bayar GR, Aydıntug YS, Sencimen M, Erdogan E, Agaoglu R. Histological evaluation of the changes in temporomandibular joint capsule and retrodiscal ligaments following autologous blood injection. *J Craniomaxillofac Surg.* 2013 Jun;41(4):316-20. doi: 10.1016/j.jcms.2012.10.010. Epub 2012 Dec 1. PMID: 23207064
35. Mayrink G, Olate S, Assis A, Sverzut A, de Moraes M. Recurrent mandibular dislocation treated by eminectomy. *J Craniofac Surg.* 2012 Sep;23(5):e516-20. doi: 10.1097/SCS.0b013e31825ab523. PMID: 22976728
36. Taglialatela Scafati C, Taglialatela Scafati S. Role of orthognathic surgery in the treatment of recurrent mandibular dislocation: importance of mandibular ramus inclination. *J Craniofac Surg.* 2012 Sep;23(5):e420-3. doi: 10.1097/SCS.0b013e31825e3ca2. PMID:22976692
37. Torres DE, McCain JP. Arthroscopic electrothermal capsulorrhaphy for the treatment of recurrent temporomandibular joint dislocation. *Int J Oral Maxillofac Surg.* 2012 Jun;41(6):681-9. doi: 10.1016/j.ijom.2012.03.008. Epub 2012 Apr 7. PMID: 22487806

- 38. Candirli C, Yüce S, Cavus UY, Akin K, Cakir B. Autologous blood injection to the temporomandibular joint: magnetic resonance imaging findings. Imaging Sci Dent. 2012 Mar;42(1):13-8. doi: 10.5624/isd.2012.42.1.13. Epub 2012 Mar 22. PMID: 22474643**
39. Chhabra S, Chhabra N. Recurrent bilateral TMJ dislocation in a 20-month-old child: a rare case presentation. J Indian Soc Pedod Prev Dent. 2011 Dec;29(6 Suppl 2):S104-6. doi: 10.4103/0970-4388.90758. PMID: 22169834
- 40. Candrl C, Yüce S, Yldrm S, Sert H. Histopathologic evaluation of autologous blood injection to the temporomandibular joint. J Craniofac Surg. 2011 Nov;22(6):2202-4. doi: 10.1097/SCS.0b013e3182326f99. PMID: 22134254**
41. Kotimäki J, Saarinen A. [Treatment of recurrent dislocation of the temporomandibular joint with botulinum toxin: an alternative approach]. Duodecim. 2011;127(19):2088-91. Finnish. PMID: 22073541
42. Undt G. Temporomandibular joint eminectomy for recurrent dislocation. Atlas Oral Maxillofac Surg Clin North Am. 2011 Sep;19(2):189-206. doi: 10.1016/j.cxom.2011.05.005. No abstract available. PMID: 21878252
43. Akinbami BO. Evaluation of the mechanism and principles of management of temporomandibular joint dislocation. Systematic review of literature and a proposed new classification of temporomandibular joint dislocation. Head Face Med. 2011 Jun 15;7:10. doi: 10.1186/1746-160X-7-10. Review. PMID: 21676208
44. Shakya S, Ongole R, Sumanth KN, Denny CE. Chronic bilateral dislocation of temporomandibular joint. Kathmandu Univ Med J (KUMJ). 2010 Apr-Jun;8(30):251-6. PMID: 21209547
- 45. Gadre KS, Kaul D, Ramanojam S, Shah S. Dautrey's procedure in treatment of recurrent dislocation of the mandible. J Oral Maxillofac Surg. 2010 Aug;68(8):2021-4. doi: 10.1016/j.joms.2009.10.015. Epub 2010 May 14. No abstract available. PMID: 20471151**

46. **Vázquez Bouso O, Forteza González G, Mommsen J, Grau VG, Rodríguez Fernández J, Mateos Micas M. Neurogenic temporomandibular joint dislocation treated with botulinum toxin: report of 4 cases. Oral Surg Oral Med Oral Pathol Oral Radiol Endod. 2010 Mar;109(3):e33-7. doi: 10.1016/j.tripleo.2009.10.046. PMID: 20219583**
47. Köhler AA, Helkimo AN, Magnusson T, Hugoson A. Prevalence of symptoms and signs indicative of temporomandibular disorders in children and adolescents. A cross-sectional epidemiological investigation covering two decades. Eur Arch Paediatr Dent. 2009 Nov;10 Suppl 1:16-25. PMID:19863894
48. Lee KH, Chou HJ. An interesting case of recurrent temporomandibular joint dislocation. N Z Dent J. 2009 Dec;105(4):128-30. PMID: 20000192
49. **Daif ET. Autologous blood injection as a new treatment modality for chronic recurrent temporomandibular joint dislocation. Oral Surg Oral Med Oral Pathol Oral Radiol Endod. 2010 Jan;109(1):31-6. doi: 10.1016/j.tripleo.2009.08.002. PMID: 19926503**
50. Sato K, Umeno H, Nakashima T. Conservative treatment for recurrent dislocation of temporomandibular joint. J Laryngol Otol Suppl. 2009;(31):72-4. doi: 10.1017/S0022215109005131. PMID: 19460209
51. **Pinto AS, McVeigh KP, Bainton R. The use of autologous blood and adjunctive 'face lift' bandage in the management of recurrent TMJ dislocation. Br J Oral Maxillofac Surg. 2009 Jun;47(4):323-4. doi: 10.1016/j.bjoms.2009.01.001. Epub 2009 Feb 25. PMID: 19243867**
52. **Machon V, Abramowicz S, Paska J, Dolwick MF. Autologous blood injection for the treatment of chronic recurrent temporomandibular joint dislocation. J Oral Maxillofac Surg. 2009 Jan;67(1):114-9. doi: 10.1016/j.joms.2008.08.044. PMID: 19070756**
53. **Güven O. Management of chronic recurrent temporomandibular joint dislocations: a retrospective study. J Craniomaxillofac Surg. 2009 Jan;37(1):24-9. doi: 10.1016/j.jcms.2008.08.005. Epub 2008 Nov 7. PMID: 18996023**

54. **Güven O. A clinical study on treatment of temporomandibular joint chronic recurrent dislocations by a modified eminoplasty technique. J Craniofac Surg. 2008 Sep;19(5):1275-80. doi: 10.1097/SCS.0b013e31818437b3. PMID: 18812851**
55. **Guarda-Nardini L, Palumbo B, Manfredini D, Ferronato G. Surgical treatment of chronic temporomandibular joint dislocation: a case report. Oral Maxillofac Surg. 2008 May;12(1):43-6. doi: 10.1007/s10006-008-0097-5. PMID: 18600361**
56. **Cascone P, Ungari C, Paparo F, Marianetti TM, Ramieri V, Fatone M. A new surgical approach for the treatment of chronic recurrent temporomandibular joint dislocation. J Craniofac Surg. 2008 Mar;19(2):510-2. doi: 10.1097/SCS.0b013e318163e42f. PMID: 18362734**
57. **Ozcelik TB, Pektas ZO. Management of chronic unilateral temporomandibular joint dislocation with a mandibular guidance prosthesis: a clinical report. J Prosthet Dent. 2008 Feb;99(2):95-100. doi: 10.1016/S0022-3913(08)60024-4. PMID:18262009**
58. **Medra AM, Mahrous AM. Glenotemporal osteotomy and bone grafting in the management of chronic recurrent dislocation and hypermobility of the temporomandibular joint. Br J Oral Maxillofac Surg. 2008 Mar;46(2):119-22. Epub 2007 Nov 1. PMID: 17935842**
59. **Kato T, Shimoyama T, Nasu D, Kaneko T, Horie N, Kudo I. Autologous blood injection into the articular cavity for the treatment of recurrent temporomandibular joint dislocation: a case report. J Oral Sci. 2007 Sep;49(3):237-9. PMID: 17928731**
60. **Stergiou GC, Obwegeser JA, Gröz KW, Zwahlen RA. [Therapy of recurrent fixed anterior TMJ dislocation with mini-plates in an aged patient with other ailments. A case report]. Schweiz Monatsschr Zahnmed. 2007;117(5):523-9. French, German. PMID: 17557644**
61. **Kurita H, Uehara S, Zhao C, Zhiyong Z, Miyazawa H, Koike T, Kurashina K. Baseline clinical and radiographic features are associated with long-term (8 years) signs/symptoms for**

subjects with diseased temporomandibular joint. Dentomaxillofac Radiol. 2007

Mar;36(3):155-9.PMID:17463100

62. Chhabra S, Chhabra N, Gupta P Jr. Recurrent Mandibular Dislocation in Geriatric Patients: Treatment and Prevention by a Simple and Non-invasive Technique. J Maxillofac Oral Surg. 2015 Mar;14(Suppl 1):231-4. doi: 10.1007/s12663-012-0454-7. Epub 2013 Feb 17. PMID: 25838702

- 63. Matsushita K, Abe T, Fujiwara T. OK-432 (Picibanil) sclerotherapy for recurrent dislocation of the temporomandibular joint in elderly edentulous patients: Case reports. Br J Oral Maxillofac Surg. 2007 Sep;45(6):511-3. Epub 2006 Oct 23. PMID: 17056162**

64. Dellon L, Maloney CT Jr. Denervation of the painful temporomandibular joint. J Craniofac Surg. 2006 Sep;17(5):828-32. PMID:17003606

Appendix IV – Included Studies

Articles relating to autologous blood injection:

- **Bayoumi** AM, Al-Sebaei MO, Mohamed KM, Al-Yamani AO, Makrami AM. Arthrocentesis followed by intra-articular autologous blood injection for the treatment of recurrent temporomandibular joint dislocation. *Int J Oral Maxillofac Surg.* 2014 Oct;43(10):1224-8. doi: 10.1016/j.ijom.2014.05.004. Epub 2014 Jun 17. PMID: 24951179
- **Candirli** C, Yüce S, Cavus UY, Akin K, Cakir B. Autologous blood injection to the temporomandibular joint: magnetic resonance imaging findings. *Imaging Sci Dent.* 2012 Mar;42(1):13-8. doi: 10.5624/isd.2012.42.1.13. Epub 2012 Mar 22. PMID: 22474643
- **Candrl** C, Yüce S, Yldrm S, Sert H. Histopathologic evaluation of autologous blood injection to the temporomandibular joint. *J Craniofac Surg.* 2011 Nov;22(6):2202-4. doi: 10.1097/SCS.0b013e3182326f99. PMID: 22134254
- **Coser** R, da Silveira H, Medeiros P, Ritto FG. Autologous blood injection for the treatment of recurrent mandibular dislocation. *Int J Oral Maxillofac Surg.* 2015 Aug;44(8):1034-7. doi: 10.1016/j.ijom.2015.05.004. Epub 2015 May 26. PMID: 26022511
- **Daif** ET. Autologous blood injection as a new treatment modality for chronic recurrent temporomandibular joint dislocation. *Oral Surg Oral Med Oral Pathol Oral Radiol Endod.* 2010 Jan;109(1):31-6. doi: 10.1016/j.tripleo.2009.08.002. PMID: 19926503
- **Gulses** A, Bayar GR, Aydintug YS, Sencimen M, Erdogan E, Agaoglu R. Histological evaluation of the changes in temporomandibular joint capsule and retrodiscal ligaments following autologous blood injection. *J Craniomaxillofac Surg.* 2013 Jun;41(4):316-20. doi: 10.1016/j.jcms.2012.10.010. Epub 2012 Dec 1. PMID: 23207064
- **Gupta** D, Rana AS, Verma VK. Treatment of recurrent TMJ dislocation in geriatric patient by autologous blood - A technique revisited. *J Oral Biol Craniofac Res.* 2013 Jan-Apr;3(1):39-41. doi: 10.1016/j.jobcr.2012.11.004. Epub 2012 Nov 20. PMID: 25737879

- **Hegab** AF. Treatment of chronic recurrent dislocation of the temporomandibular joint with injection of autologous blood alone, intermaxillary fixation alone, or both together: a prospective, randomised, controlled clinical trial. *Br J Oral Maxillofac Surg.* 2013 Dec;51(8):813-7. doi: 10.1016/j.bjoms.2013.04.010. Epub 2013 May 16. PMID: 23684013
- **Kato** T, Shimoyama T, Nasu D, Kaneko T, Horie N, Kudo I. Autologous blood injection into the articular cavity for the treatment of recurrent temporomandibular joint dislocation: a case report. *J Oral Sci.* 2007 Sep;49(3):237-9. PMID: 17928731
- **Machon** V, Abramowicz S, Paska J, Dolwick MF. Autologous blood injection for the treatment of chronic recurrent temporomandibular joint dislocation. *J Oral Maxillofac Surg.* 2009 Jan;67(1):114-9. doi: 10.1016/j.joms.2008.08.044. PMID: 19070756
- **Pinto** AS, McVeigh KP, Bainton R. The use of autologous blood and adjunctive 'face lift' bandage in the management of recurrent TMJ dislocation. *Br J Oral Maxillofac Surg.* 2009 Jun;47(4):323-4. doi: 10.1016/j.bjoms.2009.01.001. Epub 2009 Feb 25. PMID: 19243867
- **Varedi** P, Bohului B. Erratum to: Autologous blood injection for treatment of chronic recurrent TMJ dislocation: is it successful? Is it safe enough? A systematic review. *Oral Maxillofac Surg.* 2015 Sep;19(3):329-31. doi: 10.1007/s10006-015-0508-3. No abstract available. PMID: 26004293

Articles relating to botulinum toxin:

- **Oztel** M, Bilski WM, Bilski A. Botulinum toxin used to treat recurrent dislocation of the temporomandibular joint in a patient with osteoporosis. *Br J Oral Maxillofac Surg.* 2016 May 30. pii: S0266-4356(16)30094-8. doi: 10.1016/j.bjoms.2016.05.012. [Epub ahead of print] PMID: 27256802
- **Vázquez** Bouso O, Forteza González G, Mommsen J, Grau VG, Rodríguez Fernández J, Mateos Micas M. Neurogenic temporomandibular joint dislocation treated with botulinum toxin:

report of 4 cases. Oral Surg Oral Med Oral Pathol Oral Radiol Endod. 2010 Mar;109(3):e33-7.

doi: 10.1016/j.tripleo.2009.10.046. PMID: 20219583

Articles relating other modes of conservative/minimally invasive management:

- **Matsushita** K, Abe T, Fujiwara T. OK-432 (Picibanil) sclerotherapy for recurrent dislocation of the temporomandibular joint in elderly edentulous patients: Case reports. Br J Oral Maxillofac Surg. 2007 Sep;45(6):511-3. Epub 2006 Oct 23. PMID: 17056162
- **Torres** DE, McCain JP. Arthroscopic electrothermal capsulorrhaphy for the treatment of recurrent temporomandibular joint dislocation. Int J Oral Maxillofac Surg. 2012 Jun;41(6):681-9. doi: 10.1016/j.ijom.2012.03.008. Epub 2012 Apr 7. PMID: 22487806
- **Zhou** H, Hu K, Ding Y. Modified dextrose prolotherapy for recurrent temporomandibular joint dislocation. Br J Oral Maxillofac Surg. 2014 Jan;52(1):63-6. doi: 10.1016/j.bjoms.2013.08.018. Epub 2013 Sep 21. PMID: 24064304

Articles relating to eminectomy

- **Cascone** P, Ungari C, Paparo F, Marianetti TM, Ramieri V, Fatone M. A new surgical approach for the treatment of chronic recurrent temporomandibular joint dislocation. J Craniofac Surg. 2008 Mar;19(2):510-2. doi: 10.1097/SCS.0b013e318163e42f. PMID: 18362734
- **Martins** WD, Ribas Mde O, Bisinelli J, França BH, Martins G. Recurrent dislocation of the temporomandibular joint: a literature review and two case reports treated with eminectomy. Cranio. 2014 Apr;32(2):110-7. Review. PMID: 24839722
- **Mayrink** G, Olate S, Assis A, Sverzut A, de Moraes M. Recurrent mandibular dislocation treated by eminectomy. J Craniofac Surg. 2012 Sep;23(5):e516-20. doi: 10.1097/SCS.0b013e31825ab523. PMID: 22976728

- **Pentyala S**, Mysore P, Moller D, Pentyala S, Kardovich R, Martino A, Proothi M. Temporomandibular joint disorder and inner ear pruritus: resolution by eminectomy. J Craniofac Surg. 2014 Sep;25(5):1840-2. doi: 10.1097/SCS.0000000000000512. PMID: 25072971

Articles relating to Eminoplasty

- **da Costa Ribeiro R**, dos santos BJ Jr, Provenzano N, de Freitas PH. Dautrey's procedure: an alternative for the treatment of recurrent mandibular dislocation in patients with pneumatization of the articular eminence. Int J Oral Maxillofac Surg. 2014 Apr;43(4):465-9. doi: 10.1016/j.ijom.2013.10.007. Epub 2013 Nov 12. PMID: 24239140
- **Gadre KS**, Kaul D, Ramanojam S, Shah S. Dautrey's procedure in treatment of recurrent dislocation of the mandible. J Oral Maxillofac Surg. 2010 Aug;68(8):2021-4. doi: 10.1016/j.joms.2009.10.015. Epub 2010 May 14. No abstract available. PMID: 20471151
- **Guarda-Nardini L**, Palumbo B, Manfredini D, Ferronato G. Surgical treatment of chronic temporomandibular joint dislocation: a case report. Oral Maxillofac Surg. 2008 May;12(1):43-6. doi: 10.1007/s10006-008-0097-5. PMID: 18600361
- **Güven O**. A clinical study on treatment of temporomandibular joint chronic recurrent dislocations by a modified eminoplasty technique. J Craniofac Surg. 2008 Sep;19(5):1275-80. doi: 10.1097/SCS.0b013e31818437b3. PMID: 18812851
- **Medra AM**, Mahrous AM. Glenotemporal osteotomy and bone grafting in the management of chronic recurrent dislocation and hypermobility of the temporomandibular joint. Br J Oral Maxillofac Surg. 2008 Mar;46(2):119-22. Epub 2007 Nov 1. PMID: 17935842
- **Sahoo NK**, Bhardwaj PK. Radiographic assessment of changes in articular tubercle after Dautrey's procedure. J Oral Maxillofac Surg. 2013 Feb;71(2):249-54. doi: 10.1016/j.joms.2012.10.005. PMID: 23351758

- **Ying B**, Hu J, Zhu S. Modified Leclerc blocking procedure with miniplates and temporal fascial flap for recurrent temporomandibular joint dislocation. J Craniofac Surg. 2013 May;24(3):740-2. doi: 10.1097/SCS.0b013e3182802441. PMID: 23714870

Articles relating to other modes of surgical management

- **de Freitas Silva L**, Ribeiro NR, Faverani LP, Gondim RF, Maia RN. Treatment of Chronic Recurrent Temporomandibular Joint Dislocation. J Craniofac Surg. 2016 May;27(3):815. doi: 10.1097/SCS.0000000000002424. PMID: 27159865
- **Güven O**. Management of chronic recurrent temporomandibular joint dislocations: a retrospective study. J Craniomaxillofac Surg. 2009 Jan;37(1):24-9. doi: 10.1016/j.jcms.2008.08.005. Epub 2008 Nov 7. PMID: 18996023
- **Kahveci R**, Simsek ME, Akın S, Ozbek S, Ozgenel GY, Gökmen ZG. Treatment of recurrent temporomandibular joint dislocation. J Maxillofac Oral Surg. 2013 Dec;12(4):379-81. doi: 10.1007/s12663-012-0403-5. Epub 2012 Sep 9. PMID: 24431874
- **Taglialatela Scafati C**, Taglialatela Scafati S. Role of orthognathic surgery in the treatment of recurrent mandibular dislocation: importance of mandibular ramus inclination. J Craniofac Surg. 2012 Sep;23(5):e420-3. doi: 10.1097/SCS.0b013e31825e3ca2. PMID:22976692
- **Zachariah T**, Neelakandan RS, Ahamed MI. Disc Anchoring with an Orthodontic Mini-Screw for Chronic Meniscocondylar Dislocation of TMJ. J Maxillofac Oral Surg. 2015 Sep;14(3):735-44. doi: 10.1007/s12663-014-0729-2. Epub 2014 Dec 6. PMID: 26225070

Non-clinical articles

- **de Almeida VL**, Vitorino Nde S, Nascimento AL, da Silva Júnior DC, de Freitas PH. Stability of treatments for recurrent temporomandibular joint luxation: a systematic review. Int J Oral

Maxillofac Surg. 2016 Mar;45(3):304-7. doi: 10.1016/j.ijom.2015.10.022. Epub 2015 Nov 23.

Review. PMID: 26616027

- **Liddell** A, Perez DE. Temporomandibular joint dislocation. Oral Maxillofac Surg Clin North Am. 2015 Feb;27(1):125-36. doi: 10.1016/j.coms.2014.09.009. Review. PMID: 25483448
- **Murakami** K, Hori S, Yamaguchi Y, Mercuri LG, Harayama N, Maruo S, Takahashi T. Synovial plicae and temporomandibular joint disorders: surgical findings. J Oral Maxillofac Surg. 2015 May;73(5):827-33. doi: 10.1016/j.joms.2014.12.018. Epub 2014 Dec 24. PMID: 25795190
- **Sharma** NK, Singh AK, Pandey A, Verma V, Singh S. Temporomandibular joint dislocation. Natl J Maxillofac Surg. 2015 Jan-Jun;6(1):16-20. doi: 10.4103/0975-5950.168212. Review. PMID: 26668447
- **Undt** G. Temporomandibular joint eminectomy for recurrent dislocation. Atlas Oral Maxillofac Surg Clin North Am. 2011 Sep;19(2):189-206. doi: 10.1016/j.cxom.2011.05.005. No abstract available. PMID: 21878252

Appendix V – Summary of Included Appraisals

Appraisal Questions	Yes	Can't Tell	No
1. Did the study address a clearly focused question / issue?			
2. Is the research method (study design) appropriate for answering the research question?			
3. Are both the setting and the subject's representative with regard to the population to which the findings will be referred?			
4. Is the researcher's perspective clearly described and taken into account?			
5. Are the methods for collecting data clearly described?			
6. Are the methods for analysing the data likely to be valid and reliable? Are quality control measures used?			
7. Was the analysis repeated by more than one researcher to ensure reliability?			
8. Are the results credible, and if so, are they relevant for practice?			
9. Are the conclusions drawn justified by the results?			
10. Are the findings of the study transferable to other settings?			

Adapted from Crombie, The Pocket Guide to Critical Appraisal; the critical appraisal approach used by the Oxford Centre for Evidence Medicine, checklists of the Dutch Cochrane Centre, BMJ editor's checklists and the checklists of the EPPI Centre.

Study defined by first author and year of publication.

Articles relating to minimally invasive management

Appraisal Question	1	2	3	4	5	6	7	8	9	10
Study										
Autologous Blood										
Bayoumi 2014	Y	Y	Y	Y	Y	C	C	N	N	N
Candirli 2012	Y	Y	Y	Y	Y	Y	N	Y	N	Y
Candirli 2011	Y	Y	N	Y	Y	N	N	C	Y	N
Coser 2011	Y	Y	Y	Y	Y	N	N	C	C	Y
Daif 2010	Y	Y	Y	Y	Y	Y	C	Y	Y	Y
Gulses 2012	Y	Y	N	Y	Y	Y	Y	Y	Y	Y
Gupta 2012	Y	N	Y	Y	Y	N	N	N	N	Y
Hegab 2013	Y	Y	Y	Y	Y	Y	Y	Y	Y	Y
Kato 2007	Y	N	Y	Y	Y	N	N	N	N	Y
Machon 2009	Y	Y	Y	Y	Y	Y	N	Y	Y	Y
Pinto 2009	Y	N	Y	Y	Y	N	N	N	N	Y
Varedi 2015	Y	Y	Y	Y	Y	C	C	Y	Y	Y
Botulinum Toxin										
Oztel 2016	Y	N	N	Y	C	N	N	C	C	Y
Vazquez 2010	Y	Y	Y	Y	Y	N	N	N	N	Y
Other Modes										
Matsushita 2006	Y	N	Y	Y	Y	N	N	Y	N	Y
Torres 2012	Y	Y	Y	Y	Y	N	N	Y	Y	Y
Zhou 2014	Y	Y	Y	Y	Y	Y	N	Y	Y	Y

Legend		
Y = Yes	C = Can't Tell	N = No

Articles relating to surgical management

Appraisal Question	1	2	3	4	5	6	7	8	9	10
Study										
Eminectomy										
Cascone 2008	Y	N	Y	Y	Y	N	N	N	Y	Y
Martins 2014	Y	N	Y	Y	Y	N	N	Y	Y	Y
Mayrink 2012	Y	N	Y	Y	Y	N	N	Y	Y	Y
Pentyala 2014	C	C	Y	Y	N	N	N	C	C	Y
Eminoplasty										
Da Costa 2013	Y	N	Y	Y	Y	N	N	Y	Y	Y
Gadre 2010	Y	Y	Y	Y	Y	N	N	Y	Y	Y
Guarda-Nardini 2008	Y	N	Y	Y	Y	N	N	N	Y	Y
Guyen 2008	Y	Y	Y	Y	Y	N	N	Y	Y	Y
Medra 2008	Y	Y	Y	Y	Y	N	N	Y	Y	Y
Sahoo 2013	Y	Y	Y	Y	Y	N	N	N	Y	Y
Ying 2013	Y	Y	Y	Y	Y	N	N	Y	Y	Y
Other Modes										
De Freitas 2006	N	N	C	Y	N	C	N	C	C	C
Guyen 2009	Y	Y	Y	Y	Y	Y	N	Y	Y	Y
Kahveci 2013	Y	Y	Y	Y	Y	N	N	Y	Y	Y
Tagliatela 2012	Y	Y	Y	Y	Y	Y	N	Y	Y	Y
Zachariah 2015	Y	C	C	Y	Y	N	N	C	C	Y

Legend		
Y = Yes	C = Can't Tell	N = No

Appendix VI – Excluded Studies with Justification

1. Sato K, Umeno H, Nakashima T. Conservative treatment for recurrent dislocation of temporomandibular joint. *J Laryngol Otol Suppl.* 2009;(31):72-4.
 - **Not available in English (Japanese)**
2. Stergiou GC, Obwegeser JA, Gröz KW, Zwahlen RA. Therapy of recurrent fixed anterior TMJ dislocation with mini-plates in an aged patient with other ailments. A case report]. *Schweiz Monatsschr Zahnmed.* 2007;117(5):523-9.
 - **Not available in English (German)**
3. Kotimäki J, Saarinen A. [Treatment of recurrent dislocation of the temporomandibular joint with botulinum toxin: an alternative approach]. *Duodecim.* 2011;127(19):2088-91.
Finnish. PMID: 22073541
 - **Not available in English (Finnish)**
4. Wu D, Hu K, Zhou H. *Zhonghua Kou Qiang Yi Xue Za Zhi.* [Modified dextrose prolotherapy for the treatment of recurrent temporomandibular joint dislocation]. 2015 Feb;50(2):113-4. Chinese. No abstract available. PMID:25908197
 - **Not available in English (Chinese)**
5. Bouguila J, Khochtali H. [Treatment of recurrent temporomandibular dislocation by displacement of the zygomatic arch: a modification of Gosserez and Dautrey's technique]. *Rev Stomatol Chir Maxillofac Chir Orale.* 2014 Dec;115(6):374-6. doi: 10.1016/j.revsto.2014.10.011. Epub 2014 Nov 14. French. PMID:25458551
 - **Not available in English (French)**
6. Bekreev VV, Rabinovich SA, Gruzdeva TA, Gorbunova EV. [Hydraulic pressing in complex treatment of recurrent TMJ disc dislocation]. *Stomatologiya (Mosk).* 2012;91(5):34-9. Russian. PMID:23268183
 - **Not available in English (Russian)**

7. Chhabra S, Chhabra N. Recurrent bilateral TMJ dislocation in a 20-month-old child: a rare case presentation. J Indian Soc Pedod Prev Dent. 2011 Dec;29(6 Suppl 2):S104-6. doi: 10.4103/0970-4388.90758. PMID: 22169834
 - **Unrelated to inclusion criteria. Refers to 2 episodes of acute dislocation secondary to trauma.**
8. Chhabra S, Chhabra N, Gupta P Jr. Recurrent Mandibular Dislocation in Geriatric Patients: Treatment and Prevention by a Simple and Non-invasive Technique. J Maxillofac Oral Surg. 2015 Mar;14(Suppl 1):231-4. doi: 10.1007/s12663-012-0454-7. Epub 2013 Feb 17. PMID: 25838702
 - **Unrelated to inclusion criteria. Refers to chronic dislocation in elderly.**
9. Gilon Y, Johnen J, Nizet JL. How I Treat. An Anterior Temporomandibular Joint Dislocation. Rev Med Liege. 2015 Sep;70(9):411-4. French. PMID:26638440
 - **Unrelated to inclusion criteria. Refers to acute dislocation, not recurrent.**
10. Bindra A, Bithal P, Sokhal N, Arora A. Pain relief can be painful. Indian J Palliat Care. 2015 Sep-Dec;21(3):355-7. doi: 10.4103/0973-1075.164913. PMID: 26600706 Free PMC Article
 - **Unrelated to inclusion criteria.**
11. Erratum to: Autologous blood injection for treatment of chronic recurrent TMJ dislocation: is it successful? Is it safe enough? A systematic review. Varedi P, Bohluli B. Oral Maxillofac Surg. 2015 Sep;19(3):329-31. doi: 10.1007/s10006-015-0508-3. No abstract available. PMID: 26004293
 - **Erratum to paper included in study.**
12. Ogawa M, Kanbe T, Kano A, Kubota F, Makiguchi T, Miyazaki H, Yokoo S. Conservative reduction by lever action of chronic bilateral mandibular condyle dislocation. Cranio. 2015 Apr;33(2):142-7. doi: 10.1179/0886963414Z.00000000041. Epub 2014 Apr 14. PMID:25919752

- **Unrelated to inclusion criteria. Discusses management of chronic protracted temporomandibular joint dislocation**
13. Pradhan L, Jaisani MR, Sagtani A, Win A. Conservative Management of Chronic TMJ Dislocation: An Old Technique Revived. *J Maxillofac Oral Surg.* 2015 Mar;14(Suppl 1):267-70. doi: 10.1007/s12663-013-0476-9. Epub 2013 Feb 1. PMID:25838707
- **Unrelated to inclusion criteria. Discusses management of chronic protracted temporomandibular joint dislocation.**
14. Gorchynski J, Karabidian E, Sanchez M. The "syringe" technique: a hands-free approach for the reduction of acute nontraumatic temporomandibular dislocations in the emergency department. *J Emerg Med.* 2014 Dec;47(6):676-81. doi: 10.1016/j.jemermed.2014.06.050. Epub 2014 Sep 30. PMID:25278137
- **Unrelated to inclusion criteria. Discusses management of acute temporomandibular joint dislocation.**
15. Mitsukawa N, Morishita T, Saiga A, Kubota Y, Omori N, Akita S, Satoh K. Dislocation of temporomandibular joint: complication of sagittal split ramus osteotomy. *J Craniofac Surg.* 2013 Sep;24(5):1674-5. PMID:24163864
- **Unrelated to inclusion criteria. Discusses acute temporomandibular joint dislocation as a consequence of orthognathic surgery**
16. Çil AS, Bozkurt M, Bozkurt DK. Intrauterine temporomandibular joint dislocation: prenatal sonographic evaluation. *Clin Med Res.* 2014 Sep;12(1-2):58-60. doi: 10.3121/cmr.2013.1148. Epub 2013 May 13. PMID:23669613
- **Unrelated to inclusion criteria. Discusses congenital temporomandibular joint dislocation.**
17. Akinbami BO. Evaluation of the mechanism and principles of management of temporomandibular joint dislocation. Systematic review of literature and a proposed new

classification of temporomandibular joint dislocation. Head Face Med. 2011 Jun 15;7:10.

doi: 10.1186/1746-160X-7-10. Review. PMID: 21676208

- **Unrelated to inclusion criteria. Discusses diagnosis and classification of temporomandibular joint dislocation rather than surgical management.**

18. Shakya S, Ongole R, Sumanth KN, Denny CE. Chronic bilateral dislocation of temporomandibular joint. Kathmandu Univ Med J (KUMJ). 2010 Apr-Jun;8(30):251-6. PMID:21209547

- **Unrelated to inclusion criteria. Discusses chronic protracted temporomandibular joint dislocation**

19. Köhler AA, Helkimo AN, Magnusson T, Hugoson A. Prevalence of symptoms and signs indicative of temporomandibular disorders in children and adolescents. A cross-sectional epidemiological investigation covering two decades. Eur Arch Paediatr Dent. 2009 Nov;10 Suppl 1:16-25. PMID:19863894

- **Unrelated to inclusion criteria. Discusses presentation and diagnosis of paediatric temporomandibular joint dislocation.**

20. Ozcelik TB, Pektas ZO. Management of chronic unilateral temporomandibular joint dislocation with a mandibular guidance prosthesis: a clinical report. J Prosthet Dent. 2008 Feb;99(2):95-100. doi: 10.1016/S0022-3913(08)60024-4. PMID:18262009

- **Unrelated to inclusion criteria. Discusses management of chronic protracted temporomandibular joint dislocation.**

21. Kurita H, Uehara S, Zhao C, Zhiyong Z, Miyazawa H, Koike T, Kurashina K. Baseline clinical and radiographic features are associated with long-term (8 years) signs/symptoms for subjects with diseased temporomandibular joint. Dentomaxillofac Radiol. 2007 Mar;36(3):155-9. PMID:17463100

- **Unrelated to inclusion criteria. Discusses presentation of patients with temporomandibular dysfunction.**

22. Dellon L, Maloney CT Jr. Denervation of the painful temporomandibular joint. J Craniofac Surg. 2006 Sep;17(5):828-32. PMID:17003606
- **Unrelated to inclusion criteria. Discusses management of patients with temporomandibular dysfunction.**
23. Le Goff F, Lefaucheur R, Fetter D, Rouille A, Maltête D. Recurrent Bilateral Dislocation of the Temporomandibular Joint Induced by Clonazepam in a Parkinsonian Patient. Clin Neuropharmacol. 2016 Jan-Feb;39(1):66. doi: 10.1097/WNF.0000000000000124. PMID: 26757315
- **Unrelated to inclusion criteria. Discusses two episodes of acute dislocation**
24. Nishigawa K, Nakano M, Ishikawa T, Bando E, Matsuka Y. Case report of recurrent temporomandibular joint open lock associated with abrupt reduction of displaced articular disk. J Prosthodont Res. 2014 Jul;58(3):184-90. doi: 10.1016/j.jpor.2014.04.001. Epub 2014 Jun 17. PMID: 24951163
- **Unrelated to inclusion criteria. Discusses acute dislocation.**
25. Lee KH, Chou HJ. An interesting case of recurrent temporomandibular joint dislocation. N Z Dent J. 2009 Dec;105(4):128-30. PMID: 20000192
- **Excluded. Full text not available**
26. Stark TR, Perez CV, Okeson JP. Recurrent TMJ Dislocation Managed with Botulinum Toxin Type A Injections in a Pediatric Patient. Pediatr Dent. 2015 Jan-Feb;37(1):65-9. PMID: 25685976
- **Excluded. Full text not available**

Appendix VII – Data from Included Studies**A – Minimally Invasive Techniques**

Authors	Year	Journal	Type	Case Number	Modality	Follow up
Oztel M et al	2016	BJOMS	Case report	1	Botox	6 months
Coser R	2015	IJOMS	Case series	11	Blood	35 months
Varedi P	2015	Oral Maxillofac Surg	Systematic Review	-	Blood	-
Stark TR	2015	Pediatr Dent	Case Report	1	Botox	-
Bayoumi AM	2014	IJOMS	Case Series	15	Blood	1 year
Zhou H et al	2014	BJOMS	Retrospective review	45	50% dextrose	1 year
Hegab AF	2013	BJOMS	RCT	48	Blood	1 year
Gupta D	2013	J Oral Biol Craniofac Res	Case report	1	Blood	8 months
Gulses A et al	2013	J Craniomaxillofac Surg	Clinical Trial (animal)	16	Blood	4 weeks
Torres DE	2012	IJOMS	Case Series	11	Electrothermal Capsulorrhaphy	6 years
Candirli C et al	2012	Imaging Sci Dent	Prospective	14	Blood	1 month
Candirli C et al	2011	J Craniofac Surg	Clinical Trial (animal)	8	Blood	1 month
Vazquez BO et al	2010	OOOOE	Case Series	4	Botox	-
Daif ET	2010	OOOOE	RCT	30	Blood	1 year
Sato K et al	2009	J Laryngol Otol Suppl	Case series	5	IMF	2-5 years
Pinto AS	2009	JOMS	Case Series	1	Blood	-
Machon V	2009	JOMS	Case Series	25	Blood	1 year
Kato T et al	2007	J Oral Sci	Case Report	1	Blood	5 months
Matsushita K et al	2007	BJOMS	Case Series	2	OK-432	-

B – Surgical Management

Authors	Year	Journal	Type	Case number	Modality	Follow up
De Freitas Silva et al	2016	J Craniofac Surg	Letter to Editor	1	Disc plication	1 year
Zachariah et al	2015	JOMS	Case series	17	Disc plication	1 year
Pentyala S et al	2014	J Craniofac Surg	Case Report	1	Eminectomy	-
Martins WD	2014	Cranio	Case Report	2	Eminectomy	1 year
Kahveci R et al	2013	JOMS	Retrospective analysis	73	Eminoplasty	30 months
Da Costa Ribeiro R	2014	IJOMS	Case Series	2	Eminoplasty	-
Ying B et al	2013	J Craniofac Surg	Case Series	7	Eminoplasty	2 years
Sahoo NK	2013	JOMS	Case Series	10	Eminoplasty	1 year
Mayrink G	2012	J Craniofac Surg	Case Series	3	Eminectomy	5 years
Taglialatela SC	2012	J Craniofac Surg	Case Series	7	Orthognathic Surgery	1 year
Gadre KS	2010	JOMS	Retrospective	20	Eminoplasty	3 years
Güven O	2009	J Craniomaxillofac Surg	Retrospective	19	Eminectomy and Eminoplasty	1-12 years
Güven O	2008	J Craniofac Surg	Case Series	12	Eminoplasty	-
Guarda-Nardini L et al	2008	Oral Maxillofac Surg	Case Report	1	Eminoplasty	8 months
Cascone P et al	2008	J Craniofac Surg	Case Report	1	Eminectomy	-
Medra AM et al	2008	BJOMS	Prospective Study	60	Eminoplasty	1-8 years
Stergiou GC et al	2007	Schweiz Monatsschr Zahnmed	Case Report	1	Eminoplasty	-

Appendix VIII – Questionnaire used in Retrospective Patient Analysis

TMJ Surgery
Quality of Life Questionnaire
TMJ-S-QoL

Patient Name: _____

Consent for questionnaire to be included in de-identified research

General Questions:

1. Before my surgery my Jaw dislocation occurred:
 - a. Only during wide opening
 - b. Spontaneously, at any time regardless of what I was doing
2. How many times did your jaw dislocate in the 12 months prior to your surgery?
 - a. 1-3 times
 - b. 4-6 times
 - c. More than 6 times
3. How did you manage to reduce your dislocated jaw?
 - a. By myself
 - b. With help from a friend or relative
 - c. I had to go to hospital
4. Have you had any jaw dislocations since your surgery?
 - a. No
 - b. Yes, but not as often or severe as before the surgery

- c. Yes, the same as before the surgery (i.e. the surgery made no difference)
- d. Yes, much worse than before the surgery (i.e. the surgery made things worse)

TMJ-S-QOL

A. Pain

- a. I have no pain
- b. There is mild pain but I do not need medication
- c. I have moderate pain which requires regular analgesics e.g. paracetamol
- d. I have severe pain controlled only by strong analgesics e.g. panadeine forte
- e. I have severe pain which is not controlled by analgesics

B. Diet and Chewing

- a. I can chew and chew whatever I like
- b. I can chew most things except tough foods like steak and apple
- c. I only stick to soft foods such as pasta and soft bread
- d. I need to cut up all food into small pieces
- e. I can only eat food that has been put through the blender

C. Speech

- a. My speech is normal
- b. I have difficulty in saying some words
- c. I have difficulty in being understood over the telephone
- d. Only my friends and family can understand me
- e. I cannot be understood at all

D. Activity

- a. I am as active as I have ever been
- b. There are times where I can't keep up my old pace, but not often
- c. I am often tired and have slowed down my activities though I still get out

- d. I don't go out very often because I don't have the strength
- e. I am usually in bed or a chair and don't leave home

E. Recreation

- a. There are no limitations to recreation at home or away from home
- b. There are a few things I can't do but I still get out and enjoy life
- c. There are many times where I wish I could get out more, but I am not up to it
- d. There are severe limitations to what I can do, mostly I stay at home and watch TV
- e. I can't do anything enjoyable

F. Mood

- a. My mood is excellent and unaffected by my TMJ disorder
- b. My mood is generally good and only occasionally affected by my TMJ disorder
- c. I am neither in a good mood nor depressed about my TMJ disorder
- d. I am somewhat depressed about my TMJ disorder
- e. I am extremely depressed about my TMJ disorder

G. Anxiety

- a. I am not anxious about my TMJ disorder
- b. I am a little anxious about my TMJ disorder but I am coping
- c. I am very anxious about my TMJ disorder and am finding it difficult coping
- d. I am severely anxious about my TMJ disorder and am not coping at all

H. Which issues have been uppermost in your mind during the past month (circle up to 3 answers)

- a. Nothing
- b. Pain
- c. Diet and chewing
- d. Speech
- e. Activity levels

- f. Recreation
 - g. Mood
 - h. Anxiety
- I. Compared to the month before you had your TMJ surgery, how would you rate your overall health-related quality of life?
- a. Much better
 - b. Somewhat better
 - c. About the same
 - d. Somewhat worse
 - e. Much worse
- J. In general, would you say your health related quality of life has been:
- a. Excellent
 - b. Very good
 - c. Good
 - d. Fair
 - e. Poor
- K. If a relative or friend had experienced TMJ problems very similar to what you had, would you:
- a. Recommend TMJ surgery as the primary treatment
 - b. Recommend TMJ surgery only if other measures such as physiotherapy and splint therapy and medications fail
 - c. Recommend TMJ surgery only as a very last resort
 - d. Do not recommend TMJ surgery at all

Thank you very much for completing this questionnaire

Appendix IX – List of Abbreviations

ABI – autologous blood injection

CT – computerised tomography

EDTA - ethylenediaminetetraacetic acid

EMG – electromyography

Hol-YAG – Holmium:yttrium-aluminium-garnet

HREC – Human Research and Ethics Committee

IMF – intermaxillary fixation

MeSH – Medical Subject Headings

MMO – maximum mouth opening

MRI – Magnetic Resonance Imaging

OMFS – Oral and Maxillofacial Surgery

OPG – orthopantomogram

PRISMA – Preferred Reporting Items for Systematic Reviews and Meta-Analysis

PT – Pericapsular Tissues

SJS – Superior Joint Space

QoL – Quality of Life

TMJ – Temporomandibular Joint

Appendix X – Publication: Surgical management of recurrent dislocation of the temporomandibular joint: a new treatment protocol

Citation:

Tocaciu S, McCullough MJ, Dimitroulis G. Surgical management of recurrent dislocation of the temporomandibular joint: a new treatment protocol. Br J Oral Maxillofac Surg. 2018; 56(10):936-940

DOI:

10.1016/j.bjoms.2018.10.274

PMID:

30409539

Available online at www.sciencedirect.com

ScienceDirect

British Journal of Oral and Maxillofacial Surgery 56 (2018) 936–940

BRITISH
Journal of
Oral and
Maxillofacial
Surgerywww.bjoms.com

Surgical management of recurrent dislocation of the temporomandibular joint: a new treatment protocol

S. Tocaciu^{a,*}, M.J. McCullough^b, G. Dimitroulis^a^a Oral and Maxillofacial Unit, St Vincent's Hospital Melbourne, Australia^b Oral Medicine Unit, Melbourne Dental School, University of Melbourne, Australia

Accepted 22 October 2018

Available online 6 November 2018

Abstract

Recurrent dislocation of the temporomandibular joint (TMJ) is rare. It is distinct from acute or chronic dislocation and is associated with considerable morbidity and deterioration in quality of life. To formulate a practical surgical treatment algorithm, we retrospectively reviewed the management and long-term outcomes of 14 patients who presented to a single hospital department over a period of six years (2010–2016), and collected data on demographics, clinical features, operation, and outcome. Patients were followed up for a minimum of 12 months and a maximum of seven years. Results showed effective long-term resolution of symptoms after a combination of eminectomy and disc plication (meniscopexy). Patients whose symptoms had resulted from dystonia of the lateral pterygoid muscle also benefitted from additional lateral pterygoid myotomy. A combination of eminectomy and disc plication (meniscopexy) effectively provides successful long-term outcomes in this group of patients.

© 2018 The British Association of Oral and Maxillofacial Surgeons. Published by Elsevier Ltd. All rights reserved.

Keywords: Temporomandibular Joint; Eminectomy; Disc Plication; Lateral Pterygoid; Surgery; recurrent; dislocation; luxation; subluxation

Introduction

Dysfunction of the temporomandibular joint (TMJ) can result in pain and loss of function, which have a detrimental impact on a patient's quality of life (QoL).¹ Recurrent dislocation of the joint causes additional morbidity, as reduction may be needed, and each dislocation can further stretch the ligaments and capsule.²

Dislocation may be acute as a result of trauma or parafunction, or may be chronic.³ Chronic cases result from prolonged dislocation that can be caused by a lax joint capsule because

of age-related degeneration of the joint, anatomical variation of the articular components, or even the extrapyramidal side effects of anti-psychotic drugs such as haloperidol. Recurrent dislocation is defined as repeated acute dislocation of the joint that occurs sporadically over an extended time from many months to years, resulting in a functional deterioration. Between episodes, the condylar head is located in its normal position in the glenoid fossa. This is not the case in patients with a chronic condition.

Dislocation of the condylar head is usually in an anteromedial direction because of the pull from the lateral pterygoid muscle.² This luxation of the condyle anterior to the articular eminence can cause considerable damage to the joint capsule and ligaments.⁴ Stretching of these ligaments outside their normal physiological range of motion activates the golgi tendon organs and muscle spindle cells,⁴ and causes a

* Corresponding author at: Oral and Maxillofacial Unit, The Royal Dental Hospital of Melbourne, 720 Swanston Street, Melbourne, Victoria. Tel.: +61 402220643.

E-mail address: shreyatocaciu@gmail.com (S. Tocaciu).

<https://doi.org/10.1016/j.bjoms.2018.10.274>

0266-4356/© 2018 The British Association of Oral and Maxillofacial Surgeons. Published by Elsevier Ltd. All rights reserved.

reflex muscle contraction and pain.⁵ This further prevents the downward and backward movement that is required for the joint to return to its normal position.⁶

Dislocation can be caused by wide opening, in which the condylar head translates anteriorly to the eminence, or can be spontaneous as a result of aberrant pull from the lateral pterygoid muscle. A diagnosis of dystonia of the lateral pterygoid muscle may be suggested by a neuromuscular medical disorder, or by the nature of the episodes of dislocation, but currently, we know of no conclusive diagnostic test. Patients are often able to describe the cause of their dislocation (wide opening, spontaneous dislocation, or both), and often avoid behaviours that lead to it. This in turn can result in anxiety, which affects their quality of life.

Current treatments for recurrent dislocation include minimally invasive techniques such as injection of autologous blood⁷ or botulinum toxin.⁸ Surgical treatment, such as arthroscopic reshaping of the articular eminence with a diamond bur, has also been described (but currently is not widely used),⁹ as have eminectomy or eminoplasty.¹⁰ In general, surgical methods are considered superior to minimally invasive techniques, which rely largely on the induction of joint fibrosis through the use of blood or sclerosing agents.⁹ All these methods have limitations and, according to Pogrel,⁶ no gold standard treatment has been identified.

The aim of the present study was to assess the long-term outcomes after surgical treatment for recurrent dislocation of the TMJ using a combination of eminectomy and disc plication (meniscopexy). We also describe myotomy of the lateral pterygoid muscle attachment as an additional treatment in cases of dystonia.

Methods

We used the hospital's database, consultants' records, and registrars' logbooks, to identify patients who had surgical treatment for recurrent dislocation of the TMJ. Patients were treated by one oral and maxillofacial surgery (OMFS) consultant surgeon (GD), either in a private hospital (Epworth Freemasons, Melbourne), or a public hospital (St Vincent's Hospital, Melbourne). Those seen in the public health care system were treated in conjunction with an OMFS surgical registrar under the direct supervision of the consultant.

Patients treated between March 2010 and March 2016 (six years) with a follow-up period of at least 12 months, were included. They were all at least 18 years of age at diagnosis, and had had at least six episodes of dislocation requiring medical attention over a 12-month period.

We analysed the patients' characteristics, the presentation and nature of the dislocations, type of operation, and outcome, as well as the functional and psychological impact. All patients completed a standardised and validated TMJ quality of life (QoL) survey.¹

Ethics approval was granted by the Human Research and Ethics Committee, St Vincent's Hospital, Melbourne. All data were collected retrospectively, and were anonymised.

Results

We identified 14 patients (10 female and 4 male), most of whom (n = 11) were aged between 21 and 30 years. Dislocations occurred on wide opening or spontaneously, or both. In most cases they had occurred more than six times a year over a period of three or more years.

Most patients had bilateral dislocation (n = 10). Of the four in whom only one joint was affected, two were of the right and two on the left. Six patients could sometimes reduce the dislocation themselves, but eight always required medical attention, either with or without sedation. Most cases were not painful (n = 12), and were not associated with an alteration in diet (n = 11). On preoperative evaluation, 10 patients had no reduction in maximum mouth opening, although four reported that they avoided certain behaviours. One patient had a history of myotonic dystrophy, which may have directly contributed to her dislocations. Two had previously had minimally invasive treatment (autologous blood injections) that had not been successful.

All patients had eminectomy and disc plication through a preauricular approach. Preoperative computed tomography (CT) excluded pneumatisation or cranialisation of the articular eminence. Eminectomy was done to a depth of 10 – 15 mm with osteotomes and the remaining bony bed smoothed with a diamond file.

We placed two to three 4/0 prolene sutures between the posterior disc and the retrodiscal tissues to limit forward translation of the disc during mandibular opening. No discal tissue was excised. In the four patients whose principle problem was spontaneous dislocation, we combined eminectomy (the gold standard for recurrent dislocation), with lateral pterygoid myotomy, as the efficacy of myotomy alone is currently unknown. We did this to further reduce the risk of recurrence rather than to test a new technique, which may have resulted in the need for repeat arthroplasty. These patients did not have increased postoperative pain, but two reported mouth opening of less than 30 mm at 30 days. The additional procedure did not affect the results of the QoL survey.

We followed up the patients for a minimum of 12 months and a maximum of 67 months (5.6 years). None of them reported recurrence, and 11 were free from pain. Of the three who reported pain, two had mild pain that did not require analgesia, and one required non-prescription analgesia. Most patients (n = 12) had a postoperative mouth opening of more than 40 mm, and all were able to tolerate a full diet. Overall, they were satisfied with their treatment (Table 1).

Patients were asked to complete a postoperative questionnaire that was based on a previously validated TMJ-specific QoL survey.¹ Eleven responded, and they all reported no pain

Table 1

Postoperative findings. All patients had no ongoing dislocation or deviation on opening; they could eat a full diet, and were satisfied with their treatment.

Case No.	Pain	Mouth opening (mm)	Follow up (months)
1	No	>40	12
2	No	>25	12
3	No	>40	59
4	Yes	>35	30
5	No	>35	32
6	No	>35	20
7	No	>45	12
8	No	>40	12
9	Yes	>40	45
10	Yes	>30	21
11	No	>45	18
12	No	>30	70
13	No	>45	12
14	No	<20	67
Median (range)		36 (<20 to >45)	27.1

Table 2

Causes of recurrent dislocation of the temporomandibular joint (TMJ).

Age-related laxity of the joint ¹⁸
Acquired joint injury ²
Wide opening – for example, yawning, vomiting, psychogenic
Parafunction – for example, seizures
Systemic joint laxity
Connective tissue disorders such as Ehlers Danlos syndrome, Marfan syndrome
Medications such as benzodiazepines, muscle relaxants
Anatomical-shallow glenoid fossa/eminence or steep eminence
Inherent anatomical variation
Acquired – for example, loss of vertical dimension, occlusal discrepancies ²

at the time of the final consultation. There were no preoperative predictors for postoperative pain (for example, age or type of dislocation). All patients could speak normally, and nine could tolerate a full diet. Those with restrictions reported that they avoided only hard foods such as apples and steak. There was no effect on normal daily life or recreational activities, and only one patient reported a mild impact on their overall mood. Two reported mild anxiety about recurrence while others did not fear it at all.

The main issues noted by patients were pain, effect on diet, and anxiety. Eight reported that no problems were uppermost in their mind, and nine that their overall health-related QoL was much improved. This is noteworthy as, preoperatively, two had reported that it had been poor. Importantly, 10 would recommend the treatment to a friend or relative with a similar problem.

Discussion

Recurrent dislocation of the TMJ can be caused by a combination of factors (Table 2),¹¹ and every episode will further

damage the joint. The need for an operation to address both the eminence and laxity of the joint capsule has previously been discussed.¹²

The nature of the dislocation should be directly addressed when formulating a surgical plan, and an operation should be considered only after minimally invasive management, such as injection of autologous blood, has been tried.¹³ The operation aims either to remove anything that obstructs the movement of the condyle, or to prevent excessive movement of the condylar head.

Operations to obstruct the path of the condyle include LeClerc's glenotemporal osteotomy, in which the zygomatic arch is down-fractured to increase the barrier to anterior translation of the condylar head.¹⁴ Adaptations to this technique include Dautrey's procedure and several other modifications that include interpositional bone grafts or miniplates to further obstruct this movement.¹⁵ When compared with eminectomy, eminoplasty techniques are associated with reduced mouth opening, and any miniplates that have been used risk being fractured.^{15–17}

Eminectomy was first described by Myrhaug (1951), who removed the articular eminence of the temporal bone, and by so doing, removed anything that would obstruct the relocation of the condylar head after dislocation.¹⁸ Eminectomy is a mainstay of treatment and its benefits have been widely reported.¹⁹ However, some authors have recorded limitations¹⁶ and, to our knowledge, it has been described only in small case series of no more than three patients.¹⁰ It is designed to remove barriers to the reduction of the condylar head to the glenoid fossa, and is associated with increased postoperative mouth opening when compared with eminoplasty.¹⁷

Disc plication has also been described in the management of recurrent dislocation, and in a case series of 17 patients, there was no recurrence at 12 months.²⁰ The benefit of disc plication with eminectomy has been reported, as eminectomy removes barriers to the path of the condyle during function, and disc plication allows smoother movement of the disc postoperatively.²¹ Combining these treatments to improve outcomes seems logical, as it reduces the need (in a staged approach) for repeat access to the joint. However, to our knowledge, a combined surgical approach has not previously been published as a cohort study.

We know of no reports of lateral pterygoid myotomy alone for the surgical treatment of recurrent dislocation. Infiltration of botulinum toxin in the lateral pterygoid muscle has a similar effect on function, but may require repeated doses. It is a viable treatment for those who are not suitable for operation.^{9,22}

It has been postulated that lateral pterygoid myotomy with eminectomy and disc plication, may be beneficial in patients with spontaneous dislocation, and our results show its effectiveness. Based on our study, we propose a treatment protocol for patients with recurrent dislocation (Fig. 1).

Despite the small sample size, the combination of these two procedures has shown promising long-term results. The

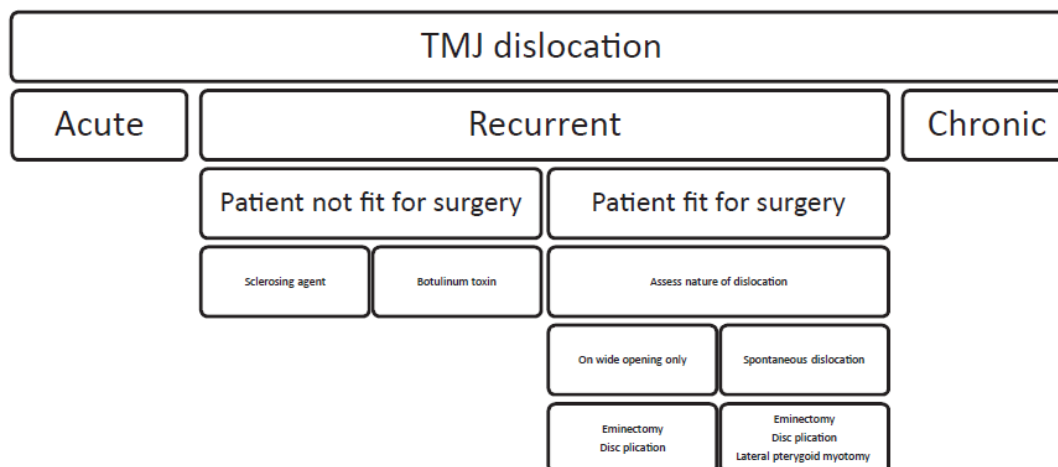


Fig. 1. Proposed treatment protocol for recurrent dislocation of the temporomandibular joint (TMJ).

addition of lateral pterygoid myotomy is a new technique for patients with spontaneous dislocation. A larger multicentre prospective study, which directly compares the different surgical methods separately and in combination, is now needed to find the most appropriate technique for the management of patients with this condition.

Conflict of interest

We have no conflicts of interest.

Ethics statement/confirmation of patients' permission

This research was granted ethics approval from the Research Governance Unit of the St Vincent's Hospital, Melbourne (LNR HREC reference number LNR/17/SVHM/19). Patients' permission not applicable.

Funding

None.

Confirmation of authorship

All authors have viewed and approved of this submission.

References

1. Dimitroulis G, McCullough M, Morrison W. Quality-of-life survey comparing patients before and after discectomy of the temporomandibular joint. *J Oral Maxillofac Surg* 2010;68:101–6.

2. August M, Troulis MJ, Kaban LB. Hypomobility and hypermobility disorders of the temporomandibular joint. In: Miloro M, editor. *Peterson's principles of oral and maxillofacial surgery*. 2nd ed. BC Decker Inc; 2004. p. 1033–50.
3. Dolwick FM, Abramowicz S, Bagheri SC. Diagnosis and management of temporomandibular joint pain and masticatory dysfunction. In: Bagheri SC, Bell RB, Khan HA, editors. *Current therapy in oral and maxillofacial surgery*. Elsevier Saunders; 2011. p. 859–68.
4. Kumar V, Abbas KA, Fausto N. *Robbins and Cotran: pathologic basis of disease*. 7th ed. Elsevier Saunders; 2004.
5. Nale JC, Tucker MR. Management of temporomandibular disorders. In: Happ J, Ellis III E, Tucker MR, editors. *Temporomandibular and other facial pain disorders in contemporary oral and maxillofacial surgery*. 6th ed. Elsevier Mosby; 2014.
6. Pogrel MA. Temporomandibular joint disorders. In: Andersson L, Kahnberg KE, Pogrel MA, editors. *Oral and maxillofacial surgery*. Wiley-Blackwell; 2010.
7. Varedi P, Bohluli B. Autologous blood injection for treatment of chronic recurrent TMJ dislocation: is it successful? Is it safe enough? A systematic review. *Oral Maxillofac Surg* 2015;19:243–52.
8. Oztel M, Bilski WM, Bilski A. Botulinum toxin used to treat recurrent dislocation of the temporomandibular joint in a patient with osteoporosis. *Br J Oral Maxillofac Surg* 2017;55:e1–2.
9. Matthews NS, editor. *Dislocation of the temporomandibular joint—a guide to diagnosis and management*. Springer; 2018.
10. Martins WD, Ribas Mde O, Bisinelli J, et al. Recurrent dislocation of the temporomandibular joint: a literature review and two case reports treated with eminectomy. *Cranio* 2014;32:110–7.
11. Sharma NK, Singh AK, Pandey A, et al. Temporomandibular joint dislocation. *Natl J Maxillofac Surg* 2015;6:16–20.
12. Cascone P, Ungari C, Paparo F, et al. A new surgical approach for the treatment of chronic recurrent temporomandibular joint dislocation. *J Craniofac Surg* 2008;19:510–2.
13. Undt G. Temporomandibular joint eminectomy for recurrent dislocation. *Atlas Oral Maxillofac Surg Clin North Am* 2011;19:189–206.
14. Gadre KS, Kaul D, Ramanojam S, et al. Dautrey's procedure in treatment of recurrent dislocation of the mandible. *J Oral Maxillofac Surg* 2010;68:2021–4.
15. Ying B, Hu J, Zhu S. Modified Leclerc blocking procedure with mini-plates and temporal fascial flap for recurrent temporomandibular joint dislocation. *J Craniofac Surg* 2013;24:740–2.

16. Güven O. A clinical study on treatment of temporomandibular joint chronic recurrent dislocations by a modified eminoplasty technique. *J Craniofac Surg* 2008;**19**:1275–80.
17. Güven O. Management of chronic recurrent temporomandibular joint dislocations: a retrospective study. *J Craniomaxillofac Surg* 2009;**37**:24–9.
18. Myrhaug H. A new method of operation for habitual dislocation of the mandible. Review of former methods of treatment. *Acta Odontol Scand* 1951;**9**:247–60.
19. Mayrink G, Olate S, Assis A, et al. Recurrent mandibular dislocation treated by eminectomy. *J Craniofac Surg* 2012;**23**:e516–20.
20. Zachariah T, Neelakandan RS, Ahamed MI. Disc anchoring with an orthodontic mini-screw for chronic meniscocondylar dislocation of TMJ. *J Maxillofac Oral Surg* 2015;**14**:735–44.
21. Erickson HP, Zuniga J. Arthroplasty and eminectomy. In: Kademani D, Tiwana P, editors. *Atlas of oral and maxillofacial surgery*. Elsevier Saunders; 2016. p. 1320–30.
22. Vázquez Bouso O, Forteza González G, Mommsen J, et al. Neurogenic temporomandibular joint dislocation treated with botulinum toxin: report of 4 cases. *Oral Surg Oral Med Oral Pathol Oral Radiol Endod* 2010;**109**:e33–7.

**Appendix XI – Draft Publication: Surgical management of recurrent TMJ dislocation – A
systematic review**

Citation:

Tocaciu S, McCullough MJ, Dimitroulis G. Surgical management of recurrent TMJ dislocation – a systematic review. Oral and Maxillofacial Surgery. 2019; 23(1) 35-45

DOI:

10.1007/s10006-019-00746-5

PMID:

30729355



Surgical management of recurrent TMJ dislocation—a systematic review

Shreya Tocaciu¹ · M. J. McCullough² · G. Dimitroulis¹Received: 25 May 2018 / Accepted: 29 January 2019 / Published online: 7 February 2019
© Springer-Verlag GmbH Germany, part of Springer Nature 2019

Abstract

Purpose Recurrent temporomandibular joint (TMJ) dislocation can be challenging to treat and the current understanding regarding aetiology and management of this condition is limited. The aim of this paper was to conduct a systematic review regarding the management of recurrent TMJ dislocation.

Methods A literature review was conducted using PRISMA guidelines to identify papers published between 2006 and 2016. The resultant papers were analysed.

Results A total of 33 papers were found relevant to the study. Minimally invasive techniques described included autologous blood injection, which was associated with an overall success of 80% at 12 months. Other modalities investigated included OK-432 sclerotherapy, laser capsulorrhaphy, botulinum toxin of the lateral pterygoid muscle or modified dextrose. These publications show promising success rates.

Surgical techniques described included disc plication, eminoplasty and eminectomy. These modalities had a similar success rate, although numbers were limited. The true incidence of recurrent TMJ dislocation is unknown and aetiology is limited to expert opinion.

Conclusion The current understanding of management for recurrent TMJ dislocation is limited to case series and case reports. This paper compiles the current understanding of management of recurrent TMJ dislocation. Compared to previous reviews, this paper describes some novel minimally invasive techniques with promising success in the management of recurrent TMJ dislocation.

Keywords Temporomandibular Joint · Eminectomy · Disc Plication · Botulinum toxin, eminoplasty · Dislocation

Introduction

Recurrent temporomandibular joint (TMJ) dislocation can be debilitating for patients and challenging with regards to diagnosis and management for practitioners.

Dislocation of the temporomandibular joint causes significant pain and anxiety for patients, and results in trauma to the joint capsule and ligaments. This dislocation may occur in one of four forms. The first form, subluxation, occurs when there are transient partial dislocations of the TMJ that are usually self-resolving. The second form, acute dislocation,

usually occurs as a result of trauma or excessive mouth opening (e.g. during yawning or after prolonged dental procedures [1]). Acute TMJ dislocation is managed via manual reduction, which may require sedation. This may be augmented with supportive bandages and soft diet. The third form, chronic dislocation, occurs when there is prolonged disarticulation of the TMJ, usually as a result of underlying laxity of the joint capsule. This may be secondary to age-related degeneration, an inherent connective tissue disorder (such as Ehler's Danlos Syndrome [1]), or as an adverse effect of antipsychotic medication such as clonazepam [2]. Chronic dislocation may be managed conservatively via positional devices, or surgically. The last form of TMJ dislocation is recurrent dislocation. This occurs when there are recurrent acute episodes of TMJ disarticulation due to either joint capsule/ligament laxity, anatomical variation in the joint or dystonia of the lateral pterygoid muscle causing spasmodic antero-medial pull on the condylar head. The four forms of TMJ dislocation are discrete in their mechanisms, and it is important to differentiate them clinically, as their approach to

✉ Shreya Tocaciu
shreyatocaciu@gmail.com

¹ Oral and Maxillofacial Unit, St Vincent's Hospital Melbourne, Fitzroy, Australia

² Oral Medicine Unit, Melbourne Dental School, University of Melbourne, Melbourne, Australia

treatment differs. Patients may have features or risk factors of more than one type of dislocation. Ideally, the type and risk factors for dislocation should be identified so that treatment can address the mechanism of dislocation.

Recurrent TMJ dislocation and its treatment are not well understood [3]. Treatment modalities described for the management of recurrent TMJ dislocation in the literature can be classified as minimally invasive or surgical. In general, conservative methods are trialled before surgical management. Currently, there is no ideal treatment guide with which to approach recurrent TMJ dislocation [4]. The aim of this study was to undertake a systematic review of current concepts regarding clinical management of recurrent TMJ dislocation. This is especially important as recently, newer treatment modalities for recurrent TMJ dislocation are emerging.

Materials and Methods

Using PRISMA guidelines (Preferred Reporting Items for Systematic Reviews and Meta-Analyses [5]), a search was carried out with the MESH terms “recurrent” “temporomandibular joint” and “dislocation”, over the last 10 years (2006–2016) using the databases PubMed (MEDLINE), Cochrane Library and Science Direct. Inclusion criteria were studies involving patients with recurrent TMJ dislocation, undergoing either minimally invasive or surgical management, where minimally invasive treatment includes intra-articular injection of blood or sclerosing agents. A total of 64 papers were found using the above terms. Papers not relating directly to recurrent TMJ dislocation or those papers not available in English were excluded (Fig. 1). This left a total of 38 papers for analysis, 33 clinical papers relating to either minimally invasive techniques or surgery and five regarding the aetiology or overview of TMJ dislocation. The papers were reviewed in relation to patient demographics, aetiology of TMJ dislocation, management and outcomes (recurrence of dislocation).

Results

A total of 33 clinical papers were found to be suitable for the basis for this review of recurrent TMJ dislocation in the last 10 years. Of these, only one paper was of level I evidence (systematic review or meta-analysis), 4 were level II evidence (randomised clinical trials), 6 level III evidence (retrospective cohort studies), 14 level IV evidence (case series), and 8 level V evidence (case report or expert opinion). The longest period of follow-up was up to 12 years. However, when assessing surgical management of recurrent TMJ dislocation specifically, the evidence was not as strong, with no level I evidence, and only one prospective

cohort study. The majority of literature on surgical management of recurrent TMJ dislocation was limited to case series or case reports.

Papers relating to overviews or opinion

Aetiology and incidence

The incidence of recurrent TMJ dislocation has not been described, although it is thought to be more often associated with females with pre-existing joint disease, and perhaps neuromuscular disorders.

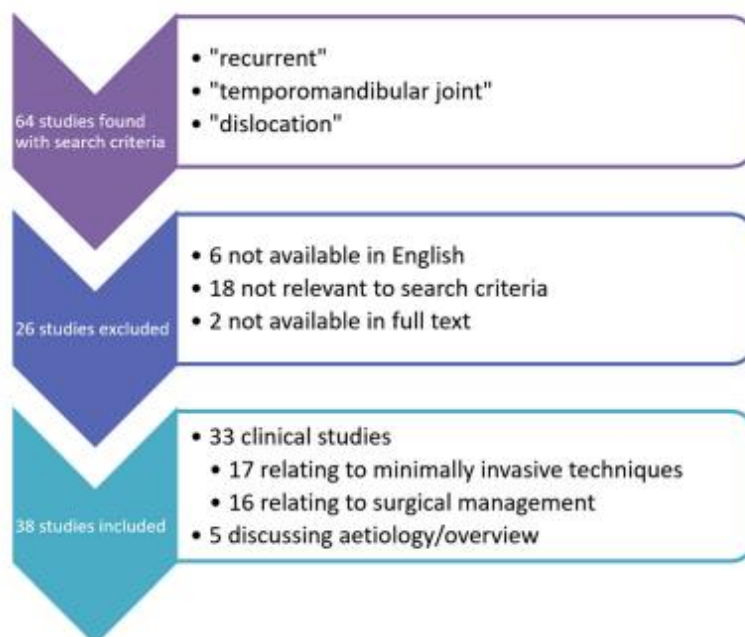
The true aetiology of recurrent TMJ dislocation is also poorly understood. The aetiology of recurrent TMJ dislocation can be based on either anatomical factors or functional factors. Murakami [6] described synovial plicae in 62.5% (18 of 28) TMJs undergoing surgery for recurrent dislocation. The role of the plicae in recurrent TMJ dislocation is not understood, but could potentially be a contributor. On the other hand, it could also be an iatrogenic sequelae of previous attempts to treat the recurrent dislocation.

Liddell considered functional factors that may contribute to recurrent TMJ dislocation. He suggested that connective tissue disease such as Ehler’s Danlos Syndrome [7] can be attributed to recurrent TMJ dislocation as a result of increased joint laxity. Furthermore, muscular dystonias resulting in insufficient joint support from the masticatory apparatus can also result in recurrent dislocation [7]. Neurodegenerative disease such as Parkinson’s and Huntington’s can cause muscular dystonia, thereby resulting in recurrent TMJ dislocation [7]. These factors predisposing to recurrent dislocation are speculation only, as the incidence of recurrent TMJ dislocation in patients with each condition is not known to be higher than the overall population.

Investigations

No papers were found assessing the sensitivity or specificity of investigations for recurrent TMJ dislocation specifically. In general, OPG (orthopantomogram) X-ray is used as a general screening tool, and may depict abnormal bony morphology of the condylar head. Sahoo [8] used OPG to assess post-operative changes in the articular eminence form after Dautrey’s procedure. This study found that the average height of the pre-operative articular eminence was 7.49 mm on the right and 7.32 mm on the left in patients with recurrent TMJ dislocation. There was no comparison to the general population.

CT and MRI are used in investigation of TMJ disease in general, but their use in investigating the cause of recurrent TMJ dislocation is unknown.

Fig. 1 Papers included and excluded in study

Treatment options

The management of recurrent TMJ dislocation should be personalised to the patient [9], with some reference to the hypothesised aetiology for that particular patient. Treatment should have a sequential approach, with minimally invasive modalities trialled before surgery is undertaken, unless a localised pathology is identified.

In general, management of recurrent TMJ dislocation is based on one of three aims. The first of these is to induce fibrosis within the peri-articular tissues. This may be via autologous blood injection, capsulorrhaphy or OK-432 sclerosing agent.

The second aim of treatment is to remove the obstruction to joint relocation. This is largely achieved via eminectomy. The third goal of treatment of recurrent TMJ dislocation is to limit anterior joint translation. This can be achieved by methods such as mini-anchor, eminoplasty or inactivating the lateral pterygoid muscle.

Treatment modalities aimed at limiting jaw joint movement need to be combined with a period of post-operative limitation of mouth opening. This should be followed by some physiotherapy to prevent joint ankylosis [10]. Undt [10] suggested in his review paper of eminectomy that surgical options for recurrent TMJ dislocation should only be considered once minimally invasive techniques have been trialled and failed.

Contraindications to eminectomy or eminoplasty include high surgical risk due to patient co-morbidities or pneumatization of the articular eminence as seen on CT or MRI imaging [9].

Efficacy of treatment

De Almeida conducted a systematic review on the management of recurrent temporomandibular joint dislocation [4]. This study found that there is no good quality evidence on efficacy of different treatment modalities. The study also suggested that some surgeons opted for eminectomy in cases where other treatment modalities had failed. This suggested that although evidence is not robust, eminectomy may be perceived as the gold standard for recurrent TMJ dislocation.

Papers discussing specific treatment modalities

Of the 33 papers describing treatment modalities for recurrent TMJ dislocation, 17 referred to minimally invasive techniques (Table 1) and 16 referred to surgical management (Table 2)

Minimally invasive treatment

Minimally invasive methods include intermaxillary fixation, injection of botulinum toxin A into the lateral pterygoid muscle, as well injections into the joint space. Materials injected into the joint space included autologous blood, modified dextrose [24] and OK-432 [25].

Botulinum toxin A injection of the lateral pterygoid muscle

Botulinum toxin A injection into bilateral lateral pterygoid muscles has been shown in two case reports [3, 22] to alleviate recurrent TMJ dislocation without recurrence at up to 6 months. Oztel and colleagues [3] described a case of a 99-

Table 1 Minimally invasive management of recurrent TMJ dislocation

Reference number	Authors	Year	Journal	Type	Case number	Modality	Follow-up (months)
[11]	Coser	2015	IJOMS	Case series	11	Blood	35
[12]	Bayoumi	2014	IJOMS	Case series	15	Blood	12
[13]	Hegab	2013	BJOMS	RCT	48	Blood	12
[14]	Machon	2009	JOMS	Case series	25	Blood	12
[15]	Kato et al.	2007	J Oral Sci	Case report	1	Blood	5
[16]	Gupta	2013	J Oral Biol Craniofac Res	Case report	1	Blood	8
[17]	Gulses et al.	2013	J Craniomaxillofac Surg	Clinical trial (animal)	16	Blood	1
[18]	Candirli et al.	2012	Imaging Sci Dent	Prospective	14	Blood	1
[19]	Candirli et al.	2011	J Craniofac Surg	Clinical trial (animal)	8	Blood	1
[20]	Pinto	2009	JOMS	Case series	1	Blood	12
[21]	Daif	2010	OIOOE	RCT	30	Blood	12
[3]	Oztel et al.	2016	BJOMS	Case report	1	Botox	6
[22]	Vazquez et al.	2010	OIOOE	Case series	4	Botox	7
[23]	Torres	2012	IJOMS	Case series	11	Electrothermal capsulorrhaphy	27
[24]	Zhou et al.	2014	BJOMS	Retrospective review	45	50% dextrose	12
[25]	Matsushita et al.	2007	BJOMS	Case series	2	OK-432	6

BJOMS, British Journal of Oral and Maxillofacial Surgery; *IJOMS*, International Journal of Oral and Maxillofacial Surgery; *OIS*, Oral and Maxillofacial Surgery; *Pediatr Dent*, Pediatric Dentistry; *J Oral Biol Craniofac Res*, Journal of Oral Biology and Craniofacial Research; *J Craniomaxillofac Surg*, Journal of Cranio-Maxillo-Facial Surgery; *Imaging Sci Dent*, Imaging Science in Dentistry; *J Craniofac Surg*, Journal of Craniofacial Surgery; *OIOOE*, Oral Surgery, Oral Medicine, Oral Pathology, Oral Radiology, Endodontology; *J Laryngol Otol Suppl*, Journal of Laryngology and Otology Supplement; *JOMS*, Journal of Oral and Maxillofacial Surgery; *J Oral Sci*, Journal of oral science

year-old woman who presented to a regional centre with bilateral recurrent TMJ dislocation. She was initially treated with manual reduction and IMF, which she did not tolerate. She was then treated with 25 units of botulinum toxin diluted in 2 ml 0.9% normal saline. The lateral pterygoids were injected trans-cutaneously via the sigmoid notch. There was no recurrence at 6 months. Vazquez et al. [22] described four cases of recurrent TMJ dislocation, all of which were thought to be neurogenic in origin with the predisposing conditions being traumatic brain injury, Alzheimer's disease, Parkinson's disease and myotonic dystrophy. The mean follow-up period was 7 months, with one patient suffering recurrence, and another patient requiring two doses of botulinum toxin. Thus, undertaking the present systemic review revealed five cases where botulinum toxin was used in the lateral pterygoid muscle to alleviate recurrent TMJ dislocation, with a combined success of 80% (4 of 5) at 6 months.

Autologous blood (ABI) into joint space Injection of autologous blood into the superior joint space and into the joint capsule has been discussed in multiple case series, and has been associated with up to 80% success rate in alleviating recurrent TMJ dislocation at 12 months [11, 12, 14, 16].

Bayoumi and colleagues described a case series of 15 patients, all who underwent bilateral injections of autologous blood, 2 ml into the superior joint space and 1 ml into the pericapsular tissues [12]. The patients were followed up for 12 months, and 80% (12 of 15) had no recurrence. Those who suffered recurrence of their dislocation did so early, at a mean of 3 weeks post procedure. Similarly, Coser et al. assessed the efficacy of ABI [11] in a cohort of eleven patients who received bilateral ABI for recurrent TMJ dislocation. Over a mean follow-up period of 30 months, 73% (8 of 11) had no recurrence.

A further study reported 25 patients with bilateral TMJ dislocation who underwent ABI and were followed up for a mean of 12 months [14]. Within 4 weeks, the success rate was 60% (15 of 25) [14]. The remaining 10 patients underwent a second treatment at this stage and at 12 months, 80% of patients (20 of 25) had no recurrence of their dislocation after either one or two treatments. Single case reports of this technique have also been published, with one of an 82-year-old man who underwent bilateral ABI for recurrent TMJ dislocation, with no recurrence at 8 months [16], another of an 84-year-old patient was treated successfully for recurrent TMJ dislocation with ABI, showing no clinical recurrence at

Table 2 Surgical management of recurrent TMJ dislocation

Reference number	Authors	Year	Journal	Type	Case number	Modality	Follow-up (months)
[1]	De Freitas Silva et al.	2016	J Craniofac Surg	Letter to Editor	1	Disc plication	12
[26]	Zachariah et al.	2015	JOMS	Case series	17	Disc plication	12
[27]	Pentyala et al.	2014	J Craniofac Surg	Case report	1	Eminectomy	Not specified
[28]	Martins	2014	Cranio	Case report	2	Eminectomy	12
[29]	Mayrink	2012	J Craniofac Surg	Case series	3	Eminectomy	60 (5 years)
[30]	Guven	2009	J Craniomaxillofac Surg	Retrospective	19	Eminectomy and eminoplasty	12–144 (1–12 years)
[31]	Kahveci et al.	2013	JOMS	Retrospective analysis	73	Eminoplasty	30
[32]	Da Costa Ribeiro	2014	IJOMS	Case series	2	Eminoplasty	12–24
[33]	Ying et al.	2013	J Craniofac Surg	Case series	7	Eminoplasty	24
[8]	Sahoo	2013	JOMS	Case series	10	Eminoplasty	12
[34]	Gadre	2010	JOMS	Retrospective	20	Eminoplasty	36
[30]	Guven	2008	J Craniofac Surg	Case series	12	Eminoplasty	48 (mean 4 years)
[35]	Guarda-Nardini et al.	2008	Oral Maxillofac Surg	Case report	1	Eminoplasty	8
[36]	Medra et al.	2008	BJOMS	Prospective study	60	Eminoplasty	12–96 (8 years)
[37]	Tagliatalata	2012	J Craniofac Surg	Case series	7	Orthognathic surgery	12

J Craniofac Surg, Journal of Craniofacial Surgery; *JOMS*, Journal of Oral and Maxillofacial Surgery; *Cranio*, Journal of Craniomandibular Practice CRANIO; *IJOMS*, International Journal of Oral and Maxillofacial Surgery; *J Craniomaxillofac Surg*, Journal of Cranio-Maxillo-Facial Surgery; *OMS*, Oral and Maxillofacial Surgery; *BJOMS*, British Journal of Oral and Maxillofacial Surgery

5 months [15], and a third describing a case where ABI was combined with a supportive head bandage for 4 weeks with no recurrence at 12 months [20].

The above papers described a total of 54 patients treated with ABI, with a success rate of 80% (43 of 54) at a mean follow-up of 16 months.

The technique of ABI described by most studies involves injection of 2–3 ml of autologous blood into the superior joint space (SJS), with or without injection of a further 1 ml into the pericapsular tissues (PT). Daif [21] showed that injection into both the SJS and PT was associated with a success of 80% (12 of 15) at 12 months compared to a success of 60% (9 of 15) if only the SJS was injected.

This success rate may be further increased with the concurrent use of intermaxillary fixation for 4 weeks [13]. Hegab described a study in which 48 patients with recurrent TMJ dislocation were divided equally into three groups. The first group received ABI into the SJS and PT. The second group received ABI in the same way, but were also treated with IMF for 4 weeks. The third group received IMF alone for 4 weeks. Of the 16 patients that received ABI alone, half ($n = 8$) had recurrence of TMJ dislocation. Three of the 16 patients treated with IMF alone had recurrence of dislocation. The combined ABI and IMF treatment group was associated with the best success, with none of the 16 patients suffering recurrent dislocation.

However, all three treatment modalities were associated with decreased mouth opening. The mean decrease in mouth opening for ABI alone, IMF alone and combined ABI and IMF were 8.5 mm, 9.13 mm and 11 mm respectively. The difference between the ABI group and the IMF group was not statistically significant, but combined treatment with both ABI and IMF was associated with a statistically significant decrease in mouth opening when compared to the other two groups. Recurrence in the ABI only group was overcome by multiple injections. No patients had recurrence after a maximum of three injections. Recurrence in the IMF alone group was overcome with a further 2 weeks of IMF.

The mechanism of action of autologous blood injection for the treatment of recurrent TMJ dislocation was explored by Candirli et al. [19] in a laboratory study using eight New Zealand white rabbits who underwent bilateral autologous blood injection, followed by IMF for 4 weeks. This was achieved via fixation of orthodontic brackets and elastics. After 4 weeks, the animals were sacrificed and the TMJs underwent histological analysis. This showed accumulation of fibrin within the joints, without an inflammatory infiltrate or vessel proliferation. Gules et al. [17] explored this further, when they compared histological changes in 16 pigs who underwent bilateral ABI versus those who received injection of normal saline only. Joints injected with autologous blood

were associated with fibrosis in the retrodiscal and pericapsular tissues, whereas histology of saline-injected joints appeared unchanged.

Candirli et al. in 2012 assessed MRI changes in human subjects 1 month after autologous blood injection [18]. This study of 14 subjects showed improvement in the condyle-glenoid fossa relationship 4 weeks after ABI. Specifically, open-mouth views showed the condyle either at or posterior to the articular eminence. This was in contrast to pre-operative MRI, where the condyle was found to be anterior to the eminence in open mouth views. There were no MRI findings suggesting of haematoma or structural joint change.

Modified dextrose injection into joint space Zhou et al. [24] described injection of lignocaine and 50% dextrose into the posterior periarticular tissues, as a method of inducing fibrosis in treatment of recurrent TMJ dislocation in 45 patients with recurrent TMJ dislocation, aged 17 to 59 years. Post operatively, patients were instructed to have a soft diet and avoid wide opening for 2 weeks. Patients were followed up for a mean of 18 months, with a success of 91% (40 of 45 patients). However, 27% (12 of 45) patients required a second injection, and 4% (2 of 45) patients required a total of three injections. No animal studies have been found investigating the histological changes induced by this technique.

OK-432 injection into joint space OK-432 is a group A streptococcal pyogenes derivative that has been treated with penicillin G and lyophilized [38]. It is therefore contraindicated in patients with a penicillin allergy. This agent can then be stored in 15-ml tubes containing 0.16 ml of EDTA (ethylenediaminetetraacetic acid) solution. OK-432 has been found to induce a local inflammatory response, resulting in fibrosis. OK-432 was used as a sclerosing agent into the temporomandibular joints of two patients unsuitable for surgical management [25]. The first of these patients was a 68-year-old man with supra-nuclear palsy who had been treated with bilateral injection of autologous blood that resulted in recurrence of dislocation at one month. He was subsequently treated with bilateral OK-432 sclerosing agent that successfully treated his dislocation at a follow-up of 6 months [25]. The second patient was a 91-year-old woman, also with bilateral recurrent TMJ dislocation, who was treated primarily with OK-432 bilaterally, and had no recurrence at 6 months [25]. No animal studies were found to explore the histological changes induced by OK-432.

Electrothermal capsulorrhaphy Stimulation of fibrosis within the TMJ with electrothermal capsulorrhaphy treatment for recurrent TMJ dislocation can be achieved via an arthroscopic approach and either Hol:YAG laser or electrocautery [23]. Only one study in the systematic review explored this treatment modality, and described a success rate of 82% (9 of 11 patients) with a long follow-up period of 27 months [23].

Surgical management

Surgical management of recurrent TMJ dislocations could be grouped into methods of disc plication, eminectomy or eminoplasty, orthognathic surgery or alloplastic joint replacement. Surgical methods are adopted when conservative methods have either failed or are not suitable due to patient factors.

Disc plication Disc plication using artificial anchors/ligaments was first described by Cottrell and Wolford [39]. In the setting of recurrent TMJ dislocation, Zachariah and his group [26] conducted a case series of 17 patients (27 joints) where the disc was plicated to the condylar head by using an orthodontic mini-screw placed into the condylar head and a non-resorbable prolene suture anchoring the posterior disc to the mini-screw [26]. There were no cases of recurrence of TMJ dislocation at 12 months using this technique [26].

Eminectomy Eminectomy is the removal of the articular eminence of the temporal bone, thus reducing obstruction to the relocation of the condylar head after dislocation. Eminectomy for TMJ dislocation was first described by Myrhaug in 1951 [40]. It has been reported as having 100% efficacy at up to 5 years; however, there have only been a small number of reports with small sample sizes of 3 or less [27–29]. Guven in 2009 assessed patients undergoing both eminectomy and eminoplasty, and found that eminectomy was associated with greater post-operative inter-incisal opening [30]. They reported on 19 patients with recurrent TMJ dislocation (a total of 37 joints), aged between 22 and 80 years (mean = 44) that were treated with eminectomy ($n = 9$) if they had either previously failed surgical treatment, had a systemic condition predisposing to dislocation (e.g. neurodegenerative disease) or if post-operative IMF was contraindicated [30]. All other patients in this study ($n = 12$) were treated with eminoplasty via an oblique osteotomy with inter-positional chin graft without fixation [30]. This study reported 100% success, with none of the 19 patients suffering recurrence of their dislocation over a follow-up period that was between 12 months and 12 years [30]. The only variation between the two techniques reported was that patients treated with eminectomy had a post-operative decrease in their mouth opening of 7 mm (mean), and those treated with eminoplasty had a decrease of 11.67 mm [30].

Eminoplasty Eminoplasty was first described by LeClerc and Girard as a glenotemporal osteotomy [41], and was later modified by Gosserez and Dautreya via interposition of a bone graft into a sub-periosteal pocket. This procedure involves down fracture of the zygomatic arch to increase both the vertical and horizontal dimension of the articular eminence. The position of the articular eminence has been reported to move

inferiorly by approximately 3.5 mm and anteriorly by approximately 4.5 mm [8]. Adaptations of this procedure have been described since LeClerc and Dautrey, including the incorporation of mini-plates and temporal fascial flaps [33]. More recently, blocking techniques have been described using calvarial [35], chin [42] or iliac bone grafts [31] fixated with or without mini-plates to produce an articular eminence over which the condyle cannot glide, thereby preventing dislocation. Risks of these blocking techniques include post-operative pain, infection and fracture of mini-plate [31].

In this systematic review, nine studies described eminoplasty for recurrent TMJ dislocation. Guven in 2009 [30] described 19 patients suffering from recurrent TMJ dislocation. These patients were managed either by eminectomy or eminoplasty as described above. Of the 12 patients in this study that underwent eminoplasty, none had recurrence at a follow-up of between 2 and 6 years. They did however report a decrease in post-operative mouth opening of 11.67 mm [30].

Godre and colleagues looked at 20 patients who underwent Dautrey's procedure for recurrent TMJ dislocation, and followed them for 18 months. There was no recurrence, and a mean decrease in MMO of 7 mm post-operatively [34].

Kahveci et al. described 73 patients who were treated for recurrent TMJ dislocation with autologous bone graft fixated to the antero-inferior surface of the articular eminence with mini-plate and screws [31]. These patients were followed up between 3 and 30 months. Post-operative maximum mouth opening (MMO) was reduced to a mean of 38 mm, although pre-operative MMO was not reported. Three cases were complicated by post-operative infection or fracture of metalware. The exact recurrence rate of TMJ dislocation was not defined in the paper [31].

Da Costa Ribeiro explored surgical treatment options for patients where eminectomy was not possible due to pneumatization of the articular eminence [32]. Two patients were treated with a modified Dautrey's procedure, where the zygomatic arch was down-fractured, and a mini-plate was applied from the lateral of the articular eminence to the displaced zygomatic arch. Both patients who underwent this procedure had no recurrence at 12 and 24 months, and had a post-operative MMO of 48 and 45 mm respectively [32].

Ying et al. also introduced a modified eminoplasty technique for recurrent TMJ dislocation [33]. Seven patients underwent a modified LeClerc blocking procedure, where two osteotomies were made along the zygomatic arch—one anterior to the articular eminence and one at the zygomaticotemporal suture. The zygomatic arch was down-fractured such that the posterior end of the segment was antero-inferior to the articular eminence. Fixation in this position was achieved via mini-plates and screws. An inferior-based temporal fascia flap was then used to plicate the antero-lateral aspect of the TMJ capsule. There was no recurrence in the study group over a follow-up period ranging from

6 to 24 months. There was a mean decrease in mouth opening of 9.8 mm. Four of the seven patients also reported improvement in TMJ pain and sounds [33].

Sahoo and colleague looked at the changes in the articular eminence dimensions after Dautrey's procedure in ten patients [8]. Dimensions were measured on OPG X-ray at 12 months, and found to have an increase in the vertical height of the eminence of 3.65 mm (average, right) and 3.52 mm (average, left), which reflects an increase of 48.73% and 48.08% respectively [8]. There was also an anterior shift of the articular eminence of 4.56 mm (average, right) and 4.51 mm (average, left). There was a mean decrease in post-operative MMO of 4.09 mm [8].

Guven in 2008 described another modification of eminoplasty. Twelve patients underwent an oblique osteotomy of the articular eminence, and interpositional autologous bone graft, which was obtained from the chin. No conventional fixation methods were used. The patients were followed up for a mean of 4.2 years, with no recurrence [42]. Guarda-Nardini also described an interpositional graft of the articular eminence, this time harvested from calvarium. In this case report of one patient, there was no recurrence at 8 months [35]. Medra looked at a larger sample size, this time of 60 patients with recurrent TMJ dislocation [36]. All patients underwent a horizontal osteotomy of the articular eminence, and interpositional autologous bone graft, wither from iliac crest or split calvarial. Fixation was either with wires, or mini-plates and screws. Patients were followed up for a mean of 36 months, with a mean post-operative MMO of 42 mm at 12 months. Five patients had temporary facial nerve paralysis, with resolution by 3 months. Three patients required removal of wire which was causing pain from impingement of surrounding tissues [36].

Orthognathic surgery Bimaxillary orthognathic surgery has been described [37] to correct dolichofacial pattern to mesofacial as a treatment modality for recurrent TMJ dislocation. This study of seven patients with class II skeletal pattern with steep mandibular plane angle and dolichofacial type, all suffering from recurrent TMJ dislocation, were treated with a combination of orthodontic and orthognathic surgery. A bimaxillary osteotomy was performed to correct the steep occlusal plane angle and correct class II skeletal relationship [37]. There was no recurrence of TMJ dislocation reported at 12-month review [37]. It was hypothesised that the correction of their hyperdivergent dentofacial deformity also corrected the recurrent TMJ dislocation by optimising the relationship between the condylar head and articular eminence.

Discussion

The aim of this study was to review the current treatment modalities available for management of recurrent TMJ

dislocation. These treatment modalities can be either minimally invasive, or surgical. Surgical treatment is aimed at either removing any obstruction to the movement of the condylar path (eminectomy) or by increasing it, thereby preventing condylar dislocation (disc plication or Dautrey's procedure and its modifications). Minimally invasive treatment includes infection of sclerosing agents in and around the TMJ, or botulinum toxin of the lateral pterygoid muscle. Since previous review articles, new sclerosing agents have been researched, with promising results.

Recurrent TMJ dislocation is not as well understood as acute or chronic dislocation [4]. Factors contributing to recurrent TMJ dislocation include dystonia of the lateral pterygoid muscle and laxity in the meniscus and lateral TMJ ligament [9]. Although usually described in middle-aged or elderly populations, recurrent TMJ dislocation can occur at all ages, including infants [43]. Recurrent dislocations can further injure the disc, capsule and TMJ ligaments, contributing to tendency for progressive internal derangement and recurrence of dislocation [10].

Search terms used in this systematic review were MESH terms "recurrent" "temporomandibular joint" and "dislocation". This aimed to capture studies on the recurrent dislocation, rather than acute dislocation, or protracted chronic subluxation. For this same reason, hypermobility was not included as a search term as this would include a broader range of TMJ disorders not specifically causing recurrent dislocation of the condylar head outside of the glenoid fossa.

Recurrent TMJ dislocation remains a management challenge for practitioners, with no ideal treatment modality. The wide variety of treatment strategies for recurrent TMJ dislocation highlights the fact that this condition is difficult to manage.

For treatment to be successful, the treatment modality needs to be tailored to address the aetiology of the recurrent dislocation. This is a challenge, as the exact aetiology of recurrent TMJ dislocation is poorly misunderstood. For example, if a lax disc is implicated, disc plication with non-resorbable sutures or a mini orthodontic screw [26] can improve the relationship between the condyle, disc and fossa subunits of the TMJ, thereby promoting synchronised movements. Alternatively, if the eminence form is implicated in the cause of recurrent dislocation, then eminectomy or eminoplasty procedures may be of benefit. Thirdly, if lateral pterygoid dystonia is causing recurrent dislocation, then lateral pterygoid myotomy or injection of botulinum toxin A into the muscle can help alleviate this problem. Identification of the aetiology of the patient's recurrent dislocation, either on history, clinical examination or imaging, has not previously been outlined. In one of the author's surgical practice (GD), patients are currently being successfully managed by eminectomy and disc plication. A lateral pterygoid myotomy is also performed if lateral pterygoid spasm or dystonia is suspected to be contributing to recurrent dislocation. Eminectomy allows free movement of the condylar head, and

avoids entrapment of the condylar anterior to the eminence, thereby avoiding the need for hospital presentation for reduction. Disc plication aims to promote synchronous movement of the condylar head and TMJ meniscus, thereby reducing ligamentous injury with hypermobility.

Injection of autologous blood into the superior joint space and lateral TMJ capsule has been extensively described in the literature, with a success rate of 80% at 16 months. This is likely due to stimulation of fibrotic changes within the retro discal tissue and joint capsule based on histological studies in pig [17] and rabbit models [19] but no structural changes have been identified on MRI [18]. Efficacy is found to be higher with injection into both the superior joint space and the peri capsular tissues when compared to the superior joint space alone [21].

Botulinum toxin injection of the lateral pterygoid muscle has also been reported to have a success of 80% at 6 months. However, the transient nature of botulinum toxin implies that patients may require multiple treatment, and currently longer term, larger cohort studies are lacking.

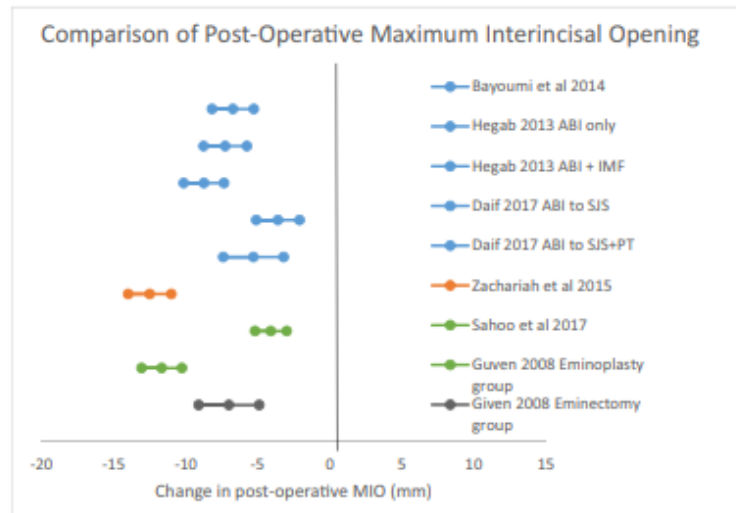
Modified dextrose has been shown to be a promising new modality for the minimally invasive management of recurrent TMJ dislocation. A study of 45 patients reported a success of 91% at 18 months, which is higher than that reported by any other modality. If this can be replicated by other researchers then perhaps modified dextrose may surpass other treatment modalities for management of recurrent TMJ dislocation.

Current papers on minimally invasive or surgical management of recurrent TMJ dislocation do not clearly advocate for one treatment modality over the other, except that as a principal, conservative or minimally invasive treatment should be trialled first. As with any systematic review of disease management, there may be a publication bias supporting positive results. One outcome that can be directly compared between the studies is the decrease in post-operative maximum inter-incisal mouth opening (MMO). Of the studies which included sufficient statistical analysis, it was found that a decrease in post-operative MMO occurs with all treatment modalities (Fig. 2), with no one treatment modality found worse than the others.

Large sample size studies on surgical management of recurrent TMJ dislocation with long-term follow-up are lacking, as are studies exploring the use of multiple surgical modalities in the same patient (e.g. disc plication and eminectomy together). Currently, the mainstay of minimally invasive management is autologous blood injection, although the potential for modified dextrose to surpass this is possible. Botulinum toxin injection of the lateral pterygoid muscle and OK-432 have also shown good results, but not in a large enough cohort.

The mainstay of surgical management of recurrent TMJ dislocation is eminectomy. However, disc plication has also shown excellent promise, with 100% success at 12 months in a group of 27 patients. Eminoplasty can also be effective, with several modifications described. Techniques involving mini-

Fig. 2 Comparison of post-operative maximum inter-incisal opening. ABI, autologous blood injection; IMF, intermaxillary fixation; SJS, superior joint space; PT, pericapsular tissues; MIO, maximum inter-incisal opening



Key:

Blue	Autologous Blood Injection
Orange	Disc Plication
Green	Eminoplasty
Grey	Eminectomy

Legend:

- ABI – autologous blood injection
- IMF – intermaxillary fixation
- SJS – superior joint space
- PT – pericapsular tissues
- MIO - maximum inter-incisal opening

plates or block grafting carry with it the risk of fixation failure and donor site morbidity respectively.

Several treatment modalities have been described for the management of recurrent TMJ dislocation. The surgeon must consider the patients suitability for surgery and possible aetiology when deciding the best approach to management. Current evidence supports the trial of ABI or modified dextrose as minimally invasive management. The success of surgical approaches (disc plication, eminectomy or eminoplasty) are equivocal, and should be tailored to the patient's situation.

Author contributions All authors made a significant contribution to this research and its publication. All authors have read and approved the final manuscript.

Data availability Raw data and further material is available on request from the corresponding author.

Compliance with ethical standards

Conflict of interest The authors declare that they have no conflicts of interest to declare.

Ethics approval This research was granted ethical approval from the Research Governance Unit of the St Vincent's Hospital Melbourne. LNR HREC reference number LNR/17/SVHM/19.

Consent for publication All authors and subjects involved in this research have consented for its publication

Publisher's note Springer Nature remains neutral with regard to jurisdictional claims in published maps and institutional affiliations.

References

1. de Feitas Silva L, Ribeiro NR, Faverani LP, Gondim RF, Maia RN (2016) Treatment of chronic recurrent temporomandibular joint dislocation. *J Craniofac Surg* 27(3):815
2. Le Goff F, Lefaucheur R, Fetter D, Rouille A, Maltête D (2016) Recurrent bilateral dislocation of the temporomandibular joint induced by clonazepam in a Parkinsonian patient. *Clin Neuropharmacol* 39(1):66
3. Oztel M, Bilski WM, Bilski A (2016) Botulinum toxin used to treat recurrent dislocation of the temporomandibular joint in a patient with osteoporosis. *Br J Oral Maxillofac Surg* 55(1):e1–e2

4. de Almeida VL, Vitorino Nde S, Nascimento AL, da Silva Júnior DC, de Freitas PH (2016) Stability of treatments for recurrent temporomandibular joint luxation: a systematic review. *Int J Oral Maxillofac Surg* 45(3):304–307
5. Moher D, Liberati A, Tetzlaff J, Altman DG, The PRISMA Group (2009) Preferred reporting items for systematic reviews and meta-analyses: the PRISMA statement. *PLoS Med* 6(7):e1000097. <https://doi.org/10.1371/journal.pmed1000097>
6. Murakami K, Hori S, Yamaguchi Y, Mercuri LG, Harayama N, Maruo S, Takahashi T (2015) Synovial plicae and temporomandibular joint disorders: surgical findings. *J Oral Maxillofac Surg* 73(5): 827–833
7. Liddell A, Perez DE (2015) Temporomandibular joint dislocation. *Oral Maxillofac Surg Clin North Am* 27(1):125–136. <https://doi.org/10.1016/j.coms.2014.09.009> Review
8. Sahoo NK, Bhardwaj PK (2013) Radiographic assessment of changes in articular tubercle after Dautrey's procedure. *J Oral Maxillofac Surg* 71(2):249–254
9. Sharma NK, Singh AK, Pandey A, Verma V, Singh S (2015) Temporomandibular joint dislocation. *Natl J Maxillofac Surg* 6(1):16–20
10. Undt G (2011) Temporomandibular joint eminectomy for recurrent dislocation. *Atlas Oral Maxillofac Surg Clin North Am* 19(2):189–206
11. Coser R, da Silveira H, Medeiros P, Ritto FG (2015) Autologous blood injection for the treatment of recurrent mandibular dislocation. *Int J Oral Maxillofac Surg* 44(8):1034–1037
12. Bayoumi AM, Al-Sebaei MO, Mohamed KM, Al-Yamani AO, Makrami AM (2014) Arthrocentesis followed by intra-articular autologous blood injection for the treatment of recurrent temporomandibular joint dislocation. *Int J Oral Maxillofac Surg* 43(10):1224–1228
13. Hegab AF (2013) Treatment of chronic recurrent dislocation of the temporomandibular joint with injection of autologous blood alone, intermaxillary fixation alone, or both together: a prospective, randomised, controlled clinical trial. *Br J Oral Maxillofac Surg* 51(8):813–817
14. Machon V, Abramowicz S, Paska J, Dolwick MF (2009) Autologous blood injection for the treatment of chronic recurrent temporomandibular joint dislocation. *J Oral Maxillofac Surg* 67(1): 114–119
15. Kato T, Shimoyama T, Nasu D, Kaneko T, Horie N, Kudo I (2007) Autologous blood injection into the articular cavity for the treatment of recurrent temporomandibular joint dislocation: a case report. *J Oral Sci* 49(3):237–239
16. Gupta D, Rana AS, Verma VK (2013) Treatment of recurrent TMJ dislocation in geriatric patient by autologous blood - a technique revisited. *J Oral Biol Craniofac Res* 3(1):39–41
17. Gulses A, Bayar GR, Aydintug YS, Sencimen M, Erdogan E, Agaoglu R (2013) Histological evaluation of the changes in temporomandibular joint capsule and retrodiscal ligaments following autologous blood injection. *J Craniomaxillofac Surg* 41(4):316–320
18. Candirli C, Yüce S, Cavus UY, Akin K, Cakir B (2012) Autologous blood injection to the temporomandibular joint: magnetic resonance imaging findings. *Imaging Sci Dent* 42(1):13–18
19. Candirli C, Yüce S, Yildm S, Sert H (2011) Histopathologic evaluation of autologous blood injection to the temporomandibular joint. *J Craniofac Surg* 22(6):2202–2204
20. Pinto AS, McVeigh KP, Bainton R (2009) The use of autologous blood and adjunctive 'face lift' bandage in the management of recurrent TMJ dislocation. *Br J Oral Maxillofac Surg* 47(4):323–324
21. Daif ET (2010) Autologous blood injection as a new treatment modality for chronic recurrent temporomandibular joint dislocation. *Oral Surg Oral Med Oral Pathol Oral Radiol Endod* 109(1):31–36
22. Vázquez Bouso O, Forteza González G, Mommsen J, Grau VG, Rodríguez Fernández J, Mateos Micas M (2010) Neurogenic temporomandibular joint dislocation treated with botulinum toxin: report of 4 cases. *Oral Surg Oral Med Oral Pathol Oral Radiol Endod* 109(3):e33–e37
23. Torres DE, McCain JP (2012) Arthroscopic electrothermal capsulorrhaphy for the treatment of recurrent temporomandibular joint dislocation. *Int J Oral Maxillofac Surg* 41(6):681–689
24. Zhou H, Hu K, Ding Y (2014) Modified dextrose prolotherapy for recurrent temporomandibular joint dislocation. *Br J Oral Maxillofac Surg* 52(1):63–66
25. Matsushita K, Abe T, Fujiwara T (2007) OK-432 (Picibanil) sclerotherapy for recurrent dislocation of the temporomandibular joint in elderly edentulous patients: case reports. *Br J Oral Maxillofac Surg* 45(6):511–513
26. Zachariah T, Neelakandan RS, Ahamed MI (2015) Disc Anchoring with an Orthodontic Mini-Screw for Chronic Meniscocondylar Dislocation of TMJ. *J Maxillofac Oral Surg* 14(3):735–744
27. Pentylala S, Mysore P, Moller D, Pentylala S, Kardovich R, Martino A, Proothi M (2014) Temporomandibular joint disorder and inner ear pruritus: resolution by eminectomy. *J Craniofac Surg* 25(5): 1840–1842
28. Martins WD, Ribas Mde O, Bisinelli J, França BH, Martins G (2014) Recurrent dislocation of the temporomandibular joint: a literature review and two case reports treated with eminectomy. *Cranio* 32(2):110–117 Review
29. Mayrink G, Olate S, Assis A, Sverzut A, de Moraes M (2012) Recurrent mandibular dislocation treated by eminectomy. *J Craniofac Surg* 23(5):e516–e520
30. Güven O (2009) Management of chronic recurrent temporomandibular joint dislocations: a retrospective study. *J Craniomaxillofac Surg* 37(1):24–29
31. Kahveci R, Simsek ME, Akın S, Ozbek S, Ozgenel GY, Gökmen ZG (2013) Treatment of recurrent temporomandibular joint dislocation. *J Maxillofac Oral Surg* 12(4):379–381
32. Da Costa Ribeiro R, dos Santos BJ Jr, Provenzano N, de Freitas PHL (2014) Dautrey's procedure: an alternative for the treatment of recurrent mandibular dislocation in patients with pneumatization of the articular eminence. *Int J Oral Maxillofac Surg* 43:465–469
33. Ying B, Hu J, Zhu S (2013) Modified Leclerc blocking procedure with miniplates and temporal fascial flap for recurrent temporomandibular joint dislocation. *J Craniofac Surg* 24(3):740–742
34. Gadre KS, Kaul D, Ramanojam S, Shah S (2010) Dautrey's procedure in treatment of recurrent dislocation of the mandible. *J Oral Maxillofac Surg* 68:2021–2024
35. Guarda-Nardini L, Palumbo B, Manfredini D, Ferronato G (2008) Surgical treatment of chronic temporomandibular joint dislocation: a case report. *Oral Maxillofac Surg* 12(1):43–46
36. Medra AM, Mahrous AM (2008) Glenotemporal osteotomy and bone grafting in the management of chronic recurrent dislocation and hypermobility of the temporomandibular joint. *BJOMS* 46: 119–122
37. Taglialatela Scafati C, Taglialatela Scafati S (2012) Role of orthognathic surgery in the treatment of recurrent mandibular dislocation: importance of mandibular ramus inclination. *J Craniofac Surg* 23(5):e420–e423
38. Ogita S, Tsuto T, Nakamura K, Deguchi E (1996) OK-432 therapy for lymphangioma in children: why and how does it work? *J Pediatr Surg* 31(4):477–480
39. Cottrell DA, Wolford LM (1993) The Mitek mini anchor in maxillofacial surgery. *J Oral Maxillofac Surg Educ Summaries and Outlines* 57(3):150
40. Myrhaug H. (1951) A new method of operation for habitual dislocation of the mandible. Review of former methods of treatment. Taylor & Francis

41. LeClerc G, Girard G (1943) Un nouveau procede de butee dans le traitement chirurgical de la luxation reidivante de la machoire inferieure. *Mem Acad Chir* 69:457–459
42. Güven O (2008) A clinical study on treatment of temporomandibular joint chronic recurrent dislocations by a modified eminoplasty technique. *J Craniofac Surg* 19(5):1275–1280
43. Chhabra S, Chhabra N (2011) Recurrent bilateral TMJ dislocation in a 20-month-old child: a rare case presentation. *J Indian Soc Pedod Prev Dent* 29(6 Suppl 2):S104–S106



Minerva Access is the Institutional Repository of The University of Melbourne

Author/s:

Tocaciu, Shreya

Title:

Surgical Management of Recurrent Temporomandibular Joint Dislocation - Systematic Literature Review and Development of a Treatment Protocol

Date:

2019

Persistent Link:

<http://hdl.handle.net/11343/233761>

File Description:

Final thesis file

Terms and Conditions:

Terms and Conditions: Copyright in works deposited in Minerva Access is retained by the copyright owner. The work may not be altered without permission from the copyright owner. Readers may only download, print and save electronic copies of whole works for their own personal non-commercial use. Any use that exceeds these limits requires permission from the copyright owner. Attribution is essential when quoting or paraphrasing from these works.