

## 福島県立医科大学 学術機関リポジトリ



Title	Successful management of preoperatively diagnosed torsion of a subserosal uterine fibroid by pneumoperitoneum laparoscopic single-port surgery
Author(s)	Endo, Yuta; Takahashi, Toshifumi; Matsumiya, Tamaki; Fukuda, Kaoru; Ueda, Makiko; Owada, Aya; Nomura, Shinji; Ota, Kuniaki; Hashimoto, Satoshi; Soeda, Shu; Nomura, Yasuhisa; Fujimori, Keiya; Tanaka, Mikio
Citation	Fukushima Journal of Medical Science. 65(3): 128-132
Issue Date	2019
URL	<a href="http://ir.fmu.ac.jp/dspace/handle/123456789/1058">http://ir.fmu.ac.jp/dspace/handle/123456789/1058</a>
Rights	© 2019 The Fukushima Society of Medical Science. This article is licensed under a Creative Commons [Attribution-NonCommercial-ShareAlike 4.0 International] license.
DOI	10.5387/fms.2019-18
Text Version	publisher

This document is downloaded at: 2020-09-02T18:40:39Z

[Case Report]

## Successful management of preoperatively diagnosed torsion of a subserosal uterine fibroid by pneumoperitoneum laparoscopic single-port surgery

Yuta Endo<sup>1,3</sup>, Toshifumi Takahashi<sup>2</sup>, Tamaki Matsumiya<sup>1</sup>, Kaoru Fukuda<sup>1</sup>, Makiko Ueda<sup>1</sup>,  
Aya Owada<sup>1</sup>, Shinji Nomura<sup>3</sup>, Kuniaki Ota<sup>2</sup>, Satoshi Hashimoto<sup>4</sup>, Shu Soeda<sup>3</sup>,  
Yasuhisa Nomura<sup>1</sup>, Keiya Fujimori<sup>3</sup> and Mikio Tanaka<sup>1</sup>

<sup>1</sup>Obstetrics and Gynecology, Ohta Nishinouchi Hospital, Fukushima, Japan, <sup>2</sup>Fukushima Medical Center for Children and Women, Fukushima Medical University, Fukushima, Japan, <sup>3</sup>Department of Obstetrics and Gynecology, Fukushima Medical University, Fukushima, Japan, <sup>4</sup>Obstetrics and Gynecology, Hoshi General Hospital, Fukushima, Japan

(Received July 3, 2019, accepted September 13, 2019)

### Abstract

**Objective :** Preoperative diagnosis and successful management of acute torsion of a subserosal fibroid by using appropriate imaging modalities and single-port laparoscopic surgery.

**Case report :** A 44-year-old nulliparous woman presented with lower abdominal pain. Computed tomography and magnetic resonance imaging with contrast enhancement revealed a tumor in the pouch of Douglas with a low contrast at the center and thin-rim enhancement. Torsion of a uterine subserosal fibroid was diagnosed preoperatively. Laparoscopic single-port surgery by pneumoperitoneum was performed. Torsion of the pedicle attached to the uterine wall was excised by bipolar coagulation and cut with scissors. The extirpated fibroid was extracted from the umbilical wound. The pneumoperitoneum single-port laparoscopic surgery was completed as a gynecologic emergency operation.

**Conclusion :** Torsional uterine fibroids are difficult to diagnose preoperatively as symptoms are nonspecific and need emergent surgical management as an acute abdomen. Preoperative diagnosis using appropriate imaging modalities is important to perform single-port laparoscopic surgery.

**Key words :** Laparoscopic myomectomy, laparoscopic single-site surgery, torsion of uterine fibroid

### Introduction

Uterine fibroids are benign gynecological neoplasms found in 20-30% of reproductive-aged women<sup>1</sup>. Most fibroids are asymptomatic. Exhibited symptoms are related to their number, size, and location. Typically, intramuscular fibroids that compress the uterine cavity cause hypermenorrhea. Subserosal fibroids are often asymptomatic and torsion is rare. Acute torsion of a subserosal fibroid presents as an acute abdomen and needs emergent treatment. If left unattended, torsion of the fibroid causes necrosis followed by peritonitis. However, accurate diagnosis of torsional sub-

serosal uterine fibroids is difficult as symptoms are nonspecific.

Laparoscopic surgery is common in acute abdomen cases. Laparoscopic myomectomy has been reported for management of torsional uterine subserosal fibroids<sup>2,3</sup>. However, there are few reports on the removal of torsional subserosal fibroids through single-port laparoscopic surgery. Herein, we report a torsional subserosal uterine fibroid diagnosed preoperatively by imaging modalities and successfully managed by single-port laparoscopic surgery.

---

Corresponding author : Toshifumi Takahashi E-mail : totakaha@fmu.ac.jp  
<https://www.jstage.jst.go.jp/browse/fms> <http://www.fmu.ac.jp/home/lib/F-igaku/>

## Case Presentation

A 44-year-old nulliparous woman presented at our hospital after lower abdominal pain for the past two days. She had rebound pain, an enlarged fist-sized uterus, and a solid, painful mass palpable in the Douglas pouch by pelvic examination. The solid and painful mass was considered to be uterine fibroids. Transvaginal ultrasonography showed a mass (62×47 mm) in the Douglas pouch. Her body temperature was 37.3°C. White blood cell count was 12,300/ $\mu$ L and serum C-reactive protein was 5.65 mg/dL. Peritonitis was diagnosed based on the results of physical examination and laboratory data. Imaging studies were performed to find the cause of the peritonitis. Abdominal computed tomography (CT) with contrast enhancement revealed a subserosal uterine fibroid with well-defined enhancement, whereas the tumor in the Douglas pouch had low contrast at the center and thin-rim enhancement (Figs. 1A and 1B). Magnetic resonance imaging (MRI) with gadolinium enhancement showed the same results as CT findings (Figs. 1C and 1D).

The pedicle of the fibroid was not confirmed by imaging studies. Putting these findings together, the diagnosis was torsion of a pedunculated subserosal uterine fibroid.

Single-port laparoscopic surgery under general anesthesia was performed immediately. An umbilical incision was made followed by the attachment of an EZ access device (Hakko Co. Ltd., Tokyo, Japan). The operation was performed through this device by three laparoscopic forceps under pneumoperitoneum laparoscopy. In the pelvic cavity, a small volume of ascites and two subserosal fibroids were seen on the posterior uterine wall. One of the subserosal fibroids located on the left side of the Douglas pouch appeared red and black (Fig. 2A). The bilateral adnexa were normal. The diagnosis of a torsional uterine subserosal fibroid was confirmed. The torsional fibroid was attached to the uterine posterior wall via the twisted pedicle and was adherent to the sigmoid colon and peritoneum. It appeared necrotic and was the suspected cause of inflammation. The twisted pedicle was cauterized with bipolar forceps and excised by scissors.

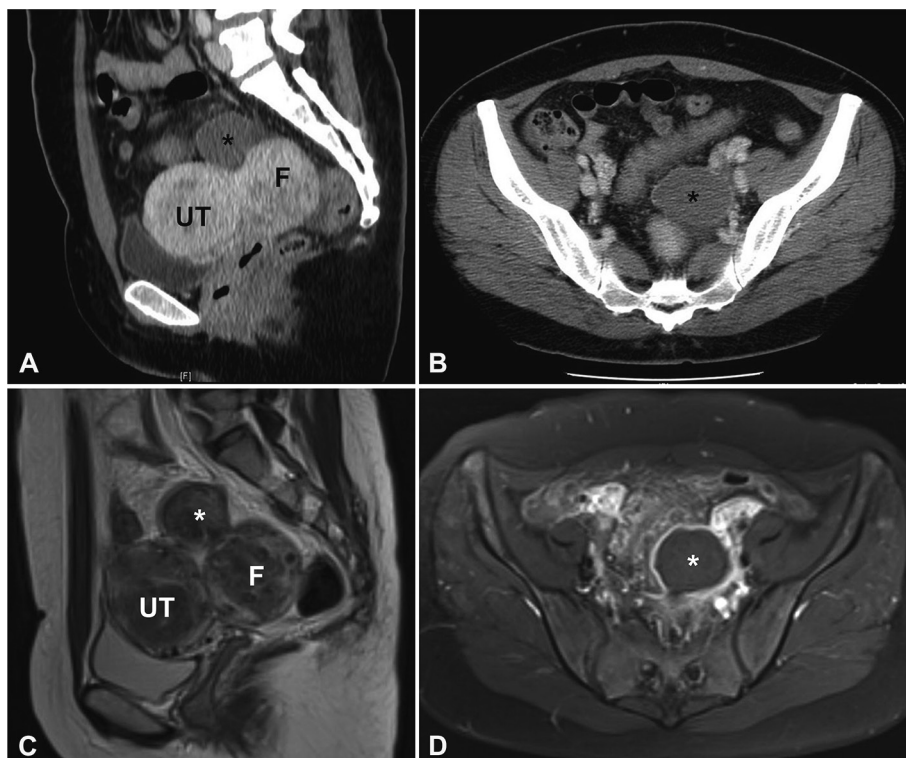


Fig. 1. Computed tomography (CT) and magnetic resonance imaging (MRI) of the torsional subserosal uterine fibroid

A : Sagittal CT scan with contrast enhancement shows enhancement of the subserosal fibroid (F) and hypo-enhancement of the mass (\*) attached to the uterus (UT). B : Axial CT scan with contrast enhancement shows thin-rim enhancement of the mass (\*). C : Sagittal T2-weighted MRI shows a subserosal fibroid (F) and the other tumor (\*). D : Axial T1-weighted fat-saturated image with contrast enhancement shows thin-rim enhancement of the mass (\*).

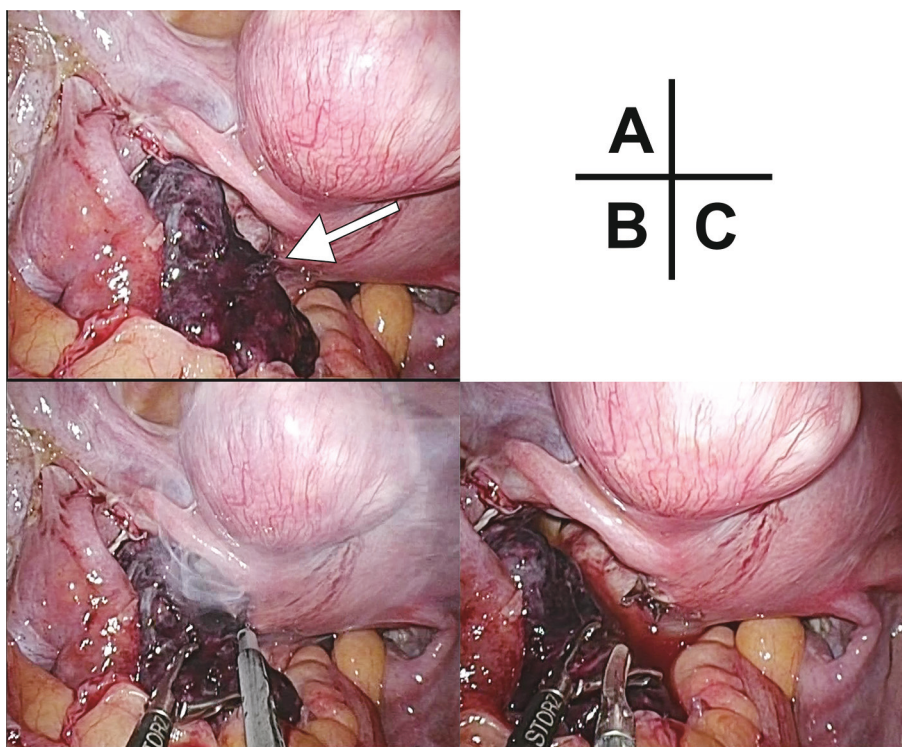


Fig. 2. Photographs of single-port laparoscopic surgery of a torsional subserosal uterine fibroid  
 A : Laparoscopic findings in the intrapelvic cavity. Necrotizing torsion of the subserosal uterine fibroid. The arrow indicates the pedicle attached to the posterior wall. B : Coagulation of the torsional pedicle with bipolar forceps. C : After cutting the pedicle with scissors.

sors. (Figs. 2B and 2C). We did not remove an additional subserosal fibroid attached to the fundus. The extirpated tumor was manually morcellated in the bag by a surgical scalpel and extracted through the umbilical wound. After suturing the umbilical wound with Vicryl 2-0 suture (Ethicon Inc., Sommerville, NJ, USA), the wound was pressed with a cotton ball.

Histopathological examination revealed a uterine leiomyoma with hemorrhagic necrosis. Recovery was uneventful and the patient was discharged three days postoperatively. Three months after the operation, the umbilical wound had healed completely (Fig. 3).

Patient consent and appropriate ethical review board approval was obtained for publication of this case report.

### Discussion

This is a rare case of acute torsion of a subserosal uterine fibroid, diagnosed preoperatively, and successfully managed by single-port laparoscopic surgery. To the best of our knowledge, this is the first report of single-port laparoscopic myomectomy under pneumoperitoneum for torsion of a subserosal

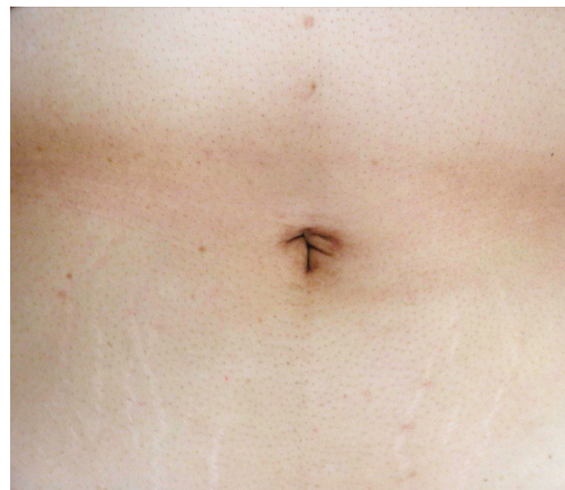

Fig. 3. Photograph of the umbilical wound site three months after single-port laparoscopic surgery  
 The umbilical wound healed three months after the operation.

uterine fibroid.

Preoperatively, acute torsion of a subserosal uterine fibroid was diagnosed by CT and MRI. As the clinical manifestations and physical findings are nonspecific, most reports of similar cases were only diagnosed intraoperatively<sup>2-4</sup>. Patients usually

complain of sudden onset, severe abdominal pain corresponding to ischemic changes and subsequent development of peritonitis. Preoperative diagnosis by imaging modalities is important for emergent operative decisions.

The primary imaging tool for acute abdomen is ultrasonography. However, diagnosing subserosal uterine fibroid torsion with ultrasonography is not easy. For diagnosing uterine fibroid torsion, color Doppler can be used to detect blood flow disruption to subserosal fibroids. However, this finding is not specific, and blood flow findings may not be observed when the pedicle of the subserosal fibroid is thin<sup>2</sup>. Other imaging modalities (CT and MRI) have better sensitivity and specificity for it. The contrast-enhanced CT findings are useful to diagnose torsion of subserosal fibroids. These fibroids have some specific features, such as poor contrast enhancement inside the fibroid, a thin rim enhancement, dark fan sign, (fan-shaped poor contrast enhancement in the uterine area adjacent to the subserosal fibroid), and ascites in the pelvic cavity<sup>1</sup>. These findings are attributed to blood flow blockage from the feeding vessel by pedicle torsion. The finding with the highest diagnostic sensitivity was ascites (100%), while the highest specificity was a dark fan sign (100%)<sup>1</sup>. In the present case, all specific imaging findings (poor contrast enhancement, thin rim enhancement, dark fan sign, and ascites) were observed.

MRI is superior to CT in evaluating the characteristics of uterine fibroids. MRI images of torsional subserosal fibroids have been reported to have similar findings to CT<sup>5</sup>. A twisted pedicle connecting the uterine corpus and fibroid has been detected by MRI<sup>6</sup>. Although the twisted pedicle was not observed by MRI in the present case, it is considered to have supplementary diagnostic value compared to CT. In this case, an additional MRI examination was performed after CT. Because patients with acute abdomen require emergent diagnosis, CT is the first choice for imaging. CT revealed that the acute abdomen was caused by pelvic masses. Then, MRI was performed to differentiate from torsion of the ovarian tumor.

Secondly, single-port laparoscopic surgery was performed to remove the twisted pedicle. This surgery has been used in various specialties including gynecologic surgery<sup>7</sup> and is superior to conventional laparoscopic surgery in cosmetic aspects<sup>8,9</sup>. In addition to cosmetic benefits, single-port laparoscopic surgery can easily remove a fibroid from the body cavity. In multi-port laparoscopic myomecto-

my, a 5-mm or 12-mm trocar is placed through the umbilical and abdominal incision, and it is necessary to use a power morcellator device for removing the fibroid from the body cavity. Fibroid morcellation with a power morcellator device can cause parasitic myoma<sup>10</sup>. In single-port laparoscopic myomectomy, the fibroid can be removed from the umbilical incision by manual incision without using a power morcellator device to prevent the occurrence of parasitic myoma. Moreover, reports show that laparoscopic single-site myomectomy outcomes are comparable to conventional multi-port laparoscopic myomectomy outcomes<sup>7,11</sup>. However, laparoscopic single-site surgery is more challenging than conventional multi-port laparoscopic surgery because of the limited motion and clashing between instruments<sup>7</sup>. Moreover, laparoscopic myomectomy requires suturing, which may be more difficult in single-port versus conventional multi-port laparoscopy. Previous reports state that the location and size of uterine fibroids are important considerations in single-site laparoscopic myomectomy<sup>12</sup>. Laparoscopic single-site myomectomy is feasible for <5 fibroids<sup>7</sup>. The present case was suitable for single-port laparoscopic myomectomy because the torsion of the fibroid was subserosal and intracorporeal suturing and tying were not required. Therefore, even with an inexperienced operator, laparoscopic single-site myomectomy may be a good option for pedunculated subserosal fibroids.

Takeda and Nakamura reported the first case of single-site laparoscopic myomectomy for torsion of a subserosal fibroid<sup>6</sup>. It was similar to the current case but was performed by an abdominal wall lifting system (gasless laparoscopy) without carbon dioxide insufflation<sup>6</sup>. The disadvantage of gasless laparoscopy is that the space in the abdominal cavity is narrower than in a pneumoperitoneum laparoscopy. In the current case, the single-site laparoscopic myomectomy was performed under pneumoperitoneum laparoscopy. This is possibly the first reported case report of single-site laparoscopic myomectomy under pneumoperitoneum for a torsional subserosal fibroid. Both gasless and pneumoperitoneum methods can be safely performed for single-port laparoscopic myomectomy.

Considering all the information available, it is important to make a differential diagnosis of uterine fibroid torsion before selection of the single-port laparoscopic surgery. When a patient with a fibroid complains of acute abdominal pain, it is usually due to other causes rather than uterine fibroids<sup>2</sup>. Therefore, it is necessary to exclude appendicitis,

gastroenteritis, torsion of ovarian tumor, pelvic inflammatory disease, ectopic pregnancy, ovarian bleeding, etc. Even when the symptom is due to uterine fibroids, the pain is mostly caused by red degeneration of fibroids<sup>1,2)</sup>. Medical history and pregnancy tests are important, and imaging modalities, such as CT, are decisive factors in the diagnosis of torsion of fibroids.

This is possibly the first report of a pneumoperitoneum single-site laparoscopic myomectomy of a torsional subserosal fibroid. Acute torsion of uterine fibroids is rare, however, preoperative diagnosis by imaging modalities is the key to performing single-site laparoscopic surgery.

### Disclosures

**Conflicts of interest :** authors have no conflicts of interest to declare.

### References

- Ohgiya Y, Seino N, Miyamoto S, *et al.* CT features for diagnosing acute torsion of uterine subserosal leiomyoma. *Jpn J Radiol*, **36** : 209-214, 2018.
- Kim HG, Song YJ, Na YJ, Choi OH. A case of torsion of a subserosal leiomyoma. *J Menopausal Med*, **19** : 147-150, 2013.
- Marcotte-Bloch C, Novellas S, Buratti MS, Caramella T, Chevallier P, Bruneton JN. Torsion of a uterine leiomyoma : MRI features. *Clin Imaging*, **31** : 360-362, 2007.
- Gupta S, Manyonda IT. Acute complications of fibroids. *Best Pract Res Clin Obstet Gynaecol*, **23** : 609-617, 2009.
- Iraha Y, Okada M, Iraha R, *et al.* CT and MR Imaging of Gynecologic Emergencies. *Radiographics*, **37** : 1569-1586, 2017.
- Takeda A, Nakamura H. Torsion of a Subserosal Myoma Managed by Gasless Laparoendoscopic Single-Site Myomectomy with In-Bag Manual Extraction. *Case Rep Obstet Gynecol*, **2016** : 7831270, 2016.
- Kim SK, Lee JH, Lee JR, Suh CS, Kim SH. Laparoendoscopic single-site myomectomy versus conventional laparoscopic myomectomy : a comparison of surgical outcomes. *J Minim Invasive Gynecol*, **21** : 775-781, 2014.
- Song T, Kim TJ, Cho J, *et al.* Cosmesis and body image after single-port access surgery for gynecologic disease. *Aust N Z J Obstet Gynaecol*, **52** : 465-469, 2012.
- Song T, Cho J, Kim TJ, *et al.* Cosmetic outcomes of laparoendoscopic single-site hysterectomy compared with multi-port surgery : randomized controlled trial. *J Minim Invasive Gynecol*, **20** : 460-467, 2013.
- Van der Meulen JF, Pijnenborg JM, Boomsma CM, Verberg MF, Geomini PM, Bongers MY. Parasitic myoma after laparoscopic morcellation : a systematic review of the literature. *BJOG*, **123** : 69-75, 2016.
- Kim JY, Kim KH, Choi JS, Lee JH. A prospective matched case-control study of laparoendoscopic single-site vs conventional laparoscopic myomectomy. *J Minim Invasive Gynecol*, **21** : 1036-1040, 2014.
- Yoon A, Kim TJ, Lee YY, *et al.* Laparoendoscopic single-site (LESS) myomectomy : characteristics of the appropriate myoma. *Eur J Obstet Gynecol Reprod Biol*, **175** : 58-61, 2014.