



### **Science Arts & Métiers (SAM)**

is an open access repository that collects the work of Arts et Métiers Institute of Technology researchers and makes it freely available over the web where possible.

This is an author-deposited version published in: <https://sam.ensam.eu>  
Handle ID: [.http://hdl.handle.net/10985/17856](http://hdl.handle.net/10985/17856)

#### **To cite this version :**

Félix P. KUHN, Antoine FEYDY, Nathalie LAUNAY, Marie-Martine LEFEVRE-COLAU, Serge POIRAudeau, Sébastien LAPORTE, Marc A. MAIER, Pavel LINDBERG - Kinetic DTI of the cervical spine: diffusivity changes in healthy subjects - Neuroradiology - Vol. 58, n°9, p.929-935 - 2016

Any correspondence concerning this service should be sent to the repository

Administrator : [archiveouverte@ensam.eu](mailto:archiveouverte@ensam.eu)



# Kinetic DTI of the cervical spine: diffusivity changes in healthy subjects

Félix P. Kuhn<sup>1</sup> · Antoine Feydy<sup>1,2</sup> · Nathalie Launay<sup>1</sup> · Marie-Martine Lefevre-Colau<sup>2,3</sup> · Serge Poiraudou<sup>2,3</sup> · Sébastien Laporte<sup>4</sup> · Marc A. Maier<sup>5,6</sup> · Pavel Lindberg<sup>5,6</sup>

## Abstract

**Introduction** The study aims to assess the influence of neck extension on water diffusivity within the cervical spinal cord. **Methods** IRB approved the study in 22 healthy volunteers. All subjects underwent anatomical MR and diffusion tensor imaging (DTI) at 1.5 T. The cervical cord was imaged in neutral (standard) position and extension. Segmental vertebral rotations were analyzed on sagittal T2-weighted images using the SpineView<sup>®</sup> software. Spinal cord diffusivity was measured in cross-sectional regions of interests at multiple levels (C1–C5).

**Results** As a result of non-adapted coil geometry for spinal extension, 10 subjects had to be excluded. Image quality of the remaining 12 subjects was good without any deteriorating artifacts. Quantitative measurements of vertebral rotation

angles and diffusion parameters showed good intra-rater reliability (ICC = 0.84–0.99). DTI during neck extension revealed significantly decreased fractional anisotropy (FA) and increased radial diffusivity (RD) at the C3 level and increased apparent diffusion coefficients (ADC) at the C3 and C4 levels ( $p < 0.01$  Bonferroni corrected). The C3/C4 level corresponded to the maximal absolute change in segmental vertebral rotation between the two positions. The increase in RD correlated positively with the degree of global extension, i.e., the summed vertebral rotation angle between C1 and C5 ( $R = 0.77$ ,  $p = 0.006$ ).

**Conclusion** Our preliminary results suggest that DTI can quantify changes in water diffusivity during cervical spine extension. The maximal differences in segmental vertebral rotation corresponded to the levels with significant changes in diffusivity (C3/C4). Consequently, kinetic DTI measurements may open new perspectives in the assessment of neural tissue under biomechanical constraints.

---

✉ Félix P. Kuhn  
Felix.Kuhn@usz.ch

<sup>1</sup> Service de Radiologie B, APHP, Centre Hospitalier Universitaire Cochin, Faculté de Médecine, Université Paris Descartes, 27 rue du Fbg St Jacques, 75679 Paris, France

<sup>2</sup> INSERM, U1153 Epidemiology and Biostatistics Sorbonne Paris Cité Center (CRESS), Epidémiologie clinique appliquées aux maladies ostéo-articulaires (Ecamo), Université Paris Descartes, Paris, France

<sup>3</sup> Service de Médecine Physique & de Réadaptation, APHP, Centre Hospitalier Universitaire Cochin, Faculté de Médecine, Université Paris Descartes, Paris, France

<sup>4</sup> Laboratoire de Biomécanique, Ecole Nationale Supérieure d'Arts et Métiers, Paris, France

<sup>5</sup> Centre de Psychiatrie et Neurosciences, INSERM U894, Paris, France

<sup>6</sup> FR3636 Neurosciences, CNRS, Université Paris Descartes, Sorbonne Paris Cité, Paris, France

**Keywords** Diffusion-weighted imaging (DWI) · Diffusion tensor imaging (DTI) · Cervical spine · Biomechanics

## Introduction

Diffusion tensor imaging (DTI) has been shown to complement morphological MRI in the assessment of neuronal integrity [1, 2]. Spinal DTI can detect subtle spinal cord damage of functional relevance in cervical spondylosis, even in the absence of corresponding signal alteration on T2-weighted (T2w) images [3]. Other studies revealed a correlation of DTI with clinical and electrophysiological measures in patient suffering from chronic spinal cord injury [4] or amyotrophic lateral sclerosis [5]. In addition, DTI can be used to identify and quantify Wallerian degeneration in descending motor

tracts after stroke [6] or to assess the functional integrity of peripheral nerves [2, 7].

A recent *ex vivo* DTI study with Monte Carlo simulations [8] suggested that axonal undulation in the spinal cord and the peripheral nervous system could influence quantitative diffusion measurements. Thus, movements of spine or tension forces on peripheral nerves may have an effect on the inter-axonal water diffusion within these neural structures. Application of DTI to the peripheral nervous system is technically challenging due to the small cross-sectional area of the nerve tissue. Regarding the spinal cord, upright low-field MR systems have been used for its dynamic assessment, but they provided limited signal-to-noise ratios [9], impeding reliable DTI measurements. Thus, to assess the effect of tension and/or compression on the cervical spinal cord, we propose DTI acquisitions in neutral supine position and during neck extension in a high-field whole body MR system.

To interpret potential dynamic changes in diffusivity within the spinal cord, biomechanical aspects have to be taken into consideration [10]. Quantification of segmental motion, reflected by an increase in the intervertebral angles during extension, may indicate the spinal cord level with the most prominent changes in axonal undulation. Nonetheless, the effect of segmental vertebral rotations may be influenced by the diameter of the spinal canal in neutral position and during extension [11–14].

Thus, the aim of the current study was to assess the influence of cervical spine extension and its corresponding biomechanical parameters on the diffusivity within the cervical spinal cord in healthy subjects.

## Methods

This prospective cross-sectional study was approved by the local institutional review board, and all subjects provided informed consent. Twenty-two healthy volunteers were examined (13 women and 9 men, age (mean  $\pm$  SD)  $52.1 \pm 7.2$  years, age range 34–61 years). Inclusion criteria were age older than 18 years, good physical health, no history of acute or chronic cervical back pain, no history of cervical spine trauma, and absence of clinical signs of spinal canal stenosis or cervical nerve root entrapment. Exclusion criteria were contraindication to MR, spinal canal stenosis [15], signs of myelopathy on T2-weighted (T2w) MR images [16], abnormal segmental motion (spondylolisthesis), and image artifacts relevant for further image processing.

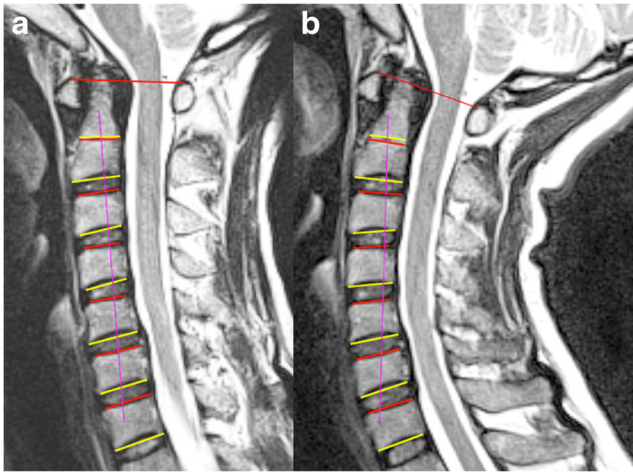
### Image acquisition

Morphological and diffusion tensor imaging of cervical spine was performed on a 1.5 T MR system (MAGNETOM Avanto, Siemens Healthcare, Erlangen, Germany). The cervical cord

was imaged in neutral position and during extension with a standard MR receive coil dedicated to spinal imaging. Extension was standardized by placing a foam roll posterior to the mid-cervical segment, resulting in a moderate neck extension. In order to minimize a potential technical bias, we acquired a second localizer for the modified position (extension) and adapted the axis of our DTI box again along the long axis of the spinal cord from C1 to C5. Sagittal and axial T2w turbo-spin echo images were acquired for anatomical correlation with the following sequence parameters: TR, 4080 ms; TE, 107 ms; echo-train length, 17; field of view,  $180 \times 180$  mm; image matrix,  $448 \times 336$ ; slice thickness, 3 mm; number of averages, 2; bandwidth, 190 Hz/Px. Single-shot echo-planar imaging (EPI) DTI was performed in the sagittal plane using 25 non-collinear gradient directions. Sensitivity encoding (SENSE) acceleration with a factor 2 was accomplished in order to reduce geometrical distortions [17]. All subjects were imaged under free breathing. Six spatial pre-saturation bands were placed to reduce ghosting artifacts from fat. *B* values were set at 0 and  $900 \text{ s/mm}^2$ ; TR, 2000 ms; TE, 95 ms; field of view,  $180 \times 180$  mm; image matrix,  $128 \times 128$ ; slice thickness, 3 mm; slice spacing, 0; resulting voxel size,  $1.4 \times 1.4 \times 3 \text{ mm}^3$ ; number of slices, 12; number of averages = 4; bandwidth, 1500 Hz/Px; total acquisition time, 4 min 26 s. These scan parameters are in accordance with recent literature [6, 18].

### Image analysis

Segmental vertebral rotation was analyzed on sagittal T2w images. For both positions, the SpineView<sup>®</sup> software (Paris, France) was used to manually identify the 4 corners of each cervical vertebral body from C2 to C7, and anterior and posterior points on the vertebral body of C1 (Fig. 1). From these points, the orientation of the vertebra was defined as the mean normed vector of the postero-anterior normed vectors of its superior and inferior end plates for level C2 to C7 and with the normed vector defined by the posterior and anterior points of C1. The mobility of each cervical level C<sub>k</sub>C<sub>k+1</sub> was then obtained using a dot product between the two normed vectors of C<sub>k+1</sub> vertebra for 2 different spinal orientations, calculated after alignment of the 2 normed vectors of the C<sub>k</sub> vertebra. The vertebral rotation angle was calculated between adjacent vertebrae. Two separate readers performed the measurements independently of each other in order to calculate inter-reader reliability. The width of the spinal canal in neutral position and during extension was measured at each level on sagittal T2w images according to Pavlov's ratio, i.e., the ratio of the diameter of the spinal canal to the diameter of the vertebral body [19], and to the space available for the cord (SAC), i.e., the ratio of the diameter of the spinal cord to the diameter of the spinal canal [20].



**Fig. 1** Sagittal T2w turbo-spin echo MR images in the neutral position (a) and during neck extension (b). The SpineView® software was used to analyze the segmental vertebral rotation angles of the cervical spine. Superior (red) and inferior (yellow) end plates were estimated for each vertebral body. The pink line shows the best fit through mid-point of vertebral bodies

Prior to further quantitative analyses, all DTI images were examined for geometrical distortions and other artifacts such as ghosting. In relation to a non-adapted coil geometry (standard MR receive coil) quantitative assessment of water diffusion was limited to the levels C1–C5. Spinal cord diffusivity parameters such as fractional anisotropy (FA), apparent diffusion coefficient (ADC), axial diffusivity (AD), and radial diffusivity (RD) were measured on a voxel-by-voxel basis (MedINRIA software, Version 1.9.0, Sophia Antipolis, France). Two independent readers assessed the reliability of the quantitative measurements by drawing whole spinal cord cross-section regions of interest (ROI) on the axial b0 images (C1–C5). To limit partial volume effects, i.e., inclusion of voxels containing cerebrospinal fluid (CSF), voxels extending into the CSF were excluded during ROI placement and only voxels with main eigenvectors ( $\lambda_1$ ) in the cranio-caudal direction were considered for further processing. The measured diffusion values include ascending and descending tracts as well as central grey matter.

### Statistical analysis

All statistical tests were performed using the STATISTICA software (Version 10, StatSoft, Inc., Tulsa, OK, USA). Inter-reader reliability of the DTI measurements and the biomechanical analyses were evaluated by calculating intra-class correlation coefficients (ICCs). ICC values were interpreted according to Kundel and Polansky [21]. Means of summed vertebral rotation angles between subjects with and without artifacts were assessed with independent sample *t* tests. Differences of diffusion parameters between the neutral position and extension were evaluated using general linear model

ANOVAs with two within-group factors: level (C1–C5) and position (neutral/extension). Bonferroni post hoc tests were used to investigate position differences at each level. Pearson correlation tests were performed between DTI variables showing significant effects of position and summed vertebral rotation angle. A non-parametric sign test was used to test whether subjects had increased or decreased vertebral rotation angles between the two positions at a single level. Statistical significance levels were set at  $\alpha=0.05$ .

### Results

As a result of non-adapted coil geometry for cervical spine extension, 10 subjects had to be excluded from further analysis due to various artifacts (predominantly ghosting and aliasing). Image quality of the remaining 12 subjects was good without any deteriorating artifacts. The means of the summed vertebral rotation angles between subjects with and without artifacts did not show any significant difference (mean  $\pm$  SD,  $6.8 \pm 7.6$  and  $3.7 \pm 8.2^\circ$ , respectively;  $p=0.39$ ). None of the patients had to be excluded due to spinal canal stenosis, signs of cervical cord myelopathy, or abnormal segmental motion.

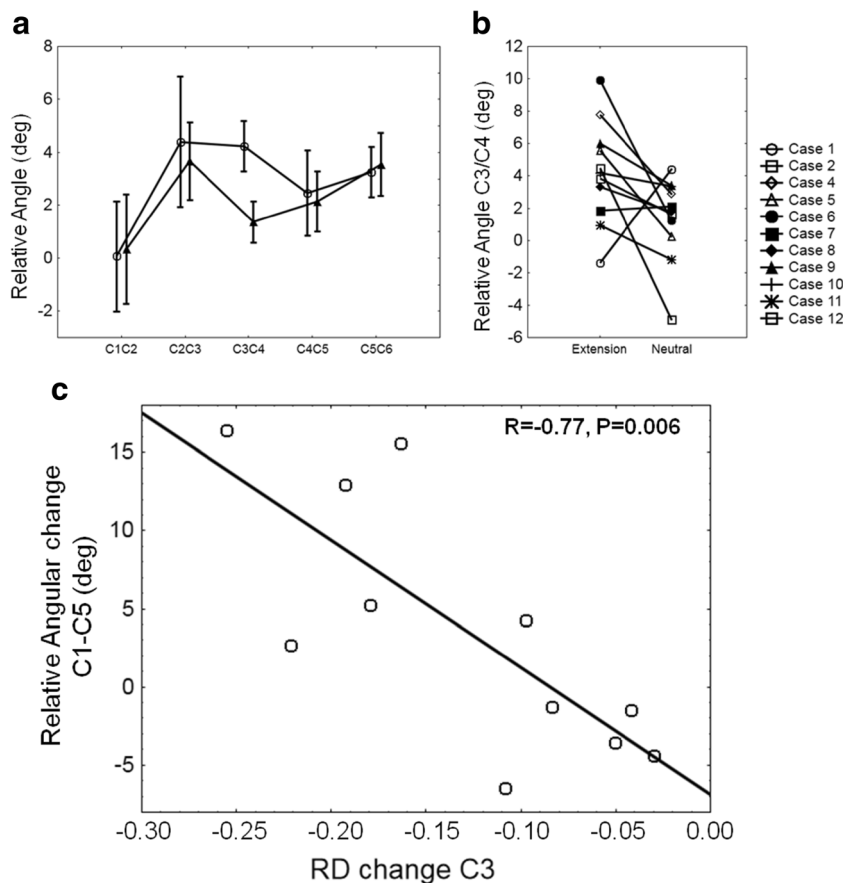
### Biomechanics

Vertebral rotation angle measurements showed good inter-rater reliability (ICC=0.84). A maximal absolute change in segmental vertebral rotation of  $2.9 \pm 4.2^\circ$  between neutral position and extension was found at the C3/C4 level, however without reaching statistical significance ( $p=0.14$ ; Fig. 2a). At this level, 9 out of 11 subjects (82 %) showed an increase in the local vertebral rotation angle (sign test,  $p=0.07$ ; Fig. 2b). Pavlov's ratio across all levels was decreased in extension (mean  $\pm$  SD,  $0.88 \pm 0.13$  in neutral position,  $0.86 \pm 0.12$  in extension) but not to a significant degree ( $p=0.19$ ). The space available for the cord (SAC) did not show any group difference between the two positions ( $p=0.53$ ).

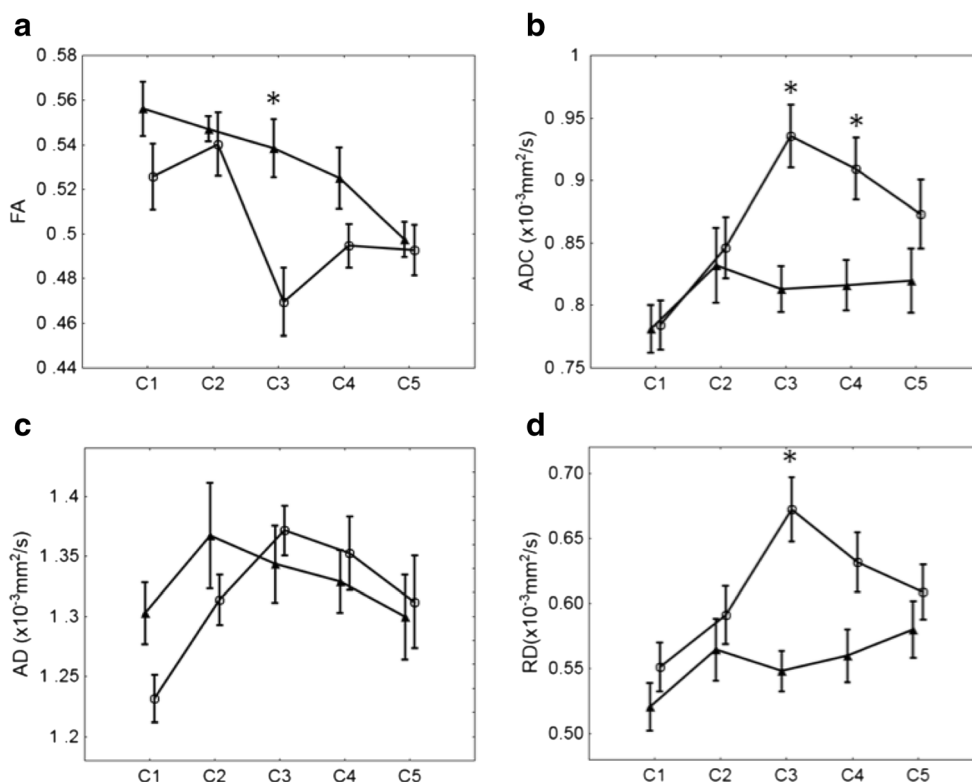
### Diffusion tensor imaging

Quantitative DTI measurements showed good inter-rater reliability for FA, ADC, AD, and RD (ICC 0.92, 0.96, 0.99, and 0.86, respectively). ANOVA indicated an interaction between position (neutral/extension) and level (C1–C5) for FA ( $p=0.021$ ), ADC ( $p=0.003$ ), AD ( $p=0.015$ ), and RD ( $p=0.010$ ) (Fig. 3). Bonferroni post hoc tests revealed a significant decrease in FA during extension at the C3 level ( $p=0.001$ ; Fig. 3a). ADC increased significantly during extension at the levels C3 and C4 (Bonferroni corrected  $p<0.01$ ; Fig. 3b). AD did not show any significant change after Bonferroni post hoc correction (Fig. 3c). RD increased significantly during extension at the C3 level (Bonferroni corrected  $p=0.0001$ ; Fig. 3d). Post hoc ANOVA

**Fig. 2** **a** Relative vertebral angle (mean  $\pm$  SE) in neutral position (filled triangles) and extension (open circles) across cervical levels calculated using Spine View®. The maximal absolute change in segmental vertebral rotation between neutral position and extension was found at the C3/C4 level. **b** At C3/C4 level, 82 % of the healthy volunteers showed an increase in the local vertebral rotation angle. **c** At the C3 level, the change in RD (extension-neutral) correlated negatively with the degree of extension, i.e., the summed vertebral rotation angle between C1 and C5. Subjects with greater vertebral angle during extension (compared to neutral) showed a greater increase in RD at C3 level



**Fig. 3** Changes in FA, ADC, AD, and RD between neutral position and extension. **a** Significant decrease in FA (mean  $\pm$  SE) during extension (open circles) compared to neutral (filled triangles) at the C3 level ( $*p < 0.001$ ). **b** ADC increased during extension at C3 and C4 levels ( $*p < 0.01$ ). **c** No significant changes in AD were found. **d** Significant increase in RD during extension at the C3 level ( $*p < 0.0001$ )



showed an equal number of voxels included in ROIs across levels in neutral position and extension (position  $F=1.9$ ,  $p=0.19$ ; position  $\times$  level  $F=0.49$ ,  $p=0.75$ ).

### Correlation of biomechanics and DTI

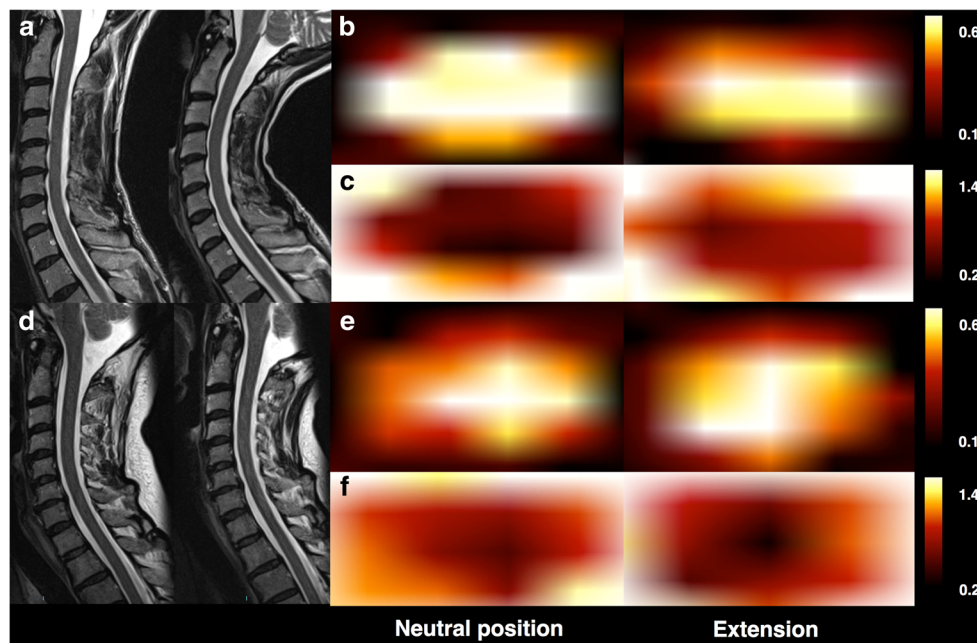
At levels C3 and C4, the increase of RD correlated positively with the degree of overall extension, i.e., the summed vertebral rotation angle between C1 and C5 ( $R=0.77$  with  $p=0.006$  at C3, Fig. 2c; and  $R=0.61$  with  $p=0.047$  at C4). No correlation was found at the levels C1, C2, and C5. Although not significant, FA changes (neutral/extension) showed a trend for a positive correlation with the summed vertebral rotation angles ( $R=0.53$ ,  $p=0.09$ ). This is illustrated in Fig. 4, which shows larger RD and FA changes at the C3 level between the neutral position and extension for a subject with a large-summed vertebral rotation angle (A, B, C) and smaller RD and FA changes for a subject with a small-summed vertebral rotation angle (D, E, F).

### Discussion

Diffusion tensor imaging revealed changes in diffusivity within the cervical spinal cord during neck extension in healthy subjects. To our best knowledge, this is the first in vivo study

demonstrating alteration in water diffusion in human neural tissue after biomechanical alterations. The application of DTI to the spinal cord is technically challenging due to the rather small cross-sectional area of the spinal cord, cardiac and respiratory motion, and varying magnetic susceptibility [22]. Nonetheless, after exclusion of artifact-deteriorated images, quantitative DTI measurements were found to be robust with good inter-rater reliability.

Based on studies by Breig [23] and Shacklock [24] describing predominant compression forces on the cervical spinal cord during posterior bending, Nilsson [8] proposed an increase in axonal undulation in the spinal cord during cervical spine extension. Our results are in line with this assumption, revealing a significant segmental decrease of FA and a significant increase of ADC and RD after neck extension. These alterations coincided with the level of maximal absolute change in segmental vertebral rotation between the two positions (observed at the C3/C4 level). In addition, RD at this level correlated negatively with the degree of overall extension, i.e., the summed vertebral rotation angle between C1 and C5. A decrease in FA, i.e., the degree of anisotropic water diffusion along the axons, may indicate more undulated nervous fibers as previously described in the referenced analytical model with Monte Carlo simulations [8]. AD reflects the principal eigenvector ( $\lambda_1$ ) of the calculated diffusion tensor, RD the mean of the remaining two eigenvectors perpendicular



**Fig. 4** Color-coded alterations in FA and RD within the whole spinal cord cross-section ROIs at the C3 level between the neutral position and extension (image interpolation implemented in the MedINRIA DTI viewing tool; quantitative analyses performed on raw data). The changes in FA and RD are proportional to the summed vertebral rotational angle. In a subject with a large-summed vertebral rotation

angle ( $16.4^\circ$ ) (a), changes in FA (b) and RD (c) are larger than changes in FA (e) and RD (f) in a subject with a small negative-summed vertebral rotation angle ( $-3.5^\circ$ ) (d). The calibration bar reflects FA values between 0.1 (black) and 0.6 (yellow) and RD values between 0.2 (black) and 1.4 (yellow), respectively

to  $\lambda_1$ , i.e.,  $(\lambda_2 + \lambda_3)/2$ , and ADC the summation of all three eigenvectors  $\lambda_1 + \lambda_2 + \lambda_3$ . Consequently, the increase of ADC and RD is congruent to the decrease in FA, yet reflecting different aspects of diffusion properties. Interestingly, RD has been shown to be the most sensitive parameter for detection of lateral spinal cord compression in patients suffering from cervical spondylosis [3], a phenomenon that primarily affects the myelin sheath [2]. On the contrary, and consistent with our results, AD is primarily affected by axonal pathologies, rather than by neuronal compression [25].

In order to minimize a potential technical bias regarding our non-isotropic voxels and the positional change, we acquired a second localizer for the modified position (extension) and adapted the axis of our DTI box again along the long axis of the spinal cord from C1 to C5. Our statistical analysis showed an equal number of voxels included in ROIs across levels in neutral position and during extension. Although a change in the axis of the ROI to the diffusion DTI matrix between neutral position and extension cannot be fully ruled out, this result suggests a constant spinal cord volume in the two positions. In addition, the applied 25 non-collinear directions ensured good sampling of diffusion within 3D space, thus potential directional alterations of nerve tracts between the two positions should not influence the measured parameters to a significant degree.

Anatomical characteristics may influence biomechanics of the spine [12, 26]. However, the Pavlov ratios and the SAC measurements did not reveal any distinct alterations in spinal canal diameter during cervical spine extension. Interestingly, at C3/4, the level with the maximal change in segmental vertebral rotation, 82 % of the subjects showed an increase of the rotation angle after moderate neck extension. This local change might indicate a more consistent feature of biomechanics in the healthy spine, although the results need to be replicated.

The examined effect of axonal undulation on water diffusivity may play a role in DTI imaging when investigating the spine but also when assessing the peripheral nervous system. Consequently, standardized positioning of the patient in the MR scanner is a prerequisite in order to generate reliable and reproducible DTI data. It has to be taken into consideration that the degree of traction and/or compression may alter DTI measurements also in the periphery, for instance in the optic, ulnar, or sciatic nerves. Recently, cervical nerve root displacement and strain during upper limb neural tension testing has been confirmed in cadavers [27, 28]. Thus, nerve root entrapment may alter quantitative DTI values not only by direct compression [29] but potentially also by nerve displacement and tension.

### Limitations

The number of healthy volunteers in this pilot study was rather small, notably after exclusion of images with

interfering artifacts due to non-adapted coil geometry. The same constraints permitted only moderate cervical spine extension and a quantitative assessment of water diffusion limited to the levels C1–C5. More pronounced extension might reveal more distinct changes in the measured diffusion parameters, but a better-adapted or flexible MR coil is advocated. With respect to previous studies [8, 23, 24], describing predominant axial compression forces on the cervical spinal cord during extension, whole cross-section ROIs were used for our measurements. In regard to the exact distribution of compression and distraction forces on the spinal cord during bending, further in vivo studies with a focus on the segment C3/4 and with a high isotropic spatial resolution are required to examine the relationship of anatomical and biomechanical characteristics with the axial distribution of these two components and to confirm our preliminary results by further minimizing a potential technical bias. This would allow investigation of potential differences between the ventral and dorsal spinal cord and between the white and gray matter. In addition, to analyze the effects of cervical spine flexion, we encourage further studies with a more adapted MR coil or advanced artifact suppression techniques.

### Conclusion

Our preliminary results suggest that diffusion tensor imaging can detect and quantify changes in water diffusivity during cervical spine extension in healthy subjects. The evoked effect of axonal undulation [8] may play a role in DTI imaging when investigating the cervical spine in patients with abnormal biomechanical constraints (e.g., in spondylotic myelopathy) and potentially also when assessing the peripheral nervous system. Further studies are warranted to assure that posture-induced cervical diffusion changes are completely attributable to biological causes and not influenced by technical constraints. Nonetheless, the measured effect has to be taken into consideration when assessing the reproducibility of DTI measurements.

**Acknowledgments** FPK received a research grant (Advanced Postdoc Mobility) from the Swiss National Science Foundation. This study was in part supported by grants to Pável Lindberg of the 'Institut pour la Recherche sur la Moelle Epinière et l'Encéphale' (IRME, Paris). The authors thank 'URC-CIC Paris Centre' for implementation and monitoring of the study.

**Compliance with ethical standards** We declare that all human and animal studies have been approved by the local institutional review board, Comité de Protection des Personnes, Île-de-France 3, and have therefore been performed in accordance with the ethical standards laid down in the 1964 Declaration of Helsinki and its later amendments. We declare that all patients gave informed consent prior to inclusion in this study.

**Conflict of interest** We declare that we have no conflict of interest.

## References

- Breckwoldt MO, Stock C, Xia A, Heckel A, Bendszus M, Pham M, Heiland S, Baumer P (2015) Diffusion tensor imaging adds diagnostic accuracy in magnetic resonance neurography. *Investig Radiol* 50(8):498–504. doi:10.1097/RLL.0000000000000156
- Heckel A, Weiler M, Xia A, Ruetters M, Pham M, Bendszus M, Heiland S, Baumer P (2015) Peripheral nerve diffusion tensor imaging: assessment of axon and myelin sheath integrity. *PLoS One* 10(6):e0130833. doi:10.1371/journal.pone.0130833
- Lindberg PG, Sanchez K, Ozcan F, Rannou F, Poiraudou S, Feydy A, Maier MA (2015) Correlation of force control with regional spinal DTI in patients with cervical spondylosis without signs of spinal cord injury on conventional MRI. *Eur Radiol*. doi:10.1007/s00330-015-3876-z
- Petersen JA, Wilm BJ, von Meyenburg J, Schubert M, Seifert B, Najafi Y, Dietz V, Kollias S (2012) Chronic cervical spinal cord injury: DTI correlates with clinical and electrophysiological measures. *J Neurotrauma* 29(8):1556–1566. doi:10.1089/neu.2011.2027
- Iglesias C, Sangari S, El Mendili MM, Benali H, Marchand-Pauvert V, Pradat PF (2015) Electrophysiological and spinal imaging evidences for sensory dysfunction in amyotrophic lateral sclerosis. *BMJ Open* 5(2):e007659. doi:10.1136/bmjopen-2015-007659
- Lindberg PG, Bensmail D, Bussel B, Maier MA, Feydy A (2011) Wallerian degeneration in lateral cervical spinal cord detected with diffusion tensor imaging in four chronic stroke patients. *J Neuroimaging* 21(1):44–48. doi:10.1111/j.1552-6569.2009.00409.x
- Lindberg PG, Feydy A, Le Viet D, Maier MA, Drape JL (2013) Diffusion tensor imaging of the median nerve in recurrent carpal tunnel syndrome—initial experience. *Eur Radiol* 23(11):3115–3123. doi:10.1007/s00330-013-2986-8
- Nilsson M, Latt J, Stahlberg F, van Westen D, Hagslatt H (2012) The importance of axonal undulation in diffusion MR measurements: a Monte Carlo simulation study. *NMR Biomed* 25(5):795–805. doi:10.1002/nbm.1795
- Khalil JG, Nassr A, Maus TP (2012) Physiologic imaging of the spine. *Radiol Clin N Am* 50(4):599–611. doi:10.1016/j.rcl.2012.04.004
- Oe S, Togawa D, Nakai K, Yamada T, Arima H, Banno T, Yasuda T, Kobayasi S, Yamato Y, Hasegawa T, Yoshida G, Matsuyama Y (2015) The influence of age and sex on cervical spinal alignment among volunteers aged over 50. *Spine (Phila Pa 1976)* 40(19):1487–1494. doi:10.1097/BRS.0000000000001071
- Lindberg PG, Feydy A, Sanchez K, Rannou F, Maier MA (2012) Measures of spinal canal stenosis and relationship to spinal cord structure in patients with cervical spondylosis. *J Neuroradiol* 39(4):236–242. doi:10.1016/j.neurad.2011.09.004
- Schmid MR, Stucki G, Duewell S, Wildermuth S, Romanowski B, Hodler J (1999) Changes in cross-sectional measurements of the spinal canal and intervertebral foramina as a function of body position: in vivo studies on an open-configuration MR system. *AJR Am J Roentgenol* 172(4):1095–1102. doi:10.2214/ajr.172.4.10587155
- Morita D, Yukawa Y, Nakashima H, Ito K, Yoshida G, Machino M, Kanbara S, Iwase T, Kato F (2015) Dynamic changes in the cross-sectional area of the dural sac and spinal cord in the thoracic spine. *Eur Spine J*. doi:10.1007/s00586-015-4173-x
- Bartlett RJ, Hill CA, Rigby AS, Chandrasekaran S, Narayanamurthy H (2012) MRI of the cervical spine with neck extension: is it useful? *Br J Radiol* 85(1016):1044–1051. doi:10.1259/bjr/94315429
- Ulbrich EJ, Schraner C, Boesch C, Hodler J, Busato A, Anderson SE, Eigenheer S, Zimmermann H, Sturzenegger M (2014) Normative MR cervical spinal canal dimensions. *Radiology* 271(1):172–182. doi:10.1148/radiol.13120370
- You JY, Lee JW, Lee E, Lee GY, Yeom JS, Kang HS (2015) MR classification system based on axial images for cervical compressive myelopathy. *Radiology* 276(2):553–561. doi:10.1148/radiol.2015142384
- Jaermann T, Pruessmann KP, Valavanis A, Kollias S, Boesiger P (2006) Influence of SENSE on image properties in high-resolution single-shot echo-planar DTI. *Magn Reson Med* 55(2):335–342. doi:10.1002/mmm.20769
- Lindberg PG, Feydy A, Maier MA (2010) White matter organization in cervical spinal cord relates differently to age and control of grip force in healthy subjects. *J Neurosci* 30(11):4102–4109. doi:10.1523/JNEUROSCI.5529-09.2010
- Pavlov H, Torg JS, Robie B, Jahre C (1987) Cervical spinal stenosis: determination with vertebral body ratio method. *Radiology* 164(3):771–775. doi:10.1148/radiology.164.3.3615879
- Presciutti SM, DeLuca P, Marchetto P, Wilsey JT, Shaffrey C, Vaccaro AR (2009) Mean subaxial space available for the cord index as a novel method of measuring cervical spine geometry to predict the chronic stinger syndrome in American football players. *J Neurosurg Spine* 11(3):264–271. doi:10.3171/2009.3.SPINE08642
- Kundel HL, Polansky M (2003) Measurement of observer agreement. *Radiology* 228(2):303–308. doi:10.1148/radiol.2282011860
- Wilm BJ, Gamper U, Henning A, Pruessmann KP, Kollias SS, Boesiger P (2009) Diffusion-weighted imaging of the entire spinal cord. *NMR Biomed* 22(2):174–181. doi:10.1002/nbm.1298
- Breig (1960) Biomechanics of the central nervous system. Almqvist & Wiksell, Stockholm
- Shacklock M (2007) Biomechanics of the nervous system. Neurodynamic Solutions, Adelaide
- Budde MD, Xie M, Cross AH, Song SK (2009) Axial diffusivity is the primary correlate of axonal injury in the experimental autoimmune encephalomyelitis spinal cord: a quantitative pixelwise analysis. *J Neurosci* 29(9):2805–2813. doi:10.1523/JNEUROSCI.4605-08.2009
- Bartlett RJ, Rigby AS, Joseph J, Raman A, Kunnacherry A, Hill CA (2013) Extension MRI is clinically useful in cervical myelopathy. *Neuroradiology* 55(9):1081–1088. doi:10.1007/s00234-013-1208-z
- Lohman CM, Gilbert KK, Sobczak S, Brismee JM, James CR, Day M, Smith MP, Taylor L, Dugailly PM, Pendergrass T, Sizer PJ (2015) 2015 young investigator award winner: cervical nerve root displacement and strain during upper limb neural tension testing: part 1: a minimally invasive assessment in unembalmed cadavers. *Spine (Phila Pa 1976)* 40(11):793–800. doi:10.1097/BRS.0000000000000686
- Lohman CM, Gilbert KK, Sobczak S, Brismee JM, James CR, Day M, Smith MP, Taylor L, Dugailly PM, Pendergrass T, Sizer PJ (2015) 2015 young investigator award winner: cervical nerve root displacement and strain during upper limb neural tension testing: part 2: role of foraminal ligaments in the cervical spine. *Spine (Phila Pa 1976)* 40(11):801–808. doi:10.1097/BRS.0000000000000687
- Eguchi Y, Ohtori S, Orita S, Kamoda H, Arai G, Ishikawa T, Miyagi M, Inoue G, Suzuki M, Masuda Y, Andou H, Takaso M, Aoki Y, Toyono T, Watanabe A, Takahashi K (2011) Quantitative evaluation and visualization of lumbar foraminal nerve root entrapment by using diffusion tensor imaging: preliminary results. *AJNR Am J Neuroradiol* 32(10):1824–1829. doi:10.3174/ajnr.A2681