

Complement dysregulation in glomerulonephritis

Kati Kaartinen^a, Adrian Safa^{b,c}, Soumya Kotha^{b,c}, Giorgio Ratti^{b,c}, Seppo Meri^{b,c,d,*}

^a Department of Nephrology, Abdominal Center, Helsinki University Central Hospital, Helsinki, Finland

^b Department of Biomedical Sciences, Humanitas University, Milan, Italy

^c Department of Bacteriology and Immunology, Translational Immunology Research Program, University of Helsinki, Helsinki, Finland

^d HUSLAB, Helsinki University Central Hospital, Helsinki, Finland

ARTICLE INFO

Keywords:

Complement
IgA glomerulonephritis
IgA nephropathy
C3 glomerulopathy
C3 glomerulonephritis
Dense deposit disease
C3 nephritic factor
Factor H
Factor H-related protein
FHR
Hemolytic uremic syndrome
Proteinuria
Eculizumab
Membranoproliferative glomerulonephritis
C3GN
aHUS
C3bBb
Plasmapheresis
Streptococcus
Sialic acid

ABSTRACT

Glomerulonephritis (GN) refers to a group of renal diseases affecting the glomeruli due to the damage mediated by immunological mechanisms. A large proportion of the disease manifestations are caused by disturbances in the complement system. They can be due to genetic errors, autoimmunity, microbes or abnormal immunoglobulins, like modified IgA or paraproteins. The common denominator in most of the problems is an overactive or misdirected alternative pathway complement activation. An assessment of kidney function, amount of proteinuria and hematuria are crucial elements to evaluate, when glomerulonephritis is suspected. However, the cornerstones of the diagnoses are renal biopsy and careful examination of the complement abnormality. Differential diagnostics between the various forms of GN is not possible based on clinical features, as they may vary greatly. This review describes the known mechanisms of complement dysfunction leading to different forms of primary GN (like IgA glomerulonephritis, dense deposit disease, C3 glomerulonephritis, post-infectious GN, membranous GN) and differences to atypical hemolytic uremic syndrome. It also covers the basic elements of etiology-directed therapy and prognosis of the most common forms of GN. Common principles in the management of GN include treatment of hypertension and reduction of proteinuria, some require immunomodulating treatment. Complement inhibition is an emerging treatment option. A thorough understanding of the basic disease mechanism and a careful follow-up are needed for optimal therapy.

1. Introduction

Complement activation and its regulation have been considered as complex phenomena. This has possibly delayed the general understanding of the complement system as a direct primary cause or as the main effector mechanism for kidney injury. In this review we will describe different forms of primary GN, where complement is involved. Usually the complement attack influences the function of the glomeruli. The glomerulus is an essential part of the nephron. Primary urine is filtered through the glomerulus and continues to the tubule, where reabsorption of urine components occurs. If renal disease is mainly affecting glomeruli, it is called glomerulonephritis. The targets in glomeruli include capillary endothelial cells, basement membrane, mesangial cells and the podocytes with their foot processes. Vast damage in glomeruli eventually affects the other parts of the nephron and in

end-stage renal disease (ESRD) it may be impossible to define the origin of the disease [1]. Some glomerulonephritides may damage only some glomeruli (focal damage), others may affect all glomeruli (diffuse damage). Global damage destroys the whole glomerulus, whereas segmental injury affects only parts of the glomerulus [2]. The nomenclature of different forms of GN is often taken directly from the histological description. Light microscopy (LM) in combination with immunofluorescence (IF) microscopy forms the basics of differential diagnostics, and electron microscopy (EM) has traditionally been considered to complete the final diagnosis [3]. For every patient commencing renal replacement therapy due to glomerulonephritis there are about 11 subjects with biopsy-proven glomerulonephritis [4]. In general, glomerulonephritides cause approximately 20% of the total burden of chronic kidney disease [1].

Glomerulonephritis can be caused by many different factors. In most

* Corresponding author at: Department of Bacteriology and Immunology, Haartman Institute, PO Box 21, FI-00014, University of Helsinki, Finland
E-mail address: seppo.meri@helsinki.fi (S. Meri).

cases, however, the damage is immune-mediated with a variable impact from genetic and environmental factors [5]. Primary glomerulonephritides are diseases limited to kidneys, but glomerular damage can also be part of a systemic illness, like vasculitis or systemic lupus erythematosus. In the latter, circulating antigen-antibody or DNA-histone complexes and their accumulation into vascular walls are believed to be a central mechanism.

The diagnosis of glomerulonephritis requires kidney biopsy, and it is not possible to recognize various glomerulonephritides solely on the basis of clinical features. However, common clinical features in all of them are hypertension combined with hematuria and variable amount of proteinuria and either normal or deranged renal function [1]. All glomerulonephritides share also the same prognostic features. Continuous heavy proteinuria, renal insufficiency and hypertension are independent markers of a progressive loss of the renal function. Also, a vast chronic damage in renal biopsy predicts a faster loss of renal function [1].

The treatment of glomerulonephritis depends highly on the clinical picture. Common principles in the management include treatment of hypertension and reduction of proteinuria. Some forms of glomerulonephritis require immunomodulating treatment [3]. The indications for immunomodulating treatment vary according to the disease and clinical scenario [1]. In rapidly progressive glomerulonephritis it is vital to commence efficient immunosuppressive treatment at an early phase of the disease in order to preserve renal function [6]. In slowly progressive diseases immunosuppressive treatment may not be indicated at all. Complement inhibition is an emerging treatment option, since in many forms of glomerulonephritis complement activation is the central mechanism causing glomerular injury. However, currently the use of complement inhibition in glomerulonephritis, unlike in atypical hemolytic uremic syndrome (aHUS), is off-label.

2. IgA glomerulonephritis

IgA glomerulonephritis (IgAN) (synonyms IgA nephropathy or Berger's disease) is the most common primary glomerulonephritis with marked differences worldwide. The annual incidence ranges between 0.2–5.7/100 000 [7]. Men are more often affected, and the usual age of diagnosis is between 20–40 years, although the disease can manifest at any age [8].

The detailed etiology of IgAN is still unresolved. The patients have several derangements in the IgA immunoglobulins, but that alone is not sufficient to cause the disease [9]. A multi-hit model has been suggested, where the initiating event is the formation of galactose-deficient IgA1 in genetically predisposed patients leading to the production of autoantibodies, formation of circulating immune complexes and finally renal deposition and injury [10]. Compared to normal IgA, a proportion of the circulating and kidney deposited IgA1 in IgAN has altered characteristics, probably due to abnormal glycosylation and/or dimerization. The altered IgA could thereby originate from mucosal surfaces and, being in the “wrong” place, activate the alternative or lectin pathways of complement [11]. Contributing factors could include microbial infections, especially on mucosal surfaces, food antigens or yet unknown other environmental factors. IgA1 immunoglobulin binding to its antigens could lead to the formation of immune complexes and eventually their accumulation in the glomeruli causing the clinically evident disease [12]. Most cases are sporadic, but familial aggregation has been described in less than 15% of the cases [13]. Healthy relatives often have the same derangements in the IgA immunoglobulin system as the patients. This strongly suggests that additional factors in the pathogenetic process are needed [14,15].

The diagnosis of IgAN is based on IF microscopy, where IgA is the predominant deposited protein in the mesangial areas. The LM findings can be variable. Also, immunoglobulins other than IgA may be present in the glomeruli, and about 90% of the patients have C3 deposits indicating complement activation in the glomeruli [8,16]. Autopsy and

histological studies have implied that C3 co-deposits may distinguish isolated IgA from nephritogenic IgA deposition, as the majority of patients with only IgA staining, but without any clinical renal disease, do not usually have C3 co-deposition [10,17,18]. In more comprehensive studies also other complement components have been detected in the glomeruli: C4d, mannose-binding lectin (MBL), L-ficolin, MBL-associated serine proteases 1, 2, and 3, properdin, factor H, factor H-related proteins (FHR1 and FHR5) and the membrane-attack complex (MAC) [19].

Hypocomplementemia is not a typical feature of IgAN, but some researchers have found high serum C3/IgA ratios, especially in combination with glomerular C3 staining and high serum C4b binding protein levels, to be indicative of a worse outcome [20–22]. Also, low circulating MASP-3 level has been associated with progressive IgAN along with increased glomerular staining of FHR5 [23]. Among the genomic loci associated with susceptibility of IgAN, the locus on chromosome 1q32 includes a cluster of genes that encode factor H-related proteins. This cluster is associated with a risk of developing IgAN [10]. Based on published data, it can be concluded that activation of complement plays a role both in the pathogenesis and as a prognostic marker in IgAN. Activation seems to be mediated by alternative and lectin pathways and happens both in circulation and locally in the glomeruli [19,24,25].

The most typical clinical picture of IgAN is that of fortuitously found hematuria and proteinuria in combination with hypertension. Less than half of the patients have temporary macroscopic hematuria during acute illness. The minority has either acute bouts of massive proteinuria resembling minimal change glomerulonephritis or rapidly progressive glomerulonephritis resembling vasculitis [15,26]. Henoch-Schönlein purpura, or preferably IgA vasculitis, is a systemic form of IgAN with purpura, arthralgias/arthritis and gastrointestinal symptoms (enteritis, pain) [27]. It is caused by small vessel vasculitis with typical IgA-dominant immune deposits in affected organs. Renal histology is identical with primary IgAN. The systemic disease is clearly more common in children, but can manifest in adulthood, as well [24]. The treatment of IgAN follows mostly the same guidelines as that in the primary disease [24]. IgAN has been reported to be linked with various other diseases (celiac disease, liver diseases, inflammatory bowel diseases and connective tissue diseases) more than one would expect merely based on coincidence. Causality is not always clear, and optimal treatment of secondary IgAN depends on the clinical scenario. Most reports suggest addressing the underlying disease with additional supportive measures for chronic kidney disease [28].

No curative treatment for IgAN is available at the moment, but a minority of the patients may undergo complete remission even without any treatment [29]. The cornerstone of the treatment is strict control of hypertension with antiproteinuric compounds (mainly renin-angiotensin blockers). Antiproteinuric treatment is indicated even in normotensive patients [3]. For selected patients a 6-month course of corticosteroids can be offered, if renal function is still good enough (eGFR > 30 ml/min), and the amount of proteinuria continues at an unacceptable level [3,24,26]. Several complement inhibiting drugs are currently being evaluated in clinical studies, but none of them is officially indicated for the treatment yet [30]. Oxford classification of histology may be guiding the treatment decisions [31], as well as a recently published prediction tool [32]. In cases resembling minimal change glomerulonephritis or rapidly progressive glomerulonephritis the treatment follows their guidelines [26]. Most patients have slowly progressive disease and ESRD develops in some 20–40 % of the patients within 20 years after diagnosis [24]. IgAN can also recur in renal transplants in some 50% of the cases. The rate of recurrence was found to be higher in studies, where protocol biopsies were performed than when biopsies were done for clinical reasons only [33].

3. Membranoproliferative glomerulonephritis (Ig-MPGN, DDD, C3GN)

Membranoproliferative glomerulonephritis (MPGN) (synonym mesangiocapillary glomerulonephritis) accounts for approximately 7–10% of all biopsy confirmed cases of glomerulonephritis (34, 35). Its annual incidence has been reported to be 0.14–0.93 /100 000. The incidence has been decreasing due to a lower occurrence of viral and bacterial infections that may cause the disease due to chronic antigenemia [7]. MPGN is mainly diagnosed in childhood or adolescence, but may occur at any age [36].

Understanding of the pathophysiology of MPGN has greatly advanced in the past 10 years. Recently, a new classification into two forms, immune complex-mediated MPGN (Ig-MPGN) and complement-mediated MPGN (C-MPGN) or C3 glomerulopathy (C3G) has been introduced [37,38]. It reflects progress in the research of the disease pathophysiology and has led to a better understanding of the underlying distinct causes. Ig-MPGN is caused by increased amounts of circulating immune complexes due to chronic antigenemia (chronic infections, autoimmune diseases, malignancies, plasma cell dyscrasias or other persistent antigen stimuli) leading to the activation of the classical pathway of complement. The evaluation should therefore focus on identifying the trigger driving the chronic antigenemia. If no trigger can be found, and the rare cases of C3G have been excluded, the disease is labeled as idiopathic Ig-MPGN [39].

C3G occurs because of dysregulation of the alternative complement pathway [40]. Known and potential underlying causes are described in Fig. 1 and their points of action in the complement cascade in Fig. 2. Dysregulation can be due to mutations in the complement proteins or to autoantibodies that promote complement activation [34]. In addition, a significant proportion of cases have been found to be due to monoclonal immunoglobulins (paraproteins) [41,42].

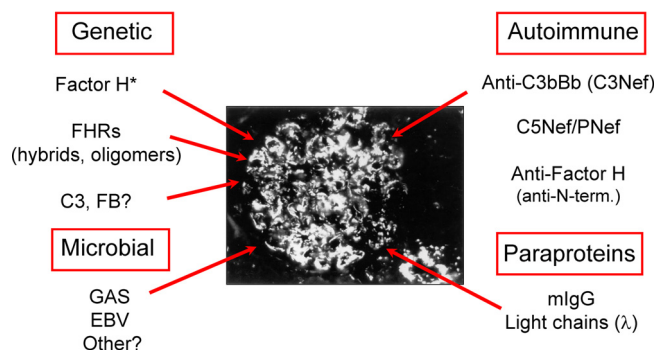
C3G is subclassified into dense deposit disease (DDD) and C3 glomerulonephritis (C3GN) based on the presence or absence, respectively, of dense glomerular basement membrane deposits by EM [34,43]. The dense deposits contain mostly an abundance of the C3b protein and factors of the terminal pathway. C3b is derived from a large-scale activation of fluid phase C3 that also leads to notably low levels of plasma C3 [44]. A specific genetic mutation or autoantibody can be found in a significant proportion of patients, but in many patients no clearly identifiable cause can be detected. In one study with 73 C3G patients, 18% had a likely pathogenic genetic variation [45]. Autoantibodies to the alternative pathway C3 convertase, C3bBb, are called C3 nephritic

factors (C3Nef). They stabilize the C3bBb complex to increase its activity and prolong its half-life similarly as properdin. C3Nef activity is noted in approximately 80–90% of DDD patients and 40–60% of the C3GN patients [45,46]. C3Nef is found more commonly in younger patients. As many of the commonly used diagnostic methods do not directly show the nature of the C3 activating factor as an IgG class autoantibody, it is possible that other factors contribute, as well. In more than one half of patients, serum C3Nef persists throughout the disease course [47]. C3Nef is associated with clinical evidence of complement activation, such as a decrease in CH50, a reduction in plasma C3 and an increase in C3 activation products. However, no clear relationship between C3Nef, plasma C3 levels and disease prognosis has always been detected [47]. Another nephritic factor has been characterized by the ability to stabilize the C5 convertase of the alternative pathway (C5Nef). This factor seems to require properdin (P), a known positive regulator of the alternative pathway. In addition, autoantibodies against the C3 convertase of the classical and lectin pathways (C4Nef) have been described [48]. These autoantibodies have been associated with both Ig-MPGN and C3G. Factor H autoantibodies can be detected in approximately 11% of C3G patients [49]. In some patients with DDD inherited mutations in factor H have been detected. The mutations either cause a deficiency of factor H or are located in the N-terminal part of factor H, which is needed for its regulatory activity [40,50].

When C3G is diagnosed, full evaluation of the complement system is recommended [50]. This includes a mutation panel analysis and determination of the nature of the complement activating factor or dysfunction in the patient blood. If no secondary cause in Ig-MPGN is found, screening similar to C3G is recommended. It has been shown that a defective control of the complement alternative pathway can be found in about 20% of Ig-MPGN patients [51,52]. Paraproteins can also cause either Ig-MPGN or C3G. In the latter case the paraprotein could act as a functional inhibitor of the complement regulating protein factor H, as we have initially described [44,53]. In this specific case monoclonal immunoglobulin lambda light chains bound directly to the third domain of factor H blocking its functional activity (binding to C3b, cofactor activity for C3b inactivation and decay accelerating activity). This “miniautoantibody”, composed of two light chains only, led to massive complement activation and plasma C3 consumption in the patient. Some paraproteins have been found to have a C3Nef activity, but in many cases, however, the exact mechanisms of the paraproteins in causing complement activation and C3G have remained unknown [54].

MPGN denotes glomerular changes characterized by mesangial expansion and hypercellularity and by thickening of the glomerular capillary wall. Eventually this leads to characteristic features with double contours in the basement membrane [55]. IF microscopy reveals bright staining for C3. For the diagnosis of C3G the intensity of C3 staining has somewhat arbitrarily been determined to be at least two orders of magnitude greater than that for any other immunoreactant, like IgG [50]. More dominant staining for immunoglobulins is characteristic for Ig-MPGN [56]. EM shows that deposits occur in the mesangial areas as well as in the subendothelial and subepithelial spaces in Ig-MPGN and C3GN, whereas in DDD they occur intramembranously and mesangially [55]. It is of note that only 71% of C3G cases have an MPGN pattern in LM [51]. In most of the other cases, the pattern shows mesangial proliferation without capillary wall changes [55]. Large hump-shaped subepithelial deposits may be seen in C3G [42]. MPGN can also be found in the absence of immune complexes or complement deposits on IF. Then thrombotic microangiopathy (TMA) should be considered [34,35,55]. Curiously, in the case of paraprotein-associated C3GN the paraproteins can be masked and may not be directly visible by IF microscopy. They can be revealed by protease treatment of the kidney sections [57]. However, since complement activation in C3G often takes place in the fluid phase, one does not need to expect deposition of the paraproteins in the kidney glomeruli.

Multiple causes of C3G



*N-term mutation or lack of FH

Fig. 1. C3 glomerulopathy has multiple causes. These include genetic mutations or autoantibodies. Also paraproteins (immunoglobulin M-components) and infectious agents can lead to C3G. FHR, factor H-related proteins; GAS, group A streptococcus; EBV, Epstein-Barr virus; mIgG, monoclonal immunoglobulins.

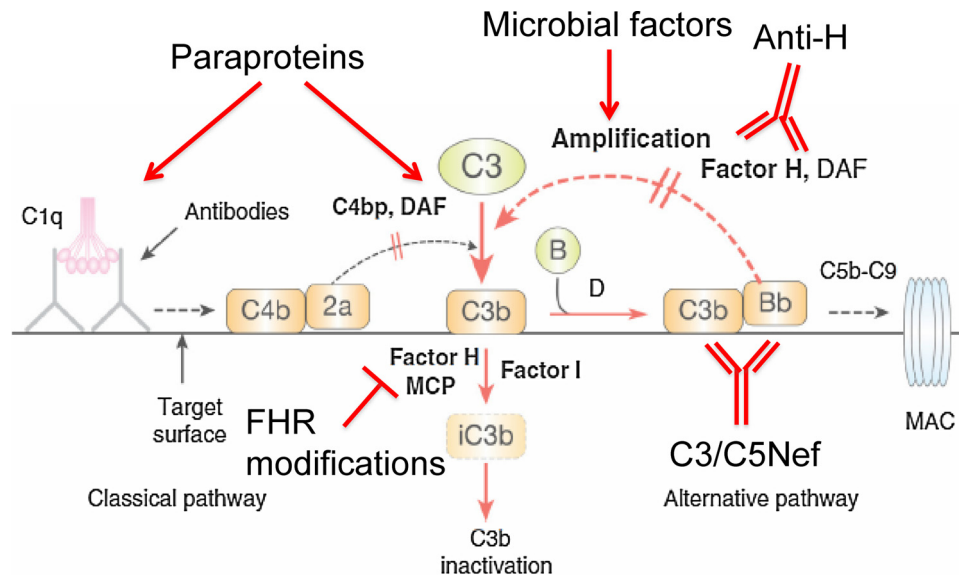


Fig. 2. Points of action of the different potential causative factors of C3G in the complement cascade. FHR, factor H-related proteins; C3/C5Nef, C3/C5 nephritic factor.

The clinical presentation of MPGN at diagnosis varies from asymptomatic hematuria and proteinuria to a more severe disease with nephrotic or nephritic syndrome or even a rapidly progressive glomerulonephritis [34]. Half of the patients have a full-blown nephrotic syndrome, while the rest either have a nephritic syndrome or no symptoms [36]. Some may also have periodic macroscopic hematuria. A third of the patients are hypertensive and even more so in progressive disease. Renal insufficiency is evident in half of the patients. MPGN can sometimes go into spontaneous remission, and fluctuations in the clinical picture are not uncommon [36]. All MPGN types have some level of hypocomplementemia, but this can also be periodic [52,58]. Individuals with C3G, especially with DDD, may develop drusen lesions in the eye as a result of an inability to remove eye pigment and misdirected complement activation, often in early adulthood [50,59]. The long-term risk for visual problems in individuals with C3G is approximately 10%. No apparent correlation, however, exists between disease severity in the kidney and in the eye [59]. Also acquired partial lipodystrophy (PLD) may develop as a direct aftermath of complement activation in 5–17% of persons with C3G [50,59].

PLD is a rare disease, characterized mainly by symmetrical loss of subcutaneous fat from the upper part of the body [60]. Apart from its linkage to DDD, PLD can be caused e.g. by an acute viral infection, diabetes mellitus, liver dysfunction, pancreatitis or systemic autoimmune diseases. Most patients with DDD-associated PLD have hypocomplementemia [61]. The C3Nef autoantibodies lead to hypercatabolism of C3 via the alternative pathway by stabilizing the activity of the C3bBb enzyme [62]. It is assumed that the loss of fat is due to a direct complement-mediated damage to adipocytes. Adipocytes play an important role in promoting complement attack, because they are the principal producers of factor D (adipsin), the specific key enzyme activating factor B, which is needed for the assembly of the C3 convertase of the alternative pathway [63].

The treatment of MPGN depends on the etiology, and has not been well established. No single treatment has been proven to be ideal in C3G. Effective treatment of hypertension and proteinuria, particularly via renin-angiotensin-aldosterone system (RAAS) blockade, is recommended, as these treatments slow progression of all proteinuric chronic glomerular diseases. Aliskiren (direct renin inhibitor) has shown positive results in three patients with DDD demonstrating decreased systemic and renal complement activation [64].

If in Ig-MPGN an underlying condition is found, the treatment needs to address this primary cause [34]. If no underlying cause can be found,

treatment aimed at reducing blood pressure and proteinuria may be sufficient. For more severe cases, immunosuppressive therapy is recommended, although the evidence of using these agents has been collected from trials prior to the novel classification system [35]. Because of its rarity and possibly also because of heterogeneity, there are only a limited number of studies addressing the treatment of C3G. Plasma infusions or exchange may be beneficial to restore the depleted plasma factor levels if the patient has been diagnosed with a complement protein deficiency or abnormality. If circulating autoantibodies that disturb complement regulation can be found, plasma exchange (or immunoadsorption of the antibodies) may be helpful [50,65]. Unfortunately, unless specifically addressed (e.g. by rituximab) the autoantibody production continues and the antibodies return back to the circulation. Also, despite the documented removal of C3Nefs, a favourable outcome may not be achieved solely by plasmapheresis [66]. It seems to be efficacious in factor H autoantibody-associated DDD. Immunosuppressive medication is often given either with or without plasma exchanges, but with variable results [67]. A recent study suggested that mycophenolate mofetil (MMF)-based immunosuppressive therapy combined with corticosteroids is beneficial in patients with C3GN and can decrease the rate of progression to end-stage kidney failure for reasons that are not completely clear [68]. Further studies are needed to tailor optimal therapies for clearly defined subgroups of patients. It is difficult to select the right therapy regimen without understanding the basic pathogenetic mechanism underlying the disease.

The second specific complement inhibitor, after C1 inhibitor for hereditary angioedema, currently available for clinical use is eculizumab, a humanized antibody against C5. It prevents C5 cleavage and generation of C5a and membrane attack complex (MAC) [69]. However, while eculizumab is effective in preventing the generation of C5a and MAC, it is unlikely to be useful, if the majority of renal damage is mediated by C3 hypercatabolism [70]. Its effectiveness has been reported in small case series and single patient reports with roughly 60% of the patients benefiting from the treatment [71]. The usefulness of eculizumab may be predicted by analyzing the activation profile of C3/C5Nef in C3G patients [71]. Soluble CR1 therapy in a murine model of human C3GN stopped alternative pathway activation resulting in normalization of serum C3 levels and clearance of its activation products from glomerular basement membranes [72]. The C3 inhibiting complement analog Cp40 prevented complement-mediated lysis of sheep erythrocytes in sera from C3G patients in vitro [73], but its pharmacokinetic properties are not optimal for treatment of C3G. Nevertheless,

rational treatment of C3G should, however, involve inhibition of C3 activation, e.g. by blocking the activity of factor D. A number of drugs that are in pre-clinical development may allow a more targeted therapy in the future [55]. It is, however, important to note the increased therapy-related risk for infections, when complement activity is suppressed.

MPGN has a progressive nature in the majority of cases. Within 10 years of diagnosis, about 40% of patients result in an ESRD and MPGN often recurs in kidney transplants leading to subsequent renal failure and restart of dialysis [34]. With DDD, the recurrence rate is about 80–90% and half of the grafts are lost due to the recurrence within 5 years [34,35].

4. Mechanisms underlying the development of C3GN

While the causes and mechanisms for DDD are relative well understood, those for C3GN are less well defined. The overall outcome in C3GN is prolonged and extensive C3 activation and C3b deposition in the glomeruli, but not in the same extent and homogenous manner as in DDD, where C3b deposition leads to dense intramembranous deposits [40]. It is apparent that C3GN can be caused by multiple factors (Fig. 1). Paraproteins occur in about one third of cases, more so in elderly patients [74,75]. In some cases, they have been shown to have direct factor H blocking or C3 nephritic factor activity. Otherwise, they seem to promote complement activation in the fluid phase and activate C3 during a prolonged time course. Whether they become deposited in situ in the kidney glomeruli and activate complement locally in situ is not clearly known. Also, their possible tissue damaging role in other organs has not been much studied yet. Paraproteins could cause amyloidosis, proliferative or fibrillary glomerulonephritis, immunotactoid glomerulopathy or cryoglobulinemia, but none of these forms have been described in the context of C3GN.

Genetic alterations constitute a heterogeneous group of causes for C3GN. Factor H-related proteins comprise a group of five plasma proteins: FHR1, FHR2, FHR3, FHR4 and FHR5 (76; Cserhalmi et al, this issue). They are all encoded in the Regulators of Complement Activation (RCA) gene cluster on chromosome 1 [77]. Because of internal homologies in the large number of sequences for individual domains (called complement control protein repeats, CCPs) this gene region is unstable. This can lead to genetic alterations, like deletions, duplications or hybrid genes [78–80]. The products or consequences of these alterations can have functional consequences that lead to the development of C3GN or to atypical haemolytic uremic syndrome (aHUS).

Each member of the FHR protein group can bind to the C3d region of C3b but, with the possible exception of FHR5, they lack their own direct complement inhibitory function. The 2 most C-terminal domains of the FHR proteins are homologous to those of factor H [76]. These domains contain the C3d as well as in some cases also the surface polyanion binding sites. In the N-terminus, instead, the FHR proteins have domains that can mediate homo- or heterodimerization [81]. The properties of FHRs suggest that they could act as competitors for factor H in binding to C3b/d-coated surfaces. They could bind to both C3d and the polyanions and inhibit factor H binding. This ability could be enhanced by their ability to assemble into dimers, which - because of multivalent binding - would have a higher avidity than factor H. In other words, the FHRs could thus control the regulatory activity of factor H and in fact promote complement activation ([81,82]; see also Cserhalmi et al in this issue).

In C3GN patients a number of different genetic variants of the FH/FHR family of proteins have been observed [40]. These include, for example, proteins containing duplicated parts of FHR1 or FHR5 and FHR3-1, FHR2-5, FHR5-2 and FHR1-5 hybrid proteins (summarized in 83). Naturally, these abnormal proteins would have the ability to disturb factor H-mediated regulation of complement activation and thereby cause C3GN or DDD. In some rare cases, also mutations in C3 or

factor B can lead to an overactive C3 convertase.

While distinct autoantibodies, like anti-H or C3Nef, or paraproteins have been discovered in patients with C3GN, the reasons for the emergence of these complement activation promoting factors is still a mystery. Paraproteins are monoclonal immunoglobulins produced by B cells or B cell-derived plasma cells. It is possible that they arise as an accidental occurrence of a B or plasma cell clone, whose product would be an immunoglobulin with an ability to cluster or polymerize in circulation or in kidney glomeruli. Some could have C3/C5Nef activity. While this could be the consequence of a spontaneous error in the immunoglobulin gene rearrangement or hypermutation process, also an underlying infection e.g. by the B cell-tropic Epstein-Barr virus could be the initial stimulating factor. Some paraproteins represent products of malignant multiple myelomas, which require specific treatment.

For the development of C3Nef or antibodies against factor H no root causes are known at the moment. Theoretically, an underlying infection by microbes that assemble C3bBb on their surfaces or carry factor H binding proteins could be envisaged to initiate autoantibody formation. Acquisition of complexes with foreign proteins into self-reactive B cells could accidentally lead to immunization against self-proteins, as well, if the foreign partner leads to activation of helper T cells. A homozygotic deficiency of the FHR3-1 gene region in the RCA cluster is known to predispose to the development of factor H autoantibodies [84,85]. This suggests that FHR1 (and/or, less likely FHR3) is needed for the maintenance of tolerance to factor H. A conformational change in factor H, mimicking that of FHR1, upon binding to microbial factor H binding proteins could thus induce autoantibody formation in a situation, where the person lacks FHR1 and therefore is not tolerant to it [86]. The anti-H autoantibodies are restricted in their characteristics, e.g. by maintaining their avidity, target specificity and often having only kappa or lambda light chains, and they also remain relatively constant in individual patients [87]. It is apparent that a mutation or an autoantibody alone would not usually be enough to cause C3GN. Precipitating factors are needed. For this, infections would also be a natural factor, that amplify complement activation and could initiate the process leading to C3GN.

5. Post-infectious glomerulonephritis

Post-infectious glomerulonephritis (PIGN) is a self-limiting glomerulonephritis that most commonly develops as a consequence of group A streptococcal infection, but can develop after other infections, as well [55,88]. *Streptococcus pneumoniae* is another bacterial pathogen, which could be involved in PIGN. Some pneumococcal strains produce neuraminidase enzyme that could sensitize glomerular structures, endothelial cells or immunoglobulins to complement attack. Sialic acids are well known to protect our own cell surfaces from complement attack.

Due to effective treatment of infections PIGN has become increasingly rare in Western countries [89]. The disease is uncommon in adults. PIGN predominantly manifests as a diffuse endocapillary glomerulonephritis [55]. Codeposition of IgG and C3 is commonly observed, while C3-dominant glomerular deposition is also observed [88]. Subepithelial humps are often seen on EM [88,89].

The clinical presentation of hematuria, less than nephrotic proteinuria and low C3 levels are typical [90]. C3-dominant glomerular deposition was previously considered to represent a later stage of PIGN. However, the emergence of C3GN as a distinct entity has led to re-assessment of this concept [88]. There have been reports where the initial presentation was PIGN, but the patients later developed chronic C3GN [91–94]. Therefore, in any patient with a C3-dominant PIGN, persistent clinical abnormalities, including hypocomplementemia, proteinuria or declining renal function, should lead to further investigation of the alternative pathway of complement [38,88]. As PIGN patients usually have low levels of circulating C3, one might even postulate that PIGN could be considered as a self-limiting form of C3G,

and that PIGN and C3G form a diseases spectrum rather than two completely distinct diseases [55,91]. Accordingly, reassessment of historical PIGN cases has led to reclassification as C3G in 25% of the cases [91].

As by definition PIGN is self-limited, supportive therapy is suggested, although even dialysis may be needed temporarily. In most severe cases, corticosteroids have also been given [88]. The clinical findings typically resolve within weeks, but complete resolution may take up to 6 months [88].

6. Membranous glomerulonephritis

Membranous glomerulonephritis (MGN) (synonym membranous nephropathy) is one of the most commonly encountered reason for adult nephrotic syndrome being twice as common in males than females. Annual incidence of 1.2/100 000 has been reported [7,95]. In children MGN is extremely rare. The usual age of onset is 50–60 years of age [96].

The MGN disease is caused by circulating autoantibodies that bind to an autoantigen on the surface of the podocytes. IgG immune complexes aggregate in the subepithelial space disturbing the normal barrier function of basement membrane. The most common target antigen is the podocyte protein M-type phospholipase A₂ receptor (PLA2R) [97]. In total, 70–80% of patients with primary MGN have detectable anti-PLA2R antibodies [97], and 3–5% have detectable anti-thrombospondin type-1 domain-containing protein 7A (THSD7A), a second target antigen identified in 2014 [98]. Anti-PLA2R antibodies are highly specific for primary MGN and are not found in other forms of glomerulonephritis or in secondary MGN. It has even been suggested that in the presence of anti-PLA2R antibodies, kidney biopsy is not necessary, unless there is a suspicion of another disease [3]. In approximately 20% of cases in adults, the MGN lesion is secondary to various disorders, including chronic infections, systemic and autoimmune diseases, drugs and malignancy [99].

Light microscopy in MGN shows thickening of the glomerular capillary wall because of subepithelial deposition of immune complexes and complement components and new basement membrane synthesis. Within the basement membrane characteristic spikes are visible [99]. Immunofluorescence analysis reveals staining for IgG, which is nearly always accompanied by C3 [100] and also PLA2R-antibodies in the primary form of the disease [99]. Electron microscopy shows subepithelial deposits [99]. Subepithelial, intramembranous and mesangial deposits suggest secondary MGN, an exclusively subepithelial location of the deposits is more typical for primary MGN. IgG subclass staining may further help in classification. IgG1, IgG2 and IgG3 generally dominate in the deposits of secondary MGN, whereas a preponderance of IgG4 is characteristic for primary MGN [99,100]. C1q is typically absent in primary MGN, but C4d is found in subepithelial deposits [100]. The mannose-binding lectin (MBL) pathway has recently emerged as a potential explanation to account for the presence of glomerular C4 in primary MGN [100]. Although serum levels of complement proteins are usually normal in primary MGN, increases in C3a and C5a levels indicated activation of complement and correlation with anti-PLA2R antibody levels in a recent Chinese study [101]. It was postulated that complement may be activated through the lectin pathway in patients with anti-PLA2R antibodies, and through the alternative pathway in patients without anti-PLA2R antibodies [101].

MGN commonly presents as nephrotic syndrome, but approximately 20% of patients with MGN present with non-nephrotic proteinuria [100]. Patients should be treated with supportive care from the time of diagnosis to minimize protein excretion. Patients with primary MGN and proteinuria > 3.5 g/d at diagnosis, and those who fail to reduce proteinuria to < 3.5 g after 6 months of supportive care or have complications of nephrotic syndrome, should be considered for immunosuppressive therapy [96]. A serology-based rather than proteinuria-based approach has also been suggested [99]. Levels of anti-

PLA2R antibodies and possibly, anti-THSD7A antibodies tightly correlate with disease activity [99]. In secondary MGN the treatment is usually dictated by the underlying cause.

As many as one third of patients with MGN have a progressive loss of kidney function and may progress to ESRD at a median of 5 years after diagnosis. The disease can recur in kidney transplants [100].

7. Hemolytic uremic syndrome

Hemolytic Uremic Syndrome (HUS) is an entity distinct from glomerulonephritis, yet it is important to keep in mind for differential diagnostic purposes, and because it also is a systemic disorder and can have a severe disease course [102]. HUS is a renal thrombotic microangiopathy characterized by a triad of symptoms; (i) microangiopathic hemolytic anemia, which means damage to red blood cells as they pass through the narrow microvasculature, (ii) thrombocytopenia, i.e. decreased levels of platelets due to the extensive formation of thrombi, and (iii) microvascular glomerular thrombosis, formation of blood clots in the kidneys, which can lead to acute renal failure [103,104]. HUS can be typical or atypical. Typical HUS is caused by Shiga- or Shiga-like toxins, which can be produced by enterohemorrhagic *E. coli* (EHEC) or *Shigella* bacteria. This form of disease is usually self-limiting, although it can be severe and lead to kidney failure and other severe complications. The causative bacteria also cause diarrhea, sometimes bloody diarrhea, and affect predominantly kidney glomeruli. The atypical form of HUS involves usually the renal and interlobular arteries and is not self-limiting. The atypical form can be sporadic or familial, whereas the typical form is only sporadic [105]. aHUS and HUS also need to be separated from other forms of thrombotic microangiopathies, like thrombotic thrombocytopenic purpura (TTP), where complement has not been shown to be directly involved. Some hints for differential diagnostics are provided in Table 1.

The most common cause for atypical HUS (aHUS) is genetic. It can be caused by mutations that were first found in factor H [106], and later in the other complement regulators, factor I or membrane cofactor protein (MCP; CD46) or in thrombomodulin, which is an inhibitor of both complement and the coagulation cascade (reviewed by Nester et al; 107). In addition, mutations in C3 and factor B that increase the activity of the C3 convertase, C3bBb, on surfaces can lead to aHUS. aHUS-related mutations in factor H are usually located in its C-terminal domains 19 and 20 that contain binding sites for the C3d domain of C3b and for negatively charged surface polyanions, notably for sialic acids, like gangliosides on endothelial cells [108–110]. Autoantibodies against the same C-terminal region of factor H cause approximately 12% of aHUS [111]. As factor H is an inhibitor of complement, the presence of these autoantibodies leads to a targeted complement attack against self-surfaces, vascular endothelia and blood cells, because of decreased local regulation of complement.

Factor H acts as a regulator of the alternative pathway of complement activation by inhibiting the C3bBb convertase and by being a cofactor for factor I in inactivating C3b to iC3b [112]. While in DDD the absence of functional factor H leads to uncontrolled alternative pathway activation in the fluid phase and deposition of C3b on the glomerular basement membranes, in aHUS the major problem is an inability of factor H to recognize C3b on polyanion containing self cell surfaces. This leads to an indiscriminate attack against endothelial cell surfaces and against blood cells including platelets. The consequences include thrombotic microangiopathy, hemolytic anemia and progressive damage in kidneys. In about 50% of cases, unless treated, the disease leads to end-stage renal failure. Depending on the nature of the original cause the disease also recurs in transplanted kidneys.

aHUS is currently treated with eculizumab, a humanized monoclonal antibody, which prevents the cleavage of C5 to C5a and C5b. Thus, both the formation of the C5a anaphylatoxin and MAC, which involves complement proteins C5b-9, are prevented. While complement-mediated microangiopathy depending on C5 activation is

Table 1
Differential diagnostics of thrombotic microangiopathies.

Disease	Total Complement Activity (CP, AP, LP)	Complement Activation Products (Bb, SC5b-9)	Mutation Analyses	Autoantibody Analyses	Shiga-toxin E.coli
TTP: Thrombotic Thrombocytopenic Purpura	Normal complement levels but decreased ADAMTS13 activity	Normal levels	Deficiency of ADAMTS13 due to mutations in chromosome 9 (in about 10% of cases)	Anti-ADAMTS13 (more common than mutation)	NA
aHUS: Atypical Hemolytic Uremic Syndrome	Decreased C3 level in some cases	Slightly elevated SC5b-9	Mutations in CFH, CFI, MCP, C3, FB, thrombomodulin. Deletion of FHR3-1 found in patients with anti-H	Anti-Factor H C-terminus	NA
DDD: Dense Deposit Disease	C3GN : decreased levels of C3	C3GN: elevated SC5b-9	DDD/C3GN: Mutations in CFH, C3 and abnormalities in CFHR-genes found in some patients	DDD: Anti-C3bBb C3 Glomerulonephritis: C3/C5 Nef, an autoantibody against C3/C5 convertase	NA
C3GN: C3 Glomerulonephritis	DDD: decreased levels of C3	DDD: elevated SC5b-9, low C3			
STEC-HUS : Shiga toxin E. coli Hemolytic Uremic Syndrome	Increased complement activation	Elevated levels of C3a, Bb and SC5b-9	NA	NA	Present

prevented, the C3-dependent immunoprotective functions, such as opsonisation are preserved. In general, the use of eculizumab results in the 'cessation of acute hemolysis', stabilization of platelet counts and improvement of renal function. Plasma exchange is used to remove anti-H autoantibodies [113]. In selected cases a combined liver-kidney transplantation has been used successfully to treat patients with aHUS [114]. The liver transplant has been needed in patients who produced mutant complement factor H.

8. Concluding remark

Glomerulonephritis comes in many different forms indicating the fact that kidneys have to handle a number of different kinds of challenges. Some forms are rare, but have educated us a lot about the clinical importance and mechanisms of the complement system activation and regulation. Luckily, this has improved the diagnostics and already in some cases led to improved therapy. Circulating harmful autoantibodies can be removed by plasmapheresis and consequences of severe terminal pathway activation can be limited by a therapeutic complement-inhibiting antibody. Successful treatment of the patients requires further research in the field and close collaboration between the clinicians and researchers with interest and special expertise in the complement system.

Acknowledgements

This work was supported by the Research Programs Unit, University of Helsinki, Finland (730483454), Sigrid Juselius Foundation, Finland (4705080) Helsinki University Hospital Grants (TYH2019311), Laboratoriolääketieteen Edistämissäätiö, Finland (4706086), an investigator-initiated grant from Alexion Corp., US (3999915) and by the Humanitas University, Milan, Italy. We want to dedicate this article to our friend, late Marco Ricci, a medical student at the Humanitas University.

References

- [1] J. Floege, K. Amann, Primary glomerulonephritides, *Lancet* 387 (2016) 2036–2048, [https://doi.org/10.1016/S0140-6736\(16\)00272-5](https://doi.org/10.1016/S0140-6736(16)00272-5).
- [2] W. Kern, F. Silva, Z. Laszik, B. Bane, T. Nadasdy, Pitha J in book *Atlas of Renal Pathology, Chapter 2, Classification of Renal Diseases and Mechanisms of Renal Injury*, W.B. Saunders Company, 1999, pp. 7–11.
- [3] J. Floege, S.J. Barbour, D.C. Cattran, J.J. Hogan, P.H. Nachman, S.C.W. Tang, J.F.M. Wetzels, M. Cheung, D.C. Wheeler, W.C. Winkelmayr, B.H. Rovin, Conference Participants. Management and treatment of glomerular diseases (part 1): conclusions from a Kidney Disease: improving Global Outcomes (KDIGO) Controversies Conference, *Kidney Int.* 95 (February (2)) (2019) 268–280, <https://doi.org/10.1016/j.kint.2018.10.018>.
- [4] O. Wirta, J. Mustonen, H. Helin, A. Pasternack, Incidence of biopsy-proven

- glomerulonephritis, *Nephrol. Dial. Transplant.* 23 (January (1)) (2008) 193–200.
- [5] W. Couser, R. Johnson, The etiology of glomerulonephritis: roles of infection and autoimmunity, *Kidney Int.* 86 (November (5)) (2014) 905–914, <https://doi.org/10.1038/ki.2014.49>.
- [6] G. Moroni, C. Ponticelli, Rapidly progressive crescentic glomerulonephritis: early treatment is a must, *Autoimmun. Rev.* 13 (7) (2014) 723–729, <https://doi.org/10.1016/j.autrev.2014.02.007>.
- [7] A. McGrogan, C. Franssen, C. de Vries, The incidence of primary glomerulonephritis worldwide: a systematic review of the literature, *Nephrol. Dial. Transplant.* 26 (2) (2011) 414–430 doi.org/10.1093/ndt/gfq665.
- [8] F.C. Berthoux, H. Mohey, A. Afiani, Natural history of primary IgA nephropathy, *Semin. Nephrol.* 28 (January (1)) (2008) 4–9, <https://doi.org/10.1016/j.semnephrol.2007.10.001>.
- [9] J. Barratt, A.C. Smith, K. Molyneux, J. Feehally, Immunopathogenesis of IgAN, *Semin. Immunopathol.* 29 (November (4)) (2007) 427–443.
- [10] D.V. Rizk, N. Maillard, B.A. Julian, B. Knoppova, T.J. Green, J. Novak, R.J. Wyatt, The emerging role of complement proteins as a target for therapy of IgA nephropathy, *Front. Immunol.* (March (10)) (2019) 504, <https://doi.org/10.3389/fimmu.2019.00504>.
- [11] S. Yeo, C. Cheung, J. Barratt, New insights into the pathogenesis of IgA nephropathy, *Pediatr. Nephrol.* 33 (5) (2018) 763–777.
- [12] R. Magistroni, V.D. D'Agati, G.B. Appel, K. Kiryluk, New developments in the genetics, pathogenesis, and therapy of IgA nephropathy, *Kidney Int.* 88 (November (5)) (2015) 974–989, <https://doi.org/10.1038/ki.2015.252>.
- [13] F. Scolari, A. Amoroso, S. Savoldi, G. Mazzola, E. Prati, B. Valzorio, B.F. Viola, B. Nicola, E. Movilli, M. Sandrini, M. Campanini, R. Maiorca, Familial clustering of IgA nephropathy: further evidence in an Italian population, *Am. J. Kidney Dis.* 33 (May (5)) (1999) 857–865.
- [14] A.G. Gharavi, Z. Moldoveanu, R.J. Wyatt, C.V. Barker, S.Y. Woodford, R.P. Lifton, J. Mestecky, J. Novak, B.A. Julian, Aberrant IgA1 glycosylation is inherited in familial and sporadic IgA nephropathy, *J. Am. Soc. Nephrol.* 19 (May (5)) (2008) 1008–1014, <https://doi.org/10.1681/ASN.2007091052>.
- [15] J.C. Rodrigues, M. Haas, Reich H.N. IgA Nephropathy, *Clin. J. Am. Soc. Nephrol.* 12 (4) (2017) 677–686, <https://doi.org/10.2215/CJN.07420716>.
- [16] H.T. Cook, Interpretation of renal biopsies in IgA nephropathy, in: Y. Tomino (Ed.), *IgA Nephropathy Today*. Contrib Nephrol, Vol. 157 Karger, Basel, 2007, pp. 44–49, <https://doi.org/10.1159/000102287>.
- [17] J. Varis, I. Rantala, A. Pasternack, H. Oksa, M. Jantti, E.S. Paunu, et al., Immunoglobulin and complement deposition in glomeruli of 756 subjects who had committed suicide or met with a violent death, *J. Clin. Pathol.* 46 (1993) 607–610.
- [18] K. Suzuki, K. Honda, K. Tanabe, H. Toma, H. Nihei, Y. Yamaguchi, Incidence of latent mesangial IgA deposition in renal allograft donors in Japan, *Kidney Int.* 63 (2003) 2286–2294, <https://doi.org/10.1046/j.1523-1755.63.6s.2.x>.
- [19] A. Tortajada, E. Gutierrez, M.C. Pickering, M. Praga Terente, N. Medjeral-Thomas, The role of complement in IgA nephropathy, *Mol. Immunol.* 24 (July (114)) (2019) 123–132, <https://doi.org/10.1016/j.molimm.2019.07.017>.
- [20] H. Komatsu, S. Fujimoto, S. Hara, Y. Sato, K. Yamada, T. Eto, Relationship between serum IgA/C3 ratio and progression of IgA nephropathy, *Intern. Med.* 43 (November (11)) (2004) 1023–1028.
- [21] K. Onda, H. Ohi, M. Tamano, I. Ohsawa, M. Wakabayashi, S. Horikoshi, T. Fujita, Y. Tomino, Hypercomplementemia in adult patients with IgA nephropathy, *J. Clin. Lab. Anal.* 21 (2) (2007) 77–84.
- [22] Y. Kawasaki, R. Maeda, S. Ohara, K. Suyama, M. Hosoya, Serum IgA/C3 and glomerular C3 staining predict severity of IgA nephropathy, *Pediatr. Int. (Roma)* 60 (February (2)) (2018) 162–167, <https://doi.org/10.1111/ped.13461>.
- [23] N.R. Medjeral-Thomas, A. Trolldborg, N. Constantinou, H.J. Lomax-Browne, A.G. Hansen, M. Willicombe, C.D. Pusey, H.T. Cook, S. Thiel, M.C. Pickering, Progressive IgA nephropathy is associated with low circulating mannan-binding lectin-associated serine Protease-3 (MASP-3) and increased glomerular factor H-Related Protein-5 (FHR5) deposition, *Kidney Int. Rep.* 3 (November (2)) (2017) 426–438, <https://doi.org/10.1016/j.ekir.2017.11.015>.

- autoantibody-associated hemolytic uremic syndrome, *J. Am. Soc. Nephrol.* 21 (December (12)) (2010) 2180–2187.
- [113] B.S. Kaplan, R.L. Ruebner, J.M. Spinale, L. Copelovitch, Current treatment of atypical hemolytic uremic syndrome, *Intractable Rare Dis. Res.* 3 (2) (2014) 34–45.
- [114] H. Jalanko, S. Peltonen, A. Koskinen, J. Puntila, H. Isoniemi, C. Holmberg, A. Pinomäki, E. Armstrong, A. Koivusalo, E. Tukiainen, H. Mäkisalo, J. Saland, G. Remuzzi, S. de Cordoba, R. Lassila, S. Meri, T.S. Jokiranta, Successful liver-kidney transplantation in two children with aHUS caused by a mutation in complement factor H, *Am. J. Transplant.* 8 (1) (2008) 216–221.