

New Observations Letter

Purposely Induced Tics: Electrophysiology**Patrick McGurrin¹, Sanaz Attaripour^{1,2}, Felipe Vial^{1,3} & Mark Hallett^{1*}**¹Human Motor Control Section, NINDS, National Institutes of Health, Bethesda, MD, USA, ²Department of Neurology, University of California, Irvine, Irvine, CA, USA, ³Facultad de Medicina Clínica Alemana, Universidad del Desarrollo, Vitacura, Región Metropolitana, CL**Keywords:** Tics, Bereitschaftspotential, voluntary movement**Citation:** McGurrin P, Attaripour S, Vial F, Hallett M. Purposely induced tics: Electrophysiology. Tremor Other Hyperkinet Mov. 2020; 10. doi: 10.7916/tohm.v0.744*To whom correspondence should be addressed. E-mail: hallettm@ninds.nih.gov**Editor:** Elan D. Louis, Yale University, USA**Received:** October 23, 2019; **Accepted:** December 6, 2019; **Published:** January 6, 2020**Copyright:** © 2020 McGurrin et al. This is an open-access article distributed under the terms of the Creative Commons Attribution–Noncommercial–No Derivatives License, which permits the user to copy, distribute, and transmit the work provided that the original authors and source are credited; that no commercial use is made of the work; and that the work is not altered or transformed.**Funding:** None.**Financial Disclosures:** Dr Mark Hallett is a consultant at Cala Health company that is currently developing a device for the treatment of essential tremor. Cala Health also funds a research project at NIH which supplements Dr. Vial's salary.**Conflicts of Interest:** The authors report no conflicts of interest.**Ethics Statement:** All patients who appear on the video have provided written informed consent and authorization for videotaping and publication of the videotape.**Introduction**

Tics are non-rhythmic movements that can be simple or complex. Clinically, they may appear as quick voluntary movements (50–200 ms),¹ but can also be longer and more sustained (>300 ms).² These movements are often described as being predictable.³ An inner tension builds which is relieved by the movement in most cases, and the movement can be suppressed for some time. Most patients report a feeling of relief once they release the movement, and therefore do not prolong the suppression. Thus, to some extent, the movement is under voluntary control. Tics have been called “unvoluntary”; a movement between voluntary and involuntary behavior.⁴

Here we present a person who can purposely induce tics. Simultaneous electroencephalography (EEG) and electromyographic (EMG) activity were recorded to capture the Bereitschaftspotential (BP) to explore the physiology of this phenomenon.

Clinical case

A 55-year-old right-handed man presented with a previous left hip injury that caused him pain and discomfort. To rehabilitate the pain, he started to practice Tai Chi, whereby he learned to flow “Chi” in his body, self-described as a bioelectrical flow in the body.

By practicing Tai Chi, he became able to voluntarily build up tension in parts of his body, which would eventually cause a jerky movement. The tension could build up at different parts of his body, but occurred most

commonly around his spine muscles, which then induced a movement in his upper torso and neck. He reports being fully in control of the buildup sensation, and being able to start and stop this buildup of “Chi” at will. With regard to the movement, he reports some volition, but that the movement does not feel entirely under voluntary control. He is able to suppress the movement after tension buildup, but states that it is unpleasant. The process of building up and releasing tension feels pleasant for the patient as he feels “relaxed” after the movement occurs.

In college, he reported purposely inducing episodes of shaking when he was in bed. Those episodes were also perceived to be pleasant. At some point, he felt that the episodes were lasting a few seconds longer than he desired. This caused him some distress, and he successfully stopped inducing them.

His neurological exam was normal. No history of alcohol, drug abuse, or family history of mental illness was known. He is currently taking Lexapro for mild depression. He denied any evidence of tic disorder as a child. There were some minor obsessive and compulsive thoughts, but he denied ever having obsessive compulsive diagnosis or traits. Lastly, he was not bothered by these symptoms and was not seeking treatment.

Electrophysiological study

Surface EMG electrodes were attached to the cervical and thoracic paraspinal muscles, as well as the left sternocleidomastoid (SCM). EEG activity was measured over Cz with a left mastoid reference and ground

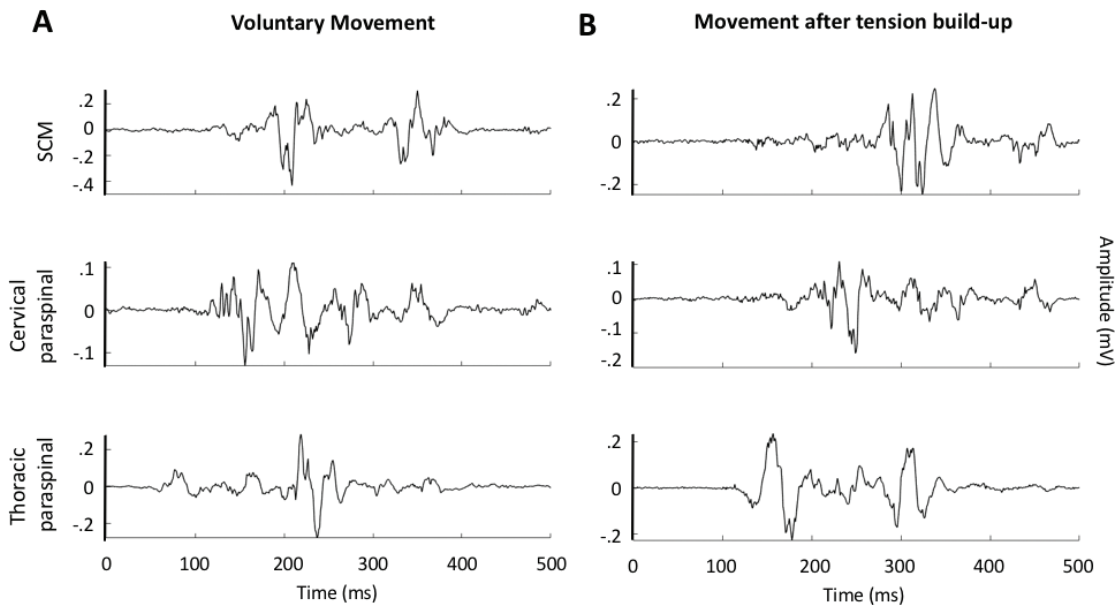


Figure 1. Electromyography of Voluntary Movement and Movement after Tension Buildup. Single traces from EMG recordings from both reported voluntary (A) and those after tension buildup (B). EMG is shown for cervical and thoracic paraspinal muscles, as well as left sternocleidomastoid (SCM).

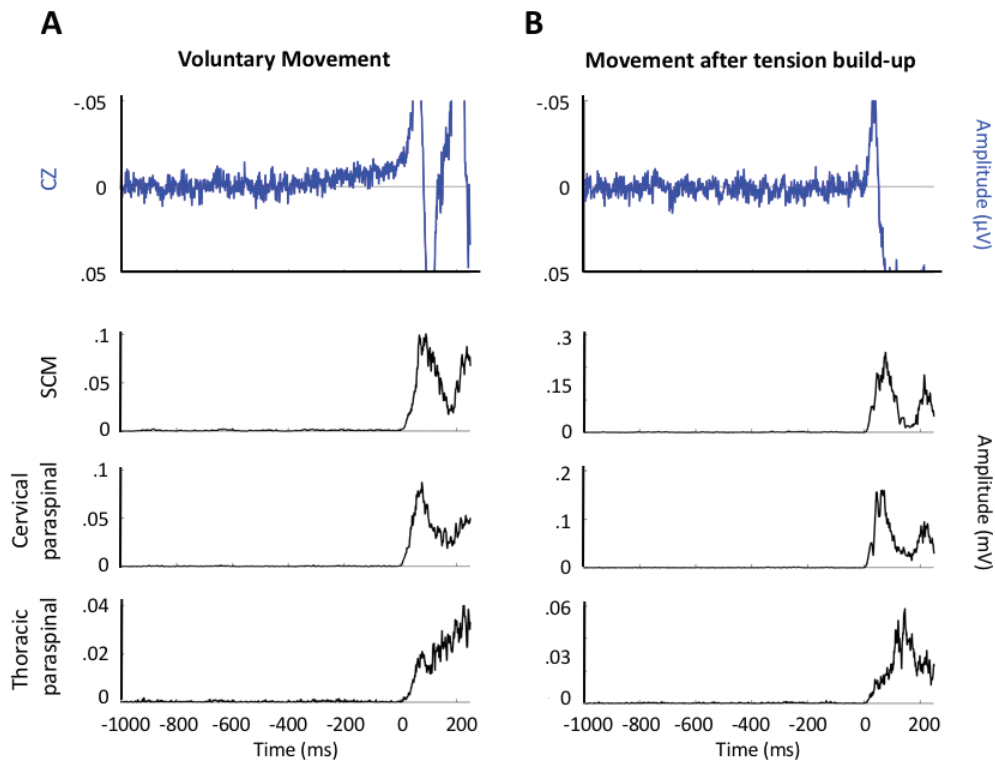


Figure 2. Back-averaging to Assess the Presence of the Bereitschaftspotential during Each Movement Type. Average traces from simultaneous EEG and rectified EMG recordings from both reported voluntary and tic-like involuntary movements. EMG is shown for cervical and thoracic paraspinal muscles, as well as left sternocleidomastoid (SCM). Markers were manually placed at the onset of each movement, and all movements were subsequently averaged to produce a single trace. A Bereitschaftspotential (BP) is visible starting roughly ~500 ms prior to movement onset (0 ms) in the case of the voluntary movement (A), but not during the movement occurring after the tension buildup (B).

on FP1. Simultaneous EMG and EEG recordings were made during movements reported as fully voluntary (Video 2) and those resulting from voluntary tension buildup (Video 1).

Movements after tension buildup were about 400 ms in duration, initiating in thoracic paraspinal muscles and subsequently in the cervical paraspinal and SCM. Overall, this recruitment pattern was consistent, although at times cervical paraspinal activity occurred prior to or concurrent with that of thoracic paraspinal. The recruitment pattern was similar during voluntary movements, but the duration of the burst was closer to 300 ms (Figure 1).

By back-averaging to the movement, we were able to identify a clear BP during the voluntary movement, but not after voluntary tension buildup (Figure 2).

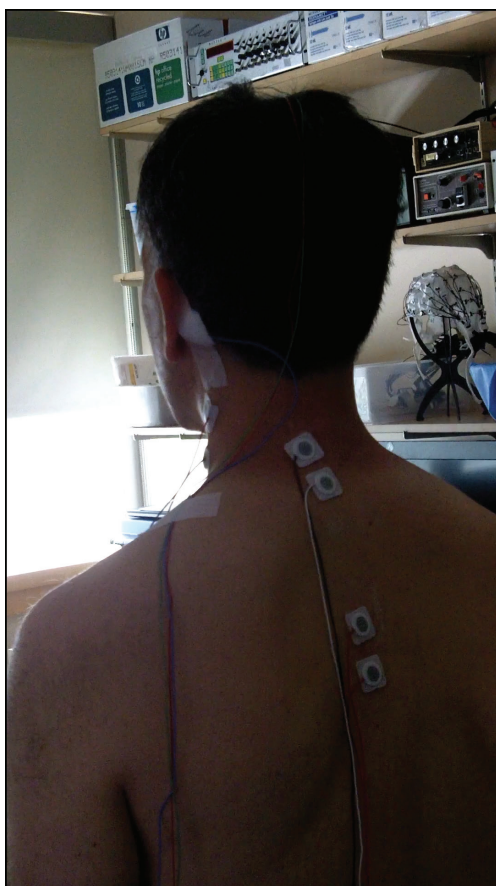
Discussion

The BP is a slowly rising negative potential originating over the supplementary motor area and premotor cortex which has been shown to precede a voluntary movement.⁵ It can be divided into an early portion (BP1) with a shallow slope and a late portion (BP2) that occurs roughly 400 ms prior to the movement and is observed to have an increased

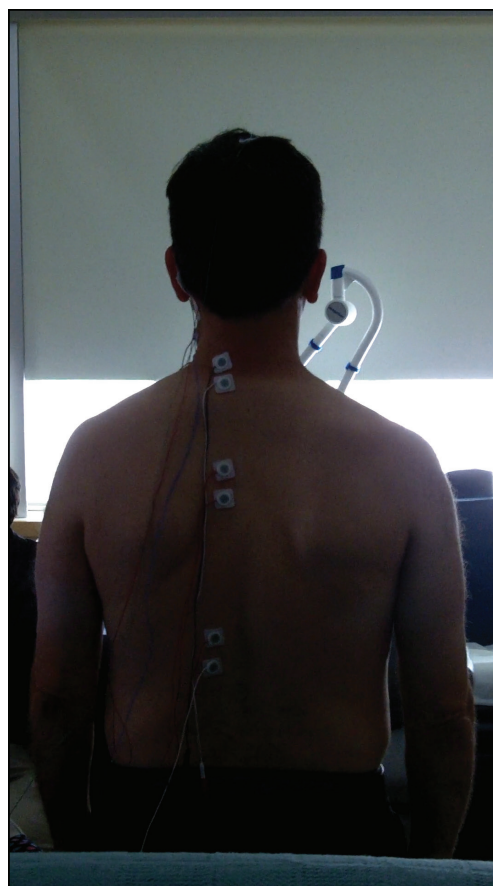
slope relative to BP1. Tic movements either will not have any BP preceding them or will have only the BP2.⁶

Here we find that a BP was present when the patient voluntarily mimicked the movement, but not after voluntary tension buildup. While we note that an absent BP is not a definitive sign of involuntariness, the presence of BP during voluntary movements, but not after voluntary tension buildup, supports the fact that the latter is an involuntary movement. Additionally, a neuroimaging study of typical tics from our group has shown pre-tic activation in the anterior insula and anterior cingulate rather than in the premotor cortex.⁷ Since the BP is generated in the premotor cortex, the lack of a BP after voluntary buildup can be understood.

The patient feels that he has control of the tension buildup, but the resulting movements to relieve the tension do not occur exactly how he would plan to perform them and he feels he has only partial volition as they occur. While we are unable to determine whether the underlying pathophysiology here is fully similar to that of tics, the evidence points toward tic disorder more than any other movement disorder. At the same time, we recognize the similar phenomenology between organic and functional tics.⁸ There are some characteristics of the movement



Video 1. Example of Tic. In this video, the patient builds tension voluntarily, but the movement is “involuntary”.



Video 2. Examples of Voluntary Movements. In this video, the patient makes voluntary movements attempting to mimic the tics.

that may point to a functional syndrome. However, given that the patient has some control over the movement, a premonitory feeling, and no BP make us think it is reasonable to classify it as organic tic. The pleasure reported after the movements may also support the diagnosis as equivalent to the relief that patients with tic disorder describe. However, we note that this sensation is typically described more as relief than pleasure.

In the case presented here, the tic occurs only in response to a purposeful initiation of tension buildup. To our knowledge, this is the first description of a purposely induced tic disorder. While almost all patients spontaneously report that the rise of tension is involuntary, we generally do not explicitly ask patients if they can control the tension preceding their movements in the manner described here. It is possible that some other patients could have more voluntary control over the buildup of tension than the subsequent movement. If so, the urge could be a more appropriate target for therapeutic suppression than the movement itself.

An alternative explanation, although counter to his history, could be that the patient has a tic disorder but mental training (Tai Chi) has enabled him to fully control his urge. This would be similar to what happens in the process of Comprehensive Behavioral Intervention for Tics for treatment of tic.

Acknowledgments

This work was supported by the NINDS Intramural program at the National Institutes of Health, NINDS.

Authors' contribution

P. McGurrin was responsible for the acquisition and interpretation of the data and writing of the report. S. Attaripour and F. Vial were responsible for the acquisition and interpretation of the data. M. Hallett was responsible interpretation of data and for writing of the report.

References

1. Hallett M. Neurophysiology of tics. *Adv Neurol* 2001;85:237–244. doi: 10.1016/S1567-424X(09)70478-7
2. Jankovic J, Stone L. Dystonic tics in patients with Tourette's syndrome. *Mov Disord* 1991;6(3):248–252. doi: 10.1002/mds.870060309
3. Hallett M. Electrophysiological evaluation of movement disorders. In: Aminoff MJ (Editor) *Aminoff's Electrodiagnosis in Clinical Neurology*, 6th Edition, Elsevier, Amsterdam, 2012;437–453.
4. Cavanna AE, Nani A. Tourette syndrome and consciousness of action. *Tremor Other Hyperkinet Mov* 2013;3:1–8. doi: 10.7916/D8PV6J33
5. Shibasaki H, Hallett M. What is the Bereitschaftspotential? *Clin Neurophysiol* 2006;117(11):2341–2356. doi: 10.1016/j.clinph.2006.04.025
6. Panyakaew P, Cho HJ, Hallett M. Clinical neurophysiological evaluation for simple motor tics. *Clin Neurophysiol Pract* 2016;1:33–37. doi: 10.1016/j.cnp.2016.04.001
7. Bohlhalter S, Goldfine A, Matteson S, Garraux G, Hanakawa T, Kansaku K, et al. Neural correlates of tic generation in Tourette syndrome: an event-related functional MRI study. *Brain* 2006;129(8):2029–2037. doi: 10.1093/brain/awl050
8. Edwards M. Tics and functional tic-like movements: can we tell them apart? *Neurology* 2019;93(17):750–758. doi: 10.1212/WNL.0000000000008372