



<https://theses.gla.ac.uk/>

Theses Digitisation:

<https://www.gla.ac.uk/myglasgow/research/enlighten/theses/digitisation/>

This is a digitised version of the original print thesis.

Copyright and moral rights for this work are retained by the author

A copy can be downloaded for personal non-commercial research or study,
without prior permission or charge

This work cannot be reproduced or quoted extensively from without first
obtaining permission in writing from the author

The content must not be changed in any way or sold commercially in any
format or medium without the formal permission of the author

When referring to this work, full bibliographic details including the author,
title, awarding institution and date of the thesis must be given

Enlighten: Theses

<https://theses.gla.ac.uk/>
research-enlighten@glasgow.ac.uk

**OPTIC NERVE HYPOPLASIA - A REVIEW AND
INVESTIGATIONAL STUDIES**

Sabah M ZEKI MB, ChB FRCS FCophth

A thesis submitted to the University of Glasgow in
candidature for the degree of MSc(Med Sci)
in the faculty of Medicine.

Tennent Institute of Ophthalmology,
University of Glasgow.

January 1990
c S M Zeki

ProQuest Number: 10983541

All rights reserved

INFORMATION TO ALL USERS

The quality of this reproduction is dependent upon the quality of the copy submitted.

In the unlikely event that the author did not send a complete manuscript and there are missing pages, these will be noted. Also, if material had to be removed, a note will indicate the deletion.



ProQuest 10983541

Published by ProQuest LLC (2018). Copyright of the Dissertation is held by the Author.

All rights reserved.

This work is protected against unauthorized copying under Title 17, United States Code
Microform Edition © ProQuest LLC.

ProQuest LLC.
789 East Eisenhower Parkway
P.O. Box 1346
Ann Arbor, MI 48106 – 1346

TABLE OF CONTENTS

CONTENTS:-

	Page
TITLE PAGE	1
TABLE OF CONTENTS	2
LIST OF TABLES	7
LIST OF FIGURES	9
MEMORANDUM	12
ACKNOWLEDGEMENTS	13
PUBLICATIONS	14
SUMMARY	15
CHAPTER 1 INTRODUCTION	19
1.1 Definition	19
1.2 Historical Background	20
1.3 Histopathology	21
1.4 Pathogenetic Mechanisms	22
1.5 Aetiology	25
1.5.1 Diabetes mellitus	26
1.5.2 Post-maturity	26
1.5.3 Young maternal age	27
1.5.4 Incidence of first born	28
1.5.5 Maternal ingestion of drugs	28
1.5.6 Genetic factors	29
1.5.7 Viral infections	30
1.6 Clinical Features	31
1.6.1 Laterality	31
1.6.2 Sex distribution	31

1.6.3	Presentation	31
1.6.4	Visual acuity	32
1.6.5	Pupillary light reactions	33
1.6.6	Refraction	33
1.6.7	Ophthalmoscopic findings	34
1.6.8	Neurological associations	35
1.6.9	Endocrinological associations	40
1.6.10	Other ocular and systemic associations	44
1.6.11	Differentiation from optic atrophy	45
1.6.12	Differentiation from hypermetropia	46
1.7	Investigations	49
1.7.1	Visual fields	49
1.7.2	Contrast sensitivity	50
1.7.3	Colour vision	50
1.7.4	Fluorescein angiography	50
1.7.5	Radiology of the optic canals	50
1.7.6	Electrophysiological investigations	51
1.8	Conclusion	52
CHAPTER 2 OBJECTIVES		54
2.1	Introduction	54
2.2	Aims and Protocol	54
2.2.1	Clinical case load	54
2.2.2	Maternal history	55

2.2.3 Visual acuity	56
2.2.4 Refractive state of the eyes	56
2.2.5 Colour vision	57
2.2.6 Contrast sensitivity	57
2.2.7 Brightness-sense comparison test	58
2.2.8 Photography and measurements	58
2.2.9 Neuro-radiology assessment	59
CHAPTER 3 PATIENTS AND METHODS	61
3.1 Patients	61
3.1.1 Patients with optic nerve hypoplasia	61
3.1.2 Control subjects	62
3.2 Methods	62
3.2.1 Maternal history	62
3.2.2 Visual acuity	63
3.2.3 Retinoscopy	63
3.2.4 Colour vision	64
3.2.5 Contrast sensitivity	64
3.2.6 Brightness-sense comparison test	66
3.2.7 Fundus photography and image analysis	68
3.2.8 Neuro-radiology assessment	70
3.2.9 Statistical methods	72
CHAPTER 4 RESULTS	73

4.1 General Results	73
4.2 Maternal History	75
4.2.1 Conditions at birth	76
4.2.2 Maternal health during pregnancy	77
4.2.3 Maternal age at birth	78
4.2.4 Smoking and alcohol intake habits of mothers	78
4.3 Visual Acuity	79
4.4 Retinoscopy	80
4.5 Colour Vision	85
4.6 Contrast Sensitivity	87
4.7 Brightness-sense Comparison Test	89
4.8 Fundus Photography and Image Analysis	90
4.8.1 Fundus photography	90
4.8.2 Image analysis	91
4.9 Neuro-radiological Assessment	93
CHAPTER 5 DISCUSSION	97
5.1 General Discussion	97
5.2 Maternal History	100
5.3 Visual Acuity	103
5.4 Retinoscopy	105
5.5 Colour Vision	108
5.6 Contrast Sensitivity	109
5.7 Brightness-sense Comparison Test	111
5.8 Fundus Photography and Image	

Analysis	112
5.9 Neuro-radiology Assessment	115
CHAPTER 6 SUGGESTIONS FOR FURTHER STUDIES	123
REFERENCES	126
APPENDIX	145

LISTS OF TABLES AND FIGURES

LIST OF TABLES:-

TABLE 1 (Following page 74)

Showing the investigations which each patient received.

TABLE 2 (Following page 79)

The patients' visual acuities with and without correction, and contrast sensitivities.

TABLE 3 (Following page 80)

The patients' retinoscopy findings.

TABLE 4 (Following page 86)

Showing the total number of errors, and errors typical of red/green deficiency.

TABLE 5 (Following page 89)

The findings of corrected visual acuity and the brightness-sense comparison test in the patient group. There is no statistically significant correlation between the two values.

TABLE 6 (Following page 92)

The relationship of the best visual acuity to the D-M/DD ratio in eyes with non segmental ONH.

TABLE 7 (Following page 93)

The relationship of the degree of astigmatism to the D-M/DD ratio in eyes with non segmental ONH.

TABLE 8 (Following page 95)

Results of cranial ultrasound of the 10 patients who underwent this examination.

TABLE 9 (Following page 95)

CT scan findings of the 15 patients who underwent this examination.

LIST OF FIGURES:-

FIGURE 1 (Following page 15)
The appearance of the optic disc in ONH.

FIGURE 2 (Following page 66)
Relationship of the percentage of light transmitted through a pair of plane polarizing filters positioned at different angles to each other.

FIGURE 3 (Following page 76)
Parity of patients and normal subjects.

FIGURE 4 (Following page 79)
Graph illustrating the proportions of patients and control subjects whose mothers smoked more than 10 cigarettes a day and who regularly drank alcohol during pregnancy.

FIGURE 5 (Following page 80)
The degree of improvement in logarithmic visual acuity, with correction, in the better eyes of nine patients with bilateral ONH.

FIGURE 6 (Following page 90)
Graph illustrating the relationship of brightness-sense

comparison test (BSC) to the difference in logarithmic visual acuity between the two eyes in the patient group.

FIGURE 7 (Following page 92)

This figure shows the best logarithmic visual acuities in the better eyes of 12 patients with bilateral ONH, and the D-M/DD ratios of these eyes.

FIGURE 8 (Following page 95)

Mid-coronal section of cranial ultrasound showing absence of the septum pellucidum (patient 5).

FIGURE 9 (Following page 95)

Axial CT scan demonstrating absence of septum pellucidum (patient 8).

FIGURE 10 (Following page 95)

Axial CT scan illustrating a porencephalic cyst (long arrow) communicating with the anterior horn of the left lateral ventricle.

FIGURE 11 (Following page 95)

Axial CT scan showing schizencephaly as a large cleft in the brain.

FIGURE 12 (Following page 95)
CT scan appearance of diffuse cerebral atrophy.

FIGURE 13 (Following page 118)
Axial CT scan showing a huge arachnoid cyst on the right side of the picture.

FIGURE 14 (Following page 118)
A. Huge bilobed suprasellar cystic mass in patient 18.
B. Low axial CT scan for patient 18 at the level of the third ventricle showing the suprasellar cyst.

MEMORANDUM

MEMORANDUM:-

This thesis is based upon the research conducted in the Tennent Institute of Ophthalmology and in the Royal Hospital for Sick Children between October 1988 and October 1989.

Supervision was provided by Dr Gordon N Dutton and Professor Wallace S Foulds

The text of this thesis was written solely by the Author.

S M Zeki

ACKNOWLEDGEMENTS

ACKNOWLEDGEMENTS:-

I would like to acknowledge the support I have had from Dr Gordon N Dutton. Our frequent discussions and his comments during the preparation of this thesis were most helpful and stimulating.

I would also like to acknowledge the help I received from Dr Anne S Hollman in helping with the assessment of the neuro-radiographs, Dr Donald Allan for his help with the statistical analyses and Mrs Anne Currie for her help with the photographic material.

I would also like to acknowledge Professor Wallace S Foulds whose teaching of Ophthalmology over the past years made this work possible. Thanks are also due to Dr John Dudgeon and Professor John V Forrester for facilitating access to patients under their care.

The protocol was devised by the Author, who carried out all the studies apart from those which are appropriately acknowledged.

PUBLICATIONS

PUBLICATIONS:-

The following papers have been submitted or accepted for publication:

1. Optic nerve hypoplasia in children. A review.
British Journal of Ophthalmology.
Zeki S M, Dutton G N.
(Accepted for publication)

2. Optic nerve hypoplasia and astigmatism. A new association.
British Journal of Ophthalmology.
Zeki S M.
(Accepted for publication)

3. Intracranial abnormalities of patients with optic nerve hypoplasia.
Hollman A S, Straiton J S, Zeki S M.
European Society of Paediatric Radiology (Munich).
(Submitted)

SUMMARY

SUMMARY:-

The literature concerning optic nerve hypoplasia (ONH) is reviewed, and a number of investigations have been carried out for patients with this disorder. The studies described in this thesis are aimed at gathering information regarding the maternal history during pregnancy and at finding the results of a number of tests which have not hitherto been performed on a group of patients with ONH.

Thirty seven patients were identified, and a number of normal subjects were also studied in order to provide an age matched control group.

The "double ring" sign was present in all affected eyes (Figure 1) except those of one patient. In the presence of hypermetropia in which ophthalmoscopic examination may show optic discs of apparently small size, this sign is particularly useful for the ophthalmoscopic diagnosis of an associated ONH. ONH should be sought in all children presenting with squint, nystagmus or with bilateral visual deficits particularly if associated with signs of hypothalamic/pituitary hormone deficiency.

A questionnaire survey study was carried out upon 27 mothers of children with ONH. An association (statistically not significant) with first born babies,

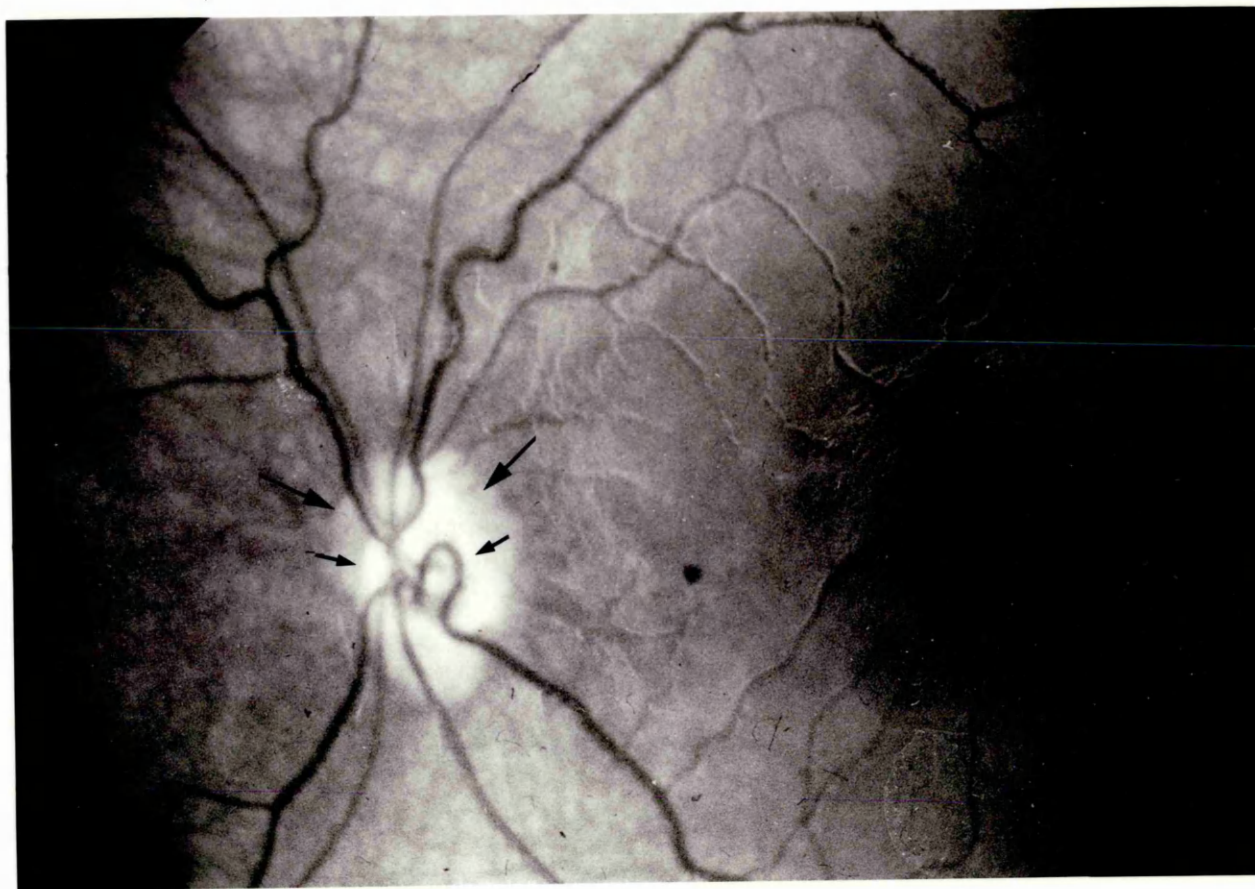


FIGURE 1

The appearance of the optic disc in ONH. The "double ring sign" is demonstrated. An inner ring representing the borders of the optic nerve (short arrows), and an outer ring representing the outer border of the glial tissue (long arrows).

and young maternal age was identified. However, the results obtained were not in accordance with a previous report of an increased prevalence of post-maturity in children with ONH, or an increased prevalence of the disorder in children born to diabetic mothers. A trend towards an increased prevalence of mothers who both smoked more than 10 cigarettes, and consumed alcohol during pregnancy was identified.

Astigmatism was common in patients with ONH. In most cases it was more severe in the 'better' eye in cases with bilateral ONH, and in patients with neuro-radiological abnormalities. No significant relationship was found between the degree of visual impairment and the severity of astigmatic refractive error. Astigmatism has not been hitherto reported in association with ONH.

Although significant astigmatic refractive error was identified in many patients in this study, the visual acuity was not improved following refractive correction.

A red green colour vision deficiency was found in 27% of patients. Colour vision deficiency has not hitherto been reported in patients with ONH.

Contrast sensitivity was reduced in 53 % of the patients with non-segmental ONH. No relationship was found with the degree of deterioration of Snellen visual acuity, or

with the degree of ONH as determined by image analysis.

Brightness-sense was found to be significantly impaired in affected eyes as compared to the fellow eye in asymmetrical bilateral cases. The test is simple to use and provides an additional test to detect optic nerve dysfunction.

This is the largest series in which the disc-macula/disc diameter ratio has been determined in patients with ONH. This study confirms that a ratio of 3 or more is a useful adjunct to the diagnosis of ONH.

Assessment of the neuro-radiographs in patients with bilateral ONH showed a large variety of abnormalities, and relatively high number of patients with bilateral ONH who had detectable intracranial abnormalities.

One patient with bilateral ONH had an intracranial arachnoid cyst, and another had an intracranial epidermoid cyst. In one child Duane's retraction syndrome was found in association with segmental ONH. These associations with ONH have not been reported previously.

The findings in this study suggest that the following tests should be performed on all children with bilateral ONH associated with significant visual deficit, even in

the absence of clinical signs of endocrine or neurological abnormalities:

1. Fasting blood glucose.
2. Fasting blood cortisol.
3. Intracranial U/S or CT scanning.

It is hoped that the further work outlined in chapter 6 will shed further light on our understanding of optic nerve hypoplasia.

INTRODUCTION

CHAPTER 1

1 . INTRODUCTION:-

1 . 1 Definition:

Optic nerve hypoplasia (ONH) is a non-progressive congenital abnormality of one or both optic nerves associated with a diminished number of axons (Mosier et al 1978, Hotchkiss & Green 1979). It constitutes a spectrum of degrees of defective vision which ranges from minimal visual impairment (with almost any type of visual field defect), to total blindness. Optic nerve hypoplasia arises when there is an under-development of the optic nerve fibres despite normal development of the mesodermal and the glial supporting tissue, and of the retinal vascular system. It is now apparent that ONH often does not represent just an isolated ocular anomaly (Acers 1983). Several clinically important endocrine and central nervous system (CNS) abnormalities are now recognised as associated conditions. Ophthalmologists are in a unique position to suspect these conditions so that appropriate therapy can be initiated.

Segmental ONH (Buchanan & Hoyt 1981), and tilted discs in association with ONH (Dorrell 1978) have also been described, thus widening the concept of ONH into a larger group of syndromes. However, for the purpose of regarding ONH as a single entity, such cases should probably be considered under a different heading.

Optic nerve aplasia is a rare condition characterized by total absence of the optic nerve, retinal ganglion cells and retinal vasculature (Weiter et al 1977).

1 . 2 Historical Background:

In 1884, Magnus described a small pale optic nerve with the presence of the retinal vessels in one eye of a young child; this case presentation was the first to completely describe all the characteristics of ONH. ONH is a condition once considered rare with only 22 reported cases by 1966 (Helveston 1966). Subsequently, between 1970 and 1980, 360 cases had either been reported or alluded to in the international literature (Acers 1981). ONH is now increasingly being recognised as an under-diagnosed cause of visual dysfunction and one of the major causes of visual impairment in children. The paucity of recorded cases may be related to the difficulties of detection and diagnosis, especially in early life.

In 1941 Reeves described a patient with hypoplasia of the optic nerves and absence of the septum pellucidum on pneumoencephalography. The term septo-optic dysplasia was first coined by De Morsier, a neuropathologist, in 1956, to describe the association of optic nerve hypoplasia with hypoplasia of the optic chiasm and of the infundibulum, the presence of a single anterior midline ventricle and the absence of the septum pellucidum and the corpus callosum.

In 1970 Hoyt et al were the first to describe pituitary dwarfism as a condition associated with ONH. In the

same year Kaplan et al, recognised that the associated growth retardation was secondary to reduced level of growth hormone.

1 . 3 Histopathology:

Histologically, a reduced number of optic nerve fibres can be demonstrated in a smaller than normal optic nerve. The retinal nerve fibre layer is diminished, the ganglion cells are reduced in number, but the outer retinal layers appear normal (Mosier et al 1978). The area surrounding the small optic disc is filled by an overgrowth of retinal pigment epithelium past the normal point of its termination (Mosier et al 1978). The commonly described double ring sign and the peripapillary cuffing is due to this overgrowth beyond the junction of the sclera and the lamina cribrosa. The interval between the two rings is occupied by the normal supportive tissue of the optic disc but not by optic nerve fibres. In an autopsy conducted in an infant with ONH and osteogenesis imperfecta who lived only 34 hours, Kreibig (1959), found that the ganglion cells and the nerve fibres were missing and the optic nerve was represented only by its supporting elements.

It is of interest that similar histopathological findings have been described in rodents (Bruckner 1951), cats (Zeeman & Tumbelaka 1916), horses (Strunjak 1941, Gelatt et al 1969) and dogs (Gelatt & Leipold 1971, Saunders & Rubin 1975, Kern & Riis 1981).

1 . 4 Pathogenetic mechanisms:

The pathogenetic mechanisms of ONH during embryological development are not fully understood. The formation of the layers of the adult retina from the cells of the inner and outer neuroblastic layers takes place by gradual differentiation which extends from the inner to the outer surface. The retinal ganglion cells and nerve fibres are the first of the adult retinal elements to appear and the rods and cones almost the last (Mann 1964). The most superficial cells of the inner neuroblastic layer migrate further inwards forming the layer of the ganglion cells from which processes grow out to form the nerve fibre layer (Mann 1964). The retinal ganglion cells normally become differentiated from the inner neuroblastic layer at the 17 mm embryonal stage (Duke Elder 1963) starting from the future macula (or posterior pole) towards the periphery. The axons grow centripetally, penetrating the mesodermal tissue of the primitive optic disc papilla to form the neural elements of the optic nerve. They penetrate the marginal zone of the neural tube at the lateral angle of the optic recess and enter the structures of the floor of the third ventricle near the junction of the telencephalon and the diencephalon at the 18 mm stage, and by the 22 mm stage their decussation gives rise to the chiasm (Duke Elder 1963). They reach the lateral geniculate body by the 22 mm stage (7th week) (Duke Elder 1963). Mesodermal elements give rise to the vascular and septal system of the optic nerve and its

dural sheath. The septum pellucidum arises at approximately the 145 mm stage (18 week) (Ellenberger & Runyan 1970, Acers 1981).

Failure of differentiation of the retinal ganglion cell layer between the 12 and 17 mm stages of embryonal development has been suggested by several authors (Scheie & Adler 1941, Duke Elder 1963, Mosier et al 1978). However, this theory presupposes that there is selective growth failure of retinal ganglion cells, since amacrine and horizontal cells which develop from the same precursor neural cells develop normally in ONH (Mosier et al 1978, Rogers et al 1981, Skarf & Hoyt 1984). Furthermore, when the optic nerve anomaly is associated with other brain deformities (which may appear anatomically in different stages of development), the above theory is also not satisfactory, for if it is correct, an underlying pathogenetic mechanism must be proposed which explains the development of multifocal pathology.

Other mechanisms have been suggested. These include stretching of the optic nerve during development of abnormal cerebral hemispheres (Ellenberger & Runyan 1970), and, in anencephaly, inadequate "target organs" may block the development of ascending pathways (Anderson et al 1967 ; Ellenberger & Runyan 1970). Funduscopic sign of "homonymous hemioptic hypoplasia" has been described and documented photographically in standard and red-free illumination in three patients

with congenital hemiplegia and hemianopia suggesting a retrograde axonal degeneration in each optic nerve and retina (Hoyt et al 1972).

Recent embryological research into the development of retinal ganglion cells has shed a new light on the pathogenesis of ONH. Major retrograde optic nerve degeneration and retinal ganglion cell death, known as "apoptosis ", occurs normally during the development of the visual pathways (Provis et al 1985). An alternative theory has therefore been put forward. This suggests that excessive regression in the number of axons in the optic nerve occurs as an anomaly in the normal development of the visual pathways. Indeed in human foetuses the number of axons in each optic nerve has been found to be 3.7 million at 16-17 weeks of gestation which declines to 1.1 million by the 31st gestational week (Provis et al 1985).

Novakovic et al (1988), have reported 6 cases. Case 1 had bilateral macular colobomas and sector hypoplasia in the part of the optic disc corresponding to the papillomacular bundle. Case 2 was six months old and had unilateral profound hypoplasia of the optic disc, a relative afferent pupillary defect and a well demarcated altitudinal visual field defect in the same eye. Such findings imply that the lesion is sited at the distal end of the optic nerve or the retina. Case 3 had unilateral ONH only, implicating the site of pathology as anterior to the optic nerve/chiasmatal junction. Case 4 had bilateral ONH, in particular affecting the nasal

4 had bilateral ONH, in particular affecting the nasal and temporal segments of both optic discs, with normal neuroradiological investigations, he also had bitemporal visual field loss suggesting a lesion in the chiasm.

Case 5 had bitemporal hemianopia and bilateral ONH mainly affecting the nasal and temporal segments of the optic discs. He also had see-saw nystagmus. The findings in this case implicate a suprasellar lesion, but this patient also had an absent septum pellucidum. The sixth case had a porencephalic cyst in the right occipital lobe, associated with left homonymous hemianopia and bilateral ONH.

These cases provide clinical evidence that ONH occurs in association with lesions at several sites in the visual pathways from the retina to the occipital lobe.

1 . 5 Aetiology:

Little is known about the factor(s) which predispose to ONH. It appears that whereas an insult to the optic nerve post-natally causes optic atrophy, an insult to the developing optic nerve on or around the 17 mm stage of embryonal development results in optic nerve hypoplasia. The nature of such an insult is not known. It is possible that a thorough and in depth maternal history, and a nutritional profile assessment of patients with ONH, in a large series could shed some light onto the nature of such insults.

1 . 5 . 1 Diabetes mellitus:

Peterson & Walton (1977), reported 17 patients born to diabetic mothers who had been taking insulin. Those patients exhibited segmental ONH, normal visual acuity in all but two patients and altitudinal or sector visual field defects corresponding to the hypoplastic areas of the disc. This was the first report to suggest a possible aetiological connection between ONH and maternal diabetes mellitus. It also suggests that ONH consequent to maternal diabetes mellitus is usually associated with normal visual acuities. A further four similar cases of segmental ONH, with normal visual acuity and altitudinal visual field defects have been reported in children born to diabetic mothers who were taking insulin (Nelson et al 1986). However, no prospective analysis of the normal population was performed in these studies. The teratogenic mechanism in diabetes has yet to be established.

1 . 5 . 2 Post-maturity:

In an epidemiological study a high rate of post-maturity was found in children with ONH (Jan et al 1977). In this study 139 blind children who were diagnosed as having bilateral optic nerve atrophy or bilateral ONH, and who were born between 1944-1974, were investigated for the incidence of bilateral optic nerve atrophy, and bilateral ONH. Only patients who lived in British Columbia during the time of the study were examined.

Hypoplasia was diagnosed when the optic disc was found to be one-third to one-half its "normal" size. They identified 20 cases of ONH, 9 patients (45%) were born post-mature, while only one was born premature.

1 . 5 . 3 Young maternal age:

The association of ONH with young maternal age has been described by a number of authors. Lippe et al (1979), found the mean maternal age of ONH cases to be 19.25 years at conception, compared with a mean of 24.7 years at delivery for all mothers in the state of Oregon. Margolith et al (1984), studied 51 cases of ONH, the mothers of children with ONH were significantly younger (mean age 22.1 years) than mothers of all newborn in British Columbia born in 1970 (mean 25.1 years), and 1980 (mean 26.0 years). Furthermore, 51.5% of cases of ONH were born to mothers who were 19 years of age or younger. Young maternal age has also been reported in association with septo-optic dysplasia syndrome, septo-optic-pituitary dysplasia and with isolated optic nerve hypoplasia (Lippe et al 1979, Robinson & Conry 1986). It is however, possible that this association stems from a higher incidence of substance abuse amongst these young mothers rather than from low maternal age per se (Lambert et al 1987). Patel et al (1975), reported four cases of ONH who were all first born children and of young mothers.

1 . 5 . 4 Incidence of first born:

In one report fifteen out of 20 cases of ONH were first born children (Walton & Robb 1970). Whereas in another report 52% of 40 patients were first born children (Acers 1981). Margolith et al (1984), studied 51 cases and reported that 54.3% of the patients were first born, compared to 37.0% in the general population in British Columbia in 1971, and 35.7% in 1980.

1 . 5 . 5 Maternal ingestion of drugs:

ONH has been reported in 48% of cases of foetal alcohol syndrome (Stromland 1985), suggesting that alcohol is a major teratogen to the developing optic nerve. A hypoplastic optic disc in that study was defined as a size equal to, or less than 2.07 square mm with the fundusoscopic signs of a double ring with sharply defined margins. The study was performed on 30 children suffering from foetal alcohol syndrome and the sizes of the optic discs were compared with 22 matched controls. A diagnosis of ONH was made whenever the measured area of the optic disc was of a size equal to, or less than, the mean area -1SD of the mean area of the normal controls. However, it could not be ruled out that some mothers might also have used psychopharmaceutic drugs during periods of the pregnancy in addition to abuse of alcohol. Taking the criterion of the size of the optic discs, alone in the above study one must expect a high false positive rate. For example if there had been, in

fact, no increased prevalence of ONH in these patients the mean-1SD limit would have been expected to give a detection rate of approximately 16%. This is assuming that there was normal distribution of sizes of the optic discs in the control group. Furthermore, in the above study the fundus photographs were not examined blind by a masked observer.

Maternal use of anticonvulsants (Hoyt & Billson 1978), quinine (McKinna1966), lysergic acid diethylamide (LSD) (Hoyt 1978) and phencyclidine (Michaud et al 1982) during pregnancy have been associated with the occurrence of optic nerve hypoplasia. In addition, history of insulin intake was obtained in 12.5% of mothers of children affected by optic nerve hypoplasia (Acers 1981). Stromland (1985), suggested in his discussion when he published a study of 30 patients with foetal alcohol syndrome, that smoking during pregnancy might have an adverse effect on the embryo and foetus. There has been no study in the literature regarding the possible role of mothers smoking, in the aetiology of ONH.

1 . 5 . 6 Genetic factors:

The literature concerning the mode of inheritance is sparse. Although a genetic defect has been suggested, and has been reinforced by reported cases of familial occurrence, ONH has rarely been shown to be genetic in

origin (Hackenbruch et al 1975; Margolith et al 1984; Taylor 1985). Kytala & Meittenin (1961), reported two brothers with bilateral ONH in a non-consanguineous family. No mechanism of genetic transmission was postulated for this sibling occurrence. Hackenbruch et al (1975), described five members of a family, spanning four generations, with bilateral ONH. Three of them were examined. They had defective vision, nystagmus and small pale optic nerves. The two others were deceased. From family records, it was presumed that the two deceased members were affected by bilateral ONH. The proposed mechanism of transmission was that of an autosomal dominant trait. However, the same clinical picture could have been inherited as an autosomal recessive.

1 . 5 . 7 Viral infections:

Cytomegalovirus infection during pregnancy has been implicated as a cause of impaired optic nerve development in four infants with cytomegalovirus infection and unilateral optic nerve abnormalities. Two had ONH, one had a partial coloboma and the fourth had microphthalmia and coloboma. Two of the mothers were diabetic, and one of these had previously given birth to a blind infant with congenital heart disease (Hittner et al 1976).

1 . 6 Clinical Features:

Optic nerve hypoplasia may be seen in three separate situations:

1. An isolated abnormality in an otherwise normal eye.
2. In grossly malformed eyes.
3. In association with a heterogeneous group of disorders most commonly involving the CNS, in particular, midline structures.

1 . 6 . 1 Laterality:

Bilateral disease has increasingly been reported as more common than unilateral disease (Billson 1973, Acers 1981, Lambert et al 1987). In the 93 patients with ONH studied by Skarf & Hoyt (1984), 41 patients had bilateral severe ONH, 41 had bilateral segmental ONH and 11 had unilateral ONH.

1 . 6 . 2 Sex distribution:

The incidence of ONH in males and females is equal (Walton et al 1970, Billson 1973, Acers 1981).

1 . 6 . 3 Presentation:

Asymmetrical as well as severe unilateral ONH commonly presents with concomitant squint, these cases are often misdiagnosed as primary squint. Trial of conventional

occlusion therapy is worthwhile in early childhood, as there may be a significant and treatable element of amblyopia superimposed upon a developmentally determined visual defect (Gardner & Irvine 1972). Moreover, ONH may leave the papillomacular bundle more or less intact (Bjorak et al 1978). Bilateral severe cases of ONH usually present with nystagmus or poor vision. A patient with ONH may have normal visual acuity but have visual field defects that pass undetected until later in life (see section 1.6.10). Patients may also present because of the associated neuro-endocrine abnormalities (Billson 1973).

1 . 6 . 4 Visual acuity:

Impairment of visual acuity in ONH is variable. It can thus be difficult to assess the visual potential of a child with ONH on the basis of the appearance of the disc alone (Seeley & Smith 1972, Smith 1980). Acers (1983), studied 24 patients with ONH in whom the size of the optic nerves as calculated by using A-scan ultrasonography, varied from 39% to 93% of a matched normal group to whom the patients were compared. Their visual acuities ranged from 6/6 to no light perception. He found no close correlation between the size of the optic nerve and the visual acuity. A single case has been reported in which a visual acuity of 6/9 (20/30) was achieved with conventional occlusion therapy, in the squinting eye of a child with severe unilateral ONH (Gardner & Irvine 1972). Cases of ONH with normal

visual acuities but with considerable defects in the inferior segments of the visual fields have been reported (Gardner & Irvine 1972, Bjorak 1978). As such patients have no difficulties in work or other daily activities, the discovery of visual field defects may lead to the late diagnosis of ONH in patients with normal visual acuity. Such defects can raise the erroneous suspicion of neurologic disease and may lead to unnecessary investigation (Bjorak 1978, Shipkin & Glaser 1979).

1 . 6 . 5 Pupillary light reactions:

Careful assessment of the pupillary light reflex is very important in suspected cases of ONH, since there is usually some demonstrable degree of afferent pathway defect. This includes cases with normal visual acuity but with extensive field defects. In unilateral or asymmetrical cases the Marcus-Gunn pupil can be elicited.

1 . 6 . 6 Refraction:

The literature concerning ONH has been reviewed (Zion 1976); 40 reported cases of ONH were found in which the refraction had been documented. The spherical and cylindrical components were thought to be distributed as in the general population.

1 . 6 . 7 Ophthalmoscopic findings:

The small size of the optic disc may be apparent on funduscopy. However, careful study of fundus photographs is recommended in all cases where the diagnosis is uncertain, or when the degree of the optic nerve abnormality is in doubt (Edwards & Layden 1970, Seeley & Smith 1972, Billson 1973). A slightly elevated blurred appearance of the optic disc margin characterizes the normal disc margin (Stromland 1985). When the normal number of nerve fibres congregates on the disc border the disc margin looks blurred. In hypoplastic optic discs there is a diminished number of nerve fibres at the disc border which may account for the sharply defined margins (Frisen & Holmegaard 1978). The most common change seen around the optic disc is the presence of a circumpapillary halo, the size of which usually corresponds to that of the normal disc (Zion 1976). This gives rise to the appearance commonly described as the "double-ring sign". The halo seen around the disc can be pigmented or non-pigmented, and can be circumferential or partial (Zion 1976). Stromland (1985), has stated that double rings occur also with normal optic discs, but no examples or evidence was shown.

For differentiation from optic nerve atrophy and from hypermetropia see sections 1.6.11, and 1.6.12.

The macula may show a featureless appearance with a flattening of the normal contours, and loss of the foveal light reflex (Martyn & DiGeorge 1987). These

changes are due to the relative absence of nerve fibres, the paucity of which can be discerned with red-free light.

The retinal vessels are usually of normal appearance as the mesodermal elements are not involved. However retinal vascular tortuosity has been reported in association with ONH (Kottow 1978).

1 . 6 . 8 Neurological associations:

Septo-optic dysplasia:

In his series in 1956, De Morsier found that 25% of 36 brains with agenesis of the septum pellucidum had significant optic nerve hypoplasia. While in 12 out of the 45 patients with ONH reported by Acers who underwent computerised tomography (CT), there was evidence of partial or complete absence of the septum pellucidum, providing an incidence of 27% (Acers 1981).

The neurological non-ocular clinical features of septo-optic dysplasia are mental retardation, spasticity, abnormalities of taste, and anosmia or hyposmia (Baker & Baker 1984). However, some patients have only mild deficits with normal intelligence (Baker & Baker 1984). Septo-optic dysplasia can occur with intact septum pellucidum (Kuriyama et al 1987). Other clinical features of septo-optic dysplasia are related to endocrinological defects (section 1.6.9) and the

treatment therefore, consists of hormone replacement therapy. Isolated absence of the septum pellucidum may be a single, asymptomatic anomaly, first diagnosed at necropsy (St.John & Reeves 1957). However, ablation of the septum pellucidum in animals impairs their ability to learn tasks requiring spatial orientation (Freid 1972). A spatial learning disorder in a 13 year old girl with severe ONH and absence of the septum pellucidum has been reported (Griffiths & Hunt 1984), and it would be useful to investigate the prevalence of such a condition in a number of such patients because it may allow designation of more suitable school education for these children.

Value of neuro-radiology in septo-optic dysplasia:

Enlargement of the pituitary stalk and infundibulum may be seen when septo-optic dysplasia is associated with diabetes insipidus (Manelfe & Rochiccioli 1979). In 3 out of 4 patients with septo-optic dysplasia examined by Kaplan et al (1970), pneumoencephalography demonstrated dilated ventricles. The suprachiasmatic cistern was also found to be enlarged on CT scan in a case of ONH with pituitary dwarfism with a normal septum pellucidum (Ishihara 1983). The anatomical defects of septo-optic dysplasia may be subtle, and an apparently normal septum pellucidum on CT does not invalidate a clinical diagnosis of a mild form of septo-optic dysplasia (Wilson et al 1984).

The merits of CT as an investigative technique are that it is relatively non-invasive, and that it has a high degree of reliability and diagnostic accuracy (Moseley 1983, Raybaud 1983). For cases of bilateral ONH, a CT scan is usually indicated to exclude midline or other cerebral structural abnormalities (Welleber & Palmer 1981). In particular it has been recommended that children with bilateral ONH, nystagmus and poor vision should undergo a thorough neuro-radiographic and endocrine work-up (Lambert et al 1987). It has been shown that CT accurately delineates the altered anatomy of septo-optic dysplasia (Manelfe & Rochiccioli 1979, Krause-Bruckner & Gardner 1980). A CT scan, or a cranial ultrasound, is particularly required in the neonate in whom it is important to determine the full extent of neurological involvement in order to anticipate any future developmental problems including growth retardation.

Skarf and Hoyt (1984), reported neuro-radiographic abnormalities in 39% of 41 children with bilateral ONH, poor vision and nystagmus. These comprised 16 patients and included 4 with absence of the septum pellucidum, 2 with absence of the corpus callosum and 2 in whom both these midline structures were missing. Three children had encephalocoeles, three had porencephaly and one had hemispheric atrophy.

The investigation of cerebral structure can also be carried out in infants through the anterior fontanelle

by means of real time cranial ultra-sound examination (Levene et al 1985). Fielder et al (1986), were the first to perform cranial ultrasound on patients with bilateral ONH. In 4 cases in which both cranial ultrasound and CT scan were performed, no additional information was gained from the CT scan. Two of the cases had absence of septum pellucidum and two had intracranial cystic spaces (Fielder et al 1986). Cranial ultrasound visualization is limited in the extreme frontal and occipital poles as well as in the most lateral parietal regions (Levene et al 1985). Cranial ultrasound can only be utilized for this purpose before the cranial sutures are closed, and it has the advantage of not requiring sedation. Comparing the resolution of CT scan to cranial U/S, CT scan has a superior resolution (Levene et al 1985).

Magnetic resonance imaging (MRI) has also been used in the new born to investigate intracranial structure and pathology. However, the role for MRI in cranial imaging of infants has not been clearly defined (Levene et al 1985).

Other CNS associations:

ONH is associated with a group of "cystic disorders" including schizencephaly (Zimmerman et al 1983, Osborne & Byrd 1988), hydrocephaly, hydranencephaly and porencephaly (Mosier et al 1978, Greenfield & Wilson et al 1980). Margolith et al (1984), reported a series of

51 patients with ONH who were referred for evaluation to the Program for Visually Impaired Children at the Children's Hospital in Vancouver. In their study, 38 patients underwent neuroradiological investigation. The abnormalities reported included absent septum pellucidum, absent corpus callosum, hydranencephaly, porencephaly, cerebral atrophy, cerebellar atrophy, cerebral infarcts and hydrocephaly.

A porencephalic cyst contains cerebrospinal fluid and usually communicates with the ventricles or the subarachnoid space. It is more commonly due to acquired focal parenchymal loss (Levene et al 1985,).

Schizencephaly is characterized by bilateral clefts which tend to be symmetrical, and extend through the entire cross-section of the cerebral hemisphere. They occur as localized arrest of growth early in development (Raybaud 1983, Zimmerman et al 1983).

ONH is associated with other CNS disorders including, cerebral atrophy (Roger et al 1981), microencephaly, anencephaly (Boniuk & Ho 1979), perinatal encephalopathy, cerebellar atrophy (Margolith et al 1984), colpocephaly (Garg 1982), basal encephalocoele (Goldhammer & Smith 1975), congenital suprasellar tumours (Taylor 1982, Farmer & Hoyt 1984), and occasionally congenital third, fourth and sixth nerve palsies and up-gaze palsy (Crawford & Morin 1983). Walker's Lissencephaly (agyria) is a form of multiple

ocular and cerebral malformations, which is also associated with ONH (Chan et al 1980).

It appears that children with severe visual loss due to ONH commonly have other neurological deficiencies including cerebral palsy, mental retardation, and seizures (Margolish & Jan 1984). Skarf and Hoyt reported neuro-radiographic abnormalities in 39% of the children in their series with bilateral optic nerve hypoplasia, poor vision and nystagmus, while 52 children with bilateral segmental ONH with good vision, and children with unilateral ONH fared better as only three had endocrine problems. Another child showed agenesis of the septum pellucidum and 4 more children had developmental delay (Skarf & Hoyt 1984). Therefore, it has been suggested that the majority of patients with unilateral and with segmental ONH have no such associated disorders (Skarf & Hoyt 1984).

In ten out of 51 cases of ONH, behavioural problems were noted. These ranged from attention deficit disorders to autistic, aggressive or violent behaviour (Margolish et al 1984).

1. 6 . 9 Endocrinological associations

Variable pituitary dysfunction is part of the syndrome of septo-optic dysplasia (Kaplan et al 1970, Margolish et al 1984, Baker & Baker 1984, Morishima & Aranoff 1986). Moreover, ONH with a normal septum pellucidum can also be associated with hypopituitarism (Costin &

Murphree 1985). ONH is associated therefore, with treatable pituitary dysfunction in which there is a wide range of severity in hormone deficiency extending to dwarfism and hypopituitarism. On the other hand, there may be slight growth hormone deficiency demonstrable in early childhood only by a subnormal response to provocative stimulation by an insulin load or by arginine infusion (Costin & Murphree 1985). Pituitary hormone levels may be normal in the non-stressed situation. The treatment therefore, of septo-optic dysplasia consists of early diagnosis of the hormonal deficit and hormone replacement therapy (Baker & Baker 1984). It has been suggested that the hypopituitarism is caused by deficiency of hypothalamic-hypophysiotropic factors (Kaplan et al 1970, Morishima & Aranoff 1986). It has been postulated that this deficiency of tropic factors is caused by an abnormality in the embryologic development of the diencephalon (Kaplan et al 1970). Although deficiency of growth hormone is the most prevalent endocrine abnormality (Margalith et al 1985, Kaplan 1970, Olivier & Billson 1986), multiple trophic hormone abnormalities are commonly present including sexual infantilism, hypoadrenalism and hyperprolactinaemia. Seizures with or without hypoglycaemia (Costin & Murphree 1985), feeding problems and lethargy may be early indicators of an endocrine disorder. Wilson et al (1978), confirmed that the hypopituitarism seen in this syndrome was caused by hypothalamic insufficiency, they demonstrated pituitary responsiveness to exogenously administered hypothalamic

releasing factors in a patient with septo-optic dysplasia and panhypopituitarism.

Since the association of pituitary hypofunction and optic nerve hypoplasia was first documented in 1970 (Hoyt et al 1970) the true incidence of hypopituitarism with ONH has not been determined in a large series of patients. It has been shown that normal growth in ONH associated with absence of growth hormone is possible, and this has been proposed to be due to elevated insulin or prolactin levels which may have promoted growth (Costin & Murphree 1985). Furthermore, unlike patients with idiopathic hypopituitarism who commonly manifest delayed growth beginning at six to fifteen months of age, children with septo-optic dysplasia and a deficiency of growth hormone will frequently have normal growth until their third or fourth year of life, possibly due to the concomitant hyperprolactinaemia (Costin & Murphree 1985, Lambert et al 1987). The 23 patients with ONH described in this study were aged between 6 months and 19 years (16 bilateral and 7 unilateral). The incidence of hypopituitarism was found to be 65% . Fine nystagmus was described as being present in the affected eyes of all the patients studied (Costin & Murphree 1985). Diabetes insipidus was also reported in association with bilateral ONH, and in association with septo-optic dysplasia (Sheridan & Robb 1978). Autopsy on one patient who had bilateral severe ONH, hypopituitarism and diabetes insipidus showed absence of the posterior lobe of the pituitary gland and the tissue

of the hypothalamus was found to be distorted in its anterior part, and the cells of the supra-optic and paraventricular nuclei were abnormally small and few in number (Patel et al 1975).

Pituitary dysfunction may also manifest itself as prolonged neonatal hyperbilirubinaemia, hypotonia and infantile hypoglycaemia without hyperinsulinaemia (Patel et al 1975, Costin & Murphree 1985). The prolonged neonatal hyperbilirubinaemia is thought to be due to hypopituitarism (Schindler & Pleasure 1985). The association between trophic hormone abnormalities, neonatal hypoglycaemia and unexplained neonatal jaundice suggests that careful ophthalmoscopy is indicated for neonates presenting with these problems (Margolith et al 1984). Hypothyroidism and growth retardation comprise other manifestations.

Pituitary dysfunction can complicate general anaesthesia, especially if it has not been recognised pre-operatively (Sherlock & McNicol 1987). General anaesthesia may be required for treatment of other associated congenital abnormalities, as well as for incidental surgical emergencies.

Skarf and Hoyt (1984) studied 93 cases of children with ONH and found that hypothyroidism was the most frequent endocrine disturbance in their patients (Skarf & Hoyt 1984). This was an unexpected finding, in view of the frequently emphasized principal association of ONH and growth hormone deficiency. In this prospective study of 93 patients with ONH, which was carried out in the

Children's Eye Clinic at the University of California Medical Centre, San Francisco, between July 1977 and May 1982, developmental delay was reported as the most common non-visual association occurring in 24% of all the cases, and in 46% of the forty one cases who had bilateral ONH, poor vision and nystagmus (Skarf & Hoyt 1984). Some of these children did not have structural anomalies detectable on CT scan, nor did they have detectable endocrine dysfunction. Therefore good vision, normal CT scan and normal endocrinological findings cannot assure normal development in a child with ONH. However, the patients with unilateral ONH in this study (11 cases) developed normally, and in patients with segmental ONH (41 cases), developmental delay was reported in only 4 cases (9.75%).

1 . 6 . 10 Other ocular and systemic associations

Other disorders associated with ONH include albinism (Weleber & Palmer 1981, Spedick & Benchamps 1986), high myopia (Skarf & Hoyt 1984), chorioretinal coloboma and optic nerve head coloboma (Brown 1982). Potter's syndrome (Brownstein et al 1976), neonatal alloimmune thrombocytopenia (Davidson et al 1989), and 80% of patients with aniridia have also been reported to have ONH (Layman et al 1974). Occasionally ONH may be found in association with microphthalmos (Crawford & Morin 1983). Other reported associations are Klippel-Trenaunay-Weber syndrome (Rathbun et al 1970), Goldenhar-Gorlin syndrome (Margolis et al 1984),

Duane's retraction syndrome (Denslow & Sims 1980), hemifacial atrophy (Edwards & Layden 1970), Meckel syndrome (MacRae et al 1972), blepharophimosis (Lloyd & Buncic 1980, Crawford & Morin 1983), Aicardi syndrome (Aicardi 1969, Harcourt 1976, Aicardi & Goutieres 1981), chondrodysplasia punctata (Levine et al 1974, Billson & Hoyt 1977), osteogenesis imperfecta (Kreibig 1959), deletion of the long arm of chromosome 13(13q-) (Weincheselbaum et al 1979), Trisomy 18 " Edward's syndrome" (Calderone et al 1983), and a single case association with the syndrome of nevus sebaceous of Jadassohn has been reported (Katz et al 1987).

Midline facial defects, have also been occasionally reported (Stewart et al 1983, Morishima & Aranoff 1986) including hare lip, cleft palate and hypertelorism. However, it has been thought that the majority of patients with unilateral and with segmental ONH have no associated disorders (Skarf & Hoyt 1984) and are therefore only detected during routine assessment by individuals aware of the condition.

1 . 6 . 11 Differentiation from optic atrophy

ONH is not infrequently incorrectly diagnosed as optic atrophy (Seeley & Smith 1972). Although glial tissue usually imposes a rather pale colour to the disc in ONH (Krause-Bruckner & Gardner 1980, Brown 1982), it may be of normal colour, and it is the size and not the colour which is the essential diagnostic feature which distinguishes optic nerve hypoplasia from optic atrophy.

Red-free light ophthalmoscopy can be useful to delineate the area of the optic disc. It has been suggested that non-progressive optic atrophy acquired any time before full development of the eye and the visual pathway, can produce a small atrophic optic disc which resembles ONH (Frisen & Holmegaard 1978).

In an infant, examination with sedation or general anaesthesia, including fundus photography, may be required to differentiate ONH from optic atrophy. Such differentiation is important in order to plan the investigation of the patient appropriately and also to provide adequate background data for counselling parents.

1 . 6 . 12 Differentiation from hypermetropia

ONH should be differentiated from high hypermetropia which may give a false impression of hypoplasia.

Therefore the refractive state of the eye should always be assessed. The small optic disc may be difficult to diagnose and clinical judgement is necessary in such cases since there are no absolute criteria and no readily available techniques for measurement.

Ophthalmoscopic diagnosis of optic nerve hypoplasia may be equivocal in hypermetropic patients, in cases of bilateral mild hypoplasia and in cases of subtle unilateral hypoplasia of the optic disc. In such cases red-free fundus photography using high resolution film can be used to examine the retinal nerve fibre layer for

evidence of defects which correspond with the visual field loss (Frisen & Holmegaard 1978). Evaluation of the retinal nerve fibre layer offers an alternative approach to the problem of recognising minor ONH. This approach is also more direct, as the neuro-anatomical hallmark of optic nerve hypoplasia is a smaller than normal number of optic nerve axons (Frisen & Holmegaard 1978). However, many cases of ONH show a uniformly thin nerve fibre layer within affected areas. This particular type of defect is much more difficult to define with certainty than are focal defects (Hoyt et al 1973).

Absolute measurement of the size of the optic disc is difficult even in emmetropic eyes, because variation in size can substantially alter the total dioptric power despite no correction being required (Sorsby 1964). An alternative method is to compare the diameter of the optic disc to other measurable parameters within the same eye. Although this assumes that the paired parameters bear a constant relationship to each other. The disc-macula: disc diameter ratio as evaluated from fundus photographs when in excess of 3 may be indicative of milder forms of ONH (Awan 1976, Wakakura & Alvarez 1987, Alvarez et al 1988).

The size of the disc image in fundus photographs is influenced by the anatomical dimensions of the eye including the axial length, corneal curvature and the shape of the fundus (Littmann 1982), and by refractive errors and optical aberrations. The magnitude of these

factors is generally not known for individual eyes, but it has been claimed that their effect is relatively small (Bengtsson 1976). Absolute measurements may be achieved by using interference fringes to produce a scale on the optic disc (Kennedy et al 1983), but this method requires sophisticated instrumentation and a very cooperative patient.

Franceschetti & Bock (1950), measured the disc diameter by means of focal illumination of the fundus with a slit lamp, using contact lens biomicroscopy with a micrometer scale. Estimation of the size of the optic disc by comparing the slit beam width on the Haag-Streit 900 slit lamp with the optic disc on contact lens biomicroscopy has also been tried for assessing the diameter of the hypoplastic optic disc relative to the beam (Beuchat & Safran 1985). These "measurements" are useful in comparing the diameter of the optic disc relative to the slit lamp beam or the scale, as their magnification when projected on the optic disc is assumed to be the same as the magnification of the optic disc, which is produced by the optical system of the eye.

Comparing the size of the disc to the size of the whole part of the fundus as seen in the standard fundus photograph, has also been suggested (Taylor 1982). Spinelli (1934), proposed indirect ophthalmoscopic measurement with a scale on the frontal or ocular lens. Direct measurements of the orbital part of the optic

nerve is possible using CT scanning. A-scan ultrasonography (Acers 1981), and B-scan ultrasonography (Boynton et al 1975) may also be useful.

1 . 7 Investigations:

1 . 7 . 1 Visual fields:

Visual field defects have been described only occasionally in ONH mainly because most of patients are too young, at presentation. However, in seventeen patients with ONH in whom the fields were tested it was shown that the commonest visual field abnormalities comprised bitemporal defects (seven cases), and generalised constriction (six cases) (Acers 1981). Bitemporal hemianopia in ONH may be a helpful sign to detect the presence of midline CNS defects (Ellenberger & Runyan 1970, Rush & Bajandas 1978).

Petersen & Walton (1977) have reported another seventeen patients with segmental ONH and good visual acuity who were all the offspring of diabetic mothers. Most had bilateral inferior altitudinal visual field defects which spared fixation. Several other forms of visual field defect have been reported including binasal defects, small arcuate defects and centrocaecal scotomata (Seely & Smith 1972).

The relationship of the pattern of the field defects to the underlying cause or association has not been

established.

1 . 7 . 2 Contrast sensitivity:

To the best of the author's knowledge no reports are available in the literature regarding the status of contrast sensitivity in patients with ONH.

1 . 7 . 3 Colour vision:

Colour vision testing has been performed in one case, and was reported as being abnormal (Walton et al 1970). No information was given on the nature of the abnormality. Colour visual function has been mentioned in only one other patient who had bilateral ONH and it was reported as being normal in both eyes (Novakovic et al 1988). No study has been performed to assess the state of colour vision in a group of patients with ONH.

1 . 7 . 4 Fluorescein angiography:

Fluorescein angiography has been performed on a single patient with bilateral ONH, and was reported as being "consistent with optic atrophy " (Walton et al 1970). No further details were given.

1 . 7 . 5 Radiology of the optic canals:

Reduction in the size of the optic canals may be seen on X-ray (Helveston 1966). The technique of axial

tomography of the optic canals has been found more useful in this regard than plain foraminal views (Boynton et al 1975). However, it has been reported that there may be a disparity in size between the right and left optic canals in normal individuals who have no ocular defects, and that this may result in a 20% difference in size (Edwards & Layden 1970). There does not appear to be a good correlation between ONH and the degree of diminution of the diameter of the optic canal as seen with optic foraminal projection (Walton et al 1970).

1 . 7 . 6 Electrophysiological investigations:

Electroretinography and electrooculography are normal in isolated ONH, but the amplitude of the visual evoked response (VER) is commonly reduced. However, it appears that the VER is useful only as a means of estimating the visual function at an early age, as it correlates with the clinical assessment of vision (Francois & De Rouck 1976, Sprague & Wilson 1981, Margolith et al 1984).

Severe bilateral cases of ONH present in early infancy with pendular nystagmus or rolling eye movements, in these cases the demonstration of a normal ERG response can be of critical diagnostic importance in differentiating the condition from conditions such as Leber's amaurosis and achromatopsia.

1 . 8 Conclusion :

In conclusion, ONH is an enigmatic condition which is increasingly being recognised. It should be sought in any child with poor vision or in patients labelled as having amblyopia resistant to occlusion. The following case report of a patient who presented after the completion of the reported study clearly illustrates this point:

CASE REPORT:

A four year old boy was referred to the RHSC. The reason for referral was growth retardation. He had had two squint operations during the year prior to his referral to the RHSC. He was diagnosed as having dense strabismic amblyopia in the left eye. On presentation to the RHSC he was fixing on near objects well with the right eye, but his left eye had a visual acuity of only light perception. He had fine bilateral pendular nystagmus and a consecutive constant exotropia of the left eye. Funduscopy showed bilateral ONH with a non-pigmented double ring sign in both eyes. Cycloplegic retinoscopy revealed 2.5 dioptres of astigmatism in the right eye and 0.75 dioptres in the left. The total spherical power for each eye was +3.75 dioptres. He was subsequently found also to have chronic hypoglycaemia and panhypopituitarism, he was thought also to have mental retardation. A cranial CT Scan was arranged which showed dilatation of the suprasellar cistern but the septum pellucidum was intact.

All children with ONH, particularly those with severe visual loss, and all bilateral cases with impaired vision, should undergo careful clinical evaluation and appropriate investigation. This should include a cranial neuro-radiological examination (Section 1.6.1). Investigation of pituitary function is carried out if warranted by the general physical examination of the child with special reference to height and weight, and should be performed upon all children with an abnormal CT appearance. Any change in the child's normal course of development and maturation signals the need for investigating the endocrinological status. The frequent association of CNS anomalies and endocrine problems with ONH is an important piece of information which the attendant ophthalmologist must convey to the paediatrician and the family practitioner, with a view to arranging appropriate and early treatment.

OBJECTIVES

CHAPTER 2

2. OBJECTIVES:-

2 . 1 Introduction:

The foregoing literature review highlights that there are many unknown features concerning ONH and its pathogenesis. The aim of the present study is to investigate certain aspects of visual function, some of which have not hitherto been evaluated, and to assess the associated neuro-radiological and the endocrinological associated abnormalities in patients with ONH.

2 . 2 Aims and Protocol:

2 . 2 . 1 Clinical case load:

Aim: To identify as many individuals as possible with ONH, to classify the degree of hypoplasia and to relate to associated diagnoses..

Protocol: The disease index of the Royal Hospital for Sick Children (RHSC), Glasgow from 1968 onward was used to identify as many patients as possible who had been coded as having ONH. Additional patients were sought from the out-patient records, patients seen by the author and patients referred to the author during the period of the study were also

included in the study.

CASE REPORT:

An eight years old (patient No 35) healthy child was referred by her General Practitioner to the out-patient department, RHSC, Glasgow, because of "squint".

She had right Duane's retraction syndrome

characterised by limited adduction in the right eye, narrowing of the palpebral aperture in this eye on attempted adduction, right inferior oblique muscle overaction, limitation of elevation, and diplopia on left gaze. There was also segmental hypoplasia of the right optic disc. Her unaided visual acuities were OD: 6/6+ OS: 6/6+. Cycloplegic retinoscopy revealed no significant refractive error.

Association of optic nerve hypoplasia with

Duane's retraction syndrome has previously been reported (Denslow & Sims 1980). However, to the best of the author's knowledge an association of segmental ONH with Duane's retraction syndrome has not hitherto been reported.

2 . 2 . 2 Maternal history:

Aim: To determine whether those features, which have hitherto been regarded as risk factors for ONH are identifiable for the

population in this study. Also to determine the role of cigarette smoking by mothers during pregnancy as a possible risk factor.

Protocol: The mothers of patients with ONH were asked to complete a questionnaire concerning their perinatal history (see section 3). The assistance of a nurse and the author were provided as required. A control group of 65 normal mothers was requested to complete the questionnaire form as well. The control group comprised mothers of children with no significant eye problems (see section 3). The results obtained from mothers of patients were compared with those from the control group.

2 . 2 . 3 Visual acuity:

Aim: To establish whether there is impairment of visual acuity in patients with ONH, and to determine its degree.

Protocol: The Snellen's chart was used to assess the visual acuity for distance. The luminance of the Snellen's chart was tested at the beginning of the period of the study.

2 . 2 . 4 Refractive state of the eyes:

Aim: To determine the incidence and

characteristics of refractive error in patients with ONH .

Protocol: Retinoscopy was performed under cycloplegia induced by 1% cyclopentolate eye drops. Retinoscopy was also performed on a group of normal individuals.

2 . 2 . 5 Colour vision:

Aim: To assess the state of colour vision in patients with ONH.

Protocol: The Ishihara pseudo-isochromatic plates were used in artificial daylight. A control group of normal subjects were also studied. The illumination of the artificial day light was measured.

2 . 2 . 6 Contrast sensitivity:

Aim: To determine the state of contrast sensitivity in patients with ONH, and to compare the findings with a group of age matched normal control subjects.

Protocol: The patients and the control subjects were tested by means of the Cambridge low contrast gratings in artificial light. The illumination was also measured.

2 . 2 . 7 Brightness-sense comparison test:

Aim: To determine the brightness-sense quantitatively in the eye with ONH and to compare it to the unaffected eye in patients with unilateral ONH, and in patients with asymmetrical ONH.

Protocol: Patients with unilateral and asymmetrical ONH were selected for this study to see if the brightness sense was asymmetrical, and the sensitivity of this test was determined. A group of normal subjects was also studied to determine the confidence limits for this investigation.

2 . 2 . 8 Photography and measurements:

Aim: To assess the relative sizes of the optic disc as compared to normal subjects.

Protocol: Forty degree colour and red-free fundus photographs were taken. The VIDS V image analysis system (AMS Ltd.) was used to assess the optic disc dimensions from a group of patients and matched but masked normal control subjects. Two coloured fundus photographs (using 64 ASA Kodak Ektachrome film), and two red-free photographs (using 400 ASA Kodak Ektachrome film) were taken for each eye of the

patient group and the control group. The clearest colour photographs or the clearest red-free photographs were selected. Readings were taken for each slide using the image analyser. These readings were taken by a "masked" observer for the vertical and the horizontal diameters of the optic discs and the disc-macula distance.

2 . 2 . 9 Neuro-radiology assessment:

Aim: To review the cranial ultrasound and cranial CT scan findings in patients who have ONH, and to assess the associated intracranial neuro-radiological deficits in patients with ONH.

Protocol: The cranial CT scans and the cranial ultrasounds of all patients with ONH were reviewed with the assistance of a consultant paediatric radiologist. The following abnormalities were sought:-

1. Cystic disorders: Hydrocephaly, hydranencephaly, porencephaly, schizencephaly and encephalocele.
2. Agenesis of the septum pellucidum.
3. Agenesis of the corpus callosum.
4. Dilatation of suprasellar and chiasmatic cistern.

5. Enlargement of the pituitary stalk and infundibulum.
6. Microcephaly.
7. Cortical atrophy in its two types diffuse and focal.
8. Cerebellar atrophy.
9. Cerebral infarction.
10. Optic nerve hypoplasia.

The range and characteristics of neurological disturbance associated with ONH was thereby determined for the cohort of patients studied.

PATIENTS AND METHODS

CHAPTER 3

3 PATIENTS AND METHODS:-

3 . 1 Patients:

3 . 1 . 1 Patients with ONH:

The sources of patients are listed below:

1. The in-patient disease index of RHSC: 17 cases
2. The RHSC Out-Patient Department diagnostic index maintained by the consultant staff: 14 cases.
3. Aberdeen Royal Infirmary (with permission of the Head of the Department): Two cases.
4. Newly identified cases during the period of the study: Two cases.
5. Patients referred to the author during the period of the study: Two cases with unilateral segmental ONH.

The in-patient disease index of the Royal Hospital for Sick Children (RHSC), Glasgow included only records of patients until 1986.

A total of 37 patients were thus identified ranging in age from 1 to 43, (the mean age of the patients was 9.97 years) and residing in Glasgow or outside Glasgow in areas including Irvine, Motherwell, Banknock, Whithorn and Dunoon. One patient who had panhypopituitarism and severe mental retardation (No 18) had died at the age of 8, therefore only her neuro-radiographs were included in the study. The 36 patients were invited to attend the author's clinic in the RHSC at the most convenient time for them and / or their parents. A letter was

distributed with a request to indicate the most convenient time(s) and to return the form in an enclosed stamped addressed envelope. Their dates of birth, sex and details of their medical conditions were recorded.

3 . 1 . 2 Control subjects:

Sixty five mothers of a group of normal children were interviewed with regard to maternal history, and comprised practically all mothers of normal children who attended the Dermatology Clinic in the RHSC with simple skin warts, during the period of the study, six mothers of patients attending the Orthopaedic Clinic, and two mothers of children with healed chalazia. A maternal history was also taken from 18 mothers of normal School children from Kelvinhaugh Primary School, those school children were identified after permission from the Health Authorities had been sought, and consent of the parents had been obtained. All the 18 school children who attended the research clinic underwent eyesight tests, and their data together with data from two normal adult volunteers were used as normal controls for the tests performed in this research.

3 . 2 Methods:

3 . 2 . 1 Maternal history:

Mothers of patients were requested to complete a questionnaire. The assistance of a nurse and the author

was provided as required. A total of 65 mothers of normal children completed the questionnaire form. The results were compared with those of the patient group.

3 . 2 . 2 Visual acuity:

The Snellen chart was used to test both the uncorrected and the corrected visual acuities for a measured distance of 6 metres. The luminance of the Snellen test type was measured by using a Solex SL 100 Lux meter; the mean screen luminance of 6 readings was 2900 asb. In cases for whom reading the Snellen letters was difficult due to young age or to mental retardation, identification of the Snellen letters was sought by asking the patient or the normal control subject to point at a letter which looked the same as the one on the Snellen chart, as on a Sheridan-Gardiner letter test form held by hand.

3 . 2 . 3 Retinoscopy:

All patients, and all control subjects received one drop of 1% Cyclopentolate to induce cycloplegia in each eye 1/2 an hour before retinoscopy. Retinoscopy was performed by using the right eye of the examiner to test the right eye of the patient, and the left eye of the examiner to test the left eye of the patient. Retinoscopy was performed from a distance of two thirds of a metre, and as close to the visual axes of the patient as possible. The patients were encouraged to look at a target positioned 6 metres away.

3 . 2 . 4 Colour vision:

Colour vision was tested by using the 24 plate edition of Ishihara pseudo-isochromatic plates in artificial daylight by means of using a VeriVide colour matching light cabinet (Leslie Hubble Ltd.) of a mean illumination of 1100 Lux. The test was performed at a distance of 75 cm. The plates were tilted so that the plane of the paper was at right angles to the line of vision. It has been recommended that a maximum of three seconds should be allowed to read each number in a plate, and 10 seconds for tracing a line. In our patients a maximum time of five seconds was allowed to read each number in a plate. For tracing a line the patient was encouraged to take a maximum of 15 seconds for each line tracing.

For analysis of the results, assessment of the readings of plates 1 to 15 determined the normality or defectiveness of colour vision. The Ishihara plates were designed to provide a test which gives a quick and accurate assessment of red/green colour vision deficiency of congenital origin. However, the author recommends that only if 5 or more plates were not read by the patient the colour vision should be regarded as deficient.

Plates for which tracing the winding lines is required were used for one patient.

3 . 2 . 5 Contrast sensitivity:

Contrast sensitivity was assessed by using the

Cambridge low contrast grating system (Clement Clarke International Ltd.) at a measured distance of 6 M. The gratings are designed to measure contrast sensitivity at only one spatial frequency. At a viewing distance of 6 metres each plate subtends 2 degrees and contains eight cycles per plate. The gratings therefore have a spatial frequency of 4 cycles / degree. It was found that such a spatial frequency to be most suitable for detecting impairment of contrast sensitivity resulting from diabetes, glaucoma and multiple sclerosis (Wilkins & Robson 1988). The Cambridge Low Contrast Gratings have a square-wave luminance profile. Spectacle correction for distance was worn whenever required. The testing room was illuminated by diffuse artificial lighting. Particular attention was paid to avoiding a visible sheen on the surface of the plates. The mean illumination of the chart taken from 6 readings was 500 Lux. Each eye was tested separately. The test comprises 12 pairs of plates. The first pair of plates serves as a demonstration. The next ten pairs of plates form 10 test stimuli. The last pair is not numbered and was not used. The subject was first shown a demonstration page and was instructed to choose which page ("top" or "bottom") contained the stripes. Then subsequent pairs of pages in numerical order were shown, and the subjects were encouraged to respond. The test was stopped when the first error occurred (or at No.10), and repeated until 4 series had been completed for each eye, each time by going " back" four plates from where the last test stopped (or to the demonstration plate). The number of

the plate at which the error occurred was noted each time, 11 was entered if no error. The four scores were added together, the resulting number is the total score for the series. The total score for each eye was converted to a measure for the contrast sensitivity by using the conversion table provided with the testing material (Wilkins & Robson 1988). The test was performed with the patient wearing distance correction whenever required.

3 . 2 . 6 Brightness-sense comparison test:

The brightness-sense comparison test is a means of determining the differences in the subjective appreciation of the brightness of a diffuse light source (Mainster & Dieckert 1980, Sadun & Lessel 1985). The patients and the control group were tested by means of a pair of plane polarizing filters in front of each eye. These were placed in a standard trial frame. The amount of light transmitted was changed by rotating the front lens. The polarizers allow maximum transmission of light when set at 0 degrees to each other, and minimum transmission when set at 90 degrees to each other. The mean amount of transmitted light was measured with each successive 5 degrees of angle difference, and the percentage of light transmitted through the pair of polarizers as compared to the maximum light transmission when they were at 90 degrees to each other was also calculated (Figure 2). Each patient was seated at a distance of 1 metre from a bright diffuse source of light

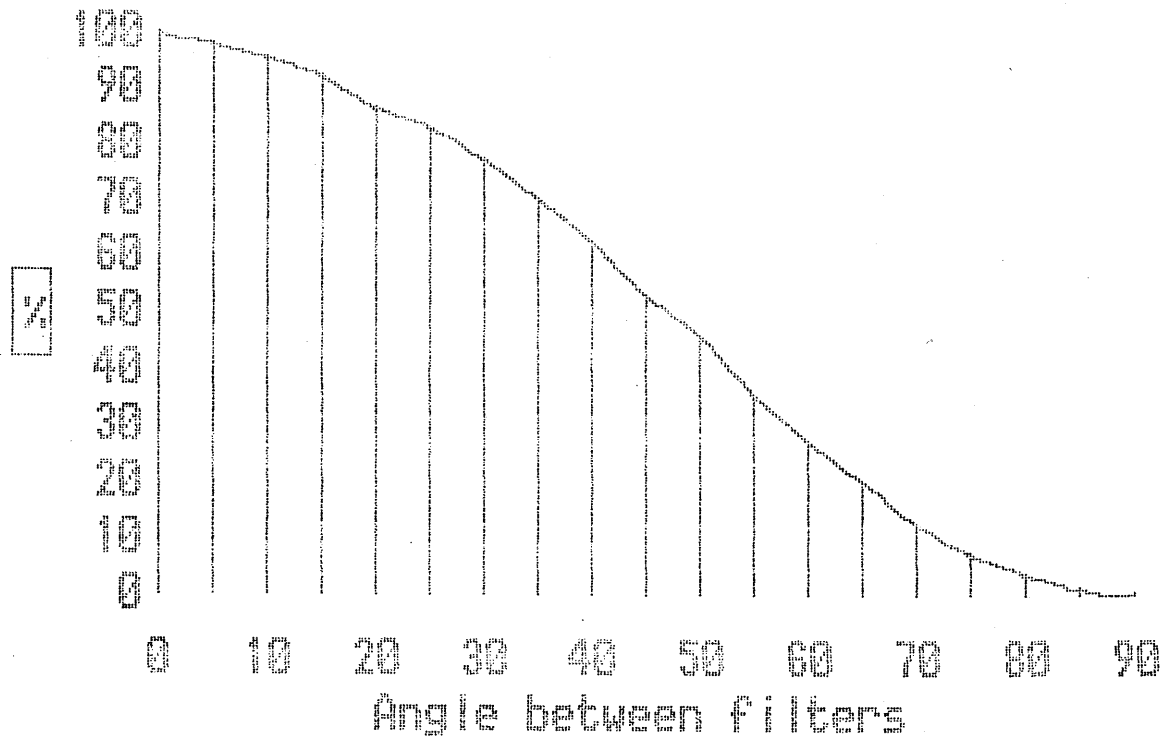


FIGURE 2

Relationship of the percentage of light transmitted through a pair of plane polarizing filters positioned at different angles to each other.

(X ray film viewing light box), the mean luminance of which was measured by using the Solex SL 100 and was 5500 asb. Each patient was encouraged to concentrate only on the brightness of the light source during the test. The sizes of the pupils were examined as the brightness is related to the size of the pupil. No patients or control subject was found to have anisocoria greater than 1 mm.

Patients were asked if they noticed any difference between the two eyes, while each pair of polarizers was positioned at an angle of 0 degrees to each other, with regard to the brightness of a diffuse light source. At the same time each eye was alternately occluded. For all patients who answered positively the test was continued. Only patients with asymmetrical ONH were able to appreciate a difference in brightness between the two eyes. The front polarizing filter in front of the "brighter" eye was rotated by the examiner at 5 degree intervals. At the same time each eye was alternately occluded until the brightness of the light source appeared the same for the two eyes. This was repeated three times. The mean value from the 3 readings was calculated.

Seventeen normal subjects were also tested to establish the degree of reliability of the subjective test. All subjects in the normal group stated that the brightness was the same for the two eyes. The polarizers were arranged at an angle of 90 degree to each other, and the normal subject was asked to state when the brightness of the diffuse test object appeared the same for the two

eyes. The angle was decreased by 5 degree intervals while the eyes were alternately occluded. The angle at which the normal subject stated that the brightness appeared the same in the two eyes was recorded. This was also repeated three times, and the average for the three readings was calculated.

The score given was the figure of the percentage of light which is not transmitted, due to the rotation of the plane polarizing filters. This depends on the angle between the two polarizing filters. Figure 2 was used to determine the scores. If the polarizing filters needed to be at an angle of 20 degree to each other for the brightness to be perceived by the patient as equal in the two eyes, the score would be calculated as the percentage of light not transmitted due to the difference between a 0 degree angle and the 20 degree angle i.e 13%. This is because when the filters are at 20 degrees to each other 87% of the light is transmitted compared to the transmission when the pair of filters is at the 0 degree angle.

3 . 2 . 7 Fundus photography and image analysis:

Fundus photography:

One drop of 1% Cyclopentolate eye drops was used to dilate the pupils. Forty degree field of view colour and red-free fundus photographs were taken by using the same fundus camera (Canon CF - 60 Z). An experiment was performed at the beginning of the study to find out the

most suitable film speed to be used for the study. This indicated that 64 ASA was the most suitable for colour photographs, and that 400 ASA was the most suitable for 40 degree red-free light fundus photography. Therefore ~~two~~ colour fundus photographs were taken for each eye using 64 ASA Kodak Ektachrome films, and two red-free photographs using 400 ASA Kodak Ektachrome films were taken for each eye of the patient group and the control group. The clearest colour photograph and the clearest red-free photographs were selected. The reason for choosing both colour and red-free photographs was to help to determine the borders of the optic disc, and the region of the fovea in difficult cases.

In two cases (Patients 16 & 36) 35 degree red free fundus photography had been taken in Aberdeen Royal Infirmary.

Image analysis:

Fundus photographs were assessed by using the VIDS V image analysis system (AMS Ltd.). The vertical and horizontal diameters of the optic disc were measured. The average disc diameter was calculated. The distance from the temporal margin of the optic disc to the fovea was also measured for each photograph from of a group of normal subjects, and of patient group. Half the average diameter of the disc was then added to the measured distance from the fovea to the temporal margin of the optic disc to calculate the "disc-macula distance". Then the disc-macula distance / average disc diameter ratio

(D-M/DD ratio) was calculated for all patients and normal subjects. The same calibration technique was used for all the slides studied. All the readings were taken and analysed separately by an independent observer (GND). The slides of the patient group and the normal subjects were mixed at random before being analysed by the observer.

3 . 2 . 8 Neuro-radiology assessment:

The Royal Hospital for Sick Children, Glasgow provides a referral service for a population of 2.5 million people. Twenty patients have been identified who had undergone neuro-radiological assessment. Of these, 15 patients had undergone CT with a second generation CT scanner (ELSCINT 820), five underwent CT and cranial real time U/S examination (ATL MK 100 system using a 5 MHz probe), and an additional five underwent U/S examination only. All the U/S films and CT scans were evaluated with the assistance of a Consultant Paediatric Radiologist (ASH) according to the following coding protocol:

- = Absent.
- + = Present.
- ? = Could not be assessed.

In assessing the septum pellucidum and the corpus callosum, a further score "+-" was given when these structures were only partially present, to indicate that they were abnormal.

The following associated abnormalities have been discerned in the past:

1. Cystic disorders: Hydrocephaly, Hydranencephaly, porencephaly and schizencephaly.
2. Agenesis of the septum pellucidum.
3. Agenesis of the corpus callosum.
4. Dilatation of suprasellar and chiasmatic cistern.
5. Enlargement of the pituitary stalk and infundibulum.
6. Microcephaly.
7. Cerebral atrophy.
8. Cerebellar atrophy.
9. Cerebral infarction.
10. Optic nerve hypoplasia.

These were actively sought for each case.

The films were reviewed independently of the previous reports. Hydrocephalus was diagnosed if the width of the lateral ventricle, at its widest part in axial or coronal views, exceeded 1 cm (regardless of the patient's age).

Kodak T Max 100 ASA film had been used to photograph the CT Scan films. These photographs are used as illustrations in this thesis.

3 . 2 . 9 Statistical methods:

Various statistical tests were used to analyse data collected, the test employed in a particular case being noted as appropriate in the text.

The chi-squared test was used with normally distributed data except when the low frequency of some occurrence rendered this test unreliable, Fisher's test was then employed.

For interval data, checks were made for normality of distribution. If the distributions were plausibly normal, the t-test was applied, while Welch's method was used if sample variances seemed unequal. On the other hand if data were non-normally distributed, the Mann-Whitney test or Wilcoxon rank sum test was chosen.

With a number of data, there were potential complications arising from the possible lack of true statistical independence of measurements on the two eyes of one subject. In such cases the mean for the two eyes was taken as the datum value for a subject unless only one eye had been assessed in which case the value for that eye was taken. The rationale for this type of analysis has been described previously (Ray & O'Day 1985, Newcombe & Duff 1987).

RESULTS

CHAPTER 4

4 RESULTS:-

4 . 1 General Results:

Six patients could not be examined as one had died and five patients did not attend, but as two of the patients who did not attend had been seen by the author himself previously (No 16 & 36), the data for those two patients were included in the study.

The neuro-radiographs of three patients who did not attend the clinic were included in the study related to the radiological assessment only. An additional female patient, who had died at the age of 8, was also included in this study.

Thirty three patients were examined in the research clinic (including the two patients from Aberdeen who had been seen by the author prior to the beginning of the study). Of these, 27 had bilateral ONH, 4 had unilateral ONH and 2 had segmental ONH. Their ages ranged from 1 to 43 years (mean age 9.97 years, and median age 6.5 years).

One of the four patients with unilateral ONH had one eye with ONH and the other eye was blind due to very high myopia. Of the patients with non-segmental ONH only one patient (No 16) showed no double-ring sign. However, she had severe constriction of the visual fields, hypothalamic obesity, cerebral palsy and mental

retardation. Comparing the diameter of her optic discs with the width of the slit lamp beam on contact lens biomicroscopy, showed her optic discs to have a diameter of 1 mm [mean average diameter in normal population: 1.42 ± 0.24 mm (mean ± 1 SD) (Beuchat & Safran 1985)]. Seventeen of the patients with ONH were male and 14 were female. Both patients with segmental ONH were female.

The thirty three patients who attended the research clinic had the following diagnoses:-

septo-optic dysplasia (SOD)	5
ONH and intracranial cyst (including two patients with associated allo-immune thrombocytopenia)	5
Bilateral ONH with hypothalamic/ pituitary dysfunction with or without absent septum pellucidum.	3
Bilateral ONH and aniridia.	1
Bilateral ONH and allo-immune thrombocytopenia. (two further patients also had intracranial cystic lesions)	1
Bilateral isolated ONH.	12
Unilateral ONH.	4
Segmental ONH.	2

The numbers of patients who underwent the different examinations are shown in table 1, and are listed below:-

<u>PATIENTS</u>	<u>AGE</u>	<u>MH</u>	<u>VA</u>	<u>RET</u>	<u>COL</u>	<u>CS</u>	<u>BSC</u>	<u>IMAGING</u>	<u>D-M/DD</u>
1	6	*	*	*				*	
2+	5							*	
3	4		*	*				*	*
4	3	*		*				*	
5	4	*	*	*				*	
6	3	*		*				*	
7	4	*	*	*				*	
8	4	*	*	*				*	
9	4	*	*	*				*	*
10	8	*	*	*	*	*	*	*	*
11+	4							*	
12	17	*	*	*	*	*	*	*	*
13	21	*	*	*				*	*
14	1	*	*	*				*	
15+	6							*	
16	19		*	*	*	*		*	*
17	11		*	*	*	*	*	*	*
18+	8							*	
19	3	*	*	*				*	*
20	2	*	*	*					*
21	7	*	*	*	*	*			
22	15		*	*	*	*	*		*
23	8	*	*	*	*	*			
24	2	*		*					
25	16	*	*	*	*	*	*		*
26	7	*	*	*				*	
27	6	*	*	*			*		*
28	14	*	*	*	*	*	*		*
29	7	*	*	*	*	*	*		*
30	7	*	*	*					*
31	26	*	*	*	*	*			*
32	4	*	*	*	*				*
33	19	*	*	*	*	*	*		*
34	4	*	*	*					*
35++	9		*	*	*	*	*		*
36	43		*	*	*	*			*
37++	22	*	*	*	*	*	*		*

+ = Patients not seen by author.
 ++ = Patients with segmental ONH.
 MH = Maternal history.
 VA = Visual acuity.
 RET = Retinoscopy.
 COL = Colour vision assessment.
 CS = Contrast sensitivity.
 BSC = Brightness-sense comparison test.

TABLE 1

 Showing the investigations which each patient
 underwent successfully .

Maternal history	27
Visual acuity	30
Contrast sensitivity	15
Colour vision	16
Brightness sense measurement	9
Retinoscopy	33
Photography	23
Neuro-radiological evaluation	20 ✓

Contrast sensitivity, colour vision and brightness-sense comparison tests could not be performed with blind patients, and were not possible in some other patients either because of very young age or mental retardation. Colour vision was also not tested when a patient could not read the demonstration plate due to poor visual acuity. Brightness sense measurement requires a high level of cooperation and could therefore only be performed in a small number of patients.

Fundus photography was attempted in all patients but was only successful in 23 patients, this was due to very young age, mental retardation and rapid nystagmus which precluded photography in some cases.

4 . 2 Maternal History:

Twenty seven mothers of the 33 patients who attended the

research clinic completed the questionnaire. In one case of ONH the mother had died, and in another case of segmental ONH the mother lived abroad permanently and the maternal history could not be obtained. In two cases (No 2 & 22) the children had been fostered and the maternal history could not be obtained. Maternal history had also been unobtainable for the mothers of the two patients from Aberdeen Royal Infirmary as the mother of one patient (No 36) had died. As to the mother of the other patient (No 16) the questionnaire form (which was posted with a stamped addressed envelope) was returned as she had changed address and her current address remains unknown.

4 . 2 . 1 Conditions at birth:

Out of 27 patients with ONH 44.5 % were first born whereas half as many were either second (22%) or third born (22%). In the 64 individuals in the control group (one did not answer this particular question), 25 were the first (39%), a further 25 were second born, and 10 patients were third born (15.6%) (Figure 3).

Statistical comparison of the two groups was performed using the chi-squared test but the results were not significantly different ($0.2 < P < 0.5$).

With regard to maturity at birth, for the 27 patients, 2

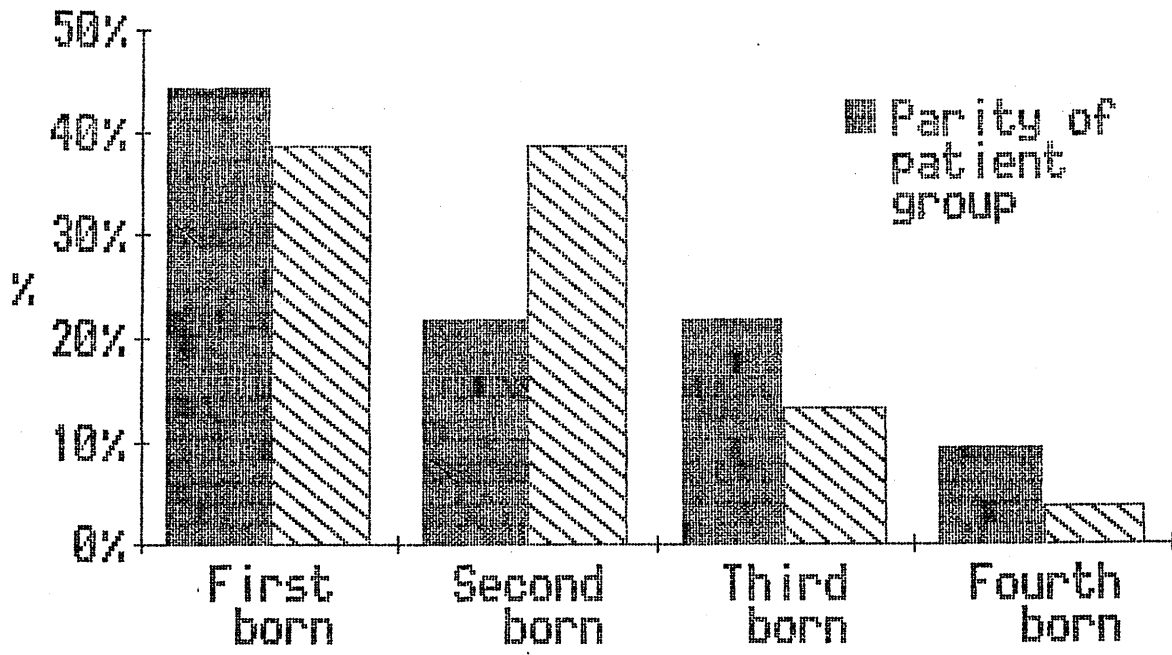


FIGURE 3

Parity of patients and normal subjects.

mothers answered "don't know", 12 children had been born at full term (48%), 5 were post-mature (20%), and 8 were premature (32%). While in the normal group of 65, one mother answered " don't know", 40 children had been born full term (62.5%), 12 post mature (18.75%) and a further 12 premature (Chi-squared test: $0.2 < P < 0.5$).

Nineteen out of 27 mothers of patients who answered the question concerning the normality or abnormality of the child's birth (the remaining 8 did not know) stated that their child's birth had been normal (73%), while normal child birth occurred in 44 of 64 in the normal group (68.75%), (Chi-squared test: $P > 0.5$).

The children whose births were reported as having been abnormal had either a forceps delivery or a Caesarian section

4 . 2 . 2 Maternal health during pregnancy:

Ante-partum haemorrhage was less common in the patient group (11.5%), than the "normal" group (15%). One mother of the 27 patients answered "don't know", while 3 mothers of the 64 subjects in the normal group gave such an answer. Only one mother in the 27 patient group was diabetic and on insulin (4%), and only one in the 65 subjects in the normal group had maturity onset diabetes.

4 . 2 . 3 Maternal age at birth:

The mean maternal age at birth for 25 patients (two mothers did not answer this particular question) was 25.5 years, while this was 27.4 years in the 57 normal group (8 mothers in this group did not answer this particular question). Statistical analysis was performed by using Welch's test ($0.2 < P < 0.5$)

4 . 2 . 4 Smoking and alcohol intake habits of mothers:

Amongst the 27 mothers in the 'patient' group, 55.5% of the mothers of patients did not smoke during pregnancy, 7.4% stated that they had had fewer than 11 cigarettes a day during pregnancy and 37% of the mothers (10 mothers) stated that they had smoked more than 10 cigarettes a day during pregnancy. This compares to a figure of 65% in the normal group of 65 who did not smoke during pregnancy, 20% (13 mothers) who smoked less than 11 cigarettes a day and 20% who smoked 11 or more a day. However, this trend was not statistically significant (Chi-squared test: $0.2 < P < 0.5$).

In the 27 mothers of patients, and in the 62 mothers of normal subjects who answered the part of the questionnaire concerning alcohol intake during pregnancy, 37% of the first group stated that they drank moderately

(1-5 units a week) during pregnancy while this was 25.8% for the normal group (Chi-squared test: $P > 0.5$).

No mother in either of the two groups stated that she drank more than 1- 5 units of alcohol in a week during pregnancy.

On looking into the number of mothers in each group who used to both smoke and drink alcohol during pregnancy I found the figure was 33.3% for the patient group of 27, and 26% for the normal group of 65. Because of the low numbers in these groups, Fisher's exact test was used in preference to the chi-squared test ($P > 0.5$).

I then looked at the number of mothers in the two groups who used to both smoke more than 10 cigarettes a day and drink alcohol during pregnancy, in the 27 mothers of patients, and the 65 mothers of normal subjects. There were 5 in the patient group (18.5%), and also 5 subjects in the control group (7.6%), (Figure 4).
Chi-squared test: $0.1 < P < 0.2$.

4 . 3 Visual Acuity:

The aided and unaided visual acuities of the patient group are listed in table 2. It was possible to assess the visual acuity quantitatively in 30 patients. They comprised five patients with visual acuity of LP in both

PATIENTS	UNAIDED		AIDED		CS	
	OD	OS	OD	OS	OD	OS
1	*	*				
3	0.5/60	3/60	0.5/60	3/60		
5	*	*				
7	6/60	2/60	6/36	2/60		
8	5/60	0.5/60	6/60	0.5/60		
9	6/18	6/12	6/18	6/12		
10	1.5/60	6/36	1.5/60	6/36		20
12	6/60+	6/60+	6/60	6/24	16	88
13	*	*				
14	*	*				
16	6/60	5/60	6/24	6/18	230	230
17	3/60	6/60	6/60	6/36	--	70
19	*	*				
20	1/60	6/9	1/60	6/9		
21	6/6++	*			480	
22	6/36	6/18	6/18	6/12	180	210
23	6/6++	0.5/60**		0.5/60	560++	
25	6/9	6/24	6/7.5	6/12	270	290
26	?++	*				
27	3/60	6/60	3/60	6/60		
28	6/60	6/36	6/60	6/36	10<	24
29	6/36	6/60	6/36	6/60	28	37
30	3/60	1.5/60	3/60	1.5/60		
31	6/7.5	6/7.5	6/6	6/6	130	130
32	6/60	6/36	6/60	6/36		
33	6/12	6/7.5	6/7.5	6/6	310	310
34	6/12	6/18	6/12	6/12		
36	*	6/18	*	6/12		110
35	6/6	6/6++	6/6	6/6	480	480++
37	6/7.5	6/6++	6/6	6/6	400	400++

* = Blind eye.

** = From an area of the retina in the nasal midperiphery.

++ = Eyes with no optic nerve hypoplasia.

+ = From the temporal midperiphery of the retina.

?++ = The visual acuity for this eye could not be tested accurately. However, it was thought to be normal.

TABLE 2

The patients' visual acuities with and without correction, and the contrast sensitivity.

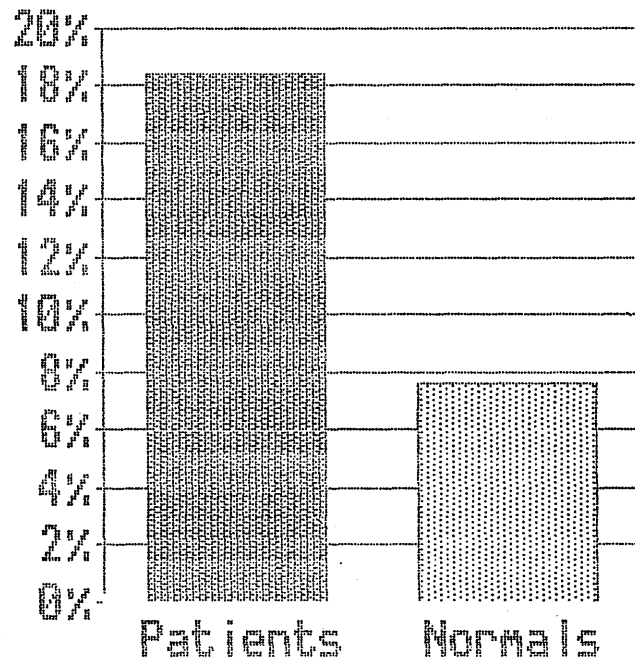


FIGURE 4

Graph illustrating the proportions of patients and control subjects whose mothers smoked more than 10 cigarettes a day and who regularly drank alcohol during pregnancy.

eyes. One patient (No 13) had no light perception and the pupils did not react either to light or to convergence. Another patient (No 32) also had aniridia but with clear corneae. Two patients had unilateral ONH, and two patients had unilateral segmental ONH. One patient (No 26) had a seeing right eye (which was thought to be normal) of indeterminate visual acuity due to mental retardation, and LP in the left eye. In a further 3 patients (4, 6, 24) quantitative visual acuity assessment was not possible.

In the 19 patients with bilateral ONH the visual acuity in either eye did not improve with glasses in 9 patients (47%). While of the 17 patients who had visual acuities of 6/9 or less, the visual acuity improved more than one Snellen line in only two eyes (11.5%) (Table 2). This trend occurred in spite of significant refractive errors in some of these

patients. In the better eye of 9 of the patients there was an astigmatic refractive error greater than 1.5 dioptres with compound hypermetropic, or compound myopic refraction (Table 3 & Figure 5) (Patients No 7, 8, 10, 12, 16, 17, 22, 27 and 28).

4 . 4 Retinoscopy:

Eighteen normal children from a local primary school who were tested and whose parents consented to their child

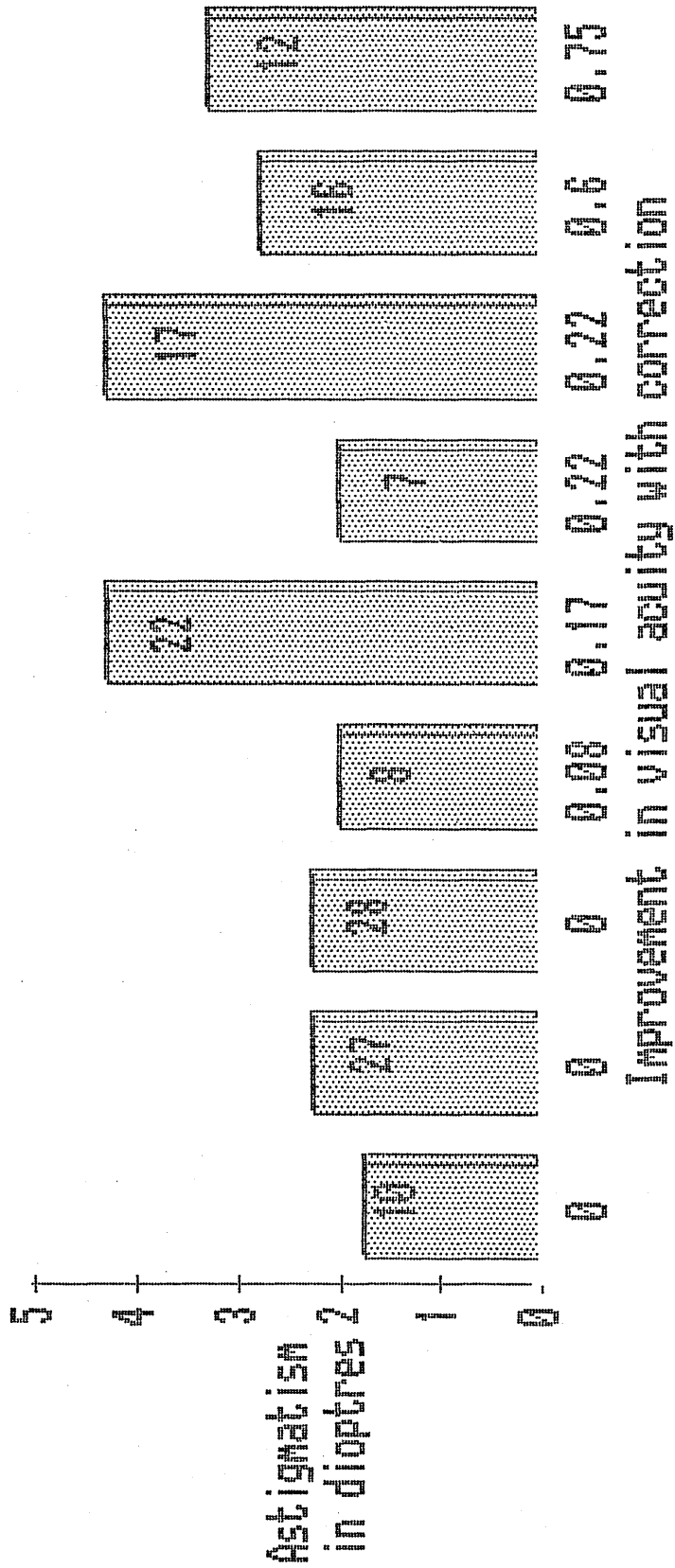


FIGURE 5

Illustrates the degree of improvement in visual acuity (logarithmic), with correction, in the better eyes of nine patients with bilateral ONH. All these eyes had astigmatism of more than 1.5 dioptre.

PATIENTS	AGE	SEX	Total spherical power		Astigmatism	
			OD	OS	OD	OS
1	6	F	2.25	2.5	1.5	0
3	4	M	1.75	0.75	1.5	0.5
4	3	F	1.62	1.12	0.25	0.75
5	4	M	3.75	2.87	0.5	0.75
6	3	F	-4.62	-3.37	0.75	1.25
7	4	F	6.25	7	2	1.5
8	4	F	-2.5	-3.25	2	3.25
9	4	F	3.12	3.12	0.25	0.25
10	8	M	2	2.12	0.5	1.75
12	17	M	-2.25	-0.87	6	3.25
13	21	F	0.12	0.00	1.75	1.5
14	1	F	4.25	4.75	1	0.5
16	19	F	1.37	2.62	0.75	2.75
17	11	M	1.25	1.12	4	4.25
19	3	M	1.62	0.5	1.25	1.5
20	2	M	2.25	2.12	0.5	0.25
21	7	M	3.37*	3.5	0.25*	0.5
22	15	F	-1.37	-1.37	4.25	4.25
23	8	F	2.12*	2.67	0.25*	0.75
24	2	M	2.5	2.5	1.5	2
25	16	M	1.25	0.75	0.5	0.5
26	7	F	5*	3.75	0.00*	2
27	6	M	1.12	2.37	2.75	2.25
28	14	M	0.5	0.37	2.5	2.25
29	7	M	1.5	2.5	1.5	2.5
30	7	M	0.25	-2.25	1.25	2.25
31	26	F	1.75	1.75	0.5	0.5
32	4	M	4.5	5	0.5	1
33	19	M	1.5	2.37	0.5	0.25
34	4	M	2	2.62	1	1.75
36	43	F	**	0.5	**	0.5
Mean astigmatism in eyes with ONH:			1.53	1.52		

Patients with segmental ONH:-

37	22	F	1.75	1.75	0.00	0.00
35	9	F	3	3	0.00	0.00

* Findings in eyes which were thought to be normal.

** This patient's right eye has high myopia, dense amblyopia and visual acuity of LP.

TABLE 3

The findings of retinoscopy in the patient group.

being refracted, underwent retinoscopy, a further two normal adult volunteers were also refracted. They were divided into two groups according to age. The first group comprised 9 normal individuals aged 4 to 7, and the second group comprised 11 normal subjects between the ages of 8 and 35. The two groups were compared. There was no statistically significant difference between the two age groups in the normal control group either with respect to the total spherical power (t-test: $P > 0.5$), or with regard to the astigmatism (t-test: $P > 0.5$).

I looked into the age variation of the total spherical power in the two groups of normal subjects, the correlation coefficient was not significant (Pearson Correlation Coefficient: $P > 0.1$). The mean total spherical power of the right eye in the younger group was +2.35 dioptres, while the mean of the total spherical power of the right eye in the older group was +2.20 dioptres. The mean astigmatism in the younger group was 0.14 dioptres in the right eye, whilst it was 0.20 dioptres for the right eye in the older group. The mean astigmatism in the left eye was 0.17 in the first group, and 0.20 in the second.

Thirty three patients underwent retinoscopic examination (Table 3). Four patients had unilateral ONH, and 2 had segmental ONH in the right eye. Both patients with segmental ONH had no degree of astigmatism in either eye. The correlation coefficient between the mean total

spherical power and age among the patient group was not significant (Pearson Correlation Coefficient: $P > 0.1$). Astigmatism was common in the 58 eyes of patients with ONH (excluding the two cases of segmental ONH who had no astigmatism) when compared with the normal subjects. This was statistically highly significant (Mann-Whitney test and Welch's test: $P < 0.001$). The mean astigmatism in the right and left eyes with ONH were 1.53 and 1.52 dioptries respectively. The proportion of patients with ONH who had astigmatism greater than 0.5 dioptries, was 62% in the 27 right eyes with ONH, and 66.5 % in the patient group's 31 left eyes with ONH (excluding the two cases of segmental ONH). Only one subject in the normal group had astigmatism of greater than 0.5 dioptre in her left eye (0.75 dioptre). Furthermore, one patient who had left unilateral ONH showed no astigmatism in the right eye, while in the eye with ONH (left eye) he had 2 dioptries of astigmatism (patient 26). Of the other three patients with unilateral optic nerve hypoplasia, one had a highly myopic blind eye, her other eye had ONH with astigmatism of 0.5 dioptre, whilst of the remaining two patients one had 0.25 dioptre of astigmatism in the normal eye, (but she had a 0.75 dioptre of astigmatism in the eye with ONH), and the last patient with unilateral ONH had 0.25 dioptre of astigmatism in the normal eye and an 0.5 dioptre in the eye with ONH. Astigmatism was even higher in patients who had proved neuro-radiological abnormalities. The mean astigmatism of the two eyes of such patients was 1.72 dioptries (Section 5.8)

Patients with bilateral ONH and whose visual acuities were known, were divided into two groups. The first group comprised patients with visual acuities worse than 6/36 in the better eyes (9 patients), and the second group comprised patients with visual acuities of 6/36 or better in the better eyes (15 patients). The degrees of astigmatism in the better eyes was compared in the two group (the average degree of astigmatism for the two eyes was taken for a patient when the visual acuities were the same in the two eyes). The group with the better visual acuities had more severe astigmatism (mean 1.84 dioptre) than the group with the worse visual acuities (mean 1.23 dioptre). However this difference was not found to be statistically significant (Welch's test: $P > 0.1$).

The mean total spherical power in the normal subjects was +2.26 dioptre, while this was +1.6 dioptre for the eyes with ONH in the patient group. However, this trend was not found to be statistically significant (Welch's test: $0.1 < P < 0.2$). The mean total spherical power was +1.4 dioptres in the right affected eyes of patients with ONH, and +1.6 dioptres in the left eyes. Twenty four eyes showed retinoscopy findings of a total spherical power less than +1.5 dioptres. Eighteen of these eyes showed a total spherical power of less than one dioptre.

In the two patients with segmental ONH, one (9 years old) had a total spherical power of +3 dioptres, and in the

22 years old this was +1.75 dioptries.

Considering the axes of astigmatism in the 58 eyes with ONH, in 63% of the eyes the axis (of the positive cylindrical lens) was either vertical or horizontal (within 5 degrees). In 37% of the abnormal eyes this axis was oblique. Seven patients (23%) with bilateral ONH had either a horizontal or a vertical axis of astigmatism in one eye, and oblique axis in the other eye. In only two patients (No 6 and 14) were the axes of positive cylinders vertical in one eye and horizontal in the other. It is interesting that each of these two patients also had neuro-radiological abnormalities. It is also of interest that three other patients (12, 17 and 19) were the only patients with mixed astigmatism (in both eyes) in this series, and each of these three patients also had neuro-radiological abnormalities. Of the patients who underwent retinoscopy, 15 had undergone neuro-radiological evaluation and three were found to have no neuro-radiological abnormalities. On assessing the degree of astigmatism in the different groups I found the mean astigmatism for eyes of patients with neuro-radiological abnormalities 1.72 dioptre. This compares to 1.22 dioptre for eyes of patients who were found normal on neuro-radiological evaluation. The mean astigmatism for eyes of patients with no neuro-radiological abnormalities and patients who did not undergo neuro-radiological examinations was 1.37 dioptre (Wilcoxon rank sum test: $P > 0.5$).

4 . 5 Colour Vision:

Eighteen normal school children and three adult volunteers underwent the same test for colour vision according to the same protocol, allowing 3 seconds to read each plate. They ranged in age from 5 to 35 years of age (mean 12.6 years). One error was made by each of 3 normal subjects, their ages were 6, 9 and 10 years. Eighteen normal subjects made no errors. The errors made by the normal group were random and not consistent with errors which would be made by a red/green colour defective individual.

Analysis of the results of the readings of the 24 plate edition of the Ishihara pseudo-isochromatic colour vision test was used to determine the normality or defectiveness of colour vision. If less than 5 errors were made then the colour vision was regarded as "normal" (See above).

Patients who were unable to read the demonstration plate because of poor vision, and patients who were unable to cooperate due to very young age or mental retardation had to be excluded from this study. In one case (No 9) the readings were not consistent and not reliable, and the test had to be discontinued.

It was possible to reliably test 14 patients for colour vision including the two patients with segmental ONH. Their ages ranged from 4 to 43 (mean age 15.3 years,

median age 12.5 years). Patients who made 5 or more errors consistent with red/green colour blindness were considered to have colour vision deficiency. Longer than the recommended time for reading the plates had to be allowed (5 seconds) for four patients, this was particularly necessary in one case when tracing a line was required (15 seconds).

Colour vision was normal in the two patients with segmental ONH. They read all the plates correctly. It was also normal in the normal fellow eye of two patients with unilateral ONH (No 21 & No 36). One patient with mild bilateral ONH (No 33) had normal colour vision but made one error. Another patient with mild bilateral ONH (No 31) was also considered normal, though she made 2 errors which were not typical of red/ green colour deficiency.

Patient 32 colour was also thought to have normal colour vision as tested with tracing lines only.

Six patients had findings suggestive of colour deficiency. Each of the six patients made five or more errors (Table 4). However, only 3 of them made 5 or more errors which were considered characteristic of red/green colour blindness.

There were 11 patients with bilateral ONH, 8 male and 4 female. Therefore 27% of the patients with bilateral ONH who were tested showed evidence of typical red / green colour defect (all were male), and 54% showed evidence of possible colour deficiency (5 male and one female).

There was no evidence of total colour blindness (on reading the plates) in any of the patients.

PATIENT	AGE	ERRORS	R/G
-----	---	---	---
10	8	7	4
12	17	12	7
16	19	0	0
17	11	5	2
21+	7	0	0
22	15	5	2
23+	8	0	0
25	16	4	2
28	14	9	5
29	7	8	5
31	26	2	0
32	4	0**	0
33	19	1	1
35*	9	0	0
36	43	0	0
37*	22	0	0

+ = The normal fellow eye of these two patients with unilateral ONH had been tested. The abnormal eyes could not be tested due to poor visual acuity.

* = Patients with segmental ONH.

** = Only the plates for tracing lines were used for this child.

TABLE 4

 Showing the total number of errors, and errors typical of red/green (R/G) colour deficiency.

In the light of the results of testing our normal subjects, if a patient is considered as colour deficient when he/she made 2 or more errors characteristic of red/green blindness, then 7 of the patients with bilateral ONH (63%) fall into this category (six male and one female).

4 . 6 Contrast Sensitivity:

Contrast is defined as $(L_{max} - L_{min}) / (L_{max} + L_{min})$ where L is the luminance recorded by a microdensitometer scanning across the gratings (Arden 1978). The Cambridge Low Contrast Gratings investigate only one spatial frequency of 4 cycles per degree. The test provides a scoring method which can be converted to an index of contrast sensitivity at this spatial frequency by referring to a table which is provided.

A group of 20 normal subjects was tested. They ranged in age from 4 to 42 (mean age 11.4 years, and median age 9.5 years). They all had visual acuities of 6/6 in each eye. The mean value of the level of contrast was taken for the two eyes in each normal subject. The mean value for all the normal subjects was 404.5.

It was possible to test for contrast sensitivity, by using the protocol outlined in chapter 3, in 15 patients.

Thirteen patients had ONH and two patients had segmental ONH. Twenty five eyes were tested in the patient group. Four of the eyes were normal fellow eyes in patients with unilateral ONH or unilateral segmental ONH, therefore those four eyes were excluded. The contrast sensitivity test was not performed when a patient could not read the demonstration plate due to poor visual acuity, mental retardation or very young age. Table 2 shows the relationship of the readings for contrast sensitivity to the visual acuities in the patients.

The values of contrast sensitivity for the patient group were significantly lower than the normal subjects. (statistical analysis was performed by comparing the mean value for the two eyes in the normal subjects to the worse eye in the patients, using the unpaired t-test: $P < 0.001$).

The 95% one-tailed confidence limit calculated from the study of normal subjects was 208. Four of the patients fell within this limit. Their visual acuities ranged from 6/6 to 6/24. The 99% one-tailed population limit was 125, and 6 of the patients fell within this limit. Four eyes with ONH (in three patients) had visual acuities of 6/6. However, their contrast scores ranged from 130 to 480 (patients 26,19 and 35). No relationship with age was found in the patient group or the normal subjects.

The findings for contrast sensitivity illustrate that contrast sensitivity as scored by using Cambridge low contrast test does not correlate with Snellen acuity (Section 5.6).

4 . 7 Brightness-sense Comparison (BSC) Test:

For the exclusion and inclusion criteria see section 3.2.6. In one case of ONH who could have been suitable for this study (No 16) the patient had moved and could not be contacted. Patient No 31 had symmetrical mild ONH with best visual acuities of 6/6 in each eye. This patient perceived the brightness as being equal in the two eyes while the polarizers were set at 0 degrees to each other, and so did both patients with segmental ONH.

It was possible to include 9 patients with variable degrees of asymmetrical ONH in this study, they all perceived a decrease of brightness with the worse eye, while the polarising filters were at 0 degrees to one another. Seventeen normal subjects were also tested. All the normal individuals perceived the brightness as being equal in the two eyes while the polarisers were at 0 degree angle to each other, thereafter they underwent the test according to the protocol outlined in chapter 3. Table 5 summarizes the findings of this test.

Patient No 33 had only a slight difference in the best visual acuity between the two eyes as tested with Snellen chart, but demonstrated markedly lower brightness sense in the worse eye. All patients have demonstrated a measurable decrease of brightness sense in the worst affected eye as compared to the less affected eye, the

<u>PATIENT</u>	<u>OD</u>	<u>OS</u>	<u>Mean degrees of rotation</u>	<u>Score for BSC*</u>
10	1.5/60	6/36	58	70
12	6/60+	6/24	18	13
17	6/60	6/36	50	53.5
22	6/18	6/12	5	2
25	6/7.5	6/12	28	20
27	3/60	6/60	30	22
28	6/60	6/36	46	48
29	6/36	6/60	21	14
33	6/7.5	6/6	16	8.5
			----- Mean: 30.5	----- 27.9

* = Brightness-sense comparison test.
+ = Fixation shown by visuscopy to be maintained temporal to the macula.

TABLE 5:

The findings of best corrected visual acuity, brightness sense comparison test, and the scores, in the patient group with non-segmental ONH.

mean angle of rotation of the front polarizing filter was 30.5 degrees. The mean score for the patient group was thus 28, indicating 28 % decrease of brightness sense in comparison to the better eye. This was generally not related to the difference in the Snellen visual acuity between the two eyes (Figure 6), although the highest score of 70 was for patient No 10 who had the largest difference in visual acuity between the two eyes.

The 17 normal control subjects had a mean score of 3.6. The data were found to be non-normally distributed and an upper limit for the normal range had to be estimated by direct calculation of percentiles (Bland 1987).

Because of the relatively small number of subjects the most extreme limit which could be calculated was the 94 % one-tailed upper limit, which was 5. With the exception of the 3 patients described above, only one patient fell within this upper limit established by the study of the normal subjects.

4 . 8 Fundus Photography and Image Analysis:

4 . 8 . 1 Fundus photography:

Fundus photography was possible in 41 eyes of 23 patients including the two patients with segmental ONH. One patient with unilateral ONH had successful photography on the normal eye only, and therefore this was excluded from the study. Photography was not possible for patients

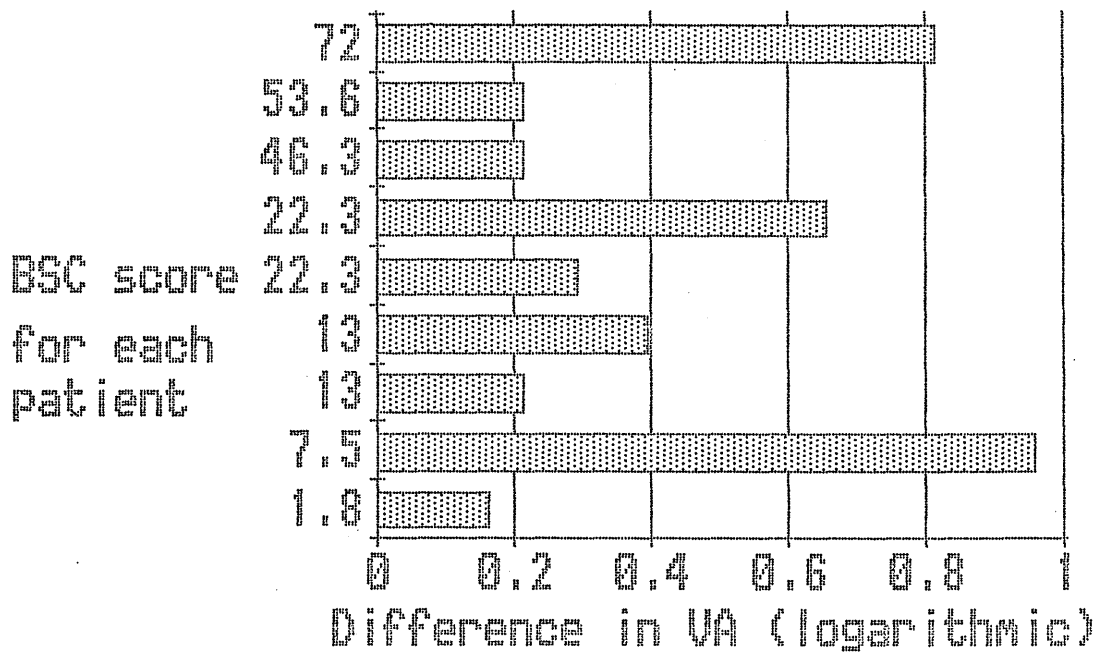


FIGURE 6

Graph illustrating the relationship of brightness-sense comparison test (BSC) to the difference in logarithmic visual acuity between the two eyes in the patient group. It shows that there is no relationship between the two values.

with mental retardation, and for few young children. In patients with rapid nystagmus photography of the fundus was difficult. Fundus photographs were also taken for both eyes of 21 normal subjects using the same protocol.

4 . 8 . 2 Image analysis:

All measurements were taken by an independent observer after the slides from normal subjects and from patients had been mixed at random. It was only possible to obtain measurements to provide the disc-macula/disc diameter ratio ($D-M/DD$) for 33 eyes in 22 patients. In three eyes the quality of the photograph was poor, in two other eyes the fovea was not included in the fundus photographs, and in a further three eyes the fovea could not be located. Therefore, the $D-M/DD$ ratio could not be calculated for these eyes.

It was also possible to determine the $D-M/DD$ for 40 eyes of 21 normal subjects. The mean for the two eyes was taken as the datum value for a subject unless only one eye had been assessed where the value for that eye was taken. The mean $D-M/DD$ ratio for the normal group was 2.63. The mean ratio for the patient group was 3.57.

Because the data were found to be non-normally distributed, an upper limit for the normal range was

estimated by direct calculation of percentiles (Bland 1987). Because of the relatively small number of subjects the most extreme limit which could be calculated was the 95 % one-tailed upper population limit, which was limit, which was 2.94. For only one patient (No 25, who had bilateral ONH, but for whom only the right eye could be photographed) was the D-M/DD below this 95% limit for normal subjects; his D-M/DD ratio was 2.80. However, this patient had a bilateral double ring sign with corrected visual acuities of OD 6/7.5 and OS 6/12 and significant difference in the brightness sense between the two eyes (Section 4.5).

I related the visual acuities for the better eyes of 12 patients with bilateral ONH for whom fundus photographs were available (blind eyes and eyes with segmental ONH were excluded), to the values of the D-M/DD ratios. I found no close relationship between the visual outcome and the severity of ONH in these patients (Figure 7, and Table 6). The visual acuities and the D-M/DD ratios were not significantly correlated in these 12 patients (Pearson Correlation Coefficient, $P > 0.1$). Furthermore, in eight patients with bilateral ONH in whom the visual acuity was asymmetrical, I found in six patients (75%) that the eye with the better visual acuity had a relatively larger D-M/DD ratio compared to the worse eye (Table 6).

For ten out of 12 (83 %) of the patients with bilateral ONH, in whom the D-M/DD ratio could be discerned, there

<u>PATIENTS</u>	<u>VA OD</u>	<u>VA OS</u>	<u>RATIO OD</u>	<u>RATIO OS</u>
3	0.5/60	3/60	3.23	4.00
9	6/18	6/12	3.04	?
10	1.5/60	6/36	6.08	4.60
12	6/60	6/24	3.26	3.61
13	*	*	3.44	3.85
16	6/24	6/18	4.08	4.24
17	6/60	6/36	?	3.67
19	*	*	3.45	3.53
20	1/60	6/9	3.87	?
22	6/18	6/12	?	4.40
25	6/7.5	6/12	2.80	?
27	3/60	6/60	3.32	3.67
28	6/60	6/36	2.91	3.58
29	6/36	6/60	?	3.48
30	3/60	1.5/60	?	3.26
31	6/6	6/6	3.68	3.14
32	6/60	6/36	3.44	3.28
33	6/7.5	6/6	3.22	3.32
34	6/12	6/18	3.47	3.10
36	*	6/12	?	3.06

* = Blind eyes
 ? = Not available

TABLE 6

The relationship of the best visual acuity to the D-M/DD ratio in eyes with non-segmental ONH.

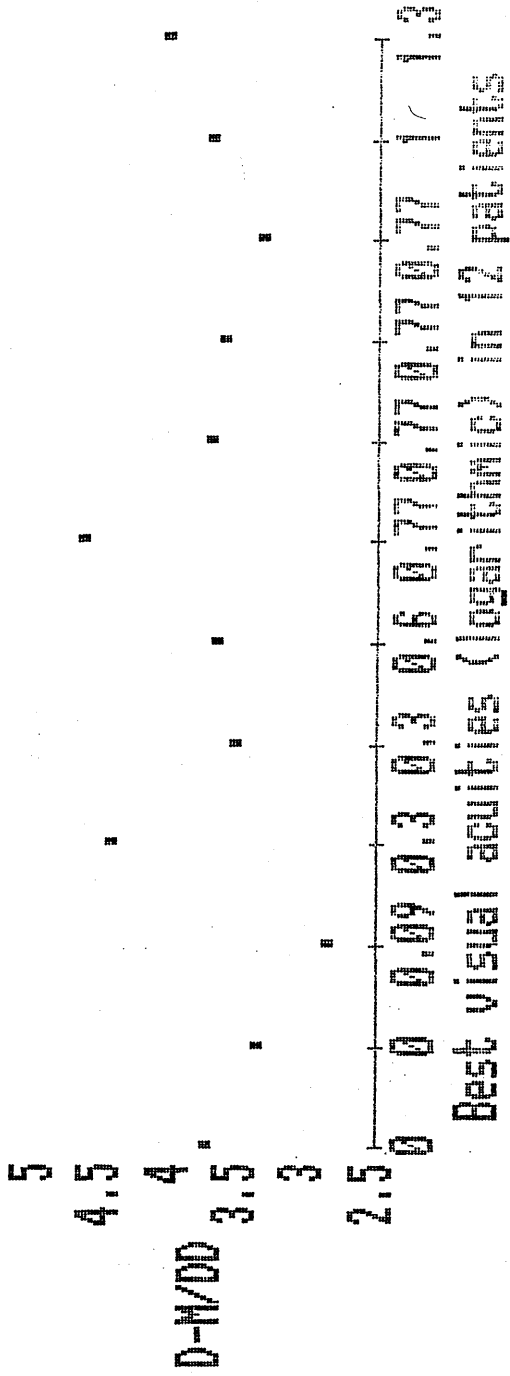


FIGURE 7

This figure shows the best logarithmic visual acuities in the better eyes of 12 patients with bilateral ONH, and the D-M/DD ratios of these eyes.

was more astigmatism in the eye with the smaller D-M/DD ratio (the eye with the relatively larger optic disc). In only one patient was the degree of astigmatism less in the eye with the smaller ratio than the other eye. In the remaining one patient there was equal astigmatism in both eyes of 0.5 dioptre (Table 7).

Considering the two patients with segmental ONH, the D-M/DD ratios for the right affected eyes were 3.33 and 3.27. For the left normal eyes these were 2.72 and 2.71 respectively.

4 . 9 Neuro-radiological Assessment:

Neuro-radiographs were assessed for twenty patients. All but one patient (No. 26) had bilateral ONH. The initial non-ophthalmic diagnoses for these patients, prior to radiography, were as follows:

Hypopituitarism	9
Mental retardation	4
Large head	2
Cerebral palsy	1
Dysequilibrium	1
None	3

Seven of the patients were blind in both eyes. Twelve had nystagmus, and 9 had squint.

<u>PATIENTS</u>	<u>AST.OD</u>	<u>AST.OS</u>	<u>RATIO OD</u>	<u>RATIO OS</u>	<u>MEAN</u>
3	1.5	0.5	3.23	4.00	3.62
9	0.25	0.25	3.04	?	3.04
10	0.5	1.75	6.08	4.60	5.34
12	6	3.25	3.26	3.61	3.44
13	1.75	1.5	3.44	3.85	3.65
16	0.75	2.75	4.08	4.24	4.16
17	4.00	4.25	?	3.67	3.67
19	1.25	1.5	3.45	3.53	3.49
20	0.5	0.25	3.87	?	3.87
22	4.25	4.25	?	4.40	4.40
25	0.5	0.5	2.80	?	2.80
27	2.75	2.25	3.32	3.67	3.50
28	2.5	2.25	2.91	3.58	3.25
29	1.5	2.5	?	3.48	3.48
30	1.00	2.25	?	3.26	3.26
31	0.5	0.5	3.68	3.14	3.41
32	0.5	1	3.44	3.28	3.36
33	0.5	0.25	3.22	3.32	3.27
34	1	1.75	3.47	3.10	3.29
36	**	0.5	?	3.06	3.06

? = Not available.

TABLE 7:

The relationship of the degree of astigmatism to the D-M/DD ratio in eyes with ONH.

The protocol outlined in section 3.2.8 was drawn up prospectively to include all previously reported neuro-radiological abnormalities. In only one case was there a discordance between the original report and the re-evaluation. This was patient No.3 who had initially been diagnosed as having a porencephalic cyst but on review was felt to have an ostensibly neuronal migration disorder, type 2 schizencephaly. Out of the 10 ultrasound films, 4 were normal. Two CT scans were normal in the 15 CT scan films which were studied.

Out of the total of 20 patients who underwent U/S and/or CT, 4 patients had no demonstrable neuro-radiological abnormalities (Patients 7, 10, 16 & 26). However, patients 10, 16, and 26 had hypopituitarism and patient 7 had mental retardation. Furthermore, patient 16 had severe constriction of the visual fields to 5 degree from fixation, hypothalamic obesity, cerebral palsy and mental retardation. The other three had squint and nystagmus. With the exception of patient 26 they all had bilateral ONH.

All seven patients who were blind in both eyes had radiological abnormalities. Three of these patients were diagnosed prior to neuro-radiology as having isolated bilateral ONH, they all showed abnormal neuro-radiological findings, in the form of absent septum pellucidum in two (one of the two patients had partial absence of the septum pellucidum), and porencephaly in

the third patient.

The commonest abnormalities were: absent septum pellucidum in 11 (55%) (Figure 8 & 9), hydrocephaly in 9 (45%), porencephaly in 5 (20%) (Figure 10), dilatation of the supra-sellar and chiasmatic cistern in 4 and absent corpus callosum in 3. One patient had schizencephaly (Figure 11). Figure 12 demonstrates the CT scan appearance in diffuse cerebral atrophy.

One patient had an intracranial arachnoid cyst, and another patient had intracranial epidermoid cyst. In two cases of absent septum pellucidum the absence was partial, and in one case the corpus callosum was partially absent. The findings of the ultrasound are listed in table 8, and of the CT scan assessment are listed in table 9. In one of the five patients (No.9) who underwent both U/S and CT examinations, U/S failed to demonstrate porencephaly due to poor quality of the imaging. In another patient (No 8) U/S failed to detect the absence of septum pellucidum, which was demonstrable on subsequent CT scanning.

Hydrocephalus was diagnosed if the width of the lateral ventricle exceeded 1 cm at its widest part in axial or coronal views, regardless of the patient's age. It was only possible to diagnose hydrocephalus in the absence of cerebral atrophy.

With regard to assessment for optic nerve hypoplasia, enlargement of the pituitary stalk and dilatation of the suprasellar and the chiasmatic cistern, these could not always be adequately assessed by the imaging technique

ABNORMALITY	PATIENTS									
	1	2	3	4**	5	6	7	8	9	10
Hydrocephaly	-	-	-	+	+	+	-	-	+	-
Hydranencephaly	-	-	-	-	-	-	-	-	-	-
Porencephaly	-	-	*	-	-	+	-	-	?	-
Absence of Corpus callosum	-	-	-+	-	-	-	-	-	+	-
Absence of Septum pellucidum	+	-+	+	+	+	-+	-	?	+	-
Microcephaly	-	-	-	-	-	-	-	-	-	-
Cerebral infarction	-	-	-	-	-	-	-	-	-	-
Cerebral cortical atrophy	-	-	-	-	-	-	-	-	-	-
Cerebellar atrophy	-	-	-	-	-	-	-	-	-	-

CODING SCHEDULE:

- = Absent.

-+ = Partially present (abnormal).

+ = Present.

? = Could not be assessed.

* This patient had bilateral type 2 Schizencephaly.

** This patient also had a huge suprasellar cyst

TABLE 8:

Results of ultrasound findings of the 10 patients who underwent this examination.

THE ABNORMALITY	PATIENTS							
	3	4	6	8	9	11	12	13
Hydrocephaly	-	+	+	-	+	+	-	+
Hydranencephaly	-	-	-	-	-	-	-	-
Porencephaly	*	-	+	-	+	-	+	-
Absence of Corpus callosum	-+	-	-	-	+	-	-	-
Absence of Septum pellucidum	+	+	-+	+	+	+	-	+
Enlargement of the pituitary stalk	?	?	?	?	?	?	?	?
Dilatation of supra- sellar and chiasmatic cistern.	-	+	-	-	?	-	+	+
Microcephaly	-	-	-	-	-	-	-	-
Cerebral infarction	-	-	-	-	-	-	-	-
Cerebral cortical atrophy	-	-	-	-	-	-	-	+
Cerebellar atrophy	-	-	-	-	-	-	-	+

CODING SCHEDULE:

- = Absent.

-+ = Partially present (abnormal).

+ = Present.

? = Could not be assessed.

* Bilateral type 2 schizencephaly.

** This patient also had a huge suprasellar cyst

Table 9:

CT scan findings of the 15 patients who underwent this examination.

(Table continues on next page)

THE ABNORMALITY	14	15	16	17	18*	19	26
Hydrocephaly	-	+	-	-	+	+	-
Hydranencephaly	-	-	-	-	-	-	-
Porencephaly	-	-	-	+	-	+	-
Absence of Corpus callosum	-	-	-	+	-	-	-
Absence of Septum pellucidum	-+	-	-	+	+	-	-
Enlargement of the pituitary stalk	?	?	?	-	?	?	-
Dilatation of supra- sellar and chiasmatic cistern.	?	-	-	-	-	+	-
Microcephaly	-	-	-	-	-	-	-
Cerebral infarction	-	-	-	-	-	-	-
Cerebral cortical atrophy	-	-	-	-	-	-	-
Cerebellar atrophy	-	-	-	-	-	-	-
Optic nerve hypoplasia	?	?	?	?	?	?	?

* This patient had a huge suprasellar epidermoid cyst proved histopathologically.

Table 9 continued.

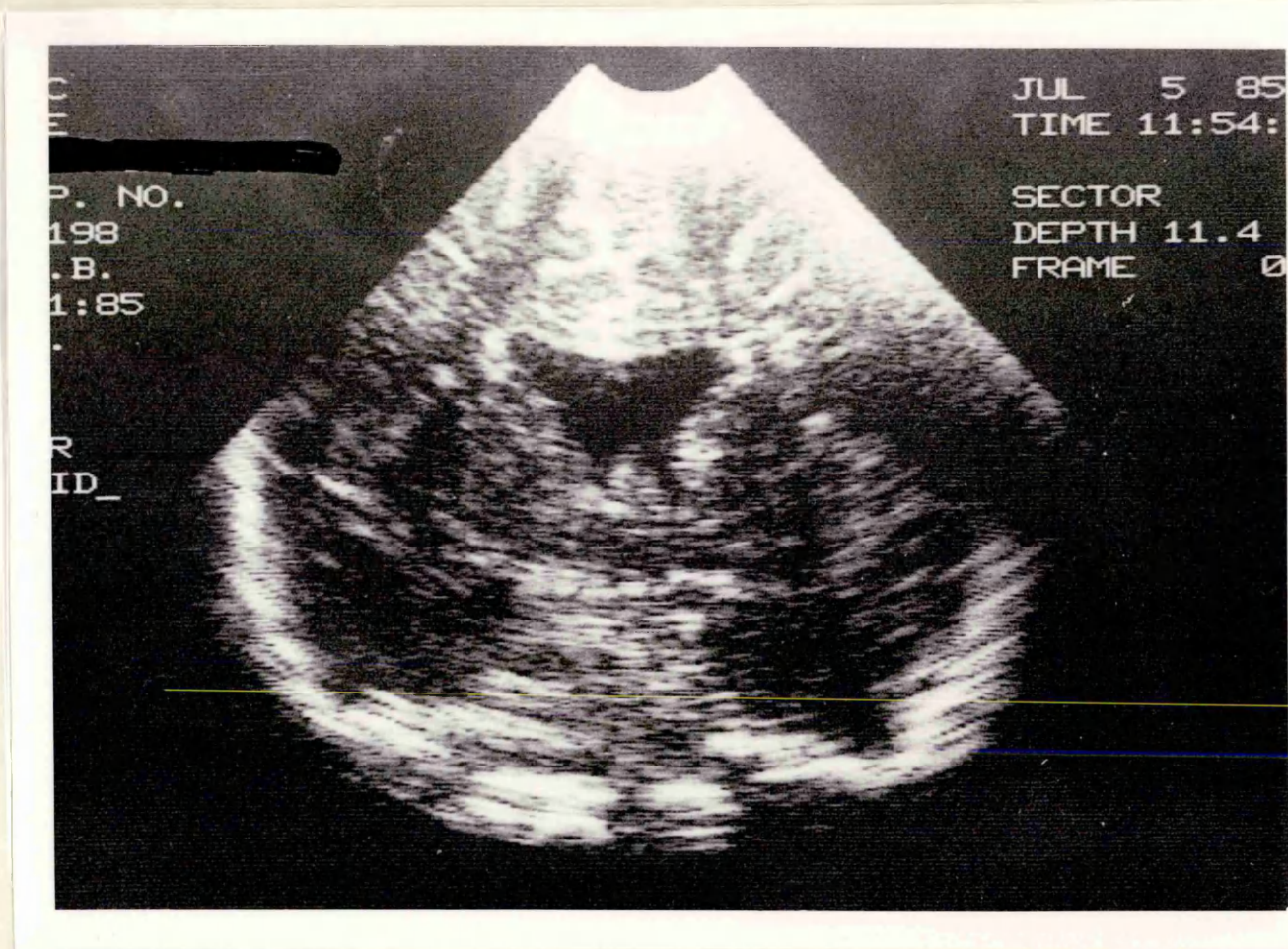


FIGURE 8

Mid-coronal section of cranial ultrasound showing absence of the septum pellucidum (patient 5).

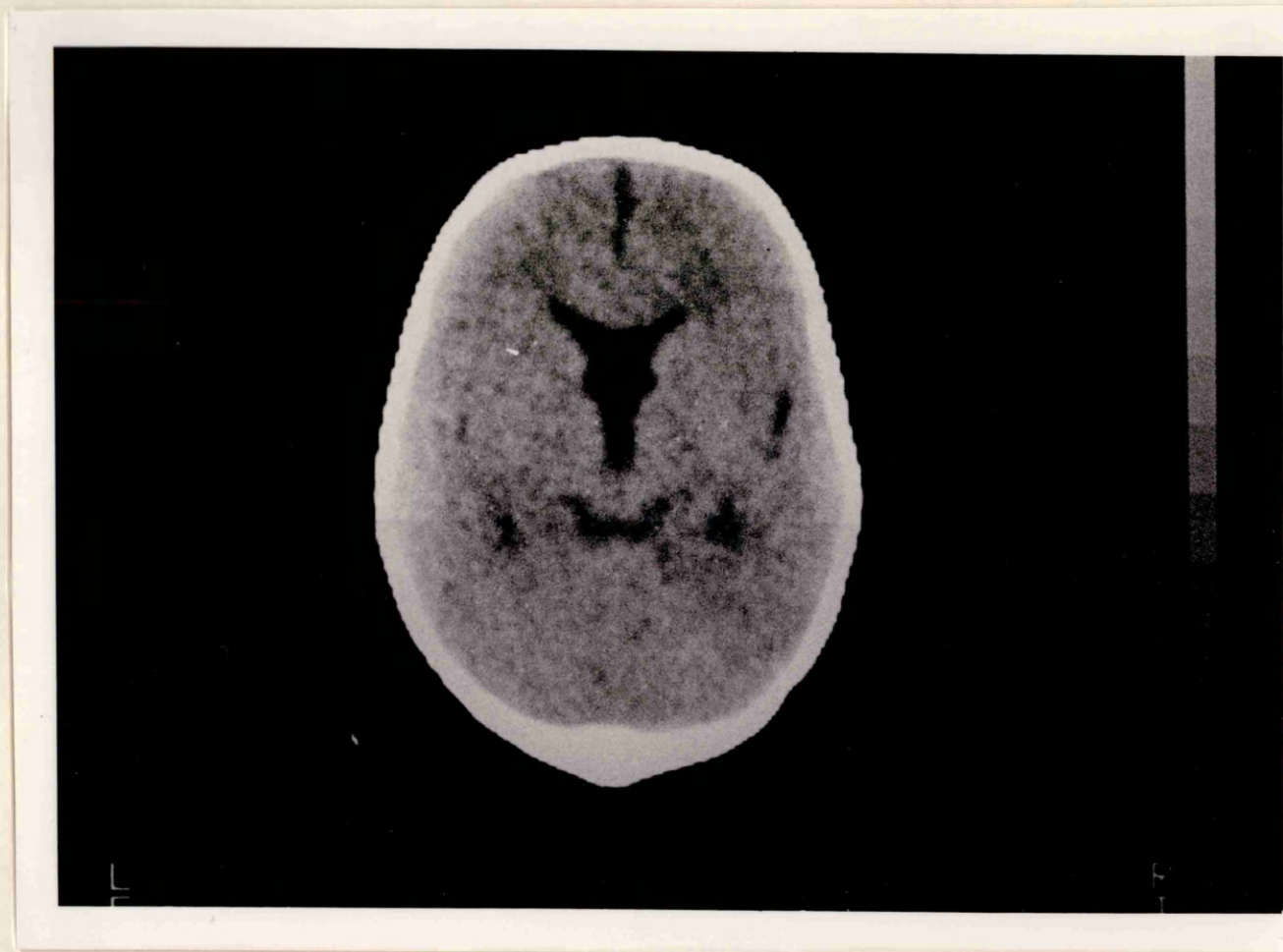


FIGURE 9

Axial CT scan demonstrating absence of septum pellucidum
(patient 8).

ELSONI ELECTRON *** RUTH HOSPITAL FOR SICK CHILDREN *
311506 - 1- 6 -15 12/27/8
RC 250 SS 0 OUT SW 12 BP 40
WINDO
ZEN1 40
WID1 140

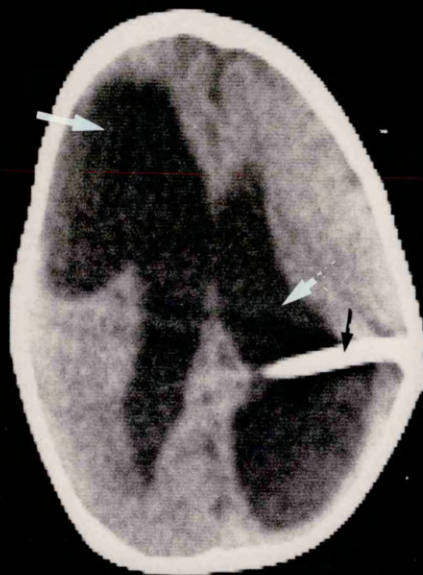

FIGURE 10

Axial CT scan illustrating a porencephalic cyst (long arrow) communicating with the anterior horn of the left lateral ventricle. The right lateral ventricle is dilated (short arrow). The high density shadow represents a shunt inserted into the right lateral ventricle (black arrow) (patient 6).

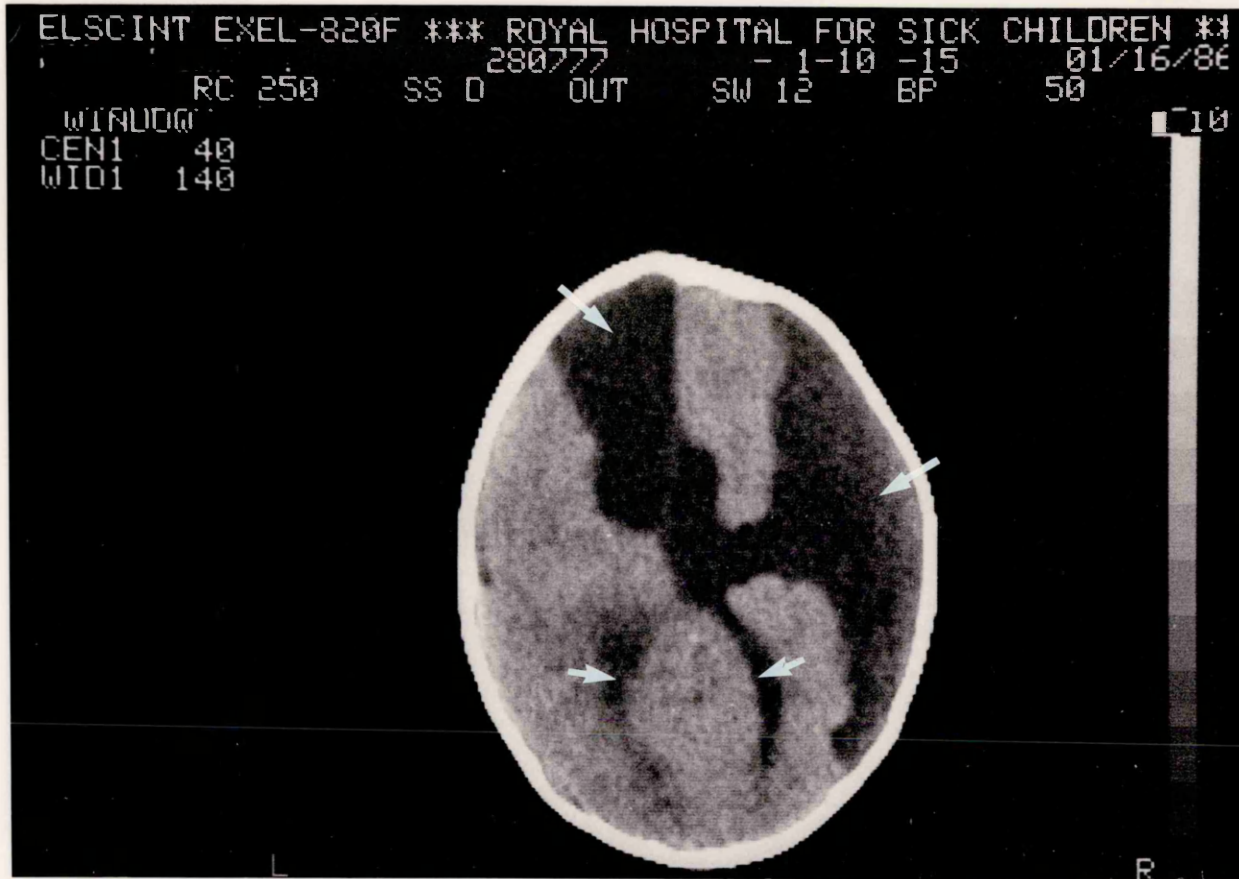


FIGURE 11

Axial CT scan showing schizencephaly as a large cleft in the brain (long arrows). The right and left lateral ventricles are marked with short arrows (patient 3).

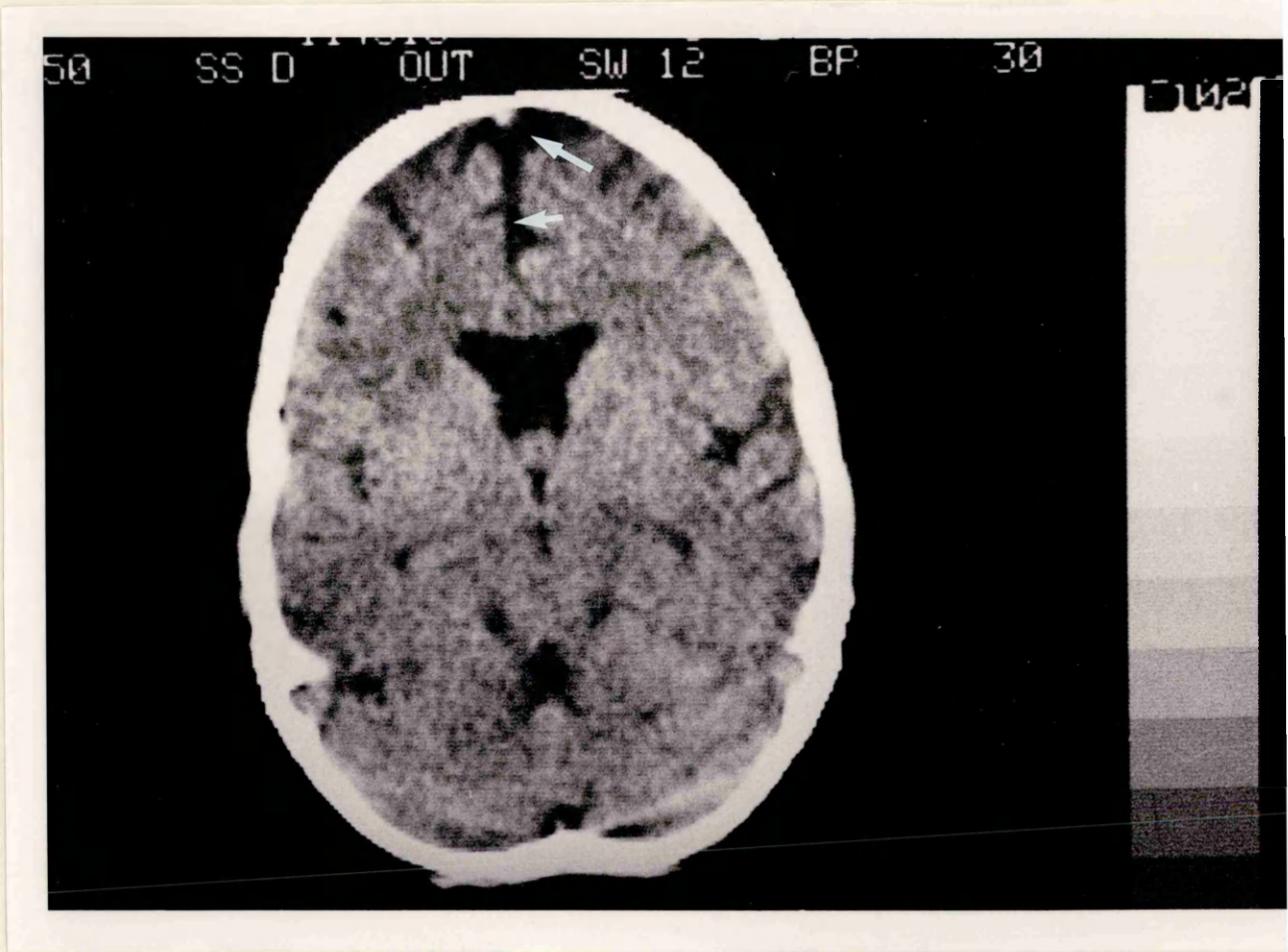


FIGURE 12

CT scan appearance of diffuse cerebral atrophy. Increased CSF over the anterior lobes (long arrow), dilated sulci and dilated inter-hemispheric fissure (short arrow) (patient 13). The septum pellucidum is absent.

because:

1. The structures were not demonstrated, and/or
2. The resolution was not adequate.

Optic nerve hypoplasia was sought in all the CT scans, but in every case no comment could be made as to the size of the optic foramina or optic nerve(s).

In only one film was the pituitary stalk demonstrable, and it was normal. In the other 14 CT films the pituitary stalk could not be clearly discerned.

Of the 20 patients who were investigated radiologically the common ocular findings were nystagmus in 9, manifest squint in 9 patients, and 7 patients were totally blind in both eyes. Nine had evidence of hypothalamus-pituitary hormone(s) deficiency (in five of these patients this hormonal deficiency was manifested by growth retardation), six of these patients had abnormalities in their neuro-radiographs. Nine patients had mental retardation, six of these showed intracranial radiological abnormalities. Six patients had cerebral palsy, four of the patients who had cerebral palsy showed radiological abnormalities.

DISCUSSION

CHAPTER 5

5 DISCUSSION:-

5 . 1 General Discussion:

ONH comprises a wide spectrum of conditions of unknown aetiology. It should be sought in any individual who has unexplained poor corrected visual acuity, low contrast sensitivity, colour deficiency and/or associated systemic abnormalities. In children it is advisable to have a high index of suspicion for this condition.

There were no patients listed in the Disease Index of the Royal Hospital for Sick Children, with ONH or with septo-optic dysplasia, until 1980. This illustrates the recently increased awareness of ONH.

In the present study, bilateral cases were much commoner than unilateral cases. This is in agreement with previous reports which indicate that bilateral disease is commoner (Billson 1973, Acers 1981, Lambert et al 1987).

All patients who showed neuro-radiological abnormalities had bilateral ONH. This is also in support of previous reports that bilateral cases are more likely to be associated with extra-ocular abnormalities (Fielder et al 1986).

A number of interesting findings have emerged from the present study. These include the associated refractive errors, colour vision defects, the findings of the D-M/DD ratio and the findings on correlating the different parameters which were studied in the patient group.

Both optic atrophy and ONH probably result from an insult which occurred during intra-uterine development. They can occur together (Section 5.7). The optic discs were "pale" in all our patients. This has been explained on the basis of the relatively increased ratio of glial to neural tissue in the optic nerve, as glial tissues are said to be unaffected in ONH (Krause-Bruckner & Gardiner 1980, Brown 1982).

The two patients with unilateral segmental ONH differed from the patients with complete ONH in many respects. They showed no evidence of colour vision defects, refractive errors, low contrast sensitivity, reduced corrected visual acuity or associated extraocular abnormalities. However, the small number of cases precludes conclusions from being drawn.

The higher D-M/DD ratio in the patients who I studied, and the higher ratio in the affected eye compared to the normal eye in the unilateral cases in this study, shows that the small size of the optic disc must be

implicated in the pathogenesis of the visual deficit. However, the findings of better visual acuity in the eye with the relatively higher ratio in six bilateral cases, suggests that other factor(s) must be involved in the low visual outcome in patients with ONH.

The "Double ring" sign was not observed in any of the normal subjects, whilst this sign was present in all eyes with ONH except patient 16 who did not show the "double ring" sign in either eye. Throughout the study I found that it was easier to identify the "double ring" sign by means of the direct ophthalmoscope, as it gives greater magnification than the indirect ophthalmoscope. I also shone the small aperture (macular) light of the standard direct ophthalmoscope onto the surface of the optic disc during ophthalmoscopy, to estimate whether the ratio of the illuminated area as a proportion of the size of the optic disc, in comparison with the other eye, would be helpful. I found this a useful method of examination to clinically assess the relative size of the optic disc in the two eyes in patients with asymmetrical or unilateral ONH. This is because a light circle entering the eye can be assumed to suffer the same degree of magnification as the optic disc size when seen by the direct ophthalmoscope (Franceschetti & Bock 1950, Beuchat & Safran 1985). The relative size of the optic disc can thus be compared to the relative size of the circle of light which is projected on the

surface of the optic disc, in a manner similar to the study of cup/disc ratio in patients with glaucoma.

The commonest neuro-radiological abnormality in this series was an absent septum pellucidum (58%). The septum pellucidum is a thin double-walled partition which lies in the mid-sagittal plane between the two lateral ventricles. It is attached to the corpus callosum and fornix. Its width has been reported as varying between 0.2 and 0.3 cm, and its height 0.9 to 1.5 cm (Lowman et al 1948).

5 . 2 Maternal History:

There was a trend towards a slightly increased incidence of first born in the patient group (44.5%). However, this result did not reach statistical significance, and is lower than stated in previous reports as being 52% (Acers 1981), 54% (Margolith et al 1984) and 75% (Walton & Robb 1970).

The mean maternal age in the patient group (25.5 years) was lower than that of the control group (27.4 years). This was not a significant statistical difference. This age difference however, was slightly higher than that previously reported by Acers (1981) of 23.8 years in mothers of the patient group, against 24.6 years in

normal controls. Lippe et al 1979, and Robinson & Conroy 1986 reported statistically significant difference between the mean maternal age of the patient group and the mean maternal age of the general population.

The raised incidence of first born in ONH and the young maternal age may be inter-related, thus for example, a raised incidence of the first may simply reflect the younger maternal age.

The results showed no increase in the prevalence of post-maturity in patients with ONH. This is not in agreement with previous report by Jan et al (1977), who found that 45% of 20 patients with ONH had been born post-mature.

The possible role of smoking in the pathogenesis of ONH has not hitherto been studied. The data on the prevalence of smoking mothers in the two group does not support a pathogenetic role for cigarette smoking in the aetiology of ONH. However, the figures for heavy smoking combined with the intake of alcohol during pregnancy are of interest. The ratio of mothers, who had both smoked more than 10 cigarettes a day and taken alcohol, in the patient group was 2.4 times higher compared with the normal subjects. However, this trend was not found to be statistically significant, probably

due to the relatively small number of mothers of patients with ONH in this study. An increased incidence of this combination of "substance" abuse has not hitherto been reported.

It was remarkable that there were no figures of drinking more than 5 units of alcohol weekly during pregnancy amongst either mothers of patients or mothers of normal subjects. On the other hand, there was a considerable number of admitted heavy smokers during pregnancy. This may have been due to the awareness of the mothers of patients with ONH of the harmful effect of alcohol intake during pregnancy. This could have resulted in some mothers not disclosing the fact that they had been drinking excessively during pregnancy. Therefore, it is likely that the figures concerning alcohol intake during pregnancy would otherwise have been different and higher. Stromland (1985), experienced difficulty in obtaining reliable data from mothers of patients with foetal alcohol syndrome regarding alcohol intake. The figures obtained in the present study concerning maternal ingestion of alcohol are markedly different from that obtained by Stromland (1985). This is because Stromland studied children who all had foetal alcohol syndrome when he found on measurements of the optic discs from fundus photographs that 48% of these to have ONH. However, in Stromland's study the role of cigarette smoking by the mothers, combined with alcohol intake was not investigated.

I was interested to find out whether there are difficulties in child birth related to patients with ONH. The patient group showed no raised prevalence of abnormal child birth when compared to the normal subjects. This is in agreement with a previous report (Walton et al 1970). The incidence of ante-partum haemorrhage was also not raised in the patient group.

Only one mother in the patient group had been diabetic and on insulin during pregnancy (3.7%). This is lower than the figures of previous studies of 12.5% (Acers 1981) and 18% (Peterson & Walton 1977).

5 . 3 Visual Acuity:

The data on the visual acuities of our patients with ONH are of interest. The visual acuities both with and without correction were the same in 58 % of the better eyes of bilateral cases, and in 7.6 % the visual acuities only improved by one Snellen line. Possible explanations for this observation include extensive damage to the ganglion cells, central scotomata, refractive amblyopia in the better eye and macular hypoplasia. It was not possible to assess the visual fields in any of the patients who had poor corrected visual acuities. However, in the worse eye of one patient (No 23) visuscopy indicated that an area nasal to the macula was employed for fixation. In the

two eyes of another patient (No 12) an area temporal to the macula was employed for fixation by each eye. Therefore it appeared more likely that the uncorrectable visual acuity in these two children was caused by large central scotomata, consecutive to underdevelopment of ganglion cells of the macula. In patients 8, 12, 17 & 22 there were high refractive errors in the better eyes and it is likely that an element of refractive amblyopia contributed to impaired visual function. Further investigation is required to compare large numbers of patients with different degrees of astigmatism or other refractive errors, but with normal optic nerves. This would confirm the role of such a mechanism of refractive amblyopia in explaining the worse than expected outcome of visual acuities with spectacle correction in these patients. In three eyes with grossly impaired visual function the fovea could not be discerned on fundus photography (Section 5.7), this suggests a degree of macular hypoplasia in those children. Macular hypoplasia has not hitherto been described as an association with ONH. However, histopathological study would be required to validate this hypothesis. In the two histo-pathological reports for humans blind with ONH, total absence of the ganglion cells and the nerve fibre layer has been documented in the affected retinae but no comments were made concerning the macular morphology (Kreibig 1959, Mosier et al 1978).

In one of the patients (No 13) who was a blind university student, and had nystagmus, the pupils did not react to light. This absence of the pupillary light reaction indicates severe involvement of the light sensitive ganglion cells and the "pupillary" fibres in the optic nerve. The pupils did not react to proprioceptive "fixation" of her own fingers either, and voluntary (volitional) convergence could not be elicited. However, it is known that the relationship of pupillary constriction with accommodation is much stronger than its relationship with convergence (Davson 1972). Nevertheless, careful examination failed to demonstrate any degree of pupillary response to convergence in this patient.

5 . 4 Retinoscopy:

Accurate retinoscopy may be difficult to perform in some children because of tightly-squeezed eyelids, nystagmus, mental retardation or because simply the child is uncooperative. Patience is necessary to obtain reliable information. At times retinoscopy had to be postponed for a later occasion hoping that the child would become used to the atmosphere of the eye clinic. I found it useful if someone else (other than the person who is going to perform retinoscopy on the child) instils the cycloplegic eye drops into the child's eyes.

This study has shown a significantly increased prevalence of astigmatism in patients with ONH. It would have been worthwhile to carry out keratometry to see whether the astigmatism was corneal or explicable on some other basis. Keratometry was not planned for those patients when drawing up the protocol for this study, and the finding of a high prevalence of astigmatism came to light towards the end of this study. An association between ONH and refractive errors has not previously been reported. The literature has been reviewed (Zion 1976). Forty reported cases of ONH were found in which the refraction had been documented. These were thought to have the same distribution as the normal population. The close association of ONH with astigmatism highlights the importance of careful retinoscopy in a child with ONH.

The degree of astigmatism was not significantly different between the patients with relatively poor visual acuities (lower than 6/36), and the patients with better visual acuities (Section 4.4). This indicates that careful retinoscopy is required even in children with relatively mild forms of ONH.

The relationship between ONH and astigmatism is not known and further investigation using keratometry may shed further light on the association between the two disorders.

It is interesting that the only two patients who had

astigmatism of opposite axes to each other in the two eyes (No 6 and 14), and the only three patients who had mixed astigmatism (No 12, 17 and 19) also had severe neuro-radiological abnormalities.

The patient group exhibited a trend towards myopia, but this was not found to be significant.

The present study has shown that in bilateral ONH, the eye with the relatively lower D-M/DD ratio tends to exhibit a greater degree of astigmatism than the fellow eye. It has also shown that in bilateral cases, it is likely that the eye with the relatively larger ratio to eventually become the eye with the better visual acuity. This paradoxical finding is difficult to explain.

It has been shown that early refractive correction decreases the risk of the subsequent development of amblyopia (Brent & Arstikaitis 1983). It has been recommended that a child with retinoscopic findings of astigmatism of 1.5 D of cylinder or more needs glasses, and in anisometropia if there is 0.75 dioptre difference of astigmatism between the two eyes then glasses are required (Brent & Arstikaitis 1983). This newly discovered association between ONH and astigmatism indicates that all children with ONH should be refracted at the earliest opportunity.

5 . 5 Colour Vision:

Plate tests for colour vision are quick and easy to use. The Ishihara test is the most popular screening test for congenital protan or deutan defects (Pokorny et al 1979). It is usual to allow normal trichromats to make two partial errors of interpretation (Pokorny et al 1979).

Ishihara pseudo-isochromatic plates are supplied without a scoring method. Therefore, it was necessary to test a group of normal age matched individuals to establish a normal baseline.

Fifty four percent of patients made 5 or more errors with both eyes. However, this could also have been related to poor visual acuities in some patients.

Therefore, scoring strictly and only on the basis of the expected response from an individual with red/green colour deficiency as outlined in the manual, and allowing the high margin of 4 errors, it was still shown that 27% of the patients with bilateral ONH (in whom it was possible to carry out colour vision test) had red/green colour deficiency. It should, however, be stressed that the Ishihara plates fail to investigate yellow/blue discrimination.

Some plates have numbers which are not seen by a typical red/green defective individual. In this study when a patient stated a number for such a plate, though wrong, the plate was not counted as an error typical of red/green deficiency. It is possible that some

children "made up" a number when they actually could not see a number. If this were the case then a higher number of children would have fallen in the red/green deficient category.

I had to allow longer than the standard recommended 3 seconds for numbers and 10 seconds for tracing a line for four patients due to young age or some degree of mental retardation.

The association of ONH with colour deficiency has not hitherto been reported.

5 . 6 Contrast Sensitivity:

Compared to electronically generated gratings the "Cambridge low contrast grating" is inexpensive and is simple to use. However, it only tests one spatial resolution. Although it has been recommended that " Cambridge low contrast grating " plates should be read four times by each eye, it proved difficult to test each eye more than three times in two cases, because the children became bored. However, multiple readings of the plates are necessary especially with children as they may want to please the doctor by claiming that they see the gratings when they do not actually see it.

The results of the contrast sensitivity test were variable even in the normal control group. In four eyes (three patients) in the patient group the visual

acuties were 6/6. However, their contrast sensitivities ranged from 130 to 480. In general the patient group exhibited a poor level of contrast sensitivity. There was no distinctive or constant pattern of relationship between the level of contrast sensitivity and visual acuity (Table 2).

The majority of children who were tested, demonstrated impaired contrast sensitivity. This is of considerable importance especially from the stand-point of education. The appreciation of contrast is fundamental to the interpretation and understanding of complex pictorial data. Our finding in patients 12 and 31 that gross impairment in contrast sensitivity may occur in the presence of ostensibly good acuity is suggestive that such patients may find difficulty in understanding and interpreting visual material in which the contrast is poor.

The contrast sensitivity test is not a specific test. It needs to be taken into account only together with other tests in making a diagnosis. Contrast sensitivity tests are also psychophysical tests. Therefore, they suffer from the disadvantage of being limited by the technique of assessment and the response of the subject being tested. They are therefore only suitable in patients who can cooperate and concentrate. They are not suitable in the very young and in children who are mentally retarded.

5 . 7 Brightness-sense Comparison Test:

The results of the brightness-sense comparison test in the patient group are consistent with previous studies on patients with acquired optic nerve disease (Sadun & Lessel 1985), Interesting findings were obtained in the patients with ONH. This had not hitherto been studied in patients with this condition. The results show the difference of brightness-sense between the two eyes of patients with bilateral asymmetrical ONH. They also suggest a marked decrease of brightness-sense in hypoplasia of the optic nerve. The results of this test in patients with ONH indicate its usefulness as an investigative tool in mild unilateral cases and in asymmetrical ONH as a means of seeking further information regarding the presence or absence of a functional deficit in the optic nerve.

The brightness sense comparison test as described in this study is a practical test and easy to use. However, it requires understanding and cooperation from the patient. Being a comparative test between the two eyes it is of diagnostic value in only unilateral and asymmetrical bilateral cases.

The brightness-sense comparison test is a subjective psychophysical test which cannot preclude psychological involvement, and it suffers the lack of basic definition. Difficulty may also arise in patients with

central scotomata in whom the central area perceives a dim area which is surrounded by a brighter area related to the normal surrounding retina.

5 . 8 Fundus Photography and Image Analysis:

An experiment with different films was performed at the beginning of the study, to determine optimum film for red-free photography. This showed that 400 ASA film was required to obtain optimal results.

In three eyes for which the photographs had been correctly exposed, the area of the fovea could not be discerned in the fundus photographs. The visual acuities in these three eyes were hand movement in two, and counting fingers in one. This suggests an element of macular hypoplasia in these eyes.

The disc-macula: disc diameter (D-M/DD) ratio is the ratio of the horizontal distance between the centre of the optic disc and the macula to the mean diameter of the optic disc, as evaluated from fundus photography. This study confirms the validity of the D-M/DD ratio in confirming ONH. This is in agreement with previous

reports (Awan 1976, Wakakura & Alvarez 1987, Alvarez et al 1988). Awan (1976) considered the horizontal meridian only as the disc diameter. Both Awan 1976, and Wakakura & Alvarez (1987) added half the transverse diameter of the optic disc to the distance between the fovea centralis and the temporal margin of the optic disc, on calculating the D-M distance. In this study the average disc diameter was calculated, and the D-M distance was measured by adding half the average disc diameter to the distance from the temporal margin of the optic disc to the fovea. Furthermore, this is the largest series of patients with ONH in whom the D-M/DD ratio has been measured.

The 95% one-tailed upper population limit of the D-M/DD ratio for the normal group in this study was 2.94. This indicates that in practice a ratio of 3 or more, provides supportive evidence for the diagnosis of ONH. This is in agreement with previous studies by Wakakura & Alvarez (1987) and by Alvarez et al (1988).

In ninety five percent of the patients in this series, the mean D-M/DD ratios of the two eyes (or the one eye when only one eye was photographed, or in unilateral cases) were above the 95% one-tailed upper population limit established by the normal control group.

The D-M/DD ratios were significantly higher than their values for normal subjects. Furthermore, in the patients with unilateral ONH the ratio was higher in

the affected eye compared to the normal eye. This clearly implies that the small size of the optic disc must be contributing to the visual deficit in the patients. However, I found that the visual acuities and the D-M/DD ratios were not significantly correlated in the patients with bilateral ONH (Figure 7).

Furthermore, the results show that 75% of patients with asymmetrical bilateral ONH had a better visual acuity in the eye with the relatively larger D-M/DD ratio (Table 6). These findings indicate that, factor(s) other than the relative size of the optic disc must have determined the eventual visual outcome. Such factors include high refractive error, refractive amblyopia and optic atrophy (Section 5.3).

Optic atrophy and ONH are two manifestations of an "insult" to the developing optic nerve. Therefore, it is likely, at least in some cases, that the pale colour of the optic disc commonly seen in ONH is not due to relative increase in the proportion of glial tissue (which is believed not to be affected in ONH), but is due to an absolute increase of the glial tissue and diminished vasculature in these optic nerves due to an associated optic atrophy.

As to the two patients with segmental ONH; although the D-M/DD ratios for the affected eyes were significantly lower than the normal fellow eyes, there was no impairment of visual acuity and no association with refractive error.

5 . 9 Neuro-radiological Assessment:

Paediatric neurological abnormalities in association with ONH are not just anatomical curiosities but carry significant management implications. They signal the need for participation of different disciplines in the management of such a child including the paediatric endocrinologist, paediatric neurologist, paediatric ophthalmologist and possibly the paediatric psychologist. As well as the parents and the educational authorities.

It is generally agreed that an isolated defect of the septum pellucidum is not associated with any specific set of clinical features (St.John & Reeves 1957). However, multiple intracranial developmental anomalies may coexist with the absence of the septum pellucidum. The early discovery of intracranial abnormalities is of clinical importance for the following reasons:

1. Endocrine abnormalities related to defects in midline structures of the brain, (mainly involving the hypothalamus/pituitary axis) must be sought. Discovery of hypoglycaemia consequent to hypopituitarism can be life saving.
2. Long term follow up of children who show no such abnormalities on initial endocrine investigation is

indicated, to identify evolving endocrine dysfunction, in particular, growth hormone deficiency.

3. Parental counselling regarding the possible "non-ocular" associations of ONH.
4. To plan the patient's education. Special schooling, may be required for some children.

The RHSC in-patient disease index was the means whereby children with ONH who underwent neuro-radiological assessment were identified. This gave rise to a high number of patients with identifiable neuro-radiological abnormalities amongst patients who were investigated. Patients with relatively mild ONH would probably not be admitted to hospital, and even for those who are admitted, the diagnosis may easily be missed. Review of the case records indicated that most of the children had been primarily under the care of a neurologist and that ONH was in most cases not the principle neurological defect.

The relatively high number of patients who had associated neuro-radiological abnormalities in our patients may also stem from the source of the data. The Royal Hospital for Sick Children, Glasgow provides a secondary referral service for paediatric ophthalmology for the population of the West of Scotland of 2.5 millions. It is possible that a number of patients with isolated ONH, particularly milder forms, are not referred to or detected in this centre. It is also

likely that a number of cases remain undiagnosed. Furthermore, the RHSC disease index contains only details of in-patients. Moreover, this sample of patients who underwent neuro-radiological evaluation is also biased because it comprises only those individuals found to have a remarkably subtle clinical sign which can only be detected by an expert. There may have been many undetected cases of ONH which have "slipped through the net".

Of the 20 patients who underwent neuro-radiographic assessment 17 patients had initial diagnoses of systemic abnormality in addition to ONH (bilateral in 19 patients). The other three were all blind in both eyes due to severe ONH.

Therefore, the indications for referral for radiological assessment were narrow and strict in the patients. It remains unknown whether any of the remaining patients, who were not investigated radiologically, have undiagnosed neuro-radiological abnormality.

Eighty percent of the 20 patients who underwent neuro-radiological evaluation showed neuro-radiological abnormalities.

Thirty five patients with non-segmental ONH were originally identified for this study. Of these 45% (16 patients) showed radiological evidence of intracranial abnormality. Only one had unilateral ONH. The anecdotal finding of a normal CT scan in patient 26 who had unilateral ONH is in agreement with previous reports that unilateral ONH is associated less commonly

with intracranial abnormalities than bilateral ONH (Skarf & Hoyt 1984, Lambert et al 1987). Excluding the four cases of unilateral ONH, the percentage of patients in this series with bilateral ONH who had neuro-radiological abnormalities is 51%.

The septum pellucidum could be abnormally thin and therefore only partially present, as shown in two patients in this series. The corpus callosum abnormality can also be partially present, as demonstrated in one case.

Absence (partial or complete) of the septum pellucidum (55%), hydrocephaly (45%), porencephaly (25%), dilatation of the supra-sellar and chiasmatic cistern (25%) and absence (partial or complete) of the corpus callosum (20%) were relatively common neuro-radiological abnormalities in the patient group who underwent radiological evaluation. These results are comparable to work published by previous authors (Skarf & Hoyt 1984, Levene et al 1985).

This study showed an intracranial arachnoid cyst (Figure 13) in one patient with bilateral ONH, and an intracranial epidermoid cyst (Figure 14) in another. These associations with ONH have not previously been reported.

There was a high prevalence of complete blindness (44%) amongst the 16 patients who were investigated radiologically and had detectable intracranial abnormalities. All patients with intracranial

ELSCINT EXEL-820F *** ROYAL HOSPITAL FOR SICK CHILDREN ***
315986 - 1 - 6 - 15 12/06/85
RC 250 SS 0 OUT SW 12 BP 50
WINDOW
CEN1 40
WID1 140

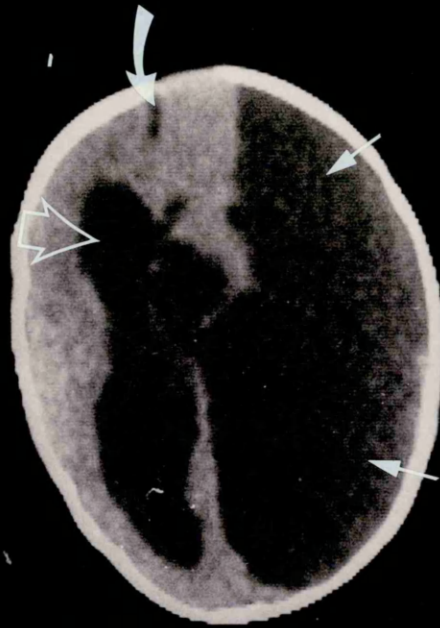


FIGURE 13

Axial CT scan showing a huge arachnoid cyst on the right side of the picture (arrows). The inter-hemispheric fissure can be seen displaced to the left (curved arrow). On the left side of the picture a dilated left lateral ventricle is seen (open arrow) (patient 4).

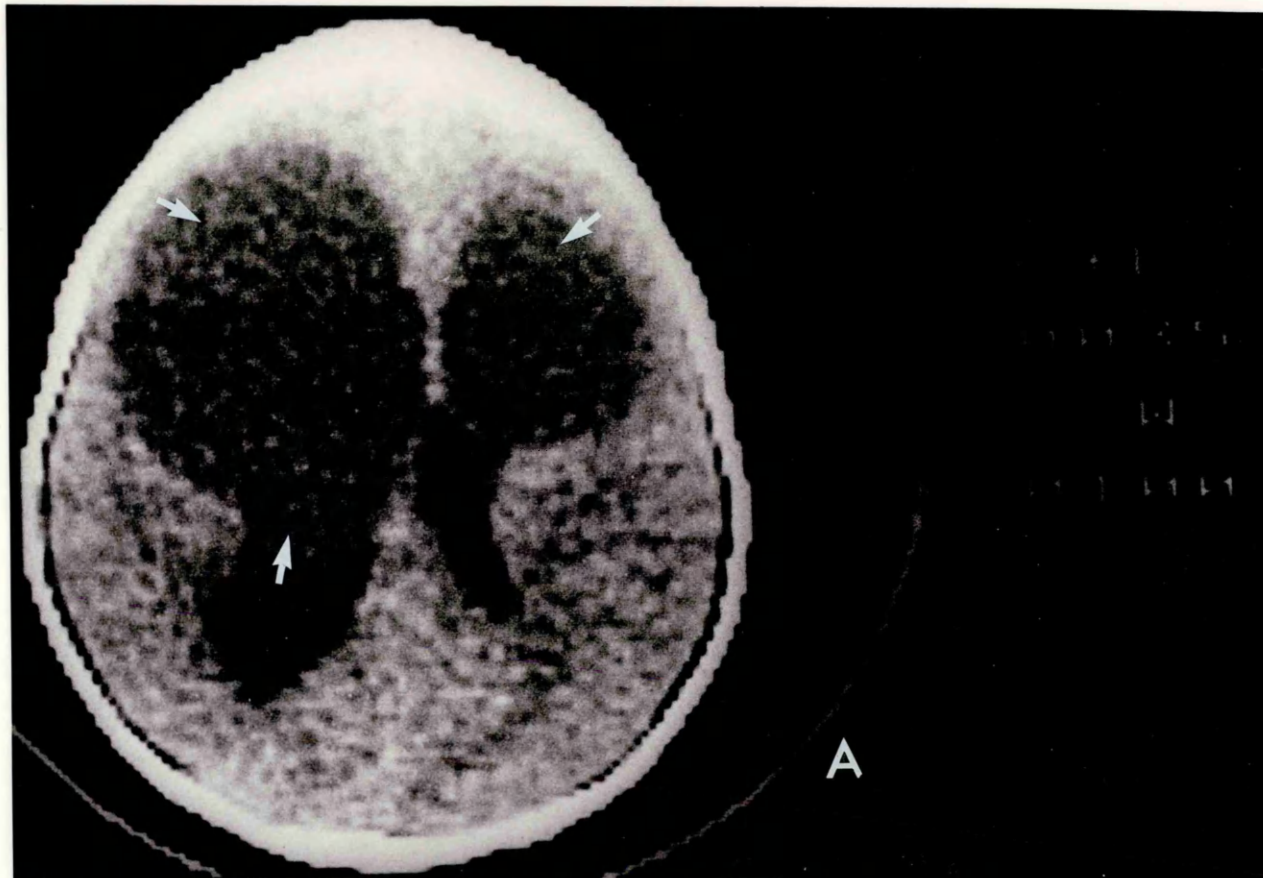
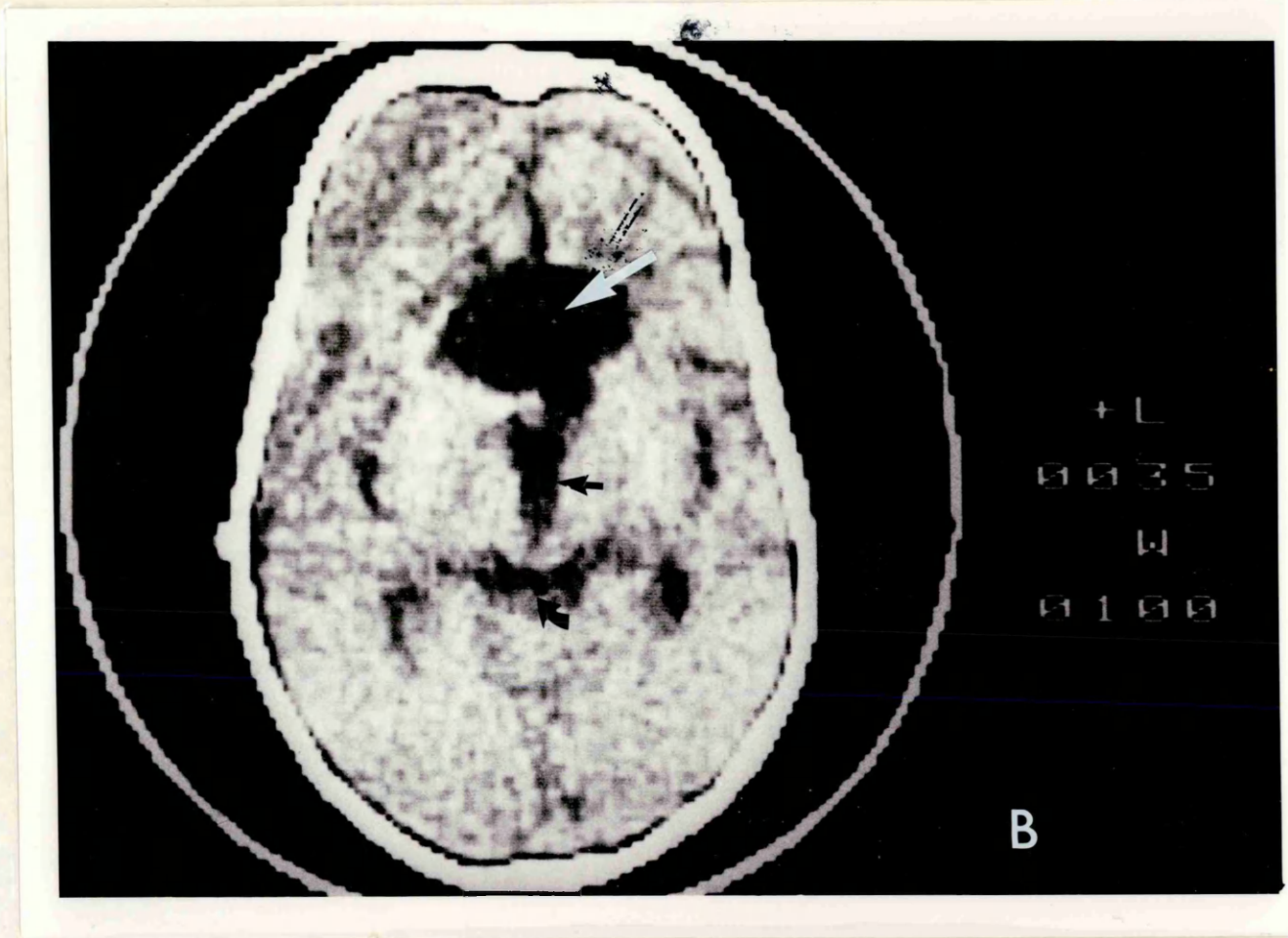


FIGURE 14

A. Huge bilobed suprasellar cystic mass, an "epidermoid cyst" (arrows), as seen on high axial CT scanning. Dilated ventricles are seen lying posterior to the mass (patient 18).



B. Low axial CT scan for patient 18 at the level of the third ventricle showing the suprasellar cyst (white arrow), dilated third ventricle (short black arrow) and dilated inter-peduncular cistern (curved arrow).

abnormalities had bilateral ONH. Nystagmus and manifest squint were also common with a prevalence of 47% for each. These figures support previous reports suggesting a high prevalence of neuro-radiological deficits in patients with ONH who have bilateral ONH, severe visual deficit and nystagmus (Lambert et al 1987).

Evidence of hypothalamic/pituitary hormone deficiency was present in 9 patients (45%), six of whom had intracranial radiological abnormalities. Growth retardation being common at 60% amongst patients who had hypopituitarism. Mental retardation was the principal diagnosis in 20% of the patients studied radiologically. However, eleven patients (55%) were eventually found to develop some degree of mental retardation, of these, eight patients had abnormal intracranial radiological findings. Patients (No. 3 and 6) were noticed on presentation to have "large heads", patient 6 had hydrocephaly and both showed other intracranial abnormalities. This indicates that hypopituitarism, growth retardation, and mental retardation with bilateral ONH are definite indications for neuro-radiological investigation on children with ONH.

The diagnostic value of cranial ultrasound and CT scan was compared in the 5 patients who underwent both investigations. It has been reported that cranial ultrasound is as good as a CT scan in demonstrating the

absence of the septum pellucidum (Fielder et al 1986). However, in one patient (No. 8) whose septum pellucidum was readily diagnosed as being absent on CT scanning, no comment could be made concerning its presence or absence from the cranial U/S films. This indicates that CT is more effective in detecting the absence of the septum pellucidum than cranial U/S. On the other hand modern high resolution ultrasound technology produces similar appearances to CT scans when imaging for absence of septum pellucidum or porencephaly. CT scanning remains better than modern U/S when imaging for cerebral or cerebellar atrophy, optic nerve hypoplasia and posterior fossa lesions. CT scanning gives complete cross-sectional images with superior resolution (Levene et al 1985). It should be stated however that cranial U/S has the advantage of being non-invasive and does not require sedation (Fielder et al 1986).

In patient number 9 who had CT finding of porencephaly (No 9), cranial U/S was of no value due to the poor quality of the film.

A normal CT scan does not necessarily presage normal brain development (Wilson et al 1984). Patient No 16 in this series had a normal CT scan but she developed hypothalamic obesity and was mentally retarded.

The CT scan has better resolution than cranial ultrasound (Levene et al 1985). The demonstration of

the pituitary stalk requires high resolution coronal CT, or Magnetic Resonance Imaging. Therefore, this abnormality may well have been underdiagnosed in patients in this series. Hydranencephaly could, on the other hand, be effectively demonstrated or excluded by either ultrasound or CT.

The condition of refraction was known in 15 of the patients who underwent radiological assessment.

It is interesting that astigmatism was even more severe in the patients who had proven radiological abnormalities. The mean astigmatism in such patients was 1.72 dioptries, compared to 1.22 dioptries in the patients who were investigated (in one, the condition of refraction is not known) and were found to be radiologically normal. However, this trend was not found to be statistically significant (Wilcoxon rank sum test: $P > 0.5$).

The two patients who had a mean astigmatism in the two eyes greater than 4 dioptries also had cerebral palsy. It is also of interest that the only 3 patients in the whole series who showed mixed astigmatism (No. 12, 17 and 19), and the only two patients who had astigmatism with opposite axes in the two eyes (No 6 and 14), also had severe neuro-radiological abnormalities.

In conclusion a high prevalence of mental retardation, hypothalamic / pituitary hormone deficiency, bilateral severe ONH and nystagmus was found in the patients who

had radiological intracranial abnormality. Three blind children were initially thought to have isolated bilateral ONH, they were found to have a non-developed / underdeveloped septum pellucidum in two, and porencephaly in one. This suggests that hypothalamic / pituitary hormone deficiency and patients with "isolated" bilateral ONH with severe visual deficit should be considered as definite indications for neuro-radiological investigations.

As intracranial U/S is a non-invasive investigation. It should be considered in all infants with bilateral ONH, even if there is no apparent deficiency of the hypothalamic / pituitary hormones, to anticipate evolving deficiency particularly of growth hormone. It would also be helpful in the estimation of the true prevalence of intracranial radiological abnormalities in infants with bilateral ONH in general.

The children with demonstrable intracranial abnormalities had more severe astigmatism than the group with normal radiographs. This suggest early retinoscopic examination in such children to optimise their visual function and their visual development.

SUGGESTIONS FOR FURTHER STUDIES

CHAPTER 6

6 SUGGESTIONS FOR FURTHER RESEARCH:-

This study has shown an increased prevalence of mothers who both smoked and drank alcohol during pregnancy. Therefore, It would be helpfull to investigate the role of excessive cigarette smoking and the role of cigarette smoking combined with alcohol intake during pregnancy in the pathogenesis of ONH in a large group of mothers of patients.

As ONH has been shown in this study to be closely associated with astigmatism, keratometric study in patients with ONH is recommended to confirm or exclude abnormal corneal curvature.

The role of refractive amblyopia in the eventual visual outcome in children with ONH, associated with high refractive error, has not previously been studied and warrants evaluation by comparing large numbers of patients with different degrees of astigmatism or other refractive errors, but with normal optic nerves. This would confirm the role of such a mechanism of refractive amblyopia in explaining the worse than expected visual acuities with spectacle correction in these patients.

An endocrinological screening study by performing fasting blood glucose and fasting blood cortisol on all

children with bilateral ONH would be required to determine the true prevalence of associated intracranial functional abnormalities in such children.

Cranial U/S is a non invasive procedure which is easy to perform in an infant. As the true prevalence of intracranial anatomical abnormalities in patients with ONH is not known, it would be helpful to perform cranial U/S on all infants with bilateral ONH particularly if associated with nystagmus.

The assessment of the growth pattern in patients with ONH to determine milder degrees of growth hormone deficiency, has yet to be performed.

In some patients with bilateral ONH, the finding of better visual acuity in the eye with the larger D-M/DD ratio suggests that the small size of the nerve is not the sole factor determining the eventual visual outcome in ONH. Histo-pathological studies would be of great help to determine the morphology of the macula in patients with ONH. The difficulty of locating the region of the macula on fundus photographs with three eyes in this series, which also had defective vision, suggest an element of macular hypoplasia in such patients.

The brightness-sense comparison test is a simple and practical test and it is suggested that it should become more widely used in clinical ophthalmology.

REFERENCES

REFERENCES:-

1. Acers T E . Optic nerve hypoplasia:
Septo-optic-pituitary dysplasia syndrome .
Transactions of the American Ophthalmological
Society 1981; 79: 425-457
2. Acers T E. Optic nerve hypoplasia and visual
function (A quantitative correlation).
Journal of Oklahoma State Medical Association
1983; 76: 409-413
3. Aicardi J, Chevrie J J, Rousselie F. Le syndrome
spasmes en flexion agenesie calleuse, anomalies
chorio-retiniennes.
Archives Francaises Pediatrie 1969; 26: 1103-1120
4. Aicardi J, Goutieres F. The syndrome of absence
of the septum pellucidum with porencephalies and
other developmental defects.
Neuropediatrics 1981; 12: 319-324
5. Alvarez E, Wakakura M, Khan Z, Dutton G N. The
disc-macula distance to disc diameter ratio: A
new test for confirming optic nerve hypoplasia in
young children.
Journal of Pediatric Ophthalmology and Strabismus
1988; 25: 151-154
6. ^f ^R Anderson S, Bro-Rasmussen F, Tygstrup I.
Anencephaly related to ocular development and
malformation.
American Journal of Ophthalmology 1967; 64:
559-566

7. Arden G B. The importance of measuring contrast sensitivity in cases of visual disturbance. British Journal of Ophthalmology 1978; 62: 198-209
8. Awan K J. Ganglionic neuroretinal aplasia and hypoplasia: aplasia and hypoplasia of optic nerve. Annals of Ophthalmology 1976; 8: 1193-1202
9. Baker A B, Baker L H. Clinical Neurology. Chapter 55. Philadelphia: Harper and Row, 1984; Vol 4: p 51
10. Beuchat L, Safran A B. Optic nerve hypoplasia: papillary diameter and clinical correlation. Journal of Clinical Neuro-ophthalmology 1985; 5: 249-253
11. Billson F A. Clinical significance of optic nerve hypoplasia. Transactions of the Ophthalmological Society N.Z. 1973; 25: 179-180
12. Billson F A, Hoyt C S. Optic nerve hypoplasia in chondrodysplasia punctata. Journal of Pediatric Ophthalmology 1977; 14: 144-147
13. Bjork A, Laurell C G, Laurell U. Bilateral optic nerve hypoplasia with normal visual acuity. American Journal of Ophthalmology 1978; 86: 524-529
14. Bland M. An introduction to medical statistics. Oxford: Oxford University Press, 1987; pp 285-288.

15. Boniuck V, Ho P K. Ocular findings in anencephaly.
American Journal of Ophthalmology 1979; 88: 613-617
16. Boynton J R, Pheasant T R, Levine M R. Hypoplastic optic nerves studied with B-scan ultrasonography and axial tomography of the optic canals.
Canadian Journal of Ophthalmology 1975; 10: 473-481
17. Brent H P, Arstikaitis M. Correction of refractive errors. In: Crawford & Morin, eds. The Eye in Childhood. New York; Crune & Stratton 1983; pp 34-35
18. Brown G C. Optic nerve hypoplasia and colobomatous defects.
Journal of Pediatric Ophthalmology and Strabismus 1982; 19: 90-93
19. Brownstein S, Kirkham T H, Kalousek D K. Bilateral renal agenesis with multiple congenital ocular anomalies.
American Journal of Ophthalmology 1976; 82: 770-774
20. Bruckner R. paltlampen mikroskopie und ophthalmoscopie um auge von ratte und maus.
Documenta Ophthalmologica. 1951; 5-6: 452-554
21. Buchanan T A, Hoyt W F. Temporal visual field defects associated with nasal hypoplasia of the optic disc.
British Journal of Ophthalmology 1981; 65:

636-640

22. Calderone J P, Chess J, Borodic G, Albert D M.
Intraocular pathology of trisomy 18 (Edward's syndrome): report of a case and review of literature.
British Journal of Ophthalmology 1983; 67:
162-169
23. Chan C C, Egbert P R, Herrick M K, Urich H. A
reappraisal of Walker's 'Lissencephaly'.
Archives of Neurology 1980; 37: 104-108
24. Costin G, Murphree A L. Hypothalamic-pituitary
function in children with optic nerve hypoplasia
American Journal for Diseases of Children 1985;
139: 249-254
25. Crawford J S, Morin J D. The Eye in Childhood,
New York; Grune & Stratton, 1983; p 397.
26. Davidson J E, McWilliam R C, Evans T J,
Stephenson J B P. Porencephaly and optic
hypoplasia in neonatal isoimmune
thrombocytopenia.
Archives of Diseases in Children 1989; 64:
858-860
27. Davson H. Physiology of the Eye. Edinburgh
& London, Churchill Livingstone, 1972; pp 412-412
28. De Morsier G. Agenesis du Septum Lucidum avec
malformation du tractus optique.
Schweizer Archiv fuer Neurologie, Neurochirurgie
und Psychiatrie 1956; 77: 267-292
29. Denslow G T, Sims M. Duane's retraction
syndrome associated with optic nerve hypoplasia.

- Journal of Pediatric Ophthalmology and Strabismus
1980; 17: 26-28
30. Dorrell D. The tilted disc.
British Journal of Ophthalmology 1978; 62: 16-20
31. Duke Elder S. System of Ophthalmology.
Vol 3, St.Louis; Mosby, 1963.
32. Edwards W C, Layden W E. Optic nerve hypoplasia.
American Journal of Ophthalmology. 1970; 70:
950-959
33. Ellinberger C, Runyan T E. Holoprosencephaly
with hypoplasia of the optic nerves, dwarfism and
agenesis of the septum pellucidum.
American Journal of Ophthalmology 1970; 70:
960-967
34. Farmer J, Hoyt C S. Monocular nystagmus in
infancy and early childhood.
American Journal of Ophthalmology 1984; 98:
504-509
35. Fielder A R, Levene M I, Trounce J Q, Tanner M S.
Optic nerve hypoplasia in infancy.
Journal of the Royal Society of Medicine 1986;
79: 25-29
36. Franceschetti A, Bock R H. Megalopapilla: A
new congenital anomaly
American Journal of Ophthalmology 1950; 33:
227-234
37. Francois J, De Rouck A. Electroretinographical
study of the hypoplasia of the optic nerve.
Ophthalmologica 1976; 172: 308-330

38. Fried P A. Septum and behaviour: A review.
Psychological Bulletin 1972; 78: 292-310
39. Frisen L, Holmegaard L. Spectrum of optic
nerve hypoplasia.
British Journal of Ophthalmology 1978; 62: 7-15
40. Gardner H B, Irvine A R. Optic nerve hypoplasia
with good visual acuity.
Archives of Ophthalmology 1972; 88: 255-258
41. Garg B P. Colpocephaly. An error of
morphogenesis?
Archives of Neurology 1982; 39: 243-247
42. Gelatt K N, Leipold H W. Case report.
Bilateral optic nerve hypoplasia in two dogs.
Canadian Veterinary Journal 1971; 12: 91-96
43. Gelatt K N, Leipold H W, Coffman J R. Bilateral
optic nerve hypoplasia in a colt.
Journal of the American Veterinary Medical
Association 1969; 155: 627-631
44. Goldhammer Y, Smith J L. Optic nerve anomalies
in basal encephalocele.
Archives of Ophthalmology 1975; 93: 115-118
45. Greenfield P S, Wilcox L M, Weiter J J, Adelman
L. Hypoplasia of the optic nerve in
association with porencephaly.
Journal of Pediatric Ophthalmology and Strabismus
1980; 17: 75-80
46. Griffiths P, Hunt S. Specific spatial defect
in a child with septo-optic dysplasia.
Developmental Medicine and Child Neurology 1984;

- 26: 395-400
47. Hackenbruch Y, Meerhoeff E, Besio R, Cardoso H. Familial bilateral optic nerve hypoplasia. American Journal of Ophthalmology 1975; 79: 314-320
48. Harcourt B. Developmental abnormalities of the optic nerve. Transactions of the Ophthalmological Society U.K. 1976; 96: 395-398
49. Helveston M E. Unilateral hypoplasia of the optic nerve. Archives of Ophthalmology 1966; 76: 195-196
50. Hittner H M, Desmond M M, Montgomery J R. Optic nerve manifestations of Cytomegalovirus infection. American Journal of Ophthalmology 1976; 81: 661-665
51. Hotchkiss M L, Green W R. Optic nerve aplasia and hypoplasia. Journal of Pediatric Ophthalmology and Strabismus 1979; 16: 225-240
52. Hoyt C S. Optic disc anomalies and maternal ingestion of LSD. Journal of Pediatric Ophthalmology 1978; 15: 286-289
53. Hoyt C S, Billson F L. Maternal anticonvulsants and optic nerve hypoplasia. British Journal of Ophthalmology 1978; 62: 3-6

54. Hoyt W F, Frisen L, Newman N N. Funduscopy of nerve fibre layer defects in glaucoma. *Investigative Ophthalmology* 1973; 12: 814-829
55. Hoyt W F, Kaplan S L, Grumbach M M, Glaser J. Septo-optic dysplasia and pituitary dwarfism. *Lancet* 1970; 1: 893-894
56. Hoyt W F, Rios-Montenegro E N, Behrens M M, Eckelhoff R J. Homonymous hemioptic hypoplasia. Funduscopy features in standard and red-free illumination in three patients with congenital hemiplegia. *British Journal of Ophthalmology* 1972; 56: 537-545
57. Ishihara M Optic hypoplasia with pituitary dwarfism. *Endocrinologia Japonica (Tokyo)* 1983; 30: 7-14
58. Jan J E, Robinson G C, Kinnis C, Macleod P J M. Blindness due to optic nerve atrophy and hypoplasia in Children: An epidemiological study. *Developmental Medicine and Child Neurology* 1977; 19: 353-363
59. Kaplan S L, Grumbach M M, Hoyt W F. A syndrome of hypopituitary dwarfism, hypoplasia of the optic nerve and malformation of procencephalon: Report of 6 patients. *Pediatric Research* 1970; 4: 480-481
60. Katz B, Wiley C A, Lee V W. Optic nerve hypoplasia and the syndrome of nevus sebaceous of Jadassohn. A new association. *Ophthalmology* 1987; 94: 1570-1576

61. Keith C G, Webb G C, Rogers J G. Absence of a lateral rectus muscle associated with duplication of the chromosome segment 7q32-34.
Journal of Medical Genetics 1988; 25: 122-127
62. Kern T J, Riis R C. Optic nerve hypoplasia in three miniature Poodles.
Journal of the American Veterinary Medical Association 1981; 178: 49-54
63. Kennedy S J, Schwartz B, Takamoto T, Eu J K T. Interference fringe scale for absolute ocular fundus measurement.
Investigative Ophthalmology and Visual Science 1983; 24: 169-174
64. Kottow J B. Congenital malformations of the retinal vessels with primary optic nerve involvement.
Ophthalmologica 1978; 176: 86-90
65. Krause-Bruckner W, Gardner D W. Optic nerve hypoplasia associated with absent septum pellucidum & hypopituitarism. ✓
American Journal of Ophthalmology 1980; 89: ✓
113-120
66. Kreibitz W. Uber Aplasie and Hypoplasie der papilla nervi optici.
Klinische Monatsblätter für Augenheilkunde 1959; 135: 212-223
67. Kuriyama M, Shigematsu Y, Konishi K, Konishi Y, Sudo M, Haruki S, Ito H. Septo-optic dysplasia with infantile spasms.

- Pediatric Neurology 1987; 4: 62-65
68. Kyttila J, Meittinen P. On bilateral aplasia of the optic nerve.
Acta Ophthalmologica 1961; 39: 416-419
69. Lambert S R, Hoyt C S, Narahara M H. Optic nerve hypoplasia.
Survey of Ophthalmology 1987; 32: 1-9
70. Layman P R, Anderson D R, Flynn J T. Frequent occurrence of hypoplastic optic discs in patients with aniridia.
American Journal of Ophthalmology 1974; 77: 513-516
71. Levene M I, Williams J L, Fawer C L. Ultrasound of the infant brain. Oxford; Blackwell Scientific, 1985; pp 142-144
72. Levine R, Snyder A, Sugarman G. Ocular involvement in chondrodysplasia punctata.
American Journal of Ophthalmology 1974; 77: 851-859
73. Lippe B, Kaplan S A, La Franchi S. Septo optic dysplasia and maternal age.
Lancet 1979; 2: 92-92
74. Littmann H. Determination of the real size of an object on the fundus of the living eye .
Klinische Monatsblätter für Augenheilkunde 1982; 180: 286-289
75. Lloyd L, Buncic J R. Hypoplasia of the optic nerve and disc. In: Smith J L ed.
Neuro-ophthalmology Focus. New York; Mason, 1980;

pp 85-96.

76. Lowman R M, Shapiro R, Collins L C. Significance of widened septum pellucidum.
Journal of Roentgenology 1948; 59: 177-196
77. MacRae D W, Howard R O, Albert D M, Hsia Y E. Ocular manifestations of the Meckel Syndrome.
Archives of Ophthalmology 1972; 88: 106-113
78. Magnus H. Zur Karuistik der angeborenen Schuerven-milbildungen.
Klinische Monatsblätter Augenheilkunde 1884; 2: 85-87
79. Mainster M A, Dieckert J P. A simple haploscopic method for quantitating colour comparison.
American Journal of Ophthalmology 1980; 89: 58-61
80. Manelfe C, Rochiccioli P. CT of septo-optic dysplasia.
American Journal of Roentgenology 1979; 133: 1157-1160
81. Mann I. The development of the human eye.
New York; Grune & Stratton. 1964, pp 80-80
82. Margolis S, Aleksic S, Charles N, Budzilovich G. Retinal and optic nerve findings in Goldenhar-Gorlin syndrome.
Ophthalmology 1984; 91: 1327-1333
83. Margolith D, Jan J E, Mc Cormick A Q, Tze W J, Lapointe J. Clinical spectrum of optic nerve hypoplasia: Review of 51 patients.
Developmental Medicine and Child Neurology 1984;

- 26: 311-322
84. Margolith D, Tze W J, Jan J E. Congenital optic nerve hypoplasia with hypothalamic pituitary dysplasia. A review of 16 cases.
American Journal of Diseases of Children 1985; 139: 361-366
85. Martyn L J, DiGeorge A. Selected eye defects of special importance in Pediatrics.
Pediatric Clinics of North America 1987; 34: 1517-1542
86. McKinna A J. Quinine induced hypoplasia of the optic nerve.
Canadian Journal of Ophthalmology 1966; 1: 261-265
87. Michaud J, Mizrahi E M, Urich H. Agensis of the vermis with fusion of the cerebellar hemispheres, septo-optic dysplasia and associated anomalies.
Acta Neuropathologica 1982; 56: 161-166
88. Morishima A, Aranoff G S. Syndrome of septo-optic-pituitary dysplasia: The clinical spectrum.
Brain and Development 1986; 8: 233-239
89. Moseley I. Computerized tomography in the investigation of visual loss.
In: The eye in General Medicine. Rose F C, ed. London; Chapman & Hall, 1983; pp 51-51
90. Mosier M A, Lieberman M F, Green W R, Knox D L. Hypoplasia of the optic nerve.
Archives of Ophthalmology 1978; 96: 1437-1442

91. Nelson M, Lessel S, Sadun A A. Optic nerve hypoplasia and maternal diabetes mellitus. Archives of Neurology 1986; 43: 20-25
92. Newcombe R G, Duff G R. Eyes or patients? Traps for the unwary in the statistical analysis of ophthalmological studies. British Journal of Ophthalmology 1987; 71: 645-646
93. Novakovic P, Taylor D S, Hoyt W F. Localising patterns of optic nerve hypoplasia - retina to occipital lobe. British Journal of Ophthalmology 1988; 72: 176-182
94. Olivier R, Billson F. Optic Nerve Hypoplasia: A review. Journal of Child Neurology 1986; 1: 181-188
95. Patel H, Tze W J, Crichton J U, McCormick A Q, Robinson G C, Dolman C L. Optic nerve hypoplasia with hypopituitarism. Septo-optic dysplasia with hypopituitarism. American Journal of diseases of Children 1975; 129: 175-180
96. Peterson R A, Walton D S. Optic nerve hypoplasia with good visual acuity and visual field defects. Archives of Ophthalmology 1977; 95: 254-258
97. Pokorny J, Smith V C, Verriest G, Pinckers A J. Congenital and acquired color vision defects. New York, London; Grune and Stratton, 1979; pp

83-86

98. Provis J M, Van Driel D, Billson F A, Russel P.
Human fetal optic nerve: Overproduction and
elimination of retinal axons during development.
Journal of Comparative Neurology 1985; 238:
92-100
99. Rathbun J E, Hoyt W F, Beard C. Surgical
management of orbitofrontal varix in
Klippel-Trenaunay-Weber syndrome.
American Journal of Ophthalmology 1970; 70:
109-112
100. Ray W A, O'Day D M Statistical analysis of
multi-eye data in ophthalmic research.
Investigative Ophthalmology and Visual Science
1985; 26: 1186-1188
101. Raybaud C. Destructive lesions of the brain.
Neuroradiology 1983; 25: 265-291
102. Reeves D L. Congenital absence of the septum
pellucidum.
Bulletin of Johns Hopkins Hospital 1941; 69:
61-71
103. Robinson G C, Conry R F. Maternal age and
congenital optic nerve hypoplasia: A possible
clue to etiology.
Developmental Medicine and Child Neurology 1986;
28: 294-298
104. Roger G L, Brown D, Gray I, Bremer D. Bilateral
optic nerve hypoplasia associated with cerebral
atrophy.
Journal of Pediatric Ophthalmology and Strabismus

- 1981; 18: 18-22
105. Rush J A, Bajandas F J. Septo-optic dysplasia
(De Morsier syndrome).
American Journal of Ophthalmology 1978; 86:
202-205
106. Sadun A A, Lessell S. Brightness-sense and
optic nerve disease.
Archives of Ophthalmology 1985; 103: 39-43
107. Saunders & Rubin. Ophthalmic pathology of
animals. New York; S. Harger, 1975; pp 155-158
108. Scheie H C, Adler F H. Aplasia of the optic
nerve.
Archives of Ophthalmology 1941; 26: 61-70
109. Schindler A M, Pleasure J R. Neonatal
hepatitis.
Hospital Practice 1985; 20: 123-124
110. Shipkin P M, Glaser J S. Optic nerve
hypoplasia a benign entity simulating acquired
neurological disease.
Transactions of the American Neurological
Association 1979; 104: 128-130
111. Seeley R L, Smith J L. Visual field defects
in optic nerve hypoplasia.
American Journal of Ophthalmology 1972; 73:
882-889
112. Sheridan S J, Robb R M. Optic nerve hypoplasia
with diabetes insipidus.
Journal of Pediatric Ophthalmology and Strabismus
1978; 15: 82-84

113. Sherlock D A, Mc Nicol L R. Anaesthesia and septo optic dysplasia.
Anaesthesia 1987; 42: 1302-1305
114. Skarf B, Hoyt C S. Optic nerve hypoplasia in children. Association with anomalies of the endocrine and CNS.
Archives of Ophthalmology 1984; 102: 62-67
115. Smith J L. Hypoplasia of the optic nerve and disc. editor's note. Neuro-ophthalmology Focus, New York; Mason, 1980; pp 95-95
116. Sorsby A. Modern Ophthalmology. Vol 3. Washington D.C.; Butterworth, 1964; pp 3-3
117. Spedick M J, Benchamps G R. Retinal vascular and optic nerve anomalies in albinism.
Journal of Pediatric Ophthalmology and Strabismus 1986; 23: 58-63
118. Spinelli F. Mikrometrie des Augenhintergrundes, Bestimmung und sklerale Lokalisation von Netzhautpunkten, ausgeführt mit speziellen Zusatzteilen am vereinfachten Gullstrandschen Ophthalmoskop.
Klinische Monatsblätter Augenheilkunde 1934; 92: 93-107
119. Spargue J B, Wilson W B. Electrophysiologic findings in bilateral optic nerve hypoplasia.
Archives of Ophthalmology 1981; 99: 1028-1029
120. Stewart C, Castro-Magana M, Sherman J, Angulo M Collipp P J. Septo optic dysplasia and median cleft face syndrome in a patient with isolated

- growth hormone deficiency and hyperprolactinemia.
American Journal of diseases of Children 1983;
137: 484-487
121. St. John J R, Reeves D L. Congenital absence
of the septum pellucidum.
American Journal of Surgery 1957; 94: 974-980
122. Stromland K. Ocular abnormalities in fetal
alcohol syndrome.
Acta Ophthalmologica (Suppl 171) 1985; 63: 1-50
123. Stunjak Z. Kongenitalna anomalija merenice
i vidog zivca u ocimizdrebeta.
Veterinary Archives 1941; 11: 236-251
124. Taylor D. Congenital tumours of the anterior
visual system with dysplasia of the optic discs.
British Journal of Ophthalmology 1982; 66:
455-463
125. Taylor D S. The genetic implications of optic
disc anomalies.
Transactions of the Ophthalmological Society U K
1985 104: 853-856
126. Wakakura M, Alvarez E. A simple clinical method
of assessing patients with optic nerve
hypoplasia. The disc-macula distance to disc
diameter ratio.
Acta Ophthalmologica 1987; 65: 612-617
127. Walton D S, Robb R M, Boston M D. Optic nerve
hypoplasia.
Archives of Ophthalmology 1970; 84: 575-578
128. Weichselbaum R R, Zakov Z N, Albert D M, Friedman
A H, Nove J, Little J B. New findings in the

chromosome 13 long-arm deletion syndrome and retinoblastoma.

Ophthalmology 1979; 86: 1191-1201

129. Weiter J J, McLean I W, Zimmerman L E. Aplasia of the optic nerve and disk.
American Journal of Ophthalmology 1977; 83: 569-576
130. Weleber R G, Palmer E A. Selected causes of blindness in infants and children.
Perspectives in Ophthalmology 1981; 5: 13-20
131. Wilkins A J, Robson J G. Cambridge low contrast gratings. Instructions for Use. Clement Clarke International (1988).
132. Wilson D M, Enzmann D R, Hintz R L, Rosenfeld G. Computed tomography findings in septo-optic dysplasia: Discordance between clinical and radiological findings.
Neuroradiology 1984; 26: 279-283
133. Wilson P W, Easley R B, Bolander F F, Hammond C B. Evidence for a hypothalamic defect in septo-optic dysplasia.
Archives of Internal Medicine 1978; 138: 1276-1277
134. Wybar K C. Acquired optic atrophy in early childhood. In: Cant J S, ed. The optic nerve. London, Henry Kimpton, 1972 pp 81-89
135. Zeeman W P C, Tumbelaka R. Das zentrale und periphere optische system bei einer kongenital blinden Katze.
Archives Klinische Ophthalmol 1916; 91: 242-263

136. Zion V. Optic nerve hypoplasia.
Ophthalmic Seminars 1976; 1: 171-196
137. Zimmerman R A, Bilaniuk L T, Grossman R I.
Computed tomography in migratory disorders of
human brain development.
Neuroradiology 1983; 25: 257-263

APPENDIX

APPENDIX:-

The questionnaire form shown overleaf was distributed to mothers of 65 normal children, and to mothers of patients with optic nerve hypoplasia. They were requested to complete the questionnaire. The assistance of a nurse and the author was provided as required.

This questionnaire is to help in research into a possible relationship between a mother's health during pregnancy and the development of certain eye problems. It would help us greatly if you could spare time to answer all the following questions. Thank you for your assistance.

1. Was your child the first born? Yes/No
If no, how many other children have you had?

2. Was your child born at full term?
Yes/No/Don't know
If no, how many weeks before/after term?

3. Do you suffer from Diabetes? Yes/No/Don't know
If yes A. What treatment are you on?

B. When did you find out that you had diabetes?

6. Was your child's birth normal?
Yes/No/Don't know
If no, please give detail.

7. Do you smoke? Yes/No

If yes. A. How many cigarettes A DAY did you
smoke BEFORE pregnancy?

(Please circle as appropriate)

1-5, 6-10, 11-15, 16-20, more than 20

B. How many cigarettes A DAY did you
smoke DURING pregnancy?

1-5, 6-10, 11-15, 16-20, more than 20

C. How many cigarettes A DAY do you
smoke AT PRESENT?

1-5, 6-10, 11-15, 16-20, more than 20

8. Do you drink alcohol? Yes/No

If yes. A. How many units* did you drink in a
week BEFORE pregnancy?

(*1 unit = half a pint of
ordinary strength lager or beer,
two glasses of wine, or a single
measure of spirit).

(please circle as appropriate)

1-5, 6-10, 11-15, 16-20, more than 20

B. How many units did you drink in a
week DURING pregnancy?

1-5, 6-10, 11-15, 16-20, more than 20

C. How many units do you drink AT
PRESENT in a week?

1-5, 6-10, 11-15, 16-20, more than 20

9. Did you take any drugs or medications during
pregnancy? Yes/No/Don't know
If yes, please give details.

10. Did you have any illnesses while pregnant?
Yes/No/Don't know
If yes, please give details.

12. What is your date of birth? Day /Month /Year

THANK YOU FOR COMPLETING THE QUESTIONNAIRE.

