



A necessary condition to keep in mind after blunt trauma: cardiac tamponade

Travma sonrası akılda tutulması gereken bir durum: kardiyak tamponad

Onur Saydam¹, Omer Tanyeli², Mehmet Atay¹, Okan Ugurlu², Mehmet Sait Altintas³

¹Karaman State Hospital Cardiovascular Surgery Department, Karaman, Türkiye

²Necmettin Erbakan University Meram Faculty of Medicine Department Cardiovascular Surgery, Konya, Türkiye

³Karaman State Hospital Cardiology, Karaman, Türkiye

Abstract

Cardiac injuries represent 1% of the thoracic traumas. Cardiac injuries can be presented as blunt or penetrating injuries. In these patients, most important factors in determining the mortality are diagnosis and treatment process. Patients with cardiac tamponade due to blunt trauma can benefit from careful physical and echocardiographic examination. In addition; communication between different centers, giving correct data about the patient, establishing coordination among physicians and making necessary preparations for surgery can prevent loss of time. In this case report we present a 22-year-old male patient who was brought to emergency service after motorcycle accident and diagnosed with cardiac tamponade.

Keywords: Cardiac Tamponade; Blunt Thorax Injury; Surgical Treatment.

Öz

Kardiyak travmalar torasik travmaların yaklaşık %1'ini oluşturmaktadır. Kardiyak yaralanmalar künt veya penetran yaralanmalar şeklinde karşımıza çıkabilir. Bu yaralanmalarda tanı ve tedavi süreci ne kadar hızlı olursa, mortalite de o kadar düşük olmaktadır. Bu hastalarda dikkatli fizik muayene ve gerekiyor ise ekokardiyografiden faydalanılarak kardiyak yaralanma tanısının erken koyulması ve cerrahi girişimin planlanması mortalite ve morbidite açısından önemlidir. Aynı zamanda farklı klinikler arasında hasta hakkında doğru bilgilendirme yapılarak hekimler arasında koordinasyon kurulması, buna göre gerekli hazırlıkların yapılarak cerrahiye giden süreçte vakit kaybının önlenmesi, hastanın hayatını kurtaran en önemli davranış olmuştur. Bu olgumuzda motorsiklet kazası sonucu acil servise kabul edilmiş ve kardiyak tamponat tanısı almış 22 yaşında erkek hastayı literatüre katkı sağlaması açısından sunduk.

Anahtar Kelimeler: Kardiyak Tamponad; Künt Toraks Yaralanması; Cerrahi Tedavi.

Received/Başvuru: 09.11.2015
Accepted/Kabul: 02.12.2015

Correspondence/İletişim
Onur Saydam
Karaman State Hospital
Cardiovascular Surgery Department,
Karaman, Türkiye
E-mail: Onursaydam@hotmail.com

For citing/Atıf için
Saydam O, Tanyeli O, Atay M,
Ugurlu O, Altintas MS. A necessary
condition to keep in mind after blunt
trauma: cardiac tamponade. J Turgut
Ozal Med Cent 2016;23(2):202-4.

INTRODUCTION

In our country the thoracic trauma rates have been increased due to increase in domestic community violence and accident rates. The ratio of chest trauma cases which requiring emergency surgery is 10.4%. The cardiac injuries represent 1% of the thoracic traumas. Cardiac injuries can be presented as blunt or penetrating injuries. The most important life-saving factors are; convenient and fast transport to the emergency service (1). In our case; we present a patient who admitted to emergency service with a blunt thorax trauma and diagnosed with left atrial appendix and left ventricular apex injury.

CASE REPORT

22-year-old male patient was brought to emergency service after motorcycle accident. First examination revealed that the patient was hypotensive (70/50 mmHg) and has tachycardia (118 / min). Medical resuscitation was applied (IV fluid therapy). In laboratory results; hemoglobin was 13.48 g / dL, hematocrit value was 40.2%. Other tests results were within normal limits. Echocardiography was performed. Effusion was observed around heart and the widest part of the effusion was 3 cm (Figure 1A). The patient was hemodynamically stable and contrast-enhanced computerized tomography (CCT) was planned to identify additional pathologies. CT showed minimal pneumothorax and diffuse pericardial effusion especially on the left ventricle and apex (Figure 1B).

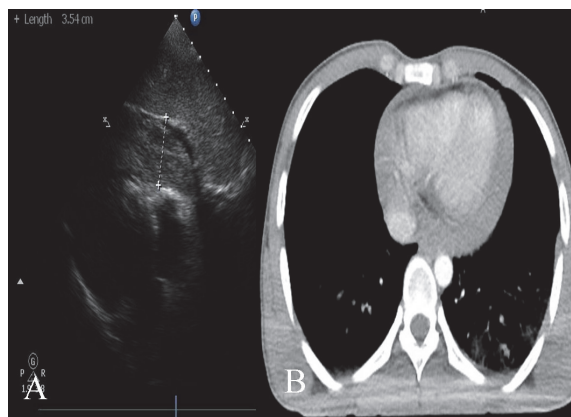


Figure 1a. Echocardiographic image of pericardial effusion and compression of right ventricle. **1b.** Contrast-enhanced computerized tomography image of pericardial effusion and flattened heart sign

There were no additional injuries. Emergency surgery was recommended to the patient. The first center who admitted the patient did not have the cardiopulmonary bypass pump. The patient was hemodynamically stable therefore, patient referred to a senior center. Supportive medical treatment was established. Prepared erythrocyte suspensions and all tests which performed at the initial hospital were sent with the patient. For rapid intervention emergency surgery conditions were

established at the senior center. The patient was transferred to the operating room after the transthoracic echocardiography. An electrocardiogram (ECG) showed a heart rate (HR) of 120 beats/min, blood pressure (BP) was of 80/55 mm Hg, and saturation of peripheral oxygen at 95%. Immediate median sternotomy was performed and after that pericardiectomy was performed (figure 2A). About 200 cc of blood ejected out of the pericardial cavity. The patient showed return of spontaneous circulation, with HR of 90 beats/min and BP of 110/85 mm Hg. The injuries were detected on left atrial appendix and left ventricular apex. Injuries were repaired with 4.0 proline plej sutures (Figure 2B). The surgery was successful, and the patient recovered well. The patient was discharged from hospital 4 days after the surgery.

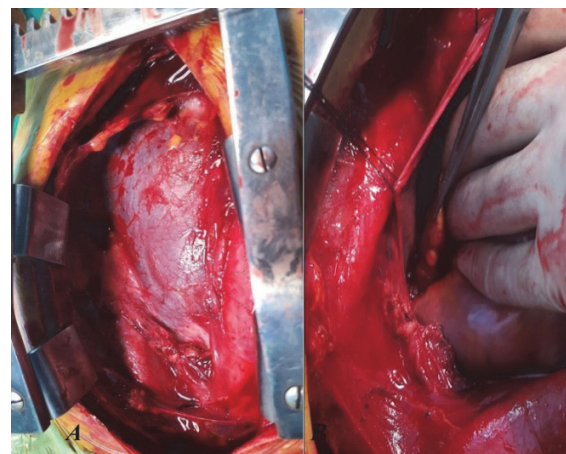


Figure 2a. Intraoperative image of pericardial reflection of cardiac tamponade **2b.** Intraoperative image of left atrial appendix wound that was repaired by using pledget.

DISCUSSION

40% of patients, who died after thoracic trauma, have been accompanied by cardiac injury. Patient population is usually under 40 years of age and this increasing the importance of early interventions (1, 2). Cardiac injuries can be presented as blunt or penetrating injuries. The most common causes of blunt chest traumas are vehicle accidents, falls from heights, occupational accidents and sports injuries (4, 5). Penetrating cardiac traumas are more common (3). Acute cardiac tamponade is an uncommon complication of blunt chest traumas but can be life-threatening. Patients with blunt chest trauma are usually presented with multiple traumas. Tamponade diagnosis needs high index of suspicion. It can mimic the other complication of trauma such as hypovolemia. Careful physical examination should be performed.

Cardiac tamponade should be suspected in patients presenting with hypotension, jugular venous distension, pulsus paradoxus, tachycardia, tachypnea and/or severe dyspnea. Echocardiography can be easily used in an emergency room with an accuracy of 86%, specificity of 97% and sensitivity of 90% in recognition of cardiac injury (6). The role of medication therapy in cardiac

tamponade is limited. Karavelioğlu et al, according to the site of the lesion, right or left thoracotomy or median sternotomy may be preferred for surgical repair in patient with cardiac tamponade (7). In our case we choose median sternotomy like Karavelioglu et al.

CONCLUSION

Cardiac tamponade is a life-threatening situation and needs a high index of suspicion for diagnosis. Rapid diagnosis and urgent intervention can be life-saving. In case of transfer of a patient to senior center, coordination between centers may be one of the most important factor that effects to mortality and morbidity.

REFERENCES

1. Arıkan S, Yücel AF, Kocakuşak A, Dadük Y, Adaş G, Önal MA. Retrospective analysis of the patients with penetrating cardiac trauma. *Ulus Travma ve Acil Cerrahi Derg* 2003;9:124-8.
2. Mandal AK, Operah SS. Unusually low mortality of penetrating wounds of the chest. Twelve years experience. *J Thorac Cardiovasc Surg* 1989;97(1):119-25.
3. Akay T, Kalp ve Damar Yaralanmaları, *Toraks Cerrahisi Bülteni* 2010;1:75-86.
4. Degiannis E, Bowley DM, Westaby S. Penetrating cardiac injury. *Ann R Coll Surg Engl* 2005;87(1):61-3.
5. Dereli Y, Öncel M, Penetrating cardiac injury in blunt trauma: a case report, *Ulus Travma ve Acil Cerrahi Derg* 2015;21(3),228-30.
6. Mataracı İ, Polat A, Çevirme D, Büyükbayrak F, Şaşmazel A, Tuncer E, . Increasing numbers of penetrating cardiac trauma in a new center. *Ulus Travma Acil Cerrahi Derg* 2010;16(1):54-8.
7. Karavelioğlu Y, Ereren E, Erenler AK, Diken AI, Yalçınkaya A. Management of Cardiac Penetrating Injuries in a Hospital without Cardiopulmonary By-Pass Pump. *Koşuyolu Heart Journal* 2014;17(2):131-4.