



Case Report

Immediate Placement of Dental Implants in non Vascularised Iliac Graft after Resection of Anterior Mandible : A Case Report

Prajesh Dubey^{*}, Vishal Bansal, Gaurav Popli, and Sahil Kapoor

Subharti Dental College & Hospital, Subhartipuram, Meerut, U.P., India

Abstract:

This case report presents a combination of surgical and prosthetic rehabilitation applied to a case in postsurgical reconstructed mandible. We report a patient suffering from desmoplastic ameloblastoma of mandible, who underwent Enbloc resection and reconstruction with iliac bone graft with simultaneous placement of dental implant in anterior mandible. Two dental implants were placed at both ends of the graft. At five years follow up, favourable osseointegration with healthy peri-implant tissue was reported.

Keywords: Desmoplastic ameloblastoma; Implants; Non vascularized bone graft

Academic Editor: Xiaoning Peng, PhD, Hunan Normal University School of Medicine

Received: April 11, 2016 **Accepted:** May 17, 2016 **Published:** June 6, 2016

Competing Interests: The authors have declared that no competing interests exist.

Consent: We confirm that the patient has given the informed consent for the casereport to be published.

Copyright: 2016 Dubey P *et al.* This is an open-access article distributed under the terms of the Creative Commons Attribution License, which permits unrestricted use, distribution, and reproduction in any medium, provided the original author and source are credited.

***Correspondence to:** Prajesh Dubey, Subharti Dental College & Hospital, Subhartipuram, Meerut, U.P., India

Email: drprajeshdubey@gmail.com

Introduction

Successful reconstruction of the mandible for functional and cosmetic defects is challenging yet an essential component. Dental and lip support, cheek support and definition of the jaw line are the major influencing factors for successful esthetic correction. Mandibular continuity defects can be caused by various ailments such as trauma, neoplasm and infection. Neoplasm of epithelial origin such as Ameloblastoma etc. though slow growing, are locally invasive and highly destructive of the surrounding dental anatomy and capable of causing facial deformity. Due to the high recurrence rates and infiltrating nature of the lesions radicle resection (En-bloc, Segmental or Hemimandibulectomy) are often the treatment of choice [1]. These continuity defects often affect the function of mastication, speech, deglutition, protection of airway and esthetics making immediate reconstruction with vascularised or non – vascularised grafting a viable option, if possible.

High osteogenic potential of autogenous bone grafts makes them the “gold standard” and viable means for the reconstruction of these types of continuity defects. Iliac crest is less invasive, does not require special armamentarium than a free flap technique and stands out amongst all the autogenous bone grafts as it offers numerous advantages such as adequate volume, reliable shape, low donor site morbidity and a distinct location from mandible to facilitate multidisciplinary approach. It not only corrects the facial contour and esthetics, but also provides an adequate bone support for successful Osseointegration of dental implant and implants supported rehabilitation.

The purpose of this article is to report a clinical case of successful prosthetic rehabilitation with osseointegrated dental implants in a non-vascularized bone graft after En Bloc resection of mandible in a case of Desmoplasticaameloblastoma.

Case Report

A 29 year old female presented to our Department of Oral & Maxillofacial surgery, with an asymptomatic swelling of spontaneous origin in her lower jaw since four months. There had been gradual increase in the size of swelling to its present size hitherto. There was no significant medical or dental history. The extra oral examination revealed no obvious facial asymmetry. The intra oral examination disclosed a mass, approximately 2.5 x 2.0 cm in dimension, extending from the mesial of right mandibular canine to mesial of right mandibular second premolar. Bucco-lingual expansion of the alveolar process of mandible was apparent. The mucosa over the swelling was non ulcerative, non suppurative, and appeared normal in color (fig.1). On palpation, the swelling was non-tender, firm to hard in consistency, non-fluctuant, non-compressible and non-pulsatile. Electric pulp vitality testing showed that all the teeth in the vicinity were vital. No lymphadenopathies or sinus were present. Radiographic examination of the mandible revealed an area of increased haziness and altered trabecular pattern with respect to the mesial surface of right mandibular canine to the distal surface of the right mandibular first pre molar extending from the alveolar crest to preapical region. The pathology has resulted in divergence of the root of canine and first premolar of right mandibular region, without any signs of root resorption (fig.2). Computed tomography of the lesion showed a predominantly lytic, multiloculated lesion, with a size of 3 cm mediolaterally, 1.8 cm anteroposteriorly, and 2.5 cm superoinferiorly (fig.3). Aspiration of the lesion was non-productive and a complete Hemogram showed values within the normal range. An incisional biopsy was performed under local anaesthesia to establish a definitive diagnosis. Histologically, the features were consistent with those of Desmoplasticaameloblastoma. En bloc resection without continuity defect was performed with the safety margin of 15 mm under general anaesthesia (fig.4) with intraoral approach and reconstruction plate was applied to reinforce the mandible. Further a b cortical iliac bone graft was harvested and two implants of 3.75 mm diameter and 13.0 mm lengths (Adin) were placed at both ends of grafts simultaneously, keeping in mind the

principles of implants placement. The grafts were placed over the recipient area and secured with 8 mm screws (fig.5). The surgical specimen consists of a portion of mandible and the teeth involved in the tumor, was sent for radiographic and histopathological examination which matched with the incisional biopsy report (fig.6).The postoperative course was uneventful. After four months, implant were exposed and secondary stability of the implant was checked with periodontal probe and was confirmed using resonance frequency analysis, which was found to be within normal limits and gingival formers were placed followed by full prosthetic rehabilitation of the patient. The patient is kept on follow up and till date after five years there is no evidence of recurrence(fig.7,8).

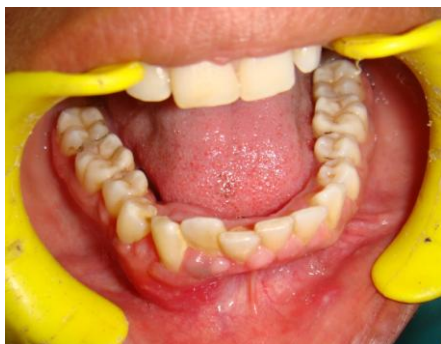

Figure 1(left) preoperative photograph

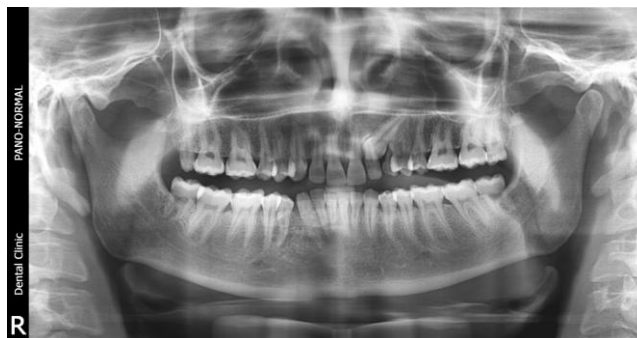

Figure 2(right) preoperative OPG

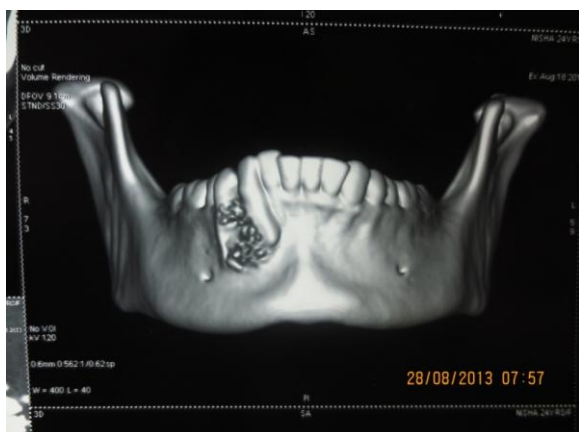

Figure 3(left) Preoperative CT scan

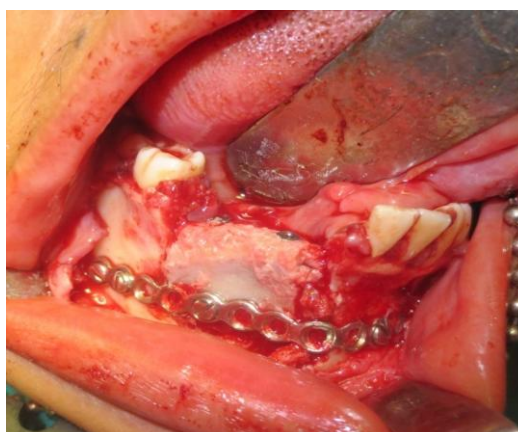


Figure 4(right) iliac crest graft with dental implant

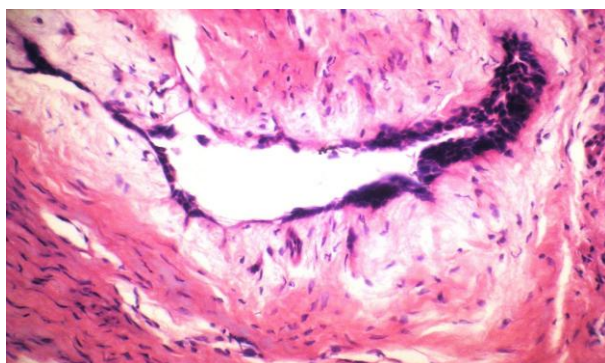


Figure 5(left) Histopathological Specimen

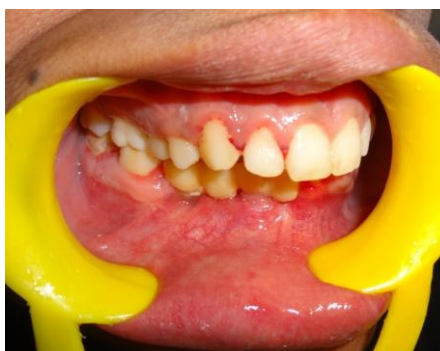

Figure 6(right) Prosthetic Rehabilitation

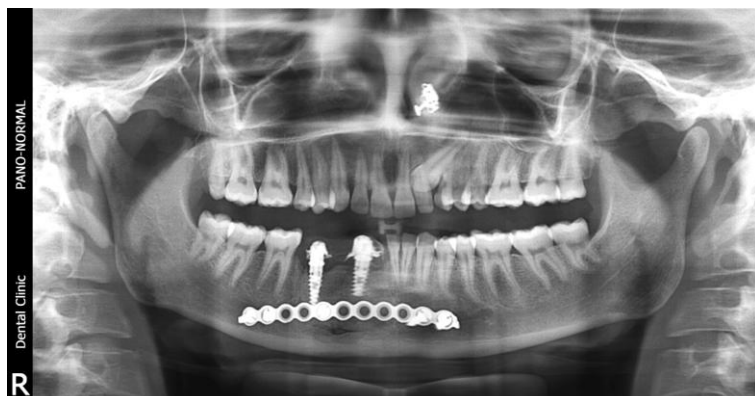

Figure 7 5 Years follow up OPG

Discussion

Reconstruction of the bony defect poses a challenge for maxillofacial surgeons because of complex structure of maxillofacial region and its anatomic relation. Several material have been introduced and tested as bone graft substitute but autogenously bone remains the gold standard for mandibular reconstruction. Autogenous bone has osteoinductive and osteoconductive properties and is immunologic safe. Various donor site for bone reconstruction in the body are ilium, rib, calvarium, tibia, maxilla and mandible. Cases with significant bone defects require a large volume of bone grafts, preferably from ilium or rib. The anterior iliac crest is the most frequently reported harvesting area, it is associated with low morbidity and can offer a large quantity of bone Arrington et al [2] 1996 reported 414 consecutive cases of iliac bone graft procedure and highlighted the major – 5% (herniation, vascular injuries, nerve injuries, deep infection, haematomas or iliac wing fractures) and major 10% (superficial infection, superficial seromas and minor haematomas) complication.

Iliac bone transplants have been widely used for mandibular reconstruction. The cortical bone of the iliac crest is thickest at the “intermediate line”, but all parts of the iliac crest are thick enough to accept dental implants. Contrarily, Rib grafts have not enough volume for the same purpose. After augmentation, iliac crest grafts can also resorb at a rate of 30-90% when a denture is placed over them [3,4]. Implants can help to minimize resorption to a rate similar to same quality of bone. Rehabilitation with a fixed dental prosthesis supported by osseointegrated implants was first described by Branemark et al [5] (1969) and has radically changed the possibilities for oral rehabilitation. Survival of the implants placed onto bone grafts is another crucial matter. According to the report of Keller et al [6], 60% to 70% of implants placed into onlay grafts survive. Implants in the presented case were placed in a 1-stage procedure. Experimental and some clinical data reveal that a 2-stage surgery may be advantageous and may have an acceptable survival rate. However Branemark et al [7] reported high success rates with use of onlay grafts in a 1 stage approach. Optimal timing for the placement of implants after bone grafting is currently controversial. However there is agreement as to the period of time necessary between grafts surgery and implant in the literature reviewed for this study, the period varied from 3 to 8 months depending on the type of reconstruction and grafts used [8,9]. The advocate of simultaneous augmentation and implant placement auto transplant resorption is significantly reduced, as well as the time requirement for prosthetic rehabilitation in a defect of up to 9cm. However, one of the major shortcoming is the impossibility to achieve the proper implant position and angulation from the prosthetic point of view [10-13]. Those who advocate delayed placement argue that simultaneous placement can bring about certain risk, such as wound dehiscence, grafts exposure, infection, partial or complete necrosis and the loss of the grafts [14-17]. Albrektsson et al [18] defined a five criteria for implant success. 1.No clinical mobility 2.No evidence of peri implant

radiolucency 3. vertical bone loss less than 0.2mm annually 4. Absence of persistent and /or irreversible signs and symptoms such as pain, infection, neuropathy, paraesthesia or violation of the mandibular canal. 5. thus, in the context of the 5 criteria above, a successful rate of 85% at the end of a five year observation period and an 80% rate at the end of a ten year period should be the minimum criteria for success. a stable implant which meet all five criteria is judged as successful. a stable implant not meeting one or several criteria is classified as a survival. Resorption of the non vascularized iliac bone grafts is an important consideration that must be carefully analysed in the treatment planning of bone reconstruction and dental implant placement. Though vascularized bone graft are the treatment of choice for mandibular replacement over 9cm in length but non vascularized bone grafts create a better contour and bone volume for facial esthetics and subsequent implant insertion and may be treatment of choice for secondary reconstruction of defect less than 9cm in length [19]. Spongy architecture and inherent quality of the cancellous bone to revascularize it earlier. around fifth day [20], could be a possible explanation for osseointegration in free vascularized bone graft. Osteocytes within their lacunae seems to survive if they are within 0.3mm of a perfusion surface [21]. Cellular survival in graft before revascularization depends on nutrition and elimination of waste product through plasmotic diffusion. Cortical bone graft remodelled by creeping substitution can produce area of necrotic bone. As a result of differing biology of cortical and cancellous bone, a cortical graft is strong initially but weakens overtime before regaining strength. There also may be a loss of dimension as a result of resorption process [22,23]. Cortical bone graft have been shown to be 40% to 50% weaker than normal bone from 6 week to 6 month after transplantation while cancellous bone graft tend to be weak initially because of their open architecture but continually gain in strength [20]. Dynamic loading and physiologic stress stimulation can prevent this resorptive process and increase bone mass. Other factors which influence the survival of the graft are host defense mechanism, recipient bed, size of the graft, preservation after harvesting, adequate bone contact with recipient bed, with or without continuity defect.

Conclusion

Early restoration of masticatory ability and aesthetic appearance is widely regarded as a therapeutic goal in patient who have severely resorbed alveolar crest, bone defects and congenital malformation. placement of single staged endo-osseous implants and use of bone grafts provides the patient, ability to regain self confidence and almost the same quality of as before. Though immediate placement of implant in non vascularized corticocancellous bone graft seems to be successful in this case report but long term study with large sample size is required to investigate the outcome.

Reference

1. Taylor G. Ameloblastoma. *CA Cancer J Clin.* 1968, 18:136-140
2. Arrington ED, Smith WJ, Chamber HG, Bucknell AL, Davino NA. Complication of iliac crest bone graft harvesting. *Clin Orthop.* 1996, 329:300-309
3. Sbordon L, Toti P, Menchini-Fabris GB, Sbordon C, Piombino P, Guidetti F. Volume changes of autogenous bone graft after alveolar ridge augmentation of atrophic maxillae and mandible. *Int J Oral Maxillofac Surg.* 2009, 38:1059-1065
4. Swart JG, Allard RH. Subperiosteal onlay augmentation of mandible: a clinical and radiographic survey. *J Oral Maxillofac Surg.* 1985, 43:183-187
5. Branemark PI, Adell R, Breine U, Hanson BO, Lindstrom J, Ohlsson A. Intraosseous anchorage of dental prosthesis. Experimental studies. *Scand J Plast Reconstr Surg.* 1969, 3(2):81-100

6. Keller, Eugene E., Tolman, Dan E., Eckert, Steven. Surgical-Prosthetic Reconstruction of Advanced Maxillary Bone Compromise with Autogenous Onlay Block Bone Grafts and Osseointegrated Endosseous Implants: A 12-Year Study of 32 Consecutive Patients. *International Journal of Oral & Maxillofacial Implants*. 1999, 14(2):197-209
7. Branemark PI, Adell R, Breine U, Hanson BO, Lindstrom J, Hallen O, Jeppson PH, Ohman A, Ohlsson A. Reconstruction of the defective mandible. *Scand J Plast Reconstr Surg*. 1975, 9:116-128
8. Misch CM, Misch CE, Resnik RR, Ismail YH. Reconstruction of maxillary alveolar defects with mandibular symphysis grafts for dental implants: a preliminary procedural report. *Int J Oral Maxillofac Surg*. 1992, 7:360-366
9. Misch CM, Misch CE. The repair of localized severe ridge defects for implant placement using mandibular bone grafts. *Implant Dent*. 1995, 4:261-267
10. Verhoeven JW, Cune MS, Terlouw M, Zoon MAOW, dePutter C. The combined use of endosteal implants and iliac crest onlay grafts in the severely atrophic mandible: a longitudinal study. *Int J Oral Maxillofac Surg*. 1997; 26(5): 351-357
11. Van SD, Naert I, Bossuyt M, et al. The rehabilitation of the severely resorbed maxilla by simultaneous placement of autogenous bone grafts and implants: A 10 year evaluation. *Clin Oral Investig*. 1997, 1: 102-108
12. Keller EE, Tolman DE, Eckert S. Surgical prosthetic reconstruction of advanced maxillary bone compromise with autogenous onlay block bone grafts and osseointegrated endosseous implants: a 12 year study of 32 consecutive patients. *Int J Oral Maxillofac Implants*. 1999, 14: 197-209
13. Lekholm U, Wannfors K, Isaksson S, Adellsson B. Oral implants in combination with bone grafts. A 3 year retrospective multicenter study using the Branemark implants system. *Int J Oral Maxillofac Surg*. 1999, 28:181-187
14. Lizuka T, Smolka W, Hallemann W, Merckse Stern R. Extensive augmentation of the alveolar ridge using autogenous calvarial split bone grafts for dental rehabilitation. *Clin Oral Implants Res*. 2004, 15: 607-615
15. Bahat O, Fontanessi RV. Efficacy of implant placement after bone grafting for three-dimensional reconstruction of the posterior jaw. *Int J Periodontics Restorative Dent*. 2001, 21: 221-231
16. Raghoobar GM, Schoen P, Meijer HJA, Stellingsma K, Vissink A. Early loading of endosseous implants in the augmented maxilla: a 1 year postoperative study. *Clin Oral Implants Res*. 2003, 14: 697-702.
17. Levin L, Nitzan D, Schwartz-Arad D. Success of dental implants placed in intraoral block bone grafts. *J Periodontol*. 2007, 78: 18-21
18. Albrektsson T, Zarb G, Worthington P, Eriksson AR. The Long Term Efficacy of Currently Used Dental Implants: A Review and Proposed Criteria of Success. JOMI on CD-ROM, 1986 Jan (11-25)
19. Pogrel MA, Podlesh S, Anthony JP, Alexander JP. A comparison of vascularized and non vascularized bone grafts for reconstruction of mandibular continuity defects. *J Oral Maxillofac Surg*. 1997, 55(11):1200-1206
20. Wilk RM. Bony reconstruction of the jaws. In: Miliro M, editor. Peterson's principles of oral & maxillofacial surgery. 2nd edition. *Hamilton (London): B C Decker*. 200, 785-787
21. Heslop BK, Zeiss IM, Nisbet NW. Studies on transference of bone: a comparison of autologous and homologous transplants with reference to osteocyte survival osteogenesis and host reaction. *Br J Exp Pathol*. 1960, 41:269-272
22. Oxlund H, Anderson NB, Ortoft G, et al. Growth hormone and mild exercise in combination markedly enhances cortical bone formation and strength in old rats. *Endocrinology*. 1998, 139(4):1899-1904
23. Duncan RL, Turner CH. Mechanotransduction and the functional of the bone to mechanical strain. *Calcif Tissue Int*. 1995, 57(5):344-358