



Conservative Treatment of A Follicular Ameloblastoma Of The Anterior Mandible: A Case Report

Narjiss Akerzoul^{1*}, Saliha Chbicheb²

¹Oral surgery Fellow, Department Of Oral Surgery, C.C.D.T, University Mohamed V, Rabat, Morocco

² Professor, Department Of Oral Surgery, C.C.D.T, University Mohamed V, Rabat, Morocco

Abstract

Introduction: Ameloblastoma is a tumor of odontogenic epithelium arising from remnants of dental lamina. It is a benign tumor but locally invasive affecting mandible more than maxilla.

Presentation of the case: A 36-year-old male patient reported with a swelling on the anterior mandibular area and extended to the right side of mandible. Orthopantomogram revealed a unilocular radiolucency extending from mesial side of tooth 34 to mesial side of 45. CT Scan showed the extension of the lesion in the mesio-distal axis. It also revealed the buccal cortical expansion and the preservation of the internal bone cortical. Enucleation conservative treatment was then performed under local anesthesia with extraction of the 43. The pathology report concluded a Follicular Unicystic Ameloblastoma. The patient was then followed up over a period of one year and showed a notable reduction of the size of the lesion with no signs of recurrence.

Conclusions: Conservative treatment is highly recommended in unicystic follicular patterns of ameloblastoma rather than radical treatment.

Keywords: Anterior Ameloblastoma; Conservative Treatment; Benign Tumor; Mandibular Ameloblastoma; Follicular Ameloblastoma

Received: August 11, 2018; **Accepted:** September 30, 2018; **Published:** October *, 2018

Competing Interests: The authors have declared that no competing interests exist.

Copyright: 2018 Akerzoul N *et al.* This is an open-access article distributed under the terms of the Creative Commons Attribution License, which permits unrestricted use, distribution, and reproduction in any medium, provided the original author and source are credited.

*Correspondence to: Narjiss Akerzoul, Oral surgery Fellow, Department Of Oral Surgery, University Mohamed V, Rabat, Morocco

Introduction

Ameloblastoma was firstly described by Cusack in 1827. It is the most common benign odontogenic tumor and represents 13–54% of all benign and malignant tumours of the jaw. There is no distinct gender predilection and most cases are diagnosed in the third to fifth decades of life. While rare in children younger than age 10 years, it is relatively uncommon in the 10 to 19 year old group [1].

Ameloblastoma accounts for about 1% of all oral tumors and about 9-11% of odontogenic tumors. It is a benign tumor but locally aggressive. There is a slight male preponderance and majority of ameloblastomas occur in mandibular ramus region. Although ameloblastomas are primarily intraosseous tumors, they have been occasionally reported in soft tissues. They are classified into unicystic, multicystic (solid), peripheral and desmoplastic types. Ameloblastoma in the anterior mandible area are rare, and can progress to large size and cause facial asymmetry, displacement of teeth, malocclusion, and pathologic fractures. The aim of this paper is to report a rare case of an anterior mandibular follicular ameloblastoma and to describe its surgical management.

Case Report

A 36-year-old male patient reported with a complaint of swelling on the right side of jaw since 1 year. Initially, the swelling was small in size which gradually increased in size. It was a little bit painful but without any pus discharge. Patient had no relevant family history and had no habit of smoking.

On extra-oral examination, the swelling was noted on the anterior mandibular area and extended to the right side of mandible (to the mandibular right premolars).

On intraoral examination, buccal cortical expansion was visible from tooth 34 to 45 region while the lingual cortical preserved (Figure 1). The tooth 44 was absent. The color of the overlying mucosa was normal. The lesion was firm in consistency and tender on palpation. Based on all these findings, many provisional diagnosis were made such as odontogenic adenomatoid tumor, a keratocyst or an ameloblastoma.

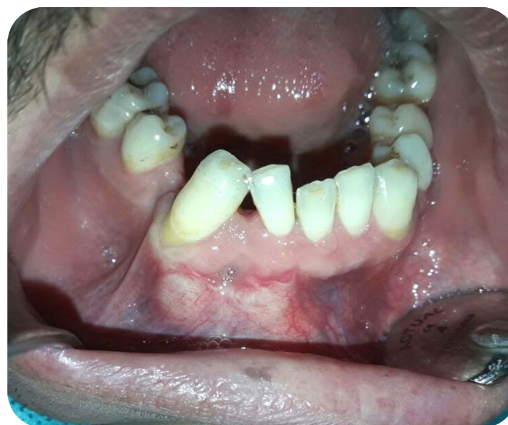
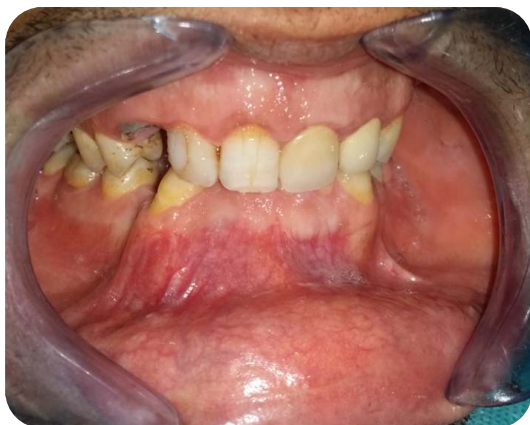
Fig 1 (A)

Fig 1 (B)

Fig 1 (A+B) Intra-oral examination showing the buccal swelling extended from 33 to 45

The patient was subjected to routine radiographic examination. Orthopantomogram revealed a unilocular radiolucency measuring about 4.0×3.0 cm in size extending from mesial side of tooth 34 to mesial side of 45

(Figure 2 A). CT Scan was then performed and showed the extension of the lesion in the mesio-distal axis from the mesial side of 34 to mesial side of 45. It also revealed the buccal cortical expansion and the preservation of the internal bone cortical (Lingual) (Figure 2 B).

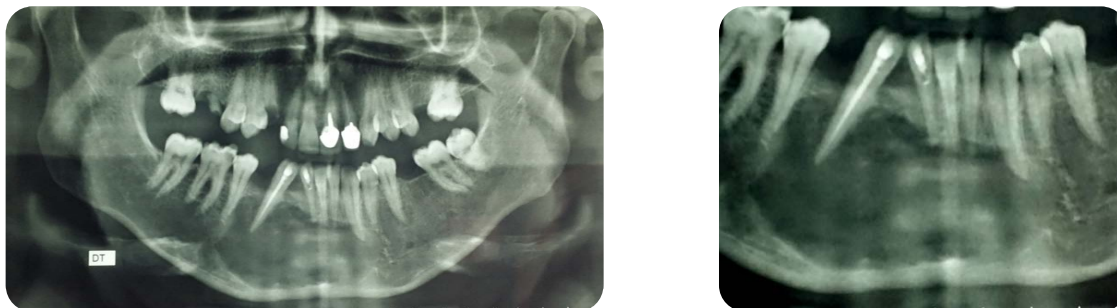

Figure 2 (A) Orthopantomogram showing the extension of the unilocular radiolucent lesion from 34 to 45

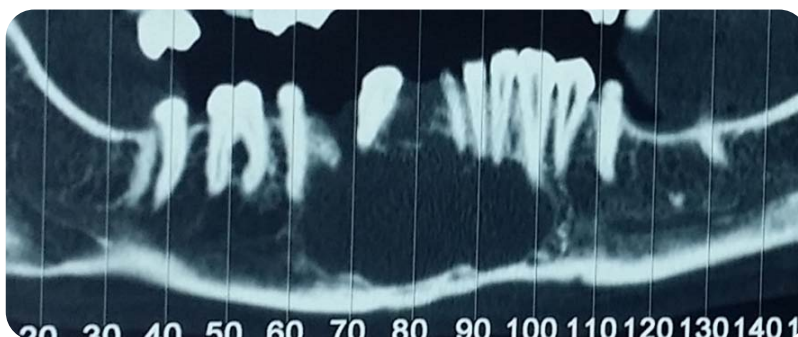


Figure 2 (B) CT Scan showing the extension of the lesion in the Mesio-Distal axis and also revealing the preservation of the lingual cortical

A buccal flap was raised in order to expose the lesion (Figure 3). Then enucleation conservative treatment was then performed under local anesthesia with extraction of the 43 (Figure 4). Hermetic post-operative sutures were performed after the surgery (Figure 5). The lesion specimen was then sent for histopathological analysis. The pathology report showed follicular cells and concluded a Follicular Unicystic Ameloblastoma (Figure 6). The patient was then followed up over a period of one year with no pain or discomfort noted and no signs of recurrence (Figure 7).

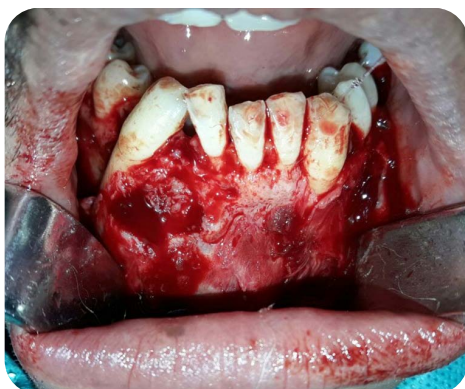

Figure 3 Intra-Oral View after raising the buccal flap with the lesion exposure and its emergence in the buccal cortical

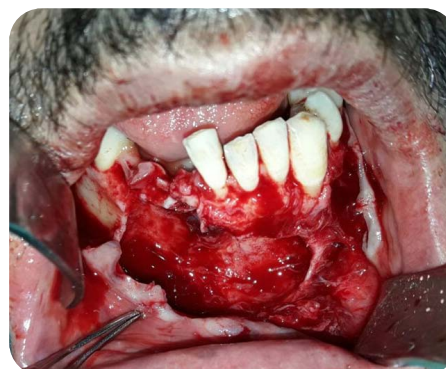

Figure 4 Intra-Oral View showing the lesion's cavity after complete enucleation and extraction of the 43

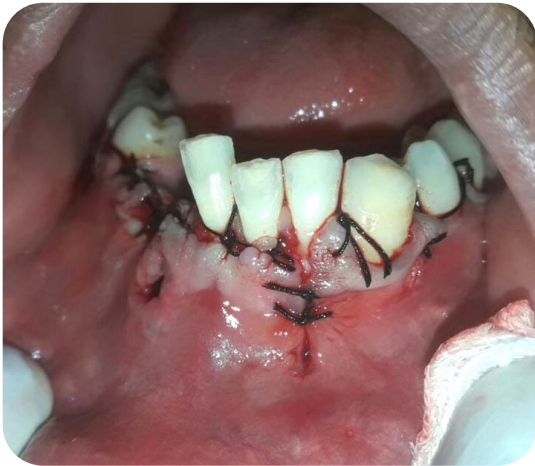

Figure 5 Post-operative sutures

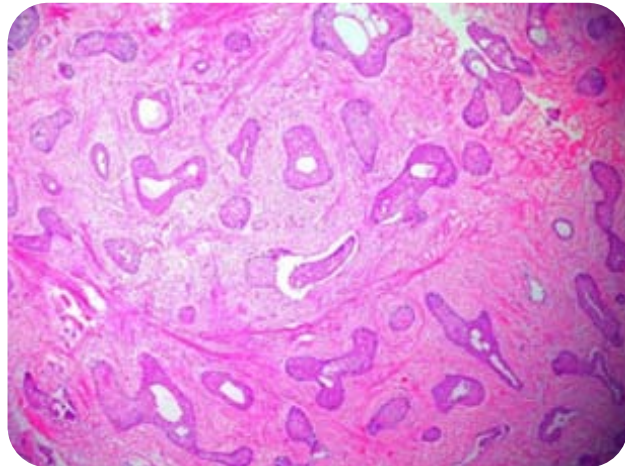


Figure 6 Histological image showing the follicular variant of ameloblastoma

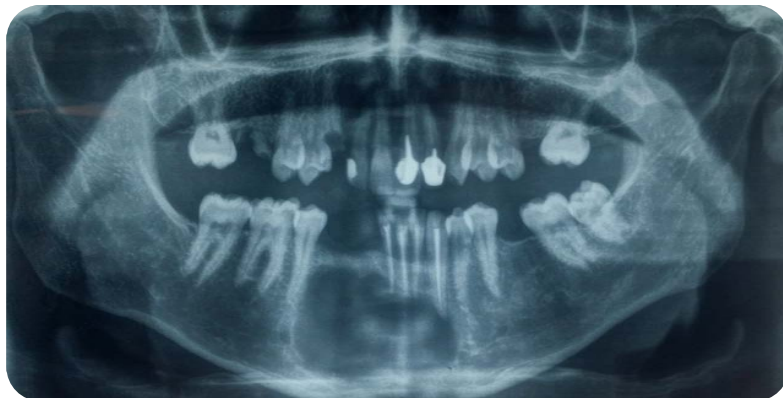

Figure 7 Follow-Up after one Month

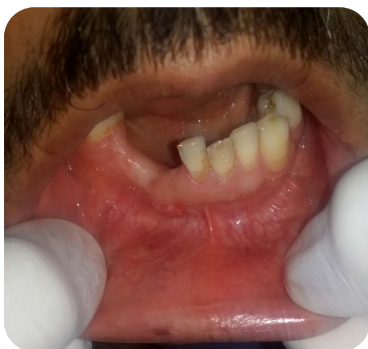

Figure 8 (A)

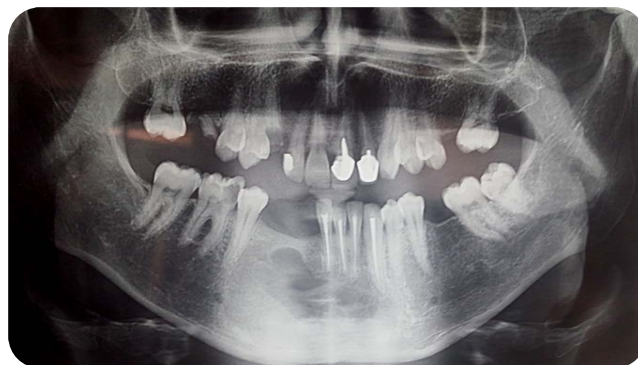

Figure 8 (B)

Figure 8 (A+B) One year follow-up: Clinical and radiological Complete healing with no sign of recurrence

Discussion

Ameloblastoma is a benign tumor of odontogenic epithelium principally of enamel organ-type tissue. The term ameloblastoma was coined by Ivey and Churchill. Ameloblastoma is the most common benign odontogenic tumor and represents 13–54% of all benign and malignant tumours of the jaw. The World Health Organization (WHO) defined ameloblastoma as a locally-invasive polymorphic neoplasia that often has a follicular or plexiform pattern in a fibrous stroma. Its behaviour has been described as being benign, but locally aggressive [1]. Ameloblastomas account for 1% of benign tumors and cysts of the jaw. Incidence is estimated to be 0.5 cases per million person-years worldwide [2]. The study by Eversole et al, showed that ameloblastomas were classified according to the histological findings into follicular, plexiform, acanthomatous, granular cell, basal cell, squamous metaplastic, and other rare types [3, 4, 5]. Ameloblastomas are also classified into unicystic, multicystic, peripheral and desmoplastic types. Robinson on reviewing 293 cases reported site incidence of 83.7% in the mandible and 16.3% in the maxilla. 6 Multicystic/solid is the most common form of ameloblastoma. They can present with huge swellings over the jaws which can result in disturbances in facial aesthetics and function, such as difficulty with mouth opening, swallowing, chewing, breathing, neurologic deficits, and pathologic fractures. Up to 80 % of ameloblastoma cases occur in the mandible, with a predilection for the posterior mandibular region [6,7].

Radiographically solid/multicystic ameloblastoma show an expansile, radiolucent, multiloculated cystic lesion, with a characteristic “soap bubble-like” appearance. We can also find a unilocular radiolucent lesion, which was the case of our patient who presented an extensive unilocular radiolucent lesion in the anterior area of the mandible. Other findings include cystic areas of low attenuation with scattered regions representing soft tissue components. There can be thinning and expansion of the cortical plate with erosion with the displacement and resorption of adjacent teeth [8]. In our case, we observed only external bony infiltration, while the internal cortical was preserved. The bony infiltration could be correlated with various factors secreted by the ameloblast cells. Abdel sayed et al., [9,10] found an increased expression of the parathyroid hormone-related protein (PTHrP) in ameloblastoma and suggested that it has a role in local bone resorption and also provided an explanation for infiltrative growth and destructive behavior of ameloblastoma. Also, other authors found that the RANKL, tumor necrosis factor- α secreted by ameloblast cells could induce the osteoclastogenesis, which in turn provide space for it to expand [11, 12, 13].

There are several histopathological subtypes-follicular, plexiform, acanthomatous, desmoplastic, granular cell, and basal cell pattern, that may exist singly or as a combination of two or more types [12]. Follicular and plexiform are the commonly encountered variants accounting for 32.5% and 28.2% respectively; followed by the acanthomatous subtype 12.1% while desmoplastic is extremely uncommon with incidence rates ranging from 4-13%. Follicular ameloblastoma consists of discrete follicles with similarity to the stellate reticulum of enamel organ and with the varying quantity of tissue stroma. Because the follicular subtype is the most common variant, some pathologists believe that the acanthomatous, granular cell, basal cell, and desmoplastic variants are subsets of the follicular ameloblastoma [14].

Surgery is the standard treatment for ameloblastomas. Historically, the extent of resection has been controversial, comprising of two surgical options: « “conservative” vs. “radical ». The former involves enucleation/curettage of the bony cavity, while the latter involves a radical operation with appropriate margins. Advantages of enucleation include the fact that it is an outpatient procedure able to be performed by many different service providers (Oral Surgeons and ENT), since it requires no reconstruction. Historical data on simple enucleation demonstrates recurrence rates 60–90 %. However, this treatment modality is currently

believed to play no role in the management of multicystic ameloblastomas, but has excellent prognosis for the unicystic follicular ameloblastoma as is in our clinical case. The “radical” surgical option is the current standard of care for multicystic ameloblastoma and includes en bloc resection with 1–2 cm bone margins and immediate bone reconstruction to help with speech and swallowing. The bony margin is defined as the distance away from the radiographic margin predicted to be disease free and oncologically safe to perform osteotomies [15, 16]. Data from 82 ameloblastoma specimens showed microscopic tumor extension 2–8 mm (mean of 4.5 mm) beyond the radiographic boundaries of the tumor. Hence recommended bone margins are 1–1.5 cm for unicystic and 1.5–2 cm for solid/multicystic histological types, and provides increased cure rates [17,18].

Conclusion

Ameloblastoma is a benign, but locally invasive odontogenic tumor with a high rate of recurrence. Treatment decisions for ameloblastoma are based on the individual patient situation and the judgment of the Oral surgeon. Resection with some safe margin is the best primary method for treating solid/multicystic ameloblastomas to avoid recurrence, but conservative treatment (enucleation) is highly recommended in unicystic follicular patterns rather than radical treatment.

References

1. Pogrel MA, Podlesh S, Anthony JP, et al. A comparison of vascularised and nonvascularised bone grafts for reconstruction of mandibular continuity defects. *J Oral Maxillofac Surg.* 1997, 55:1200-1206
2. Harvey P. Kessler. Intraosseous Ameloblastoma. *Oral Maxillofacial Surg Clin N Am.* 2004, 16; 309-322
3. Anuradha.V, Kumaran Satish, Vidya K C, Pandit Nikhil. Follicular ameloblastoma – a case report. *Journal of Dental Sciences & Oral Rehabilitation.* 2011, 300-312
4. Reichart PA, Philipsen HP, Reichart PA, PhilipsenHP (Editors). Early normal Odontogenesis with special reference to the development and fate of the dental laminae. Odontogenic tumors and allied lesions. London: Quintessence Publishing Corporation Limited. 2004:25-32
5. Philipsen HP, Reichart P, Slootweg PJ, Slater LJ, BarnesL, Eveson JW, Reichart P, Sidransky D (Editors). Neoplasms and tumor-like lesions arising from the odontogenic apparatus and maxillofacial skeleton: Introduction. Pathology and genetics of head and neck tumors. Lyon, France: *IARC Press.* 2005, 285-286
6. Robinson et al. Differential Diagnosis of Oral and Maxillofacial Lesions. 5th ed. Missouri: Mos by *Elsevier.* 2014, 6:337-340
7. White SC, Pharoah MJ, editors. 5th ed. New Delhi: Mosby-Elsevier; 2005. *Oral Radiology: Principles and Interpretation.* 2015, 2:419-22 8
8. Reichart PA, Philipsen HP, Sonner S. Ameloblastoma: biological profile of 3677 cases. *Eur J Cancer B Oral Oncol.* 1995, 31B(2):86-99
9. Leider AS, Eversole LR, Barkin ME. Cystic ameloblastoma. A clinicopathologic analysis. *OralSurg Oral Med Oral Pathol.* 1985, 60:624-630
10. Gümğüm S, Hoğören B. Clinical and radiologic behaviour of ameloblastoma in 4 cases. *J Can Dent Assoc.* 2015, 71:481-484
11. N. Akerzoul N, S. Chbicheb, W. Elwady. The Role of Free Fibula Flap in the Reconstruction of a Mandibular Ameloblastoma: A Case Report. *American Journal of Oral and Maxillofacial Surgery.* 2017, 4:5-13

12. Gardner DG. A pathologist's approach to the treatment of ameloblastoma. *J Oral Maxillofac Surg.* 1984, 3:161-166
13. Ghara A, Darwich K, Li L, et al. Long-term results of jaw reconstruction with microsurgical fibula grafts and dental implants. *J Oral Maxillofac Surg.* 2015, 65:1005
14. Neville BW, Damm DD, Allen CM, Bouquot JE. Oral and maxillofacial pathology. 2nd edition. *Philadelphia: WB Saunders*; 2012, 4:611-619
15. Gardner DG. Some current concepts on the pathology of ameloblastomas. *Oral Surg Oral Med Oral Pathol Oral Radiol Endo.* 1996, 6:660-669
16. Hong J, Yun PY, Chung IH, Myoung H, Suh JD, Seo BM, Lee JH, Cheung PH. Longterm follow up on recurrence of 305 ameloblastoma cases. *Int J Oral MaxillofacSurg.* 2017, 36:283-288
17. Robinson L, Martinez MG. Unicysticameloblastoma: a prognostically distinct entity. *Cancer* 1977, 40:2278-2285
18. Gomes CC, Duarte AP, Diniz MG, Gomez RS. Current concepts of ameloblastoma pathogenesis and treatment modalities. *J Oral Pathol Med.* 2018, 39:585-591