



## Case Report

# Hypofibrinogenemia Presenting as Intracranial Hemorrhage

Sreenivasa Rao Sudulagunta<sup>1\*</sup>, Shiva Kumar Bangalore Raja<sup>2</sup>, Mahesh Babu Sodalagunta<sup>3</sup>, Hadi Khorram<sup>4</sup>, Zahra Noroozpour<sup>4</sup>

<sup>1</sup> Department of General Medicine, Ambedkar medical College, India

<sup>2</sup> Department of Medicine, Dr. B R Ambedkar medical College, India

<sup>3</sup> Department of General Medicine, Nitte Meenakshi University, Karnataka, India

<sup>4</sup> Department of Otolaryngology, Nitte Meenakshi University, Karnataka, India

## Abstract

**Introduction:** Factor I deficiency or fibrinogen deficiency, is a rare inherited bleeding disorder related to fibrinogen function in the blood coagulation cascade. They are classified into afibrinogenemia, hypofibrinogenemia and dysfibrinogenemia. Afibrinogenemia is defined as a lack of fibrinogen in the blood, i.e. <20 mg/dl of plasma with a frequency between 0.5 and 2 per million. Hypofibrinogenemia is partial deficiency of fibrinogen with levels of 20–80 mg/dl of plasma. Estimated frequency varies from 0.5 to 3 per million.

**Case Report:** We report regarding a 46 year old female patient, who presented with complaints of severe headache and right sided weakness. Examination revealed right Hemiplegia with BP of 144/90 mm Hg. Investigations revealed Creatine Kinase: 470IU/L, normal Blood counts, ESR and CRP. Thyroid profile was normal. Fibrinogen levels were 17.9mg/dl and repeat test after 1 week showed 24.6mg/dl. ECG showed incomplete left bundle branch block. Echocardiography was normal.

**Conclusion:** Hypofibrinogenemia rarely manifests as intracranial hemorrhage but, commonly presents with oral, mucosal and gastro intestinal tract bleeding. Patients admitted with stroke should be evaluated for fibrinogen deficiency and more emphasis to be laid in case of intracranial hemorrhage and previous history of bleeding.

**Keywords:** Hypofibrinogenemia; Intracranial hemorrhage; left bundle block

**Academic Editor:** Xiaoning Peng, Hunan Normal University School of Medicine, China

**Received:** May 20, 2015; **Accepted:** July 8, 2015; **Published:** August 4, 2015

**Competing Interests:** The authors have declared that no competing interests exist.

**Consent:** We confirm that the patient has given the informed consent for the case report to be published.

**Copyright:** 2015 Sudulagunta SR *et al.* This is an open-access article distributed under the terms of the Creative Commons Attribution License, which permits unrestricted use, distribution, and reproduction in any medium, provided the original author and source are credited.

**\*Correspondence to:** Sreenivasa Rao Sudulagunta, Department of General Medicine, Ambedkar medical College, India

**Email:** [dr.sreenivas@live.in](mailto:dr.sreenivas@live.in)

## Introduction

Factor I deficiency is a rare inherited bleeding disorder related to fibrinogen function in the coagulation cascade [1]. It is classified into three distinct disorders: afibrinogenemia, hypofibrinogenemia and dysfibrinogenemia [2]. Afibrinogenemia is defined as a lack of fibrinogen in the blood with <20 mg/deciliter of plasma with estimated frequency between 0.5 and 2 per million [2]. Hypofibrinogenemia is defined as a partial deficiency of fibrinogen, clinically 20–80 mg/deciliter of plasma. Estimated frequency varies from <0.5 to 3 per million [2,3].

Among all the reported cases of fibrinogen disorders in registry, afibrinogenemia accounted for 24% of cases, hypofibrinogenemia accounted for 38%, and dysfibrinogenemia accounted for 38% [4]. These disorders follow autosomal dominant or autosomal recessive inheritance affecting both males and females. Dysfibrinogenemia and thrombosis may be overrepresented in women due to risk of thrombosis associated with pregnancy and the postpartum period.

## Case report

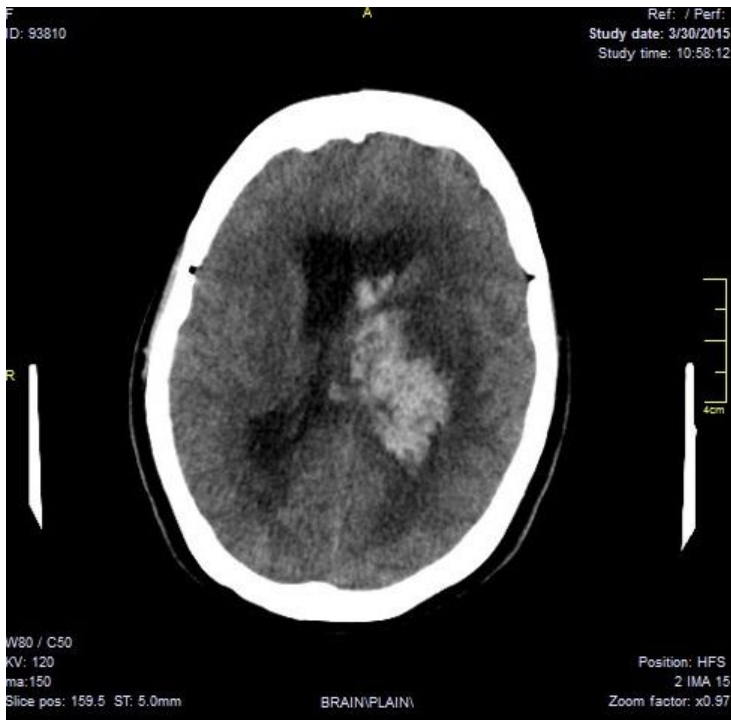
A 46 year-old woman was brought to Emergency room with sudden loss of consciousness, left sided weakness of body and history of headache. As GCS was 5/15 patient was intubated and mechanically ventilated in Intensive care unit. History from husband revealed headache, epistaxis, cough with expectoration and shortness of breath from 4 days for which she was admitted in local clinic. No history of diabetes, hypertension or ischemic heart disease was obtained.

As the condition of the patient deteriorated, she was referred from that clinic. Relatives denied illegal drug use. Her physical examination showed BP of 140/90mm hg, cyanosis, increased respiratory (30/min) and heart (120/min) rates. Babinski's reflex was elicited on right side. Chest Radiography showed alveolointerstitial infiltrate in right basal area. Computerized tomography of Brain revealed intracranial hemorrhage in the left cerebral hemisphere extending into ventricles (Figures 1, 2, 3 and 4). Investigations revealed total white blood cell count of 12,100 /mm<sup>3</sup> (Neutrophils 24%, Lymphocytes 70%, Eosinophils 3%, monocytes 3%) ESR 52mm/hr), Hemoglobin of 10mg/dl and platelet count was 179,000. The arterial blood gases had pH of 7.38, a PO<sub>2</sub> of 65 mmHg, PCO<sub>2</sub> of 35.5mmHg and 17.9 mmol/l of bicarbonate. Renal function test was normal with Creatinine of 1.4mg/dl and Blood urea of 30mg/dl. Liver function test was normal. Echocardiography was normal.

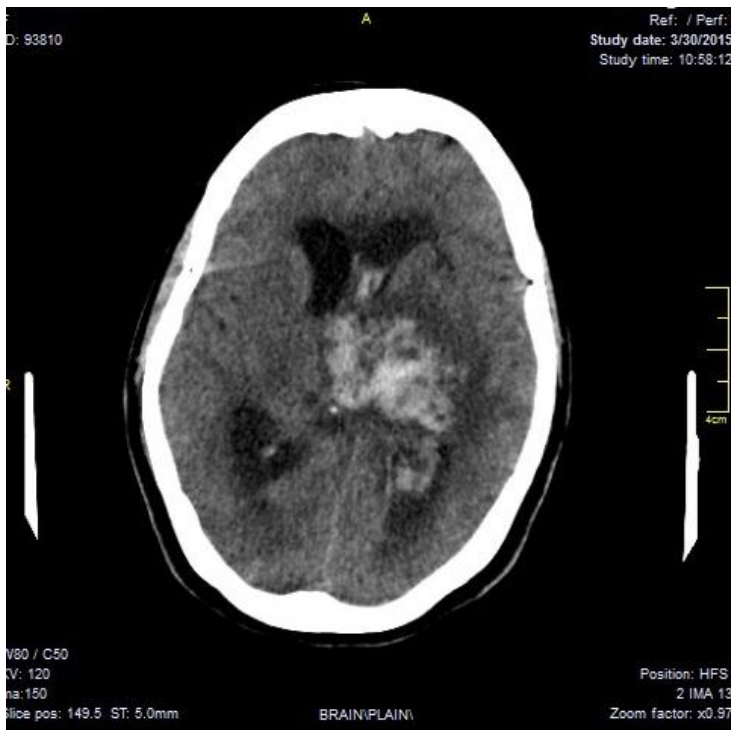
Patient did not have history of Comorbid conditions and history of recurrent mucosal bleeding in form of epistaxis and menorrhagia was present. Patient had history of 3 times abortion in 4<sup>th</sup>, 6<sup>th</sup> and 8<sup>th</sup> months of pregnancy. Investigations showed fibrinogen level of 17.9mg/dl, Factor VIII 120.2%, PT > 2 minutes, APTT > 3 minutes, TT 33.8 sec. History from relatives revealed that her father had similar bleeding episodes and death due to intracranial hemorrhage.

Patient was given fibrinogen concentrate to maintain level more than 0.8g/l. Fibrinogen concentrate is available as a powder to be dissolved in 50 ml of water and be given as a slow IV injection. The advantages of fibrinogen concentrate over cryoprecipitate are that it has less viral transmission, less immunogenic, lesser thromboembolism events [5]. Condition of patient improved over a period of 3 days

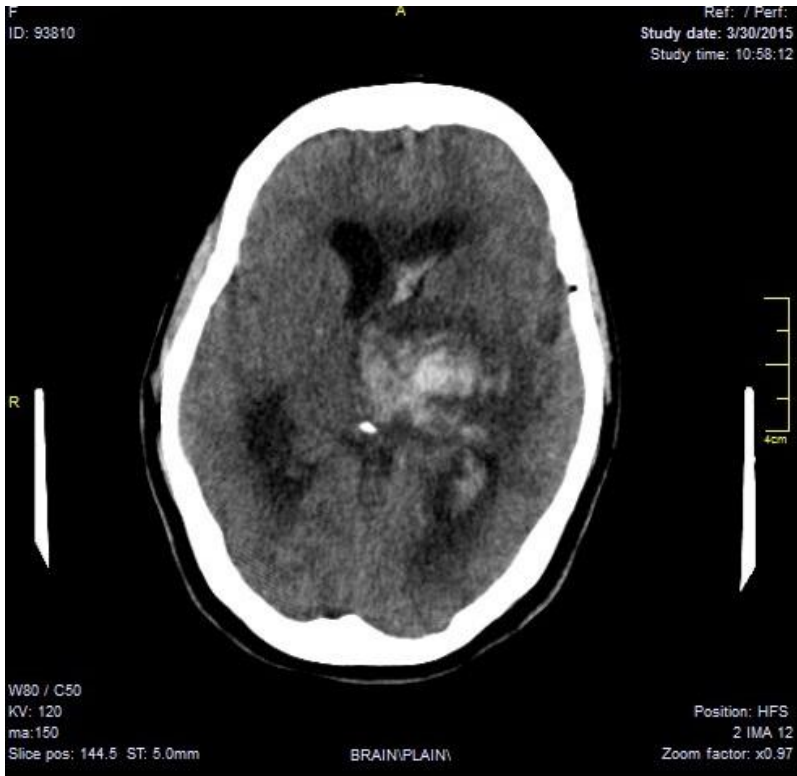
with no requirement of mechanical ventilation. Patient was shifted to medical ward after a period of 7 days. Patient was advised physiotherapy and monitoring of fibrinogen levels.



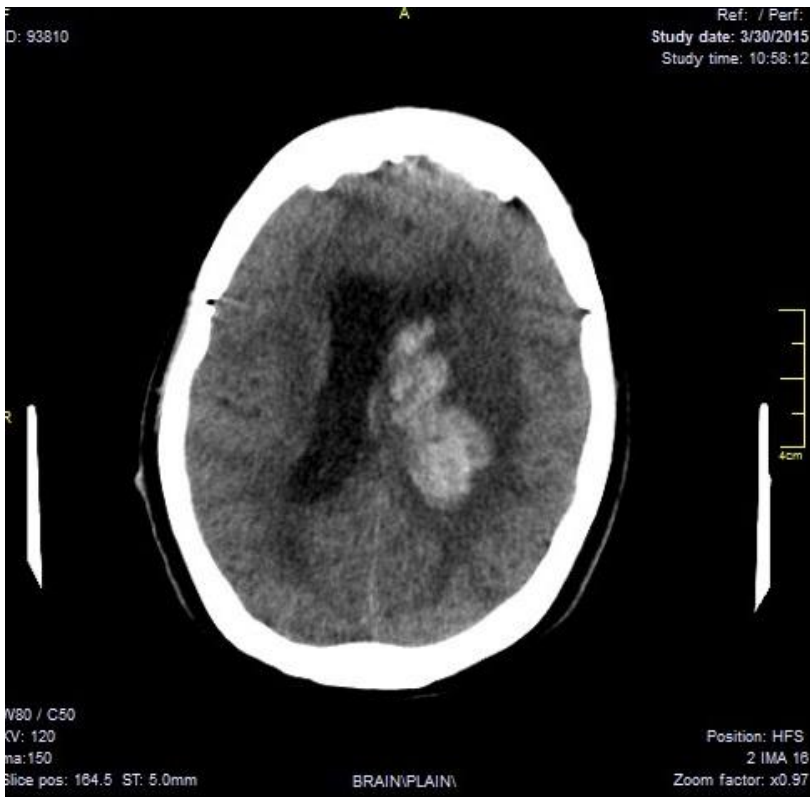
**Figure 1** Intracranial hemorrhage in the left cerebral hemisphere extending into ventricles



**Figure 2** CT Brain showing Intracranial hemorrhage extending from right to left ventricles



**Figure 3** Intracranial hemorrhage causing midline shift



**Figure 4** CT Brain showing intracranial hemorrhage in parenchyma and meningeal spaces

## Discussion

Fibrinogen is a 340-kD glycoprotein that is synthesized in the liver and circulates in plasma at a concentration of 2-4 g/L, with a half-life of 4 days [6]. A hexamer, consisting of 3 paired polypeptide chains: A- $\alpha$ , B- $\beta$ , and  $\gamma$ ; A and B refer to specific polypeptides on 2 of the chains. Synthesis of the protein in hepatocytes is under the control of 3 genes FGA, FGB, FGG located within 50 kilobases (kb) on chromosome 4. It maintains haemostatic balance as a substrate for clot formation, binds to platelet to support aggregation, has role in wound healing and Fibrin clot is a template for both thrombin binding and fibrinolytic system [7]. Dose (g) = desired increment in g/L x plasma volume (plasma volume is 0.07 x (1-hematocrit) x weight (kg). patient's personal and family history of bleeding and thrombosis should be taken into consideration for appropriate dosing of replacement therapy.

In patients with hypofibrinogenemia, bleeding episodes are usually mild and may occur following trauma or surgery [8, 9]. Our patient presenting with intracranial hemorrhage is rarely reported. Cryoprecipitate has been used as a source of fibrinogen; each bag contains 100-250 mg of fibrinogen. The guidelines for dysfibrinogenemia are not standardized due to a lack of sufficient data.

## Conclusion

Hypofibrinogenemia is a rare disease occurring almost 1 in 1 million. Fibrinogen replacement therapy is effective in preventing hemorrhage along with continuous monitoring of fibrinogen levels. Patients admitted with stroke should be evaluated for fibrinogen deficiency and more emphasis to be laid in case of intracranial hemorrhage and previous history of bleeding.

## Consent

Written informed consent was obtained from the patient for publication of this case report and accompanying images.

## References

1. Bolton-Maggs PH, Perry DJ, Chalmers EA, et al. The rare coagulation disorders--review with guidelines for management from the United Kingdom Haemophilia Centre Doctors' Organisation. *Haemophilia*. 2004, 10(5):593-628
2. <http://www.wfh.org/en/page.aspx?pid=659>
3. Vinod V Balasa, MD, <http://emedicine.medscape.com/article/960677-overview#a0199>
4. Acharya SS, Coughlin A, Dimichele DM,. Rare Bleeding Disorder Registry: deficiencies of factors II, V, VII, X, XIII, fibrinogen and dysfibrinogenemias. *J Thromb Haemost*. 2004, 2(2):248-256
5. Elliott BM, Aledort LM. Restoring hemostasis: fibrinogen concentrate versus Cryoprecipitate. *Expert Rev Hematol*. 2013, 6:277-286
6. Collen D, Tytgat GN, Claeys H, Piessens R. Metabolism and distribution of fibrinogen. I. Fibrinogen turnover in physiological conditions in humans. *Br J Haematol*. 1972, 22:681-700
7. Caroline Berube. Disorders of fibrinogen. Up to date Apr 2014

8. Peyvandi F, Haertel S, Knaub S, Mannucci PM. Incidence of bleeding symptoms in 100 patients with inherited afibrinogenemia or hypofibrinogenemia. *J Thromb Haemost.* 2006, 4(7):1634-1637
9. Acharya SS, Dimichele DM. Rare inherited disorders of fibrinogen. *Haemophilia.* 2008, 14(6):1151-1158