



Case Report

Pazopanib-Induced Heart Failure in a Metastatic Sarcoma Patient: between Reversible Side Effect and Efficacy

Valeria Lucarini¹, Stefano Madrigali¹, Roberta Lugli², Michela Maur¹, Federica Bertolini¹, Annalisa Fontana¹, Cristina Masini³, Valentina Guarneri⁴, Pierfranco Conte⁴, Massimo Dominici^{1*}

¹ Division of Oncology, Department of Medical and Surgical Sciences for Children & Adults, University Hospital of Modena and Reggio Emilia, Italy

² Division of Cardiology, Department of Medical and Surgical Sciences for Children & Adults, University Hospital of Modena and Reggio Emilia, Italy

³ Division of Oncology, Arcispedale Santa Maria Nuova IRCCS, Reggio Emilia, Italy

⁴ Department of Surgery, Oncology and Gastroenterology, Istituto Oncologico Veneto IRCCS, University of Padova, Padova, Italy

Abstract

Introduction: Pazopanib, a multi-target tyrosine-kinase inhibitor (TKI), is a relatively novel anticancer agent registered for advanced renal cell carcinoma recently emerged in the setting of advanced soft-tissue sarcoma (STS). In the early clinical trials pazopanib has been very marginally linked to left ventricular ejection fraction (LVEF) dysfunction as, on contrary, reported for other anti-angiogenesis TKIs, such as Sunitinib and Sorafenib.

Presentation of Case: We here present a case of severe, but reversible, congestive cardiac failure in a 37-year old Caucasian man affected by soft-tissue sarcoma during an efficacious treatment with pazopanib.

Conclusion: Cardiac damage from novel TKI treatments is still an underestimated phenomenon. In our patient, pazopanib was the only treatment ensuring stability of disease and its discontinuation meant disease progression. Post-approval monitoring of novel TKIs should be taken into account by clinicians including a careful monitoring of LVEF and all symptoms suggestive of cardiac dysfunction, in particular for drugs potentially capable to change the natural history of still incurable cancer.

Keywords: pazopanib; heart failure; sarcoma

Academic Editor: Xiaoning Peng, Hunan Normal University School of Medicine, China

Received: May 22, 2014; **Accepted:** August 12, 2014; **Published:** September 12, 2014

Competing Interests: The authors have declared that no competing interests exist.

Copyright: 2014 Dominici M *et al.* This is an open-access article distributed under the terms of the Creative Commons Attribution License, which permits unrestricted use, distribution, and reproduction in any medium, provided the original author and source are credited.

***Correspondence to:** Massimo Dominici, Division of Oncology, Department of Medical and Surgical Sciences for Children & Adults, University Hospital of Modena and Reggio Emilia, Italy; Email: massimo.dominici@unimore.it

Introduction

Multikinase tyrosine-kinase inhibitors (TKIs), such as Sunitinib and Sorafenib, targeting angiogenesis and cancer cell proliferative signals, have been introduced with encouraging results in the settings of renal cell carcinoma (RCC) and hepato-cellular carcinoma (HCC), while their impact in soft-tissue sarcoma (STS) has been negligible [1,2]. However, angiogenesis plays an important role in STS and vascular-endothelial growth factor (VEGF) correlates with tumor stage, grade and clinical outcome. Similarly, platelet-derived growth factor- β (PDGF- β) signaling appears to be related to tumor grade and cell proliferation [3].

Pazopanib is a multi-target TKI anti-VEGFR 1-2-3, -PDGFR α - β , -c-kit and others registered for advanced RCC [4,5]. From phase I, II and III clinical trials it has emerged that Pazopanib is also the first TKI targeting angiogenesis showing a simultaneous activity in advanced STS [6-8]. In these early clinical trials, the clinicians recognized evidence of side effects mostly related to liver and gastro-enteral toxicities and pazopanib has been marginally considered for LVEF dysfunction as, on contrary, reported for Sunitinib and Sorafenib [9-11].

Generally, TKIs cardiotoxicity can be “on target” when the factor promoting cancer cells survival plays also a functional role in normal cardiac cells, while “off target” TKI toxicity, such as the one of pan-TKIs, is generally related to their lack of selectivity. In these latter cases, the inhibition of a target not specifically responsible for cancer cell survival is causing cardiotoxicity, due to its functional presence on cardiac cells [12-14]. ABL inhibitor Imatinib, principally developed for chronic myelogenous leukemia (CML) and gastrointestinal stromal tumor (GIST) treatment, represents an example of “on target” cardiotoxicity. The pivotal trials on imatinib did not show significant rates of cardiotoxicity or did not include cardiac function monitoring [15-17]. Nevertheless, it has been subsequently reported that patients treated with imatinib could develop severe CHF [18], and Kerkela et al. described a significant left ventricular (LV) dysfunction arisen in 10 patients during treatment with imatinib [19], suggesting that ABL activity could play a role in cardiomyocytes survival.

Multi-target TKIs are expected to determine “off target” effects due to the lack of selectivity [12]. Sunitinib is a TKI inhibiting VEGFR1-3, PDGFR α - β , c-KIT and other TKs approved for advanced RCC and GIST [20]. Similarly, Sorafenib, a cell surface kinase receptors (VEGFR2-3, PDGFR- β , c-KIT) inhibitor, additionally targeting RAF kinases (CRAF, BRAF), is approved for the treatment of unresectable HCC and for advanced RCC. In an observational study, Schmidinger et al described an overall 33,8% incidence of cardiovascular events in 74 patients with mRCC treated with Sunitinib or Sorafenib after a median duration treatment of 8 weeks. This study outlined that cardiac events caused by these agents are more frequent than it has been reported in clinical trials [21], suggesting the need of a careful monitoring of heart failure in these settings. Based on this background, we here report a case of reversible decompensated heart failure in a patient with a soft tissue sarcoma (STS) briefly treated by a relatively new TKI, such as pazopanib.

Case Presentation

On December 2011 a 37-years old patient underwent right forearm amputation for a high-grade epithelioid sarcoma (pT2a N0 M0 R0 stage II), followed by six cycles of adjuvant chemotherapy with standard doses of Epirubicin plus Ifosfamide (Epirubicin 90 mg/m², total dose 180 mg each cycle, cumulative dose 1080 mg; Ifosfamide 2,5 gr/m², total dose 5 gr each cycle, cumulative dose 30 gr). In

June 2012, CT/PET scan and ultra-sound (US) revaluation showed bilateral multiple lung metastases (Fig.1A) and a subcutaneous stump recurrence. A first-line treatment with Trabectedin (1,5 mg/m² in 24h 3w; total dose 3 mg each cycle) was then introduced and, after 3 cycles, a CT scan showed a local stump and pulmonary progression (not shown). Despite the lack of symptoms, a brain magnetic resonance (MRI) additionally showed two encephalic metastatic lesions (Fig.1B, left panel). Trabectedin was then discontinued and, in December 2012, following stump pain onset, he underwent local fractioned radiotherapy (total dose 20 Gy in 5 fractions). At that time, on physical examination, the patient was in good general condition, vital signs were within normal range and an echocardiogram revealed a left ventricular ejection fraction (LVEF) of 55% An additional movie file shows this. [See Additional file 1, Video Sequence 1].

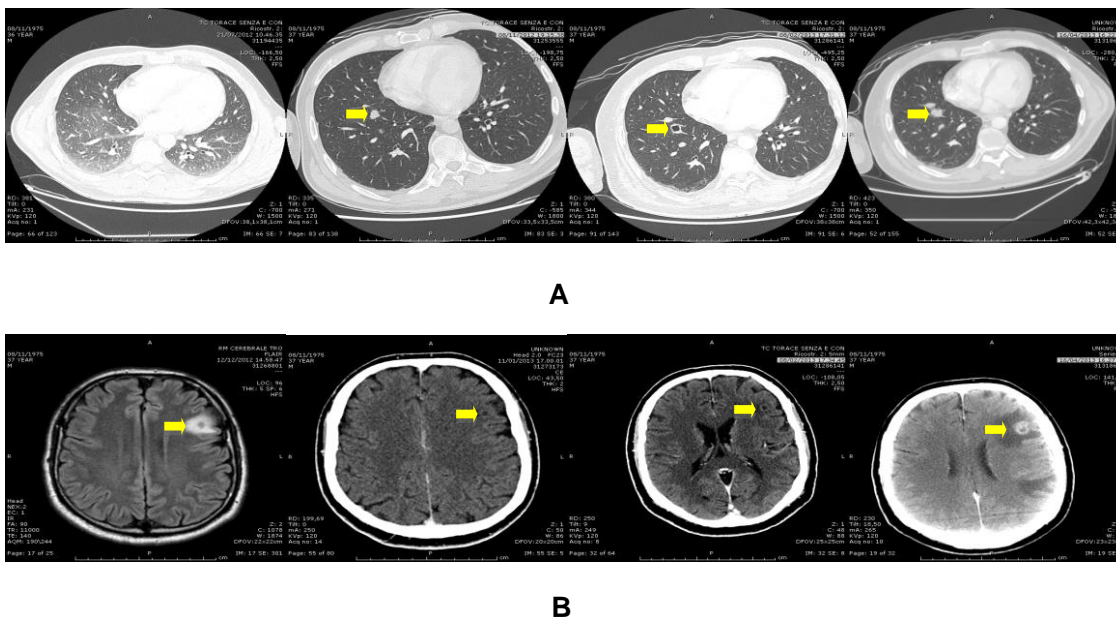


Figure 1 (A) From left to right, lung CT-scans on July 2012, November 2012, February 2013 and April 2013. (B) From left to right, brain MRI on December 2012, brain CT-scan in January 2013, February 2013 and April 2013. Arrows identify target lesions observed during pazopanib treatment and discontinuation.

On 13th December 2012 a treatment with pazopanib 800 mg/die was initiated. After 30 days, a brain CT-scan showed stable disease that was then further confirmed after 60 days (Fig.1B, middle panels). Similarly, a lung CT-scan revealed the stability of pulmonary lesions, and in some cases a central cavitation as a further indicator of a TKIs response (Fig.1, third panel from the left) [22,23]. Pazopanib treatment was maintained for 60 days and was only briefly discontinued due to low platelets counts (Grade II) in relation with the hemorrhage risks for central nervous system (CNS) metastases.

In a further physical examination, on day 75, the patient reported dyspnea on exertion and legs swelling. The ECG was normal, as well as blood tests (including troponine-I serical levels) and chest x-ray. The patient was admitted for further examination and an echocardiogram showed a significant reduction in the contractile function of the left ventricle with severe and diffuse hypokinesia with an estimated LVEF of 30% [see Additional file 1, Video Sequence 2]. A diagnose of acute heart failure was made and pazopanib treatment definitively discontinued. Patient was then prescribed comprehensive therapy including diuretics, β-blockers and ACE inhibitors. In mid-March the patient’s symptoms and signs of heart failure resolved and an echocardiogram performed on 18th March 2013 showed an

increase of LVEF (45%) [see Additional file 1, Video Sequence 3]. On April 2013 a total body CT-scan showed an increase in size of the encephalic lesions and abundant peripheral edema (Fig.1B, right panel). These lesions became rapidly symptomatic with seizure controlled by anti-epileptic medical therapy and whole-brain radiotherapy (WBRT) (30 Gy in 10 fractions) followed by Gemcitabine (1000 mg/ m² days 1,8). At the last follow up the echocardiogram showed a further amelioration of the LVEF (55%; not shown) versus the latest evaluation with no signs and symptoms of cardiac failure.

Discussion

Because of their specificity for TK receptors in tumor cells, targeted therapies by TKIs were supposed to be less cardiotoxic than conventional chemotherapy. However, only after their extensive use, a certain degree of cardiotoxicity has been emerging. The impact of TKI-related cardiotoxicity is still largely underestimated for two main reasons, on one side clinical trials do not generally include cardiac endpoints or LVEF assessment and on the other differentials of heart failure in cancer patients may be confounding since it may be related to other etiologies [12,13].

Pazopanib has been recently introduced in STS treatment with no relevant cardiotoxicity in phase I-II trials [7,8]. However, cardiotoxicity seemed to emerge in the PALETTE trial with a drop in LVEF observed in 3,8% patients in the pazopanib arm and of those only 1,2% were symptomatic. Nevertheless, in the placebo group the incidence was not dissimilar (2,4%), and the lack of a dedicated statistical analyses does not clarify the issue. Collectively, these early findings indicate the need of more attention for this complication in patients that were almost all (99%) pre-treated by anthracyclines as a further risk factor.

To our knowledge, there are no reports describing such a direct impact of pazopanib on cardiac function and the timing of occurrence in severe CHF during treatment with pazopanib has not been carefully assessed so far. Very recently, a trial evaluating the effect of repeated doses of pazopanib on cardiac conduction has been published. This study showed that pazopanib produced a concentration-independent prolongation in the QTc interval [24]. Curiously, considering retrospectively the ECG tracings in our patient over time, we also have to report a tendency to prolongation of QTc (from 449 ms of December 2012 to 478 ms of February 2013).

In general, TKIs cardiotoxicity has shown to be increased in patients with coronary risk factors, prior LV dysfunction and prior or concomitant use of anthracyclines. Our young patient had only the predisposing condition of anthracyclines pre-treatment. However, in this case LVEF was normal before starting pazopanib and strict clinical monitoring was performed during the treatment, without observing any abnormalities. Moreover, after the definitive discontinuation of Pazopanib and the introduction of the comprehensive cardiac therapy, the LVEF returned rapidly in range.

The mechanisms of myocardial damage by TKIs have not been fully investigated but some hypothesis has been advanced. These agents target the Von-Hippel-Lindau hypoxia-inducible (HIF) gene pathway. Therefore, HIF-1 related gene products seem to be mediators of response to cardiac damage, secondly VEGF-VEGFR inhibition could be relevant in patients with poorly controlled hypertension because VEGF is essential in maintaining a normal response of cardiomyocytes to pressure overload [25]. Very recently Chintalgattu et al showed that vascular pericytes are the primary cellular target of Sunitinib-induced cardiotoxicity, highlighting the role of PDGFR in pericyte survival [26]. This hypothesis may also justify the observed reversible impact of pazopanib in cardiac damage, due to the capacity of vascular pericytes to self-regenerate simultaneously supporting myocardial tissue [27].

Conclusion

In summary, cardiac damage from TKI treatment is still an underestimated phenomenon that require further investigations; rates of cardiac heart failure can be expected to be higher than in the highly selected population of patients of phase I-II trials and doses adjustments shall be careful considered based on predisposing conditions. Thus, post-approval monitoring should be taken into account by clinicians, monitoring carefully LVEF and all the symptoms suggestive of cardiac dysfunction, in particular for drugs potentially capable to change the natural history of still incurable cancer, such as STS.

Consent

Written informed consent was obtained from the patient for publication of this Case Report and any accompanying images. A copy of the written consent is available for review by the Editor of this journal.

Abbreviations

TKIs: Tyrosine-kinase inhibitors
RCC: Renal cell carcinoma
HCC: Hepato-cellular carcinoma
STS: Soft-tissue sarcoma
VEGF: Vascular-endothelial growth factor
PDGF: Platelet-derived growth factor
LVEF: Left ventricular ejection fraction
CML: Chronic myelogenous leukemia
GIST: Gastrointestinal stromal tumor
CHF: Congestive heart failure
LV: Left ventricular
CTscan: Computerized Tomography scan
PETscan: Positron emission tomography scan
US: Ultra-sound
MRI: Magnetic resonance imaging
CNS: Central nervous system
ECG: Electrocardiogram
WBRT: Whole-brain radiotherapy

References

1. Maki RG, D'Adamo DR, Keohan ML, Saulle M, Schuetze SM, Undevia SD, Livingston MB, Cooney MM, Hensley ML, Mita MM, Takimoto CH, Kraft AS, Elias AD, Brockstein B, Blachère NE, Edgar MA, Schwartz LH, Qin LX, Antonescu CR, Schwartz GK. Phase II study of sorafenib in patients with metastatic or recurrent sarcomas. *J Clin Oncol.* 2009, 27:3133-3140

2. George S, Merriam P, Maki RG, Van der Abbeele AD, Yap JT, Akhurst T, Harmon DC, Bhuchar G, O'Mara MM, D'Adamo DR, Morgan J, Schwartz GK, Wagner AJ, Butrynski JE, Demetri GD, Kehoan ML. Multicenter phase II trial of sunitinib in the treatment of nongastrointestinal stromal tumor sarcomas. *J Clin Oncol*. 2009, 27:3154-3160
3. DuBois S, Demetri G. Markers of angiogenesis and clinical features in patients with sarcoma. *Cancer*. 2007, 109:813-819
4. Harris PA, Bolor A, Cheung M, Kumar R, Crosby RM, Davis-Ward RG, Epperly AH, Hinkle KW, Hunter III RN, Johnson JH, Knick VB, Laudeman CP, Luttrell DK, Mook RA, Nolte RT, Rudolph SK, Szewczyk JR, Truesdale AT, Veal JM, Wang L, Stafford JA. Discovery of 5-([4-[[[2,3-dimethyl-2H-indazol-6-yl]methylamino]-2-pyrimidinyl]amino)-2-methyl-benzenesulfonamide (Pazopanib), a novel and potent vascular endothelial growth factor receptor inhibitor. *J Med Chem*. 2008, 51:4632-4640
5. Sternberg CN, Davis ID, Mardiak J, Szczylik C, Lee E, Wagstaff J, Barrios CH, Salman P, Gladkov OA, Cavina A, Zarbà JJ, Chen M, McCann L, Pandite L, Roychowdhury DF, Hawkins RE. Pazopanib in locally advanced or metastatic renal cell carcinoma: results of a randomized phase III trial. *J Clin Oncol*. 2010, 28:1061-1068
6. Kumar R, Knick VB, Rudolph SK, Johnson JH, Crosby RM; Crouthamel MC, Hopper TM, Miller CG, Harrington LE, Onori JA; Mullin RJ, Gilmer TM, Truesdale AT, Epperly AH; Bolor A, Stafford JA, Luttrell DK, Cheung M. Pharmacokinetic-pharmacodynamic correlation from mouse to human with pazopanib, a multikinase angiogenesis inhibitor with potent antitumor and antiangiogenic activity. *Mol Cancer Ther*. 2007, 6:2012-2021
7. Hurwitz HI, Dowlati A, Saini S, Savage S, Suttle AB, Gibson DM, Hodge JP, Merkle EM, Pandite L. Phase I trial of pazopanib in patients with advanced cancer. *Clin Cancer Res*. 2009, 15:4220-4227
8. Sleijfer S, Ray-Coquard I, Papai Z, Le Cesne A, Scurr M, Schoeffski P, Collin F, Pandite L, Marreaud S, De Brauwier A, Van Glabbeke M, Verweij J, Blay J. Pazopanib, a multikinase angiogenesis inhibitor, in patients with relapsed or refractory advanced soft tissue sarcoma: a phase II study from the European organization for research and treatment of cancer soft tissue and bone sarcoma group (EORTC study 62043). *J Clin Oncol*. 2009, 27:3126-3132
9. Van der Graaf WT, Blay J, Chawla SP, Kim D, Bui-Nguyen B, Casali PG, Schoffski P, Aglietta M, Staddon AP, Beppu Y, Le Cesne A, Gelderblom H, Judson IR, Araki N, Ovali M, Marreaud S, Hodge R, Dewji MR, Coens C, Demetri GD, Fletcher CD, Dei Tos AP, Hohenberger P. Pazopanib for metastatic soft-tissue sarcoma (PALETTE): a randomized, double-blind, placebo-controlled phase 3 trial. *Lancet*. 2012, 379:1879-1886
10. Cohen R, Oudard S. Antiangiogenic therapy for advanced renal cell carcinoma: management of treatment-related toxicities. *Invest New Drugs*. 2012, 30:2066-2079
11. Keisner SV, Shah SR. Pazopanib: the newest tyrosine kinase inhibitor for the treatment of advanced or metastatic renal cell carcinoma. *Drugs*. 2011, 71:443-454
12. Garcia-Alvarez A, Garcia-Albeniz X, Esteve J, Rovira M, Bosch X. Cardiotoxicity of Tyrosine-kinase-targeting drugs. *Cardiovasc Hematol Agents Med Chem*. 2010, 8:11-21
13. Force T, Kerkela R. Cardiotoxicity of new cancer therapeutics - mechanisms of, and approaches to, the problem. *Drug Discov Today*. 2008,13:778-784
14. Hasinoff B. The cardiotoxicity and myocyte damage caused by small molecule anticancer tyrosine kinase inhibitors is correlated with lack of target specificity. *Toxicol Appl Pharmacol*. 2010, 244:190-195
15. O'Brien SG, Guilhot F, Larson RA, Gathmann I, Baccarani M, Cervantes F, Cornelissen JJ, Fischer T, Hochhaus A, Hughes T, Lechner K, Nielsen JL, Rousselot P, Reiffers J, Saglio G, Shepherd J, Simonsson B, Gratwohl A, Goldman JM, Kantarjian H, Taylor K, Verhoef G, Bolton AE, Capdeville R, Druker BJ. Imatinib compared with interferon and low-dose cytarabine for newly diagnosed chronic-phase chronic myeloid leukemia. *N Engl J Med*. 2003, 348:994
16. Dematteo RP, Ballman KV, Antonescu CR, Maki RG, Pisters PW, Demetri GD, Blackstein ME, Blanke CD, von Mehren M, Brennan MF, Patel S, McCarter MD, Polikoff JA, Tan BR, Owzar K. Adjuvant imatinib mesylate after

- resection of localized, primary gastrointestinal stromal tumor: a randomized, double-blind, placebo-controlled trial. *Lancet*. 2009, 373:1097
17. Verweij J, Casali PG, Zalcberg J, LeCesne A, Reichardt P, Blay JY, Issels R, van Oosterom A, Hogendoorn PC, Van Glabbeke M, Bertulli R, Judson I. Progression-free survival in gastrointestinal stromal tumors with high-dose imatinib: randomized trial. *Lancet*. 2004, 364:1127
 18. Orphanos GS, Ioannidis GN, Ardavanis AG. Cardiotoxicity induced by tyrosine kinase inhibitors. *Acta Oncol*. 2009, 48:964-970
 19. Kerkela R, Grazette L, Yacobi R, Iliescu C, Patten R, Beahm C, Walters B, Shevtsov S, Pesant S, Clubb FJ, Rosenzweig A, Salomon RN, Van Etten RA, Alroy J, Durand JB, Force T. Cardiotoxicity of the cancer therapeutic agent imatinib mesylate. *Nat Med*. 2006, 12:908
 20. Goodman VL, Rock EP, Dagher R, Ramchandani RP, Abraham S, Gobburu JV, Booth BP, Verbois SL, Morse DE, Liang CY, Chidambaram N, Jiang JX, Tang S, Mahjoob K, Justice R, Pazdur R. Approval summary: sunitinib for the treatment of imatinib refractory or intolerant gastrointestinal stromal tumors and advanced renal cell carcinoma. *Clin Cancer Res*. 2007, 13:1367
 21. Schmidinger M, Zielinski CC, Vogl UM, Bojic A, Bojic M, Schukro C, Ruhsam M, Hejna M, Schmidinger H. Cardiac toxicity of sunitinib and sorafenib in patients with metastatic renal cell carcinoma. *J Clin Oncol*. 2008, 26:5204-5212
 22. Marom EM, Martinez CH, Truong MT, Lei X, Sabloff BS, Munden RF, Gladish GW, Herbst RS, Morice RC, Stewart DJ, Jimenez CA, Blumenschein GR, Onn A. Tumor cavitation during therapy with antiangiogenesis agents in patients with lung cancer. *J Thorac Oncol*. 2008, 3:351-357
 23. Kang H, Lee HY, Lee KS, Kim JH. Imaging-based tumor treatment response evaluation: review of conventional, new, and emerging concepts. *Korean J Radiol*. 2012, 13:371-390
 24. Heath EI, Infante J, Lewis LD, Luu T, Stephenson J, Tan AR, Kasubhai S, LoRusso P, Ma B, Suttle AB, Kleha JF, Ball HA, Dar MM. A randomized, double-blind, placebo-controlled study to evaluate the effect of repeated oral doses of pazopanib on cardiac conduction in patients with solid tumors. *Cancer Chemother Pharmacol*. 2013, 71:565-573
 25. Izumiya Y, Shiojima I, Sato K, Sawyer DB, Colucci WS, Walsh K. Vascular endothelial growth factor blockade promotes the transition from compensatory cardiac hypertrophy to failure in response to pressure overload. *Hypertension*. 2006, 47:887-893
 26. Chintalgattu V, Rees ML, Culver JC, Goel A, Jiffar T, Zhang J, Dunner K Jr, Pati S, Bankson JA, Pasqualini R, Arap W, Bryan NS, Taegtmeier H, Langley RR, Yao H, Kupferman ME, Entman ML, Dickinson ME, Khakoo AY. Coronary microvascular pericytes are the cellular target of sunitinib malate-induced cardiotoxicity. *Sci Transl Med*. 2013, 5:187 ra69
 27. Katare RG, Madeddu P. Pericytes from human veins for treatment of myocardial ischemia. *Trends Cardiovasc Med*. 2013, 23:66-70