

**Case Report**

Breast Metastasis from Differentiated Thyroid Carcinoma Primary: A Case Report and Review of Literature

Kevin C. Brown, BS¹, Ryan B. Fransman, BS¹, Nisha Lakhi, MD⁴, Preeti Gupta, MBBS,FRCR²,
Michael S. Ballo, MD³, Eugene Meyer, MD¹

¹ Department of Surgery; Northwest Hospital, Baltimore, Maryland, United States

² Department of Radiology, Herman & Walter Samuelson Breast Care Center; Northwest Hospital, Baltimore, Maryland, United States

³ Department of Pathology; Northwest Hospital, Baltimore, Maryland, United States

⁴ Department of Obstetrics and Gynecology, Richmond University Medical Center, Staten Island, New York, United States

Abstract

Introduction: Metastasis to the breast from non-mammary malignancy is rare, with a reported incidence of less than 1% [2-4]. Aside from hematologic malignancies and contralateral breast cancer, the most common primary malignancies that metastasize to the breast are lung, ovarian, gastrointestinal cancers, and melanoma.

Presentation of Case: We present an 82-year-old female with metastatic breast cancer arising from a primary papillary thyroid carcinoma. She presented with a palpable right breast mass 4 years after resection and treatment of a primary thyroid cancer.

Conclusion: Ultrasound guided core biopsy and immunohistochemical staining demonstrated metastatic papillary thyroid carcinoma. The patient underwent lymphoscintigraphy and subsequent resection of the breast mass along with two axillary lymph nodes.

Keywords: Breast; Metastasis; Carcinoma; Metastasis; Thyroid

Academic Editor: Xiaoning Peng, Hunan Normal University School of Medicine, China

Received: May 20, 2015; **Accepted:** July 8, 2015; **Published:** July *, 2015

Competing Interests: The authors have declared that no competing interests exist.

Consent: We confirm that the patient has given the informed consent for the case report to be published.

Copyright: 2015 Brown KC *et al.* This is an open-access article distributed under the terms of the Creative Commons Attribution License, which permits unrestricted use, distribution, and reproduction in any medium, provided the original author and source are credited.

***Correspondence to:** Kevin C. Brown, Department of Surgery; Northwest Hospital, Baltimore, Maryland, United States

Email: kcbrown@lifebridgehealth.org

Introduction

The lifetime risk of breast cancer is 12.3 percent[1]. Metastatic neoplasms to the breast and surrounding tissue are exceptionally rare and account for approximately 2% of all mammary malignancies. The most common metastasis to the breast are from a contralateral breast cancer. Non-mammary breast metastasis account for less than 1% of breast neoplasms[2-4]. In spite of its rarity, prompt and accurate diagnosis of non-mammary metastatic breast malignancy is essential in avoiding improper treatment, which may improve patient outcomes while minimizing adverse effects and complications[5, 6].

Thyroid papillary carcinoma is the most common malignancy of the thyroid and, without distant metastasis, carries a good prognosis with a mortality rate of 6%. Distant metastasis is uncommon and usually represents a more aggressive neoplasm with a worse prognosis[7-9]. TPC commonly metastasizes to local lymph nodes, the lungs and bone. A review of literature have demonstrated few cases of TPC metastasizing the breast[10, 11].

Case Presentation

An 82-year-old, African-American, non-smoker female presented to the outpatient medical clinic with complaints of a large right breast mass of a couple months duration with a recent increase in size over the past couple of weeks. She had a documented history of a 7cm poorly-differentiated thyroid carcinoma with invasion of surrounding muscle and vasculature in 2008, for which she underwent a subtotal thyroidectomy, followed by radioactive iodine treatment. Two years later, the patient was found via ultra sound to have two localized lesions of 3.3 and 2.5 cm in the midline of neck and left thyroid respectively. Biopsy confirmed recurrent poorly differentiated thyroid carcinoma and the masses were subsequently resected. In 2012, a chest computed tomography scan (CT), followed by a whole body positron emission tomography scan (PET/CT) revealed the presence of multiple ‘hot’ pulmonary nodules with a dominant 6mm nodule in the left upper lobe. Based on size and lack of symptoms, pulmonary lesions would be left to observation(Figure 1a, 1b).

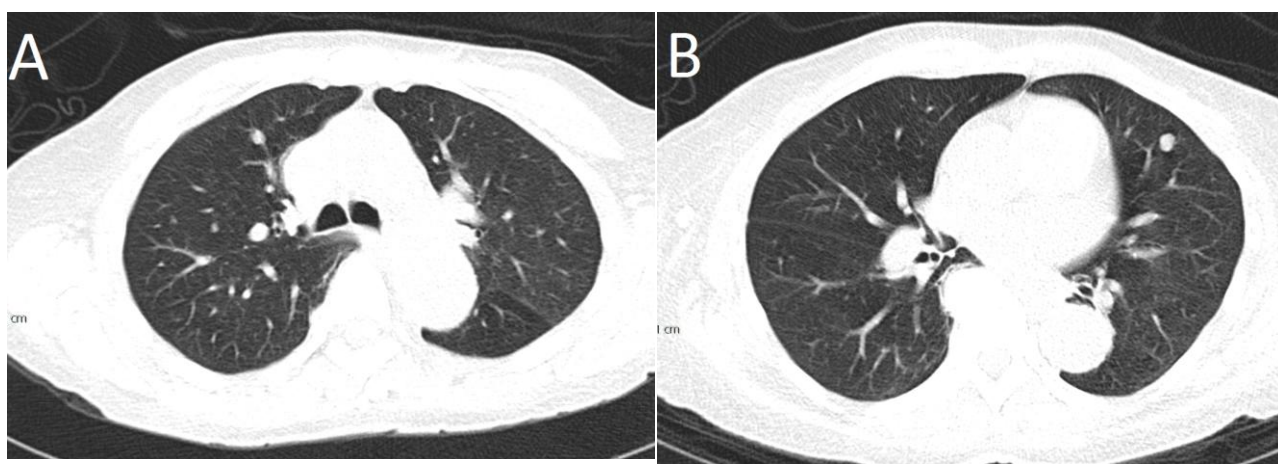


Figure 1a and 1b: CT chest: Axial sections (lung windows) showing multiple bilateral lung nodules, suspicious for metastases.

At presentation in our clinic, physical examination revealed a large, relatively hard right breast lump, palpable infero-laterally with respect to the nipple, and measuring approximately 6cm vertical and 7cm horizontal. There was no nipple retraction or discharge. Diagnostic ultrasound showed an irregular, hypoechoic mass with heterogenous echotexture at eight o'clock, 5cm from the nipple, measuring 4.5 x 3.5 x 4.4cm (Figure 2a, 2b). Targeted ultrasound of the right axilla demonstrated a normal appearing lymph node. The patient underwent an ultrasound guided core biopsy of the mass leaving a marking clip in place. Post biopsy mammography showed the mass along with biopsy clip (Figure 3a, 3b). Immunohistochemical (IHC) staining performed on the specimens were strongly positive for thyroglobulin, CK7, PAX8, vimentin and TTF-1. Cells were negative for CK20, S100, CDX2 and GATA3. Tumor cells were weakly positive for estrogen and progesterone receptor and negative for Her-2/neu; proliferation rate by Ki-67 was low (10%). IHC findings were consistent with metastatic papillary thyroid carcinoma.

Sentinel lymphoscintigraphy with 0.55 mCi technetium-99m demonstrated two small foci of uptake in the right axilla. The patient underwent a right partial mastectomy of the mass and right axillary lymph node dissection. Pathology of the mass was consistent with a primary thyroid carcinoma. Lymph nodes were negative for metastatic disease. The patient tolerated the procedure well without complication and was urged to follow up with her oncologist for post-operative treatment options.

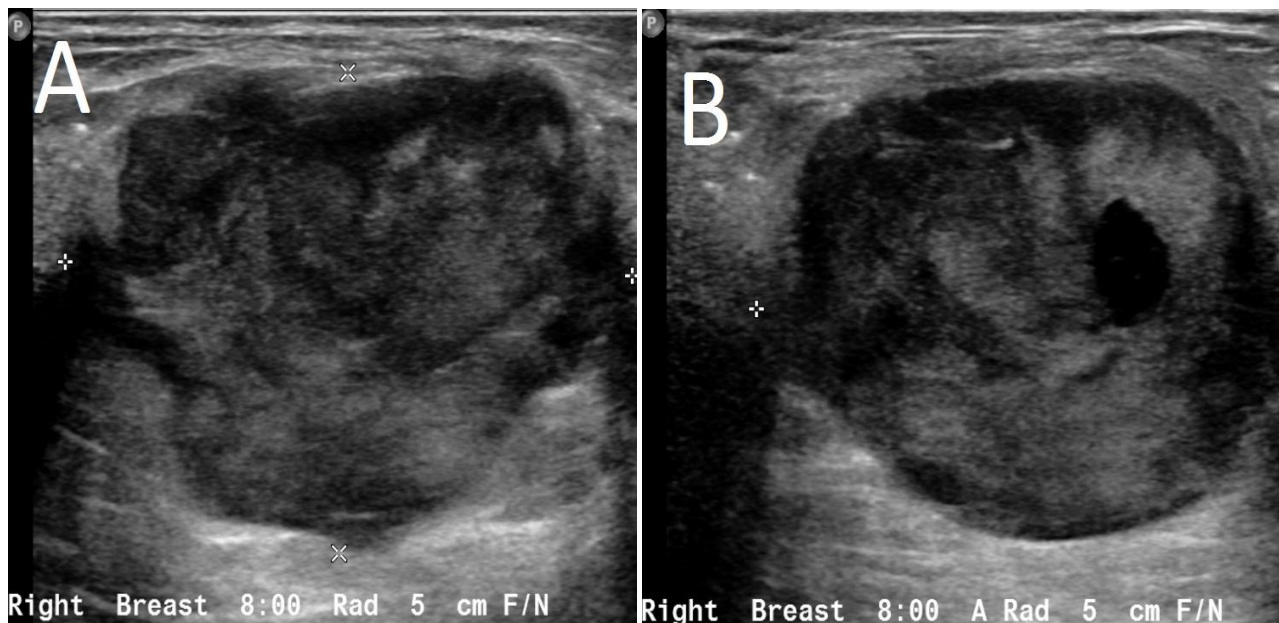


Figure 2a and 2b: Right breast ultrasound showing a hypoechoic mass with circumscribed margins at the 8:00 5 cm from nipple, corresponding to the mass seen on the mammogram.

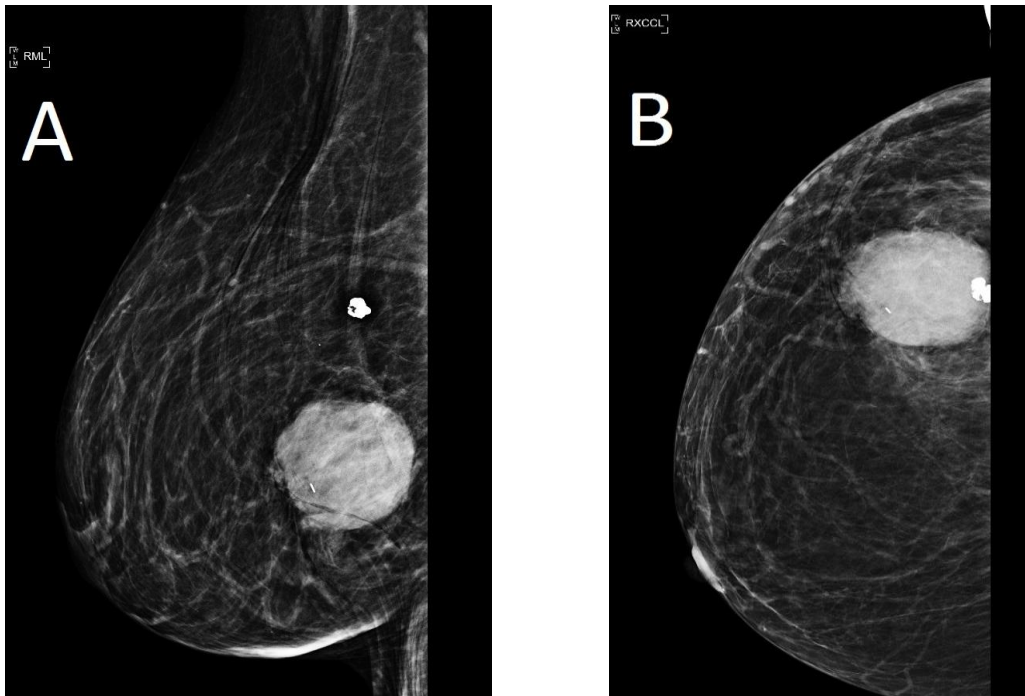


Figure 3a and Fig 3b: Right diagnostic mammogram performed after the ultrasound guided biopsy of the breast mass showing the round mass at the 8:00 location containing a biopsy clip.

Discussion

Papillary thyroid carcinoma (PTC) is a well differentiated neoplasm characterized by an indolent growth pattern with low metastatic potential and a relatively good prognosis. Usually localized to the thyroid, PTC, responds well to total thyroidectomy, radioiodine-131 ablation and hormone suppression measures and carries a mortality approaching 6 percent[7, 9]. Metastasis, conversely, drastically reduces survival rate and overall prognosis. The most common involvement being of regional lymph nodes, lung and bone. Distant metastasis to organs inclusive of brain, breast, liver, kidney and other are relatively rare, increasing the risk of being overlooked or misdiagnosed in the clinical setting[10, 11]. An increased mortality results from age over 45, multiple organ involvement, soft-tissue invasion of primary tumor, all existing in the present case[7, 8, 12]. Proper diagnosis allows for more effective treatment planning and prognosis[5, 6].

Non-mammary metastasis to the breast is uncommon with a rate of 0.4-2 percent of breast malignancies. It is even rarer for a breast malignancy to be metastasis from thyroid cancer with few more than 11 cases documented in recent literature. The median time between primary malignancy diagnosis and breast metastasis is about 2 years, with a median survival after diagnosis in the range of 10-15 months[6, 14]. Most reports of metastatic disease to the breast have been documented through independent institution reviews, case reports or meta-analyses of obtainable studies. Williams and colleagues at University of Texas M.D. Anderson Cancer Center confirmed 169 patients with metastatic disease to the breast from over a 15 year period; of these cases, 5.3% originated from the head & neck with no distinction of PTC[6]. Later, DeLair and colleagues reported 85 cases over a 20 year period from

Memorial Sloan-Kettering Cancer Center. Data from this study demonstrated that 2.5% of cases arose from PTC [2]. More recently, Zhou et al. identified 28 similar cases, none of which demonstrated metastatic PTC [15]. These studies all noted an increased incidence with a previous primary diagnosis, advanced stage of disease, and age over 45 years, but with an unpredictable occurrence of PTC.

The differentiation between primary breast cancer and metastatic cancer to the breast through imaging is challenging. A metastatic lesion could mimic a primary breast tumor. PTC in addition to other metastatic malignancies to the breast, usually present as multiple well-circumscribed masses on a mammogram and ultrasound, with potential lymph node involvement in patients with an advanced disease state. Metastatic tumors to the breast are more likely to present bilaterally, with multiple areas of involvement. Non-mammary metastatic involvement of the breast usually does not show calcifications on mammogram [4, 5, 15].

Apart from identifying the solid nature of a mass, ultrasound also assists in biopsy guidance as seen in our patient. However, it is not possible to make a definitive diagnosis of metastasis based solely on imaging findings [16]. As demonstrated in our case, immunohistochemistry played a vital role in confirming the primary tumor, in addition to ruling out a breast component. Cytokeratins are effective markers for epithelial differentiation and are highly expressed in tumors of carcinomatous nature [5, 17]. Our specimen stained positive for CK7, which is expressed in 98% and 96% of all thyroid and breast tumors respectively. CK20 stained negative which has a 0% expression in both origins. Following an algorithmic approach illustrated by Dabbs (*Diagnostic immunohistochemistry*, 2013), CK7+/CK20- our specimen stained positive for TTF-1, a marker for thyroid transcription factor 1, which is positive in all thyroid origins as well as 75% of lung carcinomas. Subsequently, thyroid origin was confirmed by staining positive for both thyroglobulin, a glycoprotein positive in all thyroid excluding anaplastic, and PAX-8, a paired box gene required for development of the thyroid. Vimentin stained positive, which is expressed in >50% of thyroid carcinoma, and <10% of breast ductal-lobular carcinoma [17].

Specimens stained negative for S-100, ruling out most carcinomas and melanoma, while a negative CDX2 and GATA3 dismissed intestinal and mammary gland origin respectively. Cells staining weakly positive for estrogen and progesterone as well as a negative stain for Her-2/Neu confirmed the exclusion of breast as the origin of this lesion. Low proliferation of nuclear protein Ki-67 contributed to the exclusion of breast derivation [17].

Conclusion

In conclusion, we report a rare case of metastatic involvement of the breast by a primary papillary thyroid carcinoma. Generally, metastatic tumors to the breast are associated with a poor prognosis with a median survival time of ten months from the time of diagnosis. It is important to consider metastatic disease in the differential diagnosis of breast masses, as the management may differ greatly. A thorough radiological examination, cytological and immunohistochemical analysis, in addition to clinical correlation provides the best opportunity to make an accurate diagnosis.

References

1. SEER Cancer Statistics Factsheets: Breast Cancer. National Cancer Institute. Bethesda, MD, <http://seer.cancer.gov/statfacts/html/breast.html>

2. DeLair DF, Corben AD, Catalano JP, Vallejo CE, Brogi E, and Tan LK. Non-mammary metastases to the breast and axilla: a study of 85 cases. *Modern Pathology : An Official Journal of the United States and Canadian Academy of Pathology, Inc*, 2013, 26, 343-9. doi:10.1038/modpathol.2012.191
3. Maounis N, Chorti M, Legaki S, Ellina E, Emmanouilidou A, Demonakou M, and Tsiafaki X. Metastasis to the breast from an adenocarcinoma of the lung with extensive micropapillary component: a case report and review of the literature. *Diagnostic pathology*. 2010, 82 . doi:10.1186/1746-1596-5-82
4. Toombs BD, and Kalisher L. Metastatic disease to the breast: clinical, pathologic, and radiographic features. *American Journal of Roentgenology*. 1977, 129:673-676
5. Cangiarella J. Metastases to the Breast. In *Breast cytohistology* (1st ed., Vol. 1, pp. 195-202). Cambridge: *Cambridge University Press*, 2013
6. Williams SA, Ehlers RA, Hunt KK, Yi M, Kuerer HM, Singletary SE, et al. Metastases to the breast from nonbreast solid neoplasms: Presentation and determinants of survival. *Cancer*. 2007, 110:731-737
7. Mazzaferri EL, Jhiang SM. Long-term impact of initial surgical and medical therapy on papillary and follicular thyroid cancer. *The American Journal of Medicine*, 1994, 97:418
8. Eustatia-Rutten CFA, Corssmit EPM, Biermasz NR, Pereira AM, Romijn JA, and Smit JW. Survival and death causes in differentiated thyroid carcinoma. *Journal of Clinical Endocrinology and Metabolism*. 2006, 91, 313-319
9. LiVolsi VA. Papillary thyroid carcinoma: an update. *Mod Pathol*. 2011, 24:S1-S9
10. Song HJ, Xue YL, Qiu ZL, and Luo QY. Uncommon metastases from differentiated thyroid carcinoma. *Hellenic Journal of Nuclear Medicine*. 2012, doi:10.1967/s002449910059
11. Corrado G, Pomati G, Russo A, Visca P, Vincenzoni C, Patrizi, L, and Vizza E. Ovarian Metastasis from Thyroid Carcinoma: A Case Report and Literature Review. *Diagnostic Pathology*. 2014, 9(1):193-193
12. Tuttle RM. Risk-adapted management of thyroid cancer. *Endocrine Practice*. 2008,14:764-774
13. Luster M, Weber T, and Verburg FA. Differentiated thyroid cancer-personalized therapies to prevent overtreatment. *Nature Reviews Endocrinology*. 2014, 10(9):563-574
14. Ota T. Papillary Carcinoma of the Thyroid with Distant Metastases to the Cerebrum: a Case Report. *Japanese Journal of Clinical Oncology*. 2001, 31, 112-115
15. Zhou S, Yu B, Cheng Y, Xu X, Shui R, Bi R, et al. Metastasis to the breast from non-mammary malignancies: A clinicopathologic study of 28 cases. *Chinese Journal of Pathology*. 2014, 43(4):231-235
16. The American Cancer Society. Diagnostic tests for breast conditions. (2014, July 21). Retrieved from:
<http://www.cancer.org/treatment/understandingyourdiagnosis/examsandtestdescriptions/forwomennfacingabreastbiopsy/breast-biopsy-diagnostic-tests-used>
17. Dabbs, D. Immunohistochemistry of Metastatic Carcinoma of Unknown Primary Site. In *Diagnostic immunohistochemistry: Theranostic and genomic applications* (Fourth ed., pp. 204-38). Philadelphia: *Saunders*. 2013