

**Case Report**

Benign Pulmonary Metastasizing Leiomyoma: A Case Report

Waleed Mohammed Alselwi*, Samir Taha Alfotih,
Faisal Azam, and Ahmed Alwabari.

Adult Oncology Department, Oncology Center , King Fahad Specialist
Hospital(KFSH-D), , Dammam, Saudi Arabia

Abstract

Introduction: Benign metastasizing leiomyoma (BML) is a rare disease, the first case of BML was reported by Steiner in 1939. It can affect any age group ranging from 30 to 75 years, but most commonly found in late childbearing period. Leiomyoma of the uterus can metastasize to different organs but lung is the most common site, hence the term pulmonary benign metastasizing leiomyoma (PBML) is used. PBML is mostly diagnosed incidentally on imaging studies for other conditions. It can occur many years after hysterectomy for Leiomyoma of uterus.

Presentation of the cases: We report a case of a 51 years old lady with chronic cough and pulmonary nodules on a computerized tomography (CT) scan. She was referred to our hospital for the management of the probable metastatic cancer. Her diagnosis was challenging but a past history of hysterectomy, radiological findings and the histopathology helped us to diagnose this rare condition of benign metastasizing leiomyoma (BML).

Conclusion: Pulmonary benign metastasizing leiomyoma is rare benign disease. It should be considered as the probable diagnosis in a female patient with pulmonary nodules and a previous history of surgery for leiomyoma of uterus. Pathological differentiation from leiomyosarcoma and other malignant metastatic condition is essential. Prognosis of PBML after surgical and/ or hormonal treatment is good.

Academic Editor: Xiaoning Peng, Hunan Normal University School of Medicine, China

Received: April 20, 2016; **Accepted:** May 17, 2016; **Published:** July 7, 2016

Competing Interests: The authors have declared that no competing interests exist.

Consent: Consent was taken from the patient for publication of this case report.

Copyright: 2016 Alselwi WM *et al.* This is an open-access article distributed under the terms of the Creative Commons Attribution License, which permits unrestricted use, distribution, and reproduction in any medium, provided the original author and source are credited.

***Correspondence to:** Waleed Mohammed Alselwi, Adult Oncology Department, Oncology Center, King Fahad Specialist Hospital(KFSH-D), Al Murekbat Area , Omar Bin Thabet Street, Dammam, Saudi Arabia

E-mail: drwaleedalselwi@yahoo.com

Introduction

Benign metastasizing leiomyoma (BML) is a rare disease, the first case of BML was reported by Steiner in 1939 [1] [2]. It can affect any age group ranging from 30 to 75 years but most commonly found in late childbearing period [3]. Leiomyoma of the uterus can metastasize to different organs but lung is the most common site, hence the term pulmonary benign metastasizing leiomyoma (PBML) is used [4]. PBML is mostly diagnosed incidentally on imaging studies for other conditions. It can occur many years after hysterectomy for Leiomyoma of uterus [5].

Case Presentation

A 51 year old lady, a mother of four children presented with chronic cough of one year and shortness of air (SOA) of two weeks duration. Cough, which was mostly dry but occasionally expectorating small amount of white sputum at night, was more pronounced in the month preceding the hospital admission. She denied any chronic medical illness or exposure to tuberculosis. She denied any other respiratory symptoms except dyspnea, but there was no fever, weight loss, decreased appetite or fatigue. She never smoked and there were no malignancies in the family.

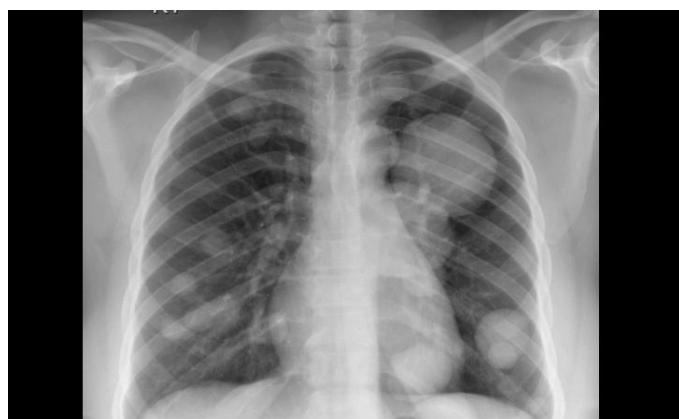

Fig. 1 Chest radiograph of PBML

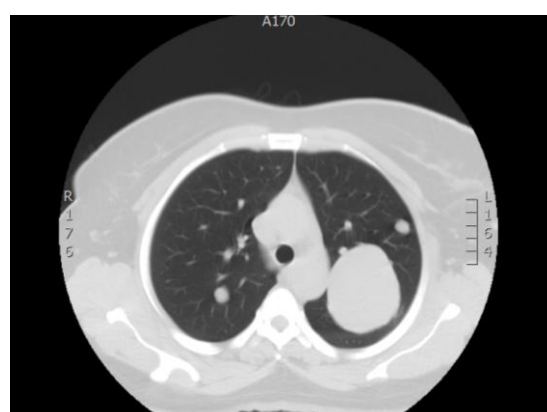
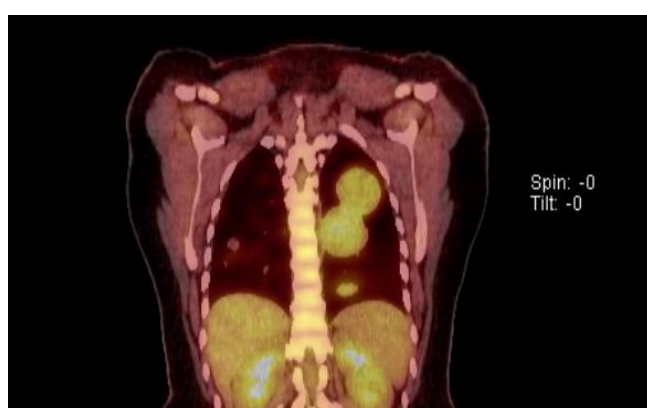


Fig 2 (left) PET-CT scan showing pulmonary nodules (PBML)

Fig 3 (Right) CT scan showing pulmonary nodules (PBML).

She had hysterectomy for uterine fibroid 15 years prior to presentation. She was referred to medical oncology department with presumed diagnosis of multiple lung metastases of unknown primary. She was mildly dyspnoeic with respiratory rate of 18 breath per minute but clear breath sounds on auscultation. Her other clinical examination was unremarkable. Oxygen saturation on pulse oxymeter was 90% on room air for which she was started on 3 liters of oxygen.

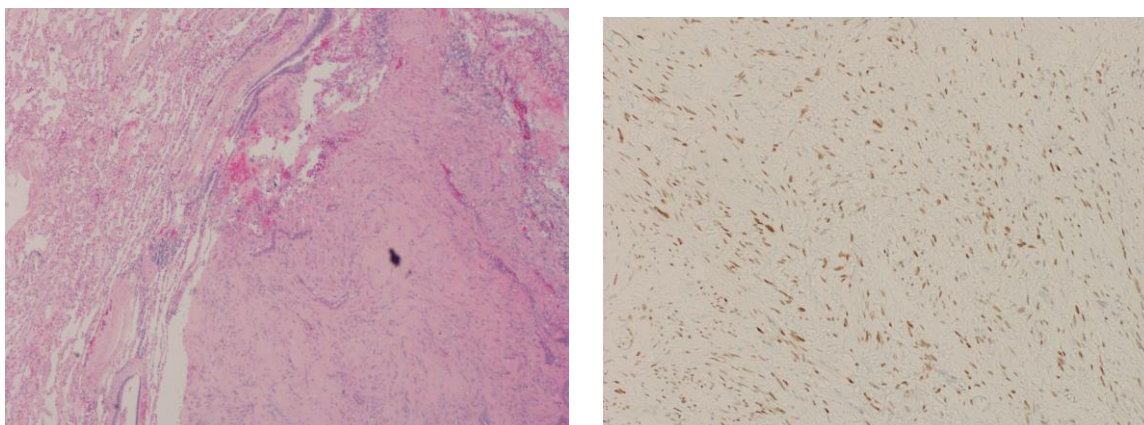


Fig4 A (left) histopathology from the lung lesion shows, spindle cell neoplasm with rare mitosis and mild cellular and nuclear atypia. **B (right)** : Immunohistochemistry for ER and PR are positive.

Chest x-ray (CXR) reported bilateral pulmonary nodules; the largest was in the left upper lobe and measured 7x8 cm (Fig1). Positron emission tomography (PET)/CT scan showed multiple bilateral FDG avid pulmonary nodules with no evidence of FDG avid disease elsewhere (Fig 2,3). The SUVmax (standardized uptake value) of different lung nodules ranged from 3 to 6.

There was no evidence of pulmonary embolism, interstitial fibrosis or consolidation. Ultrasound of the pelvis was unremarkable. Based on radiological investigations she was initially diagnosed to have a metastatic malignancy of unknown primary.

Pulmonary lesion CT guided biopsy was arranged and histopathology reported as mild to moderate cytological atypia and focal mucoid degeneration, no mitosis or definite coagulative tumor necrosis. Immunostains of tumor cells were positive for desmin, ER, PR and Smooth muscle actin. The pathological diagnosis of metastatic low grade smooth muscle neoplasm was made. Her case was discussed in the tumor board and pathology slides were reviewed. Repeat biopsy of the lung nodule with a bigger tissue was recommended by the tumor board.

Wedge resection was performed through the Left video assisted thoracoscopic surgery (VATS). The biopsy revealed spindle cell neoplasm with smooth muscle differentiation with mild cellular and nuclear atypia (fig 4 A). Histopathology reported Immunostains of tumor cells positive for smooth muscle actin, caldesmon, ER and PR (fig 4 B). Immunostains were negative for S100 protein. The Ki-67 was less than 5% and the final diagnosis was confirmed as metastasizing leiomyoma. Cytogenetic studies with FISH (Flourescence in situ hybridization) reported no deletions in chromosomes 19 and 22. Pathology paraffin blocks and slides from hysterectomy fifteen years ago were not available for a review.

The case was discussed again in the tumor board meeting and thoracic surgeon was consulted for her management. In view of multiple lung nodules it was considered to be unresectable.

The patient was informed that the final diagnosis is PBML and she was started on daily Letrozole

2.5 mg. Her cough, dyspnoea and hypoxia were significantly improved within 3 weeks of treatment. Oxygen saturation improved to 96% on room air upon discharge. On six weeks clinic follow up examination, she was clinically well and had no cough or dyspnoea. A CXR did not show any radiographic improvement and a CT scan is planned in six weeks.

Discussion

Fibroid (leiomyoma) is a benign tumour of the uterus, it accounts for half of the gynaecological tumors [6]. The risk of malignancy transformation is 0.16 - 6% [7].

The pathogenesis of this benign tumor metastasizing to the lung is not clear. Possible mechanisms include hematogenous/ lymphatics spread or proliferation from local smooth muscle tissues [8]. The most acceptable theory of dissemination is through venous circulation based on the observation that the majority of patients with PBML have a past history of surgery for leiomyoma. Our patient had a hysterectomy for leiomyoma 15 years ago. Rarely these metastases are discovered simultaneously with uterine fibroid [9].

Most patients with PBML are asymptomatic and often discovered incidentally on the chest imaging. With disease progression, patients may present with chest pain, cough or even hemoptysis [10]. The cause of death in PBML is often respiratory failure [11].

PBMLs usually develop many years after a hysterectomy or myomectomy (approximately 14.9 years). Pulmonary lesions are often bilateral (70%), unilateral in 17% and solitary in 13% of cases. The average survival after pulmonary resection is 94 months [12].

Radiographic images of the chest in PBML usually show multiple well-circumscribed non-calcified lung nodules. These nodules can be cavitating. Less commonly radiological presentation can be solitary nodule or diffuse miliary lesions [13]. FDG (Fluorodeoxyglucose) uptake on a PET/CT scan is usually faint or none [14] and SUVmax (standardized uptake value) ranges between 0.2 and 2.2 but rarely the uptake can be higher, as in our patient the a SUVmax was 3 to 6 .

Diagnosis of PBML is based on presence of benign-appearing smooth muscle tumors outside the uterus. The cells have low mitotic index (<5 mitoses per 10 high power fields), lack of pleomorphism and no local invasion. The tumor usually stains for estrogen receptor (ER) and progesterone receptor (PR) and smooth muscle actin (SMA) [2, 8] [15]. Vimentin, smooth muscle actin, desmin, ER and PR expression is present in 80% of the cases. Low Ki-67 proliferative index is noted in PBML with ratios reported to be 2.3% and 2.9% in two different studies. Ki-67 expression in leiomyosarcoma (LMS) was reported as 28.6% and 11%. [16], In Our patient Ki-67 was reported as less than 5%. Deletion in the longer arm of chromosomes 19 and 22 is frequently noticed in LMS but not in BML [4]. Our patient did not have deletions in chromosome 19, which supports the diagnosis of BML. Identical clone molecular studies on BML and leiomyoma were reported in the literature [4] [17] .

Although there is no standard treatment known but surgical resection of the pulmonary nodules is preferred [11]. Unresectable pulmonary nodules can be treated medically with hormonal manipulation (using anastrozole, tamoxifen, raloxifene, progesterone GnRH agonists) or surgically (bilateral oophorectomy) [9, 18]. Our patient's pulmonary nodules were deemed unresectable and so she was treated with hormonal manipulation and achieved an excellent clinical response.

Conclusion:

Pulmonary benign metastasizing leiomyoma is rare benign disease. It should be considered as the probable diagnosis in a female patient with pulmonary nodules and a previous history of surgery for

leiomyoma of uterus. Pathological differentiation from leiomyosarcoma and other malignant metastatic condition is essential. Prognosis of PBML after surgical and/ or hormonal treatment is good.

References

1. Steiner P. Metastasizing fibroleiomyoma of the uterus: Report of a case and review of the literature. *Am J Pathol.* 1939, 15
2. Awonuga AO, Shavell VI, Imudia AN, Rotas M, Diamond MP, Puscheck EE. Pathogenesis of benign metastasizing leiomyoma: A review. *Obstetrical & Gynecological Survey.* 2010, 65:189-195
3. Vaquero ME, Magrina JF, Leslie KO. Uterine smooth-muscle tumors with unusual growth patterns. *Journal of Minimally Invasive Gynecology.* 2009, 16:263-268
4. Patton KT, Cheng L, Papavero V. Benign metastasizing leiomyoma: Clonality, telomere length and clinicopathologic analysis. *Mod Pathol.* 2006, 19
5. Latif MF SM, Osman B and Azam F. Benign pulmonary metastasizing leiomyoma of uterus presenting as malignancy of unknown origin, a diagnostic dilemma. *Austin J Med Oncol.* 2015,
6. RA P. Pathologic considerations of uterine smooth muscle tumors. *Obstetrics and Gynecology Clinics of North America.* 1995,
7. Robboy SJ, Bentley RC, Butnor K, Anderson MC. Pathology and pathophysiology of uterine smooth-muscle tumors. *Environmental Health Perspectives.* 2000, 108:779-784
8. Fu Y, Li H, Tian B, Hu B. Pulmonary benign metastasizing leiomyoma: A case report and review of the literature. *World Journal of Surgical Oncology.* 2012, 10:1-4
9. Rivera JA, Christopoulos S, Small D, Trifiro M. Hormonal manipulation of benign metastasizing leiomyomas: Report of two cases and review of the literature. *J Clin Endocrinol Metab.* 2004, 89
10. Jautzke G, Müller-Ruchholtz E, Thalmann U. Immunohistological detection of estrogen and progesterone receptors in multiple and well differentiated leiomyomatous lung tumors in women with uterine leiomyomas (so-called benign metastasizing leiomyomas): A report on 5 cases. *Pathology - Research and Practice.* 1996, 192:215-223
11. Chen S. Pulmonary benign metastasizing leiomyoma: A case report and literature review. *J Thorac Dis.* 2014,
12. Sapmaz F. Benign metastasizing leiomyoma. *Lung.* 2008,
13. Horstmann JP, Pietra GG, Harman JA, Cole NG, Grinspan S. Spontaneous regression of pulmonary leiomyomas during pregnancy. *Cancer.* 1977, 39:314-321
14. Nakajo M, Nakayama H, Sato M, Fukukura Y, Nakajo M, Kajiya Y, Yanagi M, Tabata K, Higashi M. Fdg-pet/ct finding of benign metastasizing leiomyoma of the lung. *Acta Radiologica Short Reports.* 2012, 1
15. Kayser K, Zink S, Schneider T. Benign metastasizing leiomyoma of the uterus: Documentation of clinical, immunohistochemical and lectin histo-chemical data of ten cases. *Virchows Arch.* 2000, 437
16. Kwon Y-I, Kim T-H, Sohn JW, Yoon HJ, Shin DH, Park SS. Benign pulmonary metastasizing leiomyomatosis: Case report and a review of the literature. *The Korean journal of internal medicine.* 2006, 21:173-177
17. Tietze L, Günther K, Hörbe A, Pawlik C, Klosterhalfen B, Handt S, Merkelbach-Bruse S. Benign metastasizing leiomyoma: A cytogenetically balanced but clonal disease. *Human pathology.* 2000, 31:126-128
18. Mogi A, Hirato J, Kosaka T, Yamaki E, Kuwano H. Benign metastasizing leiomyoma of the lung: Report of a case. *General thoracic and cardiovascular surgery.* 2013, 61:719-722