

**Case Report**

# Metastatic Eccrine Porocarcinoma Respond to Combination Chemotherapy Docetaxel, Cisplatin and Infusion 5 FU with Long Disease Control

Hussein Khaled and Rasha Abo EL Hassan

Adult Oncology Unit, Nasser Institute Oncology Center, Egypt

**Abstract**

**Introduction:** Eccrine porocarcinoma (EPC) is a rare tumor. It develops from the intraepidermal ductal portion of the eccrine sweat gland. Many chemotherapeutic agents were reported to have efficacy in treatment of metastatic EPC; two of very effective agents were docetaxel and 5FU.

**Case Presentation:** We are reporting a case of 60 years old female who was diagnosed as metastatic eccrine porocarcinoma to mediastinum which was treated by systemic chemotherapy in the form of DCF: docetaxel 75 mg/m<sup>2</sup> D1, cisplatin 75 mg/m<sup>2</sup> D1 and continues infusion 5FU 750 mg/m<sup>2</sup> from D1 to D4, and this regimen was repeated every 28 days for 6 cycles.

**Conclusion:** DCF regimen can be one of the best options for stage IV EPC with long overall survival and best response rate.

**Keywords:** Metastatic Eccrine porocarcinoma; DCF; long disease control

**Academic Editor:** Xiaoning Peng, Hunan Normal University School of Medicine, China

**Received:** November 14, 2014; **Accepted:** December 24, 2014; **Published:** January 23, 2015

**Competing Interests:** The authors have declared that no competing interests exist.

**Consent:** We confirm that the patient has given the informed consent for the case report to be published.

**Copyright:** 2014 Hassan RA EL *et al.* This is an open-access article distributed under the terms of the Creative Commons Attribution License, which permits unrestricted use, distribution, and reproduction in any medium, provided the original author and source are credited.

**\*Correspondence to:** Rasha Abo EL Hassan, Adult Oncology Unit, Nasser Institute Oncology Center, Egypt; Email: [elsayedonco@hotmail.com](mailto:elsayedonco@hotmail.com)

## Introduction

Eccrine porocarcinoma EPC of sweat gland is a rare tumor, representing about 0.01% of all cutaneous tumors it is believed to arise from the intra-epithelial portion of eccrine sweat glands, first described by Pinkus and Mehregan in 1963 as an uncommon sweat gland carcinoma and the malignant counterpart of eccrine poroma [1, 2, 5].

Because of the rarity and nonspecific appearance of EPC, a tentative clinical diagnosis will never be accurate and the condition might be misdiagnosed as squamous cell carcinoma, basal cell carcinoma, seborrheic keratosis, or metastatic adenocarcinoma [5].

It was previously reported that trunk and abdominal eccrine porocarcinoma presents - 24% of cases [6], in some other reports, the predilection site is the lower extremities (55%), followed by the head and scalp (20%), upper limbs (12%), and trunk and abdomen (10%) [7].

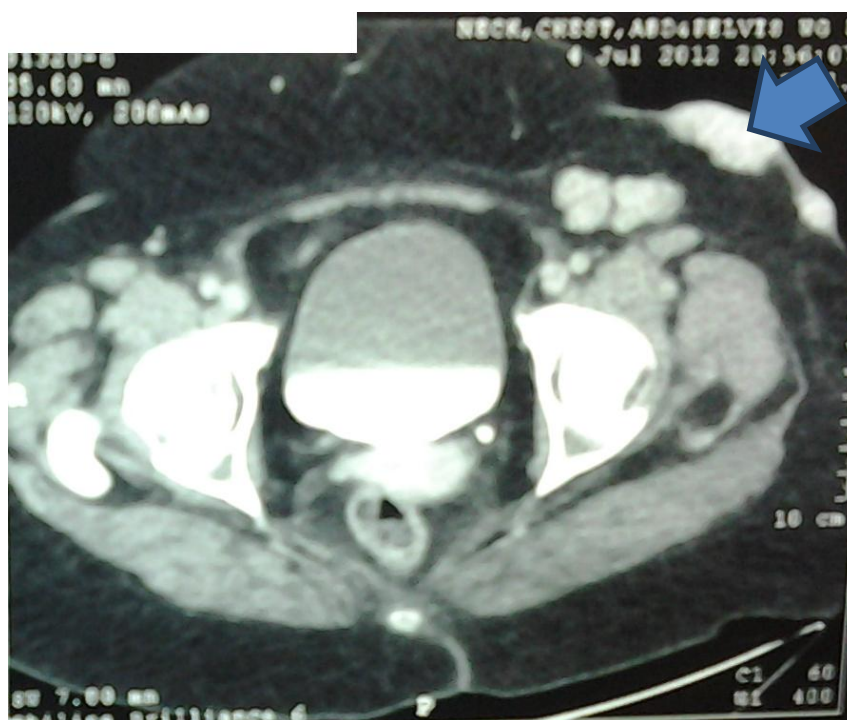Many combinations of chemotherapeutic agents were used in eccrine porocarcinoma of sweat gland [8, 9], recently one of the most reported effective agent is docetaxel [8].

In our case, we used combination of DCF which resulted in radiological complete remission and long period of disease free survival and overall survival.

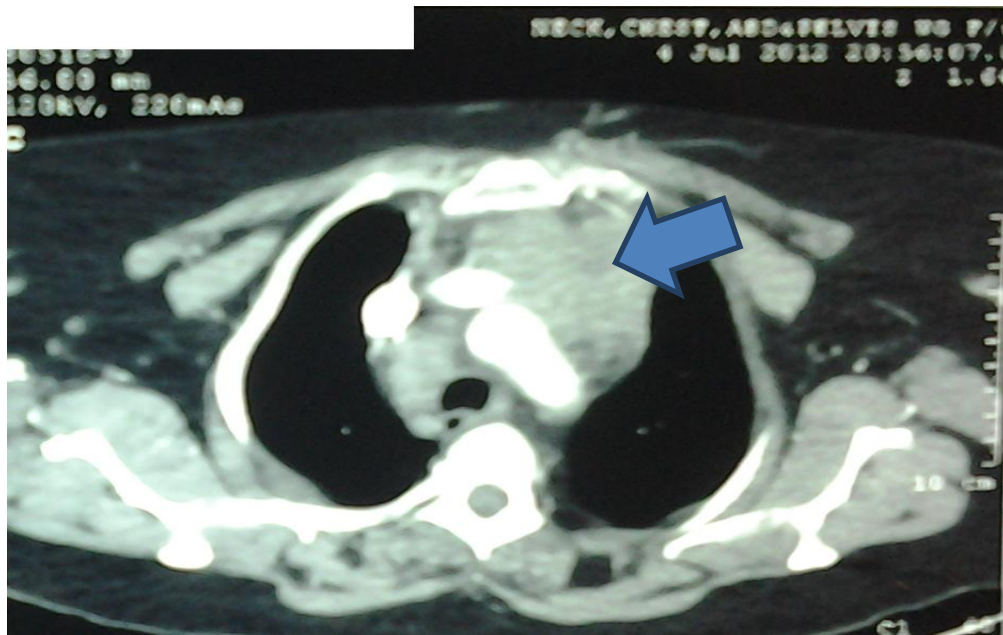
## Case report

Female patient 60 years old visited Nasser institute adult oncology unit for post-operative treatment after surgery of left groin skin lesion

The patient had a history of 11 months of painless left groin skin lesion progressive in size associated with surface ulceration The patient was not diabetic or hypertensive, she had no past history of chronic illness.



**Figure 1** Primary skin lesion 2012



**Figure 2** Mediastinal lesions before chemotherapy

### **Radiological picture:**

**CT examination was done for neck, chest, abdomen and pelvis showing:** Figs. 1, 2. The primary skin lesion in the form of ulcerative soft tissue mass measuring: 4×9×5 cm at the left groin with intact adjacent fat planes and no radiological evidence of intra-pelvic extension, multiple small inguinal lymph nodes were noted.

Also there was an enlarged amalgamated mediastinal lymphnodes 10×7.5×7 cm encasing blood vessels, with no calcification or lung nodules, The patient underwent surgery; complete excision of skin primary only was done on July 2012 under general anesthesia.

### **Pathological picture:**

**Gross picture** of large globular piece of firm, grayish yellow tissue measured 18.0×10.5×10.0 cm with covered skin ellipse measured 16.0×8.0 cm, outer surface was irregular, multiple and nodular masses. Serial cut section was homogeneously solid, with multiple variable sized nodules of matted lymphoid nodules with friable areas of necrosis.

### **Microscopic picture:**

histo-pathological examination of multiple serial section of the spacemen prepared revealed the replacement of the tissue by multiple scattered islands of moderately pleomorphic columnar looking epithelial cells with poor attempt at acinar formation and no attempts at cell nest formation. The cells showing moderate degree of cellular anaplasia, in the form of modest amount of foamy, bubbly cytoplasm, large hyper chromatic and pleomorphic nuclei with focally prominent nucleoli.

**Immunohistochemistry:** The tumor cells were strongly positive for CK7, and moderately positive for p63.

The same tumor cell were negative for CK 20, monoclonal CEA and napsin The final histopathological diagnosis was: POROCARCINOMA OF SWEAT GLAND ORIGIN.

Our final diagnosis was metastatic porocarcinoma of sweat gland to mediastinal lymph node.

### Treatment and follow up:

#### 1- First line treatment:

Primary treatment began on august 2012 by chemotherapy: DCF every 28 days for 3 cycles:

This combination chemotherapy composed of: cisplatin 75 mg/m<sup>2</sup> D1, docetaxel 75 mg/m<sup>2</sup> D1 and 5FU 750 mg/m<sup>2</sup> D1 to D4 continuous infusion

After three cycles the patient had radiological partial remission and she continued up to 6 cycles, and that was followed by radiological CR (Fig. 3). Then follow up was done every 12 weeks up to 9 months when the patient presented by new skin lesion 1×1 cm at the end of scar.

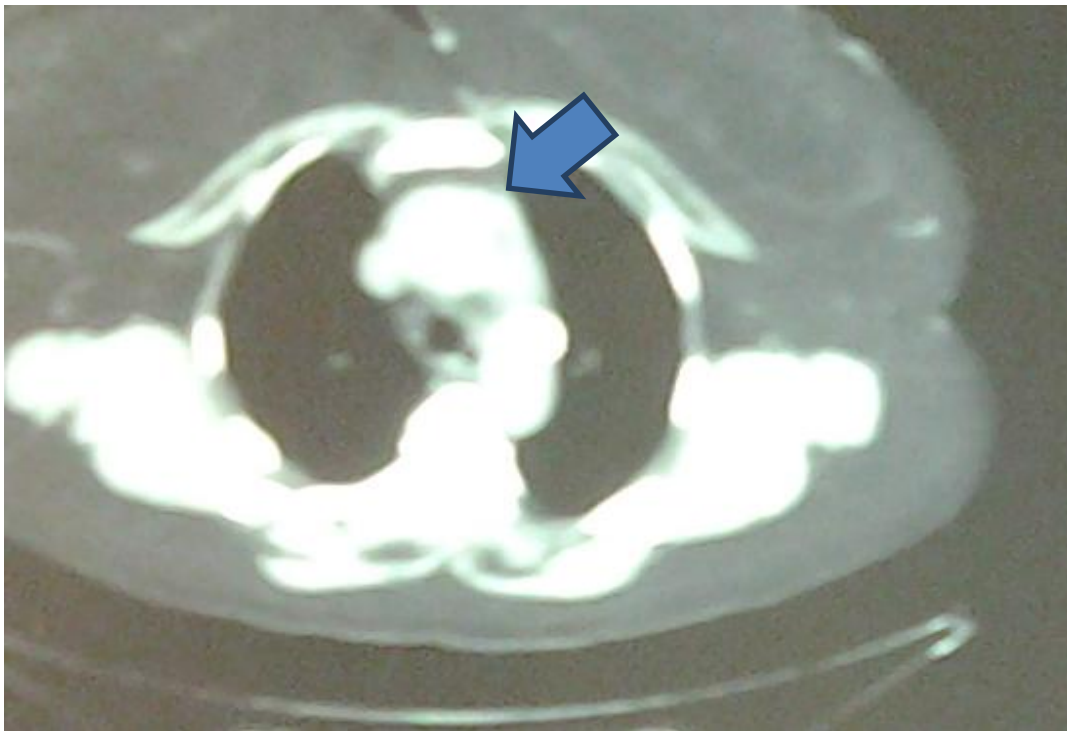


Figure 3 Mediastinal lesion disappeared post DCF chemotherapy

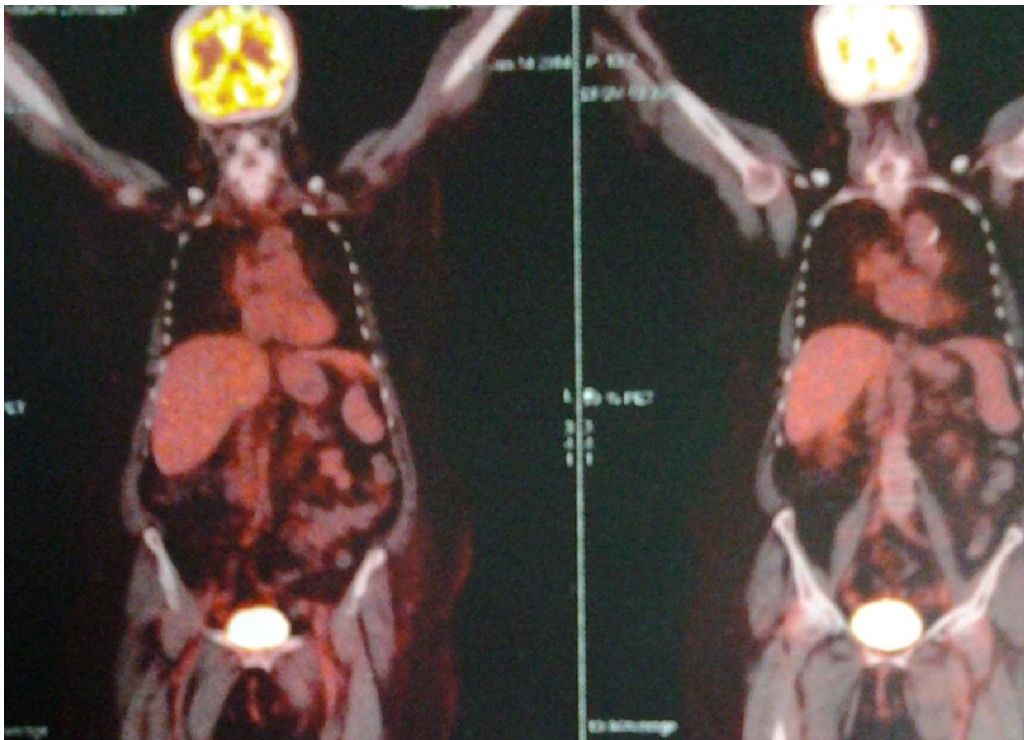
#### 2- Management of local recurrence:

CT neck, chest, abdomen and pelvis was showing no evidence of distant relapse. Total complete excision was done and showing the same histological and clinical picture of the primary.

Local recurrence was treated by local radiotherapy after complete excision with safety margins: 3 DCRT in a dose of 2000cGY 5 fractions in one week.



Positron emission tomography PET CT was done showing complete remission (Fig. 4). 6 months later, the patient presented again by second local recurrence and pelvic lymph node metastases,



**Figure 4** PET CT with no metastases post DCF chemotherapy

### 3- Management of second relapse:

There was no radiological evidence of distant metastases during the second relapse and again complete excision was done with lymph node dissection showing the same pathological diagnosis, and she is still on followup till October 2014.

## Discussion

EPC is still can be considered a rare tumor, there is no classic guidelines for treatment till now, most reported cases were showing different disease courses.

Large case series by Robson et al. [3] 69 EPC cases reported that local recurrence, lymph node metastasis, and distant metastasis were confined to 17, 20, and 10% of the cases, respectively, and concluded that aggressive behavior may be the exception, similarly, other authors reported indolent biological behavior in EPC [4].

Our case was presented at the beginning by metastatic mediastinal lymph nodes Figs. 1, 2 which appear consistent with the 20% of reported cases. It was also reported that multi-nodularity, ulceration and rapid growth may be associated with local recurrences or metastasis [3], which was consistent to the local recurrence that occurred in our case after reaching radiological complete remission by systemic chemotherapy.

Combination chemotherapy regimens using doxorubicin and cyclophosphamide and doxorubicin,

cyclophosphamide, and 5-fluorouracil have resulted in two partial responses in carcinoma of sweat gland. These responses lasted 8 and 4+ months and occurred in soft tissues and lungs [9].

Docetaxel was first used for treatment of metastatic sweat gland carcinoma on 2001 by Plunkett *et al.* [8] with good response for three months.

In our case we used combination of docetaxel with cisplatin and 5FU continuous infusion which resulted in radiological complete remission, Fig. 3, 4 and long period of overall survival and disease free survival.

Our case highlights that DCF regimen is the one of the most effective chemotherapy for systemic disease control 9 months and best response rate in the form of radiological complete remission with overall survival above 24 months,

## Conclusion

DCF regimen can be considered as one of the most effective regimens in treatment of metastatic porocarcinoma of sweat gland, further investigation and larger studies of EPC should be to put guidelines for treatment.

## Acknowledgment

Authors would like to acknowledge Prof Ahmed Badran, Prof of surgery for his great effort that that had done for this patient during and after period of surgery.

We also would like to thank all the team of medical and paramedical workers in Nasser institute oncology center who helped to reach this result of treatment.

Also we would like to thank Prof Illia Anis Prof of pathology in Cairo University, for his participation in this case by tissue diagnosis and IHC.

And before everything we would like to thank our patient for her kindness approval to publish her case.

## References

1. Pinkus H, Mehregan AH: Epidermotropic eccrine carcinoma. *Arch Dermatol.* 1963;88:597-606
2. Marone U, Caracò C, Anniciello AM, Di Monta G, Chiofalo MG, Di Cecilia ML, Mozzillo N. Metastatic eccrine porocarcinoma: report of a case and review of the literature. *World J Surg Oncol.* 2011, 9:32
3. Robson A, Greene J, Ansari N, Kim B, Seed PT, McKee PH, Calonje E. Eccrine porocarcinoma (malignant eccrine poroma): a clinicopathologic study of 69 cases. *Am J Surg Pathol.* 2001;25:710-720
4. Mehregan AH, Hashimoto K, Rahbari H: Eccrine adenocarcinoma. A clinicopathologic study of 35 cases. *Arch Dermatol.* 1983, 119:104-114
5. Sung Hoon Choi, Young Joon Kim, Hoon Kim1, Hyun-Jung Kim, Sang Hyun Nam, Young Woong Choi. *Archives of plastic surgery.* 2014, 41
6. Shiohara J, Koga H, Uhara H, Takata M, Saida T. Eccrine porocarcinoma: clinical and pathological studies of 12 cases. *J Dermatol.* 2007, 34:516-22
7. Huet P, Dandurand M, Pignodel C, and Guillot B. Metastasizing eccrine porocarcinoma: report of a case and review of the literature. *Journal of the American Academy of Dermatology.* 1996, 35: 860-864
8. Plunkett TA, Hanby AM, Miles DW, and Rubens RD. Metastatic eccrine porocarcinoma: response to docetaxel (Taxotere) chemotherapy. *Annals of Oncology.* 2001, 12:411-414
9. Coonley CJ, Kelsen DP, Huvos AG, Schaner P, Sordillo P: Chemotherapy of metastatic sweat gland carcinoma. A retrospective review. *Am J Clin Oncol.* 1985, 8:307-311