



## Case Report

# Papillary Thyroid Microcarcinoma Presenting as Horner's Syndrome: A Novel Clinical Presentation

Ammara Ashraf, Asad Azim,  
Khwaja Muhammad Azim, and Talat Waseem\*

Department of Surgery, Shalamar Medical & Dental College, Lahore, Pakistan

**Abstract**

**Background:** There is considerable worldwide rising incidence of slow growing Papillary Thyroid Microcarcinoma (PTMC) due to increasing availability of modern imaging tools. Cervical lymph node metastasis still remains the most frequent site of its metastasis. Here we present a rare case of PMC resulting in Horner's syndrome, which to our knowledge is the first case in the history of known medical literature.

**Case Report:** A 32 years old male presented with right posterior triangle cervical lymphadenopathy, drooping of right eyelid and anhidrosis for last 3 years. Biopsy of the swelling revealed metastatic papillary thyroid carcinoma. US neck and computerized tomography showed a mass in the right supraclavicular region closely adherent to the common carotid and the stellate ganglion area without any significant pathology within thyroid and the lung. The patient underwent total thyroidectomy with type II block neck dissection. The specimen revealed microscopic foci of papillary thyroid carcinoma involving right lobe, largest focus measuring 0.2cm. Cervical lymph nodes of level II were negative for cancer metastasis however level III, IV and V were positive for metastasis. Patient underwent I131 radio-ablation postoperatively and is disease free since operation.

**Conclusion:** Here we demonstrate a novel presentation of the PTMC inform of Horner's syndrome and give brief review of literature regarding presentation of PTMC.

**Keywords:** Horner's syndrome; Papillary Thyroid Microcarcinoma; lymphadenopathy; Thyroid cancer

**Academic Editor:** Xiaoning Peng, Hunan Normal University School of Medicine, China

**Received:** February 15, 2016; **Accepted:** April 18, 2016; **Published:** May 23, 2016

**Competing Interests:** The authors have declared that no competing interests exist.

**Consent:** Consent was taken from the patient for publication of this case report.

**Copyright:** 2016 Waseem T *et al.* This is an open-access article distributed under the terms of the Creative Commons Attribution License, which permits unrestricted use, distribution, and reproduction in any medium, provided the original author and source are credited.

\***Correspondence to:** Talat Waseem, Department of Surgery, Shalamar Medical & Dental College, Lahore, Pakistan

**E-mail:** [twaseem@gmail.com](mailto:twaseem@gmail.com)

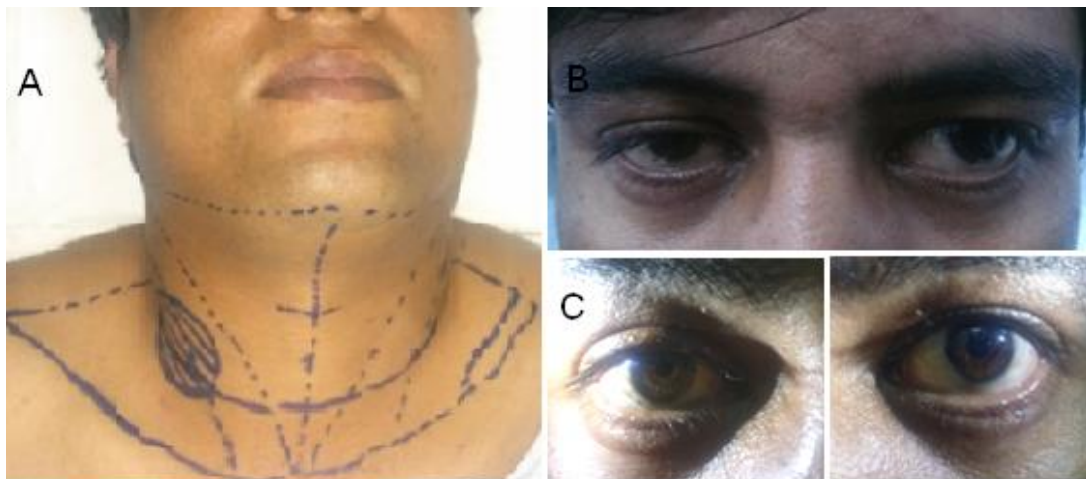## Introduction

Papillary thyroid microcarcinoma (PTMC) is defined as a small tumor that measures less than or equal to 1cm in diameter [1]. It is often undetected on clinical examination and found incidentally after thyroidectomy performed for other reasons or during a thyroid ultrasound exploration [1, 2]. PTMC can either be incidentally detected or remains occult. The average prevalence of PTMC is around 10% with a wide range 2.0–35.6% [3-7]. The clinical behavior of these tumors tends to be indolent with an excellent prognosis. Most of the series have reported a very low mortality rate between 0% and 0.4% [8-14]. Regardless of form of presentation PTMC, multicentricity, bilaterality, and minor extrathyroidal invasion are found with the same frequency as clinical PTCs, while lymph node metastases and distal metastases occur with lower frequency [8-13]. The optimal management of PTMC patients can range from observation without surgery based on a recent clinical trial carried out by Japanese authors [10-15] to total thyroidectomy with neck dissection followed by radioiodine treatment depending on the presence of aggressive characteristics [16,17].

Here we present an interesting case of occult PTMC, which presented with right sided cervical lymphadenopathy and Horner's Syndrome.

## Case Report

A 32-year-old male patient came to our department with complaints of right posterior triangle mass of the neck, drooping of right eyelid and anhydrosis of ipsilateral half of face for last 3 years. There was no significant family history of thyroid cancer.

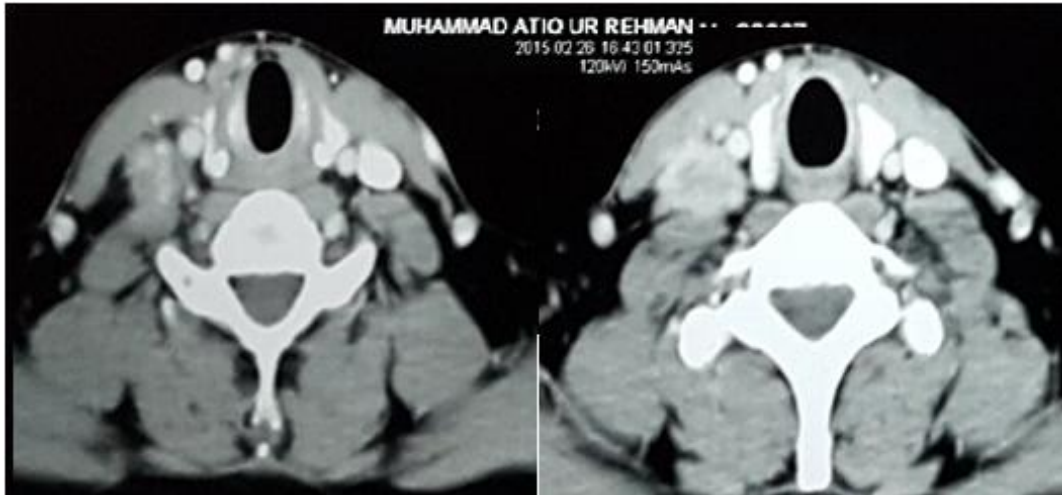

**Figure 1** A. Preoperative markings of the neck showing mass and involved lymph nodes in the patient. B. shows the right sides ptosis and C. shows the right sided papillary constriction as opposed to left.

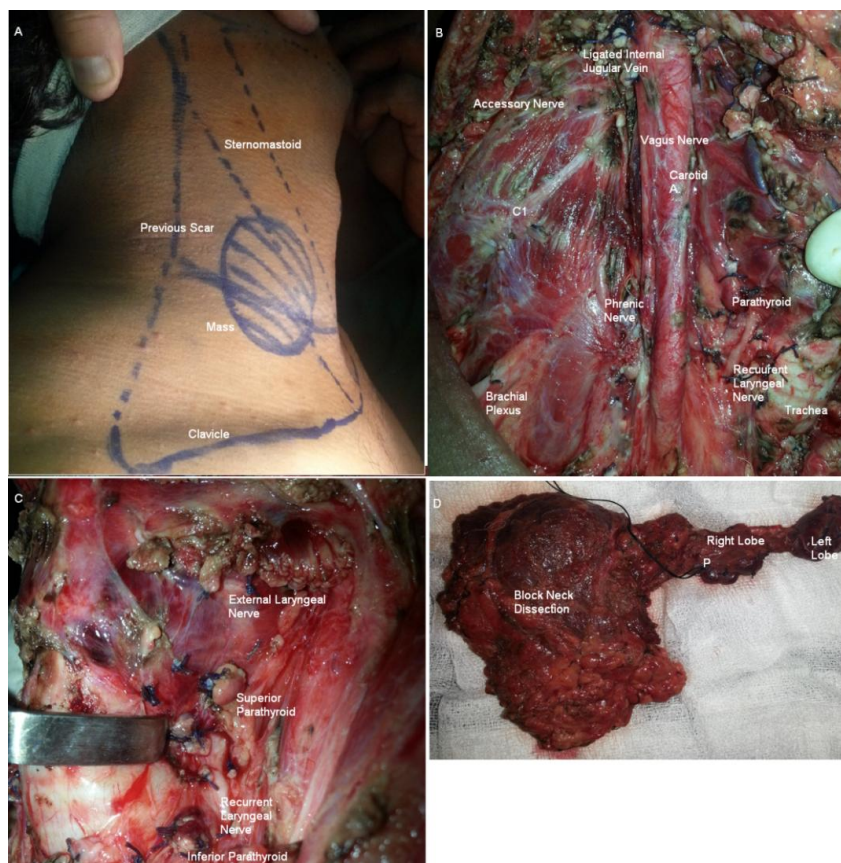
Examination of neck revealed a swelling located on right lower aspect of neck, which was hard, immobile with irregular margins. Multiple matted and discrete hard-enlarged lymph nodes were also found. On ophthalmic examination there was mild asymmetry of pupillary diameter, right being less than left, decreased palpebral aperture and negative starch test, all suggesting the diagnosis of Horner's Syndrome. FNAC of the mass revealed metastatic papillary thyroid carcinoma after which

further workup was done.

Ultrasound and CT scan of chest and neck showed a mass in the right posterior triangle region associated with cervical lymphadenopathy of level 3, 4 and 5. Thyroid gland was essentially normal on radiological grounds and no evidence of Pancoast tumor was noted (Figure 2).



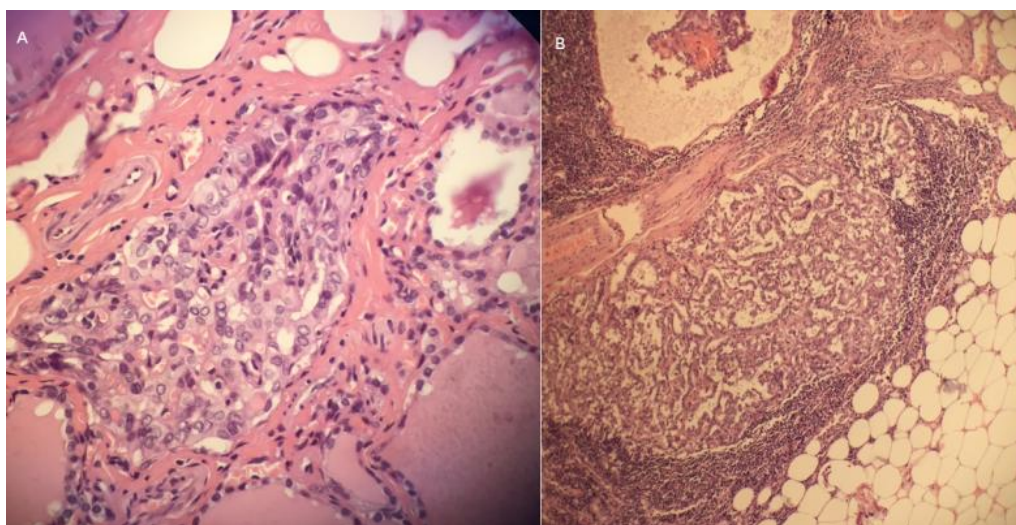
**Figure 2** shows the mass in the right suprclavicular region associated with cervical lymph node metastasis.



**Figure 3** A. shows marking of the mass. B. & C. show right and left side of neck following total thyroidectomy and right sided block neck dissection. D shows resected specimen following block neck dissection. Silk thread (P) in the right lobe marks the suspicious area for malignancy in the thyroid.

Clinical, Cytological and Imaging data collectively supported the possibility of papillary thyroid cancer with lymph node metastasis. Total Thyroidectomy with type II block neck dissection was done with predictable safety of parathyroids and recurrent laryngeal nervi. Figure 3 shows the resected specimen with silk thread marking the suspicious area of right lobe of thyroid.

Histological analysis (Figure 4) showed multiple microscopic foci of papillary thyroid carcinoma involving right lobe, largest focus measuring 0.2cm. Left lobe and Isthmus were normal. 13 level-II lymph nodes were negative for metastasis, 4 out of 19 level-III were positive for metastatic carcinoma of thyroid, 2 out of 6 level-IV were positive for metastatic carcinoma of thyroid and 1 out of 12 level-V was positive for metastatic carcinoma. Resection margins were clear of tumor. Postoperative period remained uneventful and patient was radio-ablated with I131. Patient is disease free following 2 year follow up.



**Figure 4** **A.** shows the small focus of Papillary Thyroid Microcarcinoma (PTMC) and **B.** shows metastasis within the representative lymph node.

## Discussion

Papillary Thyroid Microcarcinoma (PTMC), a small papillary thyroid tumor measuring less than 10 mm in size, is being increasingly diagnosed due to wider availability of modern diagnostics. Debate over the adequate treatment for this condition still remains open [8,14]. Despite smaller tumor size it has high incidence of lymph node metastasis ranging up to 50% urging many thyroid surgeons to opt for a very aggressive form of surgical treatment i.e total thyroidectomy with or without neck dissection depending on involvement of lymph nodes. The surgeons in favor of this aggressive form of treatment quote lower recurrence rate, unpredictable oncological behavior of tumor and better long term survival and this strategy seems reasonable in favor of better disease control. Conversely, a large series from the Mayo clinic advocates favorable results with relatively conservative approach for such smaller tumors citing a 10 year cause-specific mortality of these tumors to be just 1% [13,14]. This approach emphasizes the use of conservative surgical approach based on lesser postoperative complication profile related to total thyroidectomy, low cause-specific mortality, slow growing nature of the papillary tumors and similar survival curves. The later approach has several advantages and there is now developing consensus that smaller tumors can be managed adequately with relatively lesser radical approach in form of lobectomy and isthmectomy [13,14].

The problem lies with a smaller percentage of the patients with small tumors which exhibit higher

biological aggression and invasiveness. Many factors now have been localized which predict tumor aggression and hence favor use of relatively aggressive surgical approach. These factors include tumor size more than 5mm, multifocality, RET/PTC, BRAFV600E and TGF Beta 3 mutations and lymph node metastasis at the time of presentation [17]. A consensus yet remains to be generated on these lines after a detailed research on epidemiological behavior of the smaller papillary tumors.

Our current case belonged to this high risk group and the patient underwent total thyroidectomy considering the dilemma of not knowing where the primary is and secondly the aggressive biological behavior of the tumor as evident by massive lymph node involvement. This case highlights the fact that small size of the tumor alone is not sufficient information to go for a conservative surgical option and in future the genetic analysis of the mutations may be optimal strategy to decide the extent of surgery.

Second peculiarity of the case relates to the extensive lymph node metastasis in neck region to involve the stellate ganglion to cause Horner's syndrome. Horner's syndrome manifests as Miosis, hemifacial Anhidrosis, Ptosis and Enophthalmos. It is a syndrome caused by lesion of sympathetic chain at three different levels; 1st order central sympathetic fibers, 2nd order preganglionic pupillomotor fibers, and 3rd order postganglionic fibers. In our patient there was disruption of preganglionic fibers, which remains the most common site of lesion. The most common cause of Horner's syndrome is non-thyroidal malignancy including non-thyroidal lesions [18]. To our best knowledge we have not seen any known report in the medical literature to document a PTMC causing Horner's syndrome. Clearly in such cases it remains imperative to exclude other cause of the Horner's syndrome like Pancoast's Tumor which we did in this case.

Future research should focus on segregation of the PTMCs with higher invasive and aggressive potential based on genomic or mutational analysis. Till then total thyroidectomy would remain an appropriate treatment for even such smaller tumors in favor of better disease free survival and low recurrence rates.

## References

1. Arem MD, FACE, Ridha et al. Thyroid microcarcinoma: prevalence, prognosis, and management. *Endocrine Practice*. 1999, 5:148-156
2. Ezzat S et al. Thyroid incidentalomas: prevalence by palpation and ultrasonography. *Archives of internal medicine*. 1994, 154:1838-1840
3. Yamashita H et al. Thyroid cancer associated with adenomatous goiter: an analysis of the incidence and clinical factors. *Surgery Today*. 1997, 27:495-499
4. Rego-Iraeta A et al. Time trends for thyroid cancer in northwestern Spain: true rise in the incidence of micro and larger forms of papillary thyroid carcinoma. *Thyroid*. 2009, 19:333-340
5. Sakorafas GH et al. Microscopic papillary thyroid cancer as an incidental finding in patients treated surgically for presumably benign thyroid disease. *Journal of Postgraduate Medicine*. 53.1 (2007):23
6. Pelizzo MR et al. Papillary thyroid microcarcinoma (PTMC): prognostic factors, management and outcome in 403 patients. *European Journal of Surgical Oncology (EJSO)*. 2006, 32:1144-1148
7. Fink A et al. Occult micropapillary carcinoma associated with benign follicular thyroid disease and unrelated thyroid neoplasms. *Modern Pathology*. 1996, 9:816-820
8. Ito Y et al. An observation trial without surgical treatment in patients with papillary microcarcinoma of the thyroid. *Thyroid*. 2003, 13:381-387
9. Chow SM et al. Papillary microcarcinoma of the thyroid—prognostic significance of lymph node metastasis and multifocality. *Cancer*. 2003, 98:31-40

10. Ito Y *et al.* Clinical significance of metastasis to the central compartment from papillary microcarcinoma of the thyroid. *World journal of surgery.* 2006, 30:91-99
11. Baudin E, *et al.* Microcarcinoma of the thyroid gland. *Cancer.* 1998, 83:553-559
12. Ito Y, Miyauchi A. A therapeutic strategy for incidentally detected papillary microcarcinoma of the thyroid. *Nature Clinical Practice Endocrinology & Metabolism.* 2007, 3:240-248
13. Hay, Ian D *et al.* Ipsilateral lobectomy versus bilateral lobar resection in papillary thyroid carcinoma: a retrospective analysis of surgical outcome using a novel prognostic scoring system. *Surgery.* 1987, 102:1088-1095
14. Cooper DS *et al.* Revised American Thyroid Association management guidelines for patients with thyroid nodules and differentiated thyroid cancer: the American Thyroid Association (ATA) guidelines taskforce on thyroid nodules and differentiated thyroid cancer. *Thyroid.* 2009, 19:1167-1214
15. Roti E *et al.* Clinical and histological characteristics of papillary thyroid microcarcinoma: results of a retrospective study in 243 patients. *The Journal of Clinical Endocrinology & Metabolism.* 2006, 91:2171-2178
16. Wada N *et al.* Lymph node metastasis from 259 papillary thyroid microcarcinomas: frequency, pattern of occurrence and recurrence, and optimal strategy for neck dissection. *Annals of Surgery.* 2003, 237:399
17. Sugitani I and Fujimoto Y. Symptomatic versus asymptomatic papillary thyroid microcarcinoma: a retrospective analysis of surgical outcome and prognostic factors. *Endocrine Journal.* 1999, 46:209-216.
18. Leuchter I *et al.* Horner's syndrome and thyroid neoplasms. *ORL.* 2002, 64:49-52