



Case Report

Hepatocellular Carcinoma with Cutaneous Metastasis to Back : A Case Report

Sanghamitra Jena^{1*}, Sarbajit Das¹, Indranil Das²

¹ Department of Surgical Oncology, Saroj Gupta Cancer Centre and Research Institute, Kolkata, India

² Department of Pathology, Saroj Gupta Cancer Centre and Research Institute, Kolkata, India

Abstract

Introduction: Hepatocellular carcinoma (HCC) is the most common primary tumour of the liver. It mostly metastasise to lungs, followed by abdominal lymph nodes and bones. However, cutaneous metastases of HCC are very rare, accounting for 0.2% to 2.7% of all cutaneous metastases. The most common location is the head (usually the face), followed by the chest, the abdomen, and the limbs, but metastasis to back is very uncommon.

Presentation of Case: A 63 year old man presented with history of mild fatigue and right upper abdominal pain for two months and a swelling in the back for 15 days. He was diagnosed with hepatocellular carcinoma. With biopsy and immunohistochemistry, it was confirmed that the swelling in the back was a cutaneous metastasis from hepatocellular carcinoma, which is very rare.

Conclusion: Because cutaneous metastases are a very uncommon manifestation of HCC and metastasis to back is even more rare, the present case should increase awareness of their existence.

Keywords: Hepatocellular carcinoma; back; cutaneous; Metastasis

Academic Editor: Xiaoning Peng, Hunan Normal University School of Medicine, China

Received: September 2, 2014; **Accepted:** November 1, 2014; **Published:** December 4, 2014

Competing Interests: The authors have declared that no competing interests exist.

Consent: We confirm that family members of the patients have given their informed consents for the case report to be published.

Copyright: 2014 Jena S *et al.* This is an open-access article distributed under the terms of the Creative Commons Attribution License, which permits unrestricted use, distribution, and reproduction in any medium, provided the original author and source are credited.

***Correspondence to:** Sanghamitra Jena, Department of Surgical Oncology, Saroj Gupta Cancer Centre and Research Institute, MG Road, Thakurpukur, Kolkata, India; **Email:** docsalu@gmail.com

Introduction

Hepatocellular carcinoma (HCC) is the most common primary tumour of the liver. It is predominantly found in men 50-60 years of age, and is most commonly due to cirrhosis secondary to alcoholism, viral Hepatitis B or C, haemochromatosis, or autoimmune diseases.

Hepatocellular carcinoma metastasizes via blood, direct spread, or lymphatic dissemination. Extrahepatic metastasis of HCC has been reported in advanced disease, such as stage III and IV. In such cases, distant metastases occur from the primary site in the liver through the portal vein to the lungs most predominantly (55%), followed by abdominal lymph nodes (41%) and bones (28%) [1]. However, cutaneous metastases of HCC are very rare, accounting for 0.2% to 2.7% of all cutaneous metastases [2]. The most common location is the head (usually the face), followed by the chest, the abdomen, and the limbs [3], but metastasis to back is very uncommon.

Herein, we report a case of hepatocellular carcinoma with a cutaneous swelling in the back which on investigation was found to be metastasis from HCC.

Case History

A 63 year old man presented in May 2014 with history of mild fatigue and right upper abdominal pain for two months and a swelling in the back for 15 days. On clinical examination, there was hepatomegaly. The swelling in the back measured about 4cmx4cm [Figure 1]. It was soft in consistency, non tender and free from underlying structures. The skin over the swelling was normal.

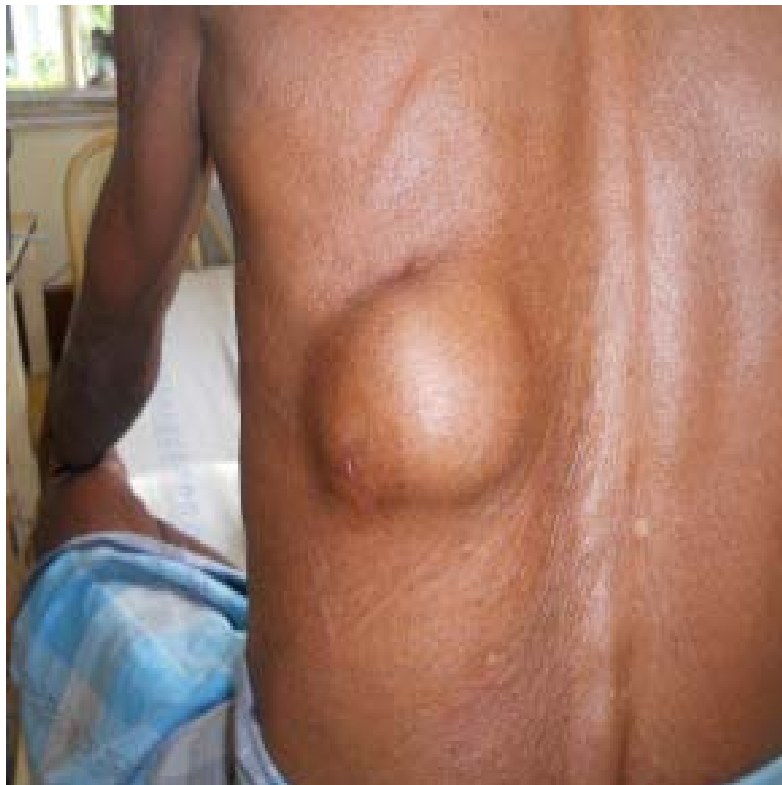

Figure 1 Clinical photograph of the patient with back lesion

Routine blood tests were carried out. Hemoglobin level was 12 g/dl (normal 13-17 g/dl), TLC and DLC and platelet count were within normal limits. Total bilirubin was 0.8 mg/dl (normal upto 1 mg/dl), SGPT - 73 U/L, SGOT - 140 U/L and Alkaline phosphatase - 675 U/L. His carcinoembryonic antigen (CEA) tumour marker level was 1.7 ng/ml (normal upto 3 ng/ml in non smokers) and alpha fetoprotein (AFP) was >1000 IU/ml (normal - 5.8 IU/ml). HBsAg test was positive, but HCV and HIV tests were negative. Computed tomography (CT) of the abdomen showed a large heterogenous space occupying lesion (SOL) of size 11 cm x 11 cm in the right lobe of the liver and a small hypodense lesion of size 2 cm x 2.4 cm in the left lobe [Figure 2]. Both the lesions had heterogenous enhancement.

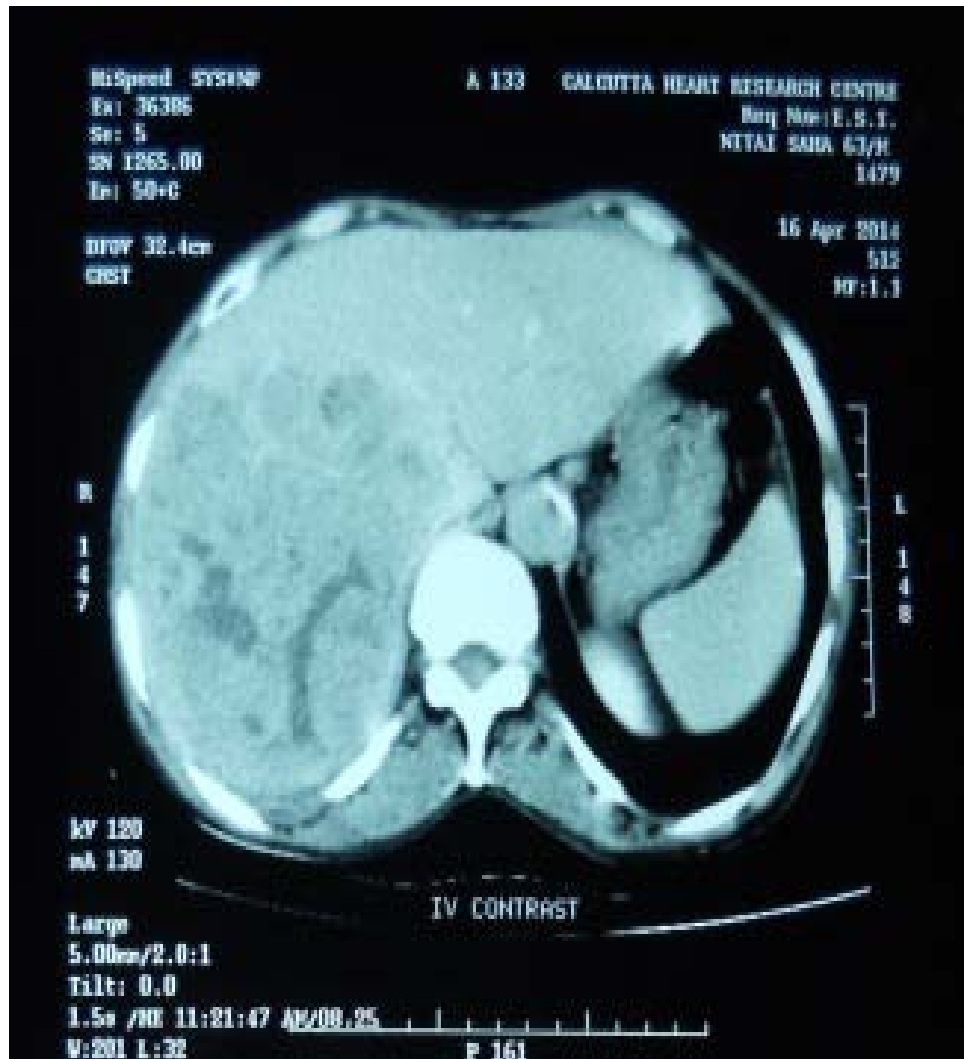

Figure 2 CT scan showing liver SOL

FNAC from the liver SOL showed clusters and discrete atypical cells having nucleomegaly, clumped chromatin, prominent nucleoli and abundant amount of cytoplasm which were consistent with hepatocellular carcinoma. Trucut biopsy from the swelling in the back revealed cutaneous metastasis from hepatocellular carcinoma [Figure 3]. The tumour cells were positive for CD10 and TTF-1 [Figure 4a & 4b] but negative for AFP, CD15, CEA and EMA.

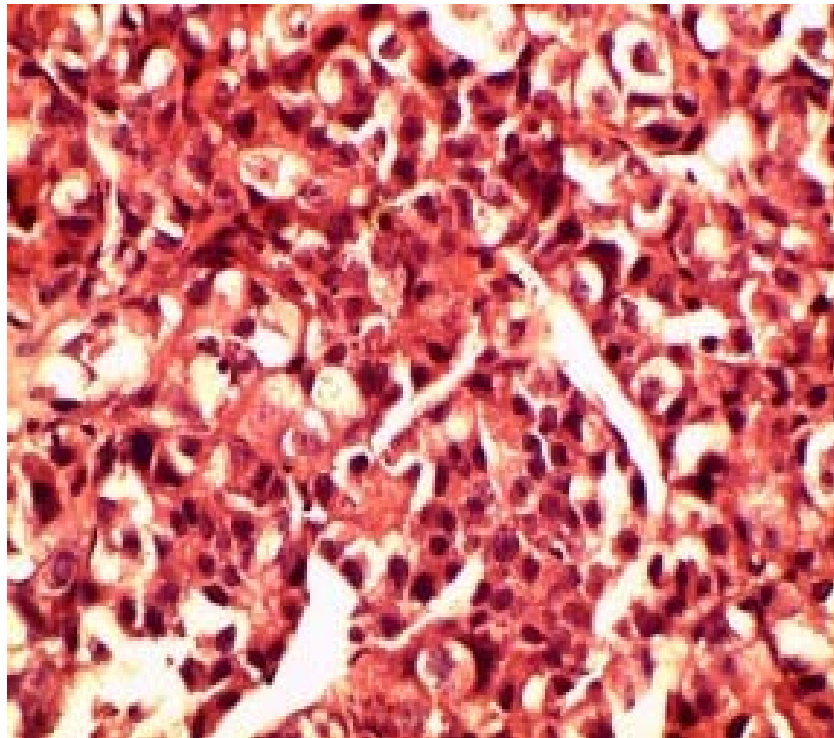


Figure 3 Histopathology of Trucut biopsy from back lesion ((haematoxylin-eosin stain 40 X)

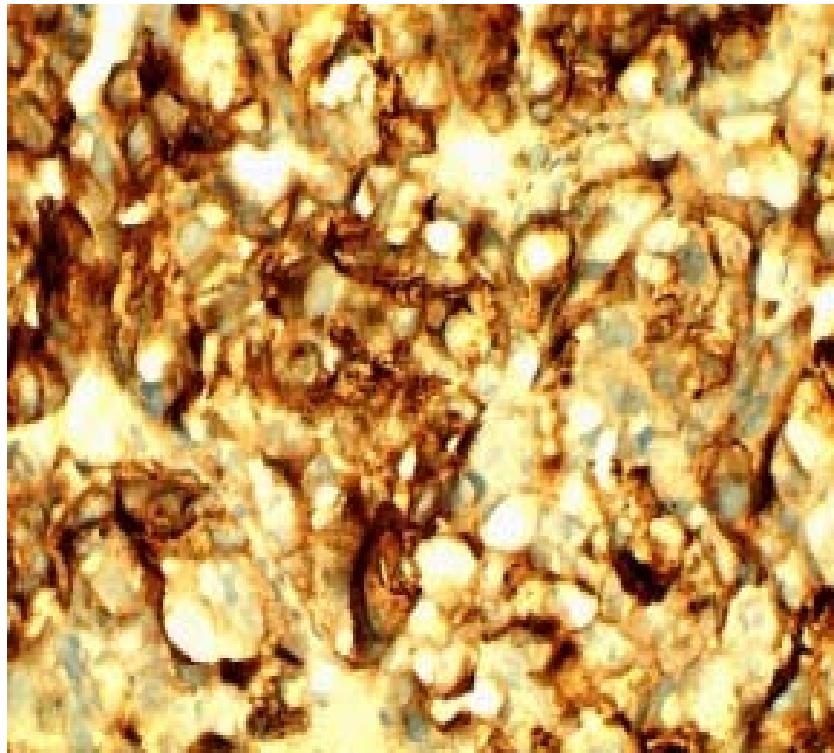


Figure 4a Tumor cells positive for CD 10

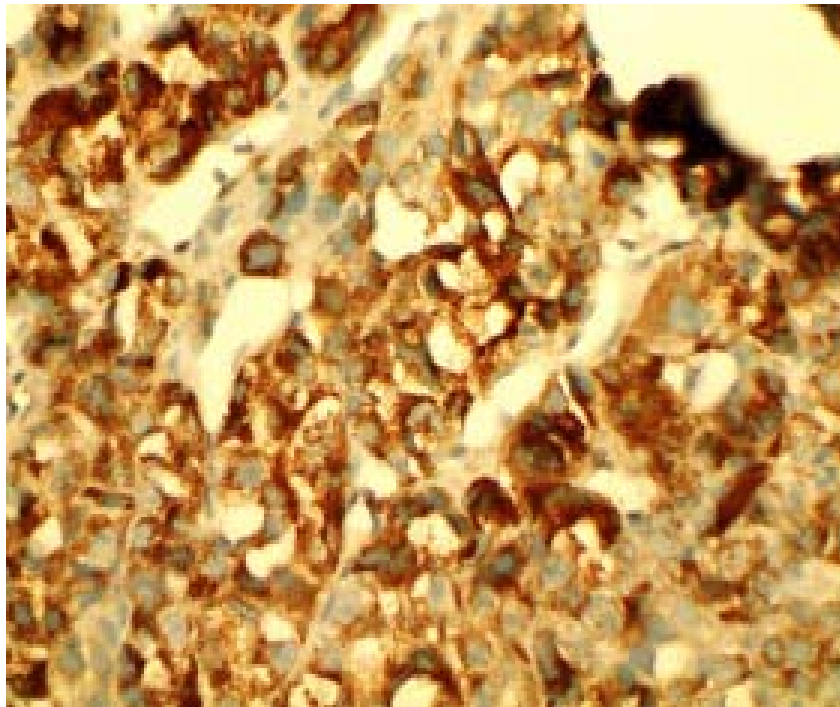


Figure 4b Tumor cells positive for TTF-1

In consideration of the disease stage (metastatic) and the patient's clinical status (Eastern Cooperative Oncology Group [ECOG] 1 - Child A), treatment with Sorafenib (800 mg/day) was carried out.

The patient is under follow-up and there is no increase in size of the lesion after two months of initiation of therapy.

Discussion

HCC is the most common primary malignant tumor of the liver, and its incidence has increased in recent years. It is predominantly found in men 50-60 years of age, and is most commonly due to cirrhosis secondary to alcoholism, viral Hepatitis B or C, haemochromatosis, or autoimmune diseases.

Hepatocellular carcinoma metastasizes via blood, direct spread, or lymphatic dissemination. Extrahepatic metastasis of HCC has been reported in advanced disease, such as stage III and IV. In such cases, distant metastases occur from the primary site in the liver through the portal vein to the lungs most predominantly (55%), followed by abdominal lymph nodes (41%) and bones (28%) [1]. However, cutaneous metastases of HCC are very rare, accounting for 0.2% to 2.7% of all cutaneous metastases [2]. These metastases can be the first manifestation of the primary tumor or, the first sign of disease recurrence [4]. Histopathological examination of the skin metastasis may reveal the identity of the primary tumor.

Cutaneous metastasis of HCC occurs most frequently in men over 50 years of age, usually in the sixth decade of life, and usually manifests as a single painless, fast-growing lesion. The most common

location is the head (usually the face), followed by the chest, the abdomen, and the limbs [3]. But this patient had metastasis to back which is very rare.

The lesions can take a variety of clinical forms but are usually firm, bluish-red or purple, 1 to 5 cm in diameter, and nonulcerated [2-5]. They may also be necrotic or purulent or resemble pyogenic granulomas [6].

Three different mechanisms by which a liver tumor can produce cutaneous metastases have been described: continuous growth from the liver parenchyma, systemic spread of disease, and tumor implantation or seeding following manipulation of the lesion using various diagnostic or therapeutic methods [7].

Histopathologic diagnosis is possible when a hepatocellular component-bile production in part of the tumor, intercellular bile canaliculi, or a trabecular growth pattern-is present [3]. From an immunohistochemical perspective, Hepatocyte paraffin 1 (HepPar-1), CD10, CEA and TTF-1 have proved to be very helpful in the diagnosis of poorly differentiated tumors [8,9]. In this patient, positivity of tumor cells for CD10 and TTF-1 helped us to reach the diagnosis.

The presence of cutaneous metastases of HCC is associated with a very poor prognosis, an increased likelihood of metastases at other sites, and a median survival of less than 5 months [10,11]. In this case the patient is surviving after two months of treatment with Sorafanib and is on regular follow-up.

Conclusion

Because cutaneous metastases are a very uncommon manifestation of HCC and metastasis to back is even more rare, the present case should increase awareness of their existence. The possibility of skin metastasis should be considered in HCC patients who present with skin lesions, and the diagnosis should be confirmed by biopsy.

Consent

The patient has given his informed consent regarding publication of his case.

References

1. Katyal S, Oliver JH 3rd, Peterson M, Ferris J, Carr B, Baron R. Extrahepatic Metastasis of hepatocellular carcinoma. *Radiology*. 2000, 216:698-703
2. Amador A, Monforte NG, Bejarano N, Martí J, Artigau E, Navarro S, et al. Cutaneous metastasis from hepatocellular carcinoma as the first clinical sign. *J Hepatobiliary Pancreat Surg*. 2007, 14:328-330
3. Magana M, Gomez LM. Skin metastasis from hepatocarcinoma. *Am J Dermatopathol*. 2009, 31:502-505
4. Royer MC, Rush WL, Lupton GP. Hepatocellular carcinoma presenting as a precocious cutaneous metastasis. *Am J Dermatopathol*. 2008, 30:77-80
5. Wood AJ, Lappinga PJ, Ahmed I. Hepatocellular carcinoma metastatic to skin: diagnostic utility of antihuman hepatocyte antibody in combination with albumin in situ hybridization. *J Cutan Pathol*. 2009, 36:262-266
6. Kubota Y, Koga T, Nakayama J. Cutaneous metastasis from hepatocellular carcinoma resembling pyogenic granuloma. *Clin Exp Dermatol*. 1999, 24:78-80

7. Martínez Ramos D, Villegas Cánovas C, Senent Vizcaíno V, Rodríguez Pereira C, Escrig Sos J, Ángel Yepes V, et al. Implante subcutáneo de un carcinoma hepatocelular tras la pun-ción aspiración con aguja fina. *Rev Esp Enferm Dig.* 2007, 99:354-357
8. Lugli A, Tornillo L, Mirlacher M, Bundi M, Sauter G, Terracciano LM. Hepatocyte paraffin 1 expression in human normal and neoplastic tissues: tissue microarray analysis on 3,940 tissue samples. *Am J Clin Pathol.* 2004, 122:721-727
9. Borscheri N, Roessner A, Rocken C. Canalicular immunostaining of neprilysin (CD10) as a diagnostic marker for hepatocellular carcinomas. *Am J Surg Pathol.* 2001, 25:1297-1303.
10. Asselah T, Condat B, Cazals-Hatem D, Hassani Z, Bernuau J, Groussard O, et al. Ectopic hepatocellular carcinoma arising in the left chest wall: a long-term follow-up. *Eur J Gastroenterol Hepatol.* 2001, 13:873-875
11. Okusaka T, Okada S, Ishii H, Nose H, Nagahama H, Nakasuka H, *et al.* Prognosis of hepatocellular carcinoma patients with extrahepatic metastases. *Hepatogastroenterology.* 1997, 44:251-257