

**Case Report**

# Parotid Adenoidcysticcarcinoma with Multiple Distant Skin Metastases: A Case Report

Serap Karaarslan<sup>1\*</sup>, Banu Yaman<sup>2</sup>, Uğur Çerçi<sup>3</sup>, Mehmet Hüsnu Buğdaycı<sup>1</sup>, and Ali Veral<sup>2</sup>

<sup>1</sup> Şifa University Pathology Department, Izmir, Turkey

<sup>2</sup> Ege University Pathology Department, Izmir, Turkey

<sup>3</sup> Şifa University Ear Nose Throat Department, Izmir, Turkey

**Abstract**

**Introduction:** Adenoid Cystic Carcinoma (ACC) is one of the malignancy and commonly seen in the minor salivary glands and hard palate. The lung is the most common hematogenous spread site, followed by the bones, liver and brain. Skin and skeletal muscle metastases are very rare.

**Case Presentation:** We present a 59-year-old male operated for a left parotid gland mass five years ago. The excision material was diagnosed as ACC. The patient developed lung metastases after about 10 months. Multiple small masses were noticed on the middle phalanxes of the right hand during a follow-up after five years and were excised. These masses were considered to be skin metastases of the parotid adenoid cystic carcinoma compared to the parotid excision.

**Conclusion:** Conclusion: Metastases of the ACC are most commonly seen in the lung, followed by the bone, liver and brain. However, skin and skeletal muscle metastases are rare. A thorough physical examination should be carried out in routine follow-ups and small lesions should not be ignored.

**Keywords:** AdenoidCysticCarcinoma; multipl metastases; skin; phalanxes

**Academic Editor:** Xiaoning Peng, Hunan Normal University School of Medicine, China

**Received:** June 30, 2014; **Accepted:** September 6, 2014; **Published:** September 23, 2014

**Competing Interests:** The authors have declared that no competing interests exist.

**Copyright:** 2014 Karaarslan S *et al.* This is an open-access article distributed under the terms of the Creative Commons Attribution License, which permits unrestricted use, distribution, and reproduction in any medium, provided the original author and source are credited.

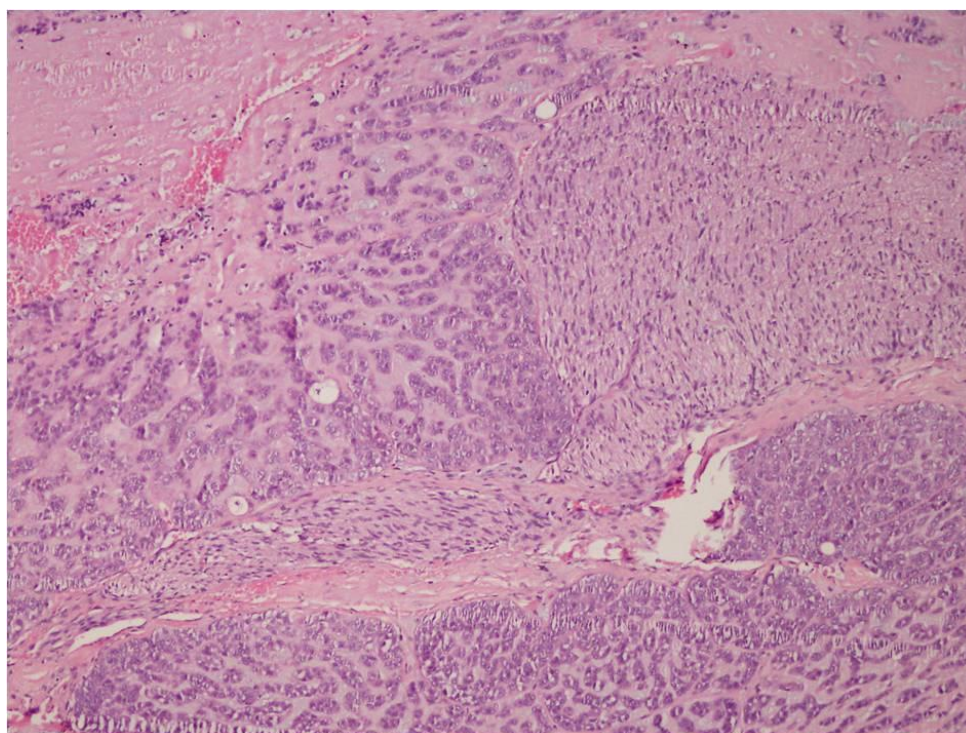
**\*Correspondence to:** Serap Karaarslan, Şifa University Pathology Department, Izmir, Turkey

## Introduction

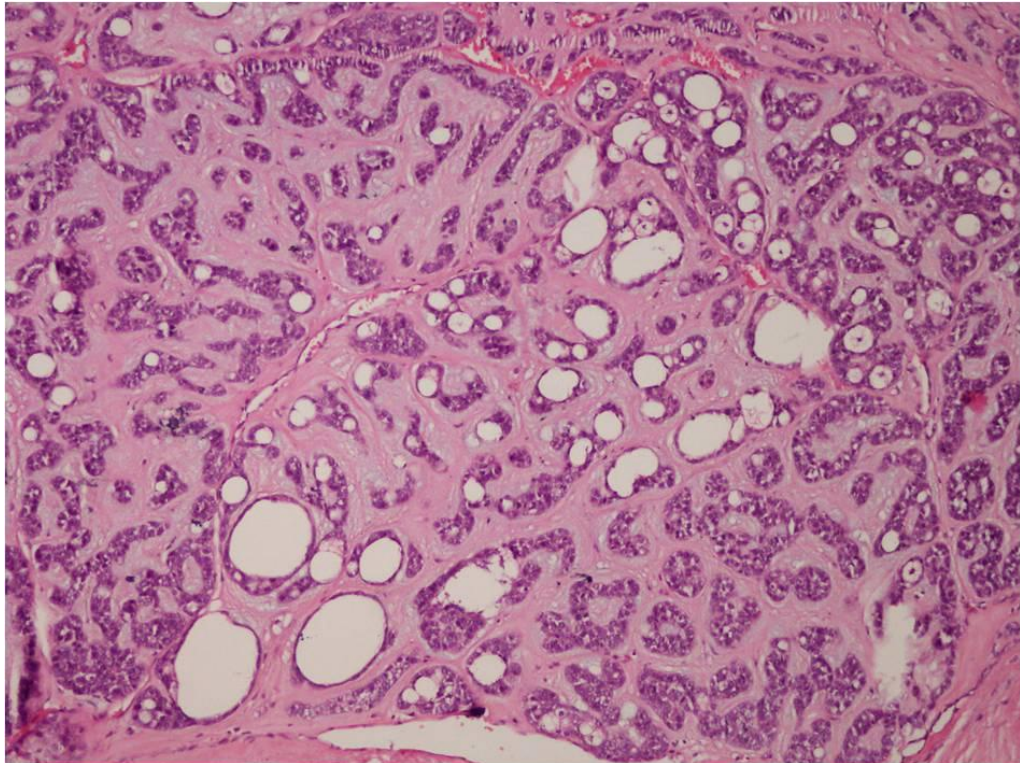
Adenoid Cystic Carcinoma (ACC) is a malignancy most commonly seen in the minor salivary glands and hard palate. It makes up 10-15% of malignant salivary gland tumors. It is less common in other regions. The incidence in the parotid is about 2-3% (1, 2, 3). The tumor was first defined by Robin et al in 1853-1854 and was named ACC in the 1930s (4). Hematogenous spread is common in the slow-growing tumor that has a tendency for perineural invasion and presents with recurrences (5,6). The distant organ metastasis rate for ACC is reported to be between 24% and 52%. Metastases most commonly involve the lung, followed by the bone, liver and brain. However, skin and skeletal muscle metastases are rare (7,8). The most important prognostic factors are tumor size and the presence of metastasis. It is a relatively favorable survival rate at five years. Few cases of skin metastases of head and neck ACC have been described in the English-language literature (7).

## Case presentation

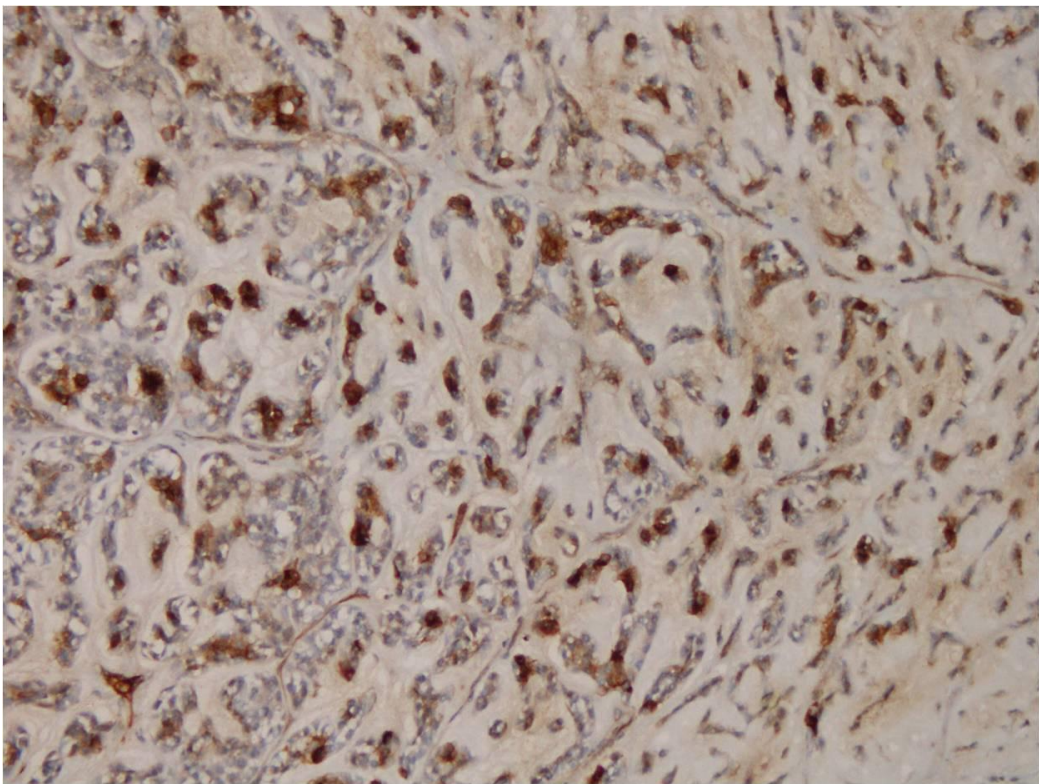
A 59-year-old male patient underwent excision for a mass in the left parotid gland five years ago. Macroscopically the parotid gland tumor was 6.5 cm in diameter. Microscopically a tumor with tubular structure on a fibromyxoid background and perineural infiltration. Cribriform pattern formation was noticed in some areas besides the tubular pattern and perineural invasion was identified (Figure 1A-B). Immunohistochemical (IHC) analysis revealed positivity for smooth muscle actin, S-100, CD117 and p53, whereas M-CEA was negative (Figure 1C-D). Ki-67 proliferation index was 20%. With this findings it was diagnosed with ACC. After 10 months from the diagnoses lung metastasis were developed. The patient had no other solid organ metastasis.



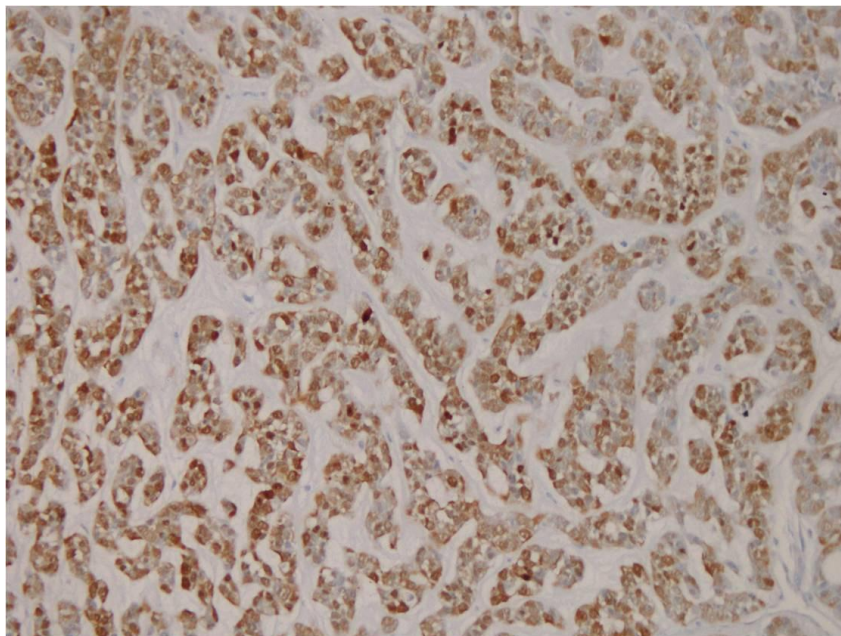
(A)



(B)

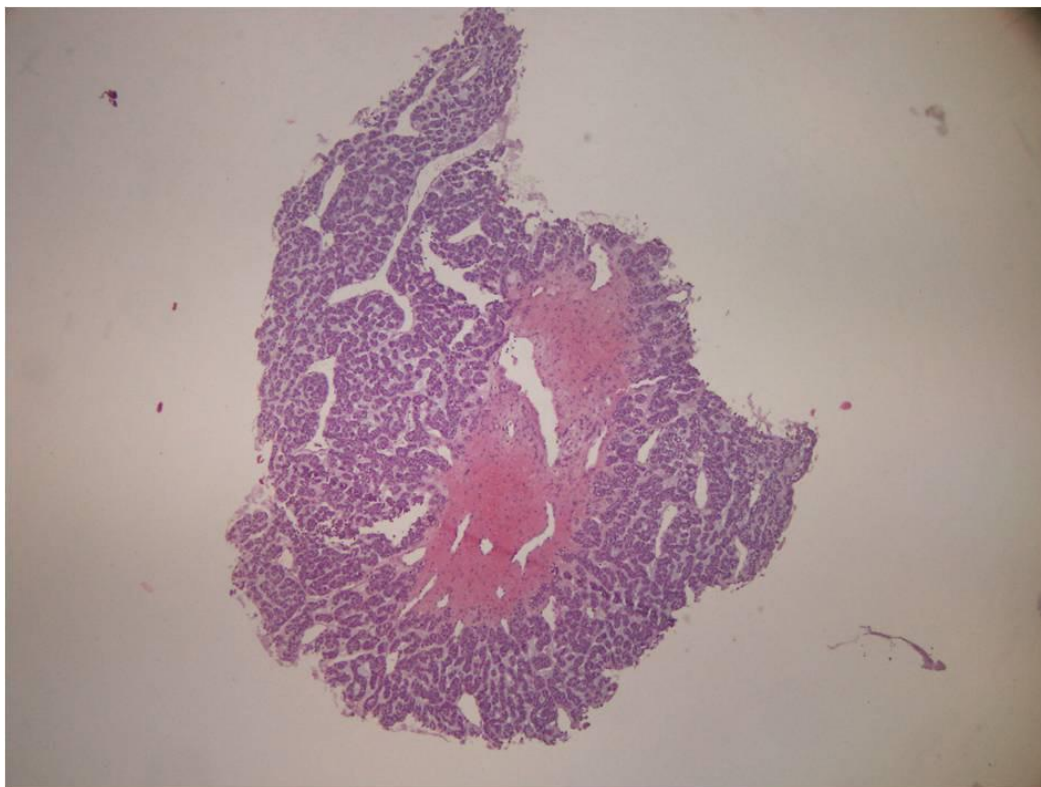


(C)

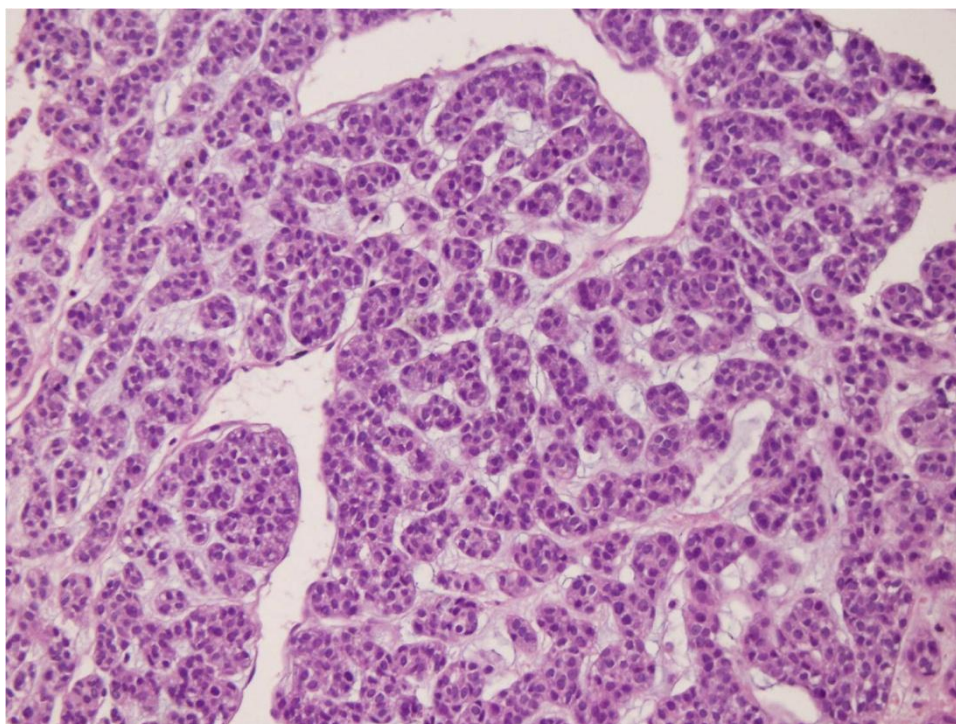


(D)

**Figure 1A:** Parotid tumor with tubular structure on a fibromyxoid background and perineural infiltration (H&E x25). B: Cribriform pattern formation was noticed in some areas besides the tubular pattern (H&Ex100). C: CD117 (+) staining was present in tumor cells on IHK examination (CD117 x200). D: Similarly, smooth muscle actin (+) staining was found in tumor cells (SMA x200).



(A)



(B)

**Figure 2A:** Phalanxes biopsy specimen small-diameter metastatic tumor focus under the epidermis with tubular pattern and a regular border (H&E x25). **B:** Tumor with an appearance identical to the parotid tumor is seen on large magnification (H&E x200).

Multiple small masses were noticed on the middle phalanxes of the right hand during routine follow-up. Microscopically a subepidermal tumor with a 0.3 cm diameter, partially separated from surrounding tissues with a regular border was seen. The tumor was composed of tubular structures created by cells with a narrow cytoplasm and monotonous nuclear properties similarly with the primary parotid ACC (Figure 2A-B). IHC the tumor was diffuse positive with pancytokeratin, focally positive with smooth muscle actin. With the clinical, radiological and pathologically findings this tumor was considered to be a skin metastasis of the parotid ACC.

Subsequent follow-up revealed that the large number of non-metabolic pulmonary parenchymal nodules detected radiologically continued with additional metastatic lesions in the left scapula, and right lower and upper extremity muscles.

## Discussion

ACC is usually seen in females in the 5th and 6th decades (6). Most common site is the minor salivary glands. Our patient was male, and the tumor was localized in the parotid. There are studies that suggest the presence of a relationship between histological pattern and prognosis. It has been reported that the prognosis may worsen if areas showing solid features increase compared to the areas with cribriform and tubular features (6, 9). There was no solid focus in the primary and metastatic tumors in our case. The primary tumor in the parotid formed cribriform and tubular structures and similarly this morphology was dominant in the metastasis. The distant organ metastasis rate for ACC has been reported as 24% to 52%. Metastases are most

commonly seen in the lung, followed by the bone, liver and brain. However, skin and skeletal muscle metastases are rare (7, 8). Our case first showed lung metastases with no other solid organ metastasis. Skin metastases appeared five years after the initial diagnosis and in a rather distant area. Bone and soft tissue metastases were detected within a short period.

Our case emerged with skin metastasis distant and small enough to be overlooked in a period when he was followed up for his stable lung metastasis. One must be aware that these cases may rarely appear with distant skin metastases. A thorough physical examination should be carried out in routine follow-up and small lesions should not be ignored.

## References

1. Luna-Ortiz K, Carmona-Luna T, Cano-Valdez AM, Mosqueda-Taylor A, Herrera-Gómez A, Villavicencio-Valencia V. Adenoidcysticcarcinoma of the tongue--clinicopathological study and survival analysis. *HeadNeckOncol*. 2009, 1:15
2. Kokemueller H, Eckardt A, Brachvogel P, Hausamen JE. Review Adenoidcysticcarcinoma of the head and neck--a 20 years experience. *Int J Oral MaxillofacSurg*. 2004, 33:25-31
3. Sengupta S, Roychowdhury A, Bhattacharya P, Bandyopadhyay A. Adenoidcysticcarcinoma on the dorsum of the tongue. *J Oral MaxillofacPathol*. 2013, 17:98-100
4. Shankar NV, Prakash SM, Sumalatha MN, Shankar A. Adenoidcysticcarcinoma of the tongue. *Int J AcadRes*. 2011, 3:580-583
5. Huang M, Ma D, Sun K, Yu G, Guo C, Gao F. Factors influencing survival rate in adenoid ysticcarcinoma of the salivary glands. *Int J Oral MaxillofacSurg*. 1997, 26:435-439
6. Soares EC, CarreiroFilho FP, Costa FW, Vieira AC, Alves AP. Review Adenoidcysticcarcinoma of the tongue: case report and literature review. *Med Oral Patol Oral CirBucal*. 2008, 13:E475-E478
7. Chang CH, Liao YL, Hong HS. Cutaneous metastasis from adenoidcysticcarcinoma of the parotid gland. *DermatolSurg*. 2003, 29:775-779
8. Perez DE, Magrin J, de Almeida OP, Kowalski LP. Multiple cutaneous metastases from a parotid adenoidcysticcarcinoma. *PatholOncolRes*. 2007, 13:167-169
9. Batsakis JG, Luna MA, el-Naggar A. Review Histopathologic grading of salivary gland neoplasms: III. Adenoidcysticcarcinomas. *AnnOtolRhinolLaryngol*. 1990, 99:1007-1009