

**Case Report**

Metastatic Clear Cell Hidradenocarcinoma: Response to Chemotherapy and Long Disease Control

Mouna Ayadi¹, Feryel Letaief^{1*}, Khadija Meddeb¹, Amina Mokrani¹, Yosra Yahyaoui², Nesrine Chrait², HendaRais H²,
Khadija Bellil², Amel Mezlini²

¹Department of Medical Oncology, Salah Azaiez Hospital, Tunis, Tunisia

²Department of Pathology, Internal Security Forces Hospital, Marsa, Tunisia

Abstract

Introduction: Hidradenocarcinoma is a rare aggressive tumor arising from sweat glands that may occur from preexisting hidradenoma or most frequently appears de novo. It is often located in the head and neck. It is also characterized by a high potential of local recurrence, metastasis and poor outcome. This tumor is often radiotherapy and chemotherapy resistant.

Presentation of case: We report a case of a 77-year-old man with a metastatic hidradenocarcinoma to the bone and lymph nodes who was operated 7 years ago for an hidradenoma of the right foot. He was treated with capecitabine-based chemotherapy with good tolerance and obtention of partial response during 10 months. After that, his disease progressed and he died 1 year after diagnosis.

Conclusion: Hidradenocarcinoma is a cancer with a poor prognosis. Because of its low prevalence and high rate of recurrence, its treatment is still controversial. Our good result demonstrates that adjunction of chemotherapy in metastatic forms is effective for a better control and long overall survival.

Keywords: Metastatic Hidradenocarcinoma; chemotherapy; capecitabine; disease control

Academic Editor: Xiaoning Peng, Hunan Normal University School of Medicine, China

Received: April 7, 2015; **Accepted:** May 29, 2015; **Published:** August 1, 2015

Competing Interests: The authors have declared that no competing interests exist.

Consent: We confirm that the patient has given the informed consent for the casereport to be published.

Copyright: 2015 Letaief L *et al.* This is an open-access article distributed under the terms of the Creative Commons Attribution License, which permits unrestricted use, distribution, and reproduction in any medium, provided the original author and source are credited.

***Correspondence to:** Feryel Letaief, Department of Medical Oncology, Salah Azaiez Hospital, Tunis, Tunisia; **Email:** feryel.ksontini@gmail.com

Introduction

Hidradenocarcinoma is a rare malignant skin tumor deriving from eccrine sweat glands. It is an aggressive tumor with a high potential of local recurrence that most metastasizes to regional lymph nodes and distant viscera. It may occur from preexisting hidradenoma or most frequently appears *de novo* [1]. Hidradenocarcinoma is often located on the head and neck and rarely on the extremities [2]. Liver, lung and bones are the distant sites of metastasis with fatal results. Because of its low prevalence and high rate of recurrence, diagnosis remains difficult and its treatment controversial. Thus, until now, there is no consensual treatment for localized or metastatic disease [3-5].

We reported a case of a 77-year-old man with a metastatic hidradenocarcinoma of the right foot. The diagnosis, clinical course and management of his tumor are described and discussed based on the data in the literature.

Case Presentation

A 70 year-old man presented to our department with a two-year history of a painful right inguinal slow-growing mass. He also complained of diffuse bone pain. In his medical history, our patient was operated for a tumor of the right foot 7 years ago. He underwent wide excision with skin graft. Histopathological examination concluded to a benign tumor: hidradenoma. Otherwise, he had no family history of malignancy. Physical examination revealed a 8x9 cm right inguinal bulky lymphadenopathy, painful, without inflammatory signs and a scar nodule of the right foot with keloid appearance (biopsy was not performed). Neurological examination noted a paresis of the left arm. Biological tests showed an inflammatory syndrome, a hypercalcemia (2.9 mmol/l) and a hypergammablobulinemia. Renal and hepatic function tests were normal.

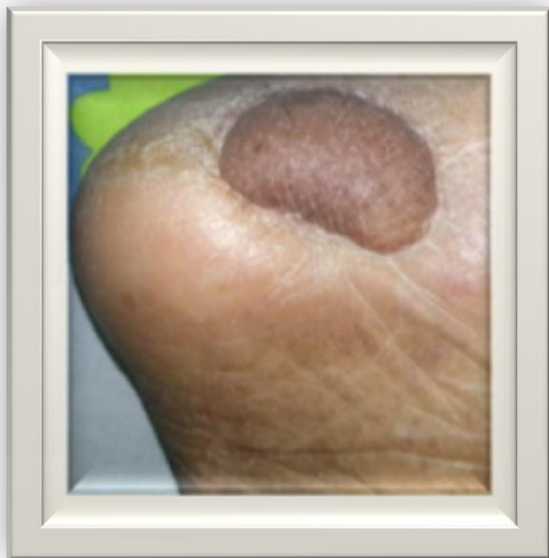

Figure 1 The scar nodule of the right foot

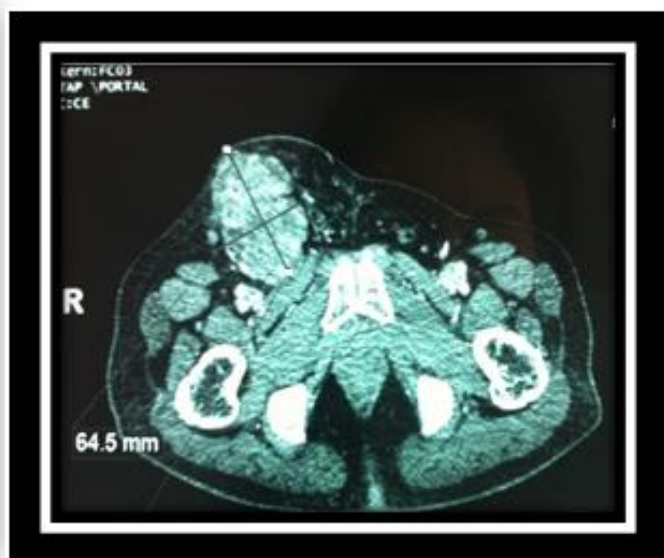


Figure 2 Initial computed tomography scan showing the right inguinal and iliac pathologic lymphadenopathy

Thoraco-abdomino-pelvic computed tomography noted multiple bone metastasis of the entire spine, iliac bones and ribs with right inguinal and iliac pathologic lymphadenopathy. We realized a biopsy of the inguinal mass.

Histopathologic examination revealed a carcinomatous proliferation including basophil cells associated to clear cells. In immunohistochemical analysis, clear cells expressed epithelial membrane antigen (EMA), S100 protein, carcinoembryonic antigen (CAE) and cytokeratin 7. Basophil cells showed a positive staining for EMA, vimentin and cytokeratin 5/6. Tumor cells were not reactive to CDX2, CD20, calretinin, CD10 and cytokeratin 19. Based on these findings, diagnosis of lymph node metastasis of hidradenocarcinoma was established.

After that, a chemotherapy was started and consisted on oral 5 fluorouracil chemotherapy: capecitabine (2500 mg/m²/day) day 1 to day 14; repeated every 21 days. Zoledronic acid was also administrated because of bone metastases. Our patient received also palliative radiotherapy to cervical spine with regression of his arm paresis. After 4 cycles of chemotherapy, clinical examination revealed an improvement in general condition with regression of the inguinal mass and bone pain. Computed tomography examination noted a partial response with stable bone lesions. Chemotherapy with capecitabine was continued for eight other cycles with a stable disease. But two months after he developed pulmonary and pleural metastasis. Second line chemotherapy was done based on intravenous vinorelbine (25 mg/m²) weekly. After two injections, he was breathless and severely dehydrated thus managed by supportive and palliative treatment, and he finally died.

Discussion

The management of this neoplasm is still controversial, mainly due to limited availability of literature. It consists mainly of surgical excision, radiation and chemotherapy [6]. For localized disease, most clinicians agree that wide surgical excision is the standard treatment [7]. For some authors, the Mohs micrographic surgery appears to be the method of choice compared to conventional wide surgical excision. This surgery would decrease local recurrence rate [8]. In a recent review of literature of 20 cases of eccrine sweat gland carcinoma treated with Mohs micrographic surgery, there was no local recurrence [9]. Nevertheless, surgical excision is until now the standard strategy.

The role of regional lymph nodes dissection is still controversial. Based on its high incidence of metastases, some authors recommend systematic lymph nodes dissection to prevent loco regional recurrence. Delgado et al proposed sentinel mapping and biopsy followed by lymph node dissection if the sentinel node was invaded. In this study, there was a high frequency of positive sentinel lymph nodes and metastases were detected in four patients of the six [10]. However, until now, there is no evidence of a benefit in survival or local control correlated with lymph node removal or sentinel lymph node mapping. It is partly due to the low prevalence of this tumor. Further studies are necessary to determine the optimal strategy [1].

The role of radiotherapy in clear cell hidradenocarcinoma has changed. Before, this tumor was considered radio-resistant. Recent reports have shown that post-operative radiotherapy improves local control and it should be performed when predictive factors of recurrence are present: positive margins, vascular, lymphatic and perineural invasion, poorly differentiated tumors, lymph node involvement and extra capsular spread [11]. The dose of radiotherapy is not consensual. In the study of Harari et al, sweat gland tumors with positive margins were treated by external beam radiotherapy: 70 Gy in the primary surgical bed and 50 Gy in the lymphatic chains with complete remission consisting of 27-35 months disease-free period [12].

The role of chemotherapy remains also unclear. No benefit of adjuvant chemotherapy has been shown until now. However, in metastatic hidradenocarcinoma, some case reports described a benefit of various chemotherapy agents. Jouary *et al* reported the benefit of capecitabine in a 60 year-old-woman with metastatic hidradenocarcinoma. Treatment resulted in more than 50% of clinical remission with acceptable clinical and biological tolerance [13]. In our case, the patient received capecitabine with partial clinical response after 4 cycles followed by a stability after 8 other cycles but the disease progressed after that. Overall survival was 12 months.

In the literature, other chemotherapy regimens has been reported using intra-venous 5 fluorouracil, doxorubicin and platin regimen leading to better disease control [14]. In another case report, a 35 year-old-woman with metastatic hidradenocarcinoma (lung metastases) was treated with navelbine and cisplatin with obtention of a stable disease after 6 cycles [15].

Target therapies have also been tested in clear cell hidradenocarcinoma (CCH). Based on histomorphologic overlap between sweat gland origin and breast adenocarcinomas, some investigators studied the expression of oestrogen receptors and HER 2 neu protein in CCH to test the efficacy of tamoxifen and trastuzumab. In the study of Nash *et al*, the investigators reported the benefit of adjuvant trastuzumab in patients whose tumors over expressed HER2 neu. A 44-year-old-man was treated with wide local excision, lymph node dissection, adjuvant radiotherapy and chemotherapy and trastuzumab because of HER 2 neu gene amplification. He performed a complete response.

In analogy to breast carcinoma and based on findings showing the benefit of trastuzumab in metastatic breast cancer, authors suggest the uses of trastuzumab in metastatic adnexal carcinomas [16].

Other investigators evaluated the efficacy of tamoxifen in eccrine adenocarcinoma [16]. Kasi *et al* reported two cases of metastatic sweat gland carcinoma with expression of oestradiol receptors , treated with tamoxifen. Hormonal therapy achieved a prolonged partial response in these patients. Shroder *et al* reported also a success of adjuvant tamoxifen therapy after a local recurrence treated by surgery in a 64-year-old-woman with a sweat gland adenocarcinoma of the scalp [17].

Conclusion

Hidradenocarcinoma remains a cancer with a poor prognosis. Our good result demonstrates that despite its chemotherapy resistance, adjunction of chemotherapy in metastatic forms is effective for a better control and long overall survival.

Consent

We confirm that family members of the patient have given their informed consents for the case report to be published.

References

1. Gauerke S, Driscoll JJ. Hidradenocarcinomas: A Brief Review and Future Directions. *Arch Pathol Lab Med.* 2010, 134:781-785
2. Yavel R, Hinshaw M, Rao V Hartig GK, Harari PM, Stewart D, Snow SN. Hidradenoma and hidradenocarcinoma of the scalp. Managed using Mohs micrographic surgery and a multidisciplinary approach: case reports and review of the literature. *Dermatol Surg.* 2009, 35:273-281

3. Mehregan AH, Hashimoto K, Rahbari H. Eccrine adenocarcinoma. A clinicopathologic study of 35 cases. *Arch Dermatol.* 1983, 119(2):104-114.
4. Santa Cruz DJ. Sweat gland carcinomas a comprehensive review. *Semin Diagn Pathol.* 1987, 4(1):38-74
5. Kaesby LE, Hadley GG. Clear cell adenocarcinoma: report of three cases with widespread metastases. *Cancer.* 1954, 7(5):934-952
6. Chintamani, Sharma R, Badran R, Badran R, Singhal V, Saxena S, Bansal A. Metastatic sweat gland adenocarcinoma: A clinico-pathological dilemma. *World J Surg Oncol.* 2003, 1(1):13
7. Shu k, Xiao Q, Büchele F, Zhang S, Jiang W, Lei T. Diagnosis and treatment of clear cell hidradenocarcinoma of the scalp. *J Huazhong Univ Sci Technolog Med Sci.* 2012, 32(6):931-936
8. Wildermore JK, Lee JB, Humphreys TR. Mohs surgery for malignant eccrine neoplasms. *Dermatol Surg.* 2004, 30(12 Pt 2):1574-1579
9. Song SS, Wu Lee W, Hamman MS, Brian Jiang SI. Mohs micrographic Surgery for eccrine porocarcinoma: An update and review of the literature. *Dermatol Surg.* 2015, 41(3):301-306
10. Delgado R, Kraus D, Coit DG, Busam KJ. Sentinel lymph node analysis in patients with sweat gland carcinoma. *Cancer.* 2003, 97(9):2279-2284
11. Lalya I, Hadadi K, Tazi el M, Lalya I, Bazine A, Andaloussy K, Elmarjany M, Sifat H, Hassouni K, Kebdani T, Mansouri H, Benjaafar N, Elgueddari BK. Radiotherapy on hidradenocarcinoma. *N Am J Med Sci.* 2011, 3(1):43-45
12. Harari PM, Shimm DS, Bangert JL, Cassady JR. The role of radiotherapy in the treatment of malignant sweat gland neoplasms. *Cancer.* 1990, 65(8):1737-1740
13. Jouary T, Kaiafa A, Lipinski P, Vergier B, Lepreux S, Delaunay M, Taëb A. Metastatic hidradenocarcinomas: efficacy of capecitabine. *Arch Dermatol.* 2006, 142(10):1366-1367
14. Trabelsi A, Olfa G, Faten H, Makrem H, Slim BA, Moncef M. Metastatic hidradenocarcinoma: surgery and chemotherapy. *North Am J Med Sci.* 2009, 1(7):372-374
15. Wan X, Wang HY, Zheng JN, Sui JC. Primary cutaneous sweat gland carcinoma. *J Cancer Res Ther.* 2014, 10(2):390-92
16. Kasi S, Benedetto P, Otrakji CL, Charyulu KK. Response of eccrine adenocarcinoma to tamoxifen. *Cancer.* 1989, 64(2):366-370
17. Schroder U, Dries V, Klussmann JP, Wittekindt C, Eckel HE. Successful adjuvant tamoxifen therapy for oestrogen receptor-positive metastasizing sweat gland adenocarcinoma. *Ann Otol Rhinol Laryngol.* 2004, 113 (3 Pt 1):242-244