

**Case Report**

Renal Cell Carcinoma with IVC Thrombus Extending up to Right Atrium and Triple Vessel Coronary Artery Disease - One-stage uro-cardiac Procedure: A case Report

Praveen Pushkar^{1*}, Shantanu Gore¹, Ishfaq Ahmad Geelani¹, Bhaba Nanda Das², and Rajesh Taneja¹

¹ Department of Urology, Indraprastha Apollo Hospital, New Delhi, India

² Department of Cardiothoracic and Vascular Surgery, Indraprastha Apollo Hospital, New Delhi, India

Abstract

Introduction: The aim of this report is to prove the possibility of simultaneous difficult cardiac and urologic operation. Important point to make in our report concerns the fact that the oncologic treatment was not delayed despite severe heart disease. There is also an advantage in avoiding second operation and hence anesthesia

Case Presentation: A 72 year old male presented to us with right renal mass lesion with tumour thrombus extending up to right atrium. He had undergone Percutaneous Transluminal Coronary Angioplasty 5 years ago and had two coronary stents in situ. Coronary angiography revealed triple vessel coronary re obstruction. After proper planning he underwent right radical nephrectomy with tumour thombectomy along with Coronary Artery Bypass Grafting in the same sitting.

Conclusion: One-stage cardiac and uro-oncologic operation can be a safe and beneficial procedure, if performed in selected patients.

Keywords: atrial thrombus; CABG, IVC thrombus; radical nephrectomy; renal cell carcinoma

Academic Editor: Xiaoning Peng, Hunan Normal University School of Medicine, China

Received: November 17, 2014; **Accepted:** December 24, 2014; **Published:** January 28, 2015

Competing Interests: The authors have declared that no competing interests exist.

Consent: We confirm that the patient has given the informed consent for the case report to be published.

Copyright: 2015 Pushkar P *et al.* This is an open-access article distributed under the terms of the Creative Commons Attribution License, which permits unrestricted use, distribution, and reproduction in any medium, provided the original author and source are credited.

***Correspondence to:** Praveen Pushkar, Department of Urology, Indraprastha Apollo Hospital, New Delhi, India;
Email: praveenpushkar@yahoo.co.in

Introduction

Standard treatment of patients with coexisting cardiac and non-cardiac diseases includes two separate operations. However, if the cardiac operation is performed first, the oncologic treatment is delayed, jeopardizing the oncologic outcome. Furthermore, the immunosuppressive effect of extracorporeal circulation may accelerate tumor growth and disseminate cancer cells. If oncologic procedure is performed first, the risk of operation is very high due to compromised cardiac status. There is also an aspect of risk and cost of two hospital stays and additional anesthesia.

Till now there have been just few publications on one-stage cardio-urologic operations and there are no reports concerning patients with combined coronary artery bypass surgery and surgery for RCC with tumor thrombus extending to right atrium.

Case Report

Seventy two years old man, (height 1.6 m; weight 76 kg) presented to our tertiary care center with a diagnosis of right renal mass lesion with tumor thrombus extending into renal vein, Inferior vena cava (IVC), up to right atrium (RA). [Figure 1] This had been found during evaluation for low grade fever of 6 months duration and weight loss with no urological complaint. He had a preexisting diabetes mellitus and coronary artery disease. He had undergone myocardial re-vascularisation procedure in the form of Percutaneous Transluminal Coronary Angioplasty (PTCA) 5 years ago and had two coronary stents in situ.

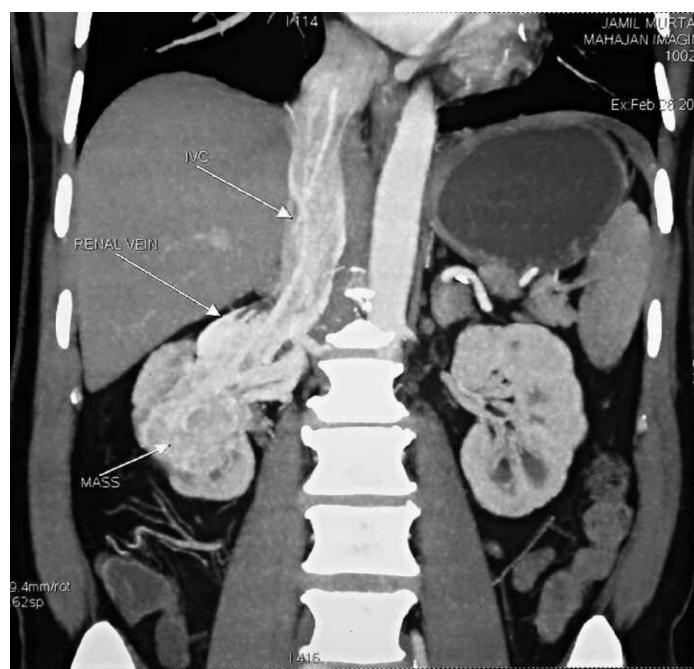


Figure 1 CT (coronal view) showing right renal mass with IVC thrombus extending above diaphragm

A cardiac evaluation was done in the form of Coronary Angiography and triple vessel coronary re obstruction was diagnosed. He was advised a myocardial revascularization procedure in the form of Coronary Artery Bypass Grafting (CABG). After discussion with the patient and his family, single stage operation was decided and carefully planned.

Under intubated general anesthesia, through anterior midline abdominal incision, transperitoneal approach, the duodenum was reflected medially and to the left to expose the left renal vein and right renal artery. The right renal artery was ligated in continuity at its origin and the left renal vein was secured in a vascular loop. A loop was placed around the IVC below the renal vessels. At this stage, through a median sternotomy, CABG was carried out on beating heart. Following this, the patient was brought under heart lung bypass machine with hypothermia. At this stage a racquet shaped incision was made on the IVC, encircling the right renal vein. The thrombus was meticulously pulled out of the IVC in its entire length. After an initial resistance, the thrombus came out as a single piece in continuity with the kidney specimen. The radical nephrectomy was completed by dividing the renal artery and excising the kidney in extra fascial plane. [Figure 2] Incisions were closed with after careful homeostasis over an abdominal and a thoracic drain.

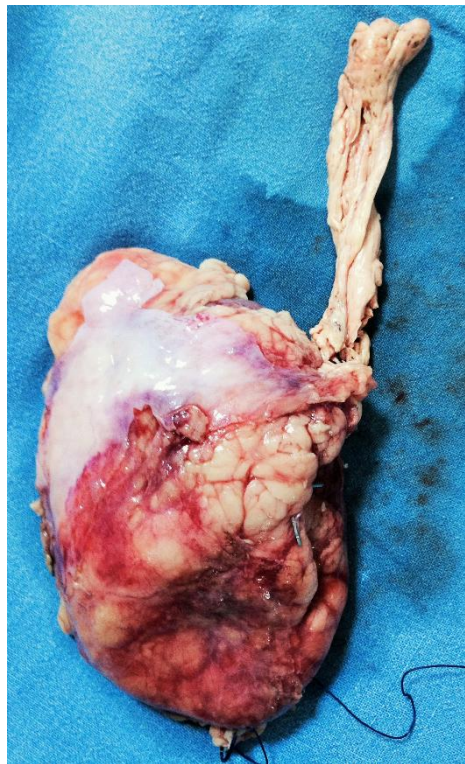


Figure 2 Radical nephrectomy specimen with IVC thrombus

18 hours post operatively, the patient required re exploration through thoracic and abdominal incisions due to fall in hemoglobin and persistent hemorrhagic drain output both from abdominal and chest drains. No definite bleeder could be identified but there was some diffuse ooze in renal fossa. The incisions were closed and the patient recovered well post operatively and maintained hemoglobin and hemodynamics. He was extubated 24 hours after re-exploration and steadily improved thereafter. He was discharged on 12th post-operative day. Histopathology revealed RCC, clear cell carcinoma with Fuhrman grade 2, T3c, N0M0.

Follow up after 6 months, with PET-MRI showed no evidence of residual disease/metastasis.

Discussion

RCC with IVC tumour thrombus extension occurs in 4-10% of cases [1]. Within this group, 2-16% have

tumours extending into right atrium [2].

If the surgery warrants use of cardiopulmonary bypass (CPBP) in cases of higher level thrombus, a cardiology consult should be requested preoperatively, in order to perform coronary angiography. The cardiovascular team would then have the information needed to perform a simultaneous coronary artery bypass at that time if necessary [3].

Various centres have reported mortality rates of 2.7%-13% for higher level thrombus depending on patient comorbidities and tumour characteristics [4].

To the best of our knowledge, this is the first reported case of patient, who underwent one-stage radical nephrectomy with thrombectomy with CABG. The aim of this report was to prove the possibility of simultaneous difficult cardiac and urologic operation. The most important point of our report concerns the fact that the oncologic treatment was not delayed despite severe heart disease. There is also an advantage in avoiding second operation and hence anesthesia. Essential disadvantages, which have to be considered are increased probability of bleeding due to heparin, operation time, its complexity and risk of patient's death. In our patient, despite meticulous hemostasis during first operation there was hemorrhagic collection in the post-operative period due to heparin effect with CABG. Meticulous closure of peritoneum was performed after re exploration to create tamponade.

One-stage cardiac and uro-oncologic operation can be a safe and beneficial procedure, if performed in selected patients by experienced cardio surgical and urological teams. There is a need of greater number of patients and long term follow-up to establish final conclusions.

Reference

1. Campbell MF, Retik RB, Vaughan ED, Walsh PC. Campbell's Urology, 7th edn. Philadelphia: **W.B. Saunders Co.**, 1998
2. Nesbitt JC, Soltero ER, Dinney CP *et al.* Surgical management of renal cell carcinoma with IVC thrombus. *Ann Thorac Surg.* 1997, 63:1592-1600
3. Pouliot F, Shuch B, Larochelle JC, Pantuck A, Belldegrun AS. Contemporary management of renal tumours with venous tumour thrombus. *J Urol.* 2010, 184:833-841
4. Terakawa T, Miyake H, Takenaka A, Hara I, and Fujisawa M. Clinical outcome of surgical management for patients with renal cell carcinoma involving the inferior vena cava. *Int J Urol.* 2007, 14:781-784