



Case Report

Fluorescent In-Situ Hybridization is the Hand Mirror of Cytogenetics: A Rare Case of Near Tetraploidy in Pediatric Acute Lymphoblastic Leukemia

Ashwini Rajan^{1*}, Deepika GS¹, Renu Ethirajan¹, Intezar Mehdi², Basavalinga S Ajaikumar², Mithua Ghosh¹, and Prasanna Kumari¹.

¹ Department of Cytogenetics and FISH, HCG Cancer Hospital, Triesta Sciences, India

² Health Care Global Enterprises Ltd. HCG Towers, 8, P Kalinga Rao Road, Sampangi Ram Nagar, Bangalore-560027, India

Abstract

Identification of specific chromosomal changes has important prognostic and biological implications in childhood Acute Lymphoblastic Leukemia (ALL). ALL cases with >90 chromosomes are rare. Here, we report a case of near-tetraploidy in a 4 year old boy diagnosed with B-cell ALL, where the ploidy was identified by Fluorescent *In-Situ* Hybridization (FISH) and confirmed by Conventional Cytogenetics. Our aim was to enumerate multiple signals observed by FISH, and to confirm the same by cytogenetics. FISH on cytogenetically fixed air-dried slides was performed by using BCR/ABL and MLL probe. Two hundred cells were scored. BMA was cultured and G-banded metaphases were analyzed in accordance with ISCN 2013. The results of the FISH test showed more than two signals and cytogenetics revealed clones of near-tetraploidy with $mn >90$, karyotype: 90-92, $<4n>XXY,-Y,-10,-10,-13,+14,+17$, along with normal clones. The tetraploidy condition compared to hyperdiploid ALL has a poorer prognosis and the rarity of these cases makes accounting on treatment decisions a supposition. Presently, the patient is on standard treatment for ALL (UK ALL regime A). The numerical abnormality detected by FISH was confirmed by cytogenetics, which facilitated in reporting the results of this case earlier than the defined turnaround time. Therefore author opines that FISH reports should also contain observed additional information along with positive or negative status of the requested test.

Keywords: Chromosome; FISH; tetraploidy

Received: October 29, 2016; **Accepted:** November 24, 2016; **Published:** December 28, 2016

Competing Interests: The authors have declared that no competing interests exist.

Consent: Consent was taken from the patient for publication of this case report.

Copyright: 2016 Rajan A *et al.* This is an open-access article distributed under the terms of the Creative Commons Attribution License, which permits unrestricted use, distribution, and reproduction in any medium, provided the original author and source are credited.

***Correspondence to:** Ashwini Rajan, Department of Cytogenetics and FISH, HCG Cancer Hospital, Triesta Sciences, India

E-mail: ashwinirajan7@gmail.com

Introduction

Acute Lymphoblastic Leukemia (ALL) is a hematological malignancy characterized by an uncanny increase in the number of white blood cells. The prevalence of ALL is most common in children under the age of 14 years when compared to adults^[1]. Pediatric ALL is characterized with increase in the modal number of chromosomes from 46. This hyperdiploid condition in childhood ALL is associated with good prognosis with a 5 year overall survival rate (OS)^[1] as they respond well to chemotherapy^[2]. There are also rare occurrences of near-triploid and near-tetraploid clones in the cultured bone marrow samples of childhood ALL patients. The near-tetraploid clones with modal number greater than 90(mn>90) have poor prognosis as they initiate chromosome instability^[3,6] when compared to the relatively stable genome of the hyperdiploid ALL cells^[2]. Cytogenetic analysis by G-banding has undisputedly been the primary tool in the diagnosis, prognosis and management of all hematological malignancies^[3]. The analysis of the acquired chromosomal changes in cancer poses' limitation due to low mitotic index and poor morphology of the chromosome, especially in pediatric cases, as aspiration of bone marrow from children is an excruciating process. The drawbacks of cytogenetics are compensated by the use of FISH. The sensitivity of this molecular technique and its specificity to detect cryptic rearrangements unidentified by cytogenetics gives FISH an edge in the assessment of chromosomal abnormalities^[4]. FISH has greatly enhanced analysis and has bridged the gap between molecular genetics and cytogenetics. This molecular cytogenetic technique proves advantageous as it contributes to the shorter analysis time, faster results and accurate diagnosis, thereby providing the relevant information for the clinicians to decide on effective treatment regimes for patients^[5,7].

Here we try to bring out the importance of both the technique and how FISH proves to be a mirror image reiterating the results obtained by cytogenetics.

Materials and Method

Case history

A four year old Indian boy, referred to Health Care Global Cancer Centre in July 2015, with a clinical history of fever, on and off for 10 days, skin bleeds and purplish patches was suspected of acute leukemia. Upon admission, bone marrow was aspirated and the differential count analysis reported hemodiluted marrow with 44% blast and morphologically the initial diagnosis was that of an MPO negative acute leukemia. The aspirate was advised for immunophenotyping for an ALL panel by Flow Cytometry. The cells gated for the sample were positive for the common ALL antigen (CD10+) with B cell lineage expressing CD19, CD20, providing an impression of C-ALLA positive B cell ALL. FISH for Multiple Lineage Leukemia (MLL) and BCR/ABL translocation and Cytogenetic analysis was also referred. MLL gene rearrangement for 11q23 by FISH, performed outside, was negative but the report stated that more than two signals of the gene were observed. Correlating the morphology, flow cytometry, FISH and cytogenetics report, the patient was diagnosed as a C-ALLA positive B-cell ALL with near tetraploidy. The patient was started on induction chemotherapy as per UK ALL regimen A and has been stable with frequent visits to the hospital.

Conventional Cytogenetics

Bone marrow aspirate in heparin was collected, counted for WBC by Hemocytometer, and three unstimulated culture was setup using RPMI 1640 medium(Gibco, ThermoFisher USA) with 15% FBS (Invitrogen, ThermoFisher USA) to obtain metaphases for standard cytogenetic analysis. The culture was harvested. Slides were casted and aged overnight at 50°C. The slides were then GTG banded for analysis. The karyotype was written in accordance with the International System for Human Cytogenetics Nomenclature (ISCN) guidelines^[8].

Molecular Cytogenetics

Air dried FISH slides were prepared using the pellet obtained from cytogenetic preparation on the second day after receiving the sample. Commercially available BCR/ABL probe (Vysis, Abbot USA) specific for the ABL gene (chromosome 9) and BCR gene (chromosome 22) was applied to the slide and hybridized overnight according to the standardized procedure. The cells were counterstained with DAPI after the post hybridization washes. Two hundred cells were scored under the fluorescent microscope (Nikon Eclipse 80i) using FITC and Texas red dual filters. The images were captured using Applied Spectral Imaging (ASI) software.

Results

FISH for BCR-ABL translocation was reported negative, on the third day of receiving the sample, with no fusion signals seen in the cells. The additional observation showed the presence of four red signals of ABL gene (9q34) and four green signals of the BCR gene (22q11.2) (Fig 1). The occurrence of the high copy number of these genes (signals), raised suspicion of a tetraploidy condition in the sample. GTG banded metaphases showed near tetraploidy along with normal karyotype which supported the findings of FISH. The chromosome modal number ranged from 90-92 and the karyotype: 90-92, $\langle 4n \rangle XXY, -Y, -10, -10, -13, +14, +17/46, XY$ (Fig 2).

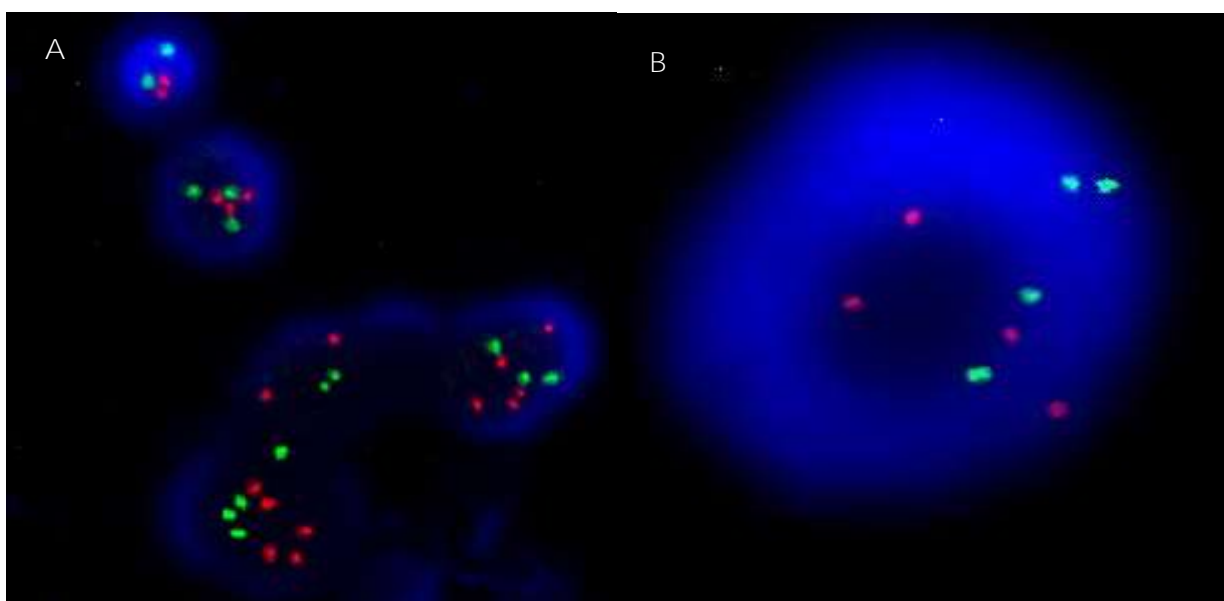


Figure 1 BCR/ABL by FISH.

A: Cells showing both normal and near tetraploid signals.

B: Cell showing four green and four red signals indicating the presence of both homologous chromosome 9 and chromosome 22.

Abbreviations: FISH=Fluorescent in situ hybridization, BCR=Breakpoint cluster region (green), ABL=Abelson(red).

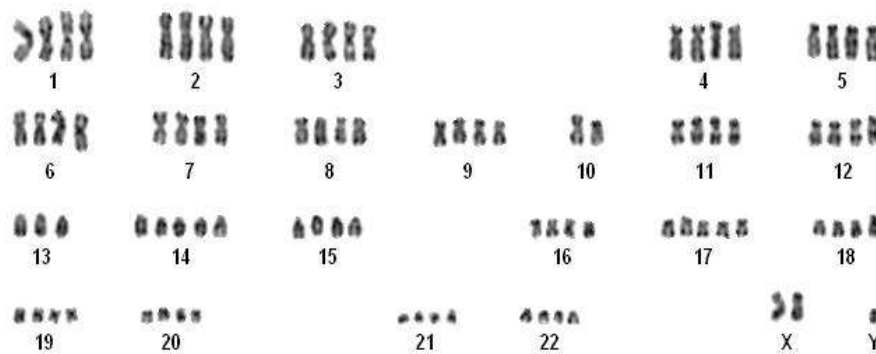


Figure 2 KARYOTYPE: 90-92, $\langle 4n \rangle XXY, -Y, -10, -10, -13, +14, +17$.

Discussion

Hyperdiploidy is a common occurrence in childhood ALL associated with good prognosis^[1]. Studies state that the presence of hyperdiploidy is a mere consequence of cell division and is more stable contributing to the favorable prognosis^[5] in contradiction to the tetraploidy condition. Chromosome instability in tetraploid clones is because of the accumulation of spontaneous DNA damage owing to the high count of chromosomes in these cells. This attribute alone cannot be confined to DNA damage as chromosome instability and ploidy in cancer is a highly sophisticated process^[2]. The present case is that of a C-ALLA positive B cell ALL with the additional manifestation of near tetraploid clone. BCR/ABL test for fusion by FISH was negative for the patient, but four copies of the BCR and ABL gene signals was observed, on the third day of receiving the sample. The suspicion of a tetraploid/ near tetraploid ALL was confirmed by cytogenetics on the fifth day. Further, multiple copies of the MLL gene was supportive of our observation. Here we emphasize the importance of these two complementing techniques^[7]. FISH is performed in hematological malignancies to report cryptic rearrangements^[4] but the numerical abnormality was also detected as an additional finding in this case without using any centromere enumeration probe (CEP). The results obtained was supported by cytogenetics findings. Early detection of the hyperdiploidy/ tetraploidy clone in childhood ALL by FISH helped in the timely prediction of the prognosis and management of the patient.

Even though cytogenetics is the preferred diagnostic tool to detect chromosomal abnormalities the contribution of FISH in this case cannot be ignored. The author opines that additional information along with the positive and negative status of the FISH tests should be provided to the clinician for final diagnosis and management of the patient.

References

1. Paulsson K, Forestier E, Lilljebjorn H, Heldrup J, Behrendtz M, Young B et al. Genetic landscape of high hyperdiploid childhood acute lymphoblastic leukemia. *Proceedings of the National Academy of Sciences*. 2010;107(50):21719-21724
2. Carroll W. Safety in numbers: hyperdiploidy and prognosis. *Blood*. 2013;121(13):2374-2376.
3. Storchova Z, Kuffer C. The consequences of tetraploidy and aneuploidy. *Journal of Cell Science*. 2008;121(23):3859-3866
4. Mazloumi S, Madhumathi D, Appaji L, Prasannakumari P. *Asian Pacific Journal of Cancer Prevention*. 2012;13(8):3825-3827
5. Kearney L. The impact of the new FISH technologies on the cytogenetics of haematological malignancies. *British Journal of Haematology*. 1999;104(4):648-658
6. Garcia D, Bhatt S, Manvelyan M, de Souza M, Binato R, Aguiar T et al. An unusual T-cell childhood acute lymphoblastic leukemia harboring a yet unreported near-tetraploid karyotype. *Mol Cytogenet*. 2011;4(1):20
7. Haltrich I, Kovács G, Cséka M, Jakab Z, Fekete G. P065 Cytogenetic and FISH findings are complementary in childhood ALL. *Blood Reviews*. 2007;21:S107
8. Shaffer L, McGowan-Jordan J, Schmid M. ISCN 2013. Basel: *Karger*; 2013