

**Case Report**

Leukemic Infiltration of the Esophagus, a Rare Etiology for a Common Disease

Yaseen Alastal, MD¹✉; Tariq A Hammad, MD¹✉; Basmah W Khalil, MD¹; Muhammad Ali Khan, MD¹; Osama Alaradi MD²; and Ali Nawras MD, FACG^{2*}

¹ Department of Internal Medicine, University of Toledo Medical Center, Unites States

² Department of Gastroenerology and Hepatology, University of Toledo Medical Center, Unites States

Abstract

Introduction: The etiology of esophagitis in patients with acute leukemia is usually related to infections, reflux, or chemotherapy toxicity. Infiltration of esophagus by leukemic cells is rarely considered in the differential diagnosis.

Presentation of Case: Here we present a case of 87-year-old male patient with a recent diagnosis of acute myelocytic leukemia who was found to have severe diffuse esophagitis secondary to leukemic infiltration.

Conclusion: Leukemic infiltration of the esophagus is a rare potential etiology of severe esophagitis in patients with disseminated leukemia. Esophageal biopsy is needed to identify the exact cause of esophageal lesions in leukemia patient.

Keywords: Esophagus; leukemia

Academic Editor: Xiaoning Peng, Hunan Normal University School of Medicine, China

Received: March 7, 2015; **Accepted:** April 20, 2015; **Published:** May 20, 2015

Competing Interests: The authors have declared that no competing interests exist.

Consent: We confirm that the patient has given the informed consent for the case report to be published.

Copyright: 2015 Nawras A *et al.* This is an open-access article distributed under the terms of the Creative Commons Attribution License, which permits unrestricted use, distribution, and reproduction in any medium, provided the original author and source are credited.

***Correspondence to:** Ali Nawras, Department of Gastroenerology and Hepatology, University of Toledo Medical Center, 3000 Arlington Avenue, Toledo, OH 43614, Unites States

Email: Ali.nawras@utoledo.edu

✉ Contributed equally to this work

Introduction

The etiology of esophagitis in patients with acute leukemia is usually related to infections, reflux, or chemotherapy toxicity. Esophageal leukemic infiltration is a rare potential cause. Here we present a case of severe diffuse esophagitis secondary to leukemic infiltration.

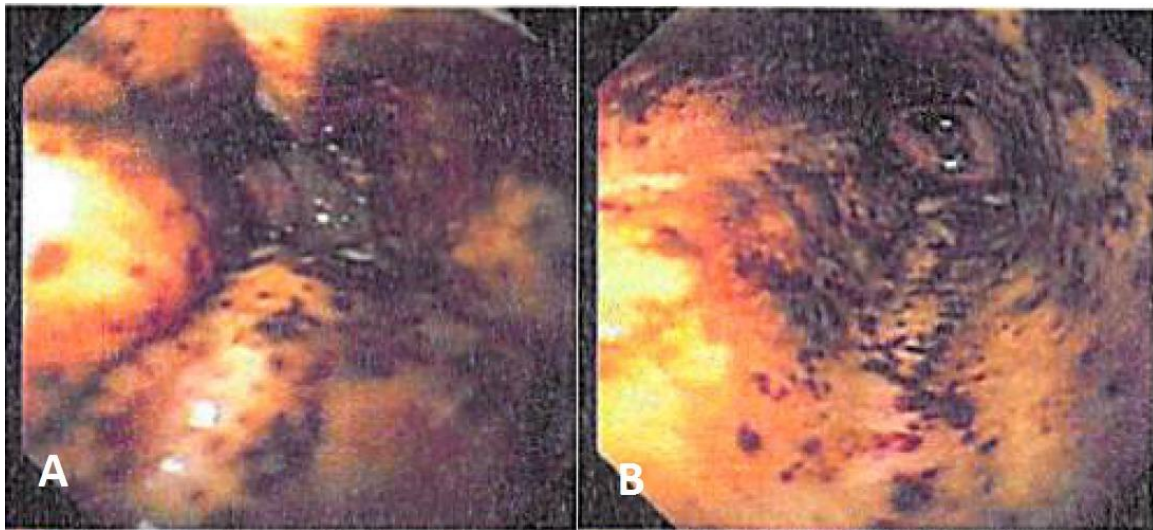


Figure 1 Endoscopic manifestations of leukemia on mid esophagus; submucosal hemorrhages, yellow exudates, severe esophagitis.

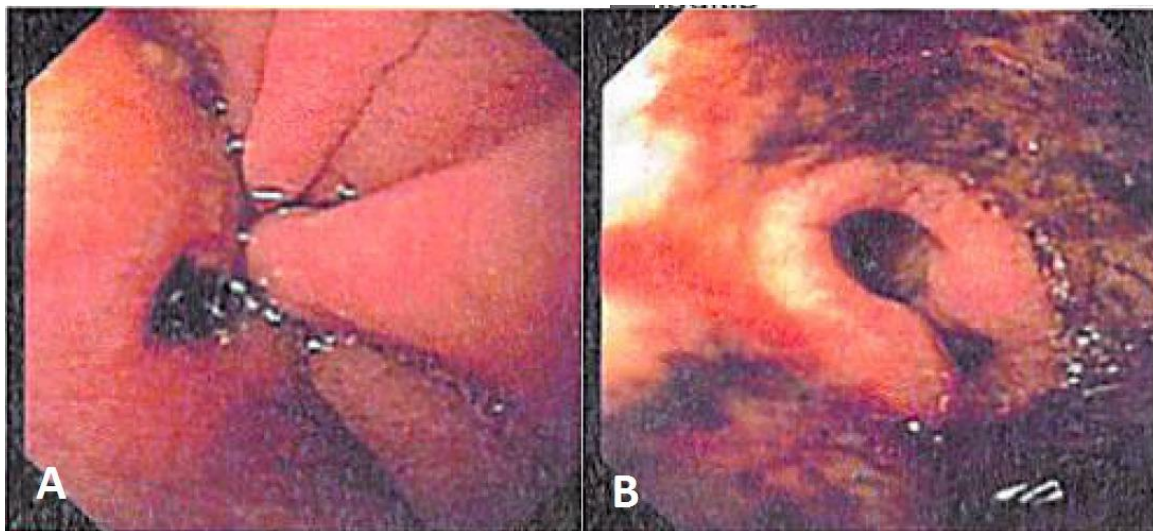


Figure 2 Endoscopic manifestations of leukemia on distal esophagus; submucosal hemorrhages, severe esophagitis.

Case presentation

87-year-old male patient presented with jaundice and worsening hiccups for 10 days. He denied nausea, vomiting, abdominal pain or fever. He was recently diagnosed with acute myelocytic leukemia and underwent 1 cycle of chemotherapy 1 month prior to presentation. Vital signs were stable. He had icteric sclera. Abdominal examination revealed mild right upper quadrant tenderness. Bowel sounds were present. Laboratory work up showed white blood cell counts of $3.4 \times 10^9/L$, hemoglobin of 10.4 g/dL, platelets of $53 \times 10^9/L$. Total bilirubin was 11 mg/dL. Alkaline phosphatase, aspartate and alanine aminotransferase levels of 506 U/L, 439 U/L and 791 U/L respectively. Abdominal ultrasound showed intra and extrahepatic biliary ductal dilatation and gallbladder stones. Patient underwent ERCP for further evaluation. During the procedure he was found incidentally to have severely ulcerative panesophagitis with yellow exudate covering parts of the esophagus and multiple submucosal hemorrhages (Figure 1 and 2). Multiple biopsies and brushing were done. Evaluation of the biliary tree showed long common bile duct stricture which was stented. Biliary duct brushing and endoscopic ultrasound guided fine needle aspiration of a lesion surrounding CBD were negative for malignancies. Pathology study of esophageal specimens revealed heavy leukemic infiltration which was confirmed by immunohistochemical stains. Viral as well as fungal stains and cultures were negative.

Discussion

Gastrointestinal involvement is a known manifestation of leukemia with ileum, stomach and proximal colon being the most common sites of involvement [1]. The reported autopsy incidence of gross gastrointestinal involvement by leukemia ranges from 14.8 to 25% [1,2]. Esophageal infiltration by leukemia has been reported in multiple autopsy series [1-3]. Gilver et al reviewed 705 autopsied cases of leukemia and lymphoma and found eight cases with grossly evident esophageal infiltration, five cases of them had had clinically manifest esophageal obstruction, and in 27.1% of 384 cases (104 cases) there were microscopic esophageal infiltrates [3]. Another autopsy study suggested that the only clinical factor identified to be significantly associated with esophageal involvement by leukemic cells was a high initial leukocyte count [4]. On the other hand, few case reports in the literature described antemortem diagnosis of esophageal involvement by leukemia. Table 1 summarizes clinical and endoscopic features of 10 reported cases of esophageal involvement by different types of leukemia at different age groups.

Different lesions have been described in the esophagus. Prolla et al did a retrospective analysis of 148 autopsies of leukemia patients and described four main types of esophageal lesions in leukemia (1) hemorrhagic lesions which may erode and ulcerate, occurred in 16 % of cases, (2) agranulocytic and pseudomembranous esophagitis with adherent membrane of necrotic debris covering eroded mucosa (4 % of cases), (3) leukemic infiltrates ranging from microscopic to grossly nodular infiltrates (13 % of cases) (4) fungal esophagitis (10.8 % of cases), while none of the above lesions were found in 46% of cases [2]. Our reported case had the first 3 features of involvement; multiple submucosal hemorrhagic lesions were noted in the endoscopic exam as black spots extending over the mid and lower esophagus, thick yellow cloudy material overlying multiple areas of severely ulcerated and eroded esophageal mucosa extending from the upper esophageal sphincter to gastroesophageal junction, and eventually the biopsy showed microscopic infiltration of esophagus by leukemic cells.

Table 1 clinical and endoscopic features of 10 reported cases of esophageal involvement with leukemia [4-9].

	Age and gender	Leukemia type	Symptoms	Endoscopic features
Slee et al 1985	71-year-old female	chronic lymphosarcoma cell leukemia	Odynophagia	erythematous and friable mucosa over the entire esophagus
Thompso 1990	73-year-old male	Acute myeloblastic leukemia	Dysphagia	High grade stricture of mid esophagus, polypoid lesions of upper and lower esophagus
Fulp et al 1993	59-year-old male	Acute myeloid leukemia (M2)	Dysphagia, dyspepsia, weight loss	Shallow ulcers in the proximal esophagus, sever erosive esophagitis in the distal esophagus
Fulp et al 1993	49-year-old male	Acute myelomonocytic leukemia (M4)	Progressive dyspepsia	Mid and distal erosive esophagitis
Fulp et al 1993	31-year-old female	Acute myelomonocytic leukemia (M4)	Severe postprandial nausea and vomiting and epigastric discomfort	NA
Isomoto et al 2001	75-year-old male	Adult T-cell leukemia	Epigastric pain and anorexia	Multiple reddish irregular flat lesions in the distal esophagus
Dixit et al 2003	4-year-old male	Acute myelomonocytic leukemia	Epigastric pain	Ulcerative masses of lower esophagus
Konstantinidis et al 2011	2-year-old male	Acute lymphoblastic leukemia	Dysphagia	Esophageal stenosis, abnormal mucosa, with micronodular appearance, vulnerable, and easily bled.
Konstantinidis et al 2011	13-year-old male	Acute lymphoblastic leukemia	Dysphagia	Distal esophagus mucosa was edematous and vulnerable, partially covered with a whitish layer
Konstantinidis et al 2011	3-year-old female	Acute lymphoblastic leukemia	Postprandial vomiting	Esophageal mucosa was dull, vulnerable, and partially covered with thick, gluish mucus.

Leukemic infiltration of esophagus can be asymptomatic; which is supported by autopsy studies that revealed microscopic esophageal infiltration in significant number of patients with no reported gastrointestinal symptoms. Similarly, the lesions in our reported case were discovered accidentally during ERCP procedure. Our patient didn't report any upper gastrointestinal symptoms apart from hiccups which could be related or unrelated to esophageal involvement by leukemia. On the other hand, different upper GI symptoms have been reported in isolated case reports of patients with leukemic infiltration of esophagus including dysphagia, odynophagia, nausea, vomiting and epigastric pain (see table 1). These symptoms are very nonspecific and could be resulted from any cause of esophagitis. Noteworthy, leukemic infiltration of esophagus should be in the differential diagnosis of new onset upper gastrointestinal symptoms in patients with acute leukemia and further work up could be warranted. Biopsy of the esophageal lesions is needed to differentiate between different causes of esophagitis in this setting.

Conclusion

Leukemic infiltration of the esophagus is a rare potential etiology of severe esophagitis in patients with disseminated leukemia. It can be limited to microscopic involvement or apparent grossly. Different endoscopic features could be visualized including submucosal hemorrhages, erosions, ulcerations and adherent membranes. Esophageal biopsy is needed to identify the exact cause of esophageal lesions in leukemia patient.

Informed Consent

Consent was obtained from the patient per our institution policy.

Acknowledgement

A case abstract was presented as poster in American College of Gastroenterology meeting (2014) at Philadelphia-Pennsylvania USA, under the name of "Leukemic Infiltration of the Esophagus, a Rare Etiology for a Common Disease".

References

1. Cornes JS, Jones TG. Leukaemic lesions of the gastrointestinal tract. *J Clin Pathol*. 1962, 15:305-13.
2. Prolla JC, Kirsner JB. The gastrointestinal lesions and complications of the leukemias. *Ann Intern Med*. 1964,61:1084-103
3. Givler RL. Esophageal lesions in leukemia and lymphoma. *Am J Dig Dis*. 1970. Jan;15(1):31-36
4. Fulp SR, Nestok BR, Powell BL, Evans JK, Geisinger KR, Gilliam JH 3rd. Leukemic infiltration of the esophagus. *Cancer*. 1993, 71(1):112-116
5. Slee GR, Wagner SM, McCullough FS. Odynophagia in patients with malignant disorders. *Cancer*. 1985, 55(12):2877-2879
6. Thompson BC, Feczko PJ, Mezwa DG. Dysphagia caused by acute leukemic infiltration of the esophagus. *AJR Am J Roentgenol*. 1990, 155(3):654
7. Isomoto H, Ohnita K, Mizuta Y, Maeda T, Omagari K, Miyazaki M, Murase K, Hasui K, Murata I, Kohno S. Adult T-cell leukemia with an unusual esophageal lesion. *Gastrointest Endosc*. 2001, 53(6):673-675

8. Dixit MP, Farias KB, McQuade M, Scott KM. Acute myelo-monocytic infiltrate of the lower esophagus in a 4-year-old renal transplant recipient. *Am J Kidney Dis*. 2003, 41(5):E16
9. Konstantinidis N, Kolarovic J, Vukavic T, Kacanski N, Vuckovic N. Esophageal leukemic infiltration in children. *J Pediatr Gastroenterol Nutr*. 2011, 52(6):781-783