

**Case Report**

Methacronous Intercostal and Peritoneal Metastases from Resected Well-differentiated Hepatocellular Carcinoma: Description of a Case and Review of Literature

Damiano Caputo, MD¹; Giuseppe Mangiameli, MD^{1*}, Chiara Taffon, MD²; Marcella Callea, MD²; Roberto Coppola, MD, FACS¹

¹ Department of General Surgery University Campus Bio-Medico di Roma, Rome, Italy

² Department of Pathology University Campus Bio-Medico di Roma, Rome, Italy

Abstract

Introduction: The aim of this report is to prove the possibility of simultaneous difficult cardiac and urologic operation. Important point to make in our report concerns the fact that the oncologic treatment was not delayed despite severe heart disease. There is also an advantage in avoiding second operation and hence anesthesia

Case Presentation: A 72 year old male presented to us with right renal mass lesion with tumour thrombus extending up to right atrium. He had undergone Percutaneous Transluminal Coronary Angioplasty 5 years ago and had two coronary stents in situ. Coronary angiography revealed triple vessel coronary re obstruction. After proper planning he underwent right radical nephrectomy with tumour thombectomy along with Coronary Artery Bypass Grafting in the same sitting.

Conclusion: One-stage cardiac and uro-oncologic operation can be a safe and beneficial procedure, if performed in selected patients.

Keywords: atrial thrombus; CABG, IVC thrombus; radical nephrectomy; renal cell carcinoma

Academic Editor: Xiaoning Peng, Hunan Normal University School of Medicine, China

Received: December 31, 2014; **Accepted:** January 22, 2015; **Published:** January *, 2015

Competing Interests: The authors have declared that no competing interests exist.

Consent: We confirm that the patient has given the informed consent for the case report to be published.

Copyright: 2015 Mangiameli G *et al.* This is an open-access article distributed under the terms of the Creative Commons Attribution License, which permits unrestricted use, distribution, and reproduction in any medium, provided the original author and source are credited.

***Correspondence to:** Giuseppe Mangiameli, Department of General Surgery, University Campus Bio-Medico di Roma, Via Alvaro del Portillo, Rome, Italy; Email: g.mangiameli@unicampus.it

Introduction

Musculoskeletal metastases from carcinoma are rare; particularly rare are intercostal metastases from hepatocellular carcinoma (HCC) [1]. They may result from diagnostic or therapeutic percutaneous procedures, but, haematogenous dissemination and ectopic hepatic foci carcinogenesis have been also suggested.

Peritoneal metastases from HCC have been described in up to 18% of patients with HCC [2] in autopsy series and in 6.3% of living patients after hepatic resection performed for HCC [3].

The aim of this paper is to describe a case of metachronous intercostal and peritoneal metastases from a previously surgical resected well-differentiated HCC on non-cirrhotic liver.

We also aimed to focus on their possible pathogenesis by reviewing the current literature.

Case presentation

A 73-years-old man was referred to our attention because of solid focal hepatic lesion detected during abdominal ultrasonography. That 55x40 mm in diameter lesion involved the fifth hepatic segment, its margins were finely irregular and echogenicity was dis-homogenous.

Patient's medical history included blood hypertension and previous transient ischemic attack. No history of hepatitis, confirmed by laboratory findings, or of alcohol abuse was present. Serum AFP was normal.

CT scan confirmed the focal lesion and showed arterial enhancement. A high density pseudo-capsule was present and no evidence of biliary ectasia was described (Figure 1). These findings were suggestive of peripheral cholangiocarcinoma or fibrolamellar HCC.

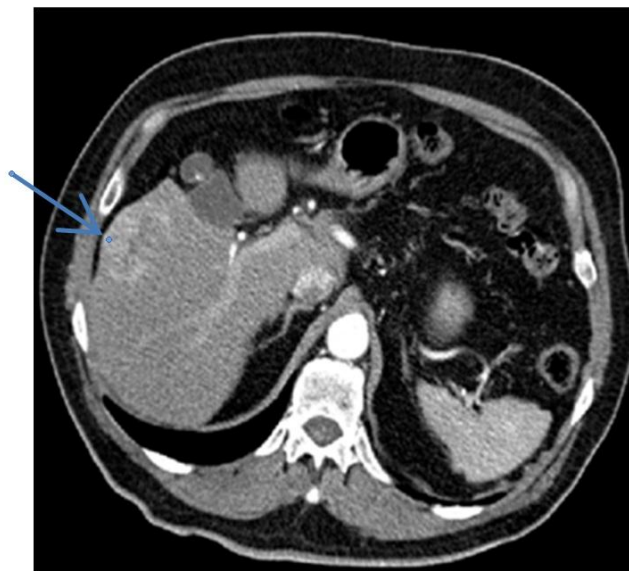

Figure 1 V hepatic segment lesion suggestive for peripheral cholangiocarcinoma or fibrolamellar HCC.

Ultrasound-guided liver biopsy was performed with 18G x 3.3 cm BioPince® needle and two samples were obtained. The collected material was sent for pathological examination and well-differentiated HCC was detected.

Our patient underwent atypical surgical resection of V-VI hepatic segment. Parenchymal section was conducted with Transcollation® technology. Cholecystectomy was also performed. Definitive histological examination showed a fragment of liver parenchyma containing a 3.8 cm intact well-differentiated HCC involving Glisson’s capsule; parenchymal resection margins were free. Postoperative course was uneventful and patient was discharged and referred to medical oncologist for follow-up.

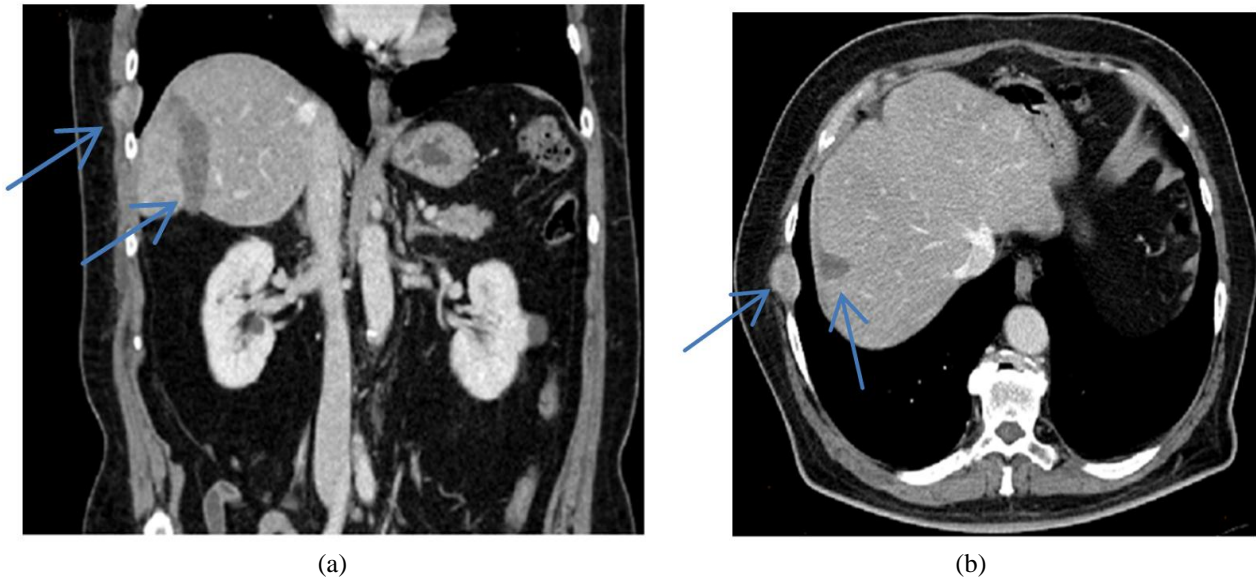


Figure 2 (a) Coronal CT scan shows solid lesion between ninth and tenth ribs in right chest wall. Results of previous hepatic surgery are also evident. (b) Axial CT scan shows solid lesion between ninth and tenth ribs in right chest wall. Results of previous hepatic surgery are also evident.

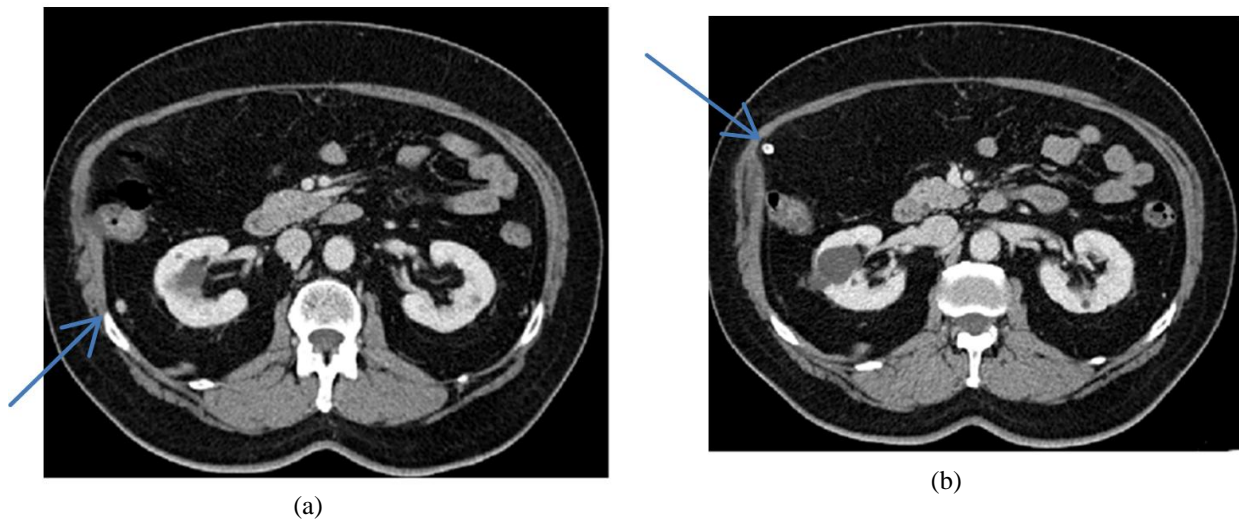


Figure 3 (a) Right latero-conal fascia lesion. (b) Pericolic fat tissue lesion close to right colonic flexure.

One year later, the patient came back to our attention because of follow-up CT scan revealed a 30 mm focal lesion in the context of right chest wall between the ninth and tenth rib. Thus, two abdominal lesions were detected respectively at the level of the right latero-conal fascia (about 7 mm of diameter) and in the upper abdominal quadrant in the context of the pericolic fat tissue close

to the right colonic flexure (about 4 mm diameter) (Figure 2a-b, 3a-b). No laboratory abnormalities were found and AFP was normal.

Percutaneous biopsy of the right chest wall lesion was performed with 18G x 3.3cm BioPince® needle. Histological examination showed metastases from well-differentiated HCC.

Patient underwent thoracotomy with en bloc resection of the intercostal lesion and its surrounding fat subcutaneous tissue (Figure 4a-b). A re-laparotomy was also performed and the two peritoneal lesions were detected respectively in the omentum and in the right lateroconal space. Omentectomy and excision of the right latero-conal space nodule were performed.

Gross examination revealed peritoneal and thoracic lobulated well-demarcated and gryish-white nodules (Figure 4c, 5a-b). Histo-pathological examination showed a well-differentiated HCC with trabecular pattern made by thickened cords of cells separated by vascular spaces and interposed connective stromal tissue (Figure 6a-b). Immuno-histochemical analysis showed diffuse and strong cytoplasmic positivity of neoplastic cells for Hepatocyte Paraffin 1 (HepPar-1) (Monoclonal Mouse anti-human Hepatocyte, clone OCK1E5, DAKO) (Figure 7).

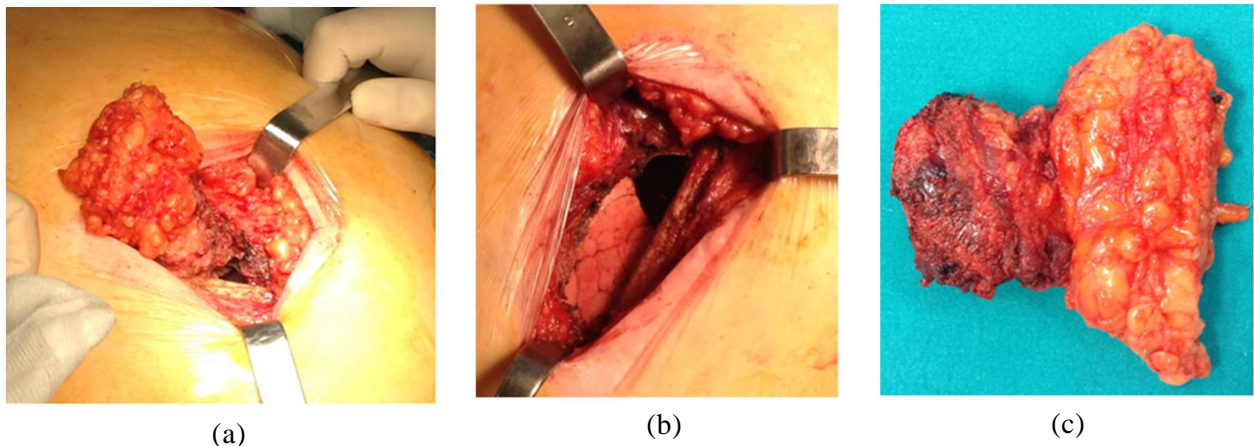


Figure 4 (a) Surgical field showing intercostal lesion exeresis. The lesion is removed en bloc with surrounding tissue. (b) Surgical field after removal of intercostal lesion. (c) Specimen of intercostal resection. Free resection margins are macroscopically showed.

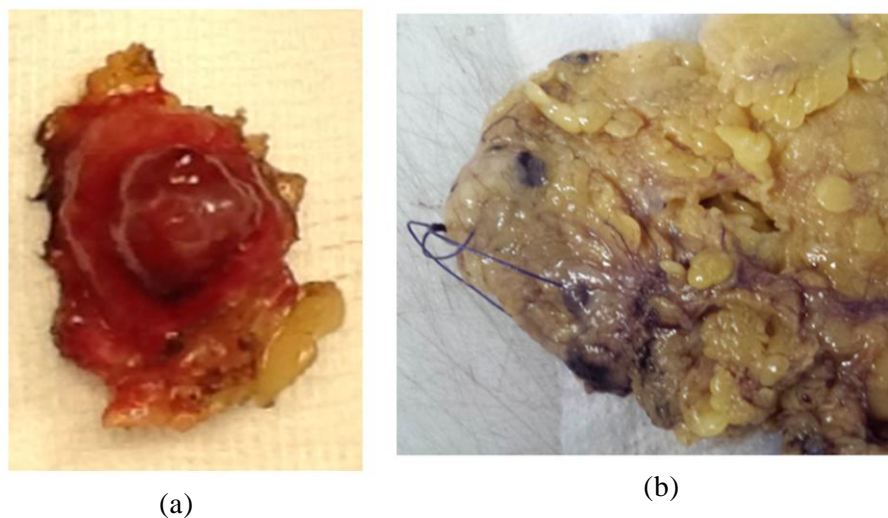
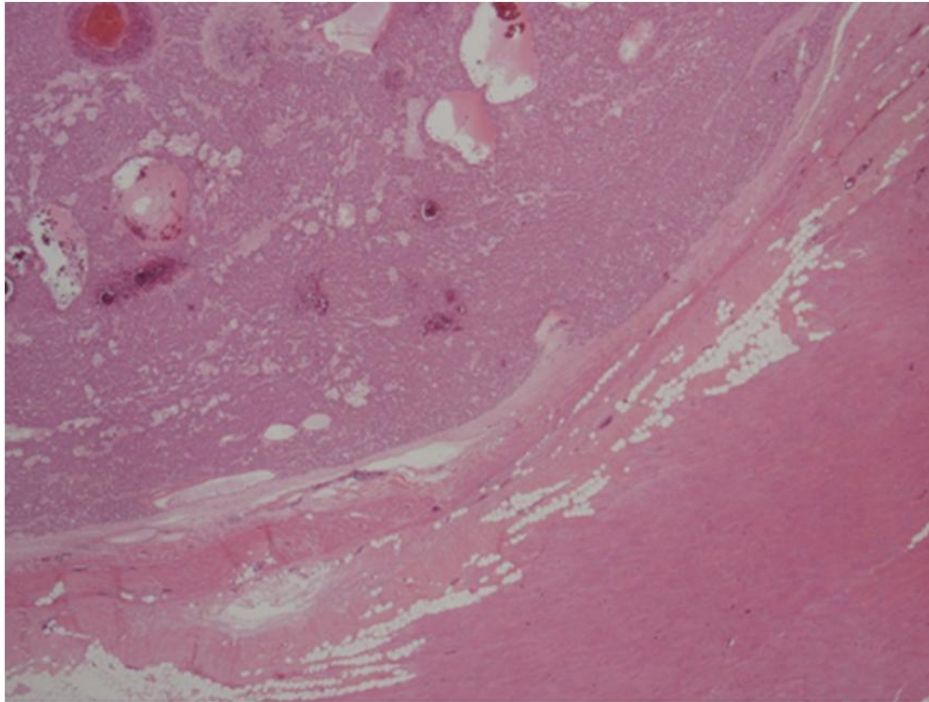


Figure 5 (a) Specimen of nodular lesion in the contest of lateroconal space fat tissue. (b) Omental lesion marked with a stitch.

Postoperative course was uneventful and patient was discharged seven days after surgery and referred to medical oncology.



(a)

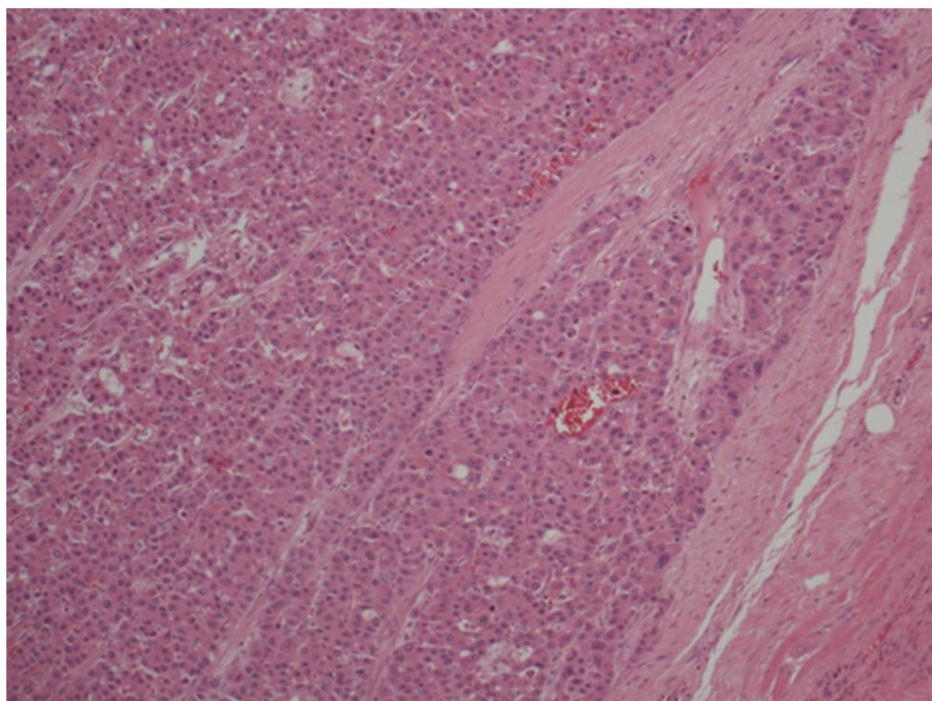


Figure 6 (a) Right chest wall HCC metastases (EE 2X). (b) Right chest wall HCC metastases (EE 10X).

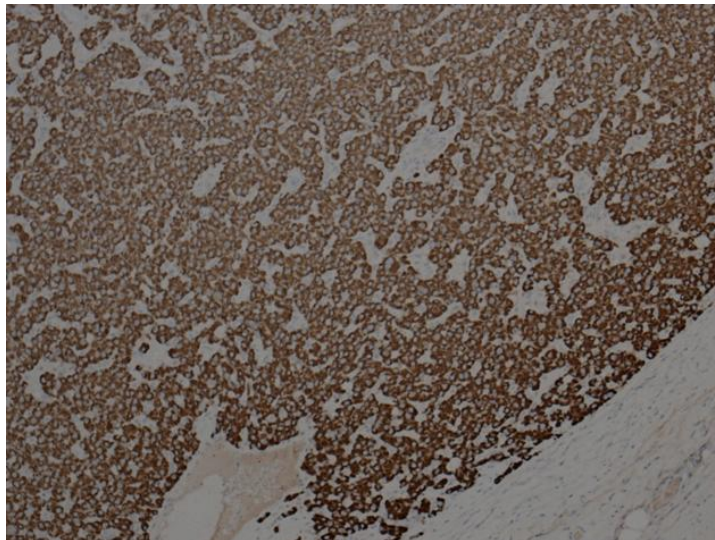


Figure 7 Right chest wall HCC metastases immunostained with anti- Hep-PAR1 antibody (10X).

Discussion

Distant metastases from HCC are a rare occurrence. In most cases lung, lymph nodes, adrenal glands and bone are involved.

Intercostal and peritoneal metastases are particularly rare. The mechanism of distant spreading has not been well defined yet.

Hoffman [4] in 2003 described a case of right chest wall intercostal metastasis from HCC.

One year later, Coban1 described the case of a patient with HCC metastasis of left hemi-thorax. The patient, affected by chronic hepatitis B, did not undergo previous diagnostic or therapeutic percutaneous procedures; therefore, the Author suggested a porto-systemic haematogenous spreading through oesophageal varices which have been identified during gastroscopy.

HCC haematogenous dissemination has been recently purposed by Furumoto too [5].

Khalbuss in 2005 reported a case of left chest wall HCC in a patient without primary HCC or liver disease [6].

In 2006, Hyun hypothesized that in absence of primary tumour, the presence of HCC metastases could be related to carcinomatous degeneration of ectopic liver tissue or to the presence of hepatoid adenocarcinoma [7]. The same Author described a case of a patient with chronic hepatitis B with a left-side chest wall HCC. In this patient, radiological diagnosis of liver cirrhosis was done but oesophageal varices were absent. Thus, histological examination of the specimen did not support both the degeneration of ectopic hepatic tissue (no normal hepatic tissue was found) or the presence of hepatoid adenocarcinoma (no adenocarcinoma structures were identified); therefore, the Author stated that a very tight follow-up was needed to highlight the unrecognized primitive, especially in presence of hepatitis B related cirrhosis.

Our case differs from those above mentioned since our patient presented an intercostal metastasis of the right hemi-thorax and primitive HCC has been resected one year before. Our patient was not affected neither by hepatitis nor cirrhosis. Moreover, peritoneal metastases were present too.

Stigliano [8] reviewed literature and reported a median risk of seeding after biopsy of 2.9% (range 0-11%).

According to this Author, we presume that an intercostal seeding occurred in our patient during percutaneous biopsy performed at the time of first surgery.

Our patient, however, also showed two peritoneal metastases; this type of metastases is rare for a HCC (about 6%) and has often been attributed to intraoperative rupture of HCC [9].

Matsukuma and Sato suggested that peritoneal involvement of HCC account for more aggressive biological behaviour of primary tumour [10]. It's interesting to note that for these Authors, who analysed autopsy series, peritoneal seeding was significantly associated with rupture of HCC (p 0.012), direct invasion of diaphragm (p 0.001) and presence of lymph-node metastases (p <0.001), whereas no association with previous percutaneous procedures (p 0.97) and histological grading (p 0.29) was reported.

Other Authors reported that only low degree of differentiation is associated with higher risk of peritoneal metastases in HCC patients [11].

In contrast to what reported by Matsukuma and Sato, in our case none of those mentioned risk factors for peritoneal dissemination were present. According to them, the high degree of differentiation was not “protective” for distant dissemination.

Terada analysed both autopsy series and surgical specimens of unusual extra-hepatic metastases from HCC; in this experience, HepPar1 and AFP represented excellent markers of extra-hepatic disease [12].

In our case HepPar1 positivity was strong but AFP was normal.

The coexistence of both peritoneal and intercostal metastases, in absence of rupture of the primary tumour in a patient previously submitted to percutaneous biopsy, allow us assume that all the metastases can be linked to the seeding during radiological procedure. Alternatively, considering that primitive HCC was intact but Glisson's capsule was involved, we should assume a double pathogenic mechanism of intercostal seeding during percutaneous procedure and peritoneal dissemination due to primary tumour manipulation during surgery.

Regarding HCC peritoneal metastases therapy, Hashimoto [11] suggested that they should always be resected in absence of other organs involvement and when primary tumour is well controlled.

Conclusion

On the basis of our present and solitary experience, we could purpose that peritoneal metastases should be resected even in addition to radically resectable intercostal metastases when systemic parenchymal disease is absent. However, we are aware that the lack of follow-up and the absence of other similar reported experience do not allow us to support this opinion.

In effect, to the best of our knowledge, this is the first report of surgical resected methachronous concomitant peritoneal and intercostal metastases of well differentiated HCC.

References

1. Coban S, Yüksel O, Köklü S, Ceyhan K, Baykara M, Dökmeçi A. Atypical presentation of hepatocellular carcinoma: a mass on the left thoracic wall. *BMC Cancer*. 2004, 4:89
2. Ikai I, Arii S, Ichida T, Okita K, Omata M, Kojiro M, Takayasu K, Nakanuma Y, Makuuchi M, Matsuyama Y, Yamaoka Y. Report of the 16th follow-up survey of primary liver cancer. *Hepatol Res*. 2005, 32:163-172

3. Nakashima T, Okuda K, Kojiro M, Jimi A, Yamaguchi R, Sakamoto K, Ikari T. Pathology of hepatocellular carcinoma in Japan. 232 Consecutive cases autopsied in ten years. *Cancer*. 1983, 51:863-877
4. Hofmann HS, Spillner J, Hammer A, Diez C. A solitary chest wall metastasis from unknown primary hepatocellular carcinoma. *Eur J Gastroenterol Hepatol*. 2003, 15:557-559
5. Furumoto K, Miura K, Nagashima D, Kojima H, Mori T, Ito D, Kajimura K, Kogire M. Solitary metastasis to the intercostal muscle from hepatocellular carcinoma: A case report. *Int J Surg Case Rep*. 2012, 3:322-326
6. Khalbuss WE, Bajestani S, D'Agostino HJ. Cytomorphology of a solitary left chest wall mass: an unusual presentation from unknown primary hepatocellular carcinoma. *Diagn Cytopathol*. 2007, 35:586-589
7. Hyun YS, Choi HS, Bae JH, Jun DW, Lee HL, Lee OY, Yoon BC, Lee MH, Lee DH, Kee CS, Kang JH, Park MH. Chest wall metastasis from unknown primary site of hepatocellular carcinoma. *World J Gastroenterol*. 2006, 12:2139-2142
8. Stigliano R1, Marelli L, Yu D, Davies N, Patch D, Burroughs AK. Seeding following percutaneous diagnostic and therapeutic approaches for hepatocellular carcinoma. What is the risk and the outcome? Seeding risk for percutaneous approach of HCC.
9. Ding JH1, Chua TC, Al-Mohaimed K, Morris DL. Hepatocellular carcinoma peritoneal metastases: report of three cases and collective review of the literature. *Ann Acad Med Singapore*. 2010, 39:734-744
10. Matsukuma S, Sato K. Peritoneal seeding of hepatocellular carcinoma: clinicopathological characteristics of 17 autopsy cases. *Pathol Int*. 2011, 61:356-62
11. Hashimoto M, Sasaki K, Moriyama J, Matsuda M, Watanabe G. Resection of peritoneal metastases in patients with hepatocellular carcinoma. *Surgery*. 2013, 153:727-731
12. Terada T, Maruo H. Unusual extrahepatic metastatic sites from hepatocellular carcinoma. *Int J Clin Exp Pathol*. 2013, 15;6:816-820