



# Li-Fraumeni Syndrome: Adopting a Diagnosis with an Unknown Family History

Jia Hong Chen<sup>1\*</sup>, David I. Kaufman MD<sup>2</sup>, Justin Chin<sup>1\*</sup>, Christine Lomiguen MD<sup>3</sup>

1. Department of Primary Care, Touro College of Osteopathic Medicine, New York, NY, USA

2. Department of Surgery, St. Joseph Hospital, Bethpage, NY, USA

3. Department of Pathology, Lake Erie College of Osteopathic Medicine, Erie, PA, USA

## Abstract:

**Introduction:** Li-Fraumeni Syndrome (LFS) is a rare, autosomal dominant disease that is typically screened for and identified in patients with a known history of cancer and family history of cancer.

**Presentation of Case:** Ms. DA is an adopted 39-year-old South American female with a past medical history of iron deficiency anemia, celiac disease, and polio. She presented with ductal carcinoma in-situ with spindle cell atypia at age 35 and leiomyosarcoma of the ankle at age 36. Genetic counseling was offered due to her age and cancer types, with subsequent genetic testing revealing a TP53-R337H mutation, which was diagnostic of LFS. Given her high risk status, extensive cancer screenings at common LFS body sites were recommended, but she was lost to follow-up. Four years later, she returned after discovering a new right breast mass on self-examination. She was referred to a new breast surgeon, who was able to establish consistent and close follow-up while providing counseling and education regarding lifetime risk and cancer trajectory of classical LFS compared to the Brazilian LFS-subtype.

**Conclusion:** The importance of having a high level of suspicion for patients with an unknown family history is crucial as seen in this case. Without a biological family history, clinicians rely on their judgement to decide when further work-up is warranted. Advancements in medicine and genetic testing have increased the ability to accurately diagnose genetic diseases to help patients make life-saving decisions about their health.

**Keywords:** Li-Fraumeni Syndrome; LFS; breast cancer; screening; adoption

**Received:** August 21, 2019; **Accepted:** October 14, 2019; **Published:** October 18, 2019

**Competing Interests:** The authors have declared that no competing interests exist.

**Consent:** Consent was taken from the patient's next of kin for publication of this case report.

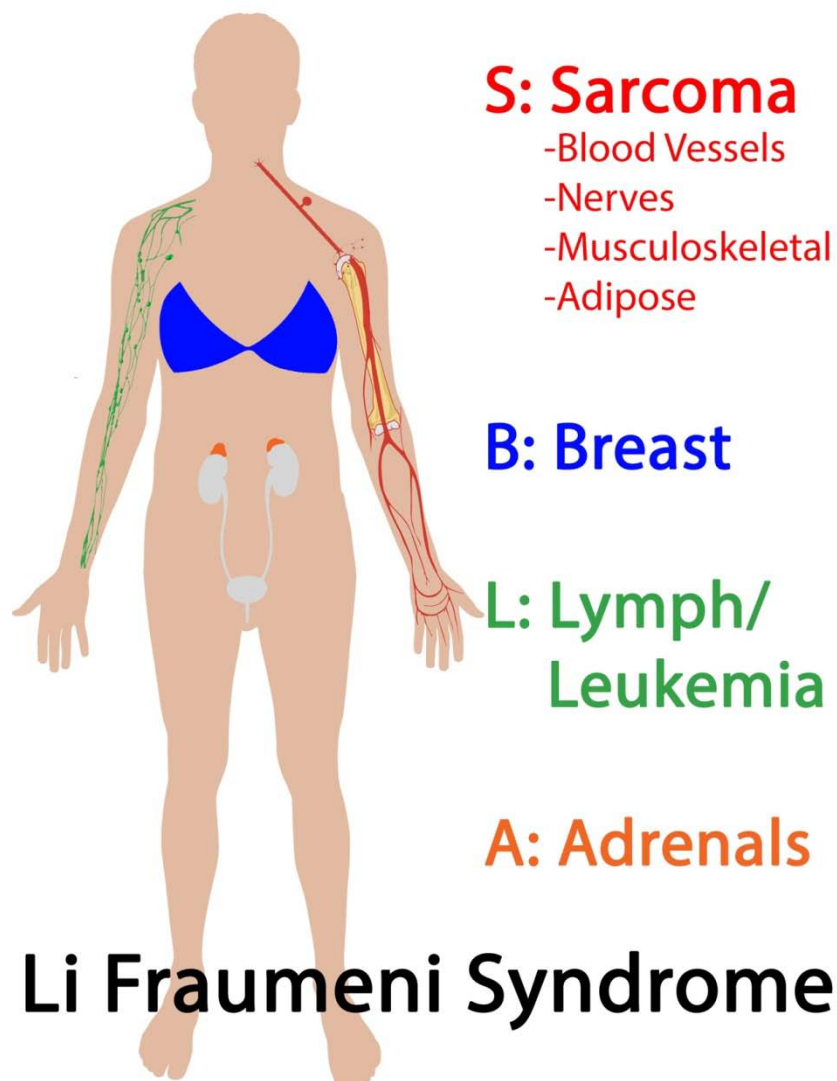
**Copyright:** 2019 Justin Chin *et al.* This is an open-access article distributed under the terms of the Creative Commons Attribution License, which permits unrestricted use, distribution, and reproduction in any medium, provided the original author and source are credited.

**\*Correspondence to:** Justin Chin, OMS-IV, Touro College of Osteopathic Medicine, 230 West 125th Street, New York, NY 10027

**Email:** [jchin2@student.touro.edu](mailto:jchin2@student.touro.edu)

## Introduction

Li-Fraumeni Syndrome (LFS) is an inherited autosomal dominant malignancy that is characterized by the development of multi-system cancers due to a deficiency in the cell cycle regulator, TP53 (Figure 1)[1]. Also known as Sarcoma-Breast-Leukemia-Adrenal Gland (SBLA) Cancer Syndrome, approximately 400 families in the United States have been described in literature with this disease since its initial characterization in 1969 [1, 2]. The overall prevalence worldwide is less known, with an estimate of over 1000 multigenerational families across 172 countries. Family history plays a significant role in risk stratification and screening protocols since definitive diagnosis requires physicians to identify the risk and order DNA sequencing to identify TP53 mutations or deletions [3]. In presence of young age and absence of family history, providers need to have an even higher index of suspicion in caring for patients with possible multi-system cancers. Here we present an adopted patient with no known biological family history with a classical LFS presentation.



**Figure 1** LFS and its common cancer associations

## Case presentation

Ms. DA is a 39-year-old South American female with a past medical history of iron deficiency anemia, celiac disease, and polio. She was adopted as a child from Brazil and was unaware of her biological family's medical history. She initially presented at age 35 for an early screening mammogram, which showed a well-circumscribed density in the central right breast. An image-guided core biopsy revealed ductal carcinoma in-situ with spindle cell atypia, with subsequent right breast lumpectomy and whole breast radiation treatment. One year later, she returned with a new left ankle mass. Excisional biopsy and resection revealed a leiomyosarcoma with clear margins noted, with radiotherapy afterwards.

Genetic counseling was offered due to her age and cancer types, with subsequent genetic testing revealing a TP53-R337H mutation, which was diagnostic of LFS. Given her high risk status, extensive cancer screenings at common LFS body sites were recommended, but she was lost to follow-up.

Four years later, she returned after discovering a new right breast mass on self-examination. Mammogram and ultrasound confirmed a benign hematoma, likely due to trauma. She was referred to a new breast surgeon, who was able to establish consistent and close follow-up while providing counseling and education regarding lifetime risk and cancer trajectory of classical LFS compared to the Brazilian LFS-subtype. After extensive discussion, the patient opted for prophylactic bilateral mastectomy and reconstruction due to concerns of prior radiotherapy exposure to her breast. Since then, she had no new complaints and is compliant with standard LFS cancer screening schedules.

## Discussion

LFS carries a primary cancer risk of up to 100%, by the age of 60 in women, and a risk of up to 73% in men [4]. Furthermore, these patients have a high risk of developing a secondary and a tertiary malignancy of about 30-57% and 38%, respectively [5, 6]. Early detection and referral for genetic screening becomes complicated in situations such as Ms. DA as LFS screening criteria consistently utilize family history as a defining feature (Figure 2)[7]. Other protocols with and without family history have also been used, with varying success rates [8-11]. Despite having an unknown family history and only fulfilling the personal history of cancer criteria, her presentation relative to her age triggered a high index of clinical suspicion and warranted further work-up.

Criteria for TP53/Molecular Testing for LFS	
Classical	1. Proband with sarcoma diagnosed before age 45 AND
	2. First-degree relative with any cancer before age 45 AND
	3. First/Second-degree relative with any cancer before age 45/sarcoma at any age
Chompret	1. Classical criteria, but before age 46
	2. Proband with multiple tumors (except breast), 2 of LFS spectrum, 1 before 46
	3. Proband with adrenocortical or choroid plexus tumor, regardless of family history
Birch	Similar to classical, however proband can also be diagnosed with brain or adrenocortical tumor in addition to sarcoma
Eeles	<b>Family history only: 2 first- or second-degree relatives with LFS spectrum malignancies, diagnosed at any age</b>

**Figure 2** Various criteria for assessing need for genetic testing in definitive diagnosis of LFS.

Subsequent cancer screenings with individuals with LFS include: annual physical, clinical, self-breast, and dermatological examinations, whole body MRI screening for secondary cancers, colorectal screening and risk-reducing bilateral mastectomy [12, 13]. High recurrences of secondary and tertiary cancers rates in LFS require patients to undergo strict surveillance studies. Of note, compared to the high lifetime primary cancer risk of most individuals/families with LFS, the Brazilian population's specific R337H founder mutation has only a 60% lifetime risk with improved survival rates post-treatment[14].

The differential diagnosis for LFS can include *BRCA1/BRCA2* mutations for breast cancer, and the family of DNA repair enzymes of *MLH1*, *MSH2*, *MSH6*, *PMS1*, and *PMS2* in mismatch repair cancer (Lynch) syndrome[12, 13]. Advances in genetic screening and testing, however, has eliminated the uncertainty of these inherited cancer syndromes through accurate diagnosis. Despite its rarity and lack of supporting family history, Ms. DA was able to make potentially lifesaving decisions due to the clinical judgement of her physicians. Further studies are required to assess the utility of genetic testing in adoption cases where family history is unavailable.

## Conclusion

Li Fraumeni Syndrome is a rare, autosomal dominant disease that is typically screened for and identified in patients with a known history of cancer and family history of cancer. As seen in this case, the importance of suspicion and clinical judgement for patients with an unknown family history is crucial. In the setting of global migration, physicians need to have high clinical suspicion when confronted with abnormal age to cancer presentations. Advancements in medicine and testing have increased our ability to accurately diagnose genetic diseases to help patients make life-saving decisions about their health and healthcare.

## Acknowledgements

The authors would like to acknowledge the staff at St. Joseph Hospital's Breast Health Center for their work and dedication.

## Competing interest and funding statement

Jia Hong Chen, David I. Kaufman MD, Justin Chin, and Christine Lomiguen MD report that there are no competing interests or financial disclosures for this study.

## Consent

Patient has given their informed consent for this case report to be published.

## References

1. Li FP, Fraumeni JF, Jr. Soft-tissue sarcomas, breast cancer, and other neoplasms. A familial syndrome? *Ann Intern Med.* 1969, 71:747-752

2. Peng G, Bojadzieva J, Ballinger ML, Li J, Blackford AL, Mai PL, Savage SA, Thomas DM, Strong LC, Wang W. Estimating tp53 mutation carrier probability in families with li-fraumeni syndrome using lfspro. *Cancer Epidemiol Biomarkers Prev.* 2017, 26:837-844
3. Malkin D. Li-fraumeni syndrome. *Genes Cancer.* 2011, 2:475-484
4. Mai PL, Best AF, Peters JA, DeCastro RM, Khincha PP, Loud JT, Bremer RC, Rosenberg PS, Savage SA. Risks of first and subsequent cancers among tp53 mutation carriers in the national cancer institute li-fraumeni syndrome cohort. *Cancer.* 2016, 122:3673-3681
5. Hisada M, Garber JE, Fung CY, Fraumeni JF, Jr., Li FP. Multiple primary cancers in families with li-fraumeni syndrome. *J Natl Cancer Inst.* 1998, 90:606-611
6. Schneider K, Zelle K, Nichols KE, Garber J. Li-fraumeni syndrome. In: Adam MP, Ardinger HH, Pagon RA, Wallace SE, Bean LJH, Stephens K, Amemiya A, eds. *GeneReviews((r))*. Seattle (WA); 1993.
7. Li FP, Fraumeni JF, Jr., Mulvihill JJ, Blattner WA, Dreyfus MG, Tucker MA, Miller RW. A cancer family syndrome in twenty-four kindreds. *Cancer Res.* 1988, 48:5358-5362
8. Chompret A, Abel A, Stoppa-Lyonnet D, Brugieres L, Pages S, Feunteun J, Bonaiti-Pellie C. Sensitivity and predictive value of criteria for p53 germline mutation screening. *J Med Genet.* 2001, 38:43-47
9. Birch JM, Hartley AL, Tricker KJ, Prosser J, Condie A, Kelsey AM, Harris M, Jones PH, Binchy A, Crowther D, et al. Prevalence and diversity of constitutional mutations in the p53 gene among 21 li-fraumeni families. *Cancer Res.* 1994, 54:1298-1304
10. Eeles RA. Germline mutations in the tp53 gene. *Cancer Surv.* 1995, 25:101-124
11. Gonzalez KD, Noltner KA, Buzin CH, Gu D, Wen-Fong CY, Nguyen VQ, Han JH, Lowstuter K, Longmate J, Sommer SS, Weitzel JN. Beyond li fraumeni syndrome: Clinical characteristics of families with p53 germline mutations. *J Clin Oncol.* 2009, 27:1250-1256
12. Ruijs MW, Verhoef S, Rookus MA, Pruntel R, van der Hout AH, Hogervorst FB, Kluijdt I, Sijmons RH, Aalfs CM, Wagner A, Ausems MG, Hoogerbrugge N, van Asperen CJ, Gomez Garcia EB, Meijers-Heijboer H, Ten Kate LP, Menko FH, van 't Veer LJ. Tp53 germline mutation testing in 180 families suspected of li-fraumeni syndrome: Mutation detection rate and relative frequency of cancers in different familial phenotypes. *J Med Genet.* 2010, 47:421-428
13. Win AK, Young JP, Lindor NM, Tucker KM, Ahnen DJ, Young GP, Buchanan DD, Clendenning M, Giles GG, Winship I, Macrae FA, Goldblatt J, Southey MC, Arnold J, Thibodeau SN, Gunawardena SR, Bapat B, Baron JA, Casey G, Gallinger S, Le Marchand L, Newcomb PA, Haile RW, Hopper JL, Jenkins MA. Colorectal and other cancer risks for carriers and noncarriers from families with a DNA mismatch repair gene mutation: A prospective cohort study. *J Clin Oncol.* 2012, 30:958-964
14. Palmero EI, Schuler-Faccini L, Caleffi M, Achatz MI, Olivier M, Martel-Planche G, Marcel V, Aguiar E, Giacomazzi J, Ewald IP, Giugliani R, Hainaut P, Ashton-Prolla P. Detection of r337h, a germline tp53 mutation predisposing to multiple cancers, in asymptomatic women participating in a breast cancer screening program in southern brazil. *Cancer Lett.* 2008, 261:21-25