



Case Report

Renal Carcinoid Tumor – Primary or Metastatic? A Case Report

Vânia Grenha^{*1}, Bruno Pereira², Rui Martins³, Hugo Coelho¹, Edson Retroz¹, Alfredo Mota¹

¹Serviço de Urologia e Transplantação Renal, Centro Hospitalar e Universitário de Coimbra, Portugal

²Serviço de Urologia, Centro Hospitalar da Cova da Beira, Portugal

³Serviço de Cirurgia Geral, Instituto Português de Oncologia, Portugal

Abstract:

Introduction: Renal carcinoid tumor is an extremely rare neoplasia. It arises from neuroendocrine cells, which have never been identified within the normal renal parenchyma. After diagnosis, which is usually histological and proceeds nephrectomy, it is therefore important to exclude a primary tumor located elsewhere. Somatostatin receptor scintigraphy is a fundamental test in identification of primary tumor/metastases.

Presentation of Case: We present a 77 year old man with this rare tumor: a primary carcinoid renal tumor, diagnosed in Portugal. He was asymptomatic and staging revealed no metastases. A partial nephrectomy was performed. After 2 years of follow up there is no evidence of clinic or imagiologic recurrence.

Conclusion: There are no neuroendocrine cells within renal parenchyma. Thus primary renal carcinoid is still a mystery. Our case confirms the existence of this entity and allows us to know more about its natural history. It is important to disclose all cases of this rare condition, so we can better treat these patients in the future.

Keywords: Primary renal carcinoid tumor; neuroendocrine cells; somatostatin receptor scintigraphy

Academic Editor: Xiaoning Peng, Hunan Normal University School of Medicine, China

Received: May 3, 2014 **Accepted:** June 11, 2014 **Published:** July 13, 2014

Competing Interests: The authors have declared that no competing interests exist.

Copyright: 2014 Grenha V *et al.* This is an open-access article distributed under the terms of the Creative Commons Attribution License, which permits unrestricted use, distribution, and reproduction in any medium, provided the original author and source are credited.

***Correspondence to:** Vânia Grenha, Serviço de Urologia e Transplantação Renal, Centro Hospitalar e Universitário de Coimbra, Portugal. Email: vaniagrenha.uro@gmail.com

Introduction

Carcinoid tumors are defined as well differentiated neuroendocrine tumors [1,2]. These tumors are rare and arise from neuroendocrine cells that are dispersed throughout the body [3]. They are commonly seen in gastrointestinal tract, lungs and pancreas and less frequently in larynx, trachea, breast, biliary duct, gallbladder, ovaries, testis, prostate and kidney [2].

Renal carcinoid tumor (RCT), such as carcinoid tumors in other locations, arises from neuroendocrine cells. However these cells have never been identified within the normal renal parenchyma. In genitourinary system, neuroendocrine cells were identified only in bladder and prostate [8]. Several theories exist about the origin of primary RCT, as discussed later.

Because of its rarity (less than 1% of carcinoid tumors), after diagnosis it's important to exclude a primary tumor located elsewhere [1]. The set of complementary tests that should be done include neuroendocrine serum markers (NSM), computed tomography (CT) or magnetic resonance imaging (MRI) and somatostatin receptor scintigraphy (SRS) with octeotide. These tests also allow staging the tumor [2].

Case Presentation

A 77 year old man presented to us with a CT scan showing a mass with a 3,5 cm diameter, located in the inferior pole of right kidney. He was asymptomatic. Staging with CT revealed no metastases. A partial nephrectomy was performed and microscopy showed that it was a well differentiated renal carcinoid.

Throughout this result, some complementary exams were required: NSM, upper endoscopy and colonoscopy, thorax radiography and SRS. Upper endoscopy and colonoscopy excluded primary intestinal tumor. Analysis revealed an elevation on 5-hydroxyindolacetic acid (5-HIAA) - 19.8mg/24h (reference range 2-6mg/24h) - and vanillylmandelic acid - 18.1mg/24h (reference range 2-7mg/24h). SRSO revealed a pancreatic foci suspicious of primary tumor or physiologic uptake (Figure 1). Pancreatic magnetic resonance was immediately performed, excluding primary pancreatic tumor.

After 2 years of follow up, our patient remains asymptomatic and there is no evidence of imagiologic recurrence.

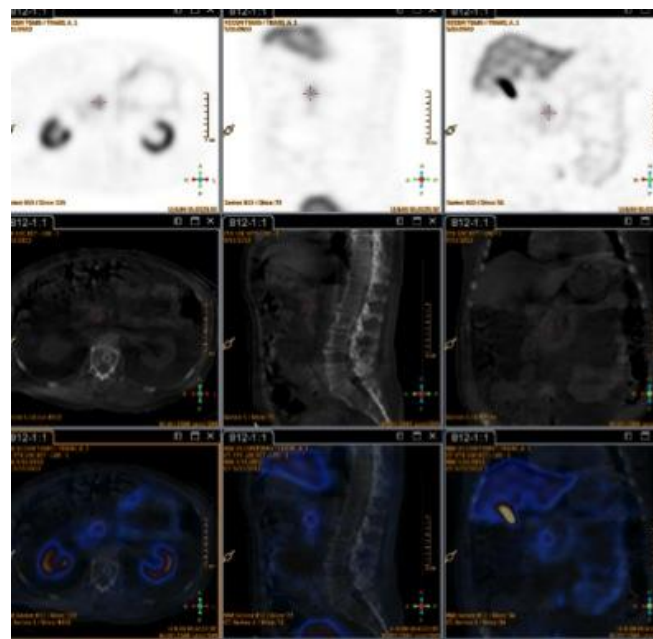


Figure 1 Somatostatin receptor scintigraphy showing the pancreatic foci suspicious of primary tumor or physiologic uptake

Discussion

RCT has been reported in literature as case reports and small reviews only. No randomised studies have been published about it [4]. Less than 100 cases have been described so far, in literature [1, 3, and 4]. The first case was reported in 1966, by Rensick et al [5]. We found only one portuguese case published [6].

The reason for this is probably related with the low prevalence of this tumor. Less than 1% of carcinoid tumors are primary genitourinary tumors and primary RCT are among the most unusual of all renal neoplasms [3]. Consequently, RCT pathogenesis, clinical behaviour, treatment and follow up are not well established yet.

RCT pathogenesis is a controversial issue, once neuroendocrine cells have never been identified in kidney parenquima, but several mechanisms have been hypothesized. It is believed that RCT may arise from primitive pluripotential stem cells that differentiate into aberrant neuroendocrine cells [4]. Another theory says that RCT arise from pre-existing or acquired hiperplasia of neuroendocrine cells found within foci of metaplastic or teratomatous epithelium [7]. And a third theory says that neuroendocrine cells derive from misplaced neural crests or pancreatic tissue within the metanephros during embryogenesis [3, 7]. The latest theories probably emerged from the finding of a higher prevalence of horseshoe kidney and teratomas, among patients with RCT.

The age of RCT diagnosis ranges between the fifth and sixth decades of life, with older age representing a bad prognosis factor. The incidence between genders has no relevant difference [4]. About a half of patients presents haematuria or flank/abdominal pain, 20% are asymptomatic, 15% have constitutional symptoms and only 13% presents with carcinoid syndrome [2, 7, 8]. In the future, with development of imaging, especially ultrasound, more RCT as other renal masses, will probably be incidentally detected [3]. That's the case of our patient, as described above.

RCT is difficult to distinguish from renal carcinoma pre-operatively, so final diagnosis is always histopathological [7]. However, histopathological examination is not sufficient to distinguish whether the tumor is a primary RCT or a metastasis [3].

Somatostatin receptor scintigraphy is recognised as an integral diagnosing and staging tool in the evaluation of carcinoid tumors. These tumors have high affinity receptors for somatostatin [9]. The radiolabeled octeotride (synthetic and slowly degraded somatostatin analog) binds somatostatin receptor with high affinity, detecting even the smallest carcinoid tumors with 85% sensitivity [2]. SRS use is therefore mandatory on RCT diagnosis, initially to exclude a primary tumor in another location and later, at follow up, to detect metastases.

The RCT natural history and prognosis are not well understood, but outcome from published literature suggests that it has a less aggressive behavior than renal cell carcinoma [1, 3]. The major bad prognostic factors are age above 40 years, tumor size over 4 cm and tumors not confined to the renal parenchyma [3].

Metastases are rare. The most common sites are paraortic or hilar lymph nodes, followed by liver, bone and lung. The presence of metastases seems to be a bad prognostic factor, although some patients with solid organ metastatic disease lived for several years [3].

Surgical treatment (total or partial nephrectomy) is the primary approach and it's apparently curative for localized disease [7]. Metastases, when present, and if possible, should also be removed or ablated, such as in other carcinoid tumors [1]. Cytotoxic chemotherapy has only limited success in treatment of metastatic disease. Somatostatin analogues like octeotride or lanreotide have been used in advanced disease with a response rate of 36-70% [1]. Octeotride not only plays an important role in decreasing the symptoms of hormonal excess but also is considered as a first line antineoplastic systemic therapy for patients with positive SRS [3].

Follow up should always exceed 5 years,

including physical examination, NSM and imaging (CT or MRI, complemented with SRS), every 3 to 6 months [3].

Conclusion

Primary RCT, despite its rarity an unknown aetiology, exists as a clinical entity. Our patient represents one of these rare cases, and fits in the literature review. Long-term studies are needed to determinate the exact clinical behavior and effective treatments for this rare tumor.

References

1. Jeung J, Cao D, Selli B, Clapp W, Oliai B, Parwani A, Allan R. Primary renal carcinoid tumors: clinicopathologic features of 9 cases with emphasis on novel immunohistochemical findings. *Human Pathology*. 2011, 42:1554-1561
2. Singh P, Malhotra A, Kashyap V. Carcinoid tumor of the kidney: An unusual renal tumor. *Indian J. Urol* 2009, 25: 537-538
3. Korkmaz T, Seber S, Yavuzer D, Gumus M, Turhal N. Primary renal carcinoid: Treatment and prognosis. *Critical Reviews in Oncology/Hematology*. 2013, 87:256-64
4. Lane B, Jour G, Zhou M. Renal neuroendocrine tumors. *Indian J Urol*. 2009, 25:155-160
5. Resnick M, Unterberger H, McLoughlin P. Renal carcinoid producing the carcinoid syndrome. *Med Times*. 1966, 94:895-896
6. Cabral Ribeiro J, Sousa L, Ribeiro Santos A. Primary neuroendocrine tumor of the kidney. *Actas Urol Esp*. 2010, 34: 907-9
7. Geramizadeh B, Khezri A, Shariat M. Renal Carcinoid Tumor. *Saudi J Kidney Dis Transplant*. 2009, 20: 462-64.
8. Shurtleff B, Shvarts O, Rajfer J. Carcinoid Tumor of the Kidney: Case Report and Review of the Literature. *Rev Urol*. 2005, 7: 229-33
9. McCaffrey J, Reuter V, Herr H, Macapinlac H, Russo P, Motzer R. Carcinoid tumor of the kidney. The use of somatostatin receptor scintigraphy in diagnosis and management. *Urologic Oncology*. 2000, 5:108-111
10. Kato Y, Nakamura K, Yamada Y, Nishikawa G, Yoshizawa T, Zennami K, Katsuda R, Tobiume M, Aoki S, Taki T. A rare case of metastatic renal carcinoid. *BMC Urology*. 2010, 10:22