



Research Article

Anticarcinogenic Effect of Probiotic Dahi and Piroxicam on DMH-induced Colorectal Carcinogenesis in Wistar Rats

Dheeraj Mohania^{1*}†, Vinod Kumar Kansal¹, Renu Sagwal¹, and Dilip Shah²

¹Animal Biochemistry Division, National Dairy Research Institute, Karnal, Haryana, India

²Center for Translational Medicine, Thomas Jefferson University, Philadelphia, PA 19107, USA

Abstract

This study examined the therapeutic effects of probiotic Dahi containing *Lactobacillus acidophilus* LaVK2 and *Lactobacillus plantarum* Lp9, alone or as well as in combination with piroxicam (PXC) as an antioxidant agent in male Wistar rats administered 1, 2-dimethylhydrazine dihydrochloride (DMH). Colorectal carcinogenesis was induced by injecting DMH subcutaneously (40 mg/kg body weight) twice a week for 2 weeks. The rats were fed with buffalo milk or probiotic Dahi alone or in combination with PXC in addition to basal diet ad libitum and euthanized at 8th, 16th and 32nd week of the experiment and examined for biochemical and histopathological profile. A significant reduction in lipid peroxidation measured as thiobarbituric acid reactive substances (TBARS) in liver and colorectal tissue, and carcinogen activating enzyme measured as β -glucuronidase activity in faeces were observed in probiotic Dahi-DMH-PXC group compared with the DMH control group. Probiotic Dahi alone or in combination with PXC was showed a significant ($P < 0.05$) protective effect by lowering the levels of TBARS, faecal β -glucuronidase and by enhancing the activity GST in liver and colorectal tissues, correlated with decreased tumor incidence, tumor multiplicity and tumor volume in gastrointestinal (GI) tract in DMH induced rats. These observations suggest that probiotic Dahi alone or conjointly with PXC may have therapeutic potential in attenuation of carcinogenesis in GI tract.

Keywords: Probiotics; Piroxicam; *Lactobacillus*; Colorectal carcinogenesis

Peer Reviewers: Guei-Sheung Liu, Department of Ophthalmology, University of Melbourne & Centre for Eye Research Australia, Australia; Anthony E. Dragun, Department of Radiation Oncology, University of Louisville School of Medicine, United States

Received: April 28, 2013; **Accepted:** July 13, 2013; **Published:** August 20, 2013

Competing Interests: The authors have declared that no competing interests exist.

Copyright: 2013 Mohania D *et al.* This is an open-access article distributed under the terms of the Creative Commons Attribution License, which permits unrestricted use, distribution, and reproduction in any medium, provided the original author and source are credited.

***Correspondence to:** Dheeraj Mohania, Department of Research, Sir Ganga Ram Hospital, Rajinder Nagar, New Delhi-110060, India. Email: dmohania@gmail.com; **Present address:** Department of Research, SirGangaRamHospital, Rajinder Nagar, New Delhi-110060, India. Tel.: +91-011-42251624, Fax: +91-011-25861002; Email: dmohania@gmail.com

Introduction

Colorectal cancer is the fourth most common cancer in men and the third most common cancer in women worldwide and is therefore a major health problem accentuating the need for effective chemopreventive strategies [1, 2]. The protective effect of nonsteroidal anti-inflammatory drugs, such as aspirin, piroxicam and sulindac, in colon cancer has been well documented in epidemiologic and animal studies [2]. In recent years, a substantial growing interest towards probiotics (live microorganism such as bacteria, beneficial to health, which when consumed in sufficient numbers confer health benefits by colonizing in the gut and inhibiting the growth of pathogenic organisms) has been developed throughout the world, leading to vigorous research on the relationship between diet, dietary constituents and their health benefits.

Convincing studies suggests that probiotics modulate the host resistance against intestinal infections, to reduce the absorption of mutagens that could contribute to colon carcinogenesis [3], reduce DNA damage induced by chemical carcinogens in the colonic mucosa of rats [4] and provide protective effects against colon cancer development [3-5]. The colonic microbiota has been identified as being capable of influencing gastrointestinal diseases and disorders including that of colorectal cancer [6]. There exists a potential role for foods that contain probiotics and/or prebiotics to change the colonic microbiota in a way that might prevent diseases such as colorectal cancer [7-10].

Piroxicam (PXC; 4-hydroxyl-2-methyl-N-2-pyridinyl-2H-1, 2,-benzothiazine-3-carboxamide-1, 1-dioxide) a nonsteroidal anti-inflammatory drugs (NSAID) is non-selective COX inhibitor, widely used for treatment of inflammatory arthritis [6], has been regarded chemopreventive agent that inhibits methylazoxymethanol acetate-, methylnitrosourea-, and AOM-induced intestinal tumors in animal models [7, 8]. PXC not only prevent but also cause regression of precancerous lesions identified as aberrant crypt foci (ACF), both of which were associated with the prevention of colon tumors in azoxymethane (AOM)-induced colon cancer in rats [9]. PXC elevates detoxification potential of tissues from the gastrointestinal tract and oesophagus, by increasing the

expression of glutathione-S-transferase (GST) in carcinogen induced gastrointestinal tumors in rats [10]. Thus, PXC may diminish the bioavailability of dietary carcinogen by impeding their absorption and by enhancing their removal through faeces leading to reduced oxidative stress and tumour formation.

Recently, our laboratory have shown that the product under current investigation attenuates the diet induced hypercholesterolemia in rats [11], and improves macrophage activity and confers protection against enteric infection in mice [19]. It converses age related deregulation of tissue antioxidant activities and decline in expression of biomarkers of ageing (peroxisome proliferators activated receptors- α , senescence marker protein-30) in hepatic and kidney tissues [20] and alleviates age induced decline in macrophage and lymphocyte functions [12]. Dahi is fermented buffalo milk widely consumed in Indian sub-continent and is prepared using mesophilic culture of lactococci, which are not probiotic in nature. Being a fermented milk product, Dahi can be an excellent medium for delivery of probiotic strains that can provide protection against colorectal cancer. In this context, the present study was carried out for the first time to evaluate the protective role of probiotic Dahi and its intervention with PXC on DMH-induced colorectal carcinogenesis in male Wistar rats.

Material and Methods

Bacterial strains

Lactococcus lactis ssp. *cremoris* NCDC-86 and *Lactococcus lactis* ssp. *lactis* biovar *diacetylactis* NCDC-60 were obtained from National Collection of Dairy Cultures, National Dairy Research Institute, Karnal, India. *Lactobacillus plantarum* Lp9 was a generous gift from Dr. V. K. Batish, Emeritus Scientist, Dairy Microbiology Division, NDRI, Karnal, India. Lactobacilli and lactococci were propagated and maintained in MRS-broth and M17 broth (Himedia Laboratories Pvt. Ltd., Mumbai, India) at 37 and 30°C, respectively and were stored at 4 to 8°C between transfers. *L. plantarum* and *L. acidophilus* were

propagated and cultured at 37°C for 24 h and 37°C for 48 h, respectively.

Preparation of Dahi and probiotic Dahi (LaLp Dahi)

Bacterial cultures were revitalized three times in reconstituted and autoclaved skim milk prior to use for preparation of fermented milk. Buffalo milk obtained from the cattle yard of the institute and standardized to 3.0% fat was heated to 90°C for 15 min and then cooled to 37°C. Dahi was prepared by culturing standardized buffalo milk with Dahi starter (*Lactococcus lactis* ssp. *cremoris* and *Lactococcus lactis* ssp. *lactis* biovar *diacetylactis*, 1% each) at 30°C for 8 h. Probiotic LaLp Dahi was prepared by culturing buffalo milk with *L. acidophilus* LaVK2, *Lactobacillus plantarum* Lp9 and Dahi culture (1.0%). The final product contained 2×10^9 cfu/g of lactococci, *L. plantarum* and *L. acidophilus* each.

Chemicals

1, 2-dimethylhydrazine dihydrochloride (DMH), piroxicam (PXC), para-Nitrophenyl- β -D-glucuronide (pNPG) and para-Nitrophenol (pNP) were purchased from Sigma-Aldrich Chemical Co. (St. Louis, MO, USA) while, 1-chloro-2, 4-dinitrobenzene (CDNB), Thiobarbituric acid (TBA), EDTA, glutathione, para-nitrophenol, Potassium phosphate were purchased from Sisco Research Laboratories (Mumbai, India). All other chemicals were obtained from s.d. Fine Chemicals Ltd., Mumbai, India or Hi-Media Lab. Ltd., Mumbai, India.

Animals and Diet

Male Wistar rats 3 weeks of age were obtained from Animal House of NDRI, India, and maintained in a small animal house. The animals were housed in stainless steel cages (2 animals per cage) throughout the study, and the room temperature was maintained at $25 \pm 2^\circ\text{C}$ with $55 \pm 5\%$ humidity and at a 12-hour light/12-hour dark cycle. The animals were used and cared for in accordance with the principles and

guidelines for humane use, and the protocol was approved by the institutional ethics committee. The composition of basal diet was starch, 63%; casein, 20%; soybean oil, 5.5%; cellulose, 5%; mineral mixture, 5%; vitamin mixture, 1%; D-L methionine, 0.2%; and choline chloride, 0.2%. Salt mixture required for 10 kg diet (500g) contained CaCO₃, 190.7g; CoCl₂.6H₂O, 0.0115g; CuSO₄.5H₂O, 0.238g; FeSO₄.7H₂O, 13.5g; KH₂PO₄, 194.5g; KI, 0.4g; MgSO₄.7H₂O, 58.62 g; MnSO₄.H₂O, 2.005g; NaCl, 69.65g; and ZnSO₄.7H₂O, 0.274g. Vitamin mixture (100g) comprised of biotin, 4 mg; folic acid, 20 mg; vitamin B₁₂, 0.3 mg; menadione, 50 mg; para aminobenzoic acid, 1 g; meso-inositol, 1 g; thiamine, 50 mg; riboflavin, 80 mg; pyridoxine, 50 mg; calcium pantothenate, 0.4g and starch, 76.946 g. Vitamin A (2 x 10⁵ IU), vitamin E (103 IU) and vitamin D (2 x 10⁴ IU) were administered to the diet through oil / fat (for 10Kg diet).

Experimental design

Animals were randomly distributed into five groups, twenty four rats in each group and fed with the probiotic supplements (20 g) in addition to basal diet for 32 weeks. Rats of Group I was fed with buffalo milk (BM) which served as control group. Rats of group II was administered DMH and served as the DMH control; rats of group III (BM-DMH-PXC) was administered with BM and PXC in DMH induced rats. Rats of group IV were accessible to probiotic Dahi and DMH, and rats of group V were offered both probiotic Dahi and PXC in DMH induced rats. DMH (40 mg/kg body weight) was administered subcutaneously (s.c.) to the rats of corresponding groups at twice a week for 2 weeks [13]. PXC (4 mg/rat or 200 mg/kg of supplements) was given daily orally [14, 15] along with the supplements (milk/probiotic Dahi) and its feeding started one week after the last dose of DMH and continued till termination of experiment. Rats were sacrificed at 8, 16 and 32 weeks of experimental time and colon and liver tissue were analyzed for thiobarbituric acid reactive substances (TARS) and glutathione-S-transferase activity. Faeces were collected by gently squeezing the rectum of rats in self sealer polypacks, immediately kept in ice and processed for β -glucuronidase activity.

Enzymatic assays

The decreased levels glutathione-S-transferase (GST) and β -glucuronidase activities were reported in DMH induced rats. To evaluate, the effects of probiotic and PXC supplement to revert this effect and maintain the normal level of enzymes in DMH induced rats, enzymes like GST and β -glucuronidase activities were determined in requisite samples.

Glutathione-S-transferase (GST) activity

The assay of GST activity was based on that described by Habig *et al* [16]. It was based on an increase in absorbance at 340 nm owing to the formation of thio-diethyl ether (conjugation of substrate with glutathione). The GST activity was calculated using molar extinction coefficient of $9.6 \text{ mM}^{-1} \text{ cm}^{-1}$ and expressed as units/mg protein, where one unit is defined as the amount of enzyme catalyzing the formation of 1 nmole of product per min.

β -glucuronidase activity

β -Glucuronidase activity was determined according to the method of Stossel modified by Perdigon *et al.* [17]. Freshly taken faeces (1g) was homogenized for 1 min with teflon pestle in chilled acetate buffer to a final volume of 30 ml, passed through surgical gauze and sonicated (Branson Sonic, Danburg, USA) for three 1 min burst at 4°C and then centrifuged at 500 xg for 15 min. Reaction mixture contained 0.1 ml of 5 times diluted supernatant from faecal homogenate, 0.15ml of acetate buffer and 0.25ml of pNPG incubated at 37°C for 5 h. The reaction was stopped with 1 ml of 0.1 M NaOH. The absorbance was read at 410 nm and the amount of pNP released determined using standard curve of pNP (1.39 to 11.1 μg). One unit of enzyme activity was defined as one nmoles of pNP liberated/h/g faeces.

Thiobarbituric acid reactive substance content

Lipid peroxidation products in liver and colorectal tissues were estimated as thiobarbituric acid-reactive substances (TBARS) as described by Uchiyama & Mahira [18] using malonyl dialdehyde (MDA) as a

standard. Briefly, the samples treated with thiobarbituric acid containing butylhydroxytoluene (10 mM) and ferrous sulfate (200 mM) were incubated for 15 min in boiling water bath, and the difference in absorbance at 520 and 535 nm was determined. The concentration of MDA determined from the standard curve prepared using 1, 1, 3, 3-tetraethoxypropane and expressed as nmoles of MDA per mg protein.

Histopathological examination of colorectal tissue

Colorectal tissue was collected after the viscera of euthanized animals from all experimental groups. The tissue was fixed in 10% formalin buffer, and was processed and embedded in paraffin following the standard protocols. The processed tissue was sectioned at 5 μm and stained with haematoxylin and eosin, and examined under light microscopy.

Tumor incidence, multiplicity, volume, number and size

The colorectal tissue was cut longitudinally for tumor analysis. The tumor number, location, incidence, multiplicity, size and volume were measured. The tumor volume was calculated by applying the following formula: $v = \pi/6 \times l \times w \times d$, where l = length, w = width and d = depth [19].

Statistical analysis

The results were expressed as mean \pm SE for each group (n=8) and analyzed by One-way analysis of variance (ANOVA) followed by the Tukey post hoc test (SYSTAT version 6.0.1, SPSS Inc, Chicago, IL, USA). Differences were considered significant at $P < 0.05$.

Results

Effect on feed intake on body weight

A significant decline in average feed intake was observed in rats treated with DMH (Table 1). Treatment

of DMH induced rats with either LaLp Dahi or PXC alone or LaLp Dahi adjuvant with PXC, restored feed intake to normal levels and increased body weight significantly ($P < 0.05$).

Effect on tumor incidence, multiplicity, volume, number and size

Table 2 and 3 summarized the data on incidence, multiplicity, volume, number and size of tumors in colorectum which clearly indicate the protective potential of LaLp Dahi and PXC against colorectal carcinogenesis. The proportion of rats that developed tumors in any part of GI tract was 90% in DMH treated control group, which was significantly ($P < 0.5$) reduced to 65%, 60%, 20% and 25% in rats treated with Buffalo milk and piroxicam, LaLp Dahi and LaLp Dahi in combination with PXC, respectively, and the

differences were not statistically significant among groups treated with PXC or LaLp Dahi. The rats treated with PXC in combination with LaLp Dahi registered further decline in tumor incidence. There was no significant difference in tumor multiplicity between DMH treated control group and the groups treated with PXC or LaLp Dahi, however the animals treated with the combinations of PXC and probiotic LaLp Dahi registered significantly lower tumor multiplicity. The average tumor volume per tumor decreased (55% to 59%) significantly ($P < 0.5$) in rats treated with PXC, LaLp Dahi, and the difference among these groups was not statistically significant.

Table 1 Effect of feeding probiotic Dahi and piroxicam (PXC) treatment on feed intake and body weight of dimethylhydrazine (DMH) treated rats

Groups	Body weight (g)							
	Average feed intake (g/d/rat)		Initial		Final		Gain	
	Mean	SEM	Mean	SEM	Mean	SEM	Mean	SEM
BM	17.8 ^a	1.9	22.2 ^a	0.3	325.2 ^a	1.0	303.0 ^a	1.0
BM-DMH	11.4 ^b	2.0	22.8 ^a	0.4	237.0 ^b	3.5	214.3 ^b	3.6
BM-DMH-PXC	16.8 ^a	2.0	23.2 ^a	0.4	304.5 ^c	3.1	281.3 ^c	3.2
LaLp Dahi-DMH	16.2 ^a	1.9	23.1 ^a	0.3	324.9 ^a	1.4	301.8 ^a	1.4
LaLp Dahi-DMH-PXC	17.0 ^a	2.0	23.1 ^a	0.4	343.6 ^d	6.1	320.5 ^d	5.9

BM, Buffalo milk; PXC, piroxicam; DMH, 1,2- dimethylhydrazine Values are mean ± SE for n=20. ^{a,b,c,d} Values within column with different superscript letters are significantly different ($P < 0.05$)

Table 2 Effect of feeding probiotic Dahi and piroxicam (PXC) treatment on tumor incidence and total number of tumors in gastrointestinal tract of rats injected with dimethylhydrazine (DMH)

	Treatment				
	BM	BM-DMH	BM-DMH--PXC	LaLp Dahi-DMH	LaLp Dahi-DMH-PXC
Gastrointestinal tract					
Tumor incidence	0	18 / 20 (90%) ^a	13 / 20 (65%) ^{ab}	12 / 20 (60%) ^b	4 / 20 (20%) ^c
Total tumor number	0	47	26	25	4

	Treatment				
	BM	BM-DMH	BM-DMH--PXC	LaLp Dahi-DMH	LaLp Dahi-DMH-PXC
Colorectum					
Tumor incidence	0	18 / 20 (90%) ^a	13 / 20 (65%) ^{ab}	12 / 20 (60%) ^b	4 / 20 (20%) ^c
Total tumor number	0	31	18	18	4
Caecum					
Tumor incidence	0	9 / 20 (45%)	5 / 20 (25%)	5 / 20 (25%)	0 / 20 (0%)
Total tumor number	0	10	8	7	0
Small Intestine					
Tumor incidence	0	2 / 20 (10%)	0 / 20 (0%)	0 / 20 (0%)	0 / 20 (0%)
Total tumor number	0	3	0	0	0
Stomach					
Tumor incidence	0	2 / 20 (10%)	0 / 20 (0%)	0 / 20 (0%)	0 / 20 (0%)
Total tumor number	0	3	0	0	0

BM, Buffalo milk; PXC, piroxicam; DMH, 1,2- dimethylhydrazine

Tumors number per tumor bearing rat. ; ^{a,b,c,d} Values within row with different superscripts letters are significantly different (P<0.05).

Table 3 Effect of feeding probiotic Dahi and piroxicam (PXC) treatment on tumor multiplicity and average tumor volume in gastrointestinal tract of rats injected with dimethylhydrazine (DMH)

	Treatment									
	BM	BM-DMH	BM-DMH-PXC	LaLp Dahi-DMH	LaLp Dahi-DMH-PXC	BM	BM-DMH	BM-DMH-PXC	LaLp Dahi-DMH	LaLp Dahi-DMH-PXC
	Mean	SEM	Mean	SEM	Mean	SEM	Mean	SEM	Mean	SEM
Gastrointestinal tract										
Tumor multiplicity [#]	0	2.61 ^a	0.47	2.0 ^a	0.16	2.08 ^a	0.27	1.0 ^b	0.0	0.0
Av. tumor volume (mm ³) / tumor	0	86.8 ^a	19.3	35.5 ^b	6.2	37.7 ^b	8.0	3.93 ^c	1.0	1.0
Av. tumor volume (mm ³) / tumor bearing animal	0	226.6 ^a	36.5	71.1 ^b	13.3	78.5 ^b	19.4	3.93 ^c	1.0	1.0
Colorectum										
Tumor multiplicity [#]	0	1.72 ^a	0.24	1.38 ^{ab}	0.13	1.5 ^{ab}	0.16	1.0 ^b	0.10	0.10
Av. tumor volume (mm ³) / tumor	0	27.9 ^a	3.6	20.3 ^{ab}	3.0	16.0 ^b	2.4	3.93 ^c	1.0	1.0
Av. tumor volume (mm ³) / tumor bearing animal	0	48.1 ^a	8.7	28.1 ^{ac}	6.4	24.0 ^{ac}	7.3	3.93 ^b	1.4	1.4
Caecum										
Tumor multiplicity [#]	0	1.11 ^a	0.12	1.6 ^a	0.25	1.4 ^a	0.19	0	0	0
Av. tumor volume (mm ³) / tumor	0	287.4 ^a	56.0	69.84 ^b	12.5	93.5 ^b	11.1	0	0	0
Av. tumor volume (mm ³) / tumor bearing animal	0	318.9 ^a	63.3	73.0 ^b	15.2	131.0 ^c	19.5	0	0	0
Small Intestine										
Tumor multiplicity [#]	0	1.5	0.4	0	0	0	0	0	0	0
Av. tumor volume (mm ³) / tumor	0	65.0	11.7	0	0	0	0	0	0	0
Av. tumor volume (mm ³) / tumor bearing animal	0	97.4	20.7	0	0	0	0	0	0	0

Stomach

Tumor multiplicity [#]	0	1.5	0.5	0	0	0	0	0	0	0
Av. tumor volume (mm ³) / tumor	0	49.2	3.7	0	0	0	0	0	0	0
Av. tumor volume (mm ³) / tumor bearing animal	0	73.9	15.4	0	0	0	0	0	0	0

BM, Buffalo milk; PXC, piroxicam; DMH, 1,2- dimethylhydrazine[#] Tumors number per tumor bearing rat. ^{a,b,c,d} Values within row with different superscripts letters are significantly different (P<0.05). Data for tumor multiplicity and tumor volume were compared by unpaired student t-test and tumor incidence by z test.

In animals treated with PXC in combination with LaLp Dahi, the average tumor volume per tumor decreased by 92-95%. The average tumor volume per tumor bearing animals in DMH treated rats was 227 mm³ which was reduced to 71-79 mm³ in animals treated with PXC and LaLp Dahi. The treatment with PXC in combination with LaLp Dahi resulted in 96 to 98% reduction in average tumor volume per tumor bearing animal.

Colorectum

The effect of treatment with piroxicam or probiotic Dahi or with combination of these two in tumor incidence in colorectum was similar to that in entire GI tract explained as above. The tumor multiplicity in colorectum in animals treated with DMH was 1.7, which decreased by feeding PXC, LaLp Dahi or combination of PXC with probiotic Dahi. The decline in tumor multiplicity could reach to the level statistically significant only in animals treated with combination of PXC and LaLp Dahi. The average tumor volume per tumor and tumor load per tumor bearing animal in DMH treated control group were 27.9

mm³ and 48.1 mm³, respectively, which declined significantly by treatment with LaLp Dahi; and the treatment with combination of PXC and probiotic Dahi was more effective in reducing tumor volume.

Caecum

The caecum was the other major site where tumor appeared in large number as results of treatment with DMH, and the incidence was half of that in colorectum. The tumor incidence in caecum decreased by 22% in rats treated with PXC or LaLp Dahi, and no tumor appeared in caecum in rats treated with PXC in combination with LaLp Dahi. The average tumor volume per tumor or tumor load per tumor bearing rat also decreased significantly by treatment with PXC or probiotic Dahi.

Small intestine and stomach

The incidence of tumor in small intestine and stomach was 10%, and no tumor appeared in this segment of GI tract in rats treated with PXC or probiotic Dahi.

Table 4 Effect of feeding probiotic Dahi and piroxicam (PXC) treatment on glutathione-S-transferase activity and the level of thiobarbituric acid-reactive substances (TBARS) in the liver of rats administered dimethylhydrazine (DMH)

Parameters	Duration Weeks	Treatment									
		BM		BM-DMH		BM-DMH-PXC		LaLp Dahi-DMH		LaLp Dahi-DMH-PXC	
		Mean	SEM	Mean	SEM	Mean	SEM	Mean	SEM	Mean	SEM
GST (mg protein)	0	75 ^A	4	75 ^A	4	75 ^A	4	75 ^A	4	75 ^A	4
	8	118 ^{a,B}	1	60 ^{b,B}	1	80 ^{c,A}	2	99 ^{d,B}	1	103 ^{d,A}	2
	16	225 ^{a,C}	4	107 ^{b,C}	4	125 ^{c,B}	2	126 ^{c,C}	3	203 ^{d,B}	11
	32	271 ^{a,D}	11	187 ^{b,D}	5	205 ^{b,C}	8	257 ^{a,D}	6	511 ^{c,C}	28
TBARS (nmoles/g tissue)	0	11.6 ^A	1.1	11.6 ^A	1.1	11.6 ^A	1.1	11.6 ^A	1.1	11.6 ^A	1.1

Parameters	Duration Weeks	Treatment									
		BM		BM-DMH		BM-DMH-PXC		LaLp Dahi-DMH		LaLp Dahi-DMH-PXC	
		Mean	SEM	Mean	SEM	Mean	SEM	Mean	SEM	Mean	SEM
	8	22.2 ^{aB}	1.1	81.1 ^{bB}	2.0	44.3 ^{cB}	2.3	37.7 ^{dB}	1.7	29.9 ^{eB}	1.6
	16	26.2 ^{aC}	1.2	87.7 ^{bC}	2.6	65.6 ^{cC}	1.7	39.9 ^{dB}	1.9	34.0 ^{eB,C}	1.9
	32	27.7 ^{aC}	1.5	118.9 ^{bD}	1.8	73.3 ^{cD}	2.3	50.5 ^{dC}	2.0	38.4 ^{eC}	2.2

Values are mean ± SE for n=8. BM, Buffalo milk; PXC, piroxicam; DMH, 1,2- dimethylhydrazine; GST, glutathione-S-transferase; TBARS, thiobarbituric acid-reactive substances. *One unit is defined as one nmole of product formed/min. ^{a,b,c,d,e} Values within a row with unlike superscripts letters were significantly different (P<0.05). ^{A,B,C,D} Values in column with unlike superscripts letters are significantly different (P<0.05).

Effect on glutathione-S-transferase activity

Glutathione-S-transferase (GST) activity in liver at different time intervals in normal and in DMH injected rats has been shown in Table 4. The glutathione-S-transferase (GST) activity in liver increased with the age of normal untreated animal reaching at 32 week 10 fold of that at day 0. The treatment with DMH decreased substantially the age related increase in hepatic GST activity. The GST activity in liver decreased in DMH treated animal by 49.2, 52.4, and 31.0% at 8th, 16th and 32nd week, relative to age matched untreated controls. The treatment of animals with PXC or feeding with probiotic Dahi, reversed to some extent the DMH induced decline in GST activity in liver. PXC and probiotic Dahi was

similarly effective in reversing DMH induced decline in GST activity in liver at 8th and 16th week of experimental period. At 32 week, the effect of probiotic Dahi was more pronounced than that of PXC, and GST activity in former groups reached to the levels similar or even above the level in age matched untreated control group. In animals treated with combinations of PXC or probiotic Dahi the increase in GST activity in liver was greater than in animals treated with PXC or probiotic Dahi individually. At 32 week of experimental period, the GST activity in liver was significantly greater in animals fed with probiotic Dahi in combination with PXC than in age matched untreated control. The treatment with LaLp Dahi along with PXC was most effective in enhancing hepatic GST activity.

Table 5 Effect of feeding probiotic Dahi and piroxicam (PXC) treatment on glutathione-S-transferase activity and the level of thiobarbituric acid-reactive substances (TBARS) in the colorectal tissue of rats administered dimethylhydrazine (DMH)

Parameters	Duration Weeks	Treatment									
		BM		BM-DMH		BM-DMH-PXC		LaLp Dahi-DMH		LaLp Dahi-DMH-PXC	
		Mean	SEM	Mean	SEM	Mean	SEM	Mean	SEM	Mean	SEM
GST (units/mg protein)	0	20.1 ^A	1.2	20.1 ^A	1.2	20.1 ^A	1.2	20.1 ^A	1.2	20.1 ^A	1.2
	8	28.1 ^{a,dB}	0.9	20.8 ^{b,A}	0.4	21.3 ^{b,A}	0.5	25.7 ^{d,A}	0.7	35.7 ^{c,B}	1.5
	16	37.3 ^{aC}	1.7	25.6 ^{bB}	1.5	29.1 ^{bB}	2.3	44.2 ^{aB}	2.1	69.0 ^{cC}	4.4
	32	57.2 ^{a,c,D}	2.7	34.8 ^{b,C}	1.5	48.1 ^{a,C}	3.2	62.9 ^{c,C}	3.8	88.4 ^{d,D}	3.6
TBARS (nmoles/g tissue)	0	3.26 ^A	0.33	3.26 ^A	0.33	3.26 ^A	0.33	3.26 ^A	0.33	3.26 ^A	0.33
	8	4.43 ^{aB}	0.33	14.10 ^{bB}	0.33	9.01 ^{cB}	0.35	7.22 ^{dB}	0.35	5.91 ^{eB}	0.23

Parameters	Duration Weeks	Treatment									
		BM		BM-DMH		BM-DMH-PXC		LaLp Dahi-DMH		LaLp Dahi-DMH-PXC	
	16	4.87 ^{a,B}	0.26	21.08 ^{b,C}	0.29	14.77 ^{c,C}	0.28	9.67 ^{d,C}	0.33	7.01 ^{e,C}	0.33
	32	6.58 ^{a,C}	0.26	31.27 ^{b,D}	0.41	22.09 ^{c,D}	0.34	11.34 ^{d,D}	0.37	8.67 ^{e,D}	0.29

Values are mean ± SE for n=8. BM, Buffalo milk; PXC, piroxicam; DMH, 1,2- dimethylhydrazine; GST, glutathione-S-transferase; TBARS, thiobarbituric acid-reactive substances.*One unit is defined as one nmole of product formed/min. ^{a,b,c,d,e} Values within a row with unlike superscripts letters were significantly different (P<0.05). ^{A,B,C,D} Values in column with unlike superscripts letters are significantly different (P<0.05).

Table 6 Effect of feeding probiotic Dahi and piroxicam (PXC) treatment on β-glucuronidase activity in faeces of rats administered dimethylhydrazine (DMH)

Parameters	Duration Weeks	Treatment									
		BM		BM-DMH		BM-DMH-PXC		LaLp Dahi-DMH		LaLp Dahi-DMH-PXC	
		Mean	SEM	Mean	SEM	Mean	SEM	Mean	SEM	Mean	SEM
βglucuronidase*	0	192 ^A	8	192 ^A	8	192 ^A	8	192 ^A	8	192 ^A	8
	8	196 ^{a,A}	5	917 ^{b,B}	69	627 ^{c,B}	7	449 ^{d,e,B}	10	419 ^{d,B}	6
	16	223 ^{a,B}	5	1141 ^{b,C}	68	576 ^{c,C}	23	416 ^{d,C}	5	327 ^{e,C}	4
	32	279 ^{a,d,C}	5	1336 ^{b,D}	69	528 ^{c,D}	14	363 ^{a,D}	10	202 ^{d,D}	9

Values are mean ± SE for n=8. BM, Buffalo milk; PXC, piroxicam; DMH, 1,2- dimethylhydrazine *One unit is defined as one nmoles of pNP liberated/h/mg protein. ^{a,b,c,d,e} Values within a row with unlike superscripts letters were significantly different (P<0.05). ^{A,B,C,D} Values in column with unlike superscripts letters are significantly different (P<0.05).

Table 5 shows the effect of treatment with PXC or feeding probiotic Dahi on GST activity in colorectal tissue. The GST activity in colorectal tissue in normal rats increased with age, and the treatment with DMH significantly reduced the age related rise in GST activity in colorectal tissue. The GST activity at 32 week in DMH treated control was only 73% above the day 0 level compared to 185% above the day 0 level observed in untreated control rats. The treatment with PXC or feeding probiotic Dahi resulted in significant increase in GST activity in colorectal tissue in DMH treated rats. The probiotic Dahi was more effective than PXC in enhancing the GST activity in colorectal tissue. When animals were treated with combination of probiotic Dahi and PXC, the GST activity in colorectal tissue, increased even beyond the levels in age matched untreated normal animals, reaching at 32 week more than 400.0% of that at day 0.

Effect on β-Glucuronidase activity

β-glucuronidase is a bacterial enzyme that hydrolyses many glucuronides, and liberates carcinogenic aglycones in the intestinal lumen. Effect of PXC or probiotic Dahi treatment on the activity of β-glucuronidase in faeces of rats at different time intervals of experimental period has been shown in Table 6. The activity of β-glucuronidase in faeces was increased with age (43.0%) at 32 week above the day 0 level. Treatment of rats with DMH result in increased activity of β-glucuronidase in the faeces by 3.3, 4.9, and 6.0 fold at 8th, 16th and 32nd week, respectively.

The treatment with PXC or feeding probiotic Dahi or combination of these two attenuated the rise in DMH induced β-glucuronidase activity in faeces. The probiotic LaLp Dahi was more effective than PXC in

attenuation of DMH induced rise in β -glucuronidase activity in faeces. The combination of probiotic Dahi and PXC was more efficacious than these two when fed alone, in attenuation of DMH induced rise in β -glucuronidase activity in faeces. Feeding DMH treated rats with LaLp Dahi or combination of probiotic Dahi with PXC brought down the activity of β -glucuronidase in faeces at 32 week of experimental period at level similar to age matched untreated normal animals.

Effect on thiobarbituric acid reactive substances levels

Accumulation of thiobarbituric acid reactive substances (TBARS), represent lipid peroxidation, is considered one of the mechanisms involved in the pathogenesis of inflammation, cancer and atherosclerosis. Depicted in Table 4 are the results of the effect of treatment with PXC or feeding probiotic Dahi or combination of these two on accumulation of TBARS in liver at different time intervals. The accumulation TBARS in liver was increased (139 %) with the age at 32 week above 0 d level. The treatment of animals with DMH increased accumulation of TBARS in liver by 256, 235 and 329 % at 8, 16 and 32 week, respectively, relative to age matched untreated control. The treatment of animals with PXC or feeding with probiotic Dahi significantly attenuated the DMH induced rise in accumulation of TBARS in liver; and the probiotic Dahi was more effective than PXC. Further, greater reduction in TBARS accumulation in liver was observed when probiotic Dahi were fed in combination with PXC. The treatment with PXC in combination with feeding LaLp Dahi was more effective in reducing the accumulation of TBARS in liver.

Table 5 shows the effect of treatment with PXC or feeding probiotic Dahi or combination of the two, on accumulation of TBARS in colorectal tissue of DMH induced rats. Like in liver, the accumulation of TBARS in colorectal tissue increased with age of animal reaching at 32 week at level almost double the level at day 0. The treatment with DMH resulted in 218, 333 and 375% rise in accumulation of TBARS in colorectal tissue at 8, 16 and 32 week, respectively, compared with

age matched untreated controls rats. The treatment with PXC or feeding probiotic Dahi or combination of the two significantly attenuated the DMH induced rise in accumulation of TBARS in colorectal tissue. Probiotic Dahi was more effective than PXC in attenuation of DMH induced accumulation of TBARS in colorectal tissues. When probiotic Dahi were given in combination of PXC, the reduction in TBARS accumulation was more pronounced.

Histopathological examination

Table 7 represents the histological analysis of tumors and distribution into adenoma, adenocarcinoma and carcinoma. In DMH control group, 16.1% tumors were carcinoma which reduced to 5.6% in PXC treated rats, and no carcinoma was seen in probiotic Dahi fed animals. The proportion of adenocarcinoma was also reduced significantly by treatment with PXC. On the other hand, the greater proportion of tumors in rats treated with PXC or probiotic Dahi or combinations of these two were of adenoma type, relative to DMH treated control rats. These results show that PXC treatment attenuated the progression of DMH induced tumors, and the probiotic Dahi improved the efficacy of PXC treatment. In DMH induced animals treated with combination of PXC and LaLp Dahi, all tumors were of adenoma type and did not progress further to adenocarcinoma. Adenoma was defined histologically as lesions in which neoplastic cells were confined to mucosal layer and characterized by benign neoplasm of both solid and surface glandular epithelia which includes non-invasive growth, well defined margins of tumors, localized cell growth, cellular dysplasia, few mitotic figures, and normal to slight increase in ratio of nucleus to cytoplasm. Adenocarcinoma (where neoplastic cells had penetrated the muscularis mucosa to invade the submucosa or deeper layers) was characterized by tumors of glandular epithelium with irregular malignant glands, varying sizes, dark nuclei, multiple layers of cells, lack of mucin producing cells. The carcinoma was characterized by malignant tumor of colonic epithelium with invasive growth, uniform glandular structures, localization of nuclei to the basal half of the neoplastic cells, poorly defined margins of

tumors, failure of cellular differentiation, many mitotic figures, high nuclear to cytoplasmic ratio, loss of polarity of the nuclei, cells vary in shape and size (cellular polymorphism) and nuclear polymorphism.

Table 7 Effect of feeding probiotic Dahi and piroxicam (PXC) treatment on progression of tumors in colorectum in DMH administered rat

Group	Adenoma (%)	Adenocarcinoma (%)	Carcinoma (%)
Buffalo milk	0	0	0
Buffalo milk-DMH	51.6 ^a	32.3 ^a	16.1 ^a
Buffalo milk-DMH-PXC	61.1 ^b	3.3 ^b	5.6 ^b
LaLp Dahi-DMH	77.8 ^c	22.2 ^c	0
LaLp Dahi-DMH-PXC	100.0 ^d	0	0

^{a,b,c,d,e} Values within column with different superscripts letters are significantly different (P<0.05).

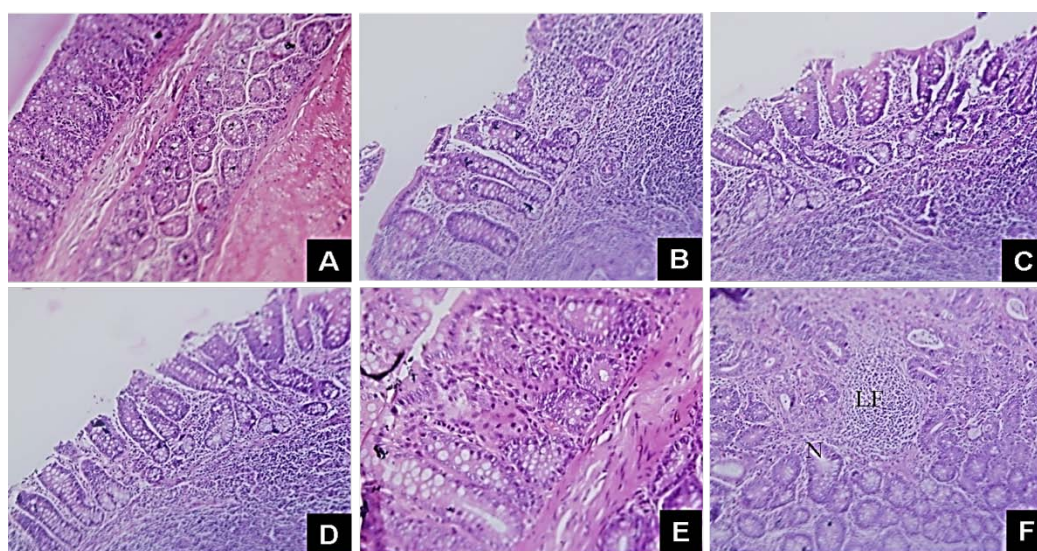


Figure 1 Longitudinal section of colonic mucosa stained with haematoxylin and eosin. (A) Normal looking colonic mucosa (200 X); (B) Colonic mucosa showing crypt disarray, atypical cells lining the surface, narrow or deeper colonic crypts and inflammatory cell infiltration in lamina propria (200 X); (C) Crypts are smaller than normal, variable in shape, crypt loss, inflammatory infiltration, crypts abscess, deep invasion of the submucosal layer and show branching (200 X); (D) There is loss of normal crypt architecture with widening of lamina propria and mild nuclear polymorphism. Submucosa reveals dense lymphomononuclear infiltrate (200 X); (E) Longitudinal section of colonic mucosa stained with haematoxylin and eosin showing architectural distortion of colonic crypts and nuclear pleomorphism (200X). Colonic mucosa showing architectural distortion, dysplasia, colonic microadenoma crypts with focal loss of polarity of lining cells and mild nuclear pleomorphism; (F) Longitudinal section of colonic mucosa stained with haematoxylin and eosin showing severe dysplasia and lymphoid follicle (LF) surrounded by normal crypts (N) (200X). Haphazard arrangement of crypts lining epithelium shows, nuclear stratification, hyperchromasia, loss of polarity, focal crowding and back to back arrangement and inflammatory infiltrate.

Histological sections of normal rats from buffalo milk-fed group displayed normal colonic architecture (Figure 1A); Most of the colonic mucosal sections in DMH treated control rats exhibited the atypical cells lining the surface, nuclear elongation, loss of polarity, mild atypia, narrow and deeper colonic crypts (Figure

1B); crypt loss, inflammatory infiltration, crypts abscess and deep invasion of the submucosal layer by aberrant colonic crypts (Figure 1C); focal loss of polarity of lining cells and mild nuclear polymorphism (Figure 1D); dysplasia and colonic microadenoma (Figure 1E). Dysplasia (loss of arrangement of cells) and hyperplasia

(abnormal multiplication of cells within defined area) were common features in DMH treated groups. Figure 2 (A & B) depicts adenocarcinoma in colon of buffalo milk fed DMH treated rats, showing irregular malignant glands (G), varying in size, dark nuclei, multiple layers of cells, lacking mucin producing cells; hyperchromatic nuclei with high nucleus to cytoplasmic ratio. Figure 2 (C & D) represents the tubulovillous adenoma having stalk covered with normal colonic-type mucosa that contrasts markedly from densely staining dysplastic epithelium of adenoma and Sessile villous adenoma (which is composed of frond-like outgrowths of epithelial cells supported by delicate connective tissue stroma giving a papillary shape) in neoplastic mucosa of buffalo milk fed DMH treated rats. Figure 2 (E & F)

shows a well-differentiated carcinoma of colon in buffalo milk fed DMH treated rats (wherein the neoplasm forms uniform gland structures, and the nuclei are localized to the basal half of the neoplastic cells) and moderately differentiated carcinoma (wherein the neoplasm is composed of complex glandular structures, with loss of polarity of the nuclei). In Figure 3 micrograph showing longitudinal section of colonic mucosa in LaLp Dahi-DMH and LaLp Dahi-DMH-PXC treated rats. (A; 200X & B; 200X) Section showing normal colonic crypt architecture with uniform appearing normal colonic glands stained in LaLp Dahi-DMH treated rat. (C & D; 200X) Section shows normal colonic glands with adequate goblet cell population in LaLp Dahi-DMH treated rats.

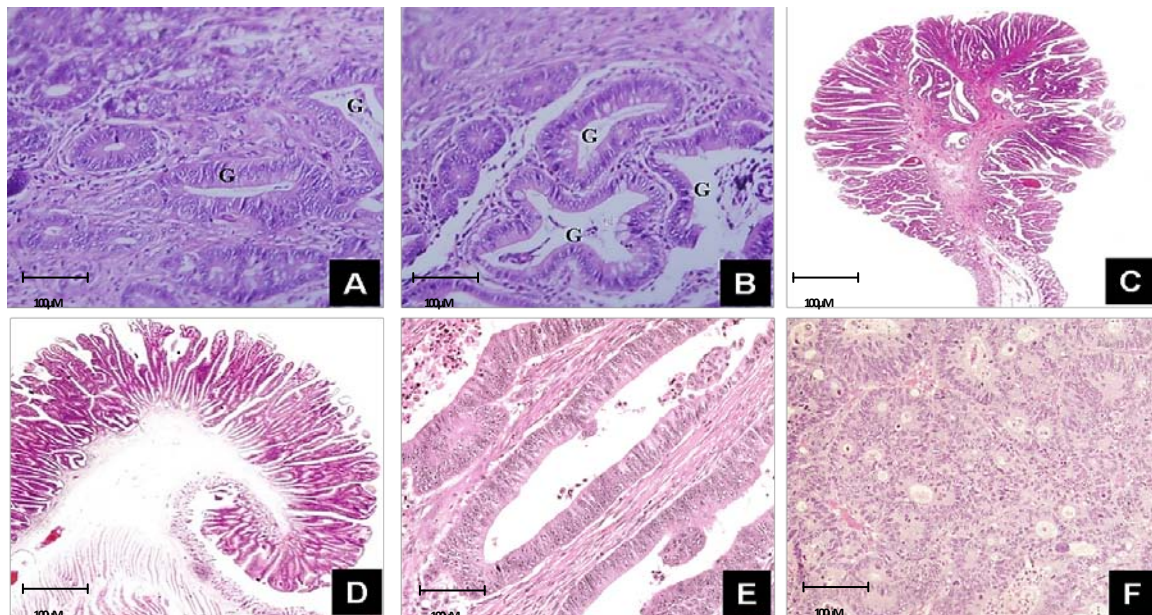


Figure 2 Micrograph showing longitudinal section of neoplastic mucosa in DMH treated rats (A & B) Longitudinal section of colon adenocarcinoma stained with haematoxylin and eosin in DMH treated rats showing malignant glands (G) irregular in shapes, varying sizes, with dark nuclei and loss of normal colonic architecture (200X); (C) A tubulovillous adenoma with stalk covered by normal colonic-type mucosa that contrast markedly with the densely staining dysplastic epithelium of the adenoma (200X); (D) Sessile villous adenoma composed of frond-like outgrowths of epithelial cells supported by a delicate connective tissue stroma giving a papillary shape (200X); (E) Micrograph showing well-differentiated carcinoma of colonic mucosa in DMH treated rats. The neoplasm forms uniform glandular structures, and the nuclei are localized to the basal half of the neoplastic cells (200X). (F) Moderately differentiated carcinoma. The neoplasm is composed of complex glandular structures, with loss of polarity of the nuclei and tumor cells lying singly and in groups (200X).

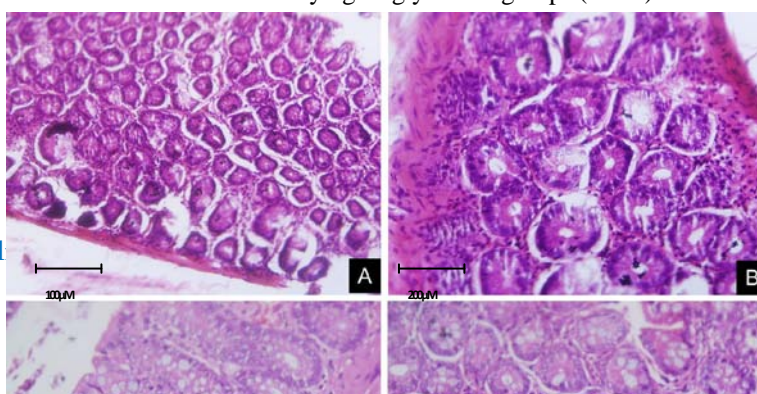


Figure 3 Micrograph showing longitudinal section of colonic mucosa in LaLp Dahi-DMH and LaLp Dahi-DMH-PXC treated rats. (A; 200X & B; 400X) Section showing normal colonic crypt architecture with uniform appearing normal colonic glands stained in LaLp Dahi-DMH treated rat. (C & D; 400X) Section shows normal colonic glands with adequate goblet cell population in LaLp Dahi-DMH treated rats.

Discussion

The present study aims to explore the protective effect of probiotic LaLp Dahi alone as well as in combination with PXC on experimental colorectal damage caused by DMH in rats. In the present study, feeding of probiotic LaLp Dahi alone, as well as in combination with PXC, was profoundly decreased in tumor incidence and lower tumor load as compared to animals received DMH alone; suggesting that probiotic Dahi may have protective effects against DMH induced colorectal carcinogenesis. Furthermore, conjointly administration of PXC with probiotic Dahi registered further abridged in tumor incidence and tumor multiplicity, suggesting for their synergistic effect. These results are in agreement with the protective role of lactic acid bacteria against the development of colon tumours [20, 21].

Probiotic LaLp Dahi significantly ($P < 0.05$) decreased the DMH induced progression of aberrant crypt foci (ACF). Piroxicam (PXC) treatment also decreased the numbers of ACF; and the effect of PXC and probiotic Dahi was additive. The numbers of ACF having multiple aberrant crypts were very few in rats fed probiotic Dahi or treated with PXC or with combination of probiotic Dahi and PXC, while in DMH treated control these increased linearly with time (data not shown). Feeding probiotic Dahi to DMH induced rats decreased significantly ($P < 0.05$) the induction and progression of mucin depleted foci (MDF). The

treatment with PXC also decreased the induction and progression of DMH induced MDF, and the probiotic Dahi improved its efficacy (data not shown). The proliferating cell nuclear antigen (PCNA) index, a marker of carcinogenesis in GI tract, increased progressively in rats challenged with DMH. The treatment with probiotic Dahi or with PXC was equally effective in preventing the rise in PCNA index in DMH treated rats. Further, PXC and probiotic Dahi acted synergistically in preventing the rise in PCNA labelling index (data not shown).

Feeding probiotic Dahi to DMH induced rats inhibited the progression of adenoma to carcinoma, and the significant inhibition ($P < 0.05$) was also observed by treatment with PXC. These results are similar to those observations where administration of probiotics in animals have been reported to prevent carcinogen-induced aberrant crypt foci formation, reduce tumor incidence, tumor volume and tumor multiplicity and increase animal survival rate [22, 23]. The mechanism could possibly involve cellular uptake of carcinogen metabolites by lactic culture cells [24].

Non-lethal and inheritable mutations in cells mediated by the interaction of carcinogen such as DMH with DNA are the initial even in the initiation of cancer. The necessary step for this process is the generation of DMH metabolites such as methyldiazonium ions and carbonium ions, which are active carcinogenic electrophiles enter the intestine primarily via blood system or in small proportion in the bile that manifest

their action in colon [23]. These metabolites are able to methylate the DNA. An increase in O6-methylguanine (O6-MeG) lesions has been shown following treatment with DMH, and this DNA damage was found primarily in the colon [23, 25]. Also, DMH can be metabolized to a methyl free radical or hydrogen peroxide in the presence of metal ion that may contribute to the initiation of lipid peroxidation [26]. Pochart *et al.* suggested that the lactic cultures colonizing the colon, may bind to methylazoxymethanol which is released into the intestinal lumen thereby minimizing its re-absorption into the circulation by physically removing it via faeces [27]. In the present study, it might be possible that the metabolites produced by probiotic Dahi alone or in combination of PXC could be involved in the protective role of probiotic Dahi against colorectal cancer.

GST is one of the important carcinogen detoxifying enzymes located almost in every organ, and present in large amounts in liver [20]. It is the detoxification/biotransformation enzyme involved in the detoxification of toxic substances such as xenobiotics, carcinogens, free radicals and peroxides by conjugating these substances with GSH [10]. In the present study, the GST activity in liver and colorectal tissue increased with age, and the treatment with DMH decreased substantially this age related increase in GST activity. The treatment of animals with PXC or feeding probiotic Dahi, reversed the DMH induced decline in GST activity in liver and colorectal tissue, and the treatment with combined PXC and probiotic Dahi was more effective. Thus, significant ($P < 0.05$) decrease in GST activity in liver and colorectal tissues of tumor-bearing rats may be due to their utilization in detoxification of carcinogenic metabolites of DMH. Similar to our results, the treatment with piroxicam has been reported to elevate the detoxification potential of gastrointestinal tissue by increasing the expression of GST in carcinogen induced rats [28]. A significant reduction ($P < 0.05$) in the activity GST in the DMH-treated group as compared to control and treatment groups (Table 5) could be responsible for the increased levels of TBARS observed during DMH-induced colorectal damage. GST enhances the biotransformation of carcinogens [29]. Induction of enzymes that are involved in the biotransformation of

carcinogens may accelerate the metabolic disposal of carcinogens [30]. Hence, induction of GST by probiotic Dahi or PXC in DMH-treated rats might lead to metabolic disposal of DMH and its metabolites, resulting in the protection of liver as well as colorectal tissues and simultaneous inhibition of colon tumorigenesis.

Our results also suggested that the detoxifying capacity of probiotic Dahi is comparable with that of our reference compound PXC. PXC elevate the detoxification potential of tissues from the gastrointestinal tract and oesophagus, by increasing the expression of GST in carcinogen induced gastrointestinal tumors in male Wistar rats [28]. Recently, the authors laboratory has shown that probiotics down-regulate carcinogen activating cytochrome P450 enzymes CYP1A1, CYP1A2 and CYP1B1 in the liver, upregulate carcinogen detoxifying γ -glutamyltranspeptidase, UDP-glucuronosyl transferase) and quinone reductase in the liver as well as in colon [41].

Several studies have suggested that the intestinal flora influence the process of carcinogenesis by producing enzymes (glycosidase, β -glucuronidase, azo-reductase and nitro-reductase), which transform pre-carcinogens into active carcinogens [28, 31]. β -glucuronidase hydrolyses glucuronides to liberate carcinogenic aglycones in the intestinal lumen. In the present study, feeding rats with PXC or probiotic Dahi diminished the DMH induced rise in β -glucuronidase activity in faeces, and the probiotic LaLp Dahi was more effective than PXC. Combined probiotic Dahi and PXC were more efficacious in attenuation of DMH induced rise in β -glucuronidase activity in faeces. These results are in agreement with earlier reports from our laboratory [32]. These results are similar to earlier studies [33], where oral ingestion of different probiotic strains reduced the bacterial β -glucuronidase, nitroreductase and azoreductase activities in faeces.

The liver inhabits a vital role in the main functions of the organism. It is particularly susceptible to chemically induced damage due to its extensive metabolic capacity and cellular heterogeneity. Lipid peroxidation has been implicated in the pathogenesis of a variety of diseases including cancer [34]. Studies have shown increased

levels of lipid peroxidation in the tumor tissue [34, 35]. In the present study, the accumulation of lipid peroxidation product- TBARS in liver increased with age, and the treatment with DMH resulted in 3-4 fold increase in accumulation of TBARS in liver and colorectal tissue. These findings are in accordance with the increased concentration of malondialdehyde observed in plasma and tissues of colorectal cancer patients [36]. Increased TBARS levels in the liver and colorectum of DMH-treated animals could be due to toxicity caused by DMH. The treatment with PXC or feeding probiotic Dahi significantly attenuated the DMH induced rise in accumulation of TBARS in liver and colorectal tissue. Probiotic LaLp Dahi was more effective than PXC in attenuation of DMH induced rise in TBARS accumulation. Treatment with combined PXC and probiotic Dahi was more efficacious in attenuation of TBARS accumulation. These results are similar to those of Yadav *et al.* who observed that oral ingestion of probiotic Dahi reduced the oxidative stress marker TBARS in rat intestinal tissues [37]. Recent study from our laboratory [32] also showed that probiotic Dahi could act as an antioxidant and can inhibit lipid peroxidation. However, future research may be needed to explore the molecular mechanism underlying the anticarcinogenic potential of probiotic Dahi alone or in combination of PXC to alleviate or reduce the colorectal carcinogenic effects of DMH.

Conclusion

In summary, the present study reveals that probiotic Dahi that is administered individually or in combination with PXC to experimental rats possesses a potent protective effect against DMH-induced colorectal carcinogenesis. These findings suggest that probiotic Dahi could have a therapeutic potential to decrease the risk of colorectal cancer and be used as a potential nutraceutical intervention in prophylaxis and treatment of colorectal cancer. This study also demonstrated that traditionally used dairy-based fermented foods may be successfully used a potential medium for the delivery of probiotics to achieve anticarcinogenic health-benefits to the consumers.

Acknowledgements

The authors wish to acknowledge the research fellowships and necessary facilities provided by University Grant Commission (UGC), Department of Biotechnology (DBT) and Indian Council of Agricultural Research (ICAR), New Delhi, and NDRI, Karnal, India. The generous gift of *L. plantarum* Lp9 strain by Dr. V.K. Batish, Dairy Microbiology Division, NDRI, Karnal, is also duly acknowledged.

References

- Center MM, Jemal A, Smith RA, Ward E. Worldwide variations in colorectal cancer. *CA Cancer J Clin.* 2009, 59:366-378
- Janne PA, Mayer RJ. Chemoprevention of colorectal cancer. *N Engl J Med.* 2000, 342:1960-1968
- Roller M, Pietro Femia A, Caderni G, Rechkemmer G, Watzl B. Intestinal immunity of rats with colon cancer is modulated by oligofructose-enriched inulin combined with lactobacillus rhamnosus and bifidobacterium lactis. *Br J Nutr.* 2004, 92:931-938
- Horie H, Zeisig M, Hirayama K, Midtvedt T, Moller L, Rafter J. Probiotic mixture decreases DNA adduct formation in colonic epithelium induced by the food mutagen 2-amino-9h-pyrido[2,3-b]indole in a human-flora associated mouse model. *Eur J Cancer Prev.* 2003, 12:101-107
- Corpet DE, Tache S. Most effective colon cancer chemopreventive agents in rats: A systematic review of aberrant crypt foci and tumor data, ranked by potency. *Nutr Cancer.* 2002, 43:1-21
- Pollard M, Luckert PH. Effect of piroxicam on primary intestinal tumors induced in rats by n-methylnitrosourea. *Cancer Lett.* 1984, 25:117-121
- Pollard M, Luckert PH, Schmidt MA. The suppressive effect of piroxicam on autochthonous intestinal tumors in the rat. *Cancer Lett.* 1983, 21:57-61
- Reddy BS, Nayini J, Tokumo K, Rigotty J, Zang E, Kelloff G. Chemoprevention of colon carcinogenesis by concurrent administration of piroxicam, a nonsteroidal antiinflammatory drug with

- d,l-alpha-difluoromethylornithine, an ornithine decarboxylase inhibitor, in diet. *Cancer Res.* 1990, 50:2562-2568
9. Pereira MA, Barnes LH, Steele VE, Kelloff GV, Lubet RA. Piroxicam-induced regression of azoxymethane-induced aberrant crypt foci and prevention of colon cancer in rats. *Carcinogenesis.* 1996, 17:373-376
 10. van Lieshout EM, Tiemessen DM, Peters WH, Jansen JB. Effects of nonsteroidal anti-inflammatory drugs on glutathione s-transferases of the rat digestive tract. *Carcinogenesis.* 1997, 18:485-490
 11. Kumar M, Nagpal R, Kumar R, Hemalatha R, Verma V, Kumar A, Chakraborty C, Singh B, Marotta F, Jain S, Yadav H. Cholesterol-lowering probiotics as potential biotherapeutics for metabolic diseases. *Exp Diabetes Res.* 2012, 2012:902917
 12. Kaushal D, Kansal VK. Age-related decline in macrophage and lymphocyte functions in mice and its alleviation by treatment with probiotic dahi containing lactobacillus acidophilus and bifidobacterium bifidum. *J Dairy Res.* 2011, 78:404-411
 13. Rodrigues MA, Silva LA, Salvadori DM, De Camargo JL, Montenegro MR. Aberrant crypt foci and colon cancer: Comparison between a short- and medium-term bioassay for colon carcinogenesis using dimethylhydrazine in wistar rats. *Braz J Med Biol Res.* 2002, 35:351-355
 14. Femia AP, Dolara P, Caderni G. Mucin-depleted foci (mdf) in the colon of rats treated with azoxymethane (aom) are useful biomarkers for colon carcinogenesis. *Carcinogenesis.* 2004, 25:277-281
 15. Wargovich MJ, Jimenez A, McKee K, Steele VE, Velasco M, Woods J, Price R, Gray K, Kelloff GJ. Efficacy of potential chemopreventive agents on rat colon aberrant crypt formation and progression. *Carcinogenesis.* 2000, 21:1149-1155
 16. Habig WH, Pabst MJ, Jakoby WB. Glutathione s-transferases. The first enzymatic step in mercapturic acid formation. *J Biol Chem.* 1974, 249:7130-7139
 17. de Moreno de LeBlanc A, Perdigon G. Reduction of beta-glucuronidase and nitroreductase activity by yoghurt in a murine colon cancer model. *Biocell.* 2005, 29:15-24
 18. Mihara M, Uchiyama M. Determination of malonaldehyde precursor in tissues by thiobarbituric acid test. *Anal Biochem.* 1978, 86:271-278
 19. Rasic JL, Kurmann JA. Bifidobacteria and their role. Microbiological, nutritional-physiological, medical and technological aspects and bibliography. *Experientia Suppl.* 1983, 39:1-295
 20. Kumar A, Singh NK, Sinha PR, Kumar R. Intervention of acidophilus-casei dahi and wheat bran against molecular alteration in colon carcinogenesis. *Mol Biol Rep.* 2009, 37:621-627
 21. Rafter J. The effects of probiotics on colon cancer development. *Nutr Res Rev.* 2004, 17:277-284
 22. Balansky R, Gyosheva B, Ganchev G, Mircheva Z, Minkova S, Georgiev G. Inhibitory effects of freeze-dried milk fermented by selected lactobacillus bulgaricus strains on carcinogenesis induced by 1,2-dimethylhydrazine in rats and by diethylnitrosamine in hamsters. *Cancer Lett.* 1999, 147:125-137
 23. Newell LE, Heddle JA. The potent colon carcinogen, 1,2-dimethylhydrazine induces mutations primarily in the colon. *Mutat Res.* 2004, 564:1-7
 24. Le Leu RK, Hu Y, Brown IL, Woodman RJ, Young GP. Synbiotic intervention of bifidobacterium lactis and resistant starch protects against colorectal cancer development in rats. *Carcinogenesis.* 2009, 31:246-251
 25. Kawanishi S, Yamamoto K. Mechanism of site-specific DNA damage induced by methylhydrazines in the presence of copper(ii) or manganese(iii). *Biochemistry.* 1991, 30:3069-3075
 26. Jackson PE, O'Connor PJ, Cooper DP, Margison GP, Povey AC. Associations between tissue-specific DNA alkylation, DNA repair and cell proliferation in the colon and colon tumour yield in mice treated with 1,2-dimethylhydrazine. *Carcinogenesis.* 2003, 24:527-533
 27. Pochart P, Marteau P, Bouhnik Y, Goderel I, Bourlioux P, Rambaud JC. Survival of bifidobacteria ingested via fermented milk during their passage through the human small intestine: An in vivo study using intestinal perfusion. *Am J Clin Nutr.* 1992, 55:78-80
 28. Kanwar SS, Vaiphei K, Nehru B, Sanyal SN. Antioxidative effects of nonsteroidal anti-inflammatory drugs during the initiation stages of experimental colon

- carcinogenesis in rats. *J Environ Pathol Toxicol Oncol.* 2008, 27:89-100
29. Szarka CE, Pfeiffer GR, Hum ST, Everley LC, Balshem AM, Moore DF, Litwin S, Goosenberg EB, Frucht H, Engstrom PF, et al. Glutathione s-transferase activity and glutathione s-transferase mu expression in subjects with risk for colorectal cancer. *Cancer Res.* 1995, 55:2789-2793
 30. Balasenthil S, Arivazhagan S, Nagini S. Garlic enhances circulatory antioxidants during 7, 12-dimethylbenz[a]anthracene-induced hamster buccal pouch carcinogenesis. *J Ethnopharmacol.* 2000, 72:429-433
 31. Marteau P, Pochart P, Flourie B, Pellier P, Santos L, Desjeux JF, Rambaud JC. Effect of chronic ingestion of a fermented dairy product containing lactobacillus acidophilus and bifidobacterium bifidum on metabolic activities of the colonic flora in humans. *Am J Clin Nutr.* 1990, 52:685-688
 32. Rajpal S, Kansal V. Buffalo milk probiotic dahi containing lactobacillus acidophilus, bifidobacterium bifidum and lactococcus lactis reduces gastrointestinal culture induced by dimethylhydrazine dihydrochloride in rats. *Milchwissenschaft* 2008, 63:122-125
 33. Ling WH, Korpela R, Mykkanen H, Salminen S, Hanninen O. Lactobacillus strain gg supplementation decreases colonic hydrolytic and reductive enzyme activities in healthy female adults. *J Nutr.* 1994, 124:18-23
 34. Goldin BR, Gorbach SL. Effect of lactobacillus acidophilus dietary supplements on 1,2-dimethylhydrazine dihydrochloride-induced intestinal cancer in rats. *J Natl Cancer Inst.* 1980, 64:263-265
 35. Hendrickse CW, Kelly RW, Radley S, Donovan IA, Keighley MR, Neoptolemos JP. Lipid peroxidation and prostaglandins in colorectal cancer. *Br J Surg.* 1994, 81:1219-1223
 36. Skrzydewska E, Stankiewicz A, Michalak K, Sulkowska M, Zalewski B, Piotrowski Z. Antioxidant status and proteolytic-antiproteolytic balance in colorectal cancer. *Folia Histochem Cytobiol.* 2001, 39 Suppl 2:98-99
 37. Yadav H, Jain S, Sinha PR. Oral administration of dahi containing probiotic lactobacillus acidophilus and lactobacillus casei delayed the progression of streptozotocin-induced diabetes in rats. *J Dairy Res.* 2008, 75:189-195