



Case Report



Malignant Transformation of Erosive Oral Mucosal Lichen Planus To Oral Squamous Cell Carcinoma: A Case Report and a Review of the Literature

Saliha Chbicheb, Narjiss Akerzoul*, and Wafaa El Wady

Department Of Oral Surgery, University Mohamed V, Rabat, Morocco

Abstract

Introduction: Oral Mucosal Lichen Planus (OMLP) is a chronic inflammatory skin disease, usually benign that affects all areas of the oral mucosa. Its diagnosis is based on the clinical examination and histological analysis. The erosive form presents a risk of malignant transformation from 0.3% to 3%, justifying the strict surveillance of the disease and effective treatment of relapses.

Case report: This is a 65 years old woman, without specific and non smoking history, reported to the Oral Surgery Department of the Consultation Center of Dental Treatment of Rabat, presenting oral lesions lasting for four years. The intraoral examination revealed the presence of white lesions in the form of plates sitting on the entire right side edge of the tongue. A biopsy was performed and concluded an erosive oral lichen planus which has been transformed to Oral Squamous Cell Carcinoma.

Discussion: Malignant transformation of the OMLP is rare and remains a subject of controversy despite numerous studies that have been devoted. It occurs most often on the atrophic and erosive forms. Several assumptions have been suggested to explain this malignant transformation, but the chronic inflammation seems to be the key factor. Tobacco and alcohol are well known carcinogenic factors, may contribute to the malignant transformation of the OMLP, but it turns out that this disease affects mostly women who have no-smoking Ethylo intoxication. So there must be other factors.

Keywords: Erosive; Oral Mucosal Lichen Planus; Oral Squamous Cell Carcinoma; Malignant transformation

Academic Editor: Xiaoning Peng, Hunan Normal University School of Medicine, China

Received: March 12, 2016; **Accepted:** April 18, 2015; **Published:** May 27, 2016

Competing Interests: The authors have declared that no competing interests exist.

Copyright: 2016 Akerzoul N *et al.* This is an open-access article distributed under the terms of the Creative Commons Attribution License, which permits unrestricted use, distribution, and reproduction in any medium, provided the original author and source are credited.

***Correspondence to:** Narjiss Akerzoul, Department Of Oral Surgery, University Mohamed V, Rabat, Morocco

Email: narjiss.akerzoul87@gmail.com

Introduction

Oral Mucosal lichen planus (OMLP) is a chronic oral inflammatory disease of unknown etiology. According to reports, 1-2% of OMLP patients develop oral squamous cell carcinoma (OSCC) in the long run. While World Health Organization (WHO) classifies OMLP as “a potentially malignant disorder,” it is still a matter of debate which mechanisms drive OMLP to such a condition. The current hypothesis connecting OMLP and OSCC is that chronic inflammation results in crucial DNA damage which over time results in cancer development. Initial studies investigating the OMLP and OSCC link were mainly retrospective clinical studies. Over the past years, several amount of information has accumulated, mainly from molecular studies on the OMLP malignant potential. The present case reports a malignant transformation of an OMLP to an OSCC in a 65 years old woman.

Case report

This is a 65 years old woman, without any specific or smoking history, reported to the Oral Surgery Department of the Consultation Center of Dental Treatment of Rabat, presenting oral lesions evolving for four years. The patient is holding a total maxillary and mandibular bridge since 4 years.

The intraoral clinical examination showed the presence of whitish lesions in the form of plates sitting across the right side edge of the tongue, with the presence of gingival ulceration next to the right premolar-molar sector (Figure1: A+B). A biopsy was performed and concluded an oral mucosal lichen planus (Figure 2).

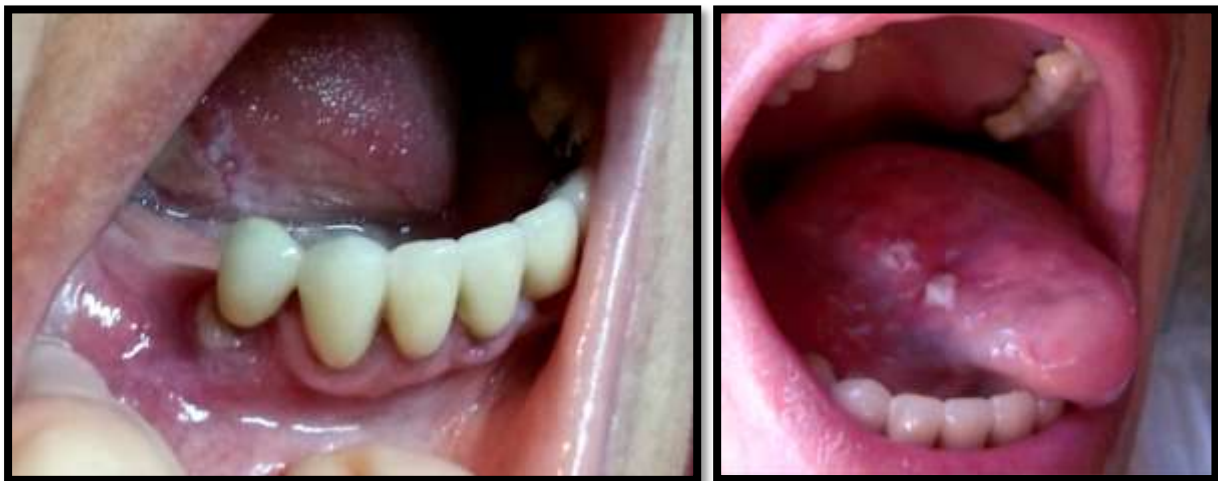

Figure 1 (A)

Figure 1 (B)

Figure 1 (A+B) : Intraoral view showing whitish lesions in the form of plates sitting across the right side edge of the tongue, with the presence of gingival ulceration next to 44.

A first-line treatment associating a local corticosteroid (toprec®) used as a mouthwash and an application of retinoids to 0.1% was prescribed, it led to a regression of the lesions. However recurrence appeared after seven months of treatment. Before this recurrence, immunosuppressive therapy (Prograf® 5%) was introduced over a period of

six months, led once again to the regression of the lesions.

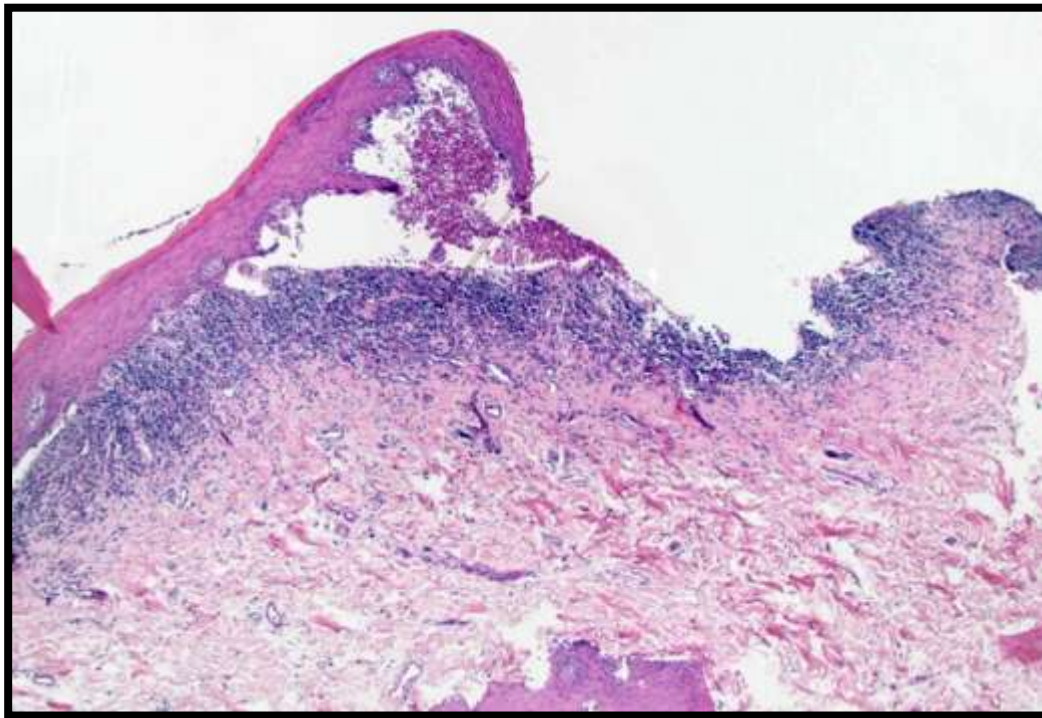


Figure 2 Histological patterns of Erosive Oral Mucosal Lichen Planus of the tongue, after the first biopsy.

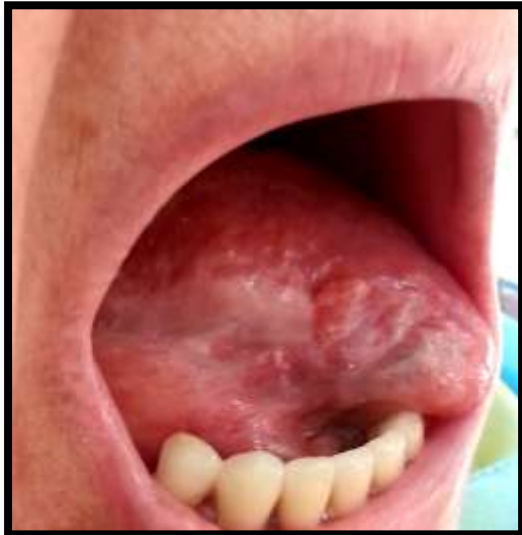

Figure 3 whitish elevations, lesions stand out and have an erosive appearance located on the right side edge of the tongue before the second biopsy, suspecting an Oral Squamous Cell Carcinoma.

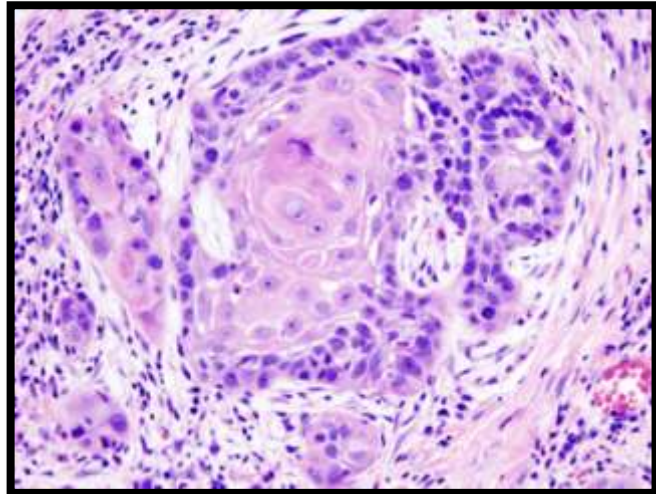


Figure 4 Histopathological features of Oral Squamous Cell Carcinoma located in the lingual region.

Another recurrence was observed after cessation of treatment. Lesions have changed in appearance with the occurrence of whitish elevations, lesions stand out and showed an

erosive appearance (Figure 3). In this situation the patient consulted a dermatologist who suggested a biopsy, but as the patient declined, general and local corticosteroid 6 months was introduced; which did not show any efficiency on the lesions.

The patient consulted again our department. A biopsy was carried out and concluded an invasive oral squamous cell carcinoma (Figure 4).

The patient was referred to the maxillofacial surgery department for an adequate surgical management of the malignant lesion, and was followed up over a period of one month (Figure 5).

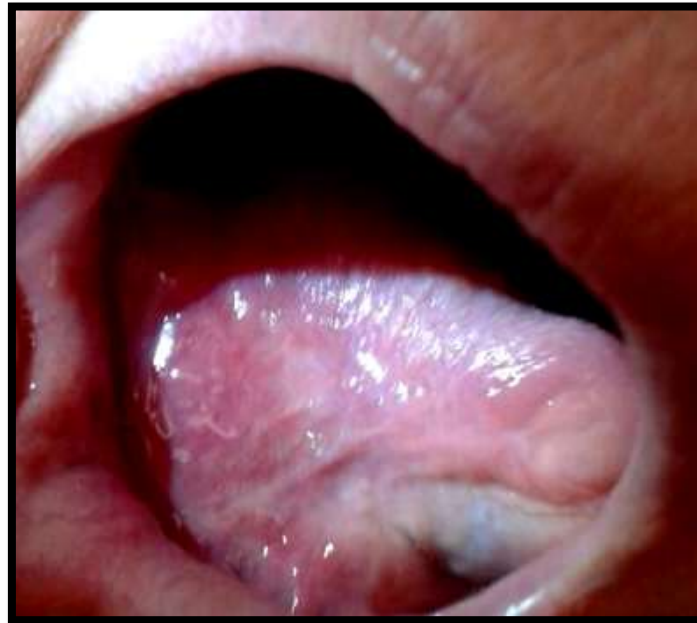

Figure 5 One month Follow-up after Surgery

Discussion

The World Health Organization (WHO) defines oral lichen planus as a potentially malignant lesion, associated with an increase in the risk of oral cancer [1]. As noted, various authors have suggested that OMLP has malignant potential, but other authors have disputed this view [2,3]. In this connection, Krutchkoff et al. in a review of 223 cases, pointed out that only 15 met strict requirements for consideration as cases of malignant transformation of an existing OMLP lesion [4]. More recently, Van Der Meij & al. have published a meta-analytical review of articles dealing with malignant transformation of oral lichen planus [5]. Of the 98 documented cases, the authors found that only 33 (34%) met the criteria of Krutchkoff et al. Of the 65 cases that did not meet these criteria, 20 were inadequately documented as regards histopathology, one as regards clinical characteristics and course, 33 as regards both histopathology and clinical characteristics; in addition, four had been followed up for less than 2 years, and seven patients were smokers [4]. Here we have reported a case in which the patient developed a squamous cell carcinoma in the same location as a lesion evolving 4 years previously as

OMLP. Clinical appearance was an isolated single unilateral lesion, with absence of bilateral lesions in the jugal mucosa. This is not the typical presentation of OMLP; however, the diagnosis was confirmed by the combination of the clinical appearance (Erosive lesion surrounded by raised whitish streaks) and histopathological findings in line with those characteristic of OMLP [5,6].

The patient showed the erosive form of OMLP, which some authors have suggested to be that with highest risk of malignant transformation. Some researchers have suggested that these erosive forms predispose the oral mucosa to the effects of other carcinogenic agents; as far as we know, however, our patient does not have a history of exposure to any major exogenous carcinogen [7-9]. In any case, malignant transformation does not appear to be exclusive to erosive OMLP [10]. Silverman & al. in a study of 214 cases of OMLP followed up on average for 7.5 years, found five of malignant transformation, three affecting erosive lesions, one affecting an atrophic lesion, and one affecting a reticular lesion [11]. Lo Muzio & al. reported 14 cases of squamous cell carcinoma associated with OMLP lesions, which in 12 of the cases were plaque-like [12]. The body-location statistics of OMLP-associated squamous cell carcinomas (SCCs) are of course different from those of SCCs in general. SCCs on the back of the tongue are very infrequent, accounting for less than 5% of all oral carcinomas [13-15]. However, malignant transformation of OMLP in this location is relatively frequent, and some authors have suggested that this location is a significant risk factor. Malignant transformation of OMLP appears to be independent of exogenous risk factors [16-18]. Thus Garcia-Pola et al. reported 4 cases of SCC in the same location as OMLP lesions, but only in one of these cases was the patient a smoker. Similarly, in the present case (in which the OMLP was conclusively diagnosed, and in which we confirmed that the SCC developed in exactly the same location as the OMLP) the patient had no history of exposure to exogenous carcinogens. The present case thus supports the view that OMLP may undergo malignant transformation, and that this does not require exogenous carcinogens [19-22].

Conclusion

Despite the current uncertainty about the probability of malignant transformation of OMLP, the fact that such transformation may occur seems increasingly certain. This argues for a need to perform routine monitoring of some subsets of OMLP patient, including patients with atrophic-erosive lesions on the tongue [20-22].

References

1. Rodriguez-Nunez I, Blanco-Carri A, Garcia-Garcia A, Gandara J. Peripheral T-cell subsets in patients with reticular and atrophic-erosive oral lichen planus. *Oral Surg Oral Med Oral Pathol Oral Radiol Endod.* 2001, 91:180-188
2. Eisenberg E. Oral lichen planus: a benign lesion. *J Oral Maxillofac Surg.* 2000, 58:1278-1285
3. Silverman S. Oral lichen planus: a potentially premalignant lesion. *J Oral Maxillofac Surg.* 2000, 58:1286-1288

4. Krutchkoff DJ, Cutler L, Laskowski S. Oral lichen planus: the evidence regarding potential malignant transformation. *J Oral Pathol*. 1978, 7:1-7
5. Van der Meij EH, Schepman KP, Smeele LE, van der wal JIE, Bezemer PD, van Der Wall I. A review of the recent literature regarding malignant transformation of oral lichen planus. *Oral Surg Oral Med Oral Pathol*. 2007, 88:307-310
6. Lind PO, Koppang HS, Aas E. Malignant transformation of oral lichen planus. *Int J Oral surg*. 2005, 14:509-516
7. Scully C, Carrozzo M. Oral mucosal disease: Lichen planus. *Br J Oral Maxillofac Surg*. 2008, 46:15-21
8. Gorouhi F, Davari P, Fazel N. Cutaneous and mucosal lichen planus: A comprehensive review of clinical subtypes, risk factors, diagnosis, and prognosis. *Scientific World Journal*. 2014, 20:34:742-826
9. Ismail SB, Kumar SK, Zain RB. Oral lichen planus and lichenoid reactions: Etiopathogenesis, diagnosis, management and malignant transformation. *J Oral Sci*. 2015, 49:89-106
10. Fitzpatrick SG, Hirsch SA, Gordon SC. The malignant transformation of oral lichen planus and oral lichenoid lesions: A systematic review. *J Am Dent Assoc*. 2014, 145:45-56
11. Silverman S Jr. Oral lichen planus: A potentially malignant lesion. *J Oral Maxillofac Surg*. 2013, 58:1286-1288
12. Lo Muzio, Jayanthi P, Rao UK, Ranganathan K. Oral lichen planus: An update on pathogenesis and treatment. *J Oral Maxillofac Pathol*. 2013, 15:127-132
13. Edwards PC, Kelsch R. Oral lichen planus: Clinical presentation and management. *J Can Dent Assoc*. 2015, 68:494-499
14. Maraki D, Yalcinkaya S, Pomjanski N, Megahed M, Boecking A, Becker J. Cytologic and DNA-cytometric examination of oral lesions in lichen planus. *J Oral Pathol Med*. 2006, 35: 227-232
15. Driemel O, Kunkel M, Hullmann M, von Eggeling F, Müller-Richter U, Kosmehl H et al. Diagnosis of oral squamous cell carcinoma and its precursor lesions. *JDDG*. 2011, 5: 1095-1100
16. Ingafou M, Leao JC, Porter SR, Scully C. Oral lichen planus: a retrospective study of 690 British patients. *Oral Dis*. 2012, 12: 463-468
17. Scully C, Beyli M, Ferreiro MC, Ficcaro G, Gill Y, Griffiths M et al. Update on oral lichen planus: etiopathogenesis and management. *Crit Rev Oral Biol Med*. 1998, 9: 86-122
18. Horowitz AM, Goodman HS, Yellowitz JA, Nourjah PA. The need for health promotion in oral cancer prevention and early detection. *J Public Health Dent*. 2006, 56: 319-330
19. Sloan P. Oral cancer screening. *Cytopathology*. 2015, 18:12-12
20. Huber MA. A review of premalignant oral conditions. *Tex Dent J*. 2012, 123: 502-509
21. Mattsson U, Jontell M, Holmstrup P. Oral lichen planus and malignant transformation: Is a recall of patients justified? *Crit Rev Oral Biol*. 2012, 13: 390-396
22. Garcia-Pola, Daftary DK, Bhonsle RB, Gupta PC, Mehta FS, Pindborg JJ. Malignant potential of oral lichen planus: observations in 722 patients from India. *J Oral Pathol Med*. 2014, 15: 71-77