

# A rare case of a solitary extramedullary plasmacytoma of the palatine tonsil

Anna Suska<sup>1</sup>, Bogdan Małkowski<sup>2</sup>, Krzysztof Halaszka<sup>3</sup>, Krystyna Gałązka<sup>4</sup>, Maciej R. Czerniuk<sup>5</sup>, Artur Jurczyszyn<sup>1</sup>

<sup>1</sup> Department of Hematology, Jagiellonian University Medical College, Kraków, Poland

<sup>2</sup> Department of Nuclear Medicine, Franciszek Łukaszczyk Oncology Centre, Bydgoszcz, Poland

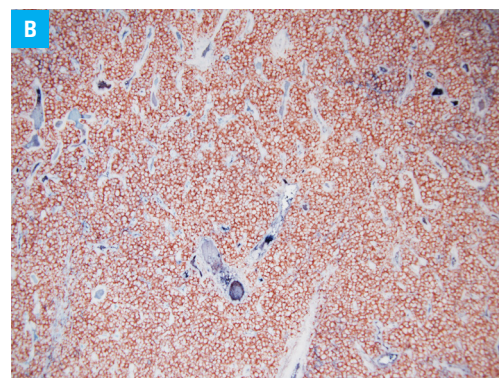
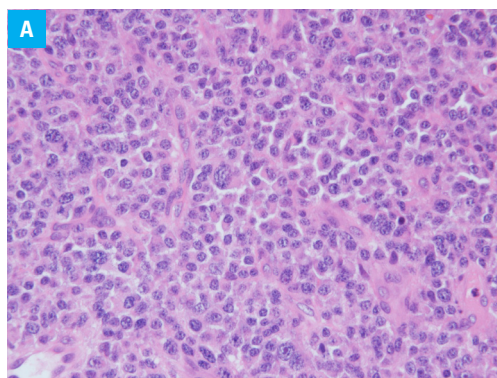
<sup>3</sup> Department of Tumor Pathology, Maria Skłodowska-Curie Institute – Oncology Center, Krakow Branch, Kraków, Poland

<sup>4</sup> Department of Pathomorphology, Jagiellonian University Medical College, Kraków, Poland

<sup>5</sup> Department of Oral Surgery, Medical University of Warsaw, Warsaw, Poland

A 48-year-old man, without a past medical history, was admitted to the emergency department due to a spontaneous bleeding from the pharynx. Coagulation parameters were normal. Dental examination excluded bleeding from periodontal tissue. Ear, nose, and throat examination revealed bleeding from the tumor of the left palatine tonsil. Histopathologic examination of the biopsy specimen showed infiltrate composed of plasma cells (FIGURE 1A). Immunophenotyping demonstrated a positive reaction to CD38, CD56, and CD138 (Supplementary material, *Figures S1–S3*), and  $\kappa$  light-chain restriction (FIGURE 1B). Additionally, a few *c-Myc*-positive cells were observed (FIGURE 1C). The result of Epstein–Barr virus–encoded small RNA in situ hybridization was negative (FIGURE 1D). No monoclonal protein was found on serum protein electrophoresis and immunofixation. No protein was detected on urinalysis.

Radiograms showed no osteolytic lesion. Bone marrow trephine biopsy findings were typical for normal hematopoiesis (FIGURE 1E), with dispersed CD138<sup>+</sup> plasma cells representing 1% of total bone marrow cells, and no light-chain restriction (Supplementary material, *Figures S4–S6*). Magnetic resonance imaging of the head and neck showed an exophytic lesion communicating with the left palatine tonsil, attached tightly to the upper esophageal sphincter and longus colli muscle (FIGURE 1F). A focal increase in <sup>18</sup>F-fluoroethyl-tyrosine (<sup>18</sup>F-FET) uptake in the left palatine tonsil was observed on positron-emission tomography–computed tomography (PET-CT) (FIGURE 1G). Based on those findings, the patient was diagnosed with solitary extramedullary plasmacytoma. Considering the locally advanced neoplastic process, the patient was not considered eligible for tonsillectomy but underwent radiotherapy



**FIGURE 1** A, B – histopathologic analysis of biopsy specimens from the left palatine tonsil tumor: A – infiltrate composed of small and medium-sized cells with plasma cell morphology, eosinophilic cytoplasm and round nuclei with fine-grained chromatin. Some cells show a nuclear polymorphism with larger nuclei and single eosinophilic nucleoli. Hematoxylin and eosin staining, magnification  $\times 400$ ; B – positive immunohistochemical reaction to light  $\kappa$  chains, magnification  $\times 100$

**Correspondence to:**

Artur Jurczyszyn, MD, PhD,  
Department of Hematology,  
Jagiellonian University Medical  
College, ul. Kopernika 17,  
31-501 Kraków, Poland,  
phone: +48 12 424 74 26,  
email: mmjrczy@cyf-kr.edu.pl

Received: November 18, 2018.

Revision accepted:

December 31, 2018.

Published online: January 4, 2019.

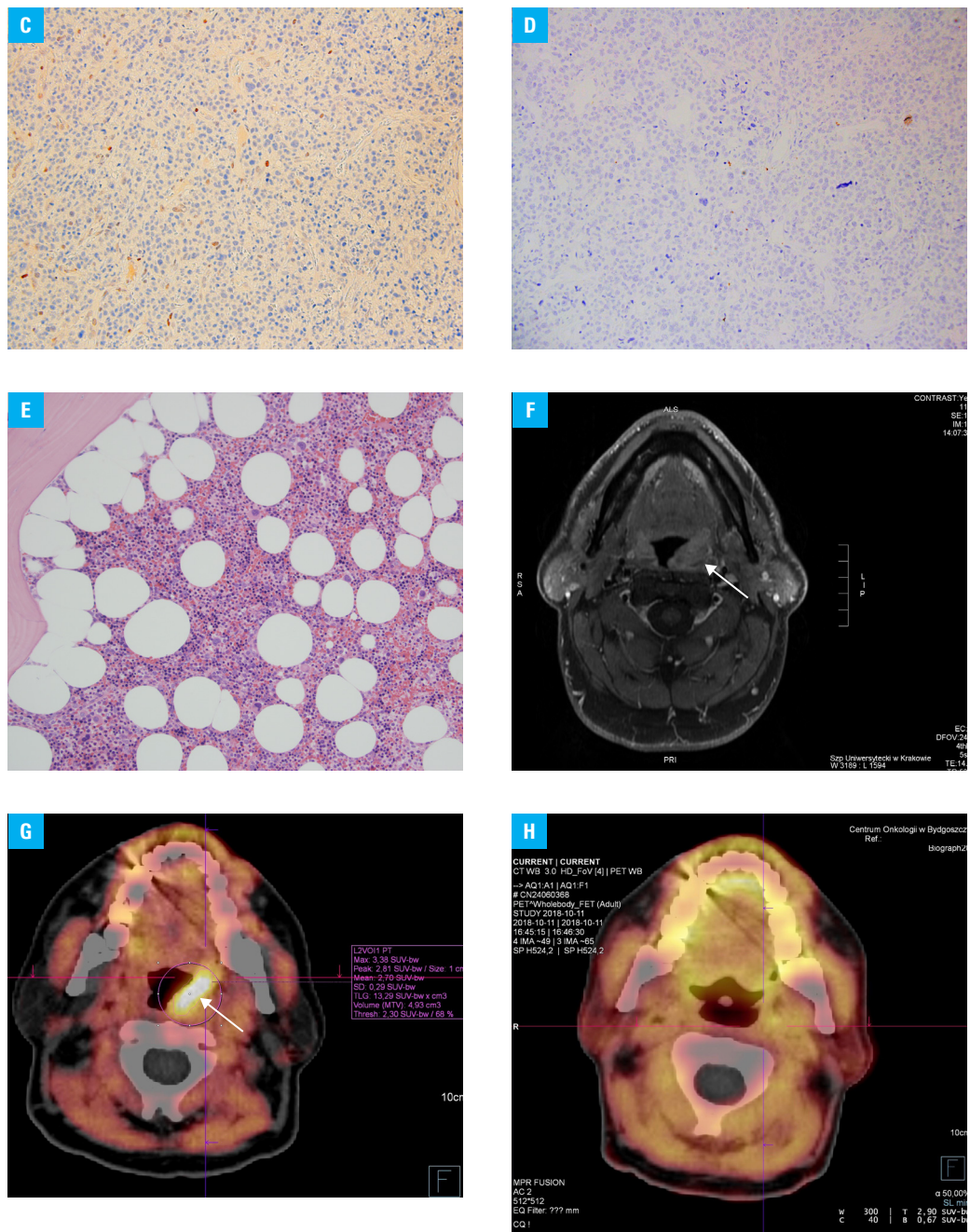
Pol Arch Intern Med. 2019;

129 (3): 201-203

doi:10.20452/pamw.4415

Copyright by Medycyna Praktyczna,

Kraków 2019



**FIGURE 1** C, D – histopathologic analysis of biopsy specimens from the left palatine tonsil tumor: positive immunohistochemical reaction to C-Myc in a few cells (C; magnification  $\times 200$ ); negative Epstein-Barr virus–encoded small RNA in situ hybridization, (D; magnification  $\times 200$ ); E – bone marrow trephine biopsy; findings typical for normal hematopoiesis, without a pathological infiltrate; hematoxylin and eosin staining, magnification  $\times 200$ ; F – magnetic resonance imaging of the head and neck in the axial plane; an exophytic lesion with irregular contours in the left dorsal oropharynx, communicating with the left palatine tonsil, extending downwards the epiglottis, with the largest cross-sectional dimension of 21 mm  $\times$  24 mm at the uvula level, tightly attached to the upper esophageal sphincter and longus colli muscle, without invasion of adjacent structures; moderately restricted diffusion with the postcontrast enhancement (arrow); G, H – fusion positron-emission tomography in the axial plane: G – focal increase in  $^{18}\text{F}$ -fluoroethyl-tyrosine uptake in the left palatine tonsil, extending onto the lateral wall of the throat, with a maximum standardized uptake value of 3.38 (arrow); H – no focal increase in  $^{18}\text{F}$ -fluoroethyl-tyrosine uptake in the left palatine tonsil

with a total dose of 54 Gy in 27 fractions. Currently, 5 months after the radiotherapy, the patient remains without progression. No increase in the standardized uptake value was found on follow-up PET-CT (FIGURE 1H).

Solitary extramedullary plasmacytoma (EMP) is a rare plasma cell tumor involving soft tissues,

with no sign of a systemic disease.<sup>1</sup> EMPs are found primarily in the head and neck region, especially in the sinonasal area; however, any other site can be affected as well.<sup>2</sup> EMPs are more common in men, with a peak incidence in the sixth decade of life.<sup>3</sup> In differential diagnosis, reactive processes, carcinoma, and lymphoma should be

considered. Diagnostic criteria include clonal plasma cell infiltration in the biopsy specimen, lack of clonal plasma cells in trephine biopsy, normal skeletal survey, and no features of end-organ damage.<sup>4</sup> Imaging studies should include magnetic resonance imaging to determine the extent of local disease and PET-CT to exclude systemic involvement.<sup>4</sup> During the latter examination, <sup>18</sup>F-FET should be used as a tracer as it exhibits no uptake in inflammatory cells, which makes it a more specific marker of neoplastic cells than <sup>18</sup>F-fluorodeoxyglucose.<sup>5</sup> Treatment is local. Radiotherapy has been considered a cornerstone, but the essential role of surgical treatment has been also highlighted.<sup>3</sup> Surgery combined with irradiation was shown to be associated with a survival benefit when compared with either surgical treatment or radiotherapy alone. In patients with unresectable tumors, radiotherapy (at least 45 Gy) should be the treatment of choice. Considering the risk of local progression and myeloma relapse, a follow-up is required.<sup>3</sup>

## SUPPLEMENTARY MATERIAL

Supplementary material is available with the article at [www.mp.pl/paim](http://www.mp.pl/paim).

## ARTICLE INFORMATION

**CONFLICT OF INTEREST** None declared.

**OPEN ACCESS** This is an Open Access article distributed under the terms of the Creative Commons Attribution-NonCommercial-ShareAlike 4.0 International License (CC BY-NC-SA 4.0), allowing third parties to copy and redistribute the material in any medium or format and to remix, transform, and build upon the material, provided the original work is properly cited, distributed under the same license, and used for noncommercial purposes only. For commercial use, please contact the journal office at [pamw@mp.pl](mailto:pamw@mp.pl).

**HOW TO CITE** Suska A, Malkowski B, Halaszka K, et al. A rare case of a solitary extramedullary plasmacytoma of the palatine tonsil. *Pol Arch Intern Med.* 2019; 129: 201-203. doi: 10.20452/pamw.4415.

## REFERENCES

- 1 Caers J, Paiva B, Zamagni E, et al. Diagnosis, treatment, and response assessment in solitary plasmacytoma: updated recommendations from a European Expert Panel. *J Hematol Oncol.* 2018; 11: 1-10. [↗](#)
- 2 Suska A, Chmura Ł, Dyduch G, et al. Primary solitary extramedullary plasmacytoma progressing to multiple bone plasmacytomas: a rare condition with therapeutic dilemmas. *Pol Arch Intern Med.* 2018; 128: 706-708. [↗](#)
- 3 Venkatesulu B, Mallick S, Giridhar P, et al. Pattern of care and impact of prognostic factors on the outcome of head and neck extramedullary plasmacytoma: a systematic review and individual patient data analysis of 315 cases. *Eur Arch Oto-Rhino-Laryngology.* 2018; 275: 595-606. [↗](#)
- 4 Rajkumar SV, Dimopoulos MA, Palumbo A, et al. International Myeloma Working Group updated criteria for the diagnosis of multiple myeloma. *Lancet Oncol.* 2017; 15: e538-e548.
- 5 Pauleit D, Zimmermann A, Stoffels G, et al. <sup>18</sup>F-FET PET compared with <sup>18</sup>F-FDG PET and CT in patients with head and neck cancer. *J Nucl Med.* 2006; 47: 256-261.