

Cytomegalovirus gastroenteritis with pyloric stenosis and persistent malabsorption in a patient with common variable immunodeficiency

Paweł Koźlik¹, Joanna Kosałka¹, Krystyna Gałązka², Kinga Paciorek³, Wojciech Sydor¹, Jacek Musiał¹

¹ 2nd Department of Internal Medicine, Jagiellonian University Medical College, Kraków, Poland

² Department of Pathology, Jagiellonian University Medical College, Kraków, Poland

³ Radiology Unit, 2nd Department of Internal Medicine, University Hospital in Krakow, Jagiellonian University Medical College, Kraków, Poland

We present a case of a 69-year-old white woman with a 13-year history of recurrent bacterial infections including sinusitis, pneumonias complicated by left lung abscess, and streptococcal sepsis. A diagnosis of common variable immunodeficiency (CVID) according to European Society for Immunodeficiencies criteria was confirmed in 2011 by serology. Lymphocyte proliferation response to polyclonal mitogens and anti-CD3 antibodies was normal; however, proliferation response to *Candida* antigens and purified protein derivative was diminished. Since regular substitution with intravenous immune globulins (IVIGs) was started, no major bacterial infection occurred.

In the 4th year of treatment, the patient's condition began to deteriorate. In 2015, she

developed stool frequency of up to 10 movements per day and presented with cachexia and ascites. Laboratory tests revealed mild anemia, hypoproteinemia, and elevated activity of liver enzymes. Abdominal computed tomography scans revealed hepatosplenomegaly, portal vein distension, bowel wall thickening, and pyloric stenosis (FIGURE 1A). Endoscopy showed congested esophageal mucosa covered with white-yellow plaques resembling regurgitated gastric content and confirmed infiltration of the duodenum and posterior part of the pylorus. Pathologic examination revealed inflammation of the esophageal and gastric mucosa consistent with cytomegalovirus (CMV) infection (FIGURE 1B) and gastroesophageal reflux disease. *Helicobacter pylori* colonization and candidiasis were excluded. Blood polymerase chain reaction confirmed the presence of CMV DNA paralleled by the positive anti-CMV immunoassays in immunoglobulin G and M classes. Therapy with intravenous ganciclovir for 19 days resulted in a decrease in stool frequency and resolution of ascites.

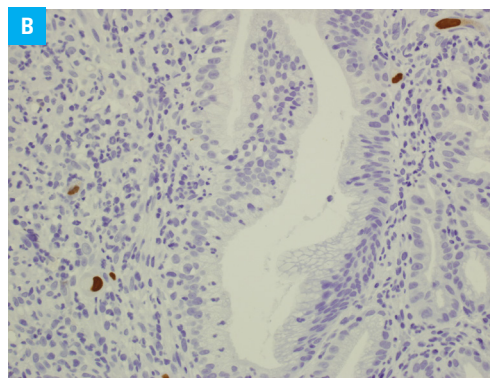
After 2 months of temporary improvement, the patient was readmitted due to signs of pyloric stenosis (vomiting after each meal), confirmed by a follow-up gastroscopic examination, which revealed a rigid and narrow pyloric canal. Histopathology was concordant with earlier findings

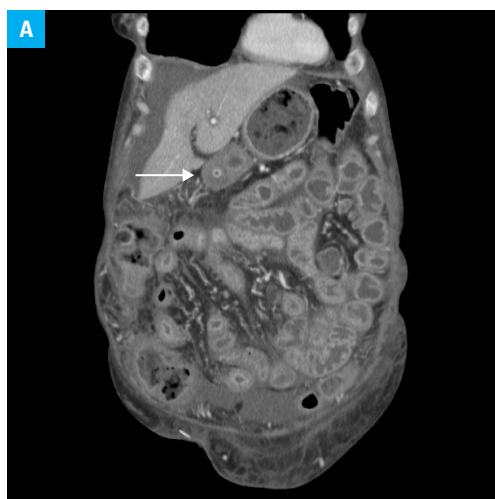

FIGURE 1 A – thickening and contrast enhancement of the alimentary tract mucosa with visible pyloric stenosis (arrow) and free fluid surrounding the liver; gastric retention is visible.

Correspondence to:
Paweł Koźlik, MD, 2nd Department
of Internal Medicine, Jagiellonian
University Medical College,
ul. Skawińska 8, 31-066 Kraków,
Poland, phone: +48 12 430 53 14,
email: pawelkozlik89@gmail.com
Received: September 2, 2018.
Revision accepted: October 22, 2018.
Published online: November 7, 2018.
Conflict of interest: none declared.
Pol Arch Intern Med. 2018;
128 (12): 783-784
doi:10.20452/pamw.4367
Copyright by Medycyna Praktyczna,
Kraków 2018

FIGURE 1 B – positive cytomegalovirus immunohistochemistry in a few scattered cells of the ulcerated gastric mucosa (magnification $\times 40$)



of CMV gastritis. Percutaneous endoscopic gastrostomy–jejunostomy was performed. Despite intensive antiviral treatment and regular IVIG administration, irreversible alimentary tract damage in the course of CMV gastroenteritis resulted in persisting malabsorption, cachexia, and ascites, which required additional parenteral nutritional support.

CVID is the most common primary immunodeficiency, occurring in approximately 1 in 25 000 of the Caucasian population.^{1,2} Cumulative incidence of opportunistic infections in CVID is reported between 5.4% and 9.2%, and *Pneumocystis jirovecii*, varicella zoster virus, *Mycobacterium* species (spp.), *Aspergillus* spp., *Toxoplasma gondii*, and *Candida* spp. are the most common pathogens.³ In contrast, only a few cases of CMV infections in CVID patients have been reported.³⁻⁵ Electron microscopy was described as a superior diagnostic modality, with direct detection of CMV in bronchoalveolar lavage, stool, or tissue samples in patients with negative blood CMV DNA tests.³

The most common clinical presentation of symptomatic CMV disease includes fever, arthralgia, myalgia, and myelosuppression; however, it may also present with evidence of end-organ involvement, such as diarrhea and abdominal pain (gastrointestinal disease), cough and hypoxia (pneumonia), blurred vision or entoptic phenomena (retinitis), or confusion (encephalitis).³ A case series indicated that CMV disease in CVID patients is often underdiagnosed.³ Early diagnosis and implementation of appropriate treatment can lead to good clinical outcome; however, in some cases organ damage is irreversible.

OPEN ACCESS This is an Open Access article distributed under the terms of the Creative Commons AttributionNonCommercialShareAlike 4.0 International License ([CC BY-NC-SA 4.0](https://creativecommons.org/licenses/by-nc-sa/4.0/)), allowing third parties to copy and redistribute the material in any medium or format and to remix, transform, and build upon the material, provided the original work is properly cited, distributed under the same license, and used for non-commercial purposes only. For commercial use, please contact the journal office at pamw@mp.pl.

REFERENCES

- 1 Raeeszadeh M, Kopycinski J, Paston SJ, et al. The T cell response to persistent herpes virus infections in common variable immunodeficiency. *Clin Exp Immunol.* 2006; 146: 234-242. [↗](#)
- 2 Webster ADB. Clinical and immunological spectrum of common variable immunodeficiency (CVID). *Iran J Allergy Asthma Immunol.* 2004; 3: 103-113.
- 3 Kralickova P, Mala E, Vokurkova D, et al. Cytomegalovirus disease in patients with common variable immunodeficiency: Three case reports. *Int Arch Allergy Immunol.* 2014; 163: 69-74. [↗](#)
- 4 Ünal B, Başsorgun Çİ, Çil Gönülcü S, et al. Cytomegalovirus colitis with common variable immunodeficiency and crohn's disease. *Case Rep Med.* 2015; 2015: 348204.
- 5 Medlicott SA, Coderre S, Horne G, et al. Multimodal immunosuppressant therapy in steroid-refractory common variable immunodeficiency sprue: a case report complicating cytomegalovirus infection. *Int J Surg Pathol.* 2006; 14: 101-106. [↗](#)